



This is a digital copy of a book that was preserved for generations on library shelves before it was carefully scanned by Google as part of a project to make the world's books discoverable online.

It has survived long enough for the copyright to expire and the book to enter the public domain. A public domain book is one that was never subject to copyright or whose legal copyright term has expired. Whether a book is in the public domain may vary country to country. Public domain books are our gateways to the past, representing a wealth of history, culture and knowledge that's often difficult to discover.

Marks, notations and other marginalia present in the original volume will appear in this file - a reminder of this book's long journey from the publisher to a library and finally to you.

Usage guidelines

Google is proud to partner with libraries to digitize public domain materials and make them widely accessible. Public domain books belong to the public and we are merely their custodians. Nevertheless, this work is expensive, so in order to keep providing this resource, we have taken steps to prevent abuse by commercial parties, including placing technical restrictions on automated querying.

We also ask that you:

- + *Make non-commercial use of the files* We designed Google Book Search for use by individuals, and we request that you use these files for personal, non-commercial purposes.
- + *Refrain from automated querying* Do not send automated queries of any sort to Google's system: If you are conducting research on machine translation, optical character recognition or other areas where access to a large amount of text is helpful, please contact us. We encourage the use of public domain materials for these purposes and may be able to help.
- + *Maintain attribution* The Google "watermark" you see on each file is essential for informing people about this project and helping them find additional materials through Google Book Search. Please do not remove it.
- + *Keep it legal* Whatever your use, remember that you are responsible for ensuring that what you are doing is legal. Do not assume that just because we believe a book is in the public domain for users in the United States, that the work is also in the public domain for users in other countries. Whether a book is still in copyright varies from country to country, and we can't offer guidance on whether any specific use of any specific book is allowed. Please do not assume that a book's appearance in Google Book Search means it can be used in any manner anywhere in the world. Copyright infringement liability can be quite severe.

About Google Book Search

Google's mission is to organize the world's information and to make it universally accessible and useful. Google Book Search helps readers discover the world's books while helping authors and publishers reach new audiences. You can search through the full text of this book on the web at <http://books.google.com/>



HC 2M6P +

A 8. A. 1911.6

Harvard University

**Library of
The Medical School**




The Gift of


Dr. Wolbach

W. D. Bouneilman











A TEXT-BOOK
OF
PATHOLOGY

With a Final Section on

POST-MORTEM EXAMINATIONS AND THE METHODS OF
PRESERVING AND EXAMINING DISEASED TISSUES

BY

FRANCIS DELAFIELD, M. D., LL. D.

EMERITUS PROFESSOR OF THE PRACTICE OF MEDICINE, COLLEGE OF PHYSICIANS AND SURGEONS,
COLUMBIA UNIVERSITY, NEW YORK

AND


T. MITCHELL PRUDDEN, M. D., LL. D.

EMERITUS PROFESSOR OF PATHOLOGY, COLLEGE OF PHYSICIANS AND SURGEONS, COLUMBIA
UNIVERSITY, NEW YORK

Third Edition

WITH THIRTEEN FULL-PAGE PLATES AND SIX HUNDRED AND EIGHTY-
SEVEN ILLUSTRATIONS IN THE TEXT, IN BLACK AND COLORS

NEW YORK
WILLIAM WOOD AND COMPANY
MDCCCXI



A 8. A. 1911. 6

COPYRIGHT, 1911
By WILLIAM WOOD & COMPANY

*Printed by
The Maple Press
York, Pa.*

PREFACE TO THE NINTH EDITION.

IN this, as in former editions of this work, it is aimed, first, to give to students and practitioners of medicine the knowledge necessary for the making of autopsies, the preservation of tissues and their preparation for microscopic examination; second, to consider the characters of the general processes which underlie the various manifestations of disease; third, to set forth the nature of infection and immunity, and to describe concisely, with such illustrations as seem necessary, the lesions of the acute infectious diseases and, so far as they are known, the microorganisms inciting them, the various phases of degeneration and inflammation, the characters of tumors, and the lesions of the general diseases, of poisoning, and of violent deaths; and, finally, to describe briefly the special lesions of different tissues and organs of the body.

In this edition, the section devoted to general pathology has been rewritten and expanded, and various phases of pathological physiology have received more attention than formerly. Also, in this, still more than in the last editions, stress has been laid upon the relationships of pathology to the allied phases of biological science, and, where it might be done without hazard to the more urgent practical aims of the work, disease has been considered as an adaptive process, and pathology viewed as one aspect of the diverse manifestations of life and energy, rather than as belonging to a special and exclusively human domain.

Dr. Delafeld no longer shares in the preparation of the work: so that the writer, deprived of the wise counsel and large experience of the senior author, is alone responsible for such alterations and additions as have been made in this as in the last three revisions.

The great and rapid accumulation of data in the wide field which this book covers has made necessary the exclusion in large measure of those phases of clinical diagnosis and practical bacteriology which are now more adequately covered in special and in larger treatises. The limitations of the book have made it necessary also to omit the consideration of many suggestive facts and recent alluring speculations bearing upon various aspects of pathological physiology, the significance and value of which are not yet adequately determined.

The book has been largely revised. A few of the older illustrations have been discarded, while over forty new ones have been added.

The references in foot-notes have been revised and considerably increased, the intention in these has been in part to indicate special studies or reviews relating to the theme under consideration; but more particularly to point out here and there publications in which a fuller

bibliography may be found than is consistent with the scope and limitations of this work.

The chapter on the Blood and the Blood-forming Organs and the chapter on Tumors have been rewritten, and the section on Malaria revised, by Professor Francis Carter Wood. My obligation to Professor Wood is very great, not only for the revisions of the text indicated, but for many helpful suggestions embodied throughout the work and for counsel and aid without which the preparation of this edition would have been impracticable.

For assistance in the preparation of material brought forward from the last edition I wish to express my continuing indebtedness to Drs. F. R. Bailey, Edward Leaming, and W. C. Clarke, and to Professors F. C. Wood, Philip Hanson Hiss, John H. Larkin, and Augustus B. Wadsworth.

To Professors Hiss, Wadsworth, Zinnser, and Wright, and to Drs. Flexner, Noguchi, and Terry I am indebted for the privilege of reproducing photographs and for many helpful suggestions.

I wish, finally, to record my appreciation of the skilful service and invaluable cooperation of Miss. S. M. Wood in the final preparation for the press of the material for this edition, in correcting the proof, and in indexing the work.

T. MITCHELL PRUDDEN

CONTENTS.

PART FIRST.

GENERAL PATHOLOGY.

INTRODUCTION, 3.

CHAPTER I.

THE CONDITIONS OF DISEASE, 8.—External conditions of disease, 9.—Internal conditions of disease, 12.

CHAPTER II.

CHANGES IN THE CIRCULATION OF THE BLOOD: General conditions, 15.—Hyperæmia and anæmia, 16.—Hæmorrhage and transudation, 20.—Resorption and absorption, 23.—Thrombosis and embolism, 24.—Experimental study of disturbances of the circulation, 34.

CHAPTER III.

REGRESSIVE TISSUE CHANGES: General considerations, 35.—Atrophy, 36.—Degeneration, 39.—Pigmentation, 53.—Necrosis, 56.

CHAPTER IV.

PROGRESSIVE TISSUE CHANGES: Hypertrophy and hyperplasia, 61.—Metaplasia, 62.—Reversion, 63.—Regeneration, 64.—Modes of cell division, 64.—General characters and limitations of cell regeneration, 68.—Regeneration of special tissues, 69.—Transplantation of tissue, 77.—The impulse to cell regeneration, 79.

CHAPTER V.

INFLAMMATION: General considerations, 81.—Types of inflammatory reaction of the body to injury, 82.—The healing of wounds, 91.—Hyperplasia and interstitial inflammation, 96.—Special phases of inflammation, 97.—The disposal of foreign and dead substances—phagocytosis—autolysis, 98.—Survey of the inflammatory process and its significance, 107.—Characterization of the inflammatory process, 110.—The experimental study of resorption of foreign material, phagocytes, etc., in inflammation, 110.—Practical study of exudative inflammation in the living frog, 111.

CHAPTER VI.

ANIMAL PARASITES: Protozoa, 114.—Worms, 123.—Arthropoda, 132.

CHAPTER VII.

PLANT PARASITES: Bacteria, morphology, physiology, and distribution, 133.—Classification of bacteria, 142.—Modes of morphological study of bacteria, 143.—Artificial cultivation of bacteria, 145.—Collection of material for bacterial cultures, 145.—Yeasts, 146.—Moulds, 147.—Methods of studying yeasts and moulds, 149.

CHAPTER VIII.

THE RELATIONS OF MICRO-ORGANISMS TO DISEASE—INFECTION AND IMMUNITY: The presence of bacteria and other micro-organisms in the body; its protective mechanism, 150.—Action of bacteria and their products in the body, 152.—Proofs of the infective nature of bacteria found in the body, 153.—Conditions influencing the occurrence of infectious diseases, 155.—Infection and immunity; infectious diseases and the nature of infection, 156.—Incubation period, 156.—Forms of infection, 157.—Communicability of infectious diseases, 158.—Immunity; nature and forms of immunity, 160.—Artificial immunization, 162.—Antitoxic immunity, 163.—Ehrlich's "side-chain" hypothesis, 165.—Bactericidal or antibacterial immunity (bacteriolytic immunity), 169.—Cytolytic substances—Cytolysis 171.—Agglutinative substances, 179.—Precipitating substances, 181.—Opsonic substances—opsonins, 183.—Leucocyte extract, 188.—Diversion of complement, 189.—Fixation of complement, 189.—Anaphylaxis, 190.—Technique, 193.—Bibliography, 196.

CHAPTER IX.

THE INFECTIOUS DISEASES: General considerations, 197.—Suppurative and allied forms of inflammation, 198.—The pyogenic bacteria, 205.—Erysipelas, 211.—Infectious pseudo-membranous inflammation of mucous membranes, 212.—Other bacteria which are frequent excitants of suppuration, 213.—Acute lobar pneumonia and other infectious diseases induced by the Diplococcus pneumoniae, 217.—Gonorrhœa and other inflammatory lesions induced by the Micrococcus gonorrhœæ, 221.—Acute cerebro-spinal meningitis, 223.—Glanders, 226.—Anthrax, 228.—Actinomycosis, 230.—Influenza, 223.—Typhoid fever, 234.—Dysentery, 247.—Asiatic cholera, 247.—Tuberculosis, 251.—Lepra, 269.—Syphilis, 270.—Rhinoscleroma, 281.—Diphtheria, 282.—Tetanus, 286.—Malta fever, 287.—Bubonic plague, 288.—Hæmorrhagic septicæmia, 289.—Malignant œdema, 291.—Meat poisoning, 291.—Botulism, 291.—Relapsing fever, 292.—Tick fever, 293.—Vincent's angina, 293.—Yaws, 293.—Hydrophobia, 294.—Acute anterior poliomyelitis, 299.—Typhus fever, 300.—Mexican typhus, 300.—Rocky Mountain spotted fever, 301.—Yellow fever, 302.—Variola, 303.—Scarlet fever, 307.—Trachoma, 308.—Measles, 309.—Malaria, 310.—Whooping-cough, 317.—Beriberi, 318.—Acute rheumatism, 318.—Infectious diseases of unknown origin, 318.—The infectious diseases of animals, 319.—Bibliography of the infectious diseases, 319.

CHAPTER X.

MALFORMATIONS: General considerations, 320.—Malformations involving single individuals, 321.—Normal and pathological conditions in which two or more individuals develop together, 327.

CHAPTER XI.

TUMORS: The nature and characters of tumors in general, 336.—Etiology of tumors, 344.—The intrinsic excitants of tumors; "Biological origin," 350.—The need of new research in tumors, 353.—The transplantation of tumors, 354.—Classification of tumors, 357.—Tumors formed by various combinations of tissue types, 358.—Complex congenital growths, teratoma, 358.—Special tumor types, 359.—Cysts, 359.—Special forms of tumors, 362.—Bibliography of tumors, 416.

CHAPTER XII.

THE LESIONS INDUCED BY POISONS: Forms of poisons, 417.—The lesions induced by exogenous poisons, 417.—Lesions induced by endogenous poisons—auto-intoxications, 426.

CHAPTER XIII.

GENERAL DISEASES, 429.—Cachexia strumipriva, myxœdema, 429.—Exophthalmic goitre, 432.—Addison's disease, 433.—Diabetes mellitus, 434.—Gout, 435.—Sunstroke, 436.—Scorbutus, 437.—Acromegalia, 438.—Purpura, 438.—Lymphatic constitution, 439.—Fever, 440.

CHAPTER XIV.

THE LESIONS IN CERTAIN FORMS OF DEATH FROM VIOLENCE: SUDDEN DEATH; Suffocation; asphyxia, 442.—Death from strangulation; hanging, 443.—Death from drowning, 443.—Sudden death, 446.

PART SECOND.

SPECIAL PATHOLOGY.

GENERAL CONSIDERATIONS, 451.

CHAPTER I.

THE BLOOD AND THE BLOOD-FORMING ORGANS: Changes in the composition and structure of the blood, 452.—The red blood cells, 456.—The white blood cells, 459.—Leucocytosis, 462.—Methods of examination of the blood, 466.—Foreign bodies in the blood, 469.—General diseases involving the blood and blood-forming organs, 471.—Chlorosis, 471.—Secondary anæmia, 472.—Pernicious anæmia, 473.—Leukæmia, 475.—Chloroma, 478.—Pseudo-leukæmia, 479.—Anæmia infantum pseudo-leukæmia, 479.—Splenic anæmia, 479.

CHAPTER II.

THE LYMPH-NODES: General characteristics of the lymph-nodes, 481.—Atrophy, 481.—Edema, 482.—Degeneration, 482.—Pigmentation, 483.—Inflammation, 483.—Hyperplasia of the lymph-nodes, 488.—Pseudo-leukæmia, 489.—Tumors, 497.—Parasites, 497.—Hæmolymp nodes, 497.

CHAPTER III.

THE SPLEEN AND THYMUS: General characteristics of the spleen, 499.—Malformations and displacements, 499.—Wounds, rupture, and hæmorrhage, 500.—Atrophy, 500.—Degeneration, 500.—Pigmentation, 501.—Disturbances of the circulation, 501.—Inflammation, 504.—Chronic endothelial hyperplasia of the spleen, 508.—Alterations of the spleen in leukæmia, and pseudo-leukæmia, 509.—Tumors, 510.—Parasites, 511.—The thymus; malformation and hypertrophy. 511.—Hæmorrhage, 511.—Inflammation, 511.—Tumors, 511.

CHAPTER IV.

THE THYROID AND ADRENALS: The thyroid; malformations, 512.—Degeneration, 512.—Disturbances of circulation, 512.—Inflammation, 512.—Struma, 513.—Tumors, 514.—Parasites, 514.—Parathyroid glands, 514.—The adrenals; malformations, 515.—Atrophy and degeneration, 515.—Thrombosis and hæmorrhage, 516.—Inflammation, 516.—Tumors, 517.—The carotid gland, 517.

CHAPTER V.

THE CIRCULATORY SYSTEM: The pericardium; injuries, 518.—Hæmorrhage, 518.—Hydropericardium, 518.—Pneumopericardium, 518.—Inflammation, 518.—Tumors, 522.—The heart; malformations and malpositions, 522.—Wounds and ruptures, 526.—Atrophy, 528.—Aneurism of the heart and valves, 529.—Thrombosis of the heart, 531.—Degeneration, 533.—Segmentation and fragmentation of the myocardium, 536.—Lesions of the coronary arteries, 537.—Sclerosis and thrombosis, 537.—Inflammation; myocarditis, 538.—Endocarditis, 542.—Stokes-Adams' disease, 549.—Hypertrophy and dilatation of the heart, 550.—Lesions of the heart valves in relation to hypertrophy and dilatation, 552.—Aortic insufficiency and stenosis, 552.—Mitral insufficiency and stenosis, 553.—Insufficiency and stenosis in the right heart, 553.—Summary of conditions leading to hypertrophy of the ventricles, 554.—Dilatation of the heart, 555.—Tumors, 556.—Parasites, 556.—The blood-vessels; hypoplasia, atrophy, and hypertrophy, 556.—The arteries; rupture and wounds, 557.—Degeneration, 557.—Inflammation, 559.—Periarteritis nodosa, 566.—Aneurism, 567.—Aneurisms of the different arteries, 570.—Stenosis and obliteration of the aorta, 571.—Tumors of the arteries, 571.—The veins; dilatation, 572.—Wounds—rupture, 573.—Thrombosis, 573.—Degeneration, 573.—Inflammation, 573.—Tumors, 575.—Parasites, 575.—The capillaries, 575.—The lymph-vessels, general characters, 576.—Lymphangiectasis, 576.—Lymphorrhagia, 576.—Thrombosis, 576.—Inflammation, 577.—Tumors, 577.

CHAPTER VI.

THE RESPIRATORY SYSTEM: The nose and its associated cavities, 579.—Malformations, 579.—Hæmorrhage, 579.—Inflammation, 579.—Tumors, 581.—The pharynx, 581.—The larynx and trachea; malformations, 581.—Hæmorrhage, 582.—Edema of the glottis, 582.—Inflammation, 582.—Tumors, 585.—The bronchi and lungs; the bronchi, hæmorrhage, 586.—Inflammation, 586.—Bronchiectasia, 589.—Tumors, 591.—Lesions of the tracheal and bronchial lymph-nodes, 592.—The lungs; malformations, 593.—Injuries; perforations, 593.—Disturbances of circulation, 593.—Hyperæmia, 593.—Edema of the lungs, 595.—Hæmorrhage and infarctions, 595.—Atelectasis, 596.—Emphysema, 597.—Gangrene, 599.—Inflammation, 600.—Acute lobar pneumonia, 603.—Lobular pneumonia and broncho-pneumonia, 608.—Interstitial pneumonia, 614.—Tuberculous pneumonia,

618.—Focal tuberculosis, 619.—Tuberculous broncho-pneumonia, 624.—Complex forms of nodular and diffuse tuberculous lesions, 627.—Formation of cavities in pulmonary tuberculosis, 628.—Secondary lesions in pulmonary tuberculosis, 629.—Distribution of lesions, 630.—Concurrent infection, 631.—Artificial pulmonary tuberculosis in animals, 631.—Syphilitic pneumonia, 633.—Tumors, 634.—The mediastinum, 636.—The pleura; hydrothorax, 636.—Hydropneumothorax, 637.—Hæmorrhage, 637.—Inflammation, 637.—Tumors, 641.

CHAPTER VII.

THE DIGESTIVE SYSTEM: The mouth; malformations, 643.—Inflammation, 643.—Tumors, 645.—The tongue; malformations, 645.—Hypertrophy and inflammation, 646.—Tumors, 646.—Micro-organisms of the mouth, 646.—The pharynx; malformations, 647.—Inflammation, 648.—Tumors, 650.—The œsophagus; malformations, 651.—Perforation and rupture, 651.—Hæmorrhage, 651.—Dilatation, 651.—Stenosis, 652.—Inflammation, 653.—Tumors, 653.—The stomach, 654.—Malformations, 654.—Cadaveric changes, 655.—Injuries, 655.—Hæmorrhage, 655.—Atrophy and degeneration, 656.—Inflammation, 656.—Ulcers of the stomach, 660.—Dilatation, 662.—Tumors, 662.—Foreign bodies, 667.—The intestines; malformations, 667.—Incarceration, 668.—Intussusception, 669.—Hernia, 670.—Wounds—ruptures, 671.—Disturbances of the circulation—hæmorrhage, 671.—Degeneration, 671.—Inflammation, 672.—The cæcum, 682.—The rectum, 683.—The appendix vermiformis, 684.—Tumors of the intestine, 688.—Intestinal concretions, 690.—Parasites, 691.—Actinomycosis, 691.—The peritoneum; malformations, 691.—Hæmorrhage, 692.—Ascites, 692.—Inflammation, 692.—Tumors, 696.—Cysts, 699.—Parasites, 699.—The salivary glands: Parotid, submaxillary, and sublingual; inflammation, 699.—Tumors of the salivary glands, 700.—The pancreas; malformations and displacements, 701.—Atrophy, degeneration, and necrosis, 702.—Hæmorrhage, 705.—Inflammation, 705.—Tumors, 706.

CHAPTER VIII.

THE LIVER: Malformations, 708.—Wounds, rupture, and hæmorrhage, 708.—Anæmia and hyperæmia, 709.—Lesions of the hepatic vessels, 711.—Atrophy of the liver, 714.—Necrosis, 714.—Degeneration, 716.—Pigmentation of the liver, 721.—Calcification, 722.—Inflammation, 722.—Hyperplasia of lymphatic tissue in the liver, 734.—Tumors of the liver, 734.—Cysts of the liver, 737.—Parasites, 738.—Lesions of the biliary passage and the gall-bladder, 740.—Tumors of the gall-bladder and larger gall-ducts, 743.—Biliary calculi, 743.

CHAPTER IX.

THE URINARY ORGANS: The kidneys; malformations, 746.—Changes in position, 747.—Compensatory hypertrophy of the kidney, 747.—Disturbances of circulation, 748.—Albuminuria and casts, 749.—Necrosis, 750.—Degeneration, 751.—Inflammation, 753.—Suppurative pyelitis and pyelo-nephritis, 771.—Hydronephrosis, 772.—Perinephritic suppuration, 772.—Cysts in the kidneys, 772.—Renal calculi, 774.—Tumors, 776.—Parasites, 781.—The urinary bladder; malformations, 781.—Changes in size and position, 782.—Wounds, rupture, perforation, 782.—Disturbances of circulation, 783.—Inflammation, 783.—Tumors, 786.—Parasites, foreign bodies and calculi, 789.—The urethra; malformations, 790.—Changes in size and position, 790.—Wounds, rupture, perforation, 791.—Inflammation, 791.—Tumors, 792.

CHAPTER X.

THE REPRODUCTIVE ORGANS OF THE FEMALE: The vulva; malformations, 793.—Hæmorrhage, hyperæmia, etc., 793.—Inflammation, 793.—Tumors, 794.—The vagina; malformations, 795.—Changes in size and position, 795.—Wounds; perforations, 796.—Inflammation, 796.—Tumors, 797.—Parasites, 797.—The uterus; congenital malformations, 797.—Changes in size, 798.—Changes in position, 800.—Rupture and perforation, 802.—Hyperæmia; uterine and peri-uterine hæmorrhage, 802.—Atrophy, degeneration, etc., 803.—Inflammation, 804.—Tumors, 809.—Chorionepithelioma of pregnancy, 820.—Chorionepithelioma with teratoma, 822.—Parasites and cysts, 822.—Lesions of the placenta, 822.—Degeneration, 823.—Hæmorrhage, 823.—Inflammation, 823.—Tumors, 824.—The ovaries; malformations, 826.—Changes in size and position, 826.—Hyperæmia and hæmorrhage, 826.—Inflammation, 827.—Tumors, 829.—The Fallopian tubes; malformations, 838.—Changes in position and size, 838.—Hæmorrhage, 839.—Inflammation, 839.—Tumors, 841.—Extra-uterine pregnancy, 841.—The mamma; malformations, 842.—Hæmorrhage, 842.—Inflammation, 843.—Tumors, 847.

CHAPTER XI.

REPRODUCTIVE ORGANS OF THE MALE: The penis; malformations, 853.—Injury and hæmorrhage, 854.—Inflammation, 854.—Tumors, 854.—The scrotum, 855.—Tumors, 855.—The testicles; malformation, 855.—Varicocele, 956.—Hydrocele, 856.—Hæmatocele, 857.—Spermatocoele, 857.—Atrophy, 857.—Inflammation, 857.—Tumors, 860.—Parasites, 863.—The seminal vesicles, 863.—Tumors, 863.—The prostate; degeneration, atrophy, and hypertrophy, 863.—Inflammation, 864.—Tumors, 866.—Parasites and concretions, 866.—Cowper's glands, 867.—The male mamma, 867.

CHAPTER XII.

VOLUNTARY MUSCLE: Necrosis, 868.—Atrophy and hypertrophy, 868.—Degeneration, 871.—Injuries, hæmorrhage, and infarction, 873.—Inflammation, 873.—Tumors, 875.—Parasites, 875.

CHAPTER XIII.

THE BONES AND JOINTS: The bones; general considerations, 876.—Atrophy, 876.—Disturbances of circulation, 877.—Healing of wounds and fractures of bone, 877.—Inflammation, 878.—Necrosis, 889.—Caries, 891.—Rachitis, 891.—Osteomalacia, 896.—Alterations of the bone-marrow in leukæmia and anæmia, 897.—Tumors, 899.—The joints, 903.—Degeneration, 903.—Inflammation, 903.—Tumors, 906.

CHAPTER XIV.

THE NERVOUS SYSTEM: The membranes and the ventricles; the dura mater cerebri, 908.—Hæmorrhage, 908.—Thrombosis, 908.—Inflammation, 909.—Tumors, 911.—The pia mater cerebri; general characters, 912.—Oedema, 913.—Hyperæmia and hæmorrhage, 913.—Inflammation, 914.—Tumors, 919.—Parasites, 921.—The dura mater spinalis, 921.—Hæmorrhage, 922.—Inflammation, 922.—Tumors, 922.—Parasites, 922.—The pia mater spinalis, 922.—Hæmorrhage, 922.—Inflammation, 923.—Tumors, 923.—Parasites, 923.—The ventricles of the brain. The ependyma and choroid plexus; general considerations, 924.—

Inflammation, 924.—Tumors, 927.—Parasites, 927.—The brain and spinal cord; malformations of the brain, 927.—Malformations of the spinal cord, 928.—Injuries of the brain, 930.—Injuries of the cord, 931.—Injuries of the nerves, 931.—Hypertrophy and atrophy of the brain, 931.—Pigmentation of the brain, 933.—Circulatory and vascular changes in the brain and spinal cord, 933.—Hyperæmia and anæmia, 934.—Edema, 934.—Hæmorrhage, 935.—Thrombosis and embolism, 940.—Lesions of the vessel walls, 942.—Degeneration and inflammation in the brain, spinal cord, and nerves, 942.—Degeneration, 946.—Secondary degenerations, 953.—Primary degenerations, 955.—Inflammation, 964.—Lesions of the brain in general paresis of the insane, 972.—Tuberculous lesions in the nervous system, 974.—Syphilitic lesions of the nervous system, 975.—Actinomycosis, 976.—Leptous inflammation, 976.—Tumors, 976.—Parasites, 979.—Holes and cysts in the brain, 979.—Pineal gland, 980.—Hypophysis cerebri, 980.—Methods of preparation of nerve tissue for microscopical study, 980.

PART THIRD.


THE METHOD OF MAKING POST-MORTEM EXAMINATIONS AND THE METHODS OF PRESERVING AND EXAMINING PATHOLOGICAL TISSUES.

CHAPTER I.

THE METHOD OF MAKING POST-MORTEM EXAMINATIONS: General considerations, 985.—External inspection, 986.—Internal examination, 990.—The head, 991.—The spinal cord, 999.—The thorax and abdomen, 1001.—The closure of the body after the post-mortem examination, 1021.—Bacterial examination of post-mortem specimens, 1021.—Autopsies in medico-legal cases, 1022.—Autopsies in cases of suspected poisoning, 1022.—Examination of the bodies of new-born children, 1023.

CHAPTER II.

GENERAL METHODS OF PRESERVING PATHOLOGICAL SPECIMENS AND PREPARING THEM FOR STUDY, 1027.—The study of fresh tissues, 1027.—Rapid fixation and frozen sections, 1028.—Fixation. Hardening and preservation, 1029.—Decalcifying, 1031.—Embedding and section-cutting, 1031.—Methods of staining, 1035.—Methods of preserving specimens for gross demonstration and for museums, 1038.—Kaiserling's method of fixing natural colors in museum specimens, 1039.—The importance of careful fixation and preservation, 1039.



LIST OF ILLUSTRATIONS.

FIG.	PAGE
1. Caisson disease,	12
2. Hyperæmia of the blood-vessels near a bronchus,	17
3. Diagram illustrating the establishment of collateral circulation in obstruction of a vein—after Ribbert,	18
4. Occluding thrombus of the iliac,	24
5. Portion of red thrombus,	25
6. Lamellated thrombus,	26
7. Organized thrombus,	28
8. Embolus lodged at the point of division of an artery,	29
9. Fat emboli in the blood-vessels of the lung,	30
10. Infarcts of the spleen,	30
11. Diagram illustrating the formation of a hæmorrhagic infarct,	31
12. Diagram illustrating the formation of an anæmic infarct,	32
13. Schematic illustration of embolism—after Ribbert,	33
14. Atrophy of muscle,	36
15. Atrophy and distortion of the liver from tight-lacing—female,	37
16. Atrophy of liver cells,	38
17. Albuminous degeneration—kidney,	39
18. Fatty degeneration—kidney,	41
19. Fatty degeneration of epithelium in the kidney,	42
20. Fatty infiltration of the heart,	43
21. Glycogen infiltration of epithelial cells,	44
22. Serous infiltration of epithelial cells,	45
23. Mucous degeneration of epithelial cells,	45
24. "Beaker cells,"	46
25. Mucous degeneration of fibrous tissue of mamma,	46
26. Hyaline degeneration in the walls of small blood-vessels,	48
27. Hyaline degeneration of muscle cells,	48
28. Amyloid degeneration of capillary blood-vessels of a glomerulus of the kidney,	49
29. Corpora amylacea,	50
30. Calcification of epithelial cells of the kidney,	51
31. Calcareous infiltration of the kidney,	52
32. Pigmentation of lungs,	53
33. Hæmatogenous pigment,	54
34. Melanotic pigment,	55
35. Pigmentation of lungs,	55
36. Necrosis of epithelium—kidney,	57
37. Gangrene of foot,	57
38. Coagulation necrosis in cells,	58
39. Coagulation necrosis in tuberculous tissue,	59
40. Cheesy degeneration in tubercle,	59
41. Phases of mitosis,	66

FIG.		PAGE
42.	Abnormal phases of mitosis,	67
43.	Regeneration of striated muscle after injury,	70
44.	Regeneration of epithelium,	71
45.	Regeneration of epithelium,	72
46.	Mitosis in granulation tissue,	73
47.	Regeneration of connective tissue,	74
48.	Developing blood-vessels in new-formed tissue,	75
49.	Regeneration of fat tissue,	77
50.	Healing of a wound of the cornea,	82
51.	Emigration of leucocytes,	84
52.	Exudative inflammation,	85
53.	Fibrin in inflammatory exudate,	86
54.	Fibrin forming around dead cells,	87
55.	Bacterial embolus in the liver,	88
56.	Bacterial embolus in the liver, with necrosis,	89
57.	Necrosis and suppuration in the liver,	90
58.	Granulation tissue,	91
59.	Granulation tissue,	92
60.	Fibroblasts of new connective tissue,	93
61.	Healing wound in the tongue of a dog,	93
62.	Cicatrical tissue,	94
63.	Exuberant granulations,	94
64.	Regeneration of epithelium,	95
65.	Phagocytes,	100
66.	Giant cells,	101
67.	Fragment of sponge in healing wound,	101
68.	Giant cells and new-formed fibrous tissue around a foreign body,	102
69.	Giant cells around foreign bodies,	103
70.	Osteoclasts,	104
71.	Fragments of necrotic muscle,	104
72.	Thoma's frog-plates,	112
73.	<i>Entamoeba histolytica</i> ,	116
74.	<i>Trypanosoma brucei</i> ,	118
75.	<i>Treponema pallidum</i> ,	119
76.	<i>Trichomonas vaginalis</i> ,	120
77.	<i>Balantidium coli</i> ,	120
78.	<i>Coccidium oviforme</i> ,	121
79.	<i>Distoma hepaticum</i> ,	123
80.	Head of <i>Tænia solium</i> ,	124
81.	<i>Tænia mediocanellata</i> . Head and proglottides,	125
82.	Cuticula of echinococcus cyst,	125
83.	Scolices of <i>Tænia echinococcus</i> ,	126
84.	Hooklets from scolex of <i>Tænia echinococcus</i> ,	126
85.	<i>Ascaris lumbricoides</i> ,	127
86.	Eggs of nematode worms,	128
87.	<i>Oxyuris vermicularis</i> ,	128
88.	<i>Trichocephalus dispar</i> ,	129
89.	<i>Trichina spiralis</i> ,	130
90.	<i>Filaria sanguinis hominis</i> ,	131
91.	<i>Sarcoptes hominis</i> ,	132
92.	<i>Pediculus capitis</i> ,	132
93.	Bacteria with flagella,	133

FIG.	PAGE
94. Three typical forms of bacteria,	133
95. Bacteria with capsules,	134
96. Growth aggregates of bacteria,	135
97. Sarcina,	135
98. Bacilli showing spores,	136
99. Cotton swab for collecting fluids containing bacteria,	145
100. Yeast,	146
101. Oidiomycosis cutis,	146
102. Oidium from oidiomycosis cutis,	147
103. <i>Aspergillus glaucus</i> ,	148
104. <i>Achorion Schönleinii</i> —favus,	148
105. Phagocytes,	161
106. Diagram of cell receptors,	166
107. Diagram of toxin molecule,	167
108. Diagram illustrating Ehrlich's hypothesis,	168
109. Diagram illustrating cytolysis,	177
110. Phagocytes, showing effect of opsonic substances,	184
111. Glass capsule,	186
112. Section of a boil—furuncle,	200
113. Pus cells,	201
114. <i>Staphylococcus pyogenes aureus</i> ,	201
115. Focal necrosis in liver,	202
116. Micrococci in exudation of pleurisy,	204
117. <i>Staphylococcus pyogenes aureus</i> ,	205
118. Infective embolus,	206
119. Micrococci in abscess of kidney,	207
120. <i>Streptococcus pyogenes</i> ,	209
121. Hæmolysis,	210
122. Erysipelas of skin,	212
123. Inflammation of trachea,	213
124. <i>Diplococcus pneumoniae</i> ,	218
125. <i>Micrococcus gonorrhoeae</i> in cells,	221
126. <i>Micrococcus gonorrhoeae</i> ,	222
127. <i>Diplococcus intracellularis</i> ,	223
128. Acute endarteritis,	224
129. Endarteritis,	225
130. <i>Bacillus mallei</i> ,	227
131. Anthrax of skin,	228
132. <i>Bacillus anthracis</i> ,	229
133. <i>Bacillus anthracis</i> containing spores,	230
134. <i>Actinomyces</i> in human bronchus,	231
135. <i>Bacillus typhosus</i> ,	235
136. Hyperplasia of Peyer's patches,	236
137. Ulcers of Peyer's patch in typhoid fever,	237
138. Ulcers of Peyer's patch in typhoid fever,	238
139. Endothelial cells in hyperplasia of Peyer's patch,	238
140. Phagocytes in lymph-node in typhoid fever,	239
141. Phagocytic and necrotic cells in lymph-vessel,	240
142. Endothelial cell proliferation in the liver,	241
143. Hyperplasia of the endothelium in the liver,	242
144. Typhoid bacilli in the spleen,	244
145. <i>Spirillum cholerae Asiaticæ</i> ,	249

FIG.	PAGE
146. Small miliary tubercle,	253
147. Miliary tubercle with giant cells,	253
148. Miliary tubercle in the lung,	254
149. Tuberculosis—exudative form,	256
150. Tubercle bacilli in sputum,	257
151. Tubercle-bacillus culture—from man,	258
152. Tubercle-bacillus culture—from bird,	258
153. Lesion of dead tubercle bacilli,	261
154. Lupus of face,	268
155. Bacilli of leprosy,	269
156. Syphilitic inflammation,	270
157. Syphilitic condyloma,	271
158. Syphilitic nodule,	272
159. Syphilitic inflammation,	273
160. Syphilitic gumma—liver,	274
161. <i>Treponema pallidum</i> ,	275
162. <i>Treponema pallidum</i> (India ink stain),	276
163. <i>Treponema pallidum</i> (silver stain),	277
164. Fibrin in diphtheritic membrane,	282
165. Diphtheritic inflammation,	283
166. <i>Bacillus diphtheriæ</i> ,	284
167. <i>Bacillus tetani</i> ,	286
168. <i>Spirochæte Obermeieri</i> ,	292
169. Hydrophobia,	294
170. Negri bodies,	296
171. Smallpox vesicle,	303
172. Trachoma bodies,	308
173. Trachoma bodies,	309
174. Abrachius,	321
175. Facial fissure,	322
176. Double harelip,	322
177. Synophthalmia, agnathia, and synotia,	323
178. Abdominal fissure,	324
179. Craniorrhachischisis,	325
180. Myelomeningocele sacralis,	326
181. Encephalocele,	327
182. Cranioschisis,	328
183. Horseshoe kidney,	329
184. Fœtus, with cord around neck and leg,	330
185. Partial intra-uterine amputation of leg,	331
186. Twins,	332
187. Thoracopagus,	333
188. Thoracopagus—pig,	334
189. Child with acardiac parasite,	335
190. Multiple nodular sarcomata,	339
191. Sarcoma of forearm,	339
192. Polypoid fibroma,	340
193. Tumor-cell embolus,	341
194. Plimmer's bodies,	348
195. Epithelial cell "inclusions,"	349
196. Dermoid cyst of skin,	361
197. Fibroma durum,	362

FIG.	PAGE
198. Fibroma molle,	363
199. Papilloma of skin,	363
200. Mucous polyp of nose,	364
201. Myxoma of larynx,	365
202. Sarcoma—large spindle-celled,	367
203. Sarcoma—spindle-celled,	368
204. Sarcoma—spindle-celled,	369
205. Sarcoma—small round-celled,	369
206. Sarcoma—large round-celled,	369
207. Melano-sarcoma,	370
208. Melano-sarcoma,	370
209. Sarcoma—giant-celled,	371
210. Sarcoma—giant-celled,	371
211. Osteo-sarcoma,	372
212. Epulis,	373
213. Angio-sarcoma,	374
214. Angio-sarcoma,	374
215. Angio-sarcoma,	374
216. Myxo-sarcoma,	375
217. Adeno-sarcoma,	376
218. Endothelioma,	377
219. Endothelioma,	378
220. Endothelioma, psammomatous form,	378
221. Endothelioma, psammomatous form,	379
222. Endothelioma,	380
223. Endothelioma,	381
224. Endothelioma,	382
225. Endothelioma,	383
226. Sacrococcygeal chordoma,	384
227. Endothelioma,	385
228. Lipoma,	386
229. Chondroma,	386
230. Glioma,	387
231. Neuroglia from glioma,	387
232. Myoma uteri,	388
233. Fibro-myoma uteri,	389
234. Neuroma ganglioniforme,	390
235. False neuroma,	391
236. Multiple fibromata,	391
237. Multiple fibromata,	391
238. Angioma telangiectoides,	393
239. Angioma cavernosum,	394
240. Congenital lymphangioma,	394
241. Carcinoma molle,	396
242. Intracanalicular fibro-adenoma,	397
243. Adenoma,	397
244. Fœtal adenoma of thyroid,	398
245. Sebaceous adenoma,	399
246. Adenoma,	400
247. Infiltrating cancer cells,	401
248. Carcinoma cells in lymph-vessel,	401
249. Metastatic carcinoma,	402

FIG.	PAGE
250. Mitosis in carcinoma,	403
251. Metastatic carcinoma,	403
252. Carcinoma of hand,	404
253. Exudative inflammation in carcinoma,	405
254. Epithelioma,	406
255. Epithelioma,	407
256. Epithelioma,	408
257. Epithelioma,	409
258. Epithelioma,	409
259. Congenital nævus,	410
260. Epithelioma, basal-celled,	411
261. Small epithelioma of face,	412
262. Small superficial epithelioma of face,	412
263. Epithelioma, giant cells,	413
264. Epithelioma, giant-celled,	413
265. Carcinoma,	414
266. Carcinoma durum,	414
267. Carcinoma gelatinosum,	415
268. Carcinoma myxomatodes,	415
269. Adamantinoma,	416
270. Myxœdema,	430
271. Cretin,	431
272. Thyroid gland in myxœdema,	432
273. Lesions of gout,	436
274. Hyperplasia of lymphoid tissue,	439
275. Enlarged thymus,	445
276. Enlarged thymus,	446
277. Suffocation from lodgment of meat in larynx,	447
278. Megakaryocytes,	465
279. Megakaryocytes,	466
280. Bone marrow,	472
281. Leukæmic infiltration of kidney	476
282. Liver in lymphatic leukæmia,	477
283. Œdema of lymph-node,	482
284. Pigmentation of lymph-node,	483
285. Hyperplastic inflammation of lymph-node,	484
286. Endothelial cells in hyperplasia of lymph-nodes,	485
287. Hyperplasia of Peyer's patch,	485
288. Chronic inflammation of lymph-node,	486
289. Lymph-node in lymphatic leukæmia,	490
290. Bone marrow in Hodgkin's disease,	491
291. Hodgkin's disease,	492
292. Hodgkin's disease,	493
293. Hodgkin's disease,	493
294. Hodgkin's disease,	494
295. Hodgkin's disease,	495
296. Hodgkin's disease,	496
297. Hodgkin's disease,	496
298. Amyloid degeneration of spleen,	501
299. Hyperæmia of spleen,	502
300. Infarction of spleen,	503
301. Chronic indurative splenitis,	505

FIG.	PAGE
302. Chronic interstitial splenitis,	506
303. Malarial spleen,	506
304. Tuberculosis of spleen,	507
305. Hyperplasia of spleen,	508
306. Hodgkin's disease,	509
307. Lymphatic leukæmia,	510
308. Colloid struma,	513
309. Fatty degeneration in adrenal,	515
310. Hæmorrhage into adrenal,	516
311. Fibrinous pericarditis,	519
312. Adhesions of pericardium,	520
313. Obliteration of pericardial sac,	521
314. Tuberculous pericarditis,	522
315. Reptilian heart,	523
316. Stenosis of pulmonary artery,	524
317. Interventricular foramen,	525
318. Fenestration of semilunar valves,	526
319. Abnormal chordæ tendineæ,	527
320. Rupture of heart,	528
321. Atrophic pericardial fat tissue,	529
322. Aneurism of heart,	530
323. Polypoid thrombus in auricle,	531
324. Globular thrombus in ventricle,	532
325. Globular thrombus in auricle,	533
326. Thrombi among heart trabeculæ,	534
327. Thrombus on edge of mitral valve,	535
328. Fatty degeneration of heart muscle,	535
329. Fatty infiltration of heart,	536
330. Bacterial embolus in heart muscle,	539
331. Chronic interstitial myocarditis,	540
332. Chronic interstitial myocarditis,	540
333. Chronic interstitial myocarditis,	541
334. Ulcerative endocarditis,	542
335. Bacteria in vegetation of heart valve,	543
336. Chronic endocarditis,	544
337. Chronic endocarditis,	545
338. Vegetation on aortic valve,	546
339. Chronic endocarditis,	546
340. Verrucous endocarditis,	547
341. Stenosis of aortic valves,	548
342. Chronic endocarditis with calcification of valves,	549
343. Hypertrophy of heart,	551
344. Transverse rupture of aorta,	558
345. Chronic arteritis,	560
346. Chronic arteritis,	560
347. Obliterating endarteritis,	560
348. Connective tissue in intima,	561
349. Chronic arteritis,	561
350. Atrophy of elastic tissue in wall of aorta,	562
351. Atheroma of aorta,	562
352. Chronic inflammation of aorta,	563
353. Chronic arteritis,	563

FIG.		PAGE
354.	Tuberculous arteritis,	566
355.	Aneurism of arch of aorta,	568
356.	Aneurism of popliteal artery,	569
357.	Tuberculous phlebitis,	574
358.	Catarrhal inflammation,	579
359.	Mucous polyp. of nose,	580
360.	Mucous polyp. of nose,	581
361.	Hyperplasia of epithelium of false vocal cords,	583
362.	Diphtheria of larynx and trachea,	584
363.	Tuberculous laryngitis,	585
364.	Papilloma of larynx,	586
365.	Acute catarrhal bronchitis,	587
366.	Chronic bronchitis,	588
367.	Chronic fibrinous bronchitis,	589
368.	Multiple bronchiectasiae,	590
369.	Adenoma of bronchi,	591
370.	Lung stones,	591
371.	Tuberculous lymph-nodes,	592
372.	Chronic congestion of lung,	594
373.	Vesicular emphysema,	597
374.	Interlobular emphysema of lung,	598
375.	Interstitial emphysema of lung,	599
376.	Lung showing tubercles with pigmentation in pleura,	602
377.	Acute lobar pneumonia,	604
378.	Acute lobar pneumonia,	604
379.	Acute lobar pneumonia,	605
380.	Exudate from lung,	606
381.	"Organizing" pneumonia,	608
382.	Broncho-pneumonia,	609
383.	Broncho-pneumonia,	610
384.	Broncho-pneumonia,	610
385.	Broncho-pneumonia,	611
386.	Broncho-pneumonia, chronic,	612
387.	Air vesicle in broncho-pneumonia with streptococci,	613
388.	Interstitial pneumonia,	614
389.	Chronic interstitial pneumonia,	615
390.	Anthracotic pigmentation of lung,	616
391.	Anthracosis of lung,	617
392.	Miliary tubercle of lung,	620
393.	Miliary tubercle of lung,	621
394.	Miliary tubercle of lung,	622
395.	"Healed tubercle" of lung,	623
396.	"Healed tubercle" of lung,	623
397.	Tuberculous inflammation of lung,	624
398.	Tuberculous broncho-pneumonia,	625
399.	Tuberculous broncho-pneumonia,	625
400.	Tuberculous broncho-pneumonia,	626
401.	Acute pulmonary tuberculosis,	628
402.	Chronic pulmonary tuberculosis,	629
403.	Experimental tuberculosis—rabbit,	632
404.	Experimental tuberculosis—rabbit,	632
405.	Experimental tuberculosis—rabbit,	633

FIG.		PAGE
406.	Secondary carcinoma of lung,	634
407.	Endothelioma of pleura,	635
408.	Endothelioma of pleura,	635
409.	Endothelioma of lung,	641
410.	Wall of branchial cyst,	647
411.	Wall of branchial cyst,	648
412.	"Adenoid" polyp of pharynx,	650
413.	Carcinoma of œsophagus,	654
414.	Degeneration of gastric epithelium in phosphorus poisoning,	656
415.	Acute catarrhal gastritis,	657
416.	Chronic gastritis,	657
417.	Chronic gastritis,	658
418.	Chronic gastritis,	658
419.	Ulcer of stomach,	660
420.	Perforating ulcer of stomach,	661
421.	Papillary adenoma of stomach,	663
422.	Carcinoma of stomach,	664
423.	Gelatinous carcinoma of stomach,	665
424.	Hair-balls from human stomach,	666
425.	Diverticulum of small intestine,	667
426.	Multiple false diverticula of intestine,	668
427.	Intussusception,	669
428.	Intussusception,	669
429.	Inguinal hernia—intestinal,	670
430.	Inguinal hernia—omental,	670
431.	Acute catarrhal enteritis,	672
432.	Nodular enteritis,	673
433.	Tuberculous ulcers of intestine,	673
434.	Tuberculous ulcer of intestine,	674
435.	Subserous tubercles,	674
436.	Tuberculous ulcers in intestine,	675
437.	Acute catarrhal colitis,	676
438.	Amœbic colitis,	677
439.	Nodular colitis,	678
440.	Nodular colitis with ulceration,	678
441.	Nodular colitis,	679
442.	Croupous colitis,	679
443.	Necrotic colitis,	680
444.	Chronic ulcerative colitis,	681
445.	Chronic colitis with ulceration,	682
446.	Hæmorrhoids,	684
447.	Acute appendicitis,	685
448.	Acute suppurative appendicitis,	686
449.	Chronic appendicitis,	687
450.	Obliteration of lumen and appendix,	687
451.	Small polyp of mucous membrane of small intestine,	688
452.	"Lymphomata" of intestine in Hodgkin's disease,	689
453.	Adenoma of rectum,	689
454.	Adenoma of rectum,	690
455.	Acute cellular peritonitis,	693
456.	Peritoneal adhesions between liver and intestine,	695
457.	Miliary tubercles of omentum,	696

FIG.	PAGE
458. Papillary fibroma of peritoneum,	697
459. Cystic papilloma of omentum,	698
460. Endothelioma of parotid,	701
461. Fatty infiltration of pancreas,	702
462. Fat necrosis in mesentery,	703
463. Fat necrosis in pancreas,	704
464. "Nutmeg liver,"	709
465. Chronic congestion of liver,	710
466. Chronic congestion of liver,	711
467. Infarction of liver,	713
468. Acute yellow atrophy of liver,	717
469. Fatty infiltration of liver,	718
470. Fatty infiltration of liver cells,	719
471. Fatty degeneration of liver cells,	719
472. Amyloid degeneration of liver capillaries,	720
473. Malarial pigmentation of liver,	721
474. Abscesses in liver containing bacilli,	723
475. Chronic interstitial hepatitis,	724
476. Chronic interstitial hepatitis,	725
477. Chronic interstitial hepatitis,	726
478. New formed gall-ducts in cirrhosis,	727
479. Hypertrophic cirrhosis of liver,	729
480. Gumma of liver,	731
481. Syphilitic hepatitis,	732
482. Miliary tubercle of liver,	733
483. Cavernous angioma of liver,	735
484. Secondary carcinoma of liver,	736
485. "Foamy liver,"	738
486. Echinococcus multilocularis of liver,	739
487. Cholangitis,	740
488. Cholangitis,	741
489. Adenoma of gall-duct,	742
490. Biliary calculi,	744
491. Horseshoe kidney,	746
492. Foetal lobulation of kidneys in adult,	747
493. Hyaline globules in uriniferous tubule,	749
494. Hyaline casts in uriniferous tubule,	750
495. Albuminous degeneration of kidney,	751
496. Fatty degeneration of epithelium in kidney,	752
497. Amyloid degeneration of capillaries in kidney,	752
498. Glycogen degeneration of epithelium in kidney,	753
499. Suppurative nephritis,	755
500. Acute diffuse nephritis,	756
501. Acute diffuse nephritis,	757
502. Acute diffuse nephritis,	758
503. Acute diffuse nephritis,	759
504. Diffuse nephritis,	760
505. Atrophied glomerulus of kidney,	761
506. Chronic diffuse nephritis,	763
507. Chronic diffuse nephritis,	764
508. Chronic diffuse nephritis,	765
509. Chronic diffuse nephritis,	766

FIG	PAGE
510. Chronic diffuse nephritis,	767
511. Chronic diffuse nephritis,	768
512. Chronic obliterating endarteritis in nephritis,	769
513. Tuberculous nephritis,	770
514. Chronic pyelo-nephritis,	771
515. Hydronephrosis,	773
516. Congenital cystic kidney,	774
517. Cyst of kidney,	775
518. Calculus in pelvis of kidney,	775
519. Adenoma of kidney,	776
520. Adenoma of kidney—hypernephroma,	777
521. Adenoma of kidney,	778
522. Adenoma of kidney, papillary,	778
523. Adenoma of kidney, alveolar,	779
524. Hypernephroma,	779
525. Hypernephroma,	780
526. Diverticula of bladder,	780
527. Hypertrophy of wall of bladder,	781
528. Acute catarrhal cystitis,	783
529. Hyperplasia of bladder epithelium,	784
530. Hyperplasia of bladder epithelium,	785
531. Papilloma of bladder,	787
532. Carcinoma of bladder,	787
533. Papillary carcinoma of bladder,	788
534. Vesical calculus,	789
535. Stricture of male urethra,	791
536. Uterus bicornis,	798
537. Hour-glass uterus,	799
538. Retroflexion of uterus,	800
539. Prolapse of uterus,	801
540. Chronic endometritis,	804
541. Chronic endometritis,	805
542. Chronic endometritis,	806
543. Hyperplasia of cervix uteri,	807
544. Uterine phlebitis,	809
545. Uterine polyp,	810
546. Extramural myomata,	811
547. Intraparietal myomata of uterus,	812
548. Glandular myoma of uterus,	813
549. Adenoma of uterus,	814
550. Adenoma of uterus,	815
551. Adenoma of uterus,	815
552. Adenoma of uterus,	816
553. Adenoma of uterus,	817
554. Carcinoma of uterus,	818
555. Carcinoma of cervix uteri,	819
556. Carcinoma of uterus,	819
557. Chorionepithelioma,	820
558. Large cells from chorionepithelioma,	821
559. Fragment of decidua,	824
560. Curettings from uterine cavity,	824
561. Hydatid mole,	825

FIG.		PAGE
562.	Hydatid mole,	825
563.	Chronic oöphoritis,	827
564.	Chronic oöphoritis,	828
565.	Papilloma of ovary,	829
566.	Papilloma of ovary,	830
567.	Sarcoma of ovary,	831
568.	Endothelioma of ovary,	831
569.	Cystadenoma of ovary,	832
570.	Cystadenomà of ovary,	833
571.	Cystadenoma of ovary, glandular,	834
572.	Cystadenoma of ovary, papillary,	834
573.	Papillary cysts of omentum,	835
574.	Follicular cysts of ovary,	836
575.	Dermoid cysts of ovary,	837
576.	Small pediculated cyst of broad ligament,	837
577.	Hydrosalpinx,	838
578.	Pyosalpinx,	839
579.	Pyosalpinx,	840
580.	Tuberculous salpingitis,	841
581.	Suppurative mastitis,	843
582.	Chronic inflammation of mammary gland,	843
583.	Carcinoma and tuberculosis of mamma,	844
584.	Hypertrophy of mamma,	845
585.	Hypertrophy of mamma,	846
586.	Hypertrophy of mamma,	846
587.	Intracanalicular fibroma of mamma,	847
588.	Fibro-adenoma of mamma,	848
589.	Pericanalicular fibroma of mamma,	849
590.	Adenoma of mamma,	849
591.	Papillary cystadenoma of mamma,	850
592.	Adenoma of mamma,	851
593.	Adenoma of mamma,	851
594.	Carcinoma of mamma, scirrhus,	852
595.	Varicocele,	856
596.	Chronic interstitial orchitis,	858
597.	Tuberculous orchitis,	859
598.	Chronic orchitis,	860
599.	Rhabdomyoma of testicle,	861
600.	Teratoma of testicle,	862
601.	Chorionepithelioma of testicle,	862
602.	Hypertrophy of prostate,	864
603.	Hypertrophy of prostate,	865
604.	Adenoma of prostate,	865
605.	Glandular hyperplasia of prostate,	866
606.	Corpora amylacea in prostate,	867
607.	Progressive muscular atrophy,	868
608.	Progressive muscular atrophy,	869
609.	Pseudo-hypertrophy of gastrocnemius muscle,	870
610.	Hyaline degeneration of muscle,	872
611.	Chronic interstitial myositis,	874
612.	Callus after fracture,	878
613.	Healed fracture,	879

FIG.		PAGE
614.	Ossifying periostitis,	880
615.	Ossifying periostitis,	880
616.	Ossifying periostitis,	881
617.	Tuberculosis of joint,	882
618.	Rarefying osteitis,	884
619.	Condensing osteitis,	885
620.	Tuberculous osteitis,	887
621.	Necrosis of bone,	890
622.	Caries of vertebræ,	891
623.	Rachitic bone,	892
624.	Rickets,	893
625.	Craniotabes,	894
626.	Thorax of rachitic child,	895
627.	Achondroplasia,	895
628.	Achondroplasia,	896
629.	Hyperplastic bone marrow,	898
630.	Normal bone marrow,	898
631.	Sarcoma of bone,	901
632.	Myelogenic sarcoma of sternum,	902
633.	Pachymeningitis interna hæmorrhagica, chronic,	909
634.	Brain sand,	910
635.	Psammoma of dura mater,	912
636.	Acute exudative meningitis,	915
637.	Acute exudative meningitis,	915
638.	Acute exudative meningitis,	916
639.	Fatty degeneration in pia mater,	917
640.	Miliary tubercle of pia mater,	918
641.	Miliary tubercle of ependyma of lateral ventricle,	919
642.	Endothelioma of cerebellum,	920
643.	Endothelioma of pia mater,	921
644.	Plates of bone in pia mater spinalis,	923
645.	Acute ependymitis,	925
646.	Congenital hydrocephalus,	926
647.	Hydromyelia,	929
648.	False heterotopia,	930
649.	Atrophy of brain convolutions,	932
650.	Diagram of circle of Willis,	933
651.	Large hæmorrhage in brain,	937
652.	Section of cord showing hæmorrhage into gray matter,	938
653.	Hæmatomyelopore,	939
654.	Degenerated brain tissue in embolic softening,	941
655.	Blood-vessels from embolic softening,	941
656.	Neurone from human cerebral cortex,	944
657.	Neurone from cerebellar cortex of guinea-pig,	945
658.	Neuroglia cell,	945
659.	Neuroglia cell,	946
660.	Neurone degeneration,	946
661.	Secondary descending degeneration,	953
662.	Secondary ascending degeneration,	954
663.	Amyotrophic lateral sclerosis,	956
664.	Tabes dorsalis,	959
665.	Tabes dorsalis,	960

FIG.	PAGE
666. Posterior spinal sclerosis,	960
667. Combined system disease,	962
668. Degenerated tissue from acute myelitis,	966
669. Poliomyelitis anterior,	967
670. Acute anterior poliomyelitis,	968
671. Landry's paralysis,	968
672. Landry's paralysis,	969
673. Landry's paralysis,	969
674. Degeneration of nerve fibres,	970
675. Multiple sclerosis in spinal cord,	973
676. Solitary tubercle of cerebellum,	974
677. Syringomyelia,	978
678. Side view of human brain,	993
679. Method of opening brain,	994
680. Method of opening brain,	995
681. Schematic picture of brain,	996
682. Brain axis separated from brain mantle,	996
683. Brain mantle seen from below,	997
684. Outlines of sections of spinal cord,	1000
685. Heart, showing lines for incision,	1006
686. Heart opened, exposing aortic valves,	1007
687. Heart opened, exposing mitral valve,	1008

PART I.

GENERAL PATHOLOGY.

INTRODUCTION.

THE successful pursuit of pathology—the science which treats of disease—depends largely upon the clearness and accuracy of the student's knowledge of normal anatomy and normal physiology. The possession of such knowledge by the reader is necessarily assumed in this epitomized presentation of a large and rapidly extending field of observation and research.

The Nature of the Living Body.—Leaving aside as not indispensable, and at present not attainable, an accurate definition of life, it is important constantly to realize that the normal living body is a complex and delicate mechanism incapable of creating new forces, but able, by means of its cellular and molecular organization, to accumulate or store energy derived from without, releasing this under fixed and definite conditions. This storing of energy is possible by means of the capacity of living body-cells to build up complex molecular combinations. These, owing to their instability, may be readily resolved into less complex and more stable combinations with the release of the stored-up energy. This it is which makes possible all expression of life.

The Chemistry of Life.—The complex molecular combinations through which energy is stored and released by cells during the processes of life are especially characterized by their content of carbon, nitrogen, hydrogen, oxygen, and sulphur. Iron and phosphorus are found in some of them while numerous other elementary substances often share in their composition. Such molecular combinations are called *proteins*. There is reason to believe that the proteid molecule is of great size and complexity, that during life it is capable of entering upon an exceedingly great variety of combinations and readjustments of its structure conditioned upon heredity and environment.

While the chemist in his researches deals largely with dead protein, it has been found convenient by certain writers to embody a conception of the living proteid molecule in the terms *biophore* or *biogen*.

It is inevitable that the proteins and their performances while sharing in the processes of life, and the various influences which determine these performances, should fix the storm centre of research into the nature of life and offer the highest promise of light upon the ultimate and fundamental problems of biology. But we must be patient and not too eager to carry the formulæ and the working hypotheses of the chemists, without due reserve, over into the domain of living things, whose story and performances, and limitations we are only just beginning to spell out.

The details of the chemistry of the life processes, so far as they are known, and their relationship to protein substances and protein metab-

olism in general, to ferments and to enzymes, and a consideration of the successes, the hopes, and the dreams of the chemists within this borderland of living matter, belong in those studies in physiological chemistry and chemical physiology which naturally precede the consideration of the problems of pathology, and should be sought in special treatises.

The Characters of Disease.—Many of the earlier views concerning life and death and health and disease, which have long since given way to more accurate conceptions, still hold a certain sway among the thoughtless, perpetuated by traditional forms of speech. One of these is that disease is an entity, something foreign to the body which may enter from without, and with which the body may struggle and fight, which it may conquer or to whose ravages it may succumb. It will be wise for the student constantly to remember that disease is not a thing, but a process. It is an abnormal performance of certain of the functions of the body. This may or may not be associated with appreciable morphological alterations of the body structure. It is those agencies and conditions to which the body has not adapted itself, which, swaying its normal capacities now one way and now another, induce the functional aberrations and structural alterations by which disease is manifested.

It follows from this that the functional abnormalities and the structural alterations which make up the signs, symptoms, and lesions of disease involve the expression of no new functional capacities which the normal body does not possess. These may be diminished or exalted; they may be perverted or abolished; or the cells may now and then revert to forms and to phases of activity which the body has long since outgrown or largely suppressed in its slow adaptation to conditions of life which now constitute the normal. But the body in disease manifests no new functions, develops no new forms of energy, reveals no new capacities.

The Significance of Cells in Pathology.—If pathology is to be for the student or the practitioner anything but a mass of more or less useful facts he must learn to correlate its data with the facts and laws of normal morphology and normal physiology. While he should be conscious always, on the one hand, of the invisible molecular changes which underlie the manifestations of energy, and, on the other, will not ignore the details of gross morphology, his attention will be most constantly drawn to the cells as the life units upon which ultimately both the form and function of living things depend. He will realize that as the cells of the normal body are what they are in form and in function because of the conditions under which they have been slowly evolved, and are at the moment placed; so when the conditions change and become abnormal, it is to the cells that he must look for an understanding of the aberrations and disturbances by which we recognize disease.

In normal physiology attention is most keenly centred to-day upon the structure and performances of cells as the field richest in the promise of significant revelations. So, also, in pathology by similar methods and with equal persistence must the structure and performances of cells under abnormal conditions be studied if we are to hope with reason for

a clearer comprehension of disease. This has long been recognized, and to the conception of the pathological processes as essentially cellular processes are due the great advances which this phase of biological science has made during the past few decades. But the newer knowledge of the cell, not as a membranous bag nor as a mere lump of protoplasm, but as a complex machine whose various structural features are of the utmost significance, has greatly widened the field of cellular pathology.

Manifestations of heredity which are displayed in the body as a whole have long been known. To-day we may and must take account of the marks of heredity in individual cell life. Not a few of what we call the aberrances of cells in disease are but the expression of cell traits and capacities latent in the environment which has become the usual and therefore the normal, but finding expression as the sway of the body-organism is released under disturbances of its equilibrium. Thus cells thrown out of function may in a measure revert in character to less differentiated types, and cells long comparatively quiescent may, under varying stimuli, assume capacities and forms which they seemed to have outgrown.

Of course, in the pursuit of pathological morphology it is the dead body and dead tissues with which we are most often engaged. But these are of special interest only as they reveal structures or indicate processes which were maintained during life. So that he who can most closely correlate the knowledge of the living cells with his observations upon those which are dead will gain most from his morphological studies.

The Interrelationship of Cells and of Organs.—While the pathology of to-day is essentially a cellular pathology, while it is illuminating and convenient to consider the cells as physiological and structural units, maintaining a certain independence of existence and function, it is nevertheless true that beyond their mere juxtaposition in the body, beyond a close mutual dependence upon the common blood supply and nerve control, there is a subtle and as yet little understood transmission of physiological impulses from cell to cell. Whether this is often by protoplasmic continuity or usually in some other way, we do not know. But it should not be left out of the account in some of the more complex and subtle problems which, in health as in disease, the life of the cell and the life of the body present.

The interrelationship of organs, and the innervation and circulation which they share in common, have most important bearings upon both the morphology and physiology of disease. This relationship will be considered briefly in the later chapters of this book, but should receive special attention in the study of clinical pathology.

The Excitants of Disease.—When we study the so-called *causes* of disease, we should remember always that, underlying the manifestations of disease, as well as sustaining the correlated processes which we name health, are the complex and ceaseless chemical transformations which in both health and disease alike supply the energy which sustains all expression of life. So that what we are wont to call the causes, whether external or internal, of disease are really not primary causes, but liber-

ating impulses or excitants which sway and modify the orderly transformations of energy constituting health, with those manifestations of perturbed function or altered structure, or both, on which our conceptions of disease are framed.

Phases and Classifications of Pathology.—Pathology, then, deals with the disturbances of function and the alterations in structure in living beings, induced by unusual agencies and conditions. The functional disturbances thus induced are embraced as symptoms of disease in *pathological physiology*, which so largely dominates the scientific activities of the physician and forms the basis for the practice of his art. The phenomena of pathological physiology are in no sense opposed to those of normal physiology, but are their inevitable correlatives when the living body is placed under sufficiently abnormal conditions. *Pathological morphology* is concerned with the structural alterations of the organism which may result from abnormal conditions. Pathological morphology deals with both the gross and the microscopic alterations of structure, and hence embraces both *pathological anatomy and pathological histology*.

But alterations in structure are so closely associated with disturbances in function, and both are so constantly dependent upon the inciting factors in disease, that an intelligent study of morphology necessitates a constant consideration of etiology and of certain phases of pathological physiology.

It is customary and convenient in the study of pathology to consider together the general or elementary abnormal processes and conditions and the etiological factors in disease without reference to their special manifestations in particular organs or parts of the body. This division of the subject is called *General Pathology*. *Special Pathology* deals with the forms and details of lesions in individual organs or parts of the body.

Correlated Sciences.—The human body is so complex in its organization that the student of pathology, like the student of normal morphology and physiology, is under the constant necessity of seeking light through the study of simpler organisms. In our extremely differentiated and intimately co-ordinated cells, many features fundamentally simple are veiled or modified; so that we can understand them only when we interpret them in the light of less advanced forms.

Thus it is that in the lore of the zoologist and the botanist we may find the key to obscure and important manifestations of aberrant cell life. It is, in truth, through the pursuit of *comparative pathology* that some of our greatest advances in the conceptions of disease have been won, and in it lies the brightest promise for the future. In the light of embryology many obscure pathological processes become plain and many clues to fruitful research are secured.

Furthermore, so much depends upon the metabolism of the body in health and disease that it is to *chemistry*, both in health and disease, that the scientific physician looks most eagerly for the solution of problems which each day become more numerous and urgent.

Finally, we are daily realizing more clearly that in those complex and subtle processes which we are wont to call vital, such physical factors as molecular constitution, surface tension, osmosis and diffusion, gravitation, elasticity, and pressure are of the highest significance and in our studies cannot be wisely ignored.

CHAPTER I.

THE CONDITIONS OF DISEASE.

Adaptation in Health and Disease.—The human body, like other living organisms, has acquired its present form and its varied functions through gradual adaptation to its environment.

The maintenance of the normal life of the body involves a normal mechanism and impulse to start with, and a constant and successful adjustment to the conditions under which it is placed. While the continuance of the state which we call *health* depends upon the approximate maintenance of the external conditions to which the body has become adapted, it should be borne in mind that the adaptive capacity of the body is in many ways so effective that it can maintain its normal structure and functions in spite of unusual surroundings and adverse influences. Thus, for example, the body can adapt itself, within the limits of what we call health, to alterations, deficiencies, or excesses of nutrient material; to varying extremes of heat or cold, moisture or dryness; to electrical tension; to animal and vegetable parasites; and to various poisons, both those which come from without and those which result from faulty metabolism. Beyond certain rather ill-defined limits, however, the adaptive capacity cannot go, and disease results.

Disposition to Disease.—The adaptive capacity may vary greatly in different individuals, depending upon age, sex, race, etc., so that adverse conditions which one individual can sustain without marked functional disturbance or structural damage may induce in another more or less serious disease. There is thus *disposition* and *relative immunity* to disease. For example, children are in general much more disposed to certain diseases than are adults. This disposition to disease is not, however, always fixed, but may give way to immunity under conditions which we shall study especially in the acute infections.

Disposition to disease may be inherited and find expression through obvious structural abnormalities or through subtle functional defects, difficult or impossible to define or detect.

Classes of Disease Conditions.—The harmful conditions to which the body may be subjected and which incite disease may be divided into two classes, *external* and *internal*. We may thus speak of external and internal conditions of disease.

It does not fall within the scope of this book to enter upon a discussion of the many and varied conditions under which disease occurs, nor to place in array the many and wearisome phases of classification which have been more or less imposing or useful in the earlier days of

pathology and medical practice. We shall consider here only some of the more general conditions of disease, referring for a study of the details of the specific excitants to later chapters.

External Conditions of Disease.

Disturbances of Nutrition.—The body may suffer through excessive or deficient nourishment. Too much food may in certain, though not in all, persons lead to an abnormal accumulation of fat. Too much food or unsuitable food may lead to disorders of the digestive apparatus or it may lead to the production within the body of metabolic substances which seriously damage important organs. There is much reason for believing that through such faulty metabolism forms of auto-intoxication may arise which damage the parenchyma of the liver and kidney, for example, so that structural as well as functional disorders arise.

On the other hand, through insufficient nutriment the fat may disappear, the voluntary muscle substance diminish, and the blood deteriorate. Inanition may, however, occur in persons whose food supply is both abundant and suitable; for example, in structural or functional disorders of the digestive organs, in the insane, etc. Nutrition may suffer also in the absence of a sufficient amount of water or proteids or inorganic salts in the food.¹

Air Supply.—Through the function of respiration a supply of oxygen is furnished to the blood in the recesses of the lungs, and excretory products are carried off. The failure of this function may be due to a lack of air bearing the oxygen or some interference with the respiratory channels or mechanism. The failure of oxygen to reach the lungs in proper condition and quantity is followed by forcible respiratory efforts which mark *dyspnœa*. A fatal suppression of respiration by the exclusion of air is called *suffocation* or *strangulation*. *Asphyxia* is a condition in which respiration is suspended, but the heart continues to beat. This condition is of frequent occurrence in the new-born, and is associated with many forms of disease of the respiratory organs. For a more detailed consideration of asphyxia, suffocation, and strangulation see p. 442.

Occupation.—Many diseases are closely dependent in origin upon unsanitary conditions associated with occupation. The dusty air prevalent in many stores, factories, theatres, court-rooms, prisons, schools, etc., may damage the lungs directly and render them more vulnerable in the presence of pathogenic micro-organisms. The high temperature and foul air common in many places of work or assembly may be serious predisponents to disease. Finally, the abuse of alcoholic drinks and tobacco may be cited among many common excesses as agencies through which the conditions of disease are fulfilled.

Damage from Excessive or Deficient Heat.—Through the heat-regu-

¹ Consult for a *résumé* of nutrition in health and disease, *Lusk*, "Elements of the Science of Nutrition," 1906.

lating mechanism of the body a remarkable adaptation to moderate elevations of temperature is possible. But the maintenance of life is incompatible with very high temperatures.

Local exposure to both extreme heat and extreme cold induces necrosis and various phases of inflammation of the tissues.

Death may be caused by the inspiration of smoke and flame; by the drinking of hot fluids; by the direct contact of flame or hot substances with the external surface of the body. It may be due to the direct effect of the agents, to secondary affections of the viscera, or to the exhaustion produced by long-continued inflammation and suppuration. Sudden death may occur after extensive burnings of the skin.¹

The burned skin divested of epidermis may present a peculiar red, hard, parchment-like appearance. If the patient have lived for some time, suppuration of the injured surface may ensue. Or there are small, bladder-like elevations of the epidermis. The base of these blisters is red, and they are surrounded by a red zone, or suppuration may have commenced. These appearances cannot be produced by heat applied to the skin after death.

After death from severe burns there is apt to be congestion of the brain and the thoracic and abdominal viscera. The lymph-nodes and the lymphatic tissues throughout the body may be swollen and the seat of endothelial cell proliferation and necrosis. There is usually albuminous degeneration of the liver and kidneys; the spleen is swollen, and the seat of focal necrosis. Focal necrosis in the bone marrow has been noted. There may be capillary thromboses, interstitial hæmorrhages in the kidney, and leucocytosis. These lesions indicate the presence of toxic substances in the body fluids, and thus the general condition may be regarded as an instance of auto-intoxication.²

Secondary lesions are not infrequent after severe burns. There may be œdema of the glottis, pseudo-membranous inflammation of the larynx and trachea, pneumonia, ulceration of the duodenum, and pyæmia with infarctions in the lungs, liver, spleen, and kidneys.

Excessive *cold* may lead to the extinction of life in the body as a whole or in exposed parts, which cannot long resist freezing.

Electricity.—*Lightning.*—Persons who are struck by lightning may die instantly, or may continue for several hours comatose or delirious, and then either die or recover; or they may die after some time from the effects of the burns and injuries received.

The post-mortem appearances are very variable. Sometimes there are no marks of external violence or internal lesions. Sometimes the clothes are burnt and torn, while the skin beneath them is unchanged. Usually there are marks of contusion and laceration, or ecchymoses, or lacerated, punctured wounds, or fractures of the bones, or superficial or deep burns. The track of the electric current may sometimes be marked by dark red arborescent streaks on the skin. Fractures are rare.

The internal viscera may be lacerated and disorganized from lightning.

Artificial Electrical Currents.—In death from powerful artificial electrical currents, either by accident, as in linemen and others, or in elec-

¹ For a study of sudden death following severe burns, consult *Silbermann*, *Virch. Arch.*, Bd. cix., p. 488, 1890, bib.

² For a study of the visceral changes following extensive burns, consult *Bardeen*, *Jour. Exp. Med.*, vol. ii., p. 501, 1897, bib. *McCrae*, *Trans. Ass. Am. Phys.*, vol. xvi., 1901, p. 153; also, *Locke*, *Boston Med. and Surg. Jour.*, vol. cxlvii., p. 480, 1902, bib.

trical executions, there may be local burnings of varying degree where the wires or electrodes come in contact with the skin. The clothes may be pierced with holes at the point of exit of the current. Internally there appear to be no marked or characteristic lesions, either gross or microscopical, in this form of death. Van Gieson and others have observed the occasional, but not constant, occurrence of small hæmorrhages in the floor of the fourth ventricle, the significance of which is doubtful. Other petechial spots have been observed beneath the serous surfaces of the endocardium, pericardium, and pleura, and on the spleen.¹

Roentgen Rays and Radium.—Exposure of the skin to the x-rays may lead to inflammation of the skin or to necrosis.²

Radium may induce similar changes.

Trauma.—The various forms of mechanical injury which the body may suffer need not be considered here in detail. The significance to life and health depends upon the extent of the injury and the part of the body affected. Thus, a concussion of the brain, even without obvious structural lesion, may be immediately fatal, while excessive laceration or crushing of a limb or muscle may be readily recovered from.

Foreign Bodies.—We shall see later how the presence of lifeless foreign bodies, or of animal and vegetable parasites—bacteria, protozoa, etc.—may be harmful to the organism, and the adaptive measures by which in favorable cases protection is secured.

Poisons.—Certain forms of poisons are to be reckoned among the external agents harmful to the body. These will be considered in a later section.

Increased Atmospheric Pressure (Caisson Disease).—An extreme increase in atmospheric pressure, such as is often nowadays maintained in tunnels, caissons, and other construction works, is sometimes the occasion of death, especially when the pressure is relieved by a too sudden return to normal conditions, that is, in what is technically called decompression. The danger seems to lie, apart from individual susceptibility, in the rapidity of the decompression.

When the pressure is relieved, susceptible individuals may breathe with difficulty, be cyanosed, and bleed from the nose, ears, eyes, and other mucous membranes. There may be pain in the joints, muscles, and abdomen. There may be paralyses, especially of the lower extremities. The bodies of the victims are often contorted from the muscular contraction, hence the common name of the condition, "the bends." All of these symptoms may be promptly relieved by recompression. On the other hand, susceptible persons may succumb within a few hours to the disorder.

The lesions in fatal cases are quite variable. During compression the blood absorbs an abnormal quantity of the gases from the air. In decompression these escape, and to this "frothing" of the blood in too rapid decompression the symptoms and lesions of caisson disease are, in part at least, due. On external inspection no lesion may be evident; or there may be marked cyanosis of the face and mucous membranes

¹ Van Gieson, "A Report of the Gross and Microscopical Examination of Six Cases of Death by Strong Electrical Currents," *New York Medical Journal*, May 7th and 14th, 1892. *Cunningham*, "The Cause of Death from Industrial Electric Currents," *New York Medical Journal*, vol. lxx., pp. 581 and 615, 1899. *Jelliffe, Peterson and Haines* "Text-book of Legal Medicine," p. 245.

² For a study of lesions in x-ray examinations see *Wolbach*, *Jour. Exp. Med.*, xxi, 415, 1909.

of the mouth, nose, etc. Crepitation of the skin may be elicited on light pressure, even though the skin be not obviously puffed up. The internal lesions are also variable. Of these, general venous congestion and frothy blood in the veins and capillaries are the most constant and characteristic. The gas in the vessels may be best seen in the pia mater cerebralis (Fig. 1) and in the omentum. Petechial hæmorrhages may

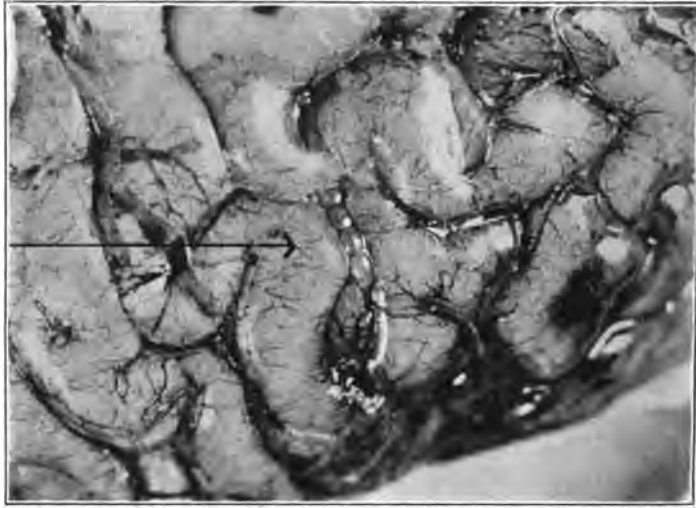


FIG. 1.—CAISSON DISEASE.
Air in the vessels of the pia mater on the surface of the brain.

be found in the brain and cord. Also the gas sometimes accumulates in small blebs in the nerve tissue.

In cases which recover from the primary effects of the pressure there may be secondary degenerations in the nervous system, paralysis, emaciation, trophic ulcers, etc.

Internal Conditions of Disease.

In distinction to those external agencies which lead to disease, there are many conditions of the body itself which are incompatible with the maintenance of health. Thus, there are general conditions, due to disturbances of metabolism, such as diabetes and gout, which we shall consider separately later, in which abnormal amounts of sugar and uric acid are present, leading to many local and general disturbances.

But by far the more common internal conditions associated with disease are the structural and functional alterations of the various organs of the body, which may lead directly or indirectly to the most complex departures from the normal. Some of these will be considered more in detail in later sections of this book. We may note here, however, as examples, a few of these complex relationships between local lesions and the general welfare of the organism.

Lesions of the heart valves lead to disturbances of the circulation of the blood in various parts of the body, so that, as we shall see later, both functional and structural changes harmful to the individual may

occur in important viscera, for example, in the lungs, the kidney, liver, blood-vessels, etc., and secondarily in the walls of the heart itself.

In the gastro-intestinal canal defective innervation, or trauma, or tumors, or constrictions may lead to the accumulation of ingested material, to innutrition, to intoxication through decomposition of the albuminous or other ingredients of the retained material.

So in the liver, an insufficient production of bile or an occlusion of the gall-ducts may lead to digestive disturbances, to a deposition of bile pigment in various parts of the body—icterus; to the accumulation of bile in the blood—cholæmia. On the other hand, an overproduction of bile may take place in the destruction of abnormal quantities of red blood cells, leading to icterus. Furthermore, through disturbances in the glycogenic function of the liver, sugar may accumulate in the blood.

These examples of the bearing of functional disturbances and structural lesions of individual organs upon each other, and upon the welfare of the body as a whole, must suffice, since the scope of this book does not permit us to enter upon this wide field of pathological physiology, for the adequate consideration of which we must refer to systematic treatises on the practice of medicine.

Race.—Examples of racial disposition to disease are not uncommon. Thus African negroes are less susceptible than are the whites to malaria. On the other hand, in this country the negro is especially vulnerable to tuberculosis.

Age is an important factor in the liability to disease, though the reason for this is in very few instances at all clear. In childhood, for example, diseases of the digestive system are readily induced by unsuitable food. In advanced life, the vascular system is a vulnerable part of the body. This apparent predisposition of age may, however, be referred to the wearing out of the vascular mechanism.

Sex appears to be a definite factor in disease disposition, for such maladies as diabetes, gout, general paralysis, tabes, etc., are more common in males than in females. But here, as in the age factor, many obvious external conditions, such as occupation, food, excesses in food and drink, syphilis, etc., may be invoked as elements of determining importance but not inherent in the condition of sex. The conditions incident to child-bearing, however, favor the occurrence of many more or less serious abnormalities of structure and function peculiar to the female.

Heredity.—The relations of heredity to disease are extremely complex and subtle, and our knowledge of the subject is still too meagre to permit of a profitable exposition within the limits which this book imposes. In certain infectious diseases, syphilis for example, the infective agent may be transmitted from the parents to the offspring. This, however, is not the conveyance of physiological or structural peculiarities, but only of an external disease excitant.

For the sake of clearness of thought and correctness of observation it is well for the student and physician to remember that those features and capacities of the organism which are inherited, are those and those alone

derived from the maternal and paternal germ plasm, or through the reaction of these upon each other. The many and varied external influences brought to bear upon the foetus during intrauterine life, may induce marked departures from the normal, but these abnormalities are not in a proper sense inherited. They are more correctly designated congenital.¹

Susceptibility to disease may be inherited, to tuberculosis, for example, though we are unable to define clearly either structural or functional traits to which this vulnerability may be attributed.

There are numerous examples of hereditary anomalies or dispositions to disease. We cannot consider them here in detail, but we may mention as examples, hæmophilia, color-blindness, myopia, neuroses of various types, polyuria, obesity, gout, and diabetes.²

¹ For an interesting and suggestive study of heredity, see *Adami's "Principles of Pathology,"* Vol. i, 1908. See also *Adami* on Inheritance and Disease in *Osler's "Modern Medicine,"* vol. i, 1906.

² For fuller exposition of the subjects considered in this chapter consult *Adami, "Principles of Pathology,"* vol. i, 1908. *Thoma, "Text-book of Pathology,"* English Trans., 1896. *Chantemesse and Podwysotsky, "Les Processus Généraux,"* 1901. *Roger, "Introduction to the Study of Medicine,"* Eng. Trans., 1901.

CHAPTER II.

CHANGES IN THE CIRCULATION OF THE BLOOD.

General Conditions.

THE circulation of the blood in the body is maintained by a very efficient and delicate mechanism capable of prompt and effective adjustment to changes in the local and general conditions under which the body is placed.

The factors especially concerned in the maintenance of the normal circulation and in its adaptability to new and unfavorable conditions are the contractile heart with its valves, the elastic arteries, the innervation of the heart and vessels, gravitation, and the various phases of pressure and suction upon the veins from external sources, direct muscular action, respiratory movements, etc., which promote the passage of the blood upon its rounds. Finally, the character of the blood itself may have an important bearing upon the efficiency of the circulatory mechanism. Alterations in any of these factors may involve disturbances of the circulation.

We may glance briefly at some of these factors in the circulation, and first at *the heart itself*. The energy sustaining the circulation is primarily derived from the contractile heart, so that the condition of its muscle and innervation are of the first significance. Should the heart muscle be enfeebled, through lack of proper nutriment or innervation or by degeneration of the muscle for example, the circulation suffers in manner and degree, depending upon the part of the heart involved. Thus if the muscle of the right ventricle is enfeebled, blood is not properly drawn into the ventricle and is not sent with sufficient force into the lungs. The venous system then becomes overfilled with blood. If the muscle of the left ventricle be enfeebled, too little blood is sent into the arterial system and the pulmonary vessels are not properly emptied.

Changes in *the valvular openings of the heart* or in the valves themselves lead to disturbances of the circulation. Thus if the openings are narrowed, too little blood passes them; or if the valves fail to close properly, some of the blood flows backward through them. In this way both the pulmonary and the systemic veins become overfilled.

The circulation may also suffer through alterations in *the walls of the blood-vessels*. The elasticity and contractility of the arterial walls are important factors in the maintenance of a normal circulation, since they sustain and reinforce the heart pressure in the blood and convert the pulsating movement imparted by that organ into a continuous, uniform flow through the capillaries and veins. If the arterial walls become stiffened and less elastic, or if their lumen becomes narrowed,

more work is thrown upon the heart muscle. Thus the peripheral circulation is impaired unless, in a manner which we shall presently consider, the power of the heart muscle is increased by hypertrophy. Obstruction of the veins may induce similar disturbances in the heart and an impaired local or general circulation.

The circulation of the blood being controlled by *the nervous system* through the distribution of nerves to both the heart and the vessels, alterations in the central nervous system affecting the *vagus* or the *sympatheticus*, or severe traumatic injuries to the body involving reflex disturbances, may induce serious local or general interference with the circulation of the blood.

The *respiratory movements* of expiration and inspiration favor the circulation of the blood, so that interference with these may be of considerable importance. Thus pleuritic effusions, severe spasms of coughing, etc., may induce changes in the pulmonary circulation and the right heart as well as in the systemic circulation.

The movements of *the muscles* of the trunk and extremities acting together with the valves of the veins contribute to the forces carrying the blood forward in circulation. Severe spasm of the muscle, as in epilepsy, tetanus, strychnine poisoning, etc., may induce stagnation of the blood in the veins of the trunk and the viscera so that it does not return properly to the heart.

These are some of the more important of the changes which the general circulation suffers in conditions which interfere with the circulatory mechanism.

The means by which the heart and the blood-vessels adapt themselves to various disturbing conditions through compensatory alterations will be considered in the chapters in "Special Pathology" dealing with these organs.

We shall now consider in more detail the local effects of a disturbed circulation.

Hyperæmia and Anæmia.

Within physiological limits the amount of blood in a part may vary considerably under vasomotor control according to the functional necessities of the part or vascular territory. Under a great variety of abnormal conditions the blood content suffers changes so excessive and so lasting as to be pathological. It is the latter alone which we are to consider here.

A part of the body may contain an excess of blood, a condition called *hyperæmia* (congestion). This is distinguished from *plethora*, which signifies a general excess of blood in the body. On the other hand, there may be too little blood in a part of the body, a condition which is called *anæmia*.

HYPERÆMIA.

Hyperæmia may occur either through increased arterial supply, *active hyperæmia* (acute congestion), or through some hinderance to the venous outflow of the part, *passive hyperæmia* (venous congestion).

Active Hyperæmia.—This may occur through dilatation of the arteries by the action of various physical and chemical agents directly upon their muscular coats, or through the vasomotor nerves, or from the reduction of pressure upon the vessels from without.

Thus, injuries or stimulation of the vasomotor nerves, heat, the sudden evacuation of large exudates, trauma, and the action on the vessels of a great variety of chemical irritants may lead to a dilatation

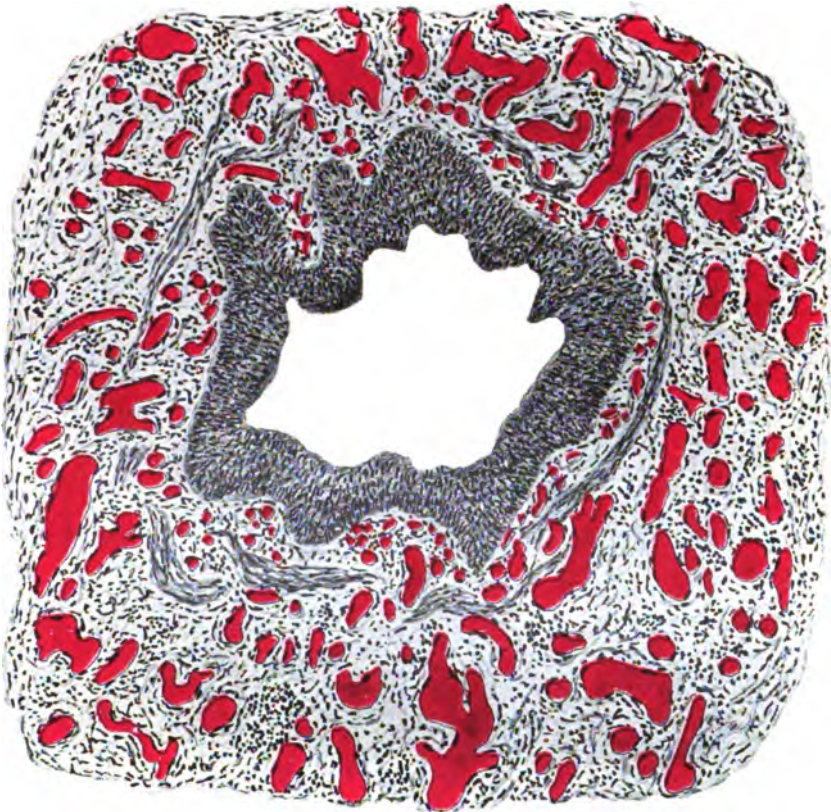


FIG. 2.—HYPERÆMIA OF THE BLOOD-VESSELS NEAR A BRONCHUS.
In chronic bronchitis.

of the vessels, and, as friction is diminished with the dilatation of the lumen, to a more rapid flow of the blood.

Under these conditions the affected region becomes redder, warmer, and may be more or less swollen, and under certain conditions the arterial characters of the blood and pulsation of the vessels may be extended into the venous trunks.

Passive Hyperæmia (venous congestion).—In passive hyperæmia due to obstruction to the outflow of blood from a part, there is an over-filling of the veins and capillaries (Fig. 2). The hinderance to the

outflow of blood may be due to compression of the vessels from without, as from tumor, aneurism, ligature, displacement, or from new interstitial tissues in various organs. It is frequently the result of thrombosis.

One of the most fruitful determining causes of passive hyperæmia is the lesions of the heart which interfere with the regular entrance and exit of the blood from that organ. Thus, in incompetence or stenosis of the mitral valve the pulmonary vessels become congested; the right ventricle does not properly empty itself. So the systemic veins in varying degrees suffer engorgement, and the viscera become involved in the secondary alterations due to chronic hyperæmia.

The effect of venous obstruction varies greatly, depending upon its degree, the rapidity of its occurrence, and upon the structure and functional importance of the part involved. If, as in most instances is the case, venous anastomoses exist between the partially or wholly

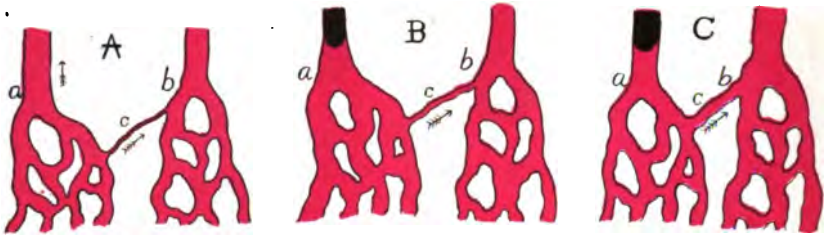


FIG. 3.—DIAGRAM ILLUSTRATING THE ESTABLISHMENT OF COLLATERAL CIRCULATION IN OBSTRUCTION OF A VEIN—AFTER RIBBERT.

The veins *a* and *b* at *A* are connected by a slender trunk, *c*. If *a* in *B* is occluded, as by a thrombus, the blood cannot all pass out of the territory drained by *a*, so that the vessels here are dilated—congestion. If, however, the small anastomosing trunk widens as at *C*, the congestion is relieved by the conveyance away of the blood through the vein *b*.

occluded and other vessels, these may enlarge, and with the establishment of this *collateral circulation* a more or less complete adaptation to the changed conditions is secured (see Fig. 3). The collateral veins and even capillaries in the involved region widen and their walls thicken; and thus while for a time hyperæmia of varying intensity may exist, this gradually resolves.

The possibilities of adaptation to venous obstruction are sometimes very great even when large trunks are concerned. Thus, a ligature of the femoral vein or a blocking of the inferior or superior vena cava may be compensated by the establishment of abundant collateral channels. On the other hand, after the blocking of the renal or splenic or of a main trunk of the portal vein, the circulation is re-established with difficulty.

If a collateral circulation be not at once and readily established, and often even if this be the case, local venous obstruction leads to certain well-defined changes in the hyperæmic region. If the obstruction be partial, the flow of blood is slower than normal; the vessels are dilated; more or less fluid may transude into the surrounding tissues; and diapedesis (see page 86) of the red blood cells may occur. On the other hand, if the obstruction be complete in a large venous trunk, the capillaries and veins in the involved region dilate; the axial stream of ery-

throcytes in the veins disappears; the entire lumen is crowded with them; the blood pressure rises; the current wavers, slows, and stops. Then the red cells become packed into a homogeneous mass in the dilated vessel—this is *stasis*. Diapedesis and transudation now occur in the capillaries and veins of the involved region. Finally, if the circulation be not re-established, hæmorrhagic infarction (see page 29) or death of the tissue—necrosis—may follow.

If the venous obstruction be removed, as may be done in the tongue or mesentery of the experimental frog (see page 111), one may observe under the microscope the disappearance of the stasis and the re-establishment of the circulation. The homogeneous blood mass resolves itself into its component corpuscles; the blood moves at first fitfully and irregularly, then the current is established; the distention diminishes, and, after a longer or shorter time, the part, if the lesion has not been too extreme, assumes its normal appearance.

In passive hyperæmia the tissue involved is more or less dark red in color—*cyanotic*—owing to the accumulation in the vessels of unaërated blood; the temperature may be lowered when the area concerned is extensive; it may also be swollen in part from the distention of the vessels, in part from the extravasation of fluid; finally, there may be pulsation and increased pressure in the veins.

If the hyperæmic condition be long continued—*chronic congestion*—the walls of the involved vessels may become thickened; there may be interstitial fibrous hyperplasia in the affected region; or there may be varying degrees of cell degeneration or of atrophy. Thus function may be interfered with or suspended.

In many instances of diminished heart power or when for any reason the blood circulates with difficulty under favorable conditions, the effect of gravity may manifest itself in dependent portions of the body or of the organs, so that these become hyperæmic. This condition is called *hypostatic congestion*. The most marked example of this condition is in the lungs of debilitated persons, the dependent portions of which frequently become engorged with blood. This is often associated with œdema, atelectasis, and more or less cellular exudate in the air spaces.

ANÆMIA.

The word anæmia is used not only to denote the lack of blood in a part, but also to indicate a reduction or alteration in various constituents of the blood itself, a condition familiarly called "poverty" of the blood. General anæmia due to impoverishment of the blood will be considered in the chapter on the Special Pathology of the Blood and the Blood-forming Organs. We are here concerned only with *local anæmia*—*ischæmia*.

Local anæmia may be due to the cutting off of the blood supply by the occlusion of the arteries in thrombosis and embolism; by ligatures; by the narrowing of the lumen through pathological processes in the wall of the vessel; by tumors, exudates, etc.; by contraction of the

vessels from nerve lesions as in Raynaud's disease; by the action upon the vessel of physical agents—cold—or by chemical substances or drugs which induce marked constriction—suprarenal extract and ergot. Furthermore, mechanical pressure upon the vessel from without or compression of an entire organ or part may induce various grades of anæmia.

The affected part or organ in anæmia becomes paler than normal, often with a yellowish tinge; the temperature is lowered; and the volume may be diminished; finally, if the absence of blood persist, the function and nutrition of the involved part suffer, and atrophy, fatty degeneration and death of tissue may occur.

If, however, the anæmia be only partial or if it be of short duration, in some organs the nutrition may not suffer in marked degree; in others, however, the brain, for example, extreme damage may follow even a temporary anæmia.

The degree, duration, and results of local anæmia are largely dependent upon the cause of the shutting off of the blood supply, and the possibility of its restoration directly or through the establishment of a collateral circulation. Thus, for example, anæmia from compression or from an arterial ligature may at once resolve if the determining cause be removed. But even though an artery remain blocked, circulation may be in a measure restored by the dilatation of anastomosing capillaries or by the backflow of venous blood into the region deprived of its vascular pressure from the closed arteries. While a certain amount of fresh blood may reach the affected region in these ways, it is only when anastomoses exist between the branches of the closed and neighboring arterial trunks that a fairly complete collateral circulation can be established. For a further consideration of this subject see Embolism, p. 28.

Hæmorrhage and Transudation.

HÆMORRHAGE.

Hæmorrhage is an escape of blood from the heart or vessels. It may occur from a rupture of the walls of the vessels, and is then called hæmorrhage by *rhexis*. The rupture may be occasioned by injury, by lesion of the walls of the vessels which renders them too weak to resist the blood pressure from within, or it may occur from the blood pressure in the thin and incompletely developed walls of new-formed vessels as in granulation tissue, tumors, etc. The arrest of hæmorrhage may take place through the contraction of the wall of the vessel or by the formation of a clot.

Under other conditions, without recognizable changes in the vessels, all the elements of the blood may become extravasated by passing, without rupture, through their walls. This is called hæmorrhage by *diapedesis*. Such hæmorrhages are usually small, but may be very extensive. They occur in the smaller veins and capillaries, the cells and fluids of the blood passing out through the cement substance between the endothelial

cells. Although no marked morphological changes have as yet been detected which explain this extravasation, it is probable that some change in the nutrition of the walls does occur which renders them more permeable. Hæmorrhage by diapedesis is apt to occur as a result of venous congestion, or when the flow of blood in the smaller vessels has been suspended for some time; or it may result from the action of some poison, or from an injury not leading to rupture; or it may occur in incompletely developed blood-vessels, in tumors and other new-formed tissues.

In the extravasation of blood by diapedesis the white blood cells may pass through the walls of the vessels, partly at least in virtue of their amœboid movements; the red cells, on the other hand, having no power of spontaneous movement, are, according to Arnold, carried passively through the walls by minute currents of fluid which, under the changed condition, stream in increased force and volume through the endothelial cement substance into the tissue spaces outside.

The altered condition of the blood-vessels leading to hæmorrhage may be local or general, and in the latter case it may either be congenital, as in some cases of the hæmorrhagic diathesis, or it may be the result of a general disease, such as scurvy, purpura, etc. The presence of bacteria in the vessels, or of bacterial or other poisons in the blood, as in malignant endocarditis and in hæmophilia neonatorum, may induce changes in the walls of the vessels, leading to extravasation.

Forms of Hæmorrhage.—Very small hæmorrhages are called *petechiæ*; larger, diffuse accumulations of blood in the interstices of the tissues are commonly called *ecchymoses* or *suggillations*. A complete infiltration of a circumscribed portion of tissue with blood is called a *hæmorrhagic infarction*. A collection of blood in a tumor-like mass is called a *hæmatoma*. Special names are given to hæmorrhage in different parts of the body; thus, bleeding in the lungs is called *hæmoptysis*; vomiting blood from the stomach, *hæmatemesis*; nosebleed, *epistaxis*; hæmorrhage from the uterus, *metrorrhagia*; certain forms of brain hæmorrhage, *apoplexy*. In the so-called *hæmaturia* the blood may be derived from either the kidney or the bladder. Sometimes the elements of the tissue into which the blood escapes are simply crowded apart; sometimes, as in the brain, they are broken down.

The extravasated blood in the tissues usually soon coagulates, although exceptionally it remains fluid for a long time. A certain number of the white blood cells may wander into adjacent lymph-vessels, or they may remain entangled with the red cells in the meshes of the fibrin. The fluid is usually soon absorbed; the fibrin and a portion of the white blood cells disintegrate and are absorbed (see page 59). The red blood cells soon give up their hæmoglobin, which decomposes and may be carried away or be deposited either in cells or in the intercellular substance at or near the seat of the hæmorrhage, either in the form of yellow or brown granules or as crystals of hæmatoidin (see page 53). Sometimes all trace of extravasations of blood in the tissues disappears, but frequently their seat is indicated for a long time by a greater or less amount of pigment or by new-formed connective tissue. Occasionally

the blood mass, in a more or less degenerated condition, becomes encapsulated by connective tissue, forming a cyst.

The action of phagocytes (see page 98) in the disposal of dead material is here, as it is under a great variety of conditions, an important factor in the restoration of the body, after lesion, to its normal conditions.

HÆMORRHAGES IN THE NEW-BORN.

Hæmorrhages, sometimes extensive, in various parts of the body—gastro-intestinal canal, mouth, nose, navel, or the viscera—are not infrequent in the first few days of life. Aside from the occasional discovery of ulcers in the gastro-intestinal walls, the reason for these hæmorrhages is not evident at autopsy. This condition has been called *morbus maculosus neonatorum*. Hæmorrhages from the skin, mucous membranes, or navel may take place in the syphilitic new-born. Hæmoglobinuria may occur in epidemic form in young children.

HÆMOPHILIA (*Hæmorrhagic Diathesis*).

This abnormal condition consists in a liability to persistent hæmorrhage on the slightest provocation, and is dependent upon some constitutional peculiarity which is unknown to us. It is usually hereditary. An uncommon thinness of the intima of the arteries has been noticed in some cases of "bleeders," and other changes have been described; but there are no constant lesions associated with the hæmorrhages, as yet discovered, which would satisfactorily account for their occurrence. The hæmorrhages may be traumatic in origin, or they may occur spontaneously from the mucous membranes.

TRANSUDATION.

Transudation is the passage, through the walls of the blood-vessels into the interstitial spaces outside, of fluid from the blood, with little or no admixture of its cellular elements. This occurs constantly, to a certain extent, under normal conditions, and forms the commencement of the lymph circulation. But when the amount of fluid passing through the walls of the blood-vessels is increased, or its outflow into the larger lymph trunks is hindered so that it accumulates in undue quantity in the interstices and lymph channels of the tissues, the condition is pathological.¹

An accumulation of transudated fluid in the interstices of the tissues is called *œdema*; in the serous cavities, *dropsy*. Extensive œdematous infiltration of the subcutaneous tissue is called *anasarca*. If the transudate accumulates in the pleural cavity the condition is called *hydrothorax*; in the pericardium, *hydropericardium*; in the ventricles of the brain, *hydrocephalus*. In similar fashion various other names are in

¹For a study of lymph formation see *Hamburger*, Ziegler's "Beiträge zur path. Anat.," Bd. 14, p. 443, 1893; for œdema see *Meltzer*, Harrington Lectures, Univ. of Buffalo, 1904; *American Medicine*, July 2, 1904; also *Pearce*, Arch. Int. Med. iii, 422, 1909.

common use for the accumulation of transudates in the body cavities; as *hydroperitoneum* (ascites), *hydrarthrosis*, *hydrocele*, etc.

Its occurrence may depend upon some hinderance to the venous circulation or increase of capillary pressure, especially when associated with alterations in the walls of the blood-vessels, or upon changes in osmotic pressure induced by a reduction in the nutrient efficiency of the blood, by injuries, or in other ways which may affect the processes of filtration and osmosis, by which chiefly, it is believed, the normal transudation of fluids occurs. There is, furthermore, strong and increasing evidence that the endothelial cells of the capillaries possess active secretory or other functional capacities which should be taken account of in the attempt to comprehend transudation as well as many other pathological phenomena and lesions. A simple interference with the outflow of lymph does not usually alone suffice to induce transudation, although it may favor its occurrence. Œdema may depend upon little understood abnormalities of the nervous system, as in the so-called neuropathic œdemas.

The transuded fluid, called *transudate*, is usually transparent and colorless or yellowish; it contains the same salts as the blood plasma, but less albumin. It may contain fat, mucin, urea, biliary acids, coloring-matter of the bile; fibrinogen is usually present in variable quantity, and, rarely, fibrin. It may contain endothelial cells from the lymph spaces, and a variable number of red and white blood cells. The amount of fluid which may accumulate in the tissue varies greatly, depending upon whether they are loose or dense in texture. The fibres and cells of loose tissues may be crowded widely apart; the cells are apt to be more granular than normal, they may contain droplets of fluid or they may be atrophied. Transudates occurring in inflammation usually contain a considerable number of white blood cells and more or less fibrin, and differ in this from the non-inflammatory transudations; but in some cases there is no sharp distinction between them. The inflammatory transudates are often called exudations or *exudates*.

Resorption and Absorption.

Under many conditions, both normal and abnormal, fluids and solid particles are taken into the recesses of the tissues from without, or are gathered from one place in the tissues to be carried in the blood or lymph currents or by cells to other parts or to places of excretion. Thus from the intestinal contents both liquid substances and small solid particles, such as fat droplets, bacteria, etc., may be taken into the body fluids. In exudative inflammations, such as pleurisy or pneumonia, large quantities of fibrin, red and white blood cells, and fluids may accumulate in the cavities, to be presently removed. So also dead tissue, blood clots, etc., and foreign bodies may be removed through various processes of resorption.

The absorption of fluid substances or the resorption of those which are rendered soluble takes place through the lymph channels, as we have seen, whence they may be eliminated through the excretory organs.

Solid material, such as fibrin, dead cells, etc., may be removed either through the action of fluids which render them soluble, lytic fluids (see p. 106), or they may be removed through the intervention of living cells, phagocytes (see p. 98). These processes will be considered in detail in a later section of this book.

Thrombosis and Embolism.

THROMBOSIS.

Thrombosis is the coagulation of the blood or the agglomeration or agglutination of the formed elements of the blood into a more or less coherent mass during life. The coagulum or mass is called a *thrombus* (Fig. 4).

Thrombi may be composed of fibrin and of red and white blood cells intermingled in about the same proportion as in an ordinary extravascular blood clot (Fig. 5). These are called *red thrombi* and usually occur from some sudden stoppage of the circulation. Other thrombi, usually such as form while the blood is in motion, may consist almost entirely of white blood cells with a little fibrin, or of these intermingled with blood platelets; or they may consist almost entirely of blood platelets; all of these forms are called *white thrombi*. Red thrombi, when decolorized by changes in the blood pigment, may somewhat resemble genuine white thrombi. *Mixed thrombi* are usually lamellated (Fig. 6) and contain varying proportions of fibrin, red and white blood cells, and platelets. The fibrin fibrils in thrombi, as elsewhere, often coalesce, forming hyaline masses. A similar change may take place in the blood platelets. Thrombi may consist almost wholly of red blood cells.

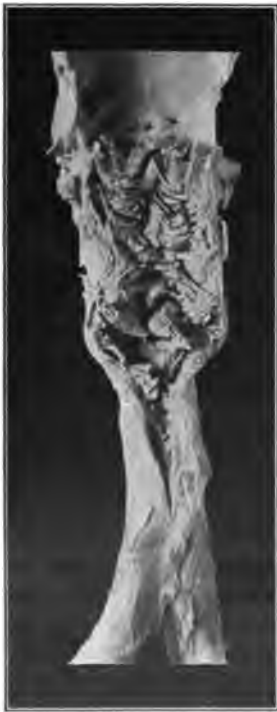

FIG. 4.—OCCLUDING THROMBUS OF THE ILIAC. The vessel is laid open, showing the lamellated clot.

Causes of Thrombosis.—Thrombi may occur as the result of an injury to the wall of a vessel, or may follow its compression or dilatation; they may result from some alteration of the wall of the vessel by disease, or by the retardation of the circulation. So long as the endothelial lining of the vessels is intact, simple retardation of the circulation does not usually alone suffice to induce coagulation; but changes in the endothelium in a

great variety of conditions, such as inflammation, degeneration, atheroma, calcification, and the presence of bacteria or their toxins, tumors, and foreign bodies, favor its occurrence, especially when associated with changes in the circulation or in the character and contents of the blood.

Thrombi may develop from an embolus. Thrombosis is a not infrequent complication of the infectious diseases as well as of the cachetic conditions associated with various acute and chronic general diseases.

One may conveniently class the various determining causes of thrombosis into: 1, those associated with a slowing of the blood current; 2, those relating to changes in the walls of the blood channels; and 3, those involving such alterations in the blood itself as favor coagulation. These factors are frequently associated.

1. Disturbances of the circulation favoring thrombosis are frequently dependent upon enfeebled heart action, and thrombi may then form in the auricles behind the valves or among the trabeculæ of the heart (Fig. 296), behind the valves of the veins, in the veins of the lower extremities, in the great venous sinuses of the brain, or wherever by reason of abnormal conditions the regular flow of the blood is interfered with—as in aneurisms, varices, etc. Such thrombi are sometimes called *stagnation thrombi*. When forming under marked asthenic conditions they are called *marantic thrombi*. In this class belong thrombi induced by pressure or ligature of the vessels.

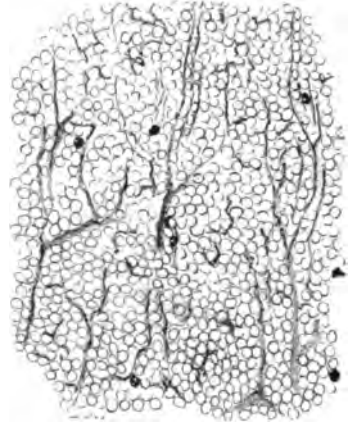


FIG. 5.—PORTION OF RED THROMBUS. This shows red blood cells, fibrin, and a few leucocytes.

2. Thrombi associated with alterations in the walls of the blood-vessels may follow mechanical injuries to the vessels and may be conservative in the control of hæmorrhage. The action of various forms of pathogenic bacteria within or in the vicinity of blood-vessels inducing lesions of the walls is a fruitful determining factor in thrombosis. This is common in acute endocarditis, in septicæmia, in various forms of phlebitis, and in tuberculosis. In chronic lesions of the walls of the heart and blood-vessels, associated with degeneration and necrosis (atheroma, calcification, etc), thrombi may form. The growth of tumors into the blood channels affords favorable conditions for the development of thrombi.

3. The alterations of the blood itself favoring thrombosis are obscure. Such are the impoverishment of the blood in anæmia, the presence of bacterial toxins or of the bacteria themselves in various infectious diseases.¹ Many of the so-called marantic thrombi are probably due to the presence of bacteria or of their toxins in the blood or in the walls of the vessels. Some cases of "white swelling" following parturition are probably of this nature.

Among the less frequent alterations of the blood favoring thrombosis may be mentioned the presence of hæmolytic substances, as in the

¹ For a study of the rôle of micro-organisms in the formation of venous thrombi see *Jakowski*, *Chl. f. Bak.*, Abth. I., Bd. 28, p. 801, 1900, bibl. Consult also *Welch* on infective thrombi, *Allbutt's "System of Medicine,"* vol. vi., p. 169.

transfusion of alien blood and the artificial introduction of certain animal and vegetable extracts.

Forms of Thrombi.—Various forms of thrombi, aside from those already described, have received special names. Thus thrombi are called *primary* or *propagated*, depending upon whether they are confined to the original site of formation or extend for some distance from the point of origin. Sometimes such extension is marked by variations in the color, density, and structure of the extending thrombus. A *secondary thrombus* is one formed upon an embolus or a pre-existent




FIG. 6.—LAMELLATED THROMBUS.

This is an occluding thrombus. At the right and also above are masses of red blood cells, while the remainder is largely fibrin in layers, indicating successive deposits.

thrombus. A thrombus may be *obstructing* or *parietal*; *solid* or *canalized*; *simple* or *infective*; it may be *arterial* or *venous*—all names whose significance is obvious.

*Agglutinative Thrombi.*¹—The recent studies on agglutination and hæmolysis (see p. 171) have led to the belief that certain thrombi occurring in infectious diseases, as well as under other conditions, may arise from the development of agglutinative substances in the blood. Under the action of these substances the red blood cells may, without the formation of fibrin, clump together, leading to thrombosis. Such thrombi are called *agglutinative thrombi*. They have been observed repeatedly in typhoid fever and other infections. In such masses of agglutinated red blood cells the individual corpuscles may not be seen,

¹ Consult Flezner, "On Thrombi Composed of Agglutinated Red Blood Corpuscles," *Journal of Medical Research*, vol. viii., p. 316; also, Pearce, *ibid.*, vol. xii., p. 329; also, Pearce and Winne, *Am. Jour. Med Sciences*, vol. cxxviii. p. 669, 1904, bibl.

the whole presenting a hyaline mass. Thus may be formed a variety of the so-called hyaline thrombi. Welch¹ has suggested the probability that under similar conditions leucocytes also may form agglutinative thrombi.

Hyaline Thrombi.—Under a variety of conditions, but especially in local and general infections and in intoxications, there is present in the capillaries and in the small arteries and veins a homogeneous, translucent, nearly colorless material, partially or wholly blocking the vessels. This hyaline material, whose origin is still in doubt, has in some instances a staining reaction similar to fibrin. In other cases hyaline thrombi are probably special forms of agglutinative thrombi (see above).

Alterations in Thrombi.—After a certain amount of shrinkage by which the fluids are squeezed out and the thrombus becomes denser and drier, the changes which occur in it may be either in the direction of degeneration and absorption or of organization. The leucocytes, the fibrin, and the blood plates may degenerate, forming a granular material which may become infiltrated with salts of lime, forming the so-called *phleboliths*, or *vein stones*. In other cases the thrombi may soften and disintegrate. This softening may be *simple* and the result of fatty or other form of tissue degeneration, resulting in a white or reddish or brown grumous mass, which may resemble, but is not, pus. Or, in many instances, softening probably occurs through the autolytic processes (see p. 106), initiated and sustained largely by leucocytes. On the other hand, softening of the thrombus may be associated with bacteria or other infectious material with general suppuration. In this “purulent” or “septic” softening of the thrombus the risk is great of a distribution of the infectious material through the circulation. Finally, the thrombus may be replaced by a new formation of vascular connective tissue, itself disappearing by autolysis or phagocytosis as the new tissue is formed. This is called “organization of the thrombus,” but in reality the new connective tissue is produced, not from the cells of the thrombus itself, but from the cells of the walls of the affected trunk, from whose vessels the new blood-vessels of the thrombus also arise (compare page 75). In this way the vessel may be completely and permanently occluded, or, more rarely, one or several channels may be established through the new connective-tissue mass (Fig. 7).

Effects of Thrombosis.—The consequences of thrombosis vary greatly, depending upon the seat, size, and nature of the thrombus. They are of two classes: 1, those depending upon the direct disturbance of circulation from the occlusion of the lumen of the vessel; and, 2, those determined by the detachment of the thrombus or the separation of a part of it, and the distribution of these through the circulatory channels to various parts of the body.

1. The occlusion of either arteries or veins may be compensated by the establishment of collateral circulation. The partial or total occlusion of an artery by a thrombus may lead to local anæmia, degeneration, necrosis, or infarction (see page 29). The obstruction of a vein

¹ Welch, Huxley Lecture, Medical News, October 18th, 1902, p. 731.

may lead to venous congestion and œdema, and to various alterations already considered under the heading of Hyperæmia.

For a further consideration of thrombosis of the heart and separate vessels see sections dealing with these organs in Special Pathology.

2. Whole thrombi or portions of these may be detached and carried forward by the blood current, or, as the result of softening and disinte-

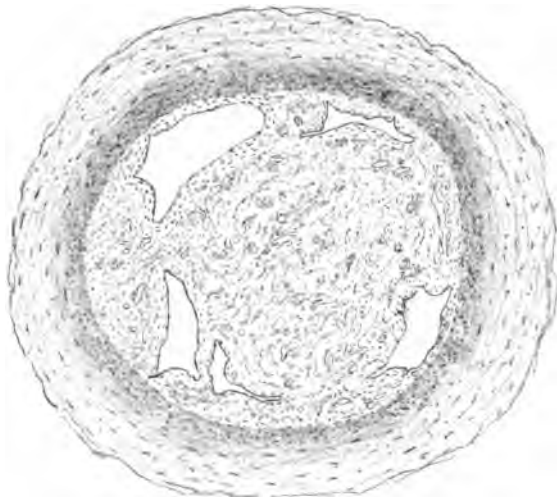


FIG. 7.—ORGANIZED THROMBUS.

This shows the vascular connective tissue which has replaced the clot, with five new channels through which the circulation is re-established.

gration, detritus, bacteria, etc., may be set free by unusual movement, by pressure, or without obvious special force.

The performances and effects of such detached portions of thrombi will be considered in the next section, under embolism.¹

THROMBOSIS OF LYMPH-VESSELS.

Thrombosis of the lymph-vessels is of occasional occurrence. The thrombus consists of fibrin and leucocytes. It may present forms and induce changes in the lymph channels analogous with the forms and effects of thrombi in the blood-vessels.

EMBOLISM.

Embolism is the obstruction of a blood-vessel by the arrest in its lumen of some material carried along in the circulating blood. The mass causing the stoppage is called an *embolus* (Fig. 8). This may be composed of a great variety of substances. The most common emboli are detached portions of thrombi, especially from the heart valves, and

¹ For a thorough and admirable consideration of the subject of thrombosis and embolism, with bibliography, consult *Welch*, Allbutt's "System of Medicine," vol. vi., pp. 155 *et seq.*

these may have all the variety of structure which thrombi present. Masses of bacteria or other animal or vegetable parasites, fragments of the heart valves and of tumors, droplets of fat from the medulla of fractured bones (Fig. 9), parenchyma cells,¹ masses of pigment, bubbles of air, etc., may form emboli. Embolism is, in a majority of cases, confined to the arteries and to the branches of the portal vein. Emboli after lodgment sometimes give rise to thrombosis, which may be very extensive.

Effects of Embolism—Infarction.—The changes which follow the more or less sudden and complete cutting off of the arterial blood from a part of the body by the lodgment of an embolus are so variable, depending upon the part of the body affected, the character of its vascular arrangement, and the possibilities of a collateral blood supply, that a concise comprehensive description is difficult.

When the arterial blood current is cut off from the affected area, this does not at once become bloodless, because its vessels still contain the residual blood and a certain amount may enter at least the periphery through adjacent capillaries and small veins. Then if the involved region be not too large and the plugged vessels have sufficient anastomoses, the establishment of a collateral circulation may after a time be effected. On the other hand, if the plugged artery does not possess anastomosing trunks or is inadequately supplied with these—that is, belongs to those vessels which are called *terminal arteries—end arteries*—the effects are more marked and lasting. There is stasis in the vessels; diapedesis of the red blood cells may occur; and while a small amount of blood may enter the periphery of the involved region through the capillaries and veins so that the vessels here may be markedly congested, the tissues are not sufficiently nourished and they suffer varying degrees of degeneration; they may die and the whole central region become necrotic. This gradually developing process is called *infarction*, and the portion of involved tissue is called an *infarct* (Fig. 10). The area of infarction corresponding to the region supplied by the occluded vessel is usually more or less wedge-shaped.

Infarcts in which the vessels are distended with blood, with interstitial hæmorrhage by diapedesis and more or less necrosis of the involved area, are called *hæmorrhagic infarcts* (Fig. 11).

¹ The presence of liver-cell emboli in the lung capillaries and in the heart clots after traumatic rupture of the liver, and in infectious diseases involving local necroses of the liver, has been described by various observers. Emboli believed to be composed largely of placental cells or of cells from the bone marrow are also described under various conditions. The facts relating to this subject of parenchyma-cell emboli and its alleged significance may be found summarized by *Lubarsch*, *Fortschritte der Medizin*, Bd. xi., pp. 805 and 845, 1893; and by *Aschoff*, *Virchow's Archiv*, Bd. cxxxiv., p. 11, 1893. Consult also *Warthin*, *The Medical News*, September 15th, 1900, *bibli.*

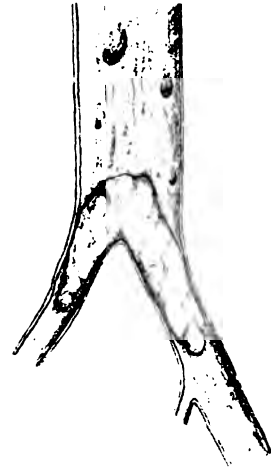


FIG. 8.—AN EMBOLUS LODGED AT THE POINT OF DIVISION OF AN ARTERY.

This is a portion of clot which has been detached from a point above and swept along the blood current. It has increased in length by coagulation at its free extremities.

After a time the infarct becomes decolorized by diffusion of the dissolved hæmoglobin, inflammatory changes occur in its periphery, the blood cells and involved tissues may undergo degeneration and be absorbed,¹ and finally the seat of the infarction may be indicated only by a mass of cicatricial tissue, which frequently contains more or less pigment.

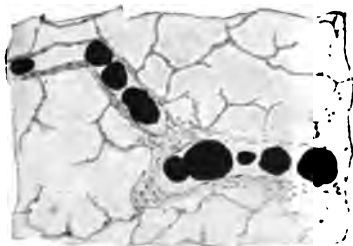


FIG. 9.—FAT EMBOLI IN THE BLOOD-VESSELS OF THE LUNG.
This followed bone fracture.

In another class of cases, instead of an excessive distention of the vessels and an extravasation of blood in the affected region the tissue is simply deprived of nourishment and undergoes necrosis. The affected area then sooner or later becomes lighter in color from the diffusion of the hæmoglobin, and it is then called an *anæmic* or *white infarct* (Fig. 12).

Inflammatory changes may occur in its periphery and a new connective-tissue capsule form around it, and the dead mass may thus persist for some time, or be gradually absorbed and replaced by cicatricial tissue. In certain instances it is believed that infarcts may be anæmic from the beginning and not, as is apparently usually the case, as the result of changes in infarcts which are at first of the hæmorrhagic type.

The scope of this book does not permit us to consider the somewhat complicated and often obscure reasons why in one case there is hæmorrhagic, in another white, infarction, as a result of embolus.

If the embolic material consists of or contains infective substances, such as some forms of bacteria, in addition to the mechanical effects of simple emboli, we may have gangrene, suppuration, formation of abscesses, etc., as the result of the local action of the infectious material, even though this may be present in very small amount.

The Location of Infarcts.—The organs in which embolic infarctions most frequently occur are the spleen, kidney, brain, lungs; less frequently the heart, retina, liver, and small intestines.

Hæmorrhagic infarction is not liable to occur in the *liver* from emboli in the branches of the portal vein, on account of the blood supply which may come to the affected region through the branches of the hepatic artery. On the other hand, embolic abscesses from infectious emboli are of not infrequent occurrence here.

The *lung* is supplied with blood through the pulmonary and the bronchial arteries; and the capillary network of the pulmonary tissue

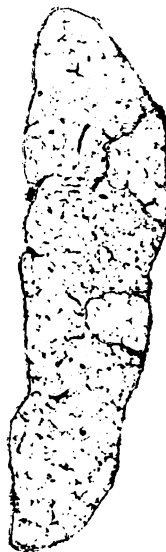

FIG. 10.—INFARCTS OF THE SPLEEN.

¹For a study of the autolytic processes in the absorption of infarcts see *Wells*, Jour. Med. Res., vol. xv., p. 149, 1906.

is so abundant that emboli in the pulmonary artery, although this is a terminal artery, do not readily lead to infarction in an otherwise healthy lung. When, however, the pulmonary circulation is disturbed, as in certain forms of heart disease, hæmorrhagic infarction may follow embolism of the pulmonary artery.

The arteries of the *kidney* and *spleen* are typical terminal arteries, and infarcts of these organs readily follow embolism. In the kidney the infarcts are most commonly anæmic; in the spleen both hæmorrhagic and anæmic infarcts are formed. Infarction in the *heart* may follow embolism, but is more commonly the result of thrombosis of branches of the coronary artery. Embolism of the *cerebral arteries* is

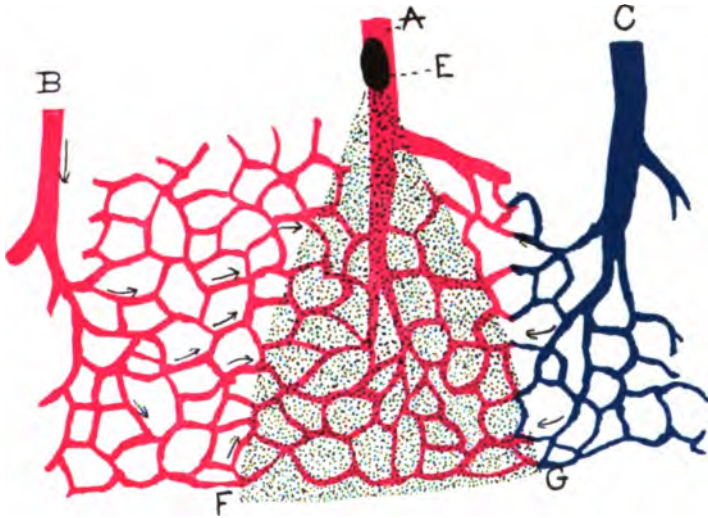


FIG. 11.—DIAGRAM ILLUSTRATING THE FORMATION OF A HÆMORRHAGIC INFARCT.

The artery, *A*, plugged by an embolus, *E*, is a terminal artery, but it has abundant capillary anastomoses, so that the territory deprived of blood is not sufficiently nourished and its tissues die; but from the abundant capillary anastomoses from the artery *B*, and from the vein *C*, a certain amount of blood enters the infarct area, which thus becomes hæmorrhagic.

seldom followed by extensive local collateral hyperæmia and hæmorrhage, but is more apt to lead to cerebral softening. Hæmorrhagic infarctions may occur exceptionally in regions not furnished with terminal arteries, as in the *small intestines*. Infarction does not follow embolism of single arterial trunks of the arms and legs because of the ready establishment of a collateral circulation.

The Sources of Emboli.—It should be remembered that as a rule emboli derived from a vein, and then most commonly detached from a venous thrombus, pass to the right side of the heart and are thence driven into the pulmonary artery, where, unless most minute, they are retained, since they cannot pass the pulmonary capillaries. Emboli in the left heart, the aorta, and the arterial system are derived from the pulmonary vein, the left heart, the aorta or its branches (Fig. 13).

Paradoxical Embolism.—While as a rule emboli follow the direction of the blood current, one does sometimes find in the arterial system emboli of considerable size without being able to locate their source in the pulmonary vein, the left heart, or the aorta or its larger branches. Furthermore, under these circumstances one may discover an obvious source in the systemic veins. Since such emboli cannot pass the pulmonary capillaries they must have passed from the venous to the arterial system through an open foramen ovale into the left auricle, thence to be driven into the arteries (Fig. 13). This is called *paradoxical embolism*. It is of infrequent occurrence.¹

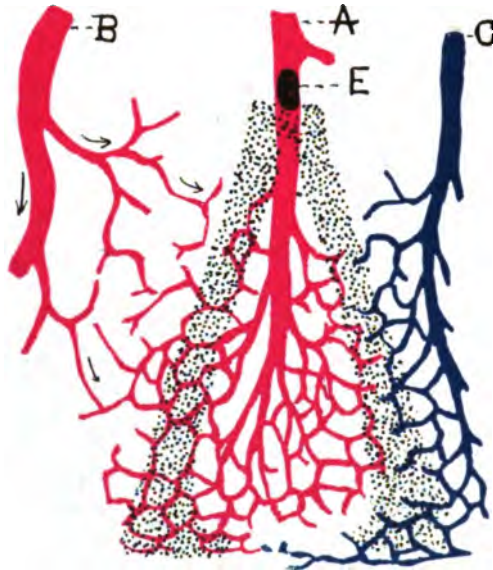


FIG. 12.—DIAGRAM ILLUSTRATING THE FORMATION OF AN ANEMIC INFARCT.

The artery *A* is a terminal artery with a few capillary anastomoses with the neighboring artery *B*, so that when the embolus, *E*, cuts off the blood from the territory supplied by it, the involved region becomes anemic save in the peripheral zone of congestion. This is an anemic infarct.

Retrograde Embolism.—Sometimes an embolus moves in a direction opposite to that of the blood current, so that one may find in a small vein an embolus obviously derived from a larger vein or from the right heart. It has been assumed in explanation of this occurrence that under certain conditions in which the venous blood empties itself into the right heart with difficulty, as in the case of tricuspid incompetence, there might be an actual reversal of the venous current on which an embolus could be conveyed. It does not, however, appear that such a reflux of the venous blood is possible. Ribbert urges the view that while a complete reversal of the current is improbable in a congested vein, a pulsation wave may form with each heart-beat which could gradually force the embolus toward the periphery along the vessel

¹ For details of unusual forms of embolism consult bibliography in Ziegler's "General Pathology," Warthin's translation of 10th Ed., 1903.

wall. This retrograde transportation of an embolus is of rare occurrence in the large veins, especially in the inferior vena cava.

The retrograde transportation of particles of tumor may give rise to very puzzling phases of metastasis.

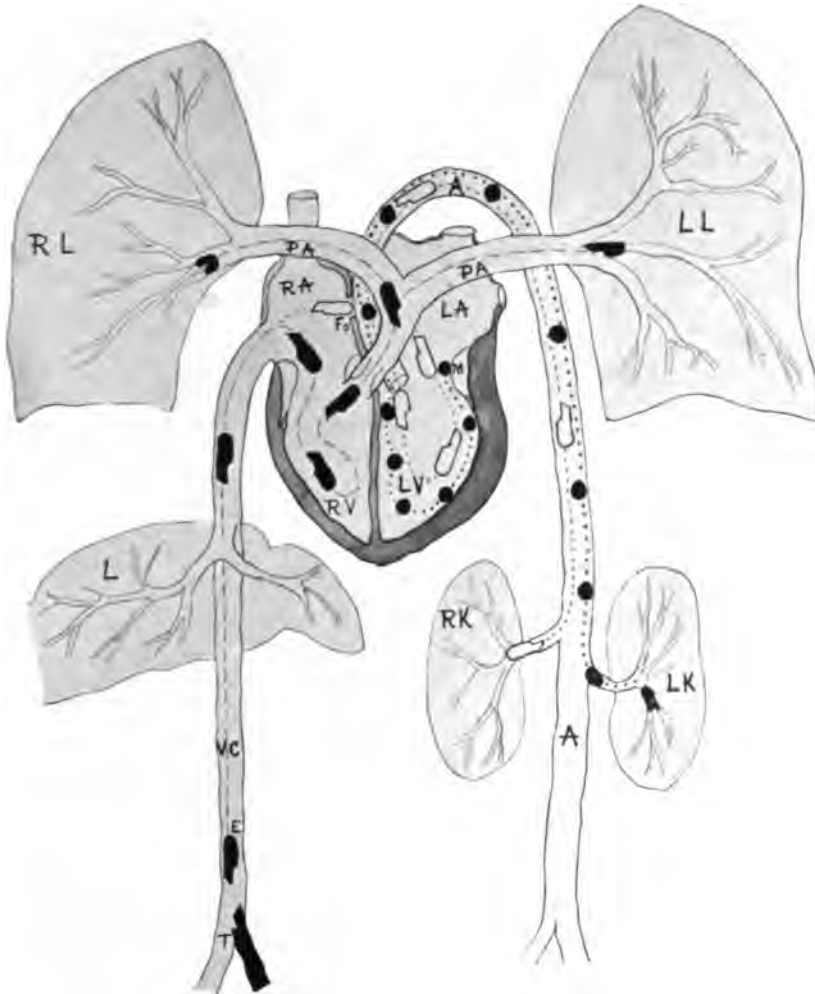


FIG. 13.—SCHEMATIC ILLUSTRATION OF EMBOLISM—AFTER RIBBERT.

The right lung, *RL*, and the left lung, *LL*, are connected with the heart through the pulmonary artery, *PA*, *PA*. The liver, *L*, and the right and left kidneys, *RK*, *LK*, are seen below with the aorta *A* and the vena cava, *VC*. The right ventricle, *RV*, and the left ventricle, *LV*, the right auricle, *RA* and the left auricle, *LA*, are exposed. From the thrombus *T*, a small portion, *E*, is detached and carried upward in the venous current through the vena cava to the heart. It turns into the pulmonary artery where it may lodge in the larger trunks in the lungs. Owing to its size it cannot pass the capillary system of the lungs, and hence cannot enter the general circulation. If, however, as is not infrequently the case, an open foramen ovale exists, such an embolus could pass through the septum into the left heart, whence it could be sent through the aorta to the viscera, as is shown by the outlined embolus. A thrombus in the left heart, say on the mitral valve at *M*, if detached as is shown in the globular mass following the dotted line, may be sent into the aorta and thence into any of the small arterial trunks. In the diagram the embolus is lodged in the left kidney.

Fat Embolism.—After fracture of the long bones, fat from the marrow may find its way through opened veins into the right heart and into the pulmonary capillaries (Fig. 9). It may be found also in the capillaries of the kidneys. Fat embolism of the pulmonary capillaries may be fatal, but in most cases does not appear to be of great significance. Fat embolism of the lungs is recorded following extensive fatty degeneration of the liver in phosphorus poisoning.¹

Emboli of Tumor Cells.—Clusters of tumor cells of considerable size may enter the vessels through erosion of their walls and may be transported in the blood current as emboli (Fig. 248, p. 401). They may lodge in the trunks of large vessels, portal vein, pulmonary artery, etc., and in addition to the usual effects of embolism they may grow, forming metastatic tumors.

Air Embolism.—It rarely happens in surgical operations that a large quantity of air enters an opened vein and is aspirated to the right side of the heart. This may prove fatal. Air bubbles may be found mingled with the blood in the right heart, in the large veins leading to the heart, and in the pulmonary capillaries. It was formerly believed that this was of not infrequent occurrence, and the presence of even small numbers of air bubbles in the blood was regarded as of extreme significance. The presence of air in the vessels is common in caisson disease (see p. 11). In certain cases gas bubbles in the blood are due to infection with a gas-forming bacterium, the *Bacillus aërogenes capsulatus* (see p. 289).²

Experimental Study of Disturbances of the Circulation.

One may observe many of the local disturbances of the circulation on the mesentery of the curarized³ frog. A loop of the intestine is drawn out through a lateral abdominal incision and laid over the glass window of a Thoma frog-plate (see Fig. 72). The part should be kept moist or irrigated with one-half-per-cent. salt solution. Under these conditions one may study various phases of hyperæmia and stasis. hæmorrhage by diapedesis and by slight injuries to the vessels. hæmorrhage by rhexis and the formation of local thrombi by which it is controlled. By pressure on the vessels various disturbances of the circulation, thrombi, etc., can be secured.⁴

By drawing forward the tongue of the curarized frog, fastening it in extension on the Thoma frog-plate designed for this purpose (Fig. 72), and ligating one of the large lateral veins, one can induce interesting phases of passive hyperæmia and transudation.

Embolism may be studied by the injection into the arteries of small particles—tobacco seed in the dog, begonia seed in the rabbit, or poppy seed—suspended in salt solution. These may be injected forcibly upward through the crural artery into the aorta. Embolism of the abdominal viscera, kidney, spleen, etc., with infarction may be thus induced.

¹ For a study of fat embolism see *Connell*, Jour. Am. Med. Assn., vol. xlv., p. 612, 1905.

² For a fuller consideration of the circulatory disturbances consult "*Les Processus Généraux*," *Chantemesse* and *Podwysnolsky*, 1901.

³ The commercial curare is so variable in strength that it is best to make an aqueous solution of about 1:1,000 strength and test the effect, using just enough to secure immobility, and no more, since serious circulatory disturbances and death of the animal are readily induced with too liberal dosage. The solution—at first a few drops—is put beneath the skin in the dorsal lymph sac. It is well to give a preliminary dose a few hours before the use of the animal, bringing him partially under the influence of the drug, and to complete the effect just before the experiment. Under these conditions the second dose may be very small and thus untoward effects upon the circulation may be avoided.

⁴ See for a further description of the method of studying the circulation in the living frog, p. 111.

CHAPTER III.

REGRESSIVE TISSUE CHANGES.

General Considerations.

THERE are three phases of activity in the transformations of energy which are characteristic of living cells. These are nutrition, reproduction, and functional activity. But while these manifestations of energy are more or less distinct as properties of living matter, they are closely interdependent. It is the suitable balance of these activities fixed by prolonged environment which determines what we call health. When this balance is disturbed beyond the limits of physiological variation, the alterations which result may be manifest, either in the diminution or destruction of tissue or in its increase or new formation. In other words, the cells of the body, when placed under conditions which seriously interfere with the orderly transformations of energy, may undergo alterations from the normal which are *regressive* on the one hand, or *progressive* on the other.

We shall in this chapter consider the regressive processes and their effects; in the next those which are progressive.

It is well to remember that the regressive as well as progressive changes in the body are not limited to pathological conditions, but form a part of the normal processes through which growth is secured and function maintained.¹

The maintenance of the normal life and structure of the cell is closely dependent upon the conditions under which it is placed. If there is lack of sufficient or proper nutriment; if the waste products are not properly eliminated; if deleterious chemical substances either coming from without or formed by defective metabolism—poisons, toxins, etc.—are present; or if harmful physical agencies such as heat, cold, pressure, etc., are active; or, finally, if the innervation be defective, both the function and the structure of the cell may suffer.

The functional changes of cells placed under unfavorable conditions are very variable and often very subtle owing to their complex and often little understood nature, and may be difficult of detection. These functional changes may or may not be associated with structural alterations which are obvious on microscopical observation. Cells may become larger than normal through increased functional activity, *hypertrophy*; they may become smaller, *atrophy*, under a variety of conditions presently to be considered. Cells may swell through imbibition of fluid; they may be altered in shape from pressure. Finally, they may suffer various

¹For a *résumé* of the relationship between normal and pathological regressive processes see *Minot*, Middleton Goldsmith Lecture on "The Embryological Basis of Pathology," *Science*, March 29th., 1901.

changes in internal structure. Various products of their metabolism or of degeneration of their cytoplasm may accumulate within them, or substances may enter from without—*degeneration* and *infiltration*.

These and other changes due to an unfavorable environment may be recovered from if not too extensive. But, on the other hand, if the damage be excessive the cell may die and suffer disintegration and absorption. This death of the cell, with subsequent physical and chemical changes, is called *necrosis*.

It frequently happens, however, that the vitality of the cell is not at once extinguished, but that the processes of life and necrosis go on for a time together, ending in either its recovery or its death. This condition is called *necrobiosis*.

Not all the cells of the body are equally sensitive to a deleterious environment. It is those which are more highly differentiated for the performance of special functions, or those which are more frequently exposed to harmful influences, which most often suffer.

Atrophy.

Atrophy is a diminution in the size of the body, of organs, or of tissue elements. It occurs as a physiological process in man as well as in certain of the lower animals. Thus in man the thymus and the umbilical vessels undergo atrophy at an early period; while in old age, atrophy of the sexual organs and of the tissues in general is the usual mark of senil-

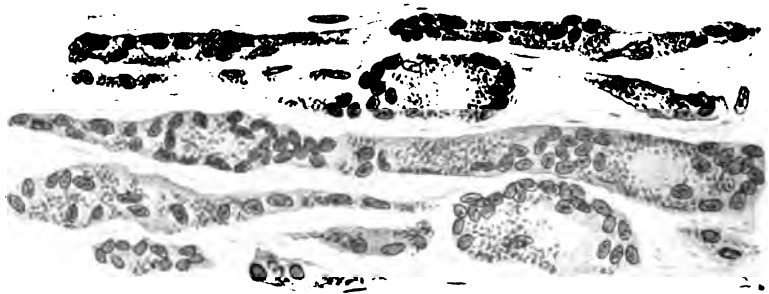


FIG. 14.—ATROPHY OF MUSCLE.

This is atrophy from disuse of the striated muscle. Owing to the muscle pigment which has collected in the atrophied fibres this is called "pigment atrophy."

ity.¹ On the other hand, as a pathological process, atrophy may occur in connection with disturbances of innervation or nutrition; from disuse or from pressure; or from the presence of poisons. Although it is convenient to name these as phases of atrophy, they are not fundamentally distinct. In *simple atrophy*, under whatever conditions it may occur, the tissue elements become smaller without marked alterations in structure,

¹ For a study of the changes in the body in development and senility see the monograph of Mühlmann, Wiesbaden, 1900, bibl.

and may finally disappear altogether. In the majority of cases, however, atrophy of cells or other tissue elements is not simple, but is associated with, and often determined by, various phases of degeneration—*degenerative atrophy*. The cytoplasm of atrophic cells is often more transparent than normal and may contain an undue proportion of pigment.

An organ which is the seat of even extensive atrophy of some of its

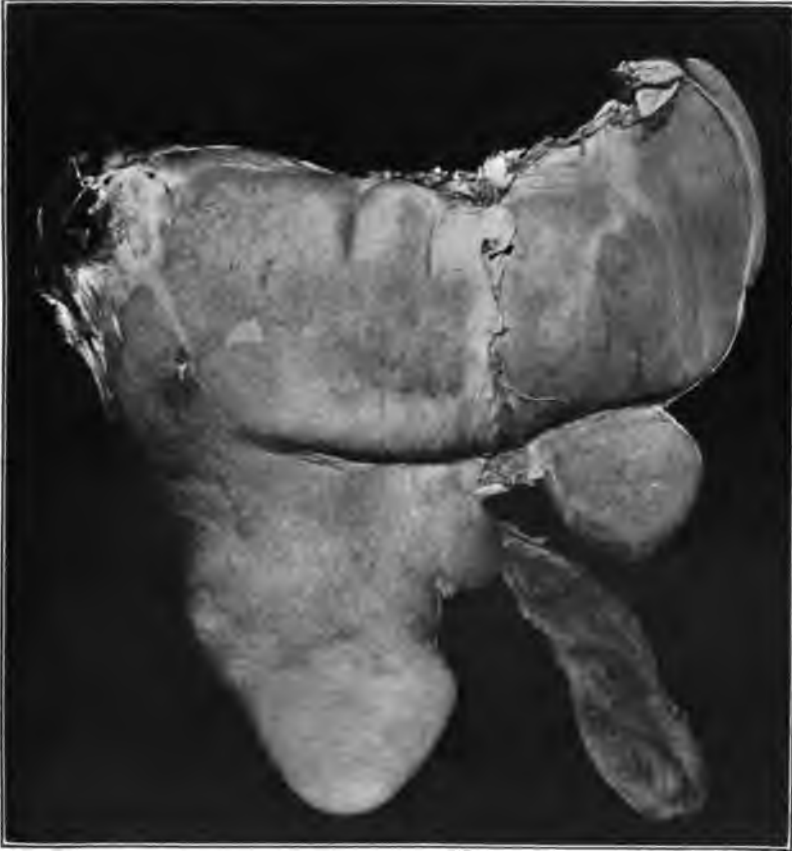

FIG. 15.—ATROPHY AND DISTORTION OF THE LIVER FROM TIGHT LACING—FEMALE.
The border of the organ is elongated and fibrous; the gall bladder is long and distorted.

cells is not necessarily diminished in size, but may even be much larger than normal. This is the case, for example, in amyloid degenerations of the liver. Sometimes the atrophy of parenchyma cells is accompanied by a new formation of connective tissue so extensive as to maintain, for a time at least, the size of the organ.

Atrophy may be general or local and it has various phases which we shall briefly consider.

General Atrophy from Malnutrition affecting the body at large may occur as the result of deficient nutriment as in starvation, or a failure to assimilate food, and in various acute and chronic diseases. Under these conditions fatty and other forms of cell degeneration occur, with loss of the general adipose and reduction in size of muscle and other body cells.

Senile Atrophy.—As the energies of life decline with the advance of years, the tissue and organs may undergo gradual and progressive atrophy, but in varying degrees. The muscle cells of the heart are more slender, and brown pigment may accumulate within them—*brown atrophy*. The parenchyma cells of the liver, kidney, and generative

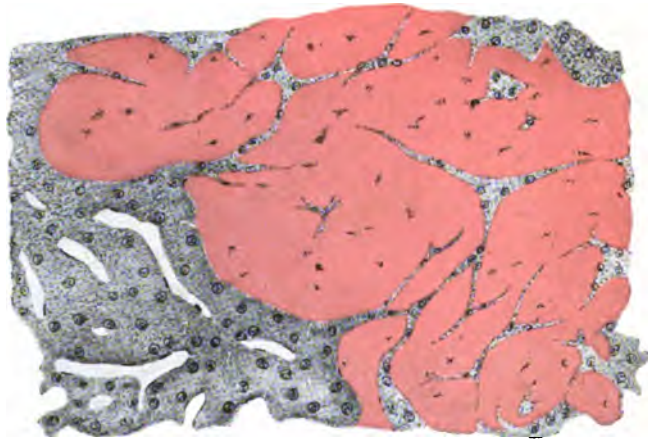


FIG. 16.—ATROPHY OF LIVER CELLS.

Pressure atrophy from amyloid degeneration of the blood-vessels.

glands and the ganglion cells become smaller and may be more or less pigmented. Similarly the bones suffer atrophic changes, becoming more brittle, and the skin becomes wrinkled and dry. Senile atrophy may be associated with significant sclerotic changes in the blood-vessels and with atrophy of the lymph-nodes, spleen, and marrow.

Atrophy from Suspension of Functional Activity—Atrophy from Disuse.—This is well exemplified in disused muscles or bones, as in various forms of paralysis. Voluntary muscles under these circumstances become more slender, lose their transverse striations, and become fibrillar. Brown pigment derived from the disappearing muscle substance may gather in masses in the remaining fibres, and the nuclei of the sarcolemma may be increased in number (Fig. 14). The fibres may finally disappear and may be replaced by fat or fibrillar connective tissue.

Pressure Atrophy.—This is seen under the ordinary conditions of modern life as the result of ill-adapted articles of dress, such as corsets, which frequently induce very marked atrophy with distortion of the liver (Fig. 15). But within the body itself pressure from a more vigorously growing tissue may induce atrophy of an adjacent part. Thus,

tumors, cysts, accumulations of fluids in various cavities, aneurisms, degeneration of blood-vessels (Fig. 16), etc., may lead to local atrophy.

Neurotic Atrophy.—While it is difficult to dissociate the direct trophic influence of the nerves upon tissues from the accompanying loss of function and interference with vascular supply, there appear to be cases of atrophy from neurotrophic influences. Atrophy of one side of the face in lesions of the trigeminus and in certain cerebral lesions, wasting of the associated muscles in destruction of the anterior cornua of the spinal cord, are examples.

Degeneration.

ALBUMINOUS DEGENERATION (Cloudy Swelling, Parenchymatous Degeneration, Acute Degeneration, Granular Degeneration).

Under a variety of conditions in which there is a disturbance of cell metabolism, but especially often in infectious diseases and in intoxications when poisonous substances come in contact with the tissues, the cells of the body show an accumulation in the cytoplasm of albuminous granules, of various sizes and forms. While bacterial toxins are common excitants of this change, other vegetable toxins, such as abrin and ricin, or mineral poisons, corrosive sublimate, may induce it. This is a type of

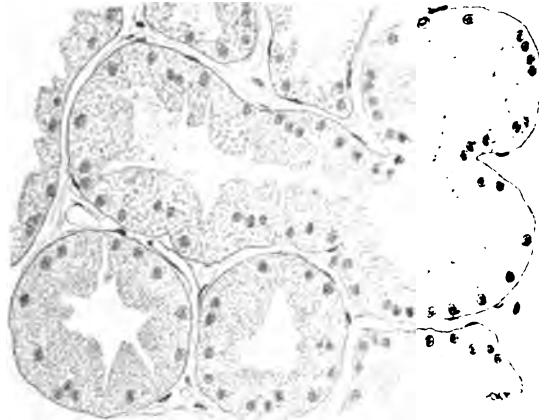


FIG. 17.—ALBUMINOUS DEGENERATION—KIDNEY.

The lesion is moderate in degree and is most marked in the largest tubule above.

cell degeneration which is so often associated with infectious diseases and certain phases of inflammation that it is sometimes regarded as a part of the inflammatory process. The cells in this condition are usually swollen and are more opaque than normal, the nucleus being usually somewhat concealed in the granules when these are numerous (Fig. 17). The albuminous granules in the cells are soluble in dilute acetic acid, but not in ether, being thus distinguished from fat.

While all the cells of the body are subject to this phase of protoplasmic degeneration, it is most pronounced and frequent in the parenchyma cells of the liver and kidney, in muscle, in epithelial cells of the mucous membranes. These are, it will be seen, cells which have a large amount of cytoplasm and in which metabolism is active and the exigencies of nutrition are imperative. The alterations in the ganglion cells of the central nervous system in infectious diseases and in various forms of intoxication are somewhat different from those occurring in other parenchyma cells and will be described in the section devoted to the Brain and Spinal Cord.

Cells in a condition of albuminous degeneration may return to their normal state, they may become fatty, or they may die, become necrotic, and disintegrate.

The liver, kidney, muscle, mucous membranes, etc., when in this condition, are often swollen and in gross appearance more opaque and gray than when normal.

The exact chemical nature of this degenerative process is obscure and will doubtless remain so until we know much more than we now do of cell structure and cell metabolism.¹

TECHNIQUE.—The microscopical study of this lesion is best made in fresh frozen sections of the tissue, by the rapid formalin method, page 1028; or in fresh tissue teased in one-half-per-cent. salt solution.

FATTY DEGENERATION AND FATTY INFILTRATION.

GENERAL CONSIDERATIONS.

It should be remembered that besides the occurrence of fat cells in fat tissue and in the interstitial tissue of various organs, the accumulation of fat in certain epithelial cells is physiological, as in the functional processes of the mammary and sebaceous glands. In the involution of the uterus—also a physiological process—extensive fatty metamorphosis of cell protoplasm occurs.

It is customary and convenient, in considering the abnormal accumulation of fat in the tissues, to assume that in one set of cases—fatty degeneration—the fat is formed by a retrograde metamorphosis or degeneration of the proteid elements of protoplasm, a process by which the integrity and capacity of the cell are compromised, while in the other—fatty infiltration—it may be due to a simple accumulation in the cell of fat formed elsewhere—a condition of less significance.

The validity of this assumption has of late been called in question. It involves in large measure the solution of the physiological problem whether normally the fat in the body is formed from proteids or from carbohydrates. Concerning this, many experiments and much argument have been made;² but it appears not yet to be solved. The traditional

¹ For a study of albuminous degeneration see *Albrecht*, Verh. Deutsch. Path. Ges., Bd. vi., p. 63 1903.

² For a critical summary of this question see *Taylor*, American Journal of the Medical Sciences, vol. cxvii., p. 569, 1899. For a study of the rôle of soluble soaps in formation of fat in cells see *Klots*, Jour. Exp. Med., vol. vii., p. 670. See also ref. to *Albrecht*, foot-note above. For a study of myelogenous substances in cells see *Albrecht*, Verh. Deutsch. Path. Ges., Bd. vi., p. 95, 1903.

distinction between fatty degeneration and fatty infiltration will therefore be made here, with such modifications and reserve as are fitting in view of our lack of knowledge.

There is apparently a certain amount of fat or closely related substances in the cytoplasm of many cells not demonstrable morphologically. Similarly there is fat in the blood which may be conveyed to cells. Under normal conditions these forms of fat enter into the metabolism of the cells and are used up.

We might perhaps wisely adopt the conception of Ribbert that fatty degeneration is a condition in which the involved cells are so damaged through various harmful agencies that the fat which they may normally contain, but which is invisible in their cytoplasm, or fat taken into the cell from without, or fat formed in the cell metabolism, is not properly metamorphosed—burned—but accumulates in droplets in the cell body.

FATTY DEGENERATION.

In fatty degeneration there is an accumulation of larger and smaller droplets of fat in the cell, sometimes so slight as to be scarcely visible, sometimes so great as largely to replace the protoplasm, crowding the nucleus to one side. These strongly refractile fat droplets are not changed by dilute acetic acid. They are soluble in ether, and when fresh

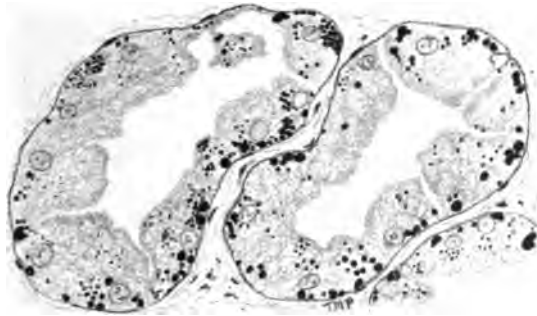


FIG. 18.—FATTY DEGENERATION—KIDNEY.
The fat droplets are stained black by osmic acid.

are stained black by osmic acid (Fig. 18) or red (Fig. 19) by Sudan III or Scharlach R (see technique below). Not infrequently, feathery clusters of delicate fat crystals are present in the cells. Cells in excessive fatty degeneration may disintegrate, forming an oily detritus in which, especially when much moisture is present, cholesterin crystals may form by decomposition of the fat.

To the naked eye, organs in a condition of marked fatty degeneration are usually larger and softer than normal, have a grayish-yellow color or

are mottled with yellowish streaks or patches, and the normal markings of cut surfaces are more or less obscured.

Fatty degeneration may be associated with or may follow albuminous degeneration and may occur under similar general conditions, as in infections, poisoning, etc. It is often associated with the processes of necrosis and disintegration in dead cells and dead tissue. It may be due to local or general disturbances of nutrition, from a great variety of causes—disturbances which either directly affect the life processes of

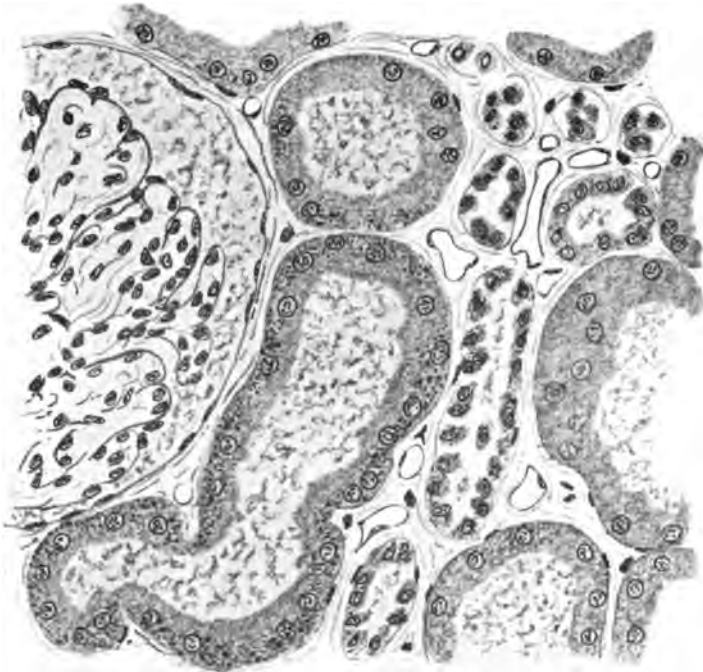


FIG. 19.—FATTY DEGENERATION OF EPITHELIUM IN THE KIDNEY.
The fat droplets are stained with Scharlach R.

the cells themselves or which produce alterations in their nutritive supply. In addition to its local occurrence, as a result of local disturbances of circulation in the vicinity of inflammations or in tumors, etc., it is apt to occur in the liver, heart muscle, and kidney in chronic exhausting diseases and in conditions and diseases to which profound anæmia is incident, in senility, or as the result of the action of certain poisons, such as phosphorus and arsenic.

The function of the cell in fatty degeneration may be greatly impaired, as in fatty degeneration of the heart muscle. On the other hand, in the liver and kidney, the function of the organ may not apparently suffer even with marked degrees of the lesion. The cell may recover if the lesion be not too profound.

FATTY INFILTRATION.

This is of common occurrence under normal as well as pathological conditions. The fat is believed to originate outside of the cells, accumulating in them, and inducing a passive atrophy of the cytoplasm. Cells in a condition of abnormal fatty infiltration are scarcely to be distinguished morphologically from those involved in fatty degeneration. The presence in the cells of large or small droplets of fat, without marks of degeneration in the remaining protoplasm, has been regarded as distinctive of infiltration.

In some phases of fatty infiltration, as in the heart (Fig. 20) or the pancreas for example, the fat accumulates in the cells of the interstitial

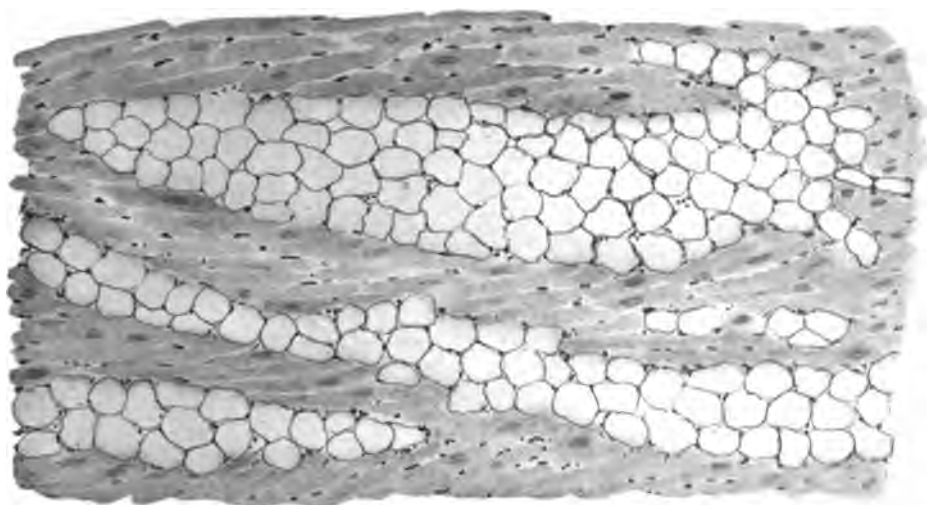


FIG. 20.—FATTY INFILTRATION OF THE HEART.

The fat cells have accumulated *between* the muscle cells of the heart, and not *within* them as in fatty degeneration.

connective tissue in a manner identical with that in which the normal panniculus adiposus is formed. The heart muscles or the gland cells are, under such conditions, affected secondarily through pressure atrophy from the accumulated fat. It should be remembered that fatty infiltration and fatty degeneration may occur simultaneously. When fat production or fat storage is largely in excess of fat consumption from either local or general causes, the condition is called *lipomatosis* or *liposis*.¹

Myelinic Degeneration.—During autolysis of cells and under certain other conditions associated with fatty degeneration and infiltration there appear irregular, double contoured, doubly refractive globules or masses, swelling up in water, soluble in alcohol and ether. The chemical nature of these so-called *myelin bodies* is as yet not clear, but they are regarded

¹ For a study of lipomatosis with bibl, see *Lyon*, *Arch. of Int. Med.*, 1910, vi, 10.

as lipid bodies, allied to soaps, in which the fatty acid essentially concerned is oleic acid.¹

TECHNIQUE.—Fatty tissues may be teased fresh in salt solution; or they may be hardened in Flemming's osmic-acid solution (see page 1030) in preparation for sectioning. Hardening in Orth's fluid and afterward in alcohol gives good results if the lesion be extensive. In tissues which have been soaked in alcohol without previous fixation of the fat, the latter is no longer present, its former seat being indicated by clear spaces filled with the mounting medium. Fat crystals, however, often persist after prolonged soaking in alcohol.

Sudan III and Scharlach R are valuable stains for fat, the fat taking on an orange or red color. The following method is recommended for this purpose.

Smears of exudates, scrapings, etc., may be made on a slide and fixed in from five to ten minutes in the vapor of formaldehyde. Stain in a saturated, filtered, seventy-per-cent. alcoholic solution of Sudan III for fifteen to twenty minutes. Wash quickly in fifty-per-cent. alcohol and transfer to water. Counterstain in hæmatoxylin or methylene blue. Mount in glycerin. Herxheimer² recommends the solution of Scharlach R to saturation in equal parts of acetone and seventy-per-cent. alcohol, differentiating in seventy-per-cent. alcohol.

Sections.—Frozen sections of fresh tissue or tissue hardened in formalin are placed for a few seconds in fifty-per-cent. alcohol. Stain for fifteen minutes or longer in Sudan III or Scharlach R. Wash quickly in fifty-per-cent. alcohol. Rinse in water. Counterstain in hæmatoxylin. Mount in glycerin. Conduct the stainings in covered dishes to avoid a precipitation of the stain by evaporation.³

GLYCOGEN INFILTRATION.

Glycogen appears under abnormal conditions in the cells as hyaline, mostly globular masses of varying size (Fig. 21). It is soluble in water,



FIG. 21.—GLYCOGEN INFILTRATION OF EPITHELIAL CELLS.

The droplets of glycogen are stained with iodine.

is stained brownish-red by iodine, and does not, like amyloid, assume a greenish color by further addition of sulphuric acid. In diabetes it may occur in large quantities in the liver cells and in the epithelial cells of the uriniferous tubules, especially in those of Henle's loop, and in leucocytes. It may be found in

fresh pus cells, in the cells of various forms of tumors, and in leucocytes in the blood in leukæmia, in chronic diseases of the gastrointestinal tract in children, and in various acute and chronic diseases.

TECHNIQUE.—If the tissue to be examined for glycogen be fresh, the iodine should be used in solution in glycerin (equal parts of Lugol's solution and glycerin), in order to avoid its solution. If specimens are to be hardened, this should be done in absolute alcohol to avoid the solution of the glycogen. Sections may be stained with picro-acid fuchsin (Van Gieson's stain) or with a dilute solution of iodine in alcohol (tincture iodine 1 part, absolute alcohol 4 parts); cleared up and studied in oil of origanum.

¹ For a study of myelins and myelin bodies occurring in fatty degeneration and otherwise see *Adami and Aschoff*, Proc. Roy. Soc. B., vol. lxxviii., 1906.

² *Herxheimer*, Cbl. Allg. Path., Bd. xiv., p. 841, 1903.

³ For method of staining fat-acid crystals see *Mallory and Wright's "Path. Technique,"* 1904, p. 388.

SEROUS INFILTRATION OF CELLS (Hydropic Degeneration, Vacuolization).

Under many pathological conditions, cells, especially those of mucous membranes, glands, muscles, tumors, etc., contain one or more larger or smaller droplets of clear fluid (Fig. 22). The cell may thus be distended. These droplets are usually extra-nuclear and may crowd the nucleus to one side of the cell. The nature and source of this accumulated fluid are not definitely known. Its transparent appearance in the granular protoplasm has given rise to the term "vacuole." It may be associated with general tissue œdema, with inflammatory and degenerative processes, etc.

Mucous and Colloid Degeneration.

There is a group of closely related translucent glyco-proteid substances which it was formerly thought practicable to distinguish by simple chemical tests especially relating to solubility. Among these are the so-called mucins and colloid. The simplicity of the earlier distinction has,

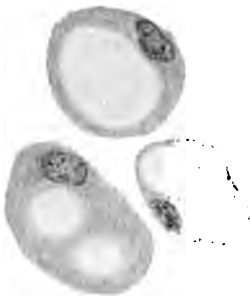

FIG. 22.—SEROUS INFILTRATION OF EPITHELIAL CELLS.



FIG. 23.—MUCOUS DEGENERATION OF EPITHELIAL CELLS.
From a cyst-adenoma of the ovary.

however, not been justified by more modern research, so that the separation of mucoid and colloid degeneration along the old lines does not express very definite chemical knowledge. It will, however, be convenient, while awaiting light from the chemist, to maintain the old distinctions between mucous and colloid degeneration, unstable as are the foundations on which they rest.

MUCOUS DEGENERATION.

Mucous degeneration may occur in cells or in intercellular substance. When occurring in cells it consists, under pathological as under normal conditions, of the transformation of the protoplasm into a translucent, ropy, semi-fluid material, occupying more space than the unaltered protoplasm and hence causing a swelling of the cells (Fig. 23). The distention of cylindrical epithelium by the accumulation of mucin-containing substances in the outer portion of the cell, with the crowding of the nucleus and the remnant of the cytoplasm toward the base, often gives the

cells the shape of a goblet or beaker (Fig. 24). Hence the name "beaker cells," often applied to them. This appearance is especially well marked when the mucinogenous contents of the cell have been discharged from the free end.

Mucins may collect in small transparent droplets within cells or may

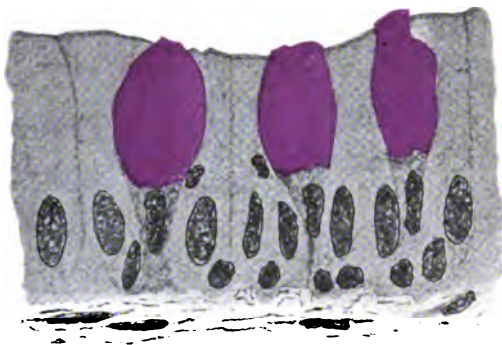

FIG. 24.—"BEAKER CELLS."

In the formation of mucous in the epithelium of the small intestine. The mucus is stained with thionin.

so distend them as to form a globular body with a scarcely visible remnant of nucleus or cytoplasm. The cells may be totally destroyed by the accumulation of the mucinous material within them. This new-formed material contains mucin in solution, which is precipitated by acetic acid and by alcohol. It swells in water and is readily stained




FIG. 25.—MUCOUS DEGENERATION OF FIBROUS TISSUE OF MAMMA.

by thionin. It occurs under a variety of conditions, sometimes as an abnormal increase of a normal function of cells, as in many catarrhs, sometimes as an entirely abnormal transformation.

In certain cases, as in many tumors, in cartilage, bone, and other tissues, the intercellular substance may undergo conversion into mucin-

containing material, losing almost entirely its original structure (Fig. 25). The cells in such cases may be affected only secondarily by the pressure which the new-formed material exerts upon them.

TECHNIQUE.—Tissues should be hardened in Orth's fluid or formalin followed by alcohol; the sections are stained with picro-acid fuchsin or with hæmatoxylin, which colors the mucin-containing portions.

COLLOID DEGENERATION.

This is very closely allied, both in chemical and morphological characters, to mucous degeneration, and in many cases there is no definite microscopic distinction between them. But colloid material, which is normally present in the thyroid, is firmer and more consistent than mucinous, does not yield a precipitate on addition of acetic acid or alcohol, and its formation is usually confined to cells; not involving intercellular substance, except by an atrophy which its accumulation sometimes induces. The cells may contain larger and smaller droplets of colloid material, or the latter may nearly or entirely replace the protoplasm and accumulate to such an extent as to cause rupture and destruction of the cell. In this way, and by the atrophy of intercellular substance which its accumulation causes, cysts may be formed containing colloid material and cell detritus. Colloid material accumulates frequently in the thyroid gland. A material resembling, if not identical with, colloid is occasionally seen in the form of homogeneous globules in the tubules of kidneys which are the seat of other lesions, in the hypophysis, and in various tumors.

TECHNIQUE.—Tissues should be hardened in formalin or Orth's fluid, and stained with picro-acid fuchsin.

Hyaline Substances.

Under a variety of conditions there are deposited in the tissues homogeneous proteid substances whose origin and nature are still obscure. Sometimes they are very abundant and seriously interfere with the function of the organs in which they occur. But frequently they are present in small amount and, with or without association with other processes, seem to be of slight importance. While some of these are characteristic in appearance and in the conditions under which they occur, and give definite gross and micro-chemical reactions, others seem at present to have no definite reactions and appearances, except the homogeneous character which they all share.

One of these substances, *amyloid*, can be definitely differentiated by its appearance, color reactions, and the conditions under which it occurs. Another, *hyaline substance*, while less individualized than amyloid, is conveniently considered for the present as a definite material. The remainder of the homogeneous substances cannot be classified now and are probably of diverse origin and composition.

HYALINE DEGENERATION.

This is the transformation of tissues into a transparent, glassy substance, much resembling amyloid in its morphological characters (Fig. 26); but which does not give the micro-chemical reactions of amyloid, and appears under different conditions.

Hyaline substance is resistant to the action of acids, and stains readily with acid fuchsin and eosin. It occurs especially in the walls of the smaller blood-vessels in various parts of the body, in voluntary muscle fibres, and sometimes involves interstitial tissue. It occurs in the thyroid, the brain, the reticular tissue of lymph-nodes, and in the

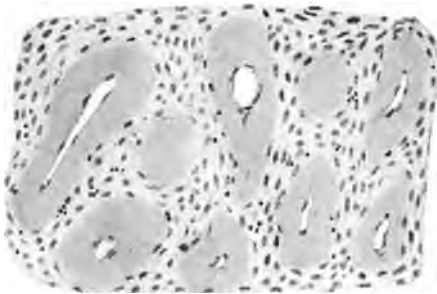


FIG. 26.—HYALINE DEGENERATION IN THE WALLS OF SMALL BLOOD-VESSELS.
From a sarcoma.

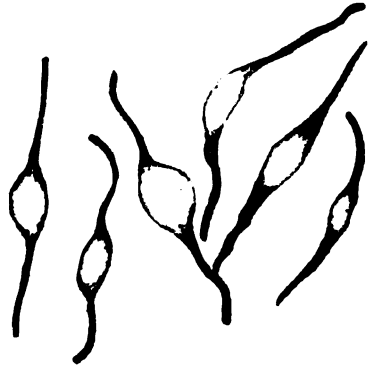

FIG. 27.—HYALINE DEGENERATION OF MUSCLE CELLS.
Infection of pregnant uterus.

ovaries; in the membrana propria of the tubules of the kidney and in Bowman's capsule; in the walls of aneurisms, in the lesions of diphtheria, tuberculosis, and syphilis; in the hyaloid membrane and vessels of the eye, and elsewhere. It occurs in the unstriated muscle fibres in infection of the uterus during pregnancy (Fig. 27). It is believed that fibrin, blood plates, and leucocytes may undergo hyaline degeneration, and in the form of so-called hyaline thrombi this substance may block the capillaries in many infectious diseases—typhoid fever, pneumonia, diphtheria, pyæmia, etc.—and under other conditions (see p. 27).

Hyaline substance is not uncommon in coarse trabeculæ or in masses as an apparent modification of fibrin in inflammatory exudates and in thrombi. Hyaline casts are common in the kidney tubules.¹

TECHNIQUE.—Hardening in alcohol, Orth's fluid, or formalin. Staining by picro-acid fuchsin or by hæmatoxylin and eosin.

AMYLOID DEGENERATION (Waxy or Lardaceous Degeneration).

This is a process by which the basement substance of various forms of connective tissue, and especially the walls of the blood-vessels, become

¹ Consult for bibliography of studies on hyaline degeneration *Lubarsch and Ostertag's "Ergebnisse der allg. path. Morphologie und Physiologie,"* etc., Jahrg. i., Abth. i., 1895, p. 210.

swollen and thickened by their conversion into a translucent, firm, glassy, colorless material, albuminous in character. For the microchemical reactions of amyloid substance see below under *Technique*. This albuminous material may be present in the tissues in such small amount as to be recognizable only under the microscope, or it may be so abundant as to give a very characteristic appearance to the tissue. Parts in which the lesion is marked are usually enlarged, and some organs, the liver, for example, may reach a very large size. Affected parts contain less blood and feel harder than normal, and have a peculiar

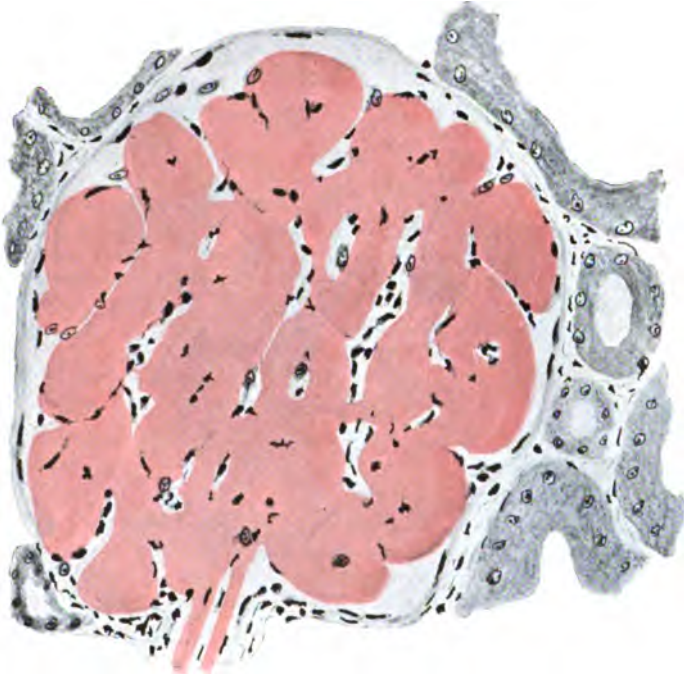


FIG. 28.—AMYLOID DEGENERATION OF CAPILLARY BLOOD-VESSELS OF A GLOMERULUS OF THE KIDNEY.
The waxy vessels are stained pink with methyl violet.

shining and translucent appearance which varies in character, depending upon the extent and distribution of the degenerated areas and upon its association with other lesions, such as fatty degeneration. It most frequently occurs in the smaller arteries and capillaries (Fig. 28), whose lumen is encroached upon by the thickening of the walls which the process involves. It is usually the media and intermediary layers of the intima which are earliest and most extensively affected. The change also often occurs in the interstitial connective tissue and membranæ propriæ of organs and in reticular connective tissue. It does not affect the parenchyma cells of organs. These, however, frequently undergo atrophy as the result of pressure from the swollen, degenerated tissue.

It is not yet known whether amyloid degeneration is due to a direct

transformation of the tissue, or is an infiltration by some abnormal material formed elsewhere and brought to it, or is derived from the blood.

Amyloid degeneration occurs most frequently and abundantly in the liver, spleen, kidneys, intestinal canal, and lymph-nodes; but it may occur, usually in a less marked degree, in other parts of the body: in the larger blood-vessels, in the interstitial tissue of the heart and mucous membranes of the air passages, and in the generative organs. It may occur locally or appear in various parts of the body at once. It most frequently occurs in connection with severe wasting diseases, particularly in those involving chronic suppuration and ulceration, especially of the bones. It is common in tuberculosis, syphilis, and the cachectic condition induced by malignant tumors, and is occasionally seen in severe malarial infection, dysentery, and leukæmia.¹

TECHNIQUE.—For microscopical examination, the tissue, either fresh or after preservation, should be cut into thin sections, and these deeply stained with one-per-cent aqueous solution of methyl violet; the sections are washed in water and mounted in glycerin. The differentiation between the amyloid and other parts is more distinct if, after staining, the specimen be dipped for an instant in HCl and alcohol 1 : 100, and then carefully rinsed, before mounting in glycerin. The degenerated areas are thus stained rose-red, while the normal tissue elements have a bluish violet color. In some cases, for reasons which we do not know, the amyloid substance does not show a well-marked reaction with methyl violet. For the detection of amyloid in fresh tissues by the iodine reaction see p. 1012.

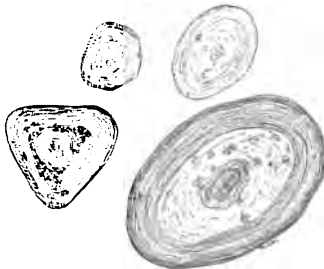


FIG. 29.—CORPORA AMYLACEA.
From prostate gland.

Corpora amylacea are small, spheroidal, homogeneous or lamellated bodies (Fig. 29), which assume a bluish color on treatment with solution of iodine or iodine and sulphuric acid. They are frequently found in the acini of the prostate gland, sometimes in large numbers; in the ependyma of the brain and cord; also in extravasations of blood and in various other situations. They may occur under normal as well as pathological conditions, and are apparently of little importance. They seem to have

nothing to do with amyloid degeneration, although they somewhat resemble its products. Some of the tube casts of the kidney resemble in many respects the corpora amylacea.²

CALCAREOUS INFILTRATION.

There is in this condition a deposition, either in cells or in the intercellular substance, of larger and smaller granules composed chiefly of phosphate and carbonate of calcium (Fig. 30). These particles, when

¹ An extended study of amyloid degeneration may be found in a monograph by *Wichmann*, *Ziegler's Beiträge*, Bd. xiii., p. 487, 1893. Also for later bibl. *Schilder*, *ibid.*, Bd., xlvi., p. 602, 1909.

A later bibliography with a summary of experiments on the production of amyloid degeneration in animals will be found in an article by *Maximow*, *Virch. Arch.*, Bd. cliii., p. 353, 1898.

² For a study of the relationship of corpora amylacea to amyloid substances, see *Ophüls*, *Jour. Exp. Med.*, vol. v., p. 111, 1900, bibl.

abundant, give hardness, brittleness, and a whitish appearance to the affected tissue. Under the microscope they appear dark by transmitted, white and glistening by reflected, light. In hæmatoxylin-stained specimens, the tissue about the lime particles and masses is apt to be deeply and diffusely colored. Tissues may be nearly completely permeated with salts, or the latter may be scattered in patches through them (Fig. 31). Sometimes large lamellated concretions are formed in tissues, usually at the seat of some old inflammatory process. Calcium salts may be deposited under abnormal conditions either in tissues or in the retained secretions and excretions of the body. In pathological calcifications they are retained, not in the diffuse state in which they

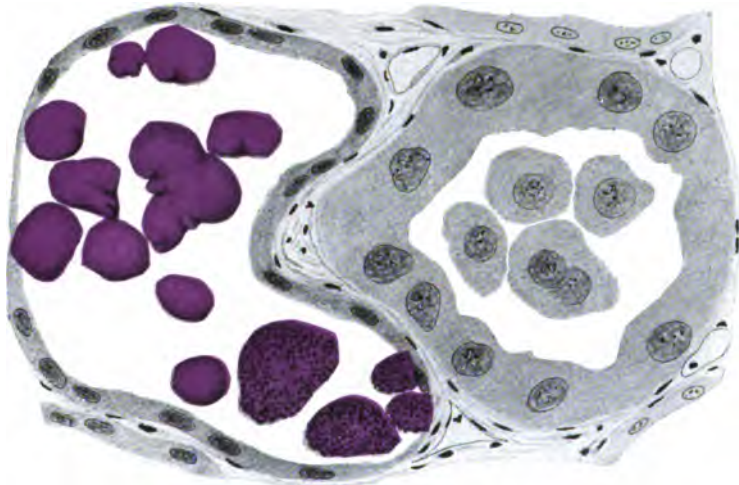


FIG. 30.—CALCIFICATION OF EPITHELIAL CELLS OF THE KIDNEY.

This is following sublimite poisoning. Some of the cells are converted into rounded, strongly refractile masses of lime salts. In others the lime is in the form of granules within the cells. The calcified parts are diffusely stained with hæmatoxylin.

exist in bone, but in particles or clumps, although the calcium compounds are essentially the same under both the normal and the pathological conditions.

Calcification in tissues usually, if not always, occurs in parts which are dead or are in a condition of reduced vitality as a result of some antecedent abnormal process, as a rule of an inflammatory nature. Fatty degeneration of cells frequently precedes calcification. Among the most common and important examples of calcareous degeneration may be mentioned those which occur in the valves of the heart in endocarditis and the walls of the blood-vessels in chronic obliterative endarteritis. It occurs in old thrombi, in old tuberculous areas, in old infarcts, in long-retained dead fœtuses, in cartilage, in ganglion cells in old age or after their death from any cause, and under many other conditions. Calcification of the epithelium and of casts in the kidney occurs after corrosive-sublimite poisoning in man (see p. 421) and may be experi-

mentally induced in animals. As examples of calcification of masses of secretion and excretion we may mention tonsillar calculi¹ in which masses of epithelial cells, bacteria, etc., are infiltrated with calcium salts. Of similar character are the preputial, bronchial, and intestinal calculi, and calculi in the ducts of various glands; and calcification in thrombi and other fibrinous structures.

The calcium salts are derived from the blood and lymph in which they are held in solution. The rationale of their deposition in damaged

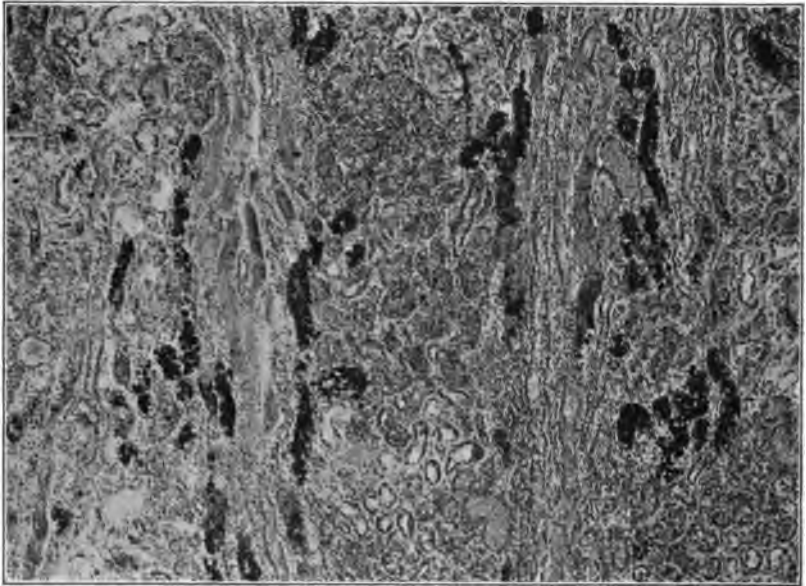


FIG. 31.—CALCAREOUS INFILTRATION (CALCIFICATION) OF THE KIDNEY. Following sublimate poisoning. The calcium salts are deposited chiefly in the necrotic and fatty epithelium of the tubules.

cells and tissues is not yet clear, though much work and discussion have centred in the problem. The presence of phosphorus in the affected areas; the existence of fatty acids in cells and tissues—since fatty degeneration so frequently precedes calcification—with which the calcium may form insoluble soaps; and proteids capable of uniting with calcium, have all been urged as determining factors. We cannot enter here upon a discussion of this point.²

TECHNIQUE.—The carbonate of lime deposited in the tissues is dissolved by dilute acids with evolution of carbonic-acid gas. This process may be observed under the microscope by running five-per-cent. hydrochloric acid under the cover-glass upon unstained sections; the gas bubbles are caught as they evolve beneath the cover.

¹ Calculi are masses of solid material of various composition precipitated from the body fluids. They will be considered under the separate organs in which they most frequently occur.

² Consult *Wells*, "Pathological Calcification," *Jour. Med. Research*, vol. xiv., 1906, p. 491, bibl. Also, for a study of the rôle of diffusible soaps in the formation of cell fats and in calcareous degeneration see *Klotz*, "Calcareous Degeneration," *Jour. Exp. Med.*, vol. vii., 1905, p. 633, and vol. viii., 1906, p. 322.

Pigmentation.

There is under normal conditions a certain amount of pigment in the body—in the rete Malpighi of the skin, in the eye, in muscle, and in fat. This pigment is elaborated by the body cells and may vary considerably in amount.

The pigment which is formed under pathological conditions may be derived from the blood—*hæmatogenous*; from the bile—*hepatogenous*; or it may be elaborated by various cells after the analogy of the normal pigment—*metabolic*. Finally, pigment may be introduced into the body from without by drugs, in tattooing, or by inhalation—*extraneous*. The pigment in the body, of whatever origin, may be in yellow, brown, black, or reddish granules, or in crystalline form. It is often deposited in cells, but may lie free in the intercellular substance. It is often transferred from place to place in the body.¹

HÆMATOGENOUS PIGMENT.—Blood pigment may form by the decomposition of hæmoglobin in thrombi, in extravasated or in the circulating blood. Under these conditions the hæmoglobin which is loosely associated with the plasma of the red blood cells readily diffuses, leaving the cells—so-called “blood shadows”—pale and almost invisible and prone to disintegrate. This destruction of blood cells is called *hæmolysis*. Hæmoglobin in solution in the body fluids² undergoes various phases of decomposition which we cannot follow in detail here. One of the derivatives or groups of derivatives of the hæmoglobin is called *hæmosiderin*.

Hæmosiderin usually appears in the form of brown or black granules either in cells or free in the tissues. It is the usual form of blood pigment resulting from hæmolysis. It gives the microchemical reaction for iron. For this test for iron in hæmosiderin see foot-note below.³

A further common decomposition product of hæmoglobin is *hæmatoidin*. Hæmatoidin is identical in chemical composition with the bile pigment, bilirubin. It may occur as red rhombic plates or acicular crystals or as granules (Fig. 33). It does not contain iron. This is



FIG. 32.—PIGMENT CONTAINING IRON WITHIN EPITHELIAL CELLS OF THE AIR VESICLES OF THE LUNGS.

The iron pigment is colored blue. This specimen is from the lungs of an employé in the Subway in New York City.

¹ See *Askanazy*, *Cbl. f. Path.*, Sep. 7th, 1906, p. 642.

² See page 456.

³ To differentiate free iron and certain of the iron-containing pigments of the hæmosiderin group, sections of the alcohol-hardened tissue are placed for an hour or longer in a two-per-cent aqueous solution of ferrocyanide of potassium. Transfer to glycerin containing 0.5 per cent. hydrochloric acid. Under these conditions the iron will be stained blue or greenish-blue (Fig. 32). In order to secure a reaction for the ferrous as well as the ferric salts, use a mixture of 1 gram each of ferro- and ferricyanide of potassium in 100 c.c. of water. Transfer to acid glycerin as above. Contrast stains may be secured by alum carmine.

There are, it should be remembered, certain iron compounds—the so-called “masked” iron—which are not demonstrable by the ordinary reaction.

For a *résumé* of the microchemical reactions for iron, with bibl., see *Tracy*, *Jour. Med. Research*, vol. xiv., 1905, p. 1. Also, *Mann*, “*Physiological Histology*,” 1902, p. 290.

the form of blood pigment which after a time is apt to form at the seat of old hæmorrhages or in old blood-clots, thrombi, etc., where it may persist for a long time.

Red blood corpuscles may be taken up by various forms of phagocytes, and within these cells the decomposition of the hæmoglobin may lead to their pigmentation.

Hæmolysis may take place in the circulating blood in many forms of poisoning, in acute infections, notably in malaria, in pernicious anæmia, in various cachexiæ, etc. The hæmoglobin thus set free in the body fluids may be eliminated through the urine, inducing hæmoglobinuria; it may be used by the liver in the formation of bile; or it



FIG. 33.—HÆMATOGENOUS PIGMENT. HÆMATOIDIN CRYSTALS AND MASSES FREE AND WITHIN LEUCOCYTES.

may undergo decomposition, and its derivatives may be deposited in the cells of various organs and in the tissues as pigment granules.

A condition called *hæmochromatosis* has been described, in which a brown pigment, probably derived from the hæmoglobin of the blood, is deposited in various tissues of the body. The organs in this condition may appear notably pigmented on gross examination. The pigment particles which are found in the epithelial cells of glands, especially of the liver and pancreas, contain iron; while an iron-free pigment may be present in the smooth muscle cells of the gastro-intestinal canal and of the blood and lymph vessels, and in connective-tissue cells. This pigmentation is commonly associated with cirrhosis of the liver. Hæmochromatosis may be associated with diabetes mellitus and cirrhosis of the liver, together with pigmentation of the skin—"bronze skin." The conditions leading to hæmochromatosis are still obscure.¹

HEPATOGENOUS PIGMENT.—Pigmentation of tissues from the bile occurs under various conditions. The bile may enter the blood and tissue fluids in obstruction of the gall ducts by inflammation, tumors, calculi, etc. In the condition called *jaundice* or *icterus* the tissues are stained yellowish or yellowish-green by bile pigment. Icterus, it should be remembered, may also occur in infectious diseases and in toxæmia, under conditions which lead to destruction of red blood cells within the vessels. Bile pigment may be deposited in the liver and elsewhere in the form of yellow or brown granules.

¹ For a careful study of hæmochromatosis, with bibliography, see *Opie*, Jour. Exp. Med., vol. iv., p. 279.

It consists largely of *bilirubin*, a substance identical with hæmatoidin, being derived from hæmoglobin through the metabolism of the liver cells.

Ochronosis.—Under conditions which are as yet little understood, minute, iron-free, gray or black granules of pigment which may be called



FIG. 34.—MELANOTIC PIGMENT IN TUMOR CELLS.
Metabolic Pigmentation.

melanotic are deposited especially in cartilage but also in other connective tissues. Melanuria may accompany this form of tissue pigmentation. This condition has been called *ochronosis*.¹

METABOLIC PIGMENT.—Pigments called *melanins*, and probably derived from albumins, may be elaborated by various forms of cells,



FIG. 35.—PIGMENTATION OF CONNECTIVE-TISSUE CELLS OF THE LUNGS.
From inhaled coal dust—anthracosis.

by processes apparently somewhat analogous with those concerned in normal pigmentation.² This is exemplified in melanotic tumors (Fig. 34), most frequently of the choroid and the skin, and possibly in the bronze skin of Addison's disease.

Pigment whose nature is not very clearly defined may form in the smooth muscle tissue of the gastro-intestinal walls, in various cachexiæ,

¹ For a study of *ochronosis* see *Pick*, *Berl. klin. Woch.*, 1906, pp. 478, 509, 556, 591.

² For a study of the nature of skin pigment consult *Abel* and *Davis*, *Journal of Experimental Medicine*, vol. i., p. 361, 1896; also *Chittenden* and *Albro*, *American Journal of Physiology*, vol. ii., p. 291, 1899. Also *Mann*, "Chemistry of the Proteids," 1906, p. 580.

in the heart muscle, in the so-called "brown atrophy," and, under certain conditions, in the liver.

EXTRANEOUS PIGMENT.—As examples of pigment introduced into the body from without, we may mention the deposition of minute particles of silver from the internal use of silver salts—*argyria*; the coloring of the skin and lymph glands from tattooing; and especially the pigmentation of the lungs and bronchial glands from the inhalation of coal and other dust—*pneumonokoniosis* (Fig. 35). This is universally present under the conditions of indoor life which modern civilization imposes. Such pigment may be brown or black, and is usually in very small particles within cells or in the intercellular stroma.

Necrosis.

Necrosis is the death of a circumscribed portion of tissue in the living body. It may be the result of insufficient nutrition from cutting off the blood supply, as by embolism, thrombosis, ligature, pressure, etc., or it may depend upon the action of destructive chemical agents, extreme degrees of temperature, the Roentgen rays and radium. It may be due to bacterial toxins or to toxins formed by the animal tissues; to nerve lesions leading to trophic disturbances; or to mechanical injury.

Defective nutrition of the body in various acute and chronic diseases disposes the individual to local necrosis when subjected to any of the direct agencies just enumerated. The general appearance of dead tissue varies greatly. In some cases there is a simple and gradual disintegration and softening of the tissue, resulting in a mass of degenerated cells and cell detritus, with more or less fluid and various chemical substances arising from decomposition. The softening of the brain in embolism is an example of simple necrotic softening—*liquefaction necrosis*. In some cases the dead tissues merely dry and shrivel gradually and become hard and dark-colored.

In another class of cases the dead tissues are permeated by fluids which may be dark red in color, from the solution of coloring matter from the blood, and may contain bacteria which induce putrefaction, with the production of gases and various new chemical substances. The tissues become swollen and granular, and disintegrate; and finally the whole may form a mass of irregular granules, with fat droplets, tyrosin, leucin, and various forms of crystals, shreds of the more resistant kinds of tissue, and bacteria.

The death of cells is marked by cessation of function and by certain morphological and chemical alterations of the body and the nucleus. As a rule the highly specialized cells, such as the functional cells of the brain, liver, and kidney, are most vulnerable in the presence of harmful conditions.

There is at first no evident morphological difference between dead cells and living cells. But very soon in the former, changes occur. The cytoplasm may swell and become homogeneous from imbibition of fluids; or, on the other hand, it may become more coarsely granular. The

nucleus stains less deeply or not at all with hæmatoxylin or other nuclear dyes (Fig. 36), owing to the disappearance of the chromatin which seems to dissolve in the tissue juices; this is called *karyolysis*. Sometimes, however, the chromatin does not dissolve, or only partially dis-

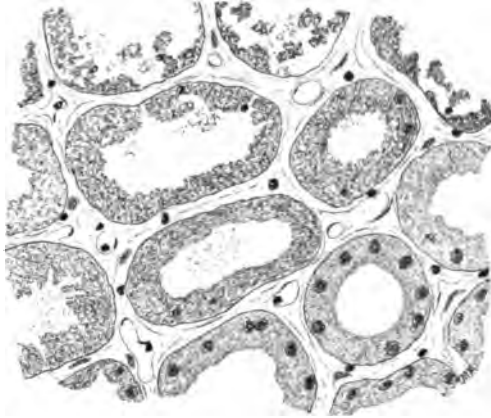


FIG. 36.—NECROSIS OF EPITHELIUM IN THE KIDNEY.

The cells in the lower portion of the cut are nearly normal; most of those above are more coarsely granular and have failed to take the nuclear stain, while at the top they are disintegrating.

appears, the remainder breaking up into irregular, more or less deeply staining granules. This is called *karyorrhexis*. The nuclei of cells which are undergoing regressive processes or dying may become smaller and denser than normal and stain more deeply; this is called *pycnosis*.



FIG. 37.—GANGRENE OF THE FOOT.

A sharp line separates the dead and gangrenous portion of the foot from the living tissues about the posterior part and the ankle.

Presently the cell body may contain fat droplets, or without this it may disintegrate.

GANGRENE.—When death of a considerable mass of tissue occurs, and this either dries, as is possible on the surface of the body, or is associated

with putrefaction in the tissue, the condition is called *gangrene*. The involved part, when on the surface of the body, may dry and become hard and brown or black—*mummification*, or *dry gangrene*¹ (Fig. 37). On the other hand it may, when putrefactive bacteria are present, in addition to its discoloration, become soft and infiltrated with foul-smelling gases—*moist gangrene*. If the affected part be comparatively bloodless, the discoloration, which is largely due to decomposition of the blood pigment, may be absent.²

FOCAL NECROSIS.—Necrosis involving a small circumscribed area of tissue, such as is frequent in toxæmia, is called *focal necrosis*, p. 203.

ULCERATION.—Necrosis with erosion involving the surface of the skin or of the mucous or serous membranes is called an *ulcer*. An ulcer may be necrotic in origin, from the cutting off of nutrition in a circumscribed area, as in some forms of gastric ulcer. This may be associated with reactive inflammatory processes which tend to promote repair. On the other hand, the process may be inflammatory in origin, death of tissue following.

COAGULATION NECROSIS.—If dead areas of tissue (whether this condition be due to mechanical injury, to disturbances of nutrition, or to

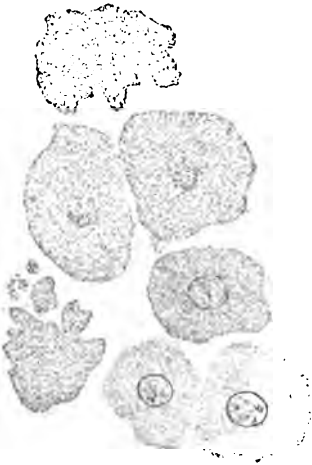

FIG. 38.—COAGULATION NECROSIS IN CELLS.

The disappearance of the chromatin from the nuclei is indicated by their failure to stain, especially marked in the upper cells.

the local action of bacterial or other poisons) contain the substances necessary for the coagulation of their albuminous constituents, or if they be bathed with body fluids from adjacent parts in which the circulation is maintained, a characteristic coagulation of the necrotic elements is apt to occur. The composition of the cells of the tissue is altered, so that the cell bodies are shining and translucent, sometimes altered in shape; while the chromatin and finally the nuclei of the cell disappear (Fig. 38). The white infarctions of the spleen and kidneys, the areas of coagulation necrosis in tuberculosis, and the pellicle in croupous inflammation of the mucous membranes are the most common examples of this lesion.

If, for example, in the spleen, one of the small arteries is plugged by an embolus, a corresponding portion of the spleen becomes anæmic and appears as a white, wedge-shaped mass, sharply defined from the surrounding splenic tissue. If such a white infarction has existed but a short time, there is hardly any difference between the appearance of its anatomical elements and those of the surrounding spleen, except that they are differently affected by staining-fluids. If the infarction is older, the cells are small and shiny and their nuclei cannot be seen.

¹ For a study of senile gangrene see *Falta*, *Zeitschr. f. Heilkunde*, Bd. xx., p. 393, 1899, bibl.

² For more detailed studies of gangrene consult works on surgery.

In croupous inflammations of mucous membranes the epithelial cells become shiny, the nuclei disappear, and the shape of the cells is changed by the coagulation necrosis, so that a number of them together often look like a network of coagulated fibrin.

Cheesy Degeneration (Caseation).—As commonly used, this term embraces the changes in the tissues which we have just considered under the more appropriate name of coagulation necrosis. But it is also applied to that form of degeneration in which, under a variety of conditions, the dead tissue elements lose their normal structural features and become converted into an irregularly granular albuminous and fatty material (Figs. 39 and 40), which sometimes tends to disintegrate and soften, sometimes dries and becomes dense and firm, or may become infiltrated with salts of calcium. Thus cheesy degeneration may, and very often does, occur in tissues which are in the condition of coagulation necrosis; but it also occurs in tissues which are not the seat of coagulation necrosis, but which, for a variety of reasons and in a variety of ways, have lost their vitality.

The terms "coagulation necrosis" and "cheesy degeneration," as commonly used, in part actually cover the same degenerative conditions in the tissues. Both are indefinite, and will no doubt remain so until we gain a more precise knowledge of the conditions under which they occur.

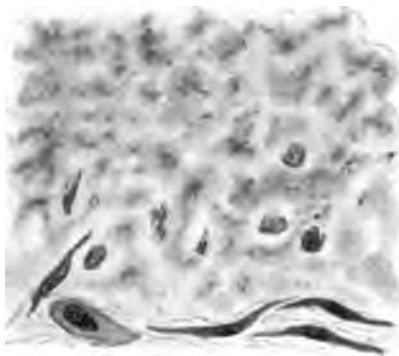


FIG. 39.—COAGULATION NECROSIS.
In tuberculous tissue.

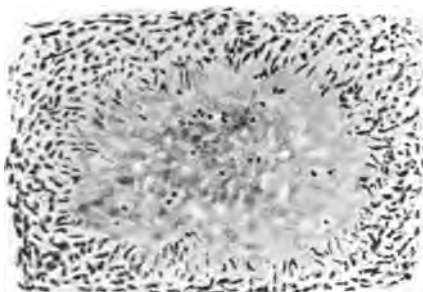


FIG. 40.—AN AREA OF CHEESY DEGENERATION
(CASEATION) IN A MILIARY TUBERCLE IN THE
LUNGS.

cast off, as in gangrene of a limb, or in bone, the dead portion here being called a *sequestrum*.

Fragments of dead cells and tissues in the living body are in part disposed of by leucocytes or other mesoblastic cells which may be attracted to them, and may cause their solution by proteolytic enzymes

FAT NECROSIS.—This is a degenerative process most frequent in the subperitoneal fat and in and about the pancreas, and especially associated with lesion of that organ. We refer for details to the special section, p. 704.

The Disposal of Necrotic Tissues.

—Necrotic tissues may be separated from the living body by inflammatory processes and wholly

which are set free or by the incorporation of particles of the dead tissue into their bodies where they are destroyed.¹

Furthermore, the absorption of necrotic tissues is in part due to proteolytic enzymes furnished by the dead and degenerating cells themselves. The self-destruction of tissues in the ways indicated is called *autolysis* (see p. 106). To what extent the lytic substances through which dead tissues are softened may be derived directly from the blood plasma is not yet clear. At any rate, through chemotaxis, phagocytosis, and autolysis considerable masses of necrotic tissue may be finally removed.² Dead bone is dissolved and disposed of by special forms of cells called *osteoclasts* (see p. 103).

Recent studies relating to the adaptation of the body to various alien substances have led to new conceptions of the nature of the processes by which the body frees itself of useless or harmful material either developed within it or introduced from without. For a fuller consideration of these processes see *cytolysis*, p. 171.

¹ See *Phagocytes*, p. 98.

² *Wells*, *Jour. Med. Res.*, vol. xv., p. 149, 1906.

CHAPTER IV.

PROGRESSIVE TISSUE CHANGES.

Hypertrophy and Hyperplasia.

HYPERTROPHY.—Under a variety of conditions, cells, larger parts of the body, or organs become larger than normal. The structural change to which this enlargement is due may be a simple increase in size of the elementary structures of the part, the cells. This is called *simple hypertrophy*. It is usually associated with some increased functional demand upon the cells and an increase in their functional capacity; as, for example, in the hypertrophy of the heart with lesions of the valves, or in the hypertrophy of one kidney, which in case of diminution or suspension of function in the other assumes the work of both—*compensatory hypertrophy*.¹

Pathological hypertrophy in response to functional demand—*functional hypertrophy*—has its physiological prototype in the changes in the uterus and in the mammary gland during pregnancy.

It should be borne in mind that the simple enlargement of a part or organ does not necessarily involve the hypertrophy of any of its structural elements. Thus there may be an increase of fat in a muscle causing its enlargement; waxy degeneration of the liver may determine great increase in the size of this organ. It is well to limit one's conception of hypertrophy to enlargement of specific structural elements of a part with maintenance or increase of functional capacity, and to consider other instances of enlargement, such as those just cited, as examples of *pseudo-hypertrophy*.

HYPERPLASIA.—In many cases the increase in size of a part or organ is due not only, or not at all, to the increase in size of its elementary structures, but to an increase in their number. This increase in number of the structural elements of a tissue or organ is called numerical hypertrophy, or *hyperplasia*.²

Hyperplasia of connective tissue is of frequent occurrence in association with atrophy of the parenchyma of various organs, replacing the damaged cells as these diminish or disappear. This is called *replacement hyperplasia*.

Hypertrophy and Hyperplasia in Special Organs.—In hypertrophy of the *heart* associated with the increased amount of work which it has to do in maintaining the circulation in various forms of valvular lesion,

¹ For bibliography of compensatory hypertrophy see reference to *Aschoff*, p. 79.

² Consult for examples of hyperplasia and hypertrophy the following sections on Regeneration and Inflammation.

pulmonary and vascular obstruction, or excessive bodily strain;¹ in hypertrophy of the unstriated muscle such as may occur in the bladder in urethral stricture, calculi, etc., in the stomach in pyloric stenosis, in the arteries in chronic diffuse nephritis; as well as in the voluntary-muscle hypertrophy from athletic exercises, etc., the individual muscle cells and fibers are increased in length and in thickness.

In hypertrophy of one *kidney* from the loss of the other or part of its own substance by operation or lesion, there is enlargement of the epithelium, especially of the convoluted tubules and of the glomerular epithelium covering the tuft, the latter being also enlarged. Changes in the collecting tubes and in the interstitial tissue are less marked even in kidneys which are greatly increased in size.

Compensatory hypertrophy of the *liver* following destruction of part of the parenchyma seems to be largely due to the new-formed liver cells, and to hyperplasia of the interstitial tissue, but the hypertrophy of the old cells occurs.

Compensatory hypertrophy of the *thyroid* and *adrenals* has been experimentally induced. Hypertrophy of one *testicle* occurs after the removal of the other, and the same is true of the *mammary gland*. Compensatory hypertrophy of the *ovaries* has not been observed.

After destructive injury to the *spleen* its function may be in a measure assumed by the bone marrow and lymphatic tissue which undergo compensatory hypertrophy.

In most of these conditions hyperplasia of the interstitial tissue is associated with the hypertrophy of the specific parenchyma cells whose response to increased functional demands is marked by simple hypertrophy.

Metaplasia.

In the development of the body there is a constant and progressive differentiation of cells. When development is complete a certain specificity exists, marked by functional and structural characters. These specific characters in cells are fairly permanent under normal conditions. Under a variety of abnormal conditions, however, they may undergo modification so that one type of cell or tissue may assume more or less completely the characters of another type. But the limitations of this change in type are strictly drawn, so that one type can assume only the characters of another which is closely related to it. This change of one form of closely related tissue into another is called *metaplasia*.

Thus, by a gradual change in the cells and stroma of fibrous tissue, this may be converted into bone, as mucous tissue may become fat tissue, and hyaline cartilage become fibrous. Metaplasia is a process involving active changes on the part of the living cells of the tissue, and should be clearly distinguished from certain degenerative and infiltrative processes, in the course of which one form of connective tissue may assume super-

¹ For conditions of cardiac hypertrophy see p. 550. For a fuller consideration of the phases and conditions of hypertrophy see *Adami "Principles of Pathology,"* i, p. 535.

ficial resemblances to others of the group, as in calcareous and mucoid degeneration.

The infiltration of the cells of fibrillar connective tissue with fat, and the reverse process in which the fat is lost, as in atrophy and emaciation, are not, strictly speaking, examples of metaplasia.

While metaplasia is most common among the members of the connective-tissue group, it sometimes occurs in other tissues. Thus, for example, the epithelium of the nose, bronchi, urinary passages, cervix uteri, and gall-bladder may under a variety of conditions assume the characters of squamous epithelium of the skin type.¹

One should be critical in estimating the value of evidences of metaplasia, which has apparently been assumed to occur more frequently than the facts justify. For example, many instances of alleged metaplasia can be equally well accounted for on the assumption of defects of development in which a certain portion of tissue has failed to complete its differentiation, thus remaining in form and in situations which simulate the results of metaplasia. Or, cells of the differing types may have grown into the region from adjacent parts.

When differentiation has advanced so that such distinct types of tissue have been formed as connective tissue, epithelium, muscle, nerve, these do not again merge through metaplasia. There is no evidence that mesoblastic tissues can be converted into those of the epiblastic or hypoblastic type or *vice versa*.

Reversion.

Under various conditions, but especially when highly differentiated cells have been thrown out of function often as the result of inflammatory processes, they appear to assume the morphological characters which belong to an early stage in their development. This is called *reversion*, *reversionary metamorphosis* or *kataplasia*. Thus the flat epithelium of the air vesicles of the lungs or the cylindrical epithelium lining the bronchi or the stomach may become cuboidal. In the kidney the epithelium of the glomeruli and also of the convoluted tubules may become cuboidal. So in chronic peritonitis the endothelium may become greatly thickened. Muscle fibres and connective-tissue cells may assume for a longer or shorter period distinctly embryonic forms. But here, as in metaplasia, one should accept the morphological evidence of reversion with due reserve, since in many instances the cells in question of the lower type may be the results of a reparative process not yet complete, and may have been derived from newly-formed cells.² Furthermore the shape of cells in general is so closely dependent upon nutrition, pressure, and mutual relationship that even slight departures from these may lead to changes in form quite as marked but not of such significance as those involved in reversion.

¹ For references to epithelial metaplasia see *Menetrier* in *Bouchar'd's "Traité de path. gén.,"* t. iii., pt. 2, p. 784. See also for a discussion of metaplasia *Ribbert's "Lehrbuch d. allg. Pathologie,"* 2d edition, 1905, p. 323, and "Geschwulstlehre," 1904. Also *Adami, "Principles of Pathology,* vol. i, p. 586.

² See *Ribbert's "Geschwulstlehre,"* p. 15, 1904. Also for general review of reversion and growth in tissues see *Adami, "A. Jacobi Festschrift,"* 1900, p. 422, and in his *Pathology,* i, p. 810.

Regeneration.

General Considerations.—It is during the earlier periods of life that the new formation of cells in the body is most active. From the fertilization of the ovum until the tissues and organs have assumed the varied forms and functions which the physiological division of labor among the cells imposes, cell proliferation and cell adaptation to a changing environment are constant and important features of individual development. After this time, under normal conditions, new cell formation is largely limited to the replacement of worn-out cells or to the restitution of such cells as may be sacrificed in the performance of their physiological functions.

The studies of Bizzozero have shown that, notwithstanding the great diversity in the capacity for physiological regeneration among tissues, they may be conveniently grouped into three classes, as follows: *First*, tissues whose cells are capable of multiplication throughout the life of the individual or for a considerable period after maturity, and so lead to a continual regeneration. These are tissues whose cells are labile and evanescent. In this class are the parenchyma cells of those glands or structures which produce formed elements, such as the spleen, lymph-nodes, bone-marrow, ovary, testicle. Also the epithelium of the skin with its hair follicles and sebaceous glands, and of the mucous membranes of the respiratory, digestive, and genito-urinary organs. *Second*, tissues whose elements increase by division up to the time of birth, or sometimes for a short period thereafter, when evidence of physiological regeneration ceases. These are tissues with permanent cells. In this class are the parenchyma cells of those glands which secrete fluid material, such as the liver, kidney, pancreas, salivary glands, etc. Also members of the connective-tissue group, fibrous tissue, cartilage and bone, and the smooth muscle fibres. *Third*, striated muscle and nerve tissue. In these tissues, division by mitosis ceases at an early period and before the tissues have acquired their special characters. Here a physiological regeneration does not occur.

This grouping of tissues in accordance with their capacity for physiological regeneration, while liable to modification under further research, affords a suggestive guide in our studies of regeneration under abnormal conditions. For beyond the regenerative capacity normally exercised by cells in response to the physiological wear and tear of life, they are frequently called upon to make good unusual losses, as the result of many forms of injury.

Regeneration of injured tissues, all new growths, as well as the hyperplasias above mentioned, are invariably brought about by proliferation or other changes in living cells. Furthermore, just as the cells of the adult organism are the offspring of one original cell, the ovum, so are all the new cells which appear in the body under abnormal conditions derived from pre-existing cells by division.

We shall now briefly summarize the morphological changes which cells undergo in division and shall then indicate the degree of regenerative capacity which various forms of tissues possess.

MODES OF CELL DIVISION.

The careful and minute study of cells during the act of division, which has been recently made, has revealed many most curious phenomena and has opened a new world of observation nearer to the elementary expression of life than has seemed possible in earlier times. It will

suffice for our purpose briefly to indicate some of the more striking features of the new cell lore.

It is well to recall at the outset that recent studies of cells have shown that even in their simplest forms they are highly organized, and that their different parts have special functions to perform. Thus the nucleus presides over the constructive metabolism or assimilative process of the cell and furnishes the physical basis upon which the transmission of hereditary characters depends. The cytoplasm of the body, on the other hand, is concerned in those phases of metabolism which result in the liberation of energy in movements of various kinds and in the formation of new chemical substances. The centrosome also in certain cells, though not apparently in all, appears to play an important part in the changes incident to division.

Two modes of cell division are commonly recognized. First, *indirect division* (mitosis, or karyokinesis); second, *direct division* (amitosis).

INDIRECT (MITOTIC) CELL DIVISION.

This is the most common mode of cell division and is especially characteristic of embryonic cells and those which are undergoing active development. While it presents great variations, its general features may be thus briefly summarized:

Among the earlier changes which are to be seen in a cell about to divide by mitosis are a condensation and an increase in the staining capacity of the chromatin of the intranuclear network. This chromatin substance gathers into a contorted thread or threads, called the *spiremes* (Fig. 41, 2), within the nucleus, whose membrane with the nucleolus gradually disappears so that the spireme lies free in the cytoplasm; and at the same time with, or preceding, these changes in the nucleus, there may be a division of the centrosome when this is present, the segments resulting from this division passing to opposite parts of the cell, usually outside the limits of the nucleus. Around each of the new centrosomes, which stain deeply with hæmatoxylin or other nuclear dyes, may be a clear zone of unstained material, or a series of fine radiating fibrils, or both; the whole forming a structure called a *polar body* (Fig. 41, 2 and 3).

Now the threads of the spireme break across transversely, forming a series of more or less rod-like bodies called *chromosomes*, which form a somewhat flattened cluster or wreath between the polar bodies, lying in a plane at a right angle to a line passing between the latter.¹ While this mass of chromosomes—sometimes called the *monaster*—has a stellar or wreath-like appearance when seen from the side, it is more band-like when viewed in profile (Fig. 41, 3 and 4).

Between the polar bodies and across the monaster there may now be stretched a bridge or spindle of delicate fibrils resembling those about the centrosome in the polar bodies.

¹ It is believed that every species has a fixed and characteristic number of chromosomes in the dividing cells, and that in forms arising by sexual reproduction this number is even. In man the number is believed by some to be 16, by others 32.

This fibril-spindle, together with the polar bodies, is called the *achromatic figure* in distinction to the structure formed from the chromatin, which stains with nuclear dyes, and is called the *chromatic figure*.

The whole complicated structure composed of both the chromatic and achromatic substance constitutes the *mitotic figure*.

Now each chromosome splits lengthwise into exactly equal parts. These parts separate into groups which pass to the polar bodies at opposite ends of the spindle. This is sometimes called the *diaster phase* of mitosis (Fig. 41, 5 and 6).

Corresponding to the division of the chromosomes into equal parts, the cell body divides, each part containing one of the groups of daughter chromosomes or diasters, together with one polar body and a part of the achromatic spindle (Fig. 41, 6). Now a new nucleus is formed

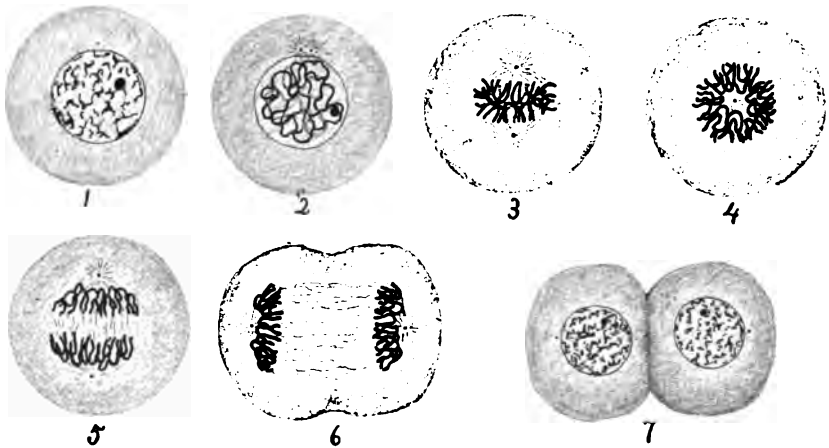


FIG. 41.—PHASES OF MITOSIS.

1. Resting cell. 2. Spireme phase: the centrosome has divided, the polar body is seen above, the nuclear membrane has not yet disappeared. 3. Monaster phase: the polar bodies have arranged themselves on either side of the monaster, here seen from the edge. 4. The monaster seen from the side. 5 and 6. Diaster phase: the chromosome clusters have separated and the achromatic figure is seen. In 6 the segmentation of the cell body has begun. 7. The completion of the nuclear division and segmentation of the cell body.

about the daughter chromosomes which gradually assume the characters of the resting intranuclear network (Fig. 41, 7). The achromatic fibrils disappear from the new cell, while the centrosome may also disappear or may take its place in the cytoplasm beside the new nucleus.

There are countless variations and details in the minute processes of mitotic cell division and much interesting conjecture as to the meaning of the various changes in mitosis, which the scope of this work does not permit us to consider. But the facts already at hand are of extreme significance to the biologist and point toward large fields of research in pathology when the normal processes shall have been more clearly and exhaustively determined.

Abnormal phases of mitosis are not infrequent. Thus, the mitotic fig-

ures may be asymmetrical, so that the distribution of chromatin substance to the daughter cells may be unequal (Fig. 42). There may be multipolar mitosis, so that, instead of two, several nuclei may form. Or, the new-formed chromosome masses may fail to share in the formation of the new nuclei.

Such abnormal mitoses are frequent in certain tumors, and they may be experimentally induced by the application of various chemical substances to living cells. Too little is known about the conditions under which abnormal mitoses occur, and too little about the nature of the impulse to cell division in general,

to justify to-day far-reaching conclusions as to the significance of these interesting abnormalities in the life of the cell.

The Significance of Mitosis.—The term *mitosis* or *karyomitosis* is applied to this indirect mode of cell division, on account of the involvement of the nuclear threads. It is also sometimes designated as *karyokinesis*, from the form changes which these threads undergo. Aside from its intrinsic biological interest, a knowledge of mitosis in proliferating cells is of importance in pathology, because the recognition of mitotic figures often enables us to decide with certainty what particular cells or cell groups are involved in the formation of new tissue. The most significant feature, however, of the whole process of mitosis, with all its intricate variations, appears to be that the chromosomes, during their separation into two or more clusters to form the basis of new cells, undergo an exact longitudinal division. So that, under normal conditions, no matter how unequal the division of the cytoplasm may be, all of the new nuclei share alike in the chromatin substance of the parent nucleus. This fact appears to be of extreme importance in the recognition of a physical basis of inheritance.¹




FIG. 42.—ABNORMAL PHASES OF MITOSIS. In both cells the mitosis is asymmetrical, and in the cell to the left tripolar.

DIRECT (AMITOTIC) CELL DIVISION.

In this, which although relatively rare, appears to be the most simple mode of cell division, without those preliminary changes in the nucleus which are seen in the mitotic cell division, the nucleus with its membrane becomes constricted and finally divides into two or more parts which become new nuclei. At the same time or following this simple nuclear division the cell body divides, and thus two or more cells may form in the place of one. Sometimes the nuclear division is not followed by a division of the cell body, and thus multinuclear cells, or "giant cells," may be formed.

¹ See summary by Wilson, *Science*, Feb. 24, 1905. For a résumé of physiology and pathology of the nucleus see Adami, *Brit. Med. Jour.*, Dec. 22, 1906, p. 1760. Consult also Adami on development and inheritance, "Principles of Pathology," vol. i.

The significance of the difference between the amitotic and the mitotic cell division is that, while in the former there is an exactly even division of chromatin to the daughter nuclei, the division in the latter is of the nuclear mass as a whole.

Amitotic, as well as mitotic, division occurs in leucocytes, in some forms of epithelium, and in pathological new formations. While the nature of the process is little understood, there appears to be much reason for the belief that, in general, amitotic division is "characteristic of highly specialized or degenerating cells in which development is approaching its end."¹

GENERAL CHARACTERS AND LIMITATIONS OF CELL REGENERATION.

It should be borne in mind, in studying the regeneration of various kinds of cells and tissues, that the acquirement by certain cells of special functional powers as the result of the physiological division of labor has involved the impairment of some of their more primitive general capacities, among these that of reproduction. Thus it is that we find in the ganglion cells an almost total lack of reproductive capacity; while in many of the gland cells this is slight, in others considerable. In some of the less highly differentiated cells of the body, on the other hand, as in certain forms of epithelium, in blood cells, and in the cells of the connective tissue, this primitive capacity of protoplasm to form new similar cells by division is maintained, and may be evoked by the changed conditions which injury or loss involves.

Although the occurrence of mitosis is the mark by which we especially recognize the regenerative process in cells, it should be remembered that mitosis or some of its phases may occur in cells, without being followed by those further changes which lead to new cells or new tissues.²

We may also often recognize new-formed cells and tissues by differences in the shape and character of the cells and the arrangement of the tissue elements, these often approaching the embryonic type in form as well as in character of development. Furthermore, the atypical arrangement often seen in new-formed cells, both in regard to each other and in their association with older tissues, may aid in the identification of the formative process.

Individual cells, even after having undergone marked structural changes—as, for example, in albuminous degeneration—or after a certain degree of physical injury, may be restored to a normal condition.

After destructive injury or loss, a full and complete replacement of cells and tissues can occur only as the result of a proliferation of cells of the same type as those to be restored. Thus a regeneration of epithelium occurs by proliferation and growth of epithelial cells alone; regen-

¹ For a comprehensive summary of facts and theories concerning the cell, both in higher and lower forms of life, consult *Wilson's* masterly work, "The Cell in Development and Inheritance."

² One is often disappointed in seeking for mitotic figures to find so few of them even in rapidly growing tissues. This is due to the fact that cell division even when active is not continuous, and periods of rest may follow the act of division. See *Thoma's* "Text-book of General Pathology," English Tr., vol. i., p. 481.

eration of muscle by muscle cells, etc. In fact, however, in the higher types of tissue, after considerable injuries with loss of substance or after destructive pathological processes, complete regeneration is not common. This, as we have seen, is because the highly specialized cells of the body are limited in their capacity for reproduction closely to the domain of physiological regeneration. What we ordinarily call healing in extensive wounds of the more highly specialized tissues is usually a provisional makeshift repair by means of new-formed connective tissue.

We have seen that the regenerative capacity in the cells of the human body is most marked in the less highly differentiated types of cells, and that it is above all connective tissues, blood-vessels, and epithelium which most freely and most completely undergo regeneration. These are relatively lowly organized tissues and serve for the maintenance or protection of more highly specialized tissues, and with them regeneration may be complete with full restoration of function.¹ But although the more highly organized tissues in man do not undergo after injury any considerable regeneration, they are, when uninjured, capable, under the stimulus of increased functional exercise, of compensatory hypertrophy, so that the loss to the organism of similar tissue is made good, an example of which is the structural hypertrophy and increased performance of one kidney after the removal of the other.²

The capacity to regenerate lost or injured parts exists to a certain extent in all animals but is most marked among the lower forms. Thus if an amœba be cut in two so as to leave one part with the intact nucleus, this part lives and the one-celled organism is completely restored. The fresh-water hydra, composed of many cells, may reproduce a large portion of the organism from a small severed fragment. The common earth worm can reproduce a severed head or tail. Crabs reproduce a whole leg if the severance takes place at a particular joint. Salamanders, snails, etc., can reproduce a leg and tail. It is further noteworthy in this connection that the larvæ of many lower forms, such as reptiles and insects, have a much greater capacity for the reproduction of lost parts than the same species have when in the adult condition.³

REGENERATION OF SPECIAL TISSUES.

Regeneration of the Nerve Tissue.—In the nervous system we find no evidence that the ganglion cells are capable of reproduction. Some phases of mitosis are occasionally found in them, although they do not appear to lead to proliferation. But if the essential parts of the ganglion cells, including the nuclei, be intact, a restoration may occur of their central as well as their peripheral branches. The fibrous and the neuroglia tissue of the central nervous system, on the other hand, may increase, and

¹ Consult *Morgan*, "Regeneration," Columbia University, Biol. Ser., 1901.

² For an illuminating discourse on the surplus of functional provision in the body see *Meltzer*, "The Factors of Safety in Animal Structure and Animal Economy," Harvey Lecture, 1907, reprinted in *Jour. Am. Med. Assn.*, xlviii, 655, 1907.

³ For a suggestive study of the laws of growth and changes in cells and tissues during development, and their relationship to the nature and cause of old age, see *Minot*, Harvey Lectures, 1905-1906. Also *Pop. Sci. Monthly*, lxxi, 1907.

in this way, even with considerable loss of substance, injuries to the brain and cord may undergo a sort of patchwork repair.

In the peripheral nerves a considerable regeneration of fibres may take place after injury, when the corresponding ganglion cells are intact. This restoration may be effected in part by fibrous tissue which bridges the damaged region and affords guides or channels along which the axis cylinders may grow out from the uninjured central segments, finding their way to their endings, as in embryonic development they stretch into the tissues far from the ganglion cells in which they originate. The restitution is possible here because the centre of nutrition and at least a limited reparative control in the ganglion cell are intact.

Further details as to degenerations and regenerations of nerves and nerve tracts may be found in the chapter devoted to The Nervous System.

Regeneration of Muscle Tissue.—Regeneration of *smooth-muscle tissue* after injury is slight. Mitosis may occur in the cells and preliminary phases of division of the body have been described, but it is doubtful whether, except possibly to a very slight extent, new cells are formed. Such healing as occurs after wounds and other injuries is largely effected by new-formed fibrous tissue.

A partial regeneration of *striated muscle* occurs after various forms of damage and losses of substance. There may be division by mitosis in the sarcolemma nuclei (Fig. 43) associated with the accumulation near



FIG. 43.—REGENERATION OF STRIATED MUSCLE AFTER INJURY.

The nuclei of the sarcolemma have proliferated and are surrounded by a small amount of non-striated protoplasm.

them of granular protoplasm, which becomes striated, either *in situ* or as independent cells. At the injured end of the muscle fibre a similar process may occur, so that these damaged fibres may be in part restored. If as the result of the injury some of the nucleated protoplasm escapes from the sarcolemma, a similar development of striated cells and cell masses may occur.

It is especially in certain forms of degeneration of the contractile substance, after typhoid fever for example, in which the nuclei, the sarcolemma, and the general framework of the tissue are uninjured, that regeneration of striated muscle fibres is most complete. After injuries with considerable destruction of the muscle tissue, regeneration is apt to be irregular and incomplete. While there is often much nuclear division and often the formation of large numbers of more or less striated and variously shaped cells, these are apt not to develop into useful muscle fibres and may disappear by degeneration and absorption or by

pressure atrophy. Here, as elsewhere in highly organized tissues, such restitution as is possible after considerable injury is achieved by fibrous tissue.

It is interesting to note that such regeneration as does occur in striated muscle is not initiated by the highly differentiated contractile substance, but by the nuclei and small residual amount of undifferentiated protoplasm, and that such more or less definitely striated cells as are formed are in many respects similar to certain forms of developing muscle cells in the embryo.

Although mitosis and nuclear division have been seen in the muscle fibres of the heart after injury, there is no evidence that new muscle can be formed. Repair, which is not infrequent, is secured by fibrous tissue.

Regeneration of Epithelium.—Owing to continuous shedding or to functional destruction of epithelium of the skin and mucous membranes and certain of their adnexa, physiological regeneration by mitosis is common.

After injuries, also, regeneration of epithelium in these situations occurs by mitosis and may be extensive and complete. The new epithelium always forms from the old, and, when surface losses are to be made good, extends inward from the edges across the injured area after a suitable substratum has been formed by fibrous tissue and blood-vessels (Fig. 44).

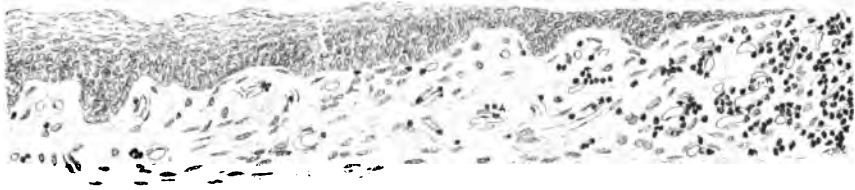


FIG. 44.—REGENERATION OF EPITHELIUM.

From a wound of the tongue. At the left is normal epithelium; at the right the thin pellicle of new-formed cells is extending over the surface of the wound.

The new epithelium is at first atypical in form and arrangement owing to the necessity for a gradual adaptation to the sustaining and associated tissues. Thus the epithelium, which at first presses forward over a healing wound of the skin, may be in the form of an irregular layer of cells (see Fig. 45) or of a thin smooth pellicle without the usual variations in size and shape by which it is later characterized when the papillæ of the new cutis are formed and the new cells have adjusted themselves to these and to each other.¹ In stratified epithelium it is the deeper layers from which the new cells chiefly arise. While amitotic division has been observed in the restitution of surface epithelium, this occurs in the more superficial cells and is believed not to be concerned in the regenerative process.

Regeneration of gland epithelium after injury is of frequent occur-

¹ For a study of the regeneration of mucous membranes see *Cornil and Carnot, Arch. de méd. exp., tome xi., p. 413 1899.* For repair of bladder mucosa, *Lasio, Virch. Arch., Bd. clxxviii., p. 65, 1904.*

rence, though this capacity varies considerably in different glands. In many cases it appears to be by a proliferation of the epithelium lining the smaller excretory ducts that the restitution is accomplished, rather than by the more highly differentiated secreting cells. This is of especial interest because it affords an excellent example of the rehearsing under abnormal conditions and for reparative ends of a developmental phase of cell life.

In the *liver* very extensive new formation of liver cells may occur after experimental removal of a portion of the organ. These new cells arising largely from the epithelium of the small gall-ducts do not form real liver tissue, however, since in this a definite relationship must exist

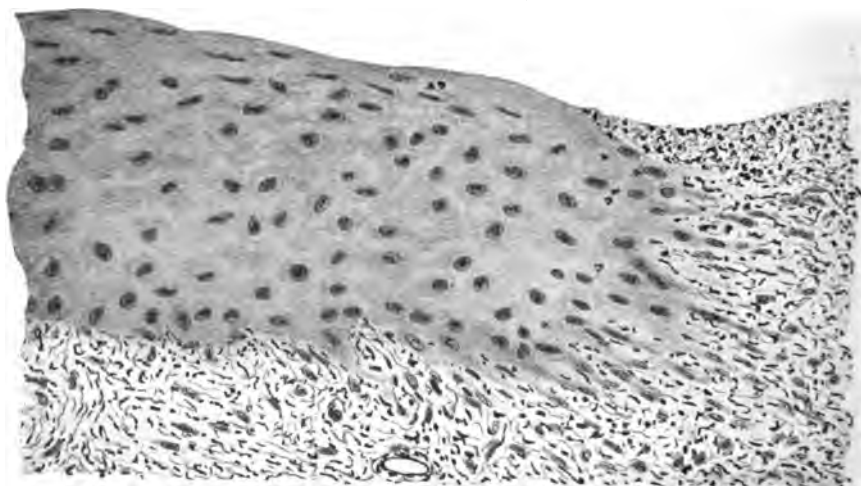


FIG. 45.—REGENERATION OF EPITHELIUM.

The epithelial cells advancing into and over the superficial portion of the granulation tissue at the right are fusiform and irregular in shape. They do not until later assume their usual forms and their relationships to one another and to the underlying tissue.

between the liver cells and the gall-ducts, the blood-vessels and the interstitial tissue. Such a relationship can be secured only under the conditions of embryonic development when all the various tissues involved are being formed together. After large destruction of liver cells in certain forms of toxæmia—called acute yellow atrophy of the liver—there may be an extensive and successful regeneration because the associated tissues are not at the same time destroyed.

In the *thyroid gland* new gland tissue may be formed after injury.

In the *kidney* the regenerative capacity of the epithelium appears to be less marked, though proliferation of the epithelium of the collecting tubes may take place and epithelium to a considerable extent may be renewed if the blood-vessels and interstitial tissue remain intact.¹

Regeneration of epithelium to a considerable extent may take place in the *mammary* and *salivary glands*. But here it is the less highly dif-

¹ Consult *Pearce*, Jour. Med. Research, vol. xx, p. 53 1909.

ferentiated cells of the excretory ducts rather than the secreting epithelium through which regeneration is secured. In the *ovary* and *testicle* a slight amount of regenerative capacity may be manifested through mitosis and division of epithelium, but its results are insignificant. The pancreas and spleen show little or no capacity for regeneration.¹

In all these cases of partial regeneration it is often difficult to determine how much of the increase in parenchyma, which undoubtedly does occur, is due to a formation of new gland tissue and how much to a compensatory hypertrophy of the old. While, therefore, it is true that after injuries to the glands a considerable regeneration of epithelium may occur, when the loss of substance is extensive it is usually rather by a fibrous-tissue repair or by a compensatory hypertrophy or hyperplasia in the uninjured portions of the organ than by the new formation of true gland tissue that restitution occurs.

Regeneration of Connective Tissue.—We have seen again and again in reviewing pathological regeneration that, in local restoration after injury, fibrous tissue plays an important part, either by itself or in association with various forms of parenchyma. New fibrous tissue readily forms in the adult to replace tissue which has been destroyed. It results from many kinds of prolonged chemical and mechanical irritants. Atrophy of the parenchyma may be followed by interstitial fibrous-tissue growth, or new fibrous tissue may develop under the influence of bacterial and other toxic substances, and it frequently forms dense capsules about the seat of old lesions or around foreign bodies.

Many forms of compensatory fibrous-tissue development will be described in the second section of this book, such as thickening of the walls of blood-vessels, inflammatory adhesions, replacement hyperplasia, etc.

We have now to consider briefly the changes involved in the new formation of this fibrous tissue. Here, as in all other tissues of the body, it is the cells alone which take the initiative, the formation of intercellular substance being always secondary to the formation of the cells and always occurring under their influence.

New connective-tissue cells may be formed by mitosis (Fig. 46), either from older connective-tissue cells, or, as now seems certain, from the endothelium of the blood-vessels² and possibly from the so-called

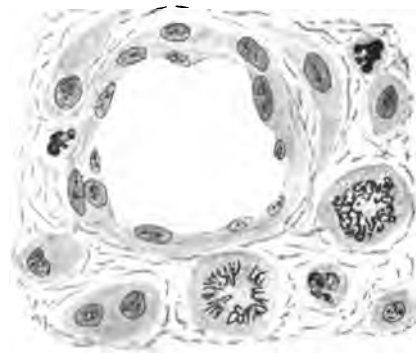


FIG. 46.—MITOSIS IN GRANULATION TISSUE.

Two of the new-formed connective-tissue cells show mitotic figures. Three leucocytes have wandered into the new tissue.

¹ For a study of compensatory hypertrophy of hæmolympf-nodes after removal of spleen, see Weidenreich, Arch. f. Mik. Anat., 1905, bibl.

² See Baumgarten, Arbeiten, Path. Inst. Tübingen, Bd. iv., p. 310.

"plasma cells."¹ In either case the cell about to divide shows an increase in the size of the body, which becomes more granular; the nucleus divides by mitosis, segmentation of the cytoplasm following. This process may be repeated so that many cells are derived from one, separated at first by a small amount of homogeneous intercellular substance. These cells, at first more or less spheroidal in form, may become larger, and polyhedral or elongated. Little by little, fine fibrils appear between the cells, sometimes apparently as extensions of their cytoplasm, sometimes along their sides in the homogeneous material in which they lie. Such new connective-tissue cells concerned in the formation of fibrillar stroma are called *fibroblasts* (Fig. 47). As the fibrous stroma increases in amount



FIG. 47.—REGENERATION OF CONNECTIVE TISSUE.

Showing fibroblasts with a few new-formed intercellular fibrils between them. The walls of the blood-vessels are very thin.

the cells, at first relatively abundant, become elongated and flattened, until as the new tissue approaches maturity the more or less dense fibrillar stroma preponderates, pressing the cells between its bundles or layers into variously shaped plaques, often fusiform or linear in profile.

In the formation of fibrillar connective tissue from endothelium the endothelial cells of thin-walled blood-vessels increase in size, stretch slender bud-like extensions into the adjacent tissue, where, after mitotic division, they assume a rôle altogether identical with that of the ordinary connective-tissue cell.

¹ PLASMA CELLS.—It is believed by many that the so-called *plasma cells* are frequently and largely concerned in the formation of new fibrous tissue. Plasma cells are rounded or polyhedral or elongated, depending upon their situation, and vary in size from that of a leucocyte to many times this size. The rounded or oval nucleus is usually excentric and commonly shows several irregular groupings of chromatin masses just beneath the membrane. The body of the plasma cell is especially characterized by the staining of its protoplasm by basic anilin dyes—the polychrome methylene blue of Unna, for example. The staining is commonly less intense near the nucleus and is otherwise frequently uneven.

Such cells occur normally in the bone-marrow, spleen, lymph-nodes, and gastro-intestinal mucosa of man, and may be found under various pathological conditions, especially in hyperplasia and the new formation of fibrous tissue. It is believed by many observers that plasma cells are direct derivatives of the small mononuclear lymphocytes, and that when these gather in the tissue by emigration, they may either undergo degeneration and destruction, or, on the other hand, they may become connective-tissue cells and share as fibroblasts in the formation of fibrillar stroma. Other observers believe some forms, at least, of plasma cells to be simply fibroblasts which have assumed a spheroid form. The origin and significance of "plasma cells" are not yet altogether clear, and we must refer to larger works for further data. See "Critical Summary of Recent Literature," by Williams, American Journal of the Medical Sciences, vol. cxix., p. 702, 1900. also "Plasma Cells in Liver," *Porcile*, Ziegler's Beitr., Bd. xxxvi., p. 375, 1904.

The formation of new connective-tissue cells may be large or it may be limited to the production of a single pair of cells; the stroma may be scanty or abundant, loose or dense; the process is essentially the same, namely, the division of cells by mitosis, and the formation by them, or under their influence, of more or less fibrillar stroma. This process, it will be seen, is practically identical with the formation of fibrous tissue in the embryo.

But here, as elsewhere, the character and extent of new tissue production are largely influenced by the environment, and particularly by the nutritive supply, so that the formation of new connective tissue in any considerable amount is closely linked to the development of blood-vessels.

Regeneration of Endothelium.—The regeneration of *endothelium*, which seems to be closely related to that of connective tissue, takes place readily. The new cells advance over denuded surfaces in a manner similar to that in epithelial repair. Whether the new cells always originate in the old neighboring endothelium or may be more directly derived from fibroblasts is not yet fully determined.

The Formation of Blood-Vessels.—The formation of blood-vessels in post-embryonic life is believed always to start in a budding or sprouting



FIG. 48.—DEVELOPING BLOOD-VESSELS IN NEW-FORMED TISSUE.

of the endothelial cells of pre-existing capillaries. The sprouts, directed outward from the endothelia of the capillaries, consist at first of buds, then of slender, conical, or filiform projections of cytoplasmic substance (Fig. 48). Now the cytoplasm of the cell from which the sprout springs may increase in amount and its nuclei divide by mitosis, so that the base of the sprout may consist of a multinuclear mass of cytoplasm or of a cluster of new-formed cells. The sprouts may extend for a long distance into the surrounding region, whether this be already organized tissue in which the vessels are increasing in number or unorganized lifeless material like blood-clot, which is to be replaced by new living structures. If a similar process be in progress in neighboring vessels, the sprouts may unite at their extremities, forming a slender solid protoplasmic bridge

from vessel to vessel. The sprouts now become thickened and gradually channelled out at the base by pressure of the blood in the vessel from which they spring. The blood enters these lengthening channels, forcing its way along them, forming a lumen as it goes. Simultaneously with this advance of the lumen, new nuclei are formed by division of the old along the sides of the vessel, and the new structure gradually assumes a distinctly cellular and vascular character. At length the channel is complete; the new vessels have well-defined endothelial walls and connective-tissue cells from without, or new connective-tissue cells which have been formed about the nuclei of the protoplasmic sprout, range themselves outside along the walls. So the new vessel takes its place in the vascular system of the part. Thus, in a short time, many new blood-vessels may form, furnishing nutritive centres about which the organization of tissue proceeds.

In the new formation of arteries it is believed that the smooth-muscle tissue is formed by a growth along the developing vessel from a pre-existing artery.

The Formation of Lymph-Vessels.—The formation of lymph channels in granulation tissue takes place in the same way as that of blood-vessels, the process being initiated by the formation of buds from the endothelium of existing vessels which push their way out into the new tissue, gradually acquiring lumina and forming anastomoses with other trunks.

Regeneration of Cartilage and Bone.—New *cartilage* may form by the proliferation either of connective-tissue cells or, to a slight extent, of cartilage cells, and the formation about the new cells of the characteristic basement substance. It is the connective-tissue cells of the perichondrium from which especially new cartilage is formed.

The new formation of *bone* under pathological conditions is not brought about by the bone cells, but by the development, first, from the cells of the periosteum or of the marrow, of a cellular connective tissue, or from the perichondrium of a form of hyaline cartilage. From these tissues, by processes essentially similar to those in the embryonic development, the new bone is formed under the influence of osteoblasts (see p. 876).

The regeneration of *bone marrow* takes place through the activities of the characteristic marrow cells together with those of the blood-vessels and cells of the connective tissue and osteoblastic type.¹

Regeneration of Lymph-Nodes.—Regeneration of lymph-nodes may take place after partial removal. This appears to be more complete in the earlier years of life. After extirpation of lymph-nodes it has been shown experimentally that new nodes may form. These Bayer believes develop from fat tissue. Further studies are needed in the regeneration of lymph-nodes and the relationship of these and lymphatic tissue to fat and other forms of connective tissue.²

¹ For studies on the regeneration of bone marrow, see *Haasler*, Arch. f. klin. Chir., Bd. l., p. 75 1895, and *Enderlen*, Deutsch. Zeits. f. Chirurg., Bd. lii, p. 293, 1899.

² Consult for bibl. of regeneration of lymph-nodes and lymph-vessels, *Meyer*, Johns Hopkins Hosp. Bull., vol. xvii., p. 185, 1906.

Regeneration of Fat Tissue.—Fat tissue is formed by the accumulation of fat droplets in the cells of various types of connective tissue, particularly in the young or embryonic forms; but adult connective tissue may change into fat tissue by a similar process. The repair of fat tissue takes place by the formation of young fibrous tissue, whose cells and stroma gradually assume the type of fat tissue. The cells of regenerating fat tissue are at first more or less spheroidal, and remnants of the cytoplasm may be seen as more or less crescentic masses pressed to one side by the accumulating fat (Fig. 49). New fat tissue which replaces atrophied organs or parts of organs, such as kidney, heart, lymph-nodes, etc., is formed in the same way.¹



FIG. 49.—REGENERATION OF FAT TISSUE.

The new-formed fat cells show a rim of cytoplasm containing the nucleus, which has been crowded to the sides of the cells by the accumulating fat.

Regeneration of Blood.—The formation of leucocytes appears to occur chiefly in the masses of lymphoid and myeloid tissue which are so widely scattered in the body in the lymph-nodes, in the spleen, and in the bone-marrow. The polynuclear leucocytes are formed in the bone-marrow, but their development may be completed in the circulating blood. Both mitotic and amitotic cell division are to be observed in the new formation of leucocytes, but the exact relationship between the new cells produced in these two ways, and their respective destinies, are not yet very clear. Regeneration of *red blood cells* seems to occur in the bone-marrow and probably in the spleen and hæmolymp-nodes through mitotic division of nucleated forms. The latter may, under pathological conditions, appear in the vessels in varying numbers (see Part II., Chapter I.).²

TRANSPLANTATION OF TISSUE.

Transplantation of various types of tissue has been frequently attempted, and is, on both theoretical and practical grounds, of considerable interest. Transplantations have been successfully made from

¹ For a study of regeneration, inflammation, etc., in fat tissue see *Kraus*, *Zeits. f. Heilkunde*, Bd. xxvii., p. 243, 1906.

² For a general and extended study upon tissue regeneration see *Marchand*, *Die Wundheilung*, Leipzig, 1901.

one part of the individual to another—*autoplastic*—or from another individual of the same species—*heteroplastic*.

A variety of general conditions favor successful transfer. The tissue to be transplanted must be alive and in good condition; young tissues are more readily transferred than old; the site to which the transfer is made must be adapted to the growth of the graft. A great difference is observed in the success of transplantation of various types of tissue. Thus, the epithelium of the skin and various forms of connective tissue may be, under favorable conditions, readily transplanted, and produce new tissue of similar type. Thus, deeply implanted epidermal tissue may grow and produce considerable new tissue, especially in the form of cysts resembling either simple or complex dermoid cysts. Experimental transplantation of various gland and other special forms of tissue, such as portions of the kidney, liver, sebaceous, salivary and mammary glands, testicles, ovary, periosteum, bone, and cartilage, show that there may be at first, if the conditions be favorable, a slight proliferation of the transplanted tissue cells. Together with this growth in the better-nourished parts of the tissue grafts there is apt to be a more or less extensive necrosis of other portions. But the proliferative activities of transplanted gland tissue are, as a rule, not permanent; they presently cease and sooner or later these tissues, with necrotic portions of the grafts, are absorbed.

Transplantation of epidermis for practical purposes has become a part of surgery, aiding in the repair of surface losses of skin. The graft properly implanted upon the granulating surface becomes closely attached by the growth into it of new connective-tissue cells and blood-vessels. The old connective tissue of the graft, as well as most of the epithelium, especially the superficial layers, usually dies and is cast off or absorbed, while new epithelium formed from the remaining cells makes its way over the granulating surfaces.

In transplantations of bone the grafts seem to furnish a nidus into which, hand-in-hand with its absorption, new bone grows under the influence of osteoblasts of the old periosteum, but does not itself apparently share in the new production of bone tissue.

Portions of the thyroid gland and of the ovary have been successfully transplanted.¹

Carrel has found that heteroplastic transplantations of whole organs—kidney, spleen, leg, segments of blood-vessels, etc.—in animals may be successfully accomplished if through accurate vascular anastomoses the circulation can be re-established, and other relationships of the parts—nerves, ducts, etc.—be properly restored.²

¹ For study of transplantation of thyroid see *Payr*, Arch. f. klin. Chir., Bd. 80, 1906.

² For a summary of observations on tissue transplantation see *Ribbert*, "Allg. Pathologie," 1905, p. 297. See also, for transplantation of organs, *Nichols*, "Third Report of the Croft Cancer Commission," Jour. Med. Res., vol. xiii., p. 221, 1905. For transplantation of human ovaries see *Cramer*, Münch. Med. Wochenschr., Sept. 25th, 1906. See also, for transplantation of organs and blood-vessels, *Carrel and Guthrie*, "Surgery, Gynecology and Obstetrics," vol. ii., p. 266, 1906; Jour. Am. Med. Assoc., Nov. 25th, 1905; Am. Jour. Med. Sci., Feb., 1906; Science, Mar. 9th, 1906, and April 13th, 1906; *Carrel*, Jour. Exp. Med., vol. x., p. 98, 1908; vol. xii., 139, 146, 1910; *Guthrie*, Jour. Exp. Med. xii, 269, 1910.

The Impulse to Cell Regeneration.

While we can thus summarize the differing capacities of the body-cells for regeneration; while we know many of the general conditions under which the impulse to cell proliferation and growth is manifested; while, further, we have learned something of the delicate mechanism through which division is controlled and effected, at the end we must acknowledge that we do not know why cells divide. We may say that it is due to a chemical or a mechanical stimulus, and it certainly may be associated with both; or that increased nutrition favors, while innutrition retards cell multiplication; we may cite direct or remote injury, or talk of the inhibition of organic control, disturbed tissue equilibrium, diminished pressure, reversion, etc., but when all is said we are forced to recur to some unknown factor in the inherited constitution of the cell which determines the measure and character of its response to the most varied influences.

The hypothesis of Ribbert, in accordance with which the capacities of cells to proliferate and grow, so manifest in embryonic life, are held in restraint in the normal adult body by a subtle correlation of cells and tissue, is most suggestive in this connection. When this mutual relationship is disturbed, as is the case under many of the conditions in which regeneration takes place, the cells, in the conception of Ribbert, are freed from certain, at least, of their organic restraints. These restraining conditions he calls "tissue tension," meaning thereby, however, something more complex and subtle than simple physical tension. Thus, free to exert their primitive capacities, formerly held in restraint by the environment, we can conceive how cells proliferate and new tissues are formed in the regenerative processes without assuming the acquirement of any new capacities and without the assumption of vague and special stimuli.¹

According to this conception, then, the regenerative processes leading to the formation of new cells and tissues are not brought into play by stimuli furnished by injuries—the so-called "formative stimuli" of an earlier time. But new cells and tissues form as the result of the release of inherent capacities of cells normally held in restraint after the developmental period, by their associations as parts of an organism. Thus, when conditions of nutrition, pressure, organic association, possibly of protoplasmic continuity or of nerve correlation, are disturbed, for example, through trauma, poisons, degenerations, prolonged hyperæmia, and various other vascular and nutritive cellular disturbances, the leash of organic control is loosened, and the primitive capacities of the cells are temporarily free to act. But, as we have seen, this

¹ For a *résumé* of Ribbert's hypothesis and its applications to regeneration, hypertrophy, etc., see Ribbert, "Allgemeine Pathologie," 2d Ed., 1905; also references under "Origin of Tumors," p. 351. For a criticism of Ribbert's views see Adami's "Pathology," vol i., p. 537, *et seq.*

See also, for summary of a new phase of research and interpretation in the nature of the "formative stimulus" involved in artificially induced cell division and artificial parthenogenesis, Loeb, "Studies in General Physiology," p. 253. For general bibliography of regeneration, compensatory hypertrophy, etc., see Aschoff, Lubarsch and Ostertag's *Ergebnisse*, Jahrg. v. for 1898, p. 22. For a full consideration of the subjects dealt with in this chapter consult the general pathology 'Les Processus Généraux' of Chantemesse and Podwysotsky, 1901.

resumption of an abeyant potency in the ordinary processes of repair is not limitless and, sooner or later, the old controlling relationships of organic associations are re-established and the reparative activities cease.¹

In a later chapter we shall see, in discussing tumors, how a more complete and lasting emancipation of certain cells, from the restraints imposed by organic association, may possibly lead to most significant and baleful consequences in the formation of malignant tumors (see p. 350).

Finally, while we have set forth somewhat at length the conceptions of Ribbert, elaborating an original hypothesis of Weigert, there are so many evidences, especially clear in lower forms of life, of the direct incitement of cells to overgrowth and proliferation by various physical and chemical agencies, under conditions in which the potencies of the so-called tissue tension cannot properly be invoked, that the assumption of direct external stimuli to regenerative cell activities in many cases seems fully justified.

¹For a consideration of the bearing of this hypothesis on compensatory hypertrophy, see Ribbert, "Lehrbuch der allg. Pathologie," 1905, p. 315.

CHAPTER V.

INFLAMMATION.

General Considerations.

The conception of inflammation was originally a clinical one in which the process was marked by special symptoms—redness, heat, swelling, pain, and impaired function. This conception was gradually enlarged to embrace the new formation of tissue which might be associated with or follow these symptoms, or which might be independent of them. After the knowledge of the importance of the cell became general it was upon the formation and accumulation of cells and other substances that attention was especially fixed. Finally, the processes and structural alterations embraced in the conception of inflammation became so varied and complex that a definition or even a characterization seemed not only difficult, but wellnigh impossible.

It is only within the past decade or two that the processes and lesions involved in inflammation have been seriously considered in the light of comparative pathology and as biological problems divorced for purposes of research from the dominance of traditional clinical conceptions. In view of our increased knowledge of the structure of cells and of the impulses immediate and hereditary which determine their performances, it seems possible now to resolve the complex processes and lesions embraced in the general notion of inflammation into more simple factors, and to arrive, if not at an exact definition, at least at a reasonable conception of the relationship of its phenomena to each other, to those of normal physiology, and to other phases of disease.

With this end in view it seems wise at first to rehearse as simply and briefly as is practicable some of the more typical of the phenomena and lesions which are commonly grouped under the term inflammation.

While the death of tissue from trauma, and degenerative alterations in the tissues in the presence of various forms of poisons are often important factors in the inflammatory processes, we shall not consider them separately here, because they are incidental rather than inherent and have already been treated in the section on Degenerations and Necrosis. But it should be noted that various phases of albuminous degeneration, local or general, which are induced by the poisons of the pathogenic bacteria, are very often associated with inflammation, and not infrequently modify, or may even determine, its occurrence.

A comprehensive survey of the conditions under which inflammation most frequently takes place shows at once that it is almost always associated with some form of injury. This may be direct trauma, or excessive heat or cold. It may be poisons of various kinds—from the cruder

inorganic poisons inducing immediate and gross tissue destruction to the subtle toxic substances which result from the metabolism of micro-organisms or from the aberrant metabolism or degeneration of the body-cells themselves. Dead cells or tissues or foreign substances of many kinds within the body are common incitants of the inflammatory processes.

Let us now look at some of the ways in which the living body responds to injury, and first at an injury which is very slight and simple.

Types of the Inflammatory Reaction of the Body to Injury.

Injury to Non-vascular Tissue.—If a small clean cut be made in living fibrillar connective tissue, not involving blood-vessels, and affecting only the cells and fibres in the vicinity of the incision, and if the sides of the wound be immediately placed and held together, the resulting changes which lead to the complete restitution of the part are comparatively simple. A small quantity of fluid which oozes from the tissue spaces sticks the sides of the cut together. Such connective-tissue cells as have been seriously injured, especially if the nuclei have suffered, die and disintegrate; and these, together with such tissue fragments as may be present, are removed by phagocytes or through autolysis and absorption. But cells whose nuclei have remained intact, whether directly upon the incision or in its immediate vicinity, become larger and more granular, may divide by mitosis, extend their bodies or processes

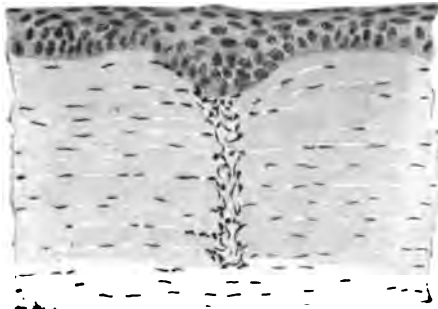


FIG. 50.—HEALING OF A WOUND OF THE CORNEA.

Without involvement of blood-vessels a few new connective-tissue cells have formed along the line of slight injury (incision), and the sides of the wound are joined by the new cells and fibrils formed by them. The epithelium has regenerated over the surface.

across the plane of incision, bridging this at intervals with living protoplasm. Under the influence of these cells, new intercellular fibres are formed, which in a short time bind the sides of the wound firmly together (Fig. 50). Thus, with but the slightest amount of tissue destruction, and with no involvement of the blood-vessels, a simple mechanical injury may be made good. This form of reaction to injury of living tissue is known to the surgeons as *healing by "first intention."* The mode of healing does not essentially differ if there be a slight injury to the blood-vessels.

In injury to a non-vascular part, like the cornea, for example, the primary reaction to the damage manifested by the fixed connective-tissue cells is often complicated by the wandering in of leucocytes from the conjunctival blood-vessels in the manner indicated in the next section. This participation of distant blood-vessels and leucocytes is, no doubt, incited by a reflex stimulation of the nerves of the blood-vessels, and may

be fostered under certain conditions by the absorption of injurious substances which are carried to the nearest blood-vessels by the lymphatics. Thus it is that in injuries to the cornea, a non-vascular part, the lesion is often complicated by the secondary participation of the adjacent blood-vessels.

Injury to Vascular Tissue.—Let us now look at the effect on a vascular tissue of an injury not immediately destructive. For this purpose the mesentery of the bladder of a curarized frog, drawn out upon a suitable plate¹ upon the stage of the microscope and kept moist by irrigation with three-fourths-per-cent. salt solution, affords a succession of most instructive pictures. The mechanical disturbance of the organs exposed, desiccation, and a variety of other physical and chemical vicissitudes to which they are subjected, are sufficiently damaging to incite a complex train of responses on the part of the living tissues.

In studying the circulation of the blood in small vessels under the microscope it should be remembered that, while the walls of these vessels are made up of living tissue and are capable of responses by movement or by structural change to external agencies, whether applied directly or through the nerves, they are also elastic pipes through which fluid flows, and that both pipes and fluid are subject to the laws of mechanics. These mechanical laws are often modified in expression, it is true, by the subtle energies which living tissues wield, but, as Thoma more than any other has shown, they are not to be ignored by the serious student of the living body, either in health or disease.

In the bladder or mesentery of the frog the arteries and veins with their connecting system of capillaries are clearly seen. When the current is rapid the cells of the blood in the arteries and veins are gathered into a red axial mass in which the separate cells may not be distinguishable, owing to their crowding and the rapid flow. Outside of this, against the walls, is a clear marginal zone in which a leucocyte is occasionally visible. If for any reason the rate of flow be considerably diminished, the leucocytes, which are specifically lighter than the red cells, gather in the marginal zone. If the current become very slow or be arrested, the marginal zone disappears and the red and white cells intermingle.²

Soon after the exposure of the bladder or mesentery the tissues become hyperæmic. The arteries, veins, and capillaries dilate, and the blood, encountering less resistance from the walls, flows more rapidly through them. This increased rapidity of the blood current does not, however, last long, although the vessel still remains dilated. After a variable period, owing, it is believed, to changes in the endothelia of the vessels, the blood meets with so much resistance that it flows more slowly than under normal conditions. Temporary or even permanent stasis may occur in some of the vessels, but this is not a constant nor a characteristic occurrence. White blood cells—leucocytes—now begin to accumulate along the inner walls of the veins and to become fixed

¹ See description of Thoma's frog-plate, p. 111.

² This distribution of the blood is almost, if not wholly, mechanical, and may be simulated in glass tubes with a fluid in which lifeless particles of different specific gravities are suspended. The particles of the lesser specific gravity assume, when the flow is established, the peripheral portion of the stream.

there, so that after a time the whole inner surface of the veins may be more or less thickly sprinkled, and even closely crowded, with adherent leucocytes. These may either lie firmly against the endothelium or be dragged slowly along by the current of blood sweeping past them. Some are dragged by the blood current into pyriform shapes, showing that they are adherent at a small point only, and thus they may be detached from the wall and rejoin the circulating blood. They may by amœboid movement crawl slowly along the interior of the wall, even against the current. In the capillaries, also, a similar comportment of the leucocytes may be seen.

After a time, which varies considerably—in the bladder sometimes within an hour after its exposure; in the mesentery usually later—some of the leucocytes commence to make their way slowly through the walls of the veins and capillaries. At first a little shining knob appears on

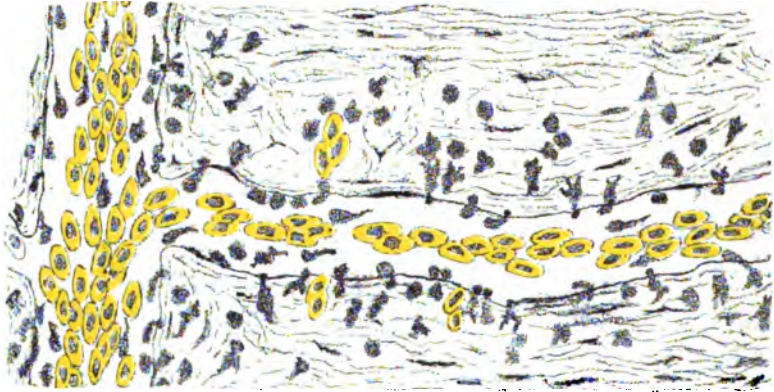


FIG. 51.—EMIGRATION OF LEUCOCYTES FROM THE BLOOD-VESSELS OF THE MESENTERY OF THE FROG.

Some of the leucocytes are clinging to the interior of the vessels; some are passing through the walls, some are wandering away through the tissue spaces. There has been diapedesis of a few red blood cells.

the outside of the wall opposite to the cell which is sticking within, and this outer portion grows larger as the part still within grows smaller, until at length the entire cell is outside of the vessel. The cell now may immediately detach itself and wander off in the tissue spaces, or it may remain for some time attached to the outside of the wall (Fig. 51). This passage of the leucocytes through the walls of the capillaries and veins—it does not occur in the arteries—is called *emigration*. The emigrating cells are largely the polynuclear leucocytes, but mononuclear forms—lymphocytes—and eosinophiles may also pass out of the vessels.

The cells pass between the endothelia through the cement substance, which apparently is in some way changed in the inflammatory process. They may pass through very rapidly, but usually their progress is slow and often interrupted, so that cells may be seen motionless for a long time in various stages of progress through the walls. A half minute, or

even less, may suffice for their passage, or they may be hours about it. Thus, after a variable time, if the conditions have been favorable, the tissues immediately around the capillaries and veins, and even those somewhat remote from them, may be more or less densely crowded with leucocytes, some motionless and in the spheroidal form, others moving about through the tissue spaces (Fig. 52). Leucocytes may pass out of the tissues on to free surfaces of the inflamed part, or they may wander into the lymph-vessels and so re-enter the circulation.

It is probable that the emigration of the leucocytes is due in part to a sort of filtration process with which the pressure of the blood within the vessels is concerned, and also to capillary attraction at the point of emergence. But the inherent contractility of the cells themselves forms,

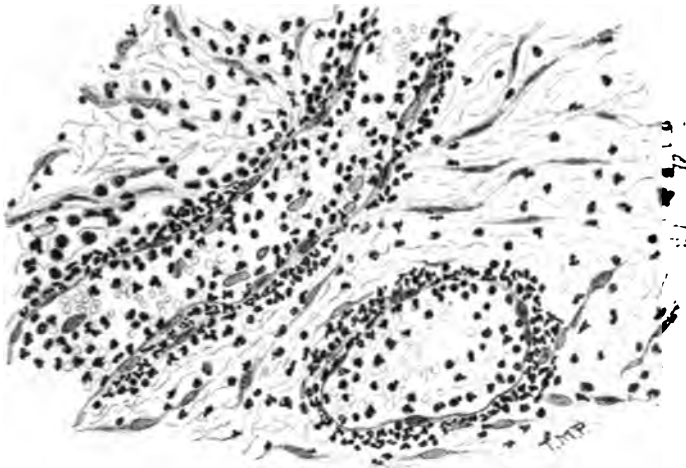

FIG. 52.—EXUDATIVE INFLAMMATION IN THE WALL OF THE APPENDIX VERMIFORMIS. Showing extravasated leucocytes in the vicinity of the blood-vessels, with oedema of the surrounding connective tissue.

doubtless, a very important factor. That in most cases *chemotaxis* plays a significant part in directing the course of the leucocytes seems to be well established, and it is largely to this agency that the gathering of leucocytes is due in the vicinity of the deleterious substances which incite inflammation.

In regard to chemotaxis it should be said in brief that the direction of locomotion in protoplasm may be determined by chemical substances in the vicinity. This is the case not only in the lower forms of life, as in certain bacteria and protozoa, but also in such cells of higher organisms as have retained a certain independence of locomotion, for example, in the leucocytes and certain cells of the connective tissue. To this form of response to external agencies the name *chemotaxis* has been applied. In some cases the effect of chemical agents in the environment is not to attract, but to repel, protoplasm. This has been called *negative chemotaxis*. Chemotaxis and certain allied responses to outside influences

have been found to play an important rôle in health as well as in some forms of disease, and have been the subject of much careful study.¹

If we return now to our observation of the living mesentery it will be found that while emigration of leucocytes is going on, the red blood cells, although for the most part carried along as usual in the current of the veins and through the capillaries, still often find their way in small, and sometimes in very large, numbers into the surrounding tissues. They are, it is believed, carried passively through the cement substance between the endothelia by minute streams of fluid which under these conditions are flowing in abnormal quantities through the walls. This extravasation of the red blood cells is called *diapedesis*. It appears to follow the emigration of the leucocytes, which seems in some fashion to prepare the way for the more mechanical exit of the red cells.

By this time it will usually be found that the tissue around the vessels is somewhat swollen and more succulent than normal, and fluid may be poured out on the free surface. The fluid which thus gathers is called *serum*. It is similar to the simple non-inflammatory transudates, except that it is richer in proteids and is mixed with cells. This serum has passed out of the blood-vessels along with the blood cells, and, as its composition differs somewhat from that of blood plasma, it is evident that it has undergone a change as it passed. The way in which this alteration in the composition of the blood plasma occurs as it passes through the walls of the vessels and becomes the serum of exudation, we do not understand. But it is probably due to metabolic processes in the endothelial cells by which what has been called a "selective filtration" is secured.

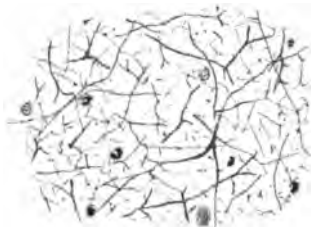

FIG. 53.—FIBRIN IN INFLAMMATORY EXUDATE.

The fluid exudate contains fibrinogenous substance, and from this, when the conditions are favorable, *fibrin* may be formed (Fig. 53) by a change similar to that which occurs in the coagulation of the blood. The leucocytes which wander into the tissue spaces outside the vessels may encounter conditions inimical to life, from innutrition or from the presence of deleterious substances, and thus these and other cells furnish, as they die and disintegrate, the fibrin ferment essential to coagulation. Clusters of fibrin fibrils may thus often be seen surrounding dead and disintegrating cells (see Fig. 54).²

If at this time the exposed bladder or mesentery of the frog be restored to the abdominal cavity and the animal placed under favorable conditions, the reaction of the vessels and cells to the unusual environment may, if the injury have not been too severe, gradually subside.

¹ For a fuller consideration of chemotaxis, with bibliography, consult *Davenport*, "Experimental Morphology," Part I., p. 32 *et seq.* For the forms of leucocytes which emigrate under various conditions see *Adler*, A. Jacobi's Festschrift, 1900, p. 309.

² For a discussion of the relationship of fibrin formation to cells which may furnish a substance inducing coagulation see *Hausser*, Virch. Arch., Bd. cliv., p. 335, 1898; also *Arnold*, Cbl. f. Path., Bd. x., p. 313, 1899.

The circulation is then re-established, the serum is absorbed, the leucocytes which have not come out upon the surface or died in the tissue spaces may re-enter the lymphatics. Fibrin, if this have been formed, and red blood cells which have escaped from the circulation are disposed of under the influence of ferments which leucocytes furnish (see p. 105), or may be carried off by the wandering leucocytes; or, as is not infrequently the case, blood pigment resulting from the reduction of the hæmoglobin which leaves the red blood cells by osmosis may remain for some time, *in situ*, as the only mark of an earlier active inflammatory process.

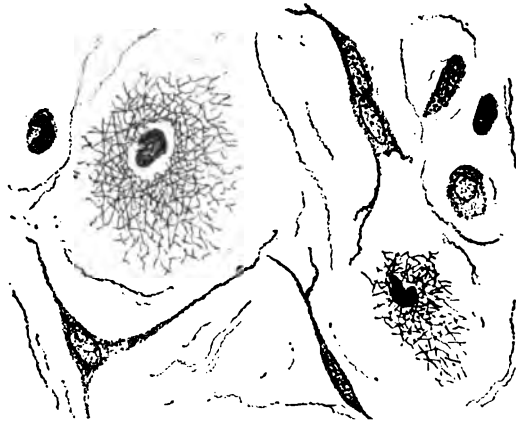


FIG. 54.—FIBRIN FORMING AROUND DEAD CELLS IN THE INTERSTICES OF TISSUE.

Thus in the living animal¹ we can learn by direct observation the way in which the serum, fibrin, and red and white blood cells get into tissues and upon free surfaces in certain forms of injury involving the blood-vessels.

We can see also by this experimental observation just what the factors are which induce the so-called "cardinal symptoms" of inflammation—the redness and heat due to hyperæmia; the swelling to accumulation of exudate; the pain to pressure on the nerves; and the impaired function to the disturbances of nutrition to which all of these factors contribute. The materials gathering in or upon the tissues under these conditions are called *exudates*, and this phase of inflammation is commonly called *exudative inflammation*.

Hand-in-hand with these changes, which are directly associated with lesions of the blood-vessels, there occur alterations of the cells of the affected part, which are not readily observed in the experimental animal, especially of the connective-tissue cells. These may suffer regressive changes—albuminous or fatty degeneration or necrosis; or, on the other hand, they may undergo progressive changes. The bodies may swell;

¹ Thoma has shown by similar studies on warm-blooded animals that the reaction to injury is in them essentially similar to that in the frog.

mitosis occurs; and they may divide. This may take place in the cells of the fibrillar connective tissue and in the endothelium of the blood- and lymph-vessels. The new-formed cells may detach themselves from their original site and join the leucocytes as wandering cells. If there are small islets of lymphoid tissue, such as are widely scattered through the body (see p. 481), these may show hyperplasia, and appear as clusters of small spheroidal cells with large deeply staining nuclei and a small amount of cytoplasm. These clusters of small cells resembling lymphocytes are especially noticeable in the vicinity of the lymph channels near small blood-vessels.

Let us now look at the effect upon a living vascular tissue of injury inflicted in a different way.

Injury from Micro-organisms.—Suppose we inject into the ear vein of a rabbit a small amount of a pure culture of a well-known and very common micro-organism, *Streptococcus pyogenes*. Little masses of the living germ will enter the heart and be driven out again through the arteries in whose smaller twiglets or in the capillaries some of them will lodge as emboli. Here in the living tissues the bacteria may find good nutrient conditions and begin to proliferate, increasing so rapidly in

number that they may distend the vessels in which they lie. If after twenty-four hours the animal be killed, and one examine the organs in which the bacterial emboli have caught and grown—in the liver, for example—he finds small blood-vessels here and there distended with bacteria. But the parenchyma and interstitial tissue about them appear to be intact (Fig. 55). If, however, the animal be allowed to live longer—say two or three days—before the examination, the condition of the tissue about the growing bacterial mass in the typical course of events shows marked and significant alteration. Immediately

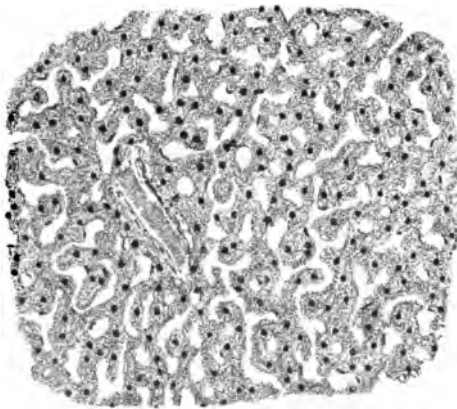


FIG. 55.—BACTERIAL EMBOLUS IN THE LIVER.

The bacteria have grown in a mass within the small blood-vessel. The liver cells in the vicinity appear unchanged.

around the bacteria the nuclei fail to take the nuclear stains (Fig. 56); the cytoplasm is unusually granular or fallen into fragments. These are the marks of cell death, and from the situation of this area of dead tissue about the colony of growing bacteria we may infer—and the inference is confirmed by a host of tests and observations—that, in growing, the bacteria have set free in the tissue about them some chemical substance whose presence is incompatible with the continuance of the life processes in the liver cells, which, in fact, has killed them.

But very soon the tissues near by show a different sort of reaction to

this active poison set free upon the spot. Leucocytes gather on the borders of the necrotic area and may form a dense ensheathing mass about it (Fig. 57). If we look for the origin of these, we find that close outside the area of dead tissue and among the gathered leucocytes the smaller blood-vessels are dilated, overfilled with blood, and such marks of the emigration of leucocytes as a tissue removed from the animal and prepared for examination may show are unmistakable. Not infrequently extravasated red blood cells and fibrin and a distention of the tissue spaces with fluid still further characterize the process as exudative inflammation.

It was observed in the exposed mesentery or bladder of the frog that the leucocytes, once outside the vessels, wandered off in various directions in the tissues, some to the surface, some to the lymph-vessels, and some far from the veins or capillaries from which they emerged. Not so here. The extravascular leucocytes gather close in the border zone of the necrotic area or enter it. And we may usually see in the outer parts of such an area of dead tissue scattered leucocytes which are themselves undergoing changes indicating the death of the cell. They too have encountered the poison set free by the growing bacteria.

The changes which have just been described as the result of experiment in the animal are practically identical with those occurring in man as the result of accidental inoculation.

If the process continue, one may find on later examination that the dead-tissue mass has softened through the action of proteolytic enzymes developed on the spot (see p. 105), the bacteria are scattered, and the whole central portion may be occupied by a grayish or yellowish grumous or fluid mass of dead cells, cell detritus, albuminous and fatty granules, bacteria and leucocytes in various stages of necrosis and disintegration.

Such a localized result of exudative inflammation with death and disintegration of tissue is called an *abscess*; the material which it contains is called *pus*. For a more detailed consideration of suppuration and the characters of pus see p. 198.¹

The changes by which, if the animal survive the formation of abscess, the active processes are brought to a standstill and repair is effected, we

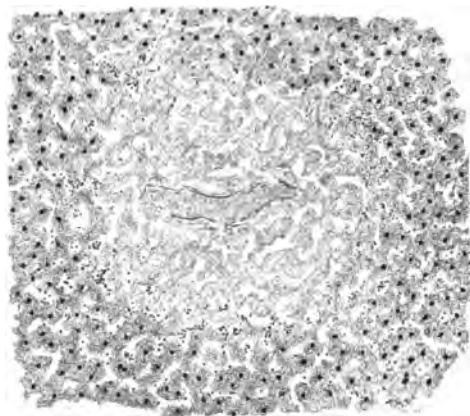


FIG. 56.—BACTERIAL EMBOLUS IN THE LIVER, WITH NECROSIS.

The bacteria are still largely confined to the vessel, but a few are outside. There is a zone of necrotic liver cells about the growing mass of cocci.

¹ For a *résumé* of forms of exudate cells, with bibl., see *Helly*, *Ziegler's Beitr. z. Path. Anat.*, Bd. xxxvii., p. 171, 1905.

need not now follow. But it concerns us here to appreciate that this is a type of one of the most important phases of the inflammatory process; a phase in which a poison produced in the body by the metabolism of micro-organisms incites a complex train of active and passive tissue changes.

Instead of forming abscesses with softening of the tissue, the pus cells and other exudates may be distributed diffusely through the interstices of the tissues, forming a so-called *purulent infiltration*.

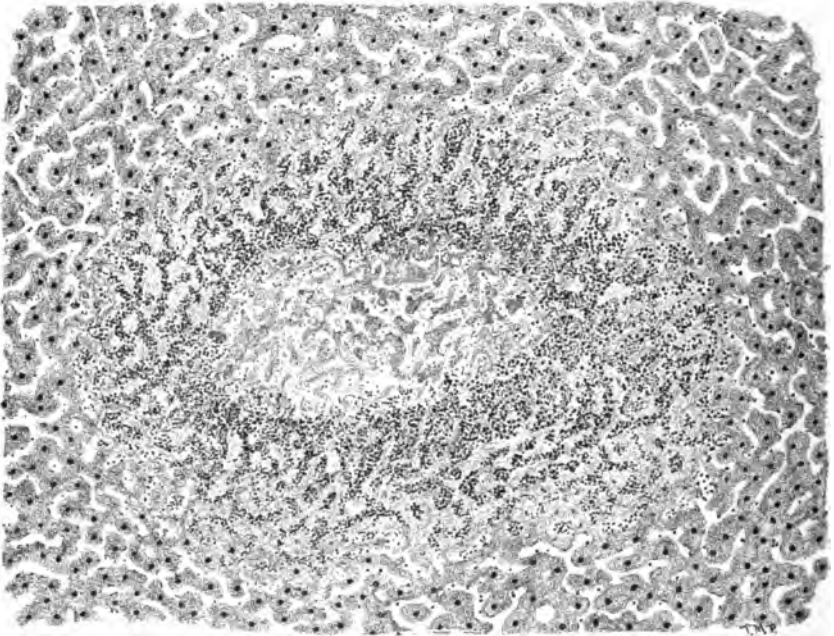


FIG. 57.—NECROSIS AND SUPPURATION IN THE LIVER FROM BACTERIAL INFECTION—EXUDATIVE AND NECROTIC INFLAMMATION.

The bacteria are scattered in masses, the liver cells about them are necrotic, while leucocytes have gathered in large numbers within the necrotic area. With slight further disintegration this mass of dead liver tissue and pus cells would form an abscess.

A narrow canal leading to a focus or area of inflammation is called a *fistula*.

In our study of illustrative phases of inflammation we now turn to the processes by which repair of injured tissues, after more or less involvement in the inflammatory phenomena, is brought about.

Resolution in Inflammation.—In many cases of exudative inflammation, after the subsidence of the active changes in the blood-vessels, the exudates are entirely though often very slowly absorbed, and the tissue returns to its normal condition; this is called *resolution*.

If many new connective-tissue cells have been formed, these may produce fibrils and thus a certain amount of new tissue may develop,

compromising the blood and lymph circulation, so that for a long time the site of the inflammation may be swollen and hard.

Under certain conditions, on the other hand—for example, in the case of a wound with loss of substance, or in an acute exudative inflammation of a serous membrane in which the surface is deprived of its normal mesothelial¹ covering, or in the healing of an abscess—a considerable amount of new tissue may be produced through the agency of old cells or of new cells formed in the inflammatory process.

We will now consider the way in which repair of a wound or injury with loss of tissue is effected.

The Healing of Wounds.

The way in which new inflammatory tissues are formed may be best understood by following the process of healing in a wound with loss of substance—for example, in a wound through the skin or a mucous membrane into the tissue beneath. At first there may be hæmorrhage.

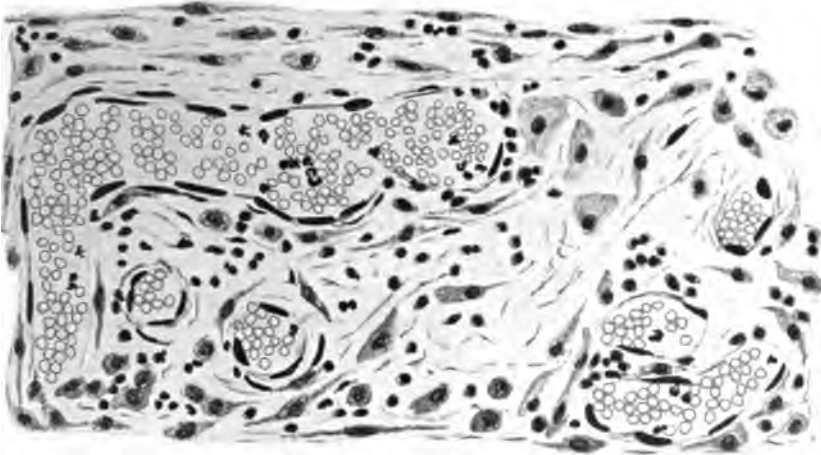


FIG. 58.—GRANULATION TISSUE.

From a healing abdominal wound. Early stage with very thin-walled blood-vessels, leucocytes, and young connective-tissue cells. There are few intercellular fibrils.

After this has ceased, the injury to the tissue, the unusual exposure of deep-seated parts, the presence of foreign substances, etc., may induce the same series of events which we have seen occurring in exudative inflammation with production of serum, fibrin, and pus. The blood-vessels dilate, the circulation becomes slower, serum transudes, and emigration sets in. Certain of the cells and fragments of intercellular

¹The morphological resemblance of the flat cells covering the surfaces of the great serous cavities—peritoneal, pleural, and pericardial—to the endothelium of the blood- and lymph-vessels has led to their being also called endothelium. But their genesis as well as certain physiological capacities which they still retain, render more fitting the name *mesothelium*. See reference to *Minot* in footnote on p. 377.

substance near the seat of injury may die, and in time are cast off or are disintegrated or dissolved and absorbed and otherwise disposed of by phagocytes (see p. 98). The tissue may become soaked and swollen by the transuded serum, and the connective-tissue cells in the vicinity may undergo proliferative or degenerative changes.

Granulation Tissue.—After a variable time, usually on the second or third day if all goes well, the surfaces of the wound may be more or less covered with tiny red nodules called *granulations*. These granulations contain numerous thin-walled blood-vessels which have sprouted out from the old vessels near the seat of injury, and around these a new

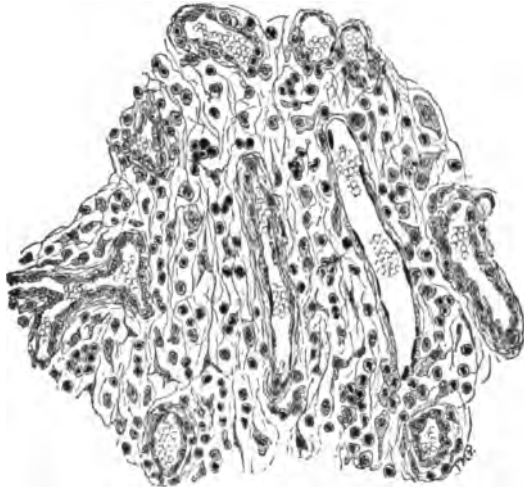


FIG. 59.—GRANULATION TISSUE FROM WOUND OF SKIN.
The walls of the blood-vessels are thicker, and intercellular fibrils are forming.

loose, succulent tissue is formed, largely, it is believed, from proliferation of connective-tissue cells. This is called *granulation tissue* (Fig. 58). On the surface of the granulations are usually pus cells in varying quantity, or the granulations may be more or less covered with dried exudate. The way in which the new blood-vessels form by protoplasmic sprouts from the old, and the manner in which connective tissue develops from older connective-tissue cells, have been already described in the section on Regeneration. Let it suffice here to say that the cells of the granulation tissue are at first mostly small and spheroidal or polyhedral, and are usually packed closely together with only a small amount of fluid intercellular substance. Presently some of the cells become larger and polyhedral, elongated, fusiform, or branched, and after a while a delicate, fibrillar intercellular substance makes its appearance about them and grows more and more abundant (Fig. 59). These larger, variously shaped cells, which appear to be formed out of the small spheroidal or indifferent cells of the granulation tissue, are usually granular, and the nucleus is generally large and distinct. Some

of these larger cells which seem to be more or less directly concerned in the formation of intercellular fibers are called *fibroblasts* (Fig. 60).

As the granulation tissue grows, new, small spheroidal cells are gathered by proliferation or by continued emigration. Some of these participate in the formation of the granulation tissue, while others, not finding conditions suitable for their further development, or even for their continued existence, die and pass off on the surface, together with some transuded fluid, as pus.

The polynuclear leucocytes do not apparently share in the formation of new tissue. To what extent this new tissue is derived from old connective-tissue cells and cells of the endothelial type—the *macrophages* of Metchnikoff—or how largely it may come from emigrated lymphocytes, assuming the characters of “plasma cells” (see p. 74), is not yet certain; but both classes of cells appear to be actively concerned.

Cicatricial Tissue.—The new tissue gradually becomes more and more dense, the intercellular substance more abundant, while the cells decrease in number and become flatter and less conspicuous. The epithelium may now grow over from the sides, forming by mitosis from the old epithelium at the edges of the wound (Fig. 61), and finally cover the new

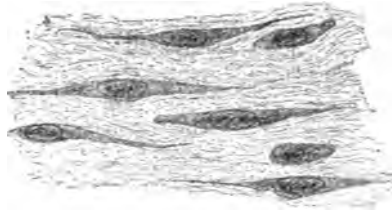


FIG. 60.—FIBROBLASTS OF NEW CONNECTIVE TISSUE IN A HEALING WOUND. There are numerous new-formed intercellular fibrils.

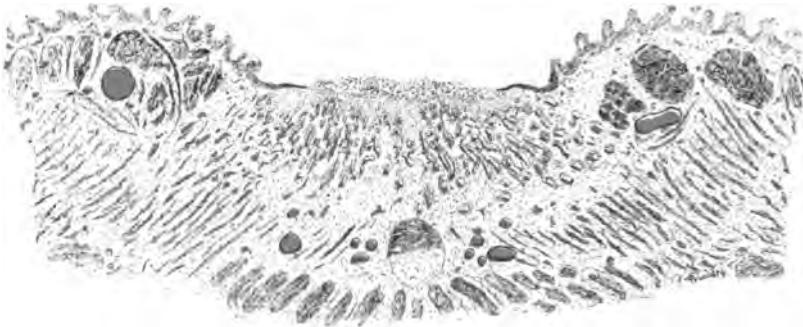

FIG. 61.—HEALING WOUND IN THE TONGUE OF A DOG.

There was loss of substance—muscle, fibrous tissue, and surface epithelium. The lost tissue has been replaced by the vascular granulation tissue, which is oldest and most dense in the deeper portion, while on the surface is a layer of tissue detritus, pus cells, etc., partly dried and forming a scab over the granulations. New epithelium is pressing forward from the old at the edges over the surface of the new-formed tissue.

vascular tissue. The new tissue, having at last undergone more or less shrinkage, with atrophy of the blood-vessels, consists of a dense, firm mass composed largely of fibrillar basement substance with a few flattened cells (Fig. 62); and with this, which is the *cicatrix*, the healing is complete. The cicatricial tissue in its shrinkage, as it becomes more

fibrillar and denser, often brings about considerable distortion of adjacent parts.

Variations in the Healing Process.—Although in the production of new tissue, in connection with or following exudative inflammation, essentially the same processes are involved in all cases, there are yet very marked differences in the degree in which the different factors share. Thus the vascular and exudative phenomena may predominate and very large quantities of serum, fibrin, or pus collect, while the amount of new-formed tissue may be insignificant. The production of a large amount of exudate,

particularly of pus cells—*suppuration*—usually marks the presence of micro-organisms whose locally elaborated poisons complicate or retard the healing process.

In other cases the formation of new tissue is the dominant feature, and the production of exudates seems to be almost entirely subordinated to this end.

The process of repair which is complicated by exudative inflammation




FIG. 62.—CICATRICAL TISSUE FROM A HEALED WOUND.




FIG. 63.—EXUBERANT GRANULATIONS.

From the inner surface of a granulating ovarian cyst containing pus. The tissue between the new capillaries is ill-formed, cedematous, and with few cells, most of which have undergone fatty degeneration.

or effected only by the gradual formation of a considerable amount of new tissue, is called by surgeons *healing by "second intention."*

The distinction between healing by first and second intention, which is of practical importance in surgery, is, from the pathological standpoint, only a quantitative one; for the restitution of the parts to the healthy condition is in both cases brought about by exudation and proliferation of cells usually under the influence of vascular changes, but in one case the latter changes are very slight, in the other more or less extensive.

There is much variation in the formation of granulation tissue. Thus, sometimes the body cells respond but feebly to the unusual conditions, and neither cell proliferation nor blood-vessel growth is active. On the other hand, the development of blood-vessels may be excessive, while other tissue formation lags. Under these conditions, loops and tangles of thin-walled, contorted new vessels may project from the granulating surface, while useful tissue formation remains in abeyance, or the new cells undergo fatty or other forms of degeneration (Fig. 63). The result of this disproportionate growth of ill-formed blood-vessels is the exuberant granulations ("proud flesh") which the surgeon frequently removes from unhealthy healing surfaces.¹

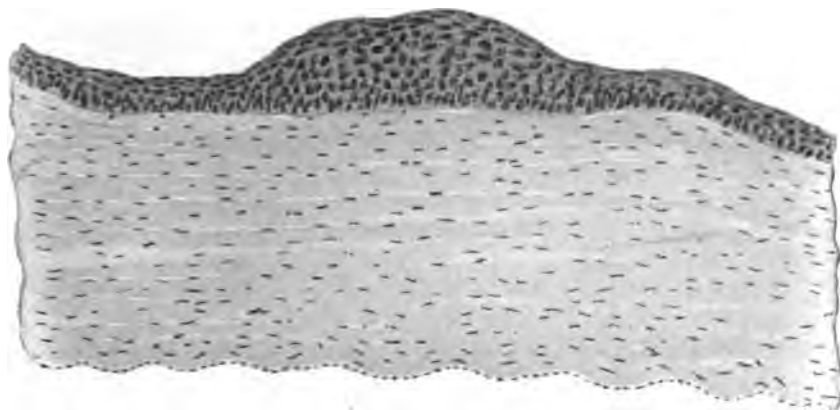


FIG. 64.—REGENERATION OF EPITHELIUM OVER SUPERFICIAL WOUND OF CORNEA—RABBIT.
The new epithelium has been formed in excess.

Cavities formed by abscesses or by necrosis in any part of the body may be filled up and their sides drawn together in a cicatrix, by the formation of a provisional mass of granulation tissue similar in character to that which grows in external wounds. So, similarly, cysts may be obliterated and ulcers partially filled and drawn into cicatricial healing. Large free surfaces, like the pleura and the peritoneum, may, through the intervention of granulation tissue, pass from the denuded condition of an active exudative inflammation, either with or without adhesions, into a condition which, though by no means a return to the normal, we yet designate as repair.

The so-called organization of a thrombus in a blood-vessel is brought about by processes practically identical with those which have just been described in the formation of new tissue in reparative inflammation in an external wound. The endothelial cells of the vessels and the connective-tissue cells in their walls proliferate, new blood-vessels develop by sprouts from the already existing smaller vessels in their walls or close about them. The new cells and new blood-vessels thus derived

¹ For a special study of granulation tissue see *Reinbach*, *Ziegler's Beitr.*, Bd. xxx., p. 102. 1901.

gradually penetrate the clot, forming new connective tissue, which replaces step by step the fibrin and blood which are gradually softened by autolysis and absorbed or removed by phagocytes.

The part which the thrombus plays in its so-called organization is thus a wholly passive one. It acts only as a temporary supporting texture for the development of the new tissue derived from other sources which step by step replaces it.

In the processes of repair by the formation of new tissues, the latter are often developed in excess, the overproduction after a time ceasing, when the normal condition is restored. Thus, if the epithelium be scraped from a small area on the front of the cornea the new epithelium which covers the injury is often heaped up in excess (see Fig. 64).

Hyperplasia and Interstitial Inflammation.

Hyperplasia of the fibrous interstitial tissue of the internal organs and other parts of the body—as, for example, in the liver, kidney, heart, nervous system, etc.—is of frequent occurrence and is usually associated with changes in the parenchyma. In some cases the formation of fibrous tissue clearly follows evident and often acute inflammatory processes and bears the same relation to antecedent reaction to injury that the cicatrix in a healing wound does to the granulation tissue from which it is formed. In other cases it is associated with long-continued hyperæmia—chronic congestion—of the organ involved. Again, gradual hyperplasia of the interstitial tissue takes place by the slow increase of cells and stroma, without evidence of an active cell proliferation or marked involvement of the blood-vessels. Finally, hyperplasia of the interstitial tissue may be and probably usually is secondary to damage to or atrophy of the parenchyma, as in the spinal cord after degeneration in nerve tracts or in the heart after damage to the muscle fibres; in the liver and kidney in connection with atrophy of the specific epithelial cells. In such cases it is often spoken of as *replacement hyperplasia*. These forms of fibrous-tissue hyperplasia will be considered with more detail in the sections dealing with the special lesions of the viscera. They have all been usually regarded as marks of inflammation. Some of them unquestionably are so; concerning others, doubt will continue until our knowledge as to their excitants considerably increases. In the mean time the term *fibrosis* is sometimes applied to the results of fibrous-tissue hyperplasia, though this is still most commonly included among the inflammatory processes.¹

Those important phases of inflammation which are due to damage from special forms of micro-organisms will be considered in detail in the chapter of this book devoted to the Infectious Diseases.

¹ For a suggestive and interesting consideration of the relationship between inflammation and various forms of "fibrosis" see *Adami*, Middleton Goldsmith Lectures, Medical Record, March 14th and 21st and April 4th and 11th, 1896.

Special Phases of Inflammation.

The several phases of the inflammatory process, which we have now considered, are fairly typical of the reaction of the living body to various forms and degrees of injury. If we look at them together and seek to gather their dominant features, we find that the changes, varied as they are in character as well as in degree, are mostly of three kinds: first, those involving a greater or less amount of *degeneration* or *necrosis*; second, those involving local disturbances of the circulation, as well as alterations in the distribution and character of the fluid and cellular elements of the blood—*exudative changes*; and third, *regenerative, productive, or reparative* changes.

Of these three groups of alterations in inflammation those involving the blood-vessels and their contents are, in a clinical sense, most striking and characteristic, and to many seem to dominate the inflammatory processes. But in fact all are closely associated. The various phases of inflammation depend upon the nature and extent of the injury, the inherent reactive vigor of the cells, and the character and position of the tissue involved.

Special names have been attached to various forms of the inflammatory process, descriptive of the feature which from the particular standpoint of the observer seems most striking or important. Some of the names are descriptive of clinical symptoms, some express the duration or character or situation of the lesion, some seek to imply more or less well-founded views of the nature of the process. Thus among the forms of exudative inflammation, those in which the extravasated serous fluid is the most marked feature are often named *serous inflammations*. If fibrin predominate, it is called *fibrinous*; if associated with much blood extravasation, it is termed *hamorrhagic*. When the agencies are present which induce the necessary vascular changes and promote the emigration and gathering, and often the destruction, of leucocytes in considerable or large numbers, we have a *suppurative* or *purulent inflammation*. If much tissue death be associated with the process, it is named *necrotic inflammation*.

Again, if certain mucous membranes or mucous glands be subjected to the inciting agencies, they may respond by an overproduction of mucus as well as by an increase of death of cells; this is *mucous* or *catarrhal inflammation*. In inflammation of the mucous membranes fibrin intermingled with other exudate sometimes forms more or less well-defined and often tough pellicles or membranes upon the surface. This is called *pseudo-membranous* inflammation. Finally, these various forms of exudate may be produced simultaneously, whence arise such compound designations as *sero-purulent, muco-purulent*, etc., inflammation. Inflammation with the formation of new tissue is called *productive* or *reparative*.

Local inflammation, especially when incited by micro-organisms, is often associated with systemic infection due to a distribution of the

inciting agents through the body. This condition will be considered in the chapter dealing with the Infectious Diseases (see page 197).

Inflammation, especially of infective origin, is so frequently associated with degenerative changes in the more highly organized cells—the parenchyma cells—of organs that when these are conspicuously involved the term *parenchymatous inflammation* has been used. It is better, however, to hold the degenerations apart and consider them as associated but not identical with the inflammatory processes. Similarly the term *interstitial inflammation*, though very commonly employed, indicates a comparatively rare occurrence. That which is embraced under the term is usually an interstitial hyperplasia secondary to damage to the parenchyma cells of organs (see p. 96).

It has seemed wise to many to attempt to draw a sharp distinction between those phases of inflammation which involve only the degeneration of tissues or the redistribution of already formed tissue elements—serum, fibrin, and blood—and those phases which are productive or reparative. But while this attempt aims at the recognition of a biological distinction of fundamental importance, it encounters the great practical difficulty that both phases of the reaction of tissues to injury, the exudative and the productive, occur together, so that none of the named classes of inflammation represent simple and unmixed forms of tissue reaction. The important thing is to conceive, as clearly as our knowledge permits, the nature of the processes which underlie these various manifestations of disturbed cell function and their associated tissue alterations. Then the names may serve useful temporary ends at least without implying too much or concealing too little knowledge.

The Disposal of Foreign and Dead Substances in the Body— Phagocytosis—Autolysis.

It was stated at the beginning of this chapter that the injuries which lead to inflammation are extremely varied. The degree and character of the resulting inflammation are closely related to the inciting agents. We have already taken as general examples of the inflammatory response to injury, one in which there was a simple mechanical damage, and the other in which a more extensive and prolonged injury was effected by the presence of living bacteria.

While it is not practicable to classify the various phases of inflammation according to the character of their incitants it is convenient to consider by themselves the effects of animal and of vegetable parasites, among the latter especially the bacteria. In subsequent chapters, under the headings of Animal Parasites and of Infectious Diseases, we shall study the special phases of injury induced by these agents and the response which the living cells and tissues of the body make to their presence.

But there are many forms of injury to cells and tissues which, though not so extensive and striking as those which we have thus far considered in our preliminary survey of inflammation, are yet of great frequency

and importance. One of these we must now consider, namely, the presence in the body of foreign substances and of dead portions of the body itself. Here again, as in so many instances, we shall come upon physiological processes spurred to unusual activity by emergency demands upon them.

The Forms and Origin of Foreign and Dead Substances.—Under the conditions of normal life, as the tissues grow and perform their functions, worn-out cells die; as bone grows it is absorbed little by little to make room for the remodeling and growth of the larger structure; more or less constantly, floating matter in the air we breathe gathers in the respiratory organs. Under all of these conditions the dead cells, the hard bone, the foreign particles, are disposed of by certain lowly organized cells, leucocytes, lymphocytes, connective-tissue cells, endothelium and mesothelium, which are called *phagocytes*.

On the other hand, there are many conditions under which foreign material abnormal in quantity and character is formed in or enters the body and must be disposed of. Thus organic pigments in the form of irregular particles or crystals are formed in the body, such as blood and bile pigment. Many foreign substances in finely divided form in large quantities enter from without, especially in the respired air, such as coal, iron, stone, smoke, and various kinds of organic dust. In various ways larger bodies, slivers of wood, particles of metal, bullets, and, in injuries or during surgical operations, fragments of clothing, ligatures, sutures, fragments of sponge, cotton, gauze, jute, etc., may remain as foreign substances doing more or less harm and inciting in various degrees the phenomena of inflammation. These, too, the phagocytes dispose of.

Finally, as the result of the greatest variety of injuries which lead to the necrosis of cells and tissues, such as mechanical damage, the action of corrosive poisons, excessive heat or cold, disturbances of circulation, various toxins, etc., the dead structures themselves become harmful to the living tissues about them, which respond in various ways to their presence, among others by certain forms of inflammation.

Let us see how the body cells and tissues comport themselves in the presence of alien substances and dead structures.

Disposal of Foreign Substances.—One of the simplest and most common of the phenomena of this class is seen in the disposal of pigment and other solid particles, whether introduced from without or formed within the body under various abnormal conditions.¹ In breathing dusty air, whether of badly cleaned dwellings, places of business or assemblage, or by those engaged in occupations involving the loading of the air with the dust of coal, smoke, iron, stone, tobacco, lint, hair, etc., in the aggregate large numbers of the dust particles enter the respiratory passages. Here sooner or later they are taken up by cells—phagocytes—and if the particles are colored they may be seen lying within the cytoplasm surrounding, but not within, the nucleus (Fig. 65). These cells may be the epithelium of the respiratory passages or of the air chambers of

¹ For a study of the removal of alien substances from the peritoneal cavity see *Buxton and Torrey Jour. Med. Res.*, vol. xv., p. 5, 1906.

the lungs, or leucocytes which have wandered out upon the surfaces. Then a large part of the foreign particles, if these be not too numerous, are carried either on the lymph currents or more frequently within cells into the lymph channels, along which they make their way to the nearest system of lymph-nodes or -nodules or to the smaller areas of lymphatic tissue which are widely distributed in the lungs as well as elsewhere in

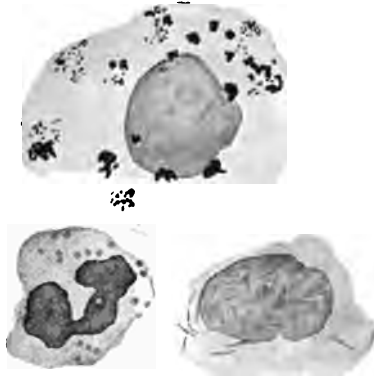


FIG. 65.—PHAGOCYTES.

The upper cell is epithelial from the lining of the air vesicles of the lungs. The pigment which it has ingested is coal dust from the air. The lower cells are leucocytes. One has taken in cocci, the other bacilli.

the body (see p. 481). In these islets of lymphatic tissue or in the lymph-nodes of the lung the foreign particles both within and without the cells are deposited and may remain for an indefinite period.

But the tissues in which they are deposited are not indifferent to the presence of any considerable accumulation of these alien substances. The connective tissue and endothelial cells swell and proliferate and new fibrils are formed enclosing the foreign material which may lie within the cells which brought them or be taken up by the new-formed or old connective-tissue cells or lie free in the interstices of the fibrils. Thus in the lymph-nodes and along the lymph

channels masses of dense fibrous tissue may be formed, shutting in the foreign material and compromising in varying degrees, sometimes completely destroying, the involved structures (see p. 485).

Similarly bacteria, which are also foreign bodies, may be taken up by phagocytes (Fig. 65) and destroyed within them by agencies presently to be considered.

If a mass of foreign particles be placed beneath the skin, or if at the seat of a hæmorrhage insoluble blood pigment is formed in considerable amount, a similar process may be observed. The pigment is more or less taken up by leucocytes or other phagocytic cells which have wandered in. A certain amount of fluid exudate may collect. New cells are formed from the old connective-tissue cells and from endothelium, and new fibrillar stroma is formed which becomes dense and assumes the character of cicatricial tissue. In these changes the new-formed cells, as well as the leucocytes, are capable of moving from place to place, that is, may become wandering cells. We have then, in this relatively simple response to a small local injury, the presence of fine foreign particles, a definite form of inflammation. This is marked, not by the phagocytosis, but by the presence of leucocytes and a certain amount of fluid exudate, by the formation of new cells, and the production of new tissue.

When the alien material out of place in the living tissue is in the form of a loose-textured mass, such as sponge, fabrics, jute, catgut, etc.,

or is a blood-clot, its interstices become filled with fluid exuded from adjacent blood-vessels, with leucocytes which wander in, and with new connective-tissue cells derived from the surrounding parts and from the endothelium of neighboring lymph-vessels. Slender blood-vessels

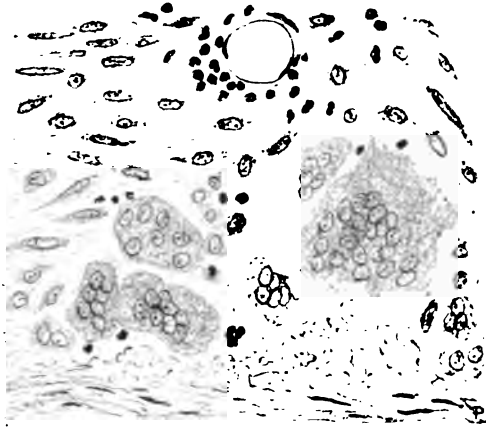


FIG. 66.—GIANT CELLS.

The giant cells are at the border of a layer of granulation tissue formed about a mass of dead fibrous tissue which is being absorbed.

form from the old ones near by and penetrate the mass, and new connective tissue is developed, having the type of granulation tissue at first, then becoming denser. If the foreign substances are capable of solution, as is the case in the fibrin and cells of a blood-clot or of catgut,

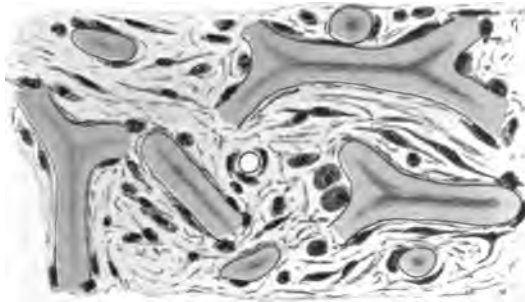


FIG. 67.—FRAGMENT OF SPONGE IN A HEALING WOUND.—THREE WEEKS.

The sponge trabeculae are not dissolved in the new-formed fibrous tissue, which has completely enclosed them.

proteolytic enzymes¹ furnished by the leucocytes or other cells may dissolve them; or they become fragmented and the fragments are taken up by phagocytic cells. These may be dissolved within these cells or may be transported to other parts of the body. Thus in the case of

¹ See Wells, p. 103.

soluble material this may at length be entirely removed and its place taken by the new tissue which gradually assumes the character of cicatricial tissue.

If the foreign substance be insoluble or largely so, as in the case of bullets, needles, hair, cotton, sponge, etc., the new cells gather about the objects; there are often giant cells among them (Fig. 66), and new blood-vessels develop among these, leading to the formation of new connective tissue which may completely invest them (Fig. 67), forming at last a dense connective-tissue capsule. In this condition such foreign objects may remain for long periods embedded in the body. If the

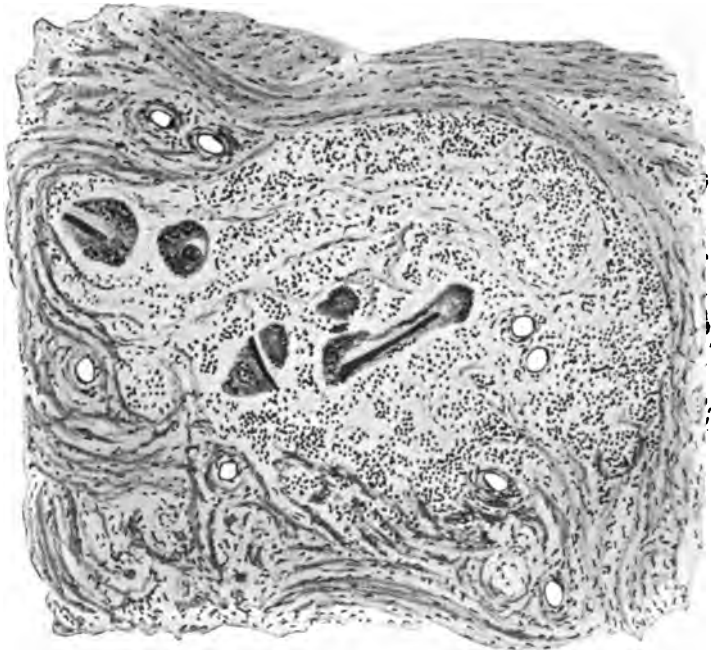


FIG. 68.—GIANT CELLS AND NEW-FORMED FIBROUS TISSUE AROUND A FOREIGN BODY—COTTON FIBRES. This is a so-called "foreign-body tubercle."

masses of foreign bodies are small, so that the local reaction is limited and circumscribed, the new tissue often in a general way resembles a tubercle (Fig. 68). Thus these new foreign-body tissue masses are sometimes called "foreign-body tubercles."

Giant Cells.—When foreign objects of considerable size—such as hair, cotton fibres, sponges, and various more solid things—get into the living body, particularly if these be insoluble, in addition to the leucocytes and the new connective-tissue cells, there often form close about them large multinuclear cells called *giant cells* (Fig. 69). These are sometimes of extraordinary size and may have several score, even hundreds, of nuclei. They are apparently formed either by the coales-

cence of new-formed cells derived from the connective-tissue cells or from old endothelium, or by the continuous division of the nuclei of a cell whose body continues to enlarge without dividing into separate cells.¹ These giant cells seem to be concerned in the attempt to dissolve the foreign substance and appear to have their prototypes in the multinuclear cells called osteoclasts (Fig. 70) which are concerned in the physiological absorption of bone during its development.

The Disposal of Dead Tissues.—The changes which we have now studied, through which alien substances are either removed from the body or are rendered relatively harmless by processes which we must regard as belonging to inflammation, are similar to those by which the body responds to the injury of dead portions of its own tissue.

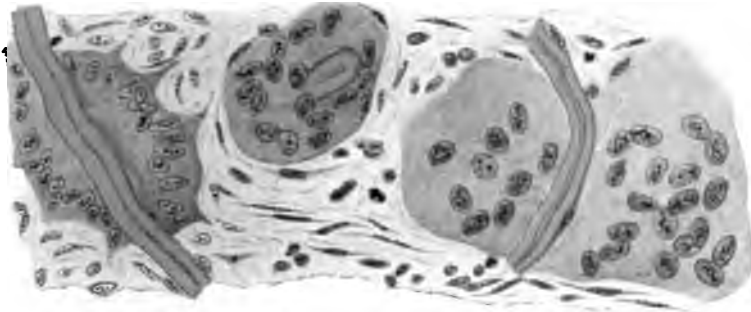


FIG. 69.—GIANT CELLS FORMED AROUND FOREIGN BODIES—COTTON FIBRES.
From a wound delayed in healing on account of the cotton fibres left in the dressing.

Thus, infarcts resulting from emboli, areas of tissue which have become necrotic from poisons or toxins, thrombi or masses of fibrinous exudate in the solid tissues or in the great serous cavities, are all virtually alien substances, and are harmful in various ways as foreign bodies are, and incite similar inflammatory phenomena. They may be in part removed by solution through the proteolytic enzymes,² or by phagocytosis; they may attract leucocytes (Fig. 71); they may lead to the proliferation of connective tissue and endothelial cells and of blood-vessels which penetrate them and form new tissue which finally replaces or encapsulates them. The so-called organization of a thrombus or of a pleural or pericardial or peritoneal exudate is not, as we have already seen, directly brought about by the aid of the structural or other elements in either the thrombus or the exudate. These are passive, except as they may aid in their own solution by autolytic substances which they furnish, while the new tissue is formed from neighboring cells and vessels.

Forms of Phagocytes.—There appear to be two most common forms of phagocytes in foci of acute exudative inflammations. First, and

¹ Giant cells may be formed from epithelium under certain conditions. For a study of giant cells, with bibliography, consult *Hektoen*, *Jour. Exp. Med.*, vol. iii., p. 21; *Fuerst*, *Ziegler's Beiträge*, Bd. xxiv., p. 440; and *Burton*, "Studies from Department of Pathology, Cornell University," vol. i.

² See *Wells*, *Jour. Med. Research*, vol. xv., p. 149, 1906, bibl.

usually the most abundant, are the polymorphonuclear leucocytes—the cells containing neutrophile granules which so readily escape from injured vessels. The other type of the two more common phagocytic cells is usually larger than the polymorphonuclears and has a single,

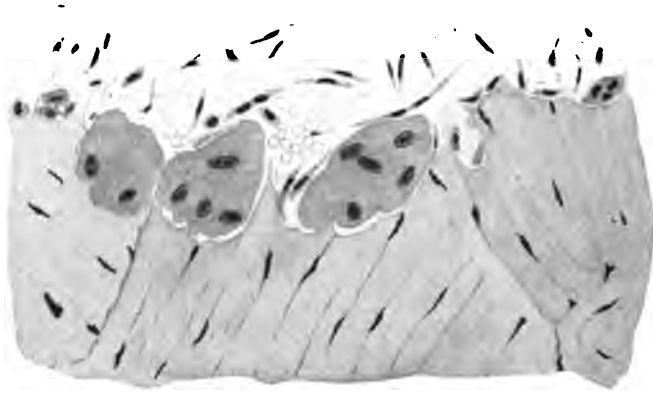

FIG. 70.—OSTEOCLASTS DISSOLVING BONE LAMELLE.
From a case of rarefying osteitis.

relatively large, rounded or irregular shaped nucleus. These mononuclear phagocytes of the second type are probably derived from connective tissue or endothelial and mesothelial cells or from lymphocytes, and have been called by Metchnikoff *macrophages*, while the smaller polymorphonuclear phagocytes are called *microphages*.

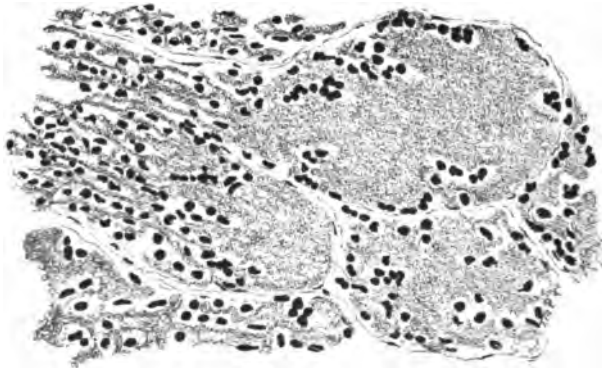


FIG. 71.—FRAGMENTS OF NECROTIC MUSCLE IN PROCESS OF ABSORPTION UNDER THE ACTION OF PHAGOCYTES.

While the performances of these two types of cells are not fully understood, it appears that the macrophages are especially concerned in the disposal of various proteid and other formed elements which they ingest, such as fragments of fibrin and tissue detritus, dead parenchyma cells of organs, red and white blood cells, etc.

On the other hand, the polymorphonuclear leucocytes—microphages—are drawn to and ingest and destroy various kinds of micro-organisms, especially the bacteria.¹

While we have thus far considered certain special cells, leucocytes, lymphocytes, and derivations of connective-tissue and endothelial cells, as the most common phagocytic cells in inflammation and repair of tissues, we should not lose sight of the fact that other types of cells are also capable of assuming this rôle. Thus the epithelium of the mucous membranes of the air vesicles of the lungs, of the liver, kidney, and other organs, frequently and under the most varied conditions ingest particles of foreign material.

The Mode of Action of Phagocytes.—As to the processes by which the phagocytic cells convert into soluble and other forms the substances which they ingest there is still some difference of opinion, though the so-called intracellular digestion and the autodigestion of tissues have been the subject of much painstaking research.

Recent studies by Opie² indicate that each of the two types of phagocytes above designated is characterized by a distinct proteolytic enzyme through which its destruction of organic substances is effected. The enzyme of the polymorphonuclear leucocytes is capable of proteolytic digestion in the presence of a neutral or alkaline reaction, but not in an acid medium. This enzyme Opie calls *leuco-protease*. The larger mononuclear cells, on the other hand, the "macrophages" or "macrocyles," which appear to be especially concerned with the ingestion and destruction of cellular and other formed elements, contain an enzyme active in the presence of a weak acid, but inactive in an alkaline medium. This enzyme is called *lympho-protease* by Opie.

Blood serum, according to Opie, inhibits the action of leuco-protease, and lympho-protease is not active in an alkaline medium. Hence, the living tissues of the body are not digested by the leuco-protease, which is active only within the bodies of the microcytes, where it is free from the inhibiting action of the serum, while the alkalinity of the blood plasma protects the tissues from the action of the lympho-protease. It is apparently the action of these proteolytic ferments, present in considerable quantities either within or without the cells or both, in foci of exudative inflammation, which leads to the softening of tissue which characterizes abscesses and which, in part at least, brings about the more gradual solution of necrotic tissues, fibrin, etc.³

The action of micro-organisms, especially the bacteria, as incitants of inflammation through the injury which they cause, and the ways in which the body reacts to and disposes of them, through the action of phagocytes or otherwise, will be considered later under the heading of Infectious Diseases.⁴

¹ For a consideration of the ways in which bacteria are destroyed by leucocytes, see pp. 161 and 178. See also ref. to Buxton and Torrey, foot-note, p. 99.

² Opie, Jour. Exper. Medicine, vol. viii., 1906, pp. 410 and 536.

³ See ref. Wells, p. 103; also ref. to Levene, "Autolysis," p. 107.

⁴ For a consideration of Ehrlich's hypothesis as to the way in which bacteria are destroyed in the body see p. 176.

It should be borne in mind, in considering the varied and complex performances of phagocytic cells under abnormal conditions, that these are only the manifestation in exaggerated form in the presence of emergencies of physiological capacities of many kinds of cells. To Metchnikoff especially we owe our knowledge of the phagocytic powers of cells in general. In such lowly organisms as amœba and in many other cells throughout the animal kingdom he has shown that through ingestion and intracellular digestion cells not only are nourished but protect themselves against harmful agents and influences.¹

Autolysis.—All the manifestations of cell life are brought about by the breaking down or disintegration of chemical substances in the cytoplasm by processes akin to those of combustion. It has long been believed that this was exclusively a property of living matter. But it has recently become known that dead cells also under certain conditions have the power of self-disintegration. This is called *autolysis*. It takes place in the absence of micro-organisms through the action of which organic material is decomposed in the commoner processes of putrefaction. Thus portions of fresh organs removed from the body with the avoidance of bacterial contamination, that is, in a sterile condition, if immersed in chloroform water, or toluol, or other substances which do not cause alterations of the tissue but do prevent the growth of micro-organisms, and kept at about body temperature, undergo gradual softening. This softening is accompanied by definite structural changes in the cells. The nuclear chromatin disintegrates or goes into solution; the cytoplasm degenerates, chemical analysis showing products of the disintegration of proteid substances. The changes are analogous with those taking place in organic material, cells, etc., under the influence of the digestive enzymes, pepsin and trypsin, but are due not to these but to other enzymes belonging to the cells themselves (see p. 105.)

It appears, for reasons into which we cannot enter here, that the proteolytic enzymes active in the autolysis of dead tissues are present in the living body and are probably concerned among other things in the gradual removal of dead and enfeebled structures as these become defective, useless, or harmful. It has been shown that the vigorous, living cells, in spite of their autolytic powers, probably maintain their integrity through the presence in the body-fluids of substances antagonistic to the autolytic enzymes. Thus it appears that under normal conditions a very nice balance exists between the autolytic enzymes and antagonistic substances within the body. Under a variety of abnormal conditions, such as diseases of the respiratory and circulatory systems, phosphorus poisoning, and, as has been shown by Flexner,² in infectious diseases, autolysis may be in a marked degree exalted.

It is probable that the autolytic substances in the living body are important not only in disposing of damaged or dead or harmful tissues,

¹ See Metchnikoff, "Comparative Pathology of Inflammation," English trans., 1893; and "Immunity in Infective Diseases," 1905. Consult also p. 196.

² Flexner, Trans. Assn. Amer. Phys., vol. xviii., p. 359, 1903.

but also in the protection of the body against invading micro-organisms through their destruction—see immunity and bacteriolysis, pages 160 and 173 or by their share in the elaboration of substances which antagonize the action of their toxins—see antitoxins, page 163.¹

Survey of the Inflammatory Process and its Significance.

Inflammation a Modification of Physiological Processes.—If now, from the vantage-ground which we have won by our study of various typical phases of inflammation, we seek to gain an insight into the forces which dominate the varied processes, we note at once that from first to last the cell and tissue performances in inflammation, however exaggerated or perverted, are only the expression of physiological capacities which belong to the structures involved. Thus the contractions and dilatations of the vessels are paralleled in health. The exuding of fluids through their walls occurs by processes akin to those by which blood pressure, osmosis, and selective filtration in endothelial cells maintain the initial circulation into and through the tissue spaces. Emigration is a physiological process which we find excessive here, because there are structural alterations in the walls of the vessels which permit a freer exit of the cells, and because there are also present new and active chemical agents which, just as in normal conditions though in exaggerated fashion, excite and control the movement and direction of the leucocytes. The healing processes, complex as they seem to be, are actually but a rehearsal under the unusual and often difficult conditions of cell and tissue formation, which is characteristic of the normal period of development. Phagocytosis is a factor of the greatest importance in the normal as well as in these abnormal performances of the body cells.

The degenerative phenomena, among which must be reckoned the formation of fibrin, are, as we have seen, incidental rather than primary factors in inflammation.

Thus in all the manifold manifestations of abnormal cell performance in inflammation we find no new functions, no new cell capacities.

The Significance of Inflammation.—We are now brought face to face with the final question: What does inflammation mean?

In those phases which involve the repair of wounds and the regeneration of lost tissues it is not difficult to recognize conservative and beneficial processes. But how is it with those phases of inflammation in which the blood-vessels are largely involved and exudates formed—serum, fibrin, and pus? Are we to be contented here with a simple summary of the phenomena and with the recognition that these are the results of exaggerated or physiological cell and tissue performances in the face of injury? Or, on the other hand, is there reason for the belief that these abnormal manifestations of cell life in the presence of an unusual and deleterious environment may, after all, be in the main con-

¹For an interesting *résumé* of autolysis with bibl. see *Levene*, Jour. Amer. Med. Assn., vol. xlvii, pp. 774 and 866, 1906. For a fuller consideration of the subjects dealt with in this chapter consult the general pathology, "Les Processus Généraux" of *Chantemesse* and *Podwysotsky*, 1901, or *Wells*, "Chemical Pathology," 1907.

servative in their nature, and, even as normal cell functions do, tend—within the limitations of an emergency—to the welfare of the individual?

The Rôle of the Exudates.—In the hope of gaining some light upon this question let us look a little more closely at the part which the exudates play in exudative inflammation; and first at the leucocytes.

The Leucocytes.—It was through the painstaking and brilliant studies of Metchnikoff¹ that attention was directed to the importance in this connection of comparative studies upon the comportment of lower forms of life in response to injury.

It was found that amœba, one of the simplest of organisms, when cut in two may undergo complete restitution of the part containing the nucleus, provided the latter be uninjured. The remaining portion may live for a time, but ultimately dies. Furthermore, it was found that amœba and other lowly forms of living beings are capable, by the use of their simple digestive processes, of destroying micro-organisms which are taken into their interior and which might otherwise damage or kill them. Thus it was established that the digestive mechanism may become protective in lowly organized cells.

Rising in the scale of living beings, it is found that in forms in which considerable differentiation of some of the cells has taken place, whether there be a distinct circulatory apparatus or not, certain other cells are left in a more primitive state: these are phagocytic and can ingest or otherwise destroy deleterious material.

When we come to man and other warm-blooded animals, it is upon the leucocytes which have retained so many of the capacities of undifferentiated protoplasm that attention is especially concentrated. It has been found, as we have already seen, that the movement of leucocytes may be directed toward (sometimes from) chemical substances set free in their vicinity. This chemotaxis is frequently manifested in the vicinity of dead cells or tissues which are the seat of destructive metabolism. But it is especially in relation to micro-organisms of various forms that chemotaxis in the leucocytes is of the highest significance to us here.

Highly virulent micro-organisms may for a time repel the leucocytes, probably through negative chemotaxis, but these may later approach. On the other hand, leucocytes most often migrate toward bacteria which have gained entrance to the body. It has been proven that leucocytes, especially the polynuclear neutrophiles, and frequently large mononuclear forms, may take into their interior and destroy living bacteria. Dead bacteria also, as well as other inert material, they can engulf and destroy.

The Body Fluids.—This capacity of leucocytes and other mesodermal cells—endothelia, etc.—to take up living bacteria and kill and digest them was persistently and ably urged by Metchnikoff and his pupils as the chief protective agency in the body against bacterial incursions, and to these observers all the other phenomena of inflammation formerly seemed of secondary importance. But it was soon shown that this ex-

¹ Metchnikoff, "Comparative Pathology of Inflammation," Eng. trans., 1893.

treme view is not correct. For it was demonstrated by many observers that the body fluids, especially blood serum, are capable of killing bacteria with which they come in contact. When, however, this remarkable quality of the body fluids was investigated, it was found that it is most pronounced under conditions which involve the breaking-down of leucocytes or the liberation of the destructive substances into the fluids. It was possible now to demonstrate that the leucocytes do, in fact, contain a germicidal proteid substance or substances. These substances, which appear to be closely associated with or related to nucleinic acid, have been called "alexines" or "protective proteids."¹ It has been further demonstrated that while the eosinophile cells may move toward bacteria, they are not phagocytic, but may set free granules which appear to favor the destruction of the germs.

It thus appears that the earlier view of the almost exclusive importance of phagocytosis is not sustained, but that even more than in the action of living phagocytes the protective agencies are to be sought in the body fluids. But it is also clear that the protective capacities of the body fluids are the result of cell activities, as indeed might have been inferred in advance of the long line of careful experiments which finally led to the demonstration.

The importance of this protective power of the body cells and body fluids is not exhausted with their germicidal action. For not less significant is the rôle which these may assume in the establishment of other phases of immunity to the incursion of micro-organisms. This will be considered later in the general survey of the infectious maladies (page 160).

If now one seek for ways in which the other exudates, serum, and fibrin may be useful to the individual, it is obvious that in the dilution of locally engendered poisons and in their removal from a vulnerable region the fluid may at times be beneficial. Fibrin, too, by closing inflammatory foci, through temporary adhesions, or by the sealing of absorbent surfaces, may limit the extension of injurious agents, as is so frequently the case in local infectious injuries in the peritoneal and pleural cavities. That the regeneration and repair of tissue which may be associated with or follow the more active phases of inflammation are, as a rule, beneficent, is not doubtful.

There is, of course, another side to the matter. For new cicatricial tissues which have formed in the process of repair may be so situated as to cause serious impairment of functional performance or even fatal strictures. The gathering of leucocytes, too, may be so excessive and their proliferation so extreme as to lead to delayed healing or to serious exhaustion from suppuration. But notwithstanding these irregularities and failures there seems to be good reason for the belief that, on the whole, the processes involved in inflammation are conservative, and, within the limitations which may be set by the varied and changing conditions of injury, tend to maintain the welfare and sustain the life of the individual.

¹ For further consideration of this subject see p. 160.

CHARACTERIZATION OF THE INFLAMMATORY PROCESS.

The general conception of inflammation which we have just set forth looks beyond the gross manifestations of disordered function and altered structure, by which it was originally marked, and beyond the complex and varied expressions of aberrant cell activities, with which our later science has mostly dealt, to the fundamental qualities of living substance. And thus at last, with the heart of the subject in view, a characterization of inflammation becomes possible which is suggestive and useful, though it may not indeed be final. Perhaps among many such characterizations, that of Adami¹ is on the whole the most clear and precise, and with him we may at present wisely consider inflammation as "the local attempt at the repair of injury." The fundamental conception upon which this characterization is based is that inflammation is an emergency measure incited by injury, in which the body adapts to unusual ends as best it can mechanisms and powers normally maintained for other purposes.

This view of inflammation, however much it may be modified as our knowledge grows, recognizes a far-reaching significance in the complex processes involved. And while throwing light upon the practical problems of the physician, it points the way to a broader conception of other abnormal conditions in which also the adaptation of physiological cell capacities to new conditions seems to furnish a clew to many manifestations of disease as yet but little understood.²

Now that we have gained a conception of the inflammatory processes in general and some suggestions as to their significance, it does not seem necessary to enter here upon a detailed description of the variations which they present, since these are largely influenced by the character of the inciting agents and by the situation in which they act. Such details as may fall within the scope of this work are given in the section dealing with micro-organisms as inciting factors in disease, and in the part dealing with the lesions of special organs.³

The Experimental Study of Resorption of Foreign Material, Phagocytes, etc., in Inflammation.

Aside from clinical material illustrating the healing of wounds and various phases of repair from the lower animals, by very simple operations, to be done with local or general anæsthesia, one may obtain many valuable series of demonstrative lesions.

¹ For a fuller consideration of inflammation from the point of view which in general is here adopted, one may consult the excellent article on "Inflammation" by Adami in Allbutt's "System of Medicine," vol. i., p. 54.

In Thoma's work on "General Pathology," vol. i., is a clear exposition of the various processes concerned in inflammation, with a fuller recognition than is commonly accorded to them of the mechanical factors involved. In both of these works the more important bibliography may be found.

For bibliography and critical *résumé* of studies on pathological organization, inflammation, etc., see Borst, Lubarsch and Ostertag's *Ergebnisse*, Jahrg. iv., for 1897, p. 461. See also references under Regeneration, page 79, and under Tumors, page 351.

² Consult, for a clear and comprehensive view of adaptation in pathological processes, Welch, *Transactions of the Congress of American Physicians*, vol. iv., p. 284, 1897.

³ For a systematic and extensive *résumé* of inflammatory phenomena, phagocytosis, chemotaxis, emigration, diapedesis, protoplasmic poisons and irritants, the nature of exudates, and the general physical chemistry of the cell, with extensive bibl., see Heinz, "Handbuch d. exp. Path. u. Pharmakol.," 1904, Bd. i.

PHAGOCYTES.—The injection of 1 per cent. agar—such as is used for bacterial cultures, which fluidifies at about 40° C. and becomes semisolid on cooling—into the anterior chamber of the eye or into the subcutaneous tissue of the rabbit gives most instructive pictures of absorption and phagocytosis. Phagocytes of connective-tissue origin bring about the solution of the mass and permeate it. If the agar be colored with Berlin blue in the form used for blood-vessel-injection masses, the phagocytes may become more or less filled with the blue granules as absorption proceeds. In the absorption from the anterior chamber in dark-colored rabbits the origin of the phagocytes in the iris is revealed by their pigmented character. Giant cells are often formed in this process, aiding in the resorption.

The action of phagocytes in disposing of foreign material in the lungs may be seen by making intratracheal injections of a watery emulsion of lampblack or finely powdered charcoal in rabbits. The pigment particles will be found both free and within epithelial phagocytes in the air vesicles within a few days. The animal should be sacrificed and the lungs filled with formalin solution or alcohol through the trachea (see p. 1010), after which the tissue is embedded and sectioned.

Very instructive studies may be made of the disposal of insoluble foreign bodies by the implanting of small fragments of cotton, jute, elder pith, etc., beneath the skin, and their removal after varying intervals.¹

Practical Study of Exudative Inflammation on the Living Frog.

In the study of exudative inflammation it is of the highest value to see the phenomena of emigration, diapedesis, etc., on the living animal. The curarized frog is best adapted for this purpose,² and either the mesentery or the bladder affords much clearer pictures than the tongue or the web, which are sometimes recommended.

THE MESENTERY.—In a fully curarized frog an incision is made through the skin along the abdomen in the axillary line, care being taken to avoid or ligate a large vein which usually crosses the line of incision. The abdominal wall is then cut through in the same line, and a loop of small intestine drawn out, care being taken to bring out only as much as may be necessary to expose over the glass window of Thoma's frog plate³ (see Fig. 72) a small area of mesentery. The loop may be fixed by short pins passed through the superficial layers of the intestine into strips of cork which are crowded in beside the raised glass window. The exposed loop should be irrigated with three-fourths-per-cent salt solution which may be made to trickle over the part from a reservoir through a glass cannula held by the cannula-holder (see Fig. 72). Peristaltic movements of the intestine sometimes cause the field of observation to shift and stasis may occur if the loop be drawn too tightly. But through a little attention to adjustment from time to time difficulties may be reduced to a minimum. For long observations a cover-glass may be laid upon the loop under which the irrigation proceeds.

In this way observations may be made on arteries, capillaries, and veins, extending over several hours. Long focal distance, high-power lenses may be used.

THE BLADDER.—The bladder of the frog is a bilobed organ opening into a cloaca just within the anus and common to it and the intestine. To expose the bladder an incision is made in the axillary line along the lower half of the abdomen, including the skin and the abdominal wall. The bladder frequently prolapses at once to a moderate extent through this opening. Now a glass cannula is made with a tapering tip with the

¹ For a full exposition of methods of experimental pathology relating to inflammation see *Heinz*, "Handbuch d. exp. Path. u. Pharmak.," Bd. i., Th. i., p. 255, 1904.

For many suggestive studies in phagocytosis see *Melchnikoff's* "Immunity in Infectious Diseases." Consult, for the technique of studies on absorption from the peritoneum, *Buxton and Torrey*, Jour. Med. Res., vol. xv., p. 5, 1906.

² For the use of curare see p. 34.

³ Thoma's frog plates are of three forms, adapted for the study of the tongue, the mesentery, and the bladder or lung. They are plates of brass covered with hard rubber in which glass windows are set so that when put on the stage of the microscope the light passes up through the exposed organ to the eye. They are provided with cannula-holders for irrigation with physiological salt solution and with pipes for carrying away the waste irrigation fluid. The three forms of plate are shown in Fig. 72.



FIG. 72.—THOMA'S FROG PLATES.

The upper plate is adapted to the study of the circulation in the mesentery. The middle plate is for the bladder and lung. The lower plate is for the tongue.

tip for about half an inch bent to an angle of about 45° to the axis of the tube. The tube should be large enough to pass the anal orifice with difficulty except at the tip and along the bent portion.

A thread is now passed through the skin just behind the anus, the ends being left free. The cannula and a short length of flexible rubber tubing slipped over the larger end are filled with three-quarter-per-cent. salt solution, this being retained by a clip on the tube. The bent point of the cannula is now inserted into the cloaca and its tip carried forward into the base of the bladder and fastened in place by the thread. The frog is laid on its back on the Thoma plate adapted to the bladder and lung (Fig. 72). The rubber tube is attached to a slightly raised flask so that the salt will siphon into the bladder under a very low pressure. Now if the clip be released the bladder will appear in the opening of the abdomen and will be pressed out as a transparent bag by the salt solution over the glass window in the plate. Great care should be taken to avoid more distention of the bladder than is necessary to keep it spread over the glass, since the circulation is very easily disturbed or interrupted. A cover-glass may be laid upon the bladder or held in place over and touching it by an upright attached to the plate for this purpose, and irrigation with salt solution started and maintained.

If the circulation is compromised one should see that the base of the extruded portion of bladder is not pressed upon by the abdominal walls; that it is not overfilled and is not pressed too much by the cover. By attending to those points in a frog not over-curarized one may maintain the circulation for hours. Since the wall of the bladder is very thin, consisting of little else than the almost invisible epithelial lining, a membranous connective-tissue wall reinforced here and there by slender bundles of smooth muscle cells, and the blood-vessels, one secures in this organ pictures of the blood-vessels of incomparable clearness and may study the minutest phases of the circulation and its disturbances, emigration, etc. The contraction of the muscle bundles brings about occasional shifting of the field, but this is not usually a serious drawback to continuous observation even with high-power lenses.

On the whole, though slightly more difficult to prepare, the bladder is to be preferred to the mesentery for studies on the minute phenomena of emigration, diapedesis, hæmorrhage, etc., and it is admirably suited to the study of the local effect of drugs, such as adrenalin, on the circulation.

In neither the mesentery nor the bladder is it necessary to injure the organ further than is inevitable in the preliminary operation and exposure, in order to incite the inflammatory phenomena in the vessels. In both organs the course of the emigrated leucocytes may be followed through the interstices of the tissues after they have left the vessels. It is most instructive after the observations on the living animal are completed to pith or decapitate the frog, fill the bladder with a fixative such as Orth's fluid, in which the organ after ligating is placed, and finally to scrape off the epithelium, stain with hæmatoxylin and eosin, and mount pieces of the wall in balsam for study.

THE LUNG.—The circulation in the lung and various phases of its disturbance may be studied on the living frog by the use of the Thoma plate especially adapted for the bladder. The preliminary operation is made in the axillary line, the long incision reaching forward to the axilla. A cannula tapering to one end so as to pass between the folds of the glottis for five or six mm., but not to slip further in, is tied in place by a thread through the snout of the curarized animal. A flexible rubber tube over the free end of the cannula, which extends a couple of centimetres beyond the snout and is controlled by a clip, enables one to blow into the lung and force it out through the incision. The inflation should not be excessive and the base of the lung should not be constricted. The animal is placed on its back upon the plate with the distended lung over the glass window and irrigated in the manner above indicated for the bladder. The picture of the circulatory districts of the single-sac lung with the blood shooting through the rich capillary network and entering the veins is most interesting and important for one who would appreciate the significance of lung lesions involving, as most of them do, disturbances of the circulatory mechanism.

CHAPTER VI

ANIMAL PARASITES.

Protozoa.

General Characters of the Protozoa.—The protozoa are, with few exceptions, unicellular animal organisms of a primitive type, reproducing by division, by budding, and by spore formation. Some are very minute, others many millimetres in diameter. Some of them seem to lie between and to link the two great divisions of living beings somewhat arbitrarily established—the animals and the plants.

While some of the protozoa are relatively simple in structure, others are extremely complex. The life cycle, also, of some forms is simple, while others, passing through sexual and asexual phases, present at different periods the greatest diversity in form and function.

Some protozoa maintain an independent existence, others are parasitic for men and animals. Among the parasitic forms are important groups which require residence in the body of more than one animal species for the completion of their life cycle. Many of the protozoa possess organs of locomotion, pseudopodia, flagella, and cilia.

Our knowledge of the protozoa parasitic in man is of recent date, but is accumulating with great rapidity especially as regards tropical forms. Many forms are so difficult to study and to classify that for the moment, in numerous instances, conjecture and a balancing of probabilities and analogies are made to do duty in lieu of facts.

Although not yet proven, it is widely believed that some if not all of the exanthemata, yellow fever, and it may be hydrophobia, are probably incited by some form of parasitic protozoa.

Modes of Transmission of Protozoan Parasites.—Some forms of protozoa are transmitted by *contact*, as in certain trypanosomes and the syphilis organism; others are *ingested* with food and drink.

Congenital transmission of the syphilis organism is of frequent occurrence.

So confident are many observers that small-pox and scarlatina are incited by protozoan parasites, presumably by such as in the development of their life cycle form minute spores, that they venture to assume that in these diseases, at least, the infective agent may be *air-borne* in floating dust.

Finally, in many instances, infection takes place through *transmission by intermediate hosts*. This is the case in malaria, yellow fever, and with certain trypanosomes and sporozoa. In the transmission of the malarial organism by the mosquito and in some trypanosomes, important phases in the life cycle of the parasite take place in the body

of the intermediate host. Other insects—ticks, bed-bugs, and leeches—act as intermediaries, especially among the lower animals.

The Effects of Protozoan Parasites upon their host are in many cases obvious, in many quite obscure. We shall consider some of these in the brief review of species which follows.

Cultivation of Protozoa.—It has been found practicable to cultivate artificially some forms of protozoa—amœbas, trypanosomes—by modifications of the methods so fruitful with the bacteria. But, owing partly to the complexity of the life cycle in some of the protozoa, and to the fact that some are always naturally parasitic under peculiarly complex conditions, the knowledge thus far derived from artificial cultivation is limited.

The scope of this book does not permit more than this brief general survey of the protozoa which, as we are but just beginning to realize, share so largely in the infective maladies of man and the lower animals. Nor can we do more than consider briefly some of the most significant forms which are related to human pathology.¹

The Classification of Protozoa.—The protozoa are commonly separated into four primary divisions which are based upon the existence or the character of motile organs, pseudopodia, flagella, and cilia, as follows:

- I. SARCODINA.—Movement by pseudopodia.
- II. MASTIGOPHORA.—Movement by flagella.
- III. INFUSORIA.—Movement by cilia.
- IV. SPOROZOA.—Without motile organs; all parasitic.

I. SARCODINA.

The protozoa of this division are usually of simple structure, characterized mainly by motile organs in the form of changeable, broad or slender, protoplasmic processes—pseudopodia. Reproduction is by division and by spores.

In the class of rhizopoda of this division are forms parasitic and pathogenic in man. Among the longest and best known of these are the amœbas.

Entamœba histolytica (*Amœba dysenteriae*) is of considerable pathologic importance. Councilman and Laffeur² in 1891 first definitely established the significance of this protozoan parasite which they called *Amœba dysenteriae*, a name now superseded by *Entamœba histolytica* of Schaudinn.

It has been repeatedly found in acute and chronic dysentery, most frequently in the tropics, in the intestinal contents, at the bottom of the

¹ For a résumé of our present knowledge of the parasitic and other protozoa, consult Nory, *The Rôle of Protozoa in Pathological Processes*, Path. Soc., Phila., x, 1907. *Calkins, Protozoology*, 1909, is a valuable and readable epitome of the subject and rich in interesting data and views bearing upon human and animal pathology, bibl. See also the excellent epitome in *Park and Williams, Pathogenic Bacteria and Protozoa*, 1910, where also references to standard works will be found.

² *John Hopkins Hosp. Rep.*, ii., 395, 1891.

intestinal ulcers, and in the secondary abscesses, especially of the liver, which may accompany ulcerative colitis. The amœba is believed to be the inciting factor, in some cases, in both the primary ulcerative colitis and its complicating abscesses (see page 676).

This amœba (Fig. 73) is a spheroidal cell, from five to eight times the diameter of a red blood cell, with granular protoplasm and a vesicular nucleus. It often contains larger and smaller vacuoles. Frequently, especially when the amœba is active, a portion of the protoplasm appears almost homogeneous—ectosarc—while the rest—endosarc—is granular. When moving it assumes various forms, thrusting out and withdrawing nearly homogeneous pseudopodia. It may also change its shape without progressive movement. It occurs in acute and chronic dysentery, frequently in Egypt, occasionally in Russia, India and the Philippines, and is often seen in the United States.¹

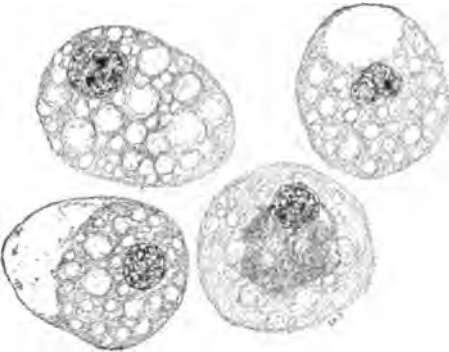


FIG. 73.—*ENTAMOEBA HISTOLYTICA*.
From the intestinal wall near an ulcer in amœbic colitis.

The parasite is capable of making its way between the epithelial cells of the intestinal canal, but the way in which lesions are induced is not clear. The organism has been artificially cultivated.²

Animal inoculations with this species have given positive results. For the details of these as well as the differentiation between this and the common non-pathogenic intestinal *Entamoeba coli*, see special works on protozoa and clinical pathology.

Other species of amœba have been found in the human mouth, intestines, and bladder, but are apparently not pathogenic. The *Entamoeba coli* is very frequently present in health and in intestinal disorders other than dysenteric.³ There is reason to believe that amœbas are acquired through drinking water and uncooked foods.

NEGRI BODIES AND CYTORYCTES.

The so-called "Negri bodies," (page 295), so constantly present in brain cells in hydrophobia, and certain cell inclusions in the lesions of small-pox, have been interpreted as parasitic protozoa, named respectively *Neuroryctes hydrophobiae* and *Cytoryctes variolae*, and classified among the pathogenic rhizopods.

¹ We refer for further details concerning the *Entamoeba histolytica* to the work of *Councilman and Lafleur* on "Amœbic Dysentery," Johns Hopkins Hospital Reports, vol. ii., p. 395, 1891. For a method of differential staining of the *Entamoeba histolytica* see *Mallory*, Journal of Experimental Medicine, vol. ii., p. 529, 1897. For a résumé of Amœbas, cultivation and significance, see *Musgrave and Clegg*, Bureau of Govt. Labt. Dept. of the Interior, Biological Laboratory No. 18, Oct., 1904, and *Strong* on "Amœbic Dysentery," in Osler's "Modern Medicine," vol. i.

² See *Musgrave and Clegg* ref. above.

³ See *Craig*, Jour. Infec. Dis., v., 324, 1908.

II. MASTIGOPHORA.

These organisms are of definite or changeable shape, with or without a membrane. They are characterized by the possession of one or more undulating or vibratile processes or flagella. Some forms seem to be closely related to the bacteria.

Trypanosomes.—Among the flagellated protozoa the trypanosomes are of much significance, occurring as free swimming parasites in the blood of both cold- and warm-blooded animals—mammals, birds, reptiles—and in the intestines of certain blood-sucking insects—flies, mosquitoes.

Trypanosomes are elongated, usually pointed, and may have one or two flagella and an undulating membrane at the side attached to the flagella (Fig. 74). The membrane is often attached in folds or undulations so that the movement of the parasite in swimming is somewhat augur-like. They reproduce by division.

In many instances the trypanosomes seem to be of no special significance to the host, but in several of the lower animals and in man some species are markedly pathogenic.

Trypanosomes are common in wild rats in all countries. The species infesting these animals, *Tr. lewisi*, can be readily transmitted with the blood to a fresh animal by injection and does not appear to interfere with the well-being of the rats. A certain immunity to subsequent injections seems to be conferred by the presence of these parasites in the blood of the rat, from which they usually disappear in two or three months.

Novy and McNeal first successfully cultivated the *Trypanosoma lewisi* and other forms on nutrient agar containing varying amounts of defibrinated or laked rabbit blood.

Pathogenic Trypanosomes.

Tsetse-fly Disease.—Among the more important of the trypanosome infections we may note *Nagana* or the tsetse-fly disease (Fig. 74). This infectious disease of cattle, horses, and mules occurring in Africa, especially in Zululand, has long been known and was at one time of great economic importance. It is characterized by fever, emaciation, edema, etc.

In 1894 Bruce discovered a trypanosome—*Tr. brucei*—in the blood of the affected animals. He also found that the parasite was conveyed to healthy animals through the bite of a tsetse-fly of that country—*Glossina morsitans*—which had shortly before bitten an infected animal. The original source of the parasite was found to be the wild animals of the region, which did not appear to be affected by it. Man is immune to this species of trypanosome.

Surra.—This disease of horses and cattle, occurring in India, and possibly in other tropical countries, has been shown to be due to a trypanosome, *Tr. evansi*, which is conveyed from infected to healthy animals by a fly.

Several other diseases of wild and domestic animals are known to be incited by trypanosomes.

Sleeping Sickness.—The “sleeping sickness” is very common and fatal among the negroes of equatorial Africa, assuming in the Congo region the character of a veritable pestilence whose victims number hundreds of thousands. White men are not exempt. The disease, still rapidly extending, is characterized by lethargy, debility, emaciation,

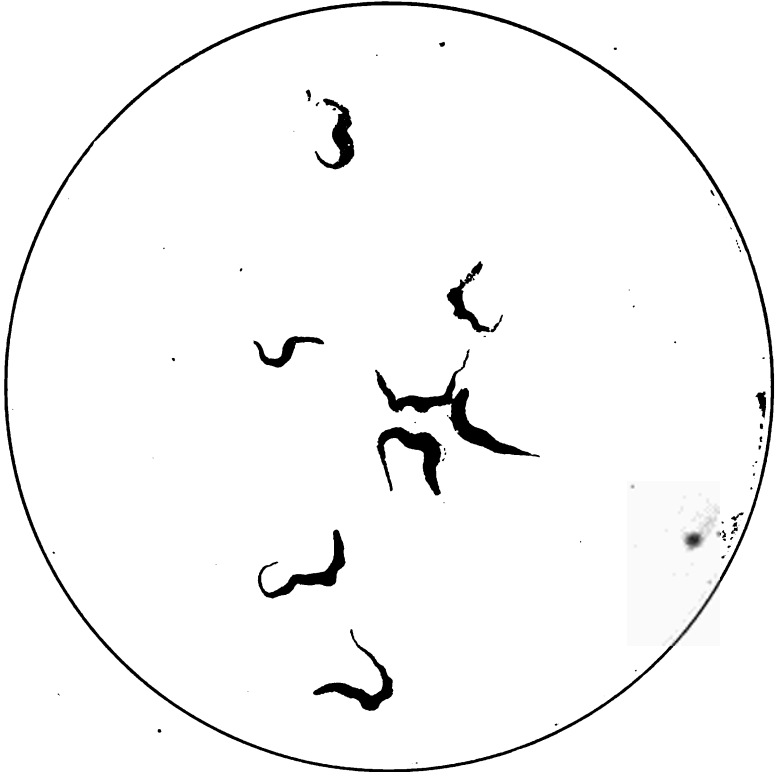


FIG. 74.—*TRYPANOSOMA BRUCEI*.

The protozoan parasite of the tsetse-fly disease of Africa.

drowsiness, coma, and death. It is incited by a trypanosome, *Tr. gambiense*, which also is conveyed by a tsetse-fly, *Glossina palpalis*. The lesions noted are congestion of the meninges with fluid exudate and enlargement of the lymph-nodes, spleen, and liver.¹

Spirochæta.—Among the spirally curved bacteria it has been customary to recognize a genus called *Spirillum*, the members of which have a rigid spirally curved body, and a genus called *Spirochæta*, in which

¹ For a summary of trypanosomes and diseases incited by them, see *Novy*, The Harvey Lectures, 1905-6; Jour. Am. Med. Assn., Jan. 5, 1907. For a study of trypanosomiasis with special reference to service in the Philippine Islands, see *Musgrave and Clegg*, Department of Interior, U. S. A., Bureau of Government Laboratories, 1903. For a study of specific chemical therapy in trypanosomiasis, see *Terry*, Arch. Int., Med., iii., 98, 1909.

the organisms are also spirally curved but are described as flexible. These genera have been considered to embrace closely related bacterial forms.

The discovery by Schaudinn of *Spirochæta*, now called *Treponema pallidum* (Fig. 75), in the lesions of syphilis has given rise to many critical studies of spirochetes, and while we cannot enter here into the details of the matter, it has finally become probable, if not entirely proven, that the spirochetes are protozoa and not bacteria or at least that the protozoan characters are predominant in them.¹

The remarkable achievement of Ehrlich in creating, on a carefully projected theoretical basis, the synthetical chemical compound of arsenic, dioxidydiamidoarsenobenzol, popularly known as 606, which has

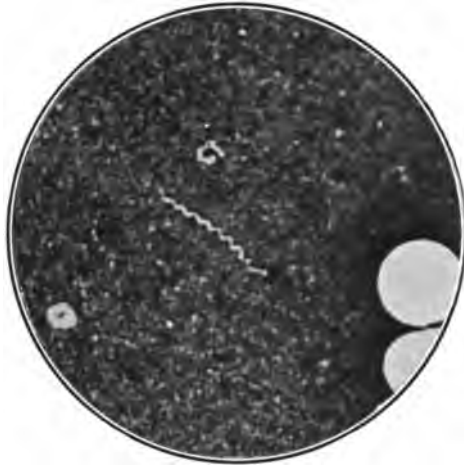

FIG. 75.—*TREPONEMA PALLIDUM*.
Stain by the India ink-method (see p. 278).

a specific destructive action on the life not only of the spirochetes of syphilis and of relapsing fever, but upon trypanosomes as well, would indicate a relationship between the spirochetes and the protozoa which tends to confirm the evidence from morphology.

Treponema (Spirochæta) Pallidum.—This organism, now believed to be a protozoan and the inciting agent in syphilis, is described in connection with the lesions of that disease on page 274.

Spirochæta Obermeieri.—The protozoan organism inducing relapsing fever and *Spirochæta pertenuis* of Castellani will be considered among the infectious diseases, see page 292.

The occurrence of spirochetes in tumors is as yet of such uncertain significance that this mention may suffice.

Leishman-Donovan Bodies.—In some forms of cachexial fever of India associated with enlarged spleen and marks of profound toxæmia—the so-called kala-azar; dum-dum fever—there have been found in the spleen, blood, etc., peculiar bodies

¹ For a discussion of this subject, see *Calkins' "Protozoology,"* p. 231, 1910.

now known as the Leishman-Donovan bodies which were believed to belong to the trypanosomes and have given rise to much discussion. More recently they have been placed in the genus *Herpetomonas*—an allied form of flagellata or protozoa—in which are organisms commonly parasitic in the fly. The organism is believed to be transmitted to man through the bite of the bed-bug. For further details, see p. 480.

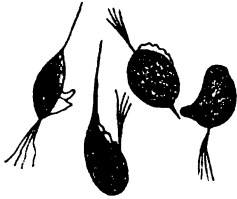


FIG. 76.—TRICHOMONAS VAGINALIS.
After Dock.

Trichomonas vaginalis has an oval or pear-shaped body from 0.015 to 0.025 mm. long, with a cluster of flagella at one end and an undulating membrane, frequently mistaken for cilia, upon the side (Fig. 76). It is of occasional occurrence in vaginal exudates. The possibility of mistaking the *T. vaginalis* for human spermatozoa should be borne in mind in medico-legal examinations, although to an observer familiar with either structure such a mistake could hardly occur.

Some forms of *Trichomonas* have been found in the urine of man, in the intestines, and in the sputum.¹

III. INFUSORIA.

The infusoria are the most highly differentiated of the protozoa. They have numerous motor appendages or cilia, which may persist through life or in some forms be replaced in the adult stage by suctoria. They reproduce chiefly by fission, or budding. Among the ciliated infusoria, few if any are pathogenic in man. The *Balantidium coli* (Fig. 77) is an ovoidal organism from 0.06 to 0.1 mm. long; it is a common parasite of swine in some regions, and has been found a few times in the intestinal tract of man under conditions which indicated its probable pathogenic significance.

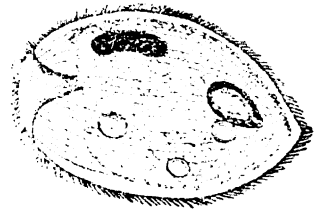


FIG. 77.—BALANTIDIUM COLI.
After Braun

IV. SPOROZOA.

The sporozoa are all parasitic, living at some period of their life cycle in the cells of their host, and are especially characterized by their reproduction through encystment and spore formation and absence of definite motile organs. Many forms of the organisms, especially the spores, are very minute and difficult of identification.

The sporozoa are widely distributed, being found as parasites in nearly all classes of animals. They may invade the gastro-intestinal canal and the kidney and their adnexa, the blood, muscle, connective tissue, and skin. While many of them appear to be harmless to their host, others may do serious damage by blocking the tissue spaces and thus, or in other ways, inducing necrosis, atrophy, or cell death. Some forms are wholly intracellular, others remain for only a part of their life cycle within single forms of cells, passing then to other cells or to the

¹ For original studies of *Trichomonas* with historical summary and bibliography, see Dock, *Am. Jour. Med. Sc.*, vol. cxi, p. 1, 1896.

body cavities or to hosts of a different species. The life cycle of many forms is extremely complex. On account of their strict parasitism and the requirements in some instances of an interchange of hosts, precluding the methods of culture applicable to many of the lower organisms, the life history of many forms is still unknown or obscure.

The classification of the Sporozoa is still tentative, but one may conveniently recognize the following orders:

1. *Gregarinx*.—These are round or elongated parasites, some of the higher forms presenting partitions in the cell with special development of one end for attachment. They are parasitic in certain cold-blooded animals, especially the invertebrates. The young stages only are intracellular, mature forms occurring in the body spaces.

2. The *Myxosporidia* are parasitic in certain of the invertebrates, in fishes and batrachians. Epidemics among silk worms incited by a parasite of this class have occasioned serious losses. Many species are concerned in diseases of fish, in which they may cause extensive deep foci of necrosis and ulceration.

3. *Coccidia*.—Organisms of this order are parasitic in certain of the invertebrates, in birds, reptiles, and mammals. They are round or oval, usually intracellular parasites having no free motile adult stage. They are most frequently found in the epithelium of the intestine and liver.

One of the most common forms in the mammalia is *Coccidium oviforme* (Fig. 78) which is of frequent occurrence in the liver of the rabbit, forming a part of the contents of yellowish irregular shaped masses, resembling tumors, or in the form of cysts.¹

The parasites surround themselves with a capsule within which elongated sporozites develop. This encapsulated form may be taken up by a new host in which the sporozites are set free and enter the epithelial cells in which they again become encapsulated.

The occurrence of *Coccidium oviforme* has been recorded in the liver, kidney, and heart-muscle of man.

Another smaller form, occurring in the intestinal epithelium of dogs, cats, and rabbits, has been found in two cases in a similar situation in man.

Rixford and Gilchrist² have described in detail two cases of protozoan (coccidoidal) infection of the skin and other organs, making a careful comparison between these and organisms somewhat resembling them which have been found in various skin lesions.

4. *Sarcosporidia*.—In this order of the Sporozoa the usually elongated slender early stage is found in between the muscle fibres and bundles of vertebrates—mouse, hog, and, in a few instances, in man. These are commonly known as the "tubes of Miescher" or "of Rainey." Reni-

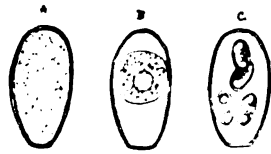


FIG. 78.—*COCCIDIUM OVIFORME*.
This shows the encapsulated form of the parasite, with the formation of spores.

¹ See Tyzzer, Jour. Med. Res., vol. vii., p. 235, 1902, bibl.

² Johns Hopkins Hospital Reports, vol. i., p. 209, 1896, bibliography.

form or falciform spores are developed. The adult forms are spheroidal or elongated. The life cycle is not well known.¹

5. *Hæmosporidia*.—These parasites of the blood form a large group occurring in the corpuscles or plasma of vertebrates—amphibia, reptiles,² birds, and mammals. Some forms are among the most important of the protozoan parasites of man. They are of small size; the adult form is motile. One stage in the life cycle is passed in the blood of the vertebrate host. Another stage or cycle may be passed in the body of some insect, acting as an intermediate host.

Among the mammalian hæmosporidia we may mention the hæmatozoa of malaria and the hæmatozoon of Texas fever.

Malaria.—The characters of the malarial hæmatozoon, for which the mosquito acts as intermediate host, are described in detail on page 312.

Texas Fever.—Texas fever (tick fever), a disease of cattle marked by fever, debility, and hæmoglobinuria, occurs in many parts of the world—North and South America, Europe, and Africa. The hæmatozoon inducing Texas fever was discovered by Theobald Smith and Kilbourne³ and is now called *Piroplasma bigeminum*.⁴ In one stage it is a minute pyriform organism occurring often in pairs in the red blood cells of its host. Free forms have been found in the blood. While its life cycle has not been completely worked out, Smith and Kilbourne showed that a cattle tick acting as an intermediate host transmits the parasite through her eggs and larvæ. It is through these young ticks that fresh cattle become infected.⁵ Other species of *Piroplasma* have been found in the dog in various countries; still others in horses and sheep.

Methods of Study of the Protozoa:

The protozoa may be studied in the living condition either in the fluids in which they are found or in three-quarter-per-cent. salt solution. They may be killed and preserved by allowing a drop of one-per-cent. osmic acid to run under the cover-glass, and replacing this after an hour by glycerin lightly tinged with eosin. Or they may be killed by sublimate solution and stained.

Many of the smaller forms show well when dried on the cover-glass and stained with the anilin dyes by the methods used for bacteria (see p. 143).

The movements of the *Entamœba histolytica* in the fæces or in the contents of abscesses, which frequently contain them in enormous numbers, may be studied on the warm stage in three-quarter-per-cent. salt solution. Its morphology may be studied in tissue containing it, such as intestinal ulcers, abscesses, etc., which have been hardened in alcohol and stained either with methylene blue or hæmatoxylin, the former being especially commended by Councilman and Lafleur.

The attempts to obtain pure cultures of certain forms of *Amœba* and similar or allied forms of protozoa have been partially successful. The method by which McNeal and Novy obtained pure culture of trypanosomes, namely, by the use of ordinary nutrient agar containing rabbit's blood, is of high promise in related forms of protozoa.

¹ For a study of the production of sarcosporidia in the mouse see *Theobald Smith*, *Trans. Assn. Am. Phys.*, vol. xvi, p. 576, 1901.

² See *Langmann*, "Hæmosporidia in American Reptiles and Batrachians," *N. Y. Med. Jour.*, January 7, 1899.

³ *Smith*, *Bull. Bur. An. Industry*, No. 1, 1893.

⁴ *Piroplasma* and allied genera are now often described under the generic name *Babesia*, and the form here considered is named *Babesia bovis*.

⁵ For a summary of observations on Texas fever (Hæmoglobinuria of Cattle) see *Kossel*, in *Kolle and Wassermann's "Handbuch der Mikroorganismen,"* Bd. i., p. 841, bibl.

For details of this method as well as a *résumé* of the cultivation of protozoa, consult *McNeal and Nory*, "Contributions to Medical Research, Vaughan Anniversary Volume," 1903, p. 549.

Metazoa.

Among the multicellular parasites, the worms—the flat flukes and tape-worms as well as the round worms and a few insects—form the most important classes for our consideration. But for the details concerning these as well as the other larger parasites we must refer to special works on parasitology.

It may be said in general that the metazoan parasites may be harmful to the structure or the function of the host, though the damage is often very slight, either by their local presence, occluding canals, obstructing vessels, inducing local irritation, or structural damage, or by their movements about the body; by the appropriation of food belonging to the host; or, finally, by the setting free of deleterious metabolic products of their own manufacture.

This toxic action of certain parasites is especially marked by the more or less pronounced eosinophilia present in a large proportion of patients who are the victims of invasion by parasitic worms.¹

The frequent anæmia associated with the presence of metazoan parasites and the local injuries inflicted by them, especially of the mucous membranes, through which the body is made more vulnerable to secondary bacterial invasion, are all of considerable importance. Some of these effects will be referred to in the following brief series of individual forms of metazoan parasites.

WORMS.

TREMATODA (Flukes).

These worms are small, flat, tongue-shaped, or leaf-like creatures, with an intestine, and a discoidal structure on the under surface, by means of which they attach themselves. There are several genera and species found in man. The most common genus is *Distoma*. Of these *D. hepaticum* is of most frequent occurrence (Fig. 79). It is about 30 mm. long, and usually occurs in the gall-ducts and gall-bladder. The embryos are often attached to water plants, from eating which the infection is believed to occur. *D. lanceolatum* is more slender, pointed at the ends, 8 to 10 mm. long, and has been found a few times in the gall-bladder. *D. sinense* is a slender worm about 15 mm. long, and has been found in the bile in considerable numbers, particularly in the Chinese. *D. hæmatobium* is a more nearly cylindrical worm; the sexes are distinct, the male from 12 to 14 mm. long, the female 16 to 18 mm. long, and the parasite occurs, especially in Egyptians, in the portal and other abdominal veins.



FIG. 79.—*DISTOMA HEPATICUM*.
About natural size.

¹ See for a study of the influence of parasites on the host, *Ward*, *Science*, vol. xxv., p. 201, 1907; consult also *Shiple and Fearnside*, *Jour. Economic Biology*, vol. i., 1906.

CESTODA (Tape Worms).

These important worms consist, in the mature state, of more or less rectangular or elongated flat segments, each one representing a single individual, arranged in a linear series to form a colony. At one end of this, called the head, is a variously formed structure for the attachment of the colony to its host. The neck and head are called the *scolex*, while the segments are called *proglottides*. These worms have neither mouth nor alimentary canal. They are hermaphrodites, the sexes being united in the proglottides. The head and neck (*scolex*) may exist as an immature form in various tissues and organs where they are encysted, and are often called *cysticercus*.

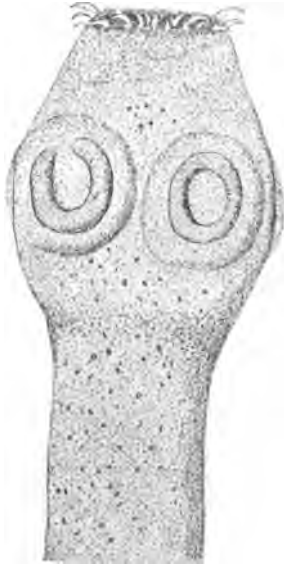

FIG. 80.—HEAD OF *TÆNIA SOLIUM*.
× about 40.

Tænia solium is of infrequent occurrence in man. It may be several metres in length, and may be coiled up or stretched out in the small intestines. Several worms may be in the gut at one time. The head, about the size of a pin's head (Fig. 80), has a projecting proboscis or rostellum, around which are arranged a double row of horny hooklets. Below these are four sucking discs at the sides of the head. The hooklets of the anterior row are larger than those in the posterior row, and are from 0.16 to 0.18 mm. long. The proglottides, when fully developed, are from 10 to 12 mm. long and from 5 to 6 mm. wide, but those nearest the head are much shorter and immature. The eggs of *T. solium* are ovoidal structures, about 0.03 mm. in diameter. The embryo of this worm is most commonly seen in the muscles of the pig as an

encysted scolex, commonly called a "measle." It occasionally occurs in man in the muscles, brain, eye, etc., and is called *Cysticercus cellulosæ*. It is usually about the size of a pea, but may be as large as a pigeon's egg and surrounded by a connective-tissue capsule.

Infection with the worm occurs in the human subject from the ingestion of insufficiently cooked "measly" pork, or, in the case of *Cysticercus cellulosæ*, from the ingestion of the eggs, which may, in a variety of ways in uncleanly persons, get into the food.

Tænia mediocanellata (*T. saginata* LEUCKART).—The head of this species is somewhat cuboidal, with neither rostellum nor hooklets, but with four sucking discs (Fig. 81). The segments are generally broader and shorter than in *T. solium*, and the worm is usually larger. In the embryonal form the scolex occurs as the *Cysticercus tæniæ mediocanellatæ* in the form of small cysts in the muscles of cattle, from the eating of which in the uncooked condition the infection occurs. This is the most common tapeworm in the United States.

Tenia echinococcus.—This worm in the mature condition forms a short, small colony inhabiting the intestine of the dog. The head is about 0.3 mm. in diameter and has a double row of hooklets around the rostellum. The proglottides are three or four in number, the last being the larger. The entire colony is not more than 4 to 5 mm. in length. The significance of this parasite in human pathology depends upon the cysts, called *hydatids*, which it forms, in the immature or cysticercus stage, in various parts of the body. Intimate association with dogs favors the acquirement of this parasite. When the eggs of the mature worm get into the intestinal canal of man they undergo partial development and find their way into the tissues and organs, most frequently into the liver. Here cysts are formed which become encapsulated by a connective-tissue membrane produced by the inflammatory reaction of the organ.

The cyst wall of the parasite is formed of two layers—an outer, finely lamellated layer called the *cuticula* (Fig. 82), and an inner, granular layer containing, muscle fibres and blood-vessels called the *parenchymatous layer*. Inside of the primary cyst, secondary cysts sometimes form, called *daughter cysts*; and within the latter, tertiary cysts, called *granddaughter cysts*, may develop. On the inner surface of the cysts, either primary, secondary, or tertiary, the scolices or heads of the immature worm are formed. These develop in the walls of the pediculated vesicles called *brood capsules*. The walls of these vesicles have a lamellated cuticula and a parenchymatous layer similar to those of the primary cysts. The scolices, of which there may be several in each brood capsule, are similar to the heads of the mature tapeworm. They are about 0.3 mm. in diameter,



FIG. 82.—CUTICULA OF ECHINOCOCCUS CYST. Showing lamellated structure.

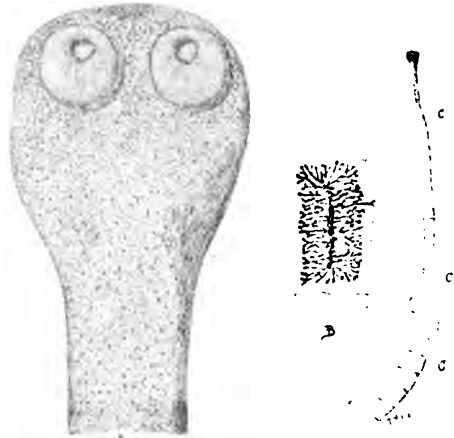


FIG. 81.—TENIA MEDIUMCANELLATA. HEAD AND PROGLOTTIDES.

A, head \times about 15. B, mature proglottid, showing generative apparatus. C, head and fragments of immature proglottides, showing gradual tapering of the neck. Natural size.

having a rostellum surrounded by a double row of hooklets and four sucking discs (Fig. 83). At the posterior end of the scolex is a pedicle by which it is originally attached to the wall of the brood capsule. Little, lamellated concretions of lime salts are often present

in the scolex. The anterior portion of the scolex, the rostellum, hooklets, and suckers, are often invaginated in the posterior portion. The scolices may be free inside of the brood capsules, or, owing to the rupture of the latter, they may be free in the cavity of the primary cysts. They may die and degenerate, forming a granular mass in which

the hooklets may be embedded, or the hooklets may be free in the brood capsules or in the primary cysts. Sterile cysts are often found, that is, those in which neither brood capsules nor scolices are developed.

The cysts contain, in addition to the scolices, a clear, gelatinous fluid. This fluid may become turbid by admixture with disintegrated scolices or fragments of the parenchymatous layer, or it may contain fatty detritus, cholesterin crystals, and particles of lime salts.

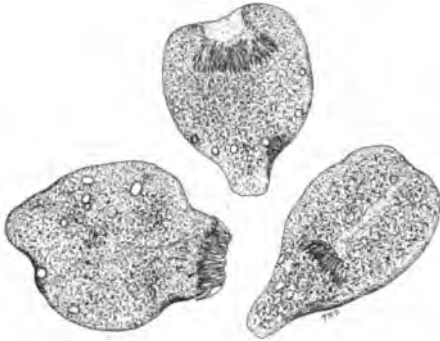


FIG. 83.—SCOLICES OF *TENIA ECHINOCOCCUS*. In one the rostellum is projected; in the others it is withdrawn.

The fluid may be partially absorbed, leaving a thick, grumous material within the cysts, which may become calcified or converted into a stony mass. When the scolices are not found entire the diagnosis may be made by the discovery of the separate hooklets (Fig. 84) or fragments of the characteristically lamellated cyst walls. The connective-tissue walls of the primary cysts may become fatty, or caseous, or calcified.

Sometimes the secondary vesicles project outward instead of inward, forming a series of cysts outside of the primary one. This variety of development is sometimes seen in man, but is more common in the domestic animals. It is called *Echinococcus scoleicipariens* or *exogena*.

Another variety of echinococcus, called *E. multilocularis*, is almost always found in the liver, and appears to be the result of incomplete and disturbed development of the embryos or cysts. It consists of a congeries of irregular, usually small cysts (Fig. 486, p. 739), surrounded by broad and narrow bands of connective tissue, and sometimes containing gelatinous fluid and scolices or hooklets; but the latter structures are commonly absent or difficult of detection. The whole is often surrounded by a dense connective-tissue capsule which may be calcified. The entire mass often presents an alveolar structure and was formerly regarded as a tumor—alveolar cancer. The diagnosis may be established by the discovery of the hooklets or scolices, or fragments of the lamellated cuticula. This form of the parasite is rare in America.




FIG. 84.—HOOKLETS FROM SCOLEX OF *TENIA ECHINOCOCCUS*.

There are four or five other species of *tænia*, occurring rarely in man.

Tænia nana.—This species occurs in the form of small colonies, about 15 mm. in length. The rostellum is surrounded by a single row of hooklets. It is frequently found in the intestinal contents of Italian children, of the inmates of asylums for the insane, and of a considerable proportion of the population of some of the Southern States. *Tænia flavopunctata*, a species about which little is known, is reported twice in America as occurring in the intestine of young children. *Tænia madagascariensis*, also little known and rare, has been seen in two children in Madagascar.

Tænia cucumerina.—This species occurs in colonies about 20 cm. long. The head is very small and spheroidal, and has four rows of hooklets. It is frequent in the small intestines of dogs and cats. It occurs occasionally in man. Its scolex inhabits the dog louse, and infection may occur in man by the transference of the lice or the embryos of the parasite to the mouth, as the result of the filthy habit of kissing dogs and cats or permitting the face to be licked by them.

Bothriocephalus latus.—This, the largest of the human tape worms, has very broad, quadrangular proglottides. The head is ovoidal and about 2 mm. long and 1 mm. broad. It has no proper sucking discs and no hooklets, but by long grooves on either side of the head the animal attaches itself to its host. The neck is long and filiform. It occurs most frequently in Europe, particularly in the northern provinces. The eggs undergo partial development in water, and are taken up by the pike and eel-pout, and perhaps by other fresh-water fish, from the ingestion of whose flesh in an imperfectly cooked condition the human infection occurs. Two other species of *Bothriocephalus* have been described as of rare occurrence in man: *B. cordatus* in Greenland and Iceland, and *B. cristatus*.

NEMATODA (Round Worms).

These worms are in general cylindrical, elongated, usually pointed at the ends, and sometimes filiform. The surface is sometimes smooth, sometimes irregularly beset with hairs and papillæ, or possesses longitudinal elevated striæ or transverse rings; but the body is not segmented.

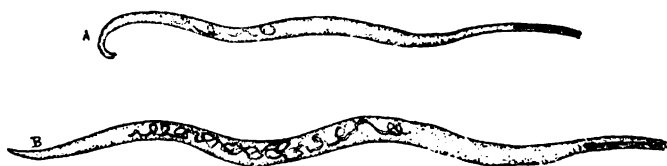

FIG. 85.—*ASCARIS LUMBRICOIDES*. About half natural size.
A, Male. B, Female. After Perls.

There is a mouth at the anterior portion, and a ventral anus near the posterior end. The intestine is straight. The sexes are in most forms distinct, the male being in general smaller than the female.

Ascaris lumbricoides.—This is one of the most common of the human intestinal parasites, and is of particularly frequent occurrence in children. It is of a light-brownish or reddish color. The female is from 30 to 40 cm. long and from 5 to 6 mm. thick. The male is somewhat more than half as large (Fig. 85). Both sexes are pointed at the ends, the posterior end of the male being curved into a spined hook. The eggs, from 0.05 to 0.06 mm. in diameter, are surrounded by an albuminous envelope (Fig. 86 A) and are quite resistant to destructive agencies.

The mode of development and life history of these parasites are not very well understood. Their usual seat in man is the small intestine, but they may wander into the stomach, and exceptionally get into the mouth, nose, bronchi, gall-passages, peritoneal cavity, etc. They may be single in the gut or present in great numbers.

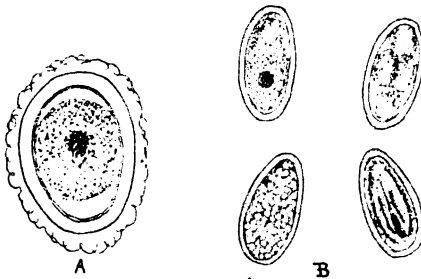


FIG. 86.—EGGS OF NEMATODE WORMS.

A, Eggs of *Ascaris lumbricoides*, \times about 300.
B, eggs of *Oxyuris vermicularis*, \times about 250.

Two other species of ascaris have been found in man. *A. maritima* was found in the vomit of a child in Greenland, in an immature condition. *A. mystax*, a tolerably common form in cats and dogs, has been found a few times in man. It is smaller than *A. lumbricoides*.

Oxyuris vermicularis (Threadworm or Pinworm).—This species is very small; the female has a pointed tail and is about 1 cm. long. The posterior end of the male, which is about 4 mm. long, is

blunt, and after death somewhat curled (Fig. 87). The eggs (Fig. 86 B) are produced in great numbers, are oval, and about 0.052 mm. long. This parasite is very common in children, and may be present in large numbers in the colon. This worm is known to infest only the human subject, and infection doubtless occurs by the ingestion of the eggs, which are widely distributed in a variety of ways on many objects, fruits, etc.

Strongylus gigas.—This is a slender red worm, the female being sometimes 1 metre long and over 1 cm. in diameter. It has been found several times in the pelvis of the kidney in man. It is more common in the wolf, fox, horse, seal, and some other animals.

Strongylus longevaginat.—The female is about 2.5 cm. long, the male, as usual, shorter. It is of a yellowish-white color, and has been found once in the lung of a boy in Germany.

Strongylus subtilis.—A very small species (female 5.6–7 mm. long) has been described by Looss as occurring in Egypt in the human intestine. But it is believed to be without pathological significance.

Uncinaria (Hookworm).—There are two forms of hookworm, that common in European and other countries, *Uncinaria duodenalis* (*Ankylostoma duodenale*), Stiles, and the hookworm of the New World, *Uncinaria americana*, Stiles. The latter worm is from 7–11 mm. long. The mouth is furnished with a chitinous capsule and chitinous claws and teeth. It is found especially in the small intestine. The head is burrowed into the mucous membrane of the host and the animal is nourished by the blood which it sucks. Ecchymoses may be produced at the point of attachment or even severe hæmorrhage. The worms are often present in large



FIG. 87.—*OXYURIS VERMICULARIS*.
A, Female. B, Male.

numbers. The eggs are deposited in the intestine of the host, escaping in the fœces. These may develop in a short time outside the body and then the parasite can gain access to the host either through the skin or by the mouth.

Hookworm disease, uncinariasis, is widespread, involving in this country the Southern States and adjacent islands where it is of serious importance on account of anæmia, gastro-enteritis, hæmorrhage, and general debility, etc., which often mark its presence. It is estimated that in some districts 90 per cent. of the inhabitants are affected.

By proper attention to sanitation in the disposal of excreta, the ravages of this parasite could be checked.

Trichocephalus dispar (Whipworm).—The males and females are of nearly equal size, 4 to 5 cm. long. A little less than one-half of the body (the posterior portion) is about 1 mm. thick, and in the male is rolled into a flattened spiral, but in the female is but slightly bent. The anterior part of the body is very slender (Fig. 88) and is embedded in the mucous membrane of the host. The eggs are elongated, oval-shaped, about 0.05 mm. long and about one-half as wide, with a thick brown capsule. This




FIG. 88.—TRICHOCEPHALUS DISPAR.
From the skin of the mons veneris.

parasite is very common in some countries, especially in France and southern Italy. It is commonly found in the cæcum, usually in small, but sometimes in very large, numbers. It is generally of little pathological significance, commonly producing no symptoms. Its developmental history is not well known.

Trichina spiralis.—The female of this common parasite is, in the mature condition, about 3 mm. long, the male from 1 to 1.5 mm. long; they are filiform in shape and white in color. The young are born in the form of tiny worms about 0.01 mm. in length and somewhat similar to the adult in shape. Infection occurs in man from the ingestion of insufficiently cooked pork. The muscle of the diseased pig contains the embryos of the parasite in an encysted condition. In the stomach the capsule of the worm is dissolved and the embryos are set free. They very rapidly mature, increasing in size, and the females give birth in the small intestine to very large numbers of young. It is estimated that a single female may give birth to from 1,300 to 1,500 young. These find their way through the mucous membrane and wall of the gut, into various parts of the body.¹

The exact course which they take in getting out of the gut is not fully established; probably they traverse the tissues in different ways. At any rate, they find their way to the voluntary striated muscle tissue, which they penetrate, and enter the muscle fibres. Here they cause a disintegration of the contractile substance, and coil themselves inside of the sarcolemma. In this situation they become encapsulated by material in part furnished by themselves, in part by means of the inflam-

¹ Herrick and Janevay have found the embryo in the blood, see Arch. Int. Med. iii., 263, 1909.

matory reaction which their presence induces in the connective tissue of the muscle. The worms are surrounded inside the capsule by granular material (Fig. 89). The capsule after a time becomes partially calcified, and in this condition may be readily seen by the naked eye as a tiny white speck. In this encysted state they may remain inactive but living for an indefinite, often for a very long time. Most frequently the cysts contain but one embryo, but they may contain from two to four. The embryo may die and its remains become calcified.

The same course of events follows when the muscle trichinæ are eaten by the pig or a variety of other animals.

The embryos in the muscle are killed by a temperature of 55° C. and by some of the methods of curing pork.

The embryos may mature and a new generation be born within from five to eight days after the ingestion of the diseased meat.

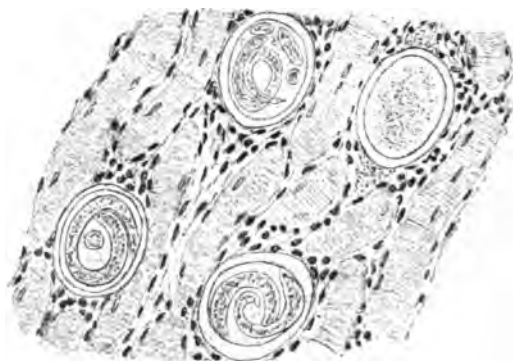


FIG. 89.—TRICHINA SPIRALIS.

The parasites are encysted in muscle. In one capsule the parasite has died, and the granular material replacing it is calcified.

As the result of the presence of these parasites in the body, if the invasion be severe, nutrition may be impaired and catarrhal enteritis, broncho-pneumonia, hyperplasia of the mesenteric lymph-nodes, and fatty degeneration of the liver may occur. Leucocytosis with a great increase in the number of eosinophile cells is common.¹ The encapsulated embryos may be found in enormous numbers in various voluntary muscles of the body, but they are most apt to be found, when not very abundant, in the muscles of the neck and larynx, in the intercostals and the diaphragm. They tend to collect toward the tendinous extremities of the muscles. Trichinæ also occur in the rat, cat, mouse, and other animals.

Filaria medinesis (Guinea worm).—This is a thread-like worm, the female being sometimes as much as 80 cm. long and from 0.5 to 1.7 mm. thick. The male, which is rarely found, is much smaller, measuring only about 4 cm. in length. It is common in the East, and inhabits the subcutaneous connective tissue, in which it often gives rise to abscesses and ulcers. Eosinophilia is commonly present. The embryos

¹ See Albert, Am. J. Med. Sci., Aug., 1910.

live for a time free in fresh water, and are taken up by a species of fresh-water crustacean, in whose body they undergo further development, and by the ingestion of which the infection of the human subject occurs.

Filaria sanguinis hominis.—The embryo of this parasite, which inhabits the blood and lymph of man, especially in Brazil, Egypt, and some parts of the Orient, and occasionally occurs in this country, is about 0.35 mm. long, rounded anteriorly, and pointed at the tail (Fig. 90). It has about the diameter of a red blood cell. It occurs, sometimes in great numbers, in the blood during the night time, being as a rule absent during the day. It may occur in the urine in connection with chyluria and hæmaturia. The mature female is from 8 to 10 cm. long, and has been found inhabiting the lymph-vessels of man, particularly in the scrotum and lower extremities.

Owing to the obstructions which it causes in the lymph circulation, and to the local irritation which its presence induces, it sometimes gives rise to lymphangiectasis,¹ œdema, abscesses, and perhaps elephantiasis. Eosinophilia is common. One of the




FIG. 90.—*FILARIA SANGUINIS HOMINIS*
—EMBRYONIC FORM FROM THE BLOOD.

embryonic stages of development is believed to take place in the body of a species of nocturnal mosquito. Through the bodies of the dead mosquitoes, which are liable to fall into the drinking-water, it is believed that the spread of the parasite may occur.

There are several other species of filaria occasionally found in man which it is not necessary to enumerate here.²

Rhabdonema strongyloides.—A small, filiform worm from 1 to 2 mm. in length is found, often in enormous numbers, in the intestines, biliary and pancreatic ducts of man in Cochin China and in Italy, giving rise to endemic diarrhœa. It has been thought that there are at least two species, which have been described under the generic name *Agullula* but recent researches by Leuckart have led him to believe them to be different developmental stages of the same form, for which he suggests the above name.

Methods of Study of Worms.

Filaria sanguinis may be preserved by preparing a smear of the blood containing it on a slide in the usual way (see p. 316), and staining with methylene blue.

The larger parasites may be hardened in formalin and studied whole after dehydration in alcohol and clearing in oil of cedar or organum. Or sections may be made after embedding, and stained and mounted in the usual way.

The examination of muscle for trichina is often of great practical importance. For this purpose small pieces of fresh muscle are squeezed into a thin sheet between two slides, and examined with a low power. A considerable number of bits of muscle should be examined, particularly from the above-mentioned favorite situations, before excluding them in a suspected case, because they are sometimes present in small numbers. A thorough search is of special importance in the examination of pork,

¹ For a study of filarial lymphatic varix see *Opie*, *Trans. Assn. Am. Phys.*, vol. xvi., p. 314.

² For bibliography consult *Lothrop and Pratt*, *Am. Jour. Med. Sciences*, vol. cxx., p. 525, 1900.

since, owing to the enormous fertility of the parasites, even a moderate number may give rise to a severe infection.

For the minute examination of the parasite, bits of muscle should be hardened in Orth's fluid and alcohol, decalcified if necessary, and, after embedding in celloidin, thin sections cut and stained double with hæmatoxylin and eosin, and mounted in balsam. Bits of muscle may be also teased, the embryos picked out with a needle, and the cysts either broken open under a lens with the needle, or squeezed under the cover-glass. The embryo worm thus set free may be mounted in a mixture of equal parts of glycerin and saturated aqueous picric acid. The adult forms, which may be obtained by feeding rabbits with uncooked trichinous muscle, and examining after the proper interval, may be hardened in Orth's fluid, and mounted in a mixture of equal parts of picric acid and glycerin, or in the same mixture which has been lightly tinged with eosin.

Arthropoda.

The scope of this work does not permit us to enter in detail into the subject of external parasites, which will be found described in treatises on diseases of the skin or in the general works on parasites referred to below. But, owing to their frequent occurrence and practical importance, we may briefly describe two of the more common forms of arthropods, the "itch insect" and the "louse."

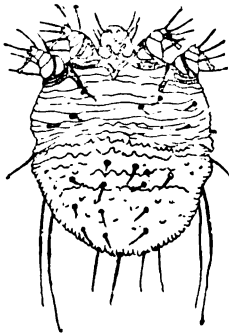


FIG. 91.—*SARCOPTES HOMINIS*—THE "ITCH INSECT." Female; back view. After Furstenberg.

The common "itch insect"—*Sarcoptes hominis* (*Acarus scabiei*)—is shaped somewhat like a turtle, with a chitinous covering, and presents the general appearance seen in Fig. 91. The female is about 0.45 mm. long, the male a little smaller.

The parasite bores little tunnels in the skin, in which the eggs are laid and the young hatched. After a few days these bore fresh channels in the

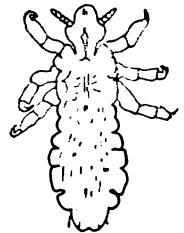


FIG. 92.—*PEDICULUS CAPITIS*—THE "HEAD LOUSE." Male. After Braun.

skin. For their detection a bit of the superficial layer of the skin is snipped out with curved scissors, dehydrated and cleared up with oil of cloves, and examined under a low power, when the tunnels and the parasites, if present, will be readily visible.

The head louse, *Pediculus capitis*, is from 1 to 2 mm. long, the female being slightly the larger. The general appearance of the insect is seen in Fig. 92.¹

Methods of Study of Insects.

These, if small, may be cleared in turpentine and mounted in balsam, or sections may be cut after embedding in paraffin.

¹ *Bibliography.*—Especially to be recommended for detailed description of human and animal parasites is the small work of Brumpt, "Precis de Parasitologie," Paris, 1910.

Consult also, especially for the forms of eggs and other parts of animal parasites which may be found in the excreta, von Jaksch, Wood, or Simon, or other works on clinical microscopy.

The Reports of the Bureau of Animal Industry of the U. S. Department of Agriculture contain many valuable data relating to animal parasites and the diseases of animals in the United States.

See for a general study of the effects of parasites on their host, Ward, Science, vol. xxv., 201, 1907.

CHAPTER VII

PLANT PARASITES.

THE plant parasites of man belong among the simplest of living organisms. Three distinct groups are of frequent occurrence in or upon the body. These are:

1. *Bacteria*, or fission fungi (Schizomycetes).
2. *Yeasts*, or yeast fungi, or sprouting fungi (Blastomycetes).
3. *Moulds*, or mould fungi (Hyphomycetes).

The first group, the bacteria, is of the greatest significance, because it contains organisms which are very frequently the excitants of serious disease.

The scope of this work does not permit more than a brief outline of the rapidly increasing knowledge of the forms, nature, and performances of the bacteria. For details we refer to special treatises on bacteriology.¹

I. Bacteria.

MORPHOLOGY, PHYSIOLOGY, AND DISTRIBUTION.

Bacteria are minute unicellular plants devoid of chlorophyll, multiplying by transverse division and in some cases preserving the species by the formation of spores.

The colorless, sometimes granular protoplasm is enclosed by a membrane, and some forms are surrounded by a transparent capsule. Not




FIG. 93.—BACTERIA WITH FLAGELLA.




FIG. 94.—TYPICAL FORMS OF BACTERIA.
COCCI, BACILLI, AND SPIRILLA.

infrequently parts of the protoplasm appear less dense than the rest, as if from vacuolation, and a few observers have claimed to demonstrate in certain forms a nuclear substance.

Many of the bacteria, especially bacilli and spirilla, less frequently the cocci, have hair-like processes called *flagella* which are apparently organs of locomotion (Fig. 93). These may be single or in tufts; may be

¹ *Hiss and Zinsser*, "Text-book of Bacteriology," 1910; *Park and Williams*, "Pathogenic Bacteria and Protozoa," 1910.

at one or both ends or over the general surface. Their number and distribution seem sometimes to be characteristic of special forms. (See *Motility* below.)

Forms of Bacteria.—The various forms of bacteria may be grouped into three classes (Fig. 94).

1. *Spheroidal bacteria.*—Cocci or micrococci (singular, coccus,¹ micrococcus).

2. *Rod-like bacteria.*—Bacilli (singular, bacillus).

3. *Spiral bacteria.*—Spirilla (singular, spirillum).

All straight bacteria which have one axis longer than the other are called bacilli, even though the form is oval rather than rod-like. The ends of bacilli may be square or rounded, and in stained preparations, in some cases, concave.

While the cocci elongate a little in preparation for fission and in this condition present a slight irregularity in the length of their axes, and thus resemble bacilli, the complete observation of their life cycle rarely permits error in the determination of the primary group to which a given micro-organism belongs.

Variations in Form and Size.—Some bacteria present slight modifications of the fundamental form in certain phases of their growth and under various chemical and physical conditions. Thus some of the cocci after division are slightly flattened on their contiguous sides—biscuit-shaped; certain bacilli may bulge slightly in the middle—*clostridium* forms; others may be larger at one end than at the other—racket-shaped; bacilli from the same culture may present considerable irregularities in breadth and especially in length. The morphology may differ somewhat under different growth conditions. But these slight variations in form rarely give rise to serious difficulty in classification.



FIG. 95.—BACTERIA WITH CAPSULES. (Pneumococcus.)

Finally, when bacteria are placed under conditions unfavorable for the maintenance of their life processes, and when they are dead, they are often irregularly swollen and contorted or may undergo partial disintegration, giving rise to what are known as “*involution forms.*”

While all bacteria are minute² there is among them considerable diversity in size, some being many times larger than others.³

Certain bacteria, those of the diphtheria group for example, contain deeply staining bodies called *metachromatic granules* the nature of which is as yet undetermined.

Reproduction of Bacteria.—When the bacteria are about to multiply by fission they elongate, a dividing septum forms, they become con-

¹Pronounced *kok'-us*, plural *kok'-si*. The term *micro-organism* includes all of these forms of minute and lowly plants. They are sometimes spoken of collectively as *germs* or *microbes*.

²Some forms, those for example inducing the pleuro-pneumonia of cattle, are beyond the present resolving power of the microscope—ultramicroscopic.

³For convenience of expression microscopists have agreed to let the letter μ stand for the word *micromillimetre*, which is one-thousandth part of a millimetre. This unit of measure, equal to about one-twenty-five thousandth of an inch, is often called a *micron*.

stricted at a right angle to the axis elongation, and finally two independent organisms are produced. The multiplication of bacteria by fission may, when the conditions are favorable, occur so rapidly¹ as to give rise within a few hours to an enormous number of new individuals.

AGGREGATIONS OF BACTERIA.—

In many cases, the new individuals thus developed fall apart in a form identical with that of the parent cell. In some species, on the other hand, the new-formed individuals are prone to cling together with greater or less tenacity, thus giving rise to growth aggregates which are more or less characteristic (Fig. 96). Thus among the cocci there are those in which a large part of the new individuals cling together in pairs. These forms are called *diplococci*. In others the pairs cling together in longer aggregates or chains. Such are called *streptococci*.

A similar occurrence in the bacilli gives rise to *diplobacilli* and *streptobacilli*. Some of the spiral forms are due to the close junction end to end of oppositely curved segments.

Certain cocci divide in two directions at right angles to each other, giving rise to four cocci clinging together and lying in the same plane. These are called tetrads or *merismopodia*.

Finally cocci may divide along three planes at right angles to each other, giving rise to cuboidal packets of eight germs or some multiple of this—such growth groups are called *sarcina*² (Fig. 97).

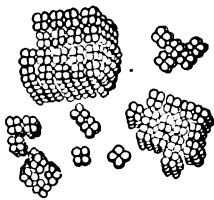


FIG. 97.—SARCINA.
Showing growth aggregates
in cuboidal masses.



FIG. 96.—GROWTH AGGREGATES OF BACTERIA.
1, Diplococcus; 2, streptococcus; 3, merismopodia; 4, diplobacillus; 5, streptobacilli; 6, curved bacteria forming chains.

Higher Bacteria.—There is a family of filamentous or branching organisms which are often spoken of as *polymorphous* or *higher bacteria*, some of which may indeed be links between the bacteria and higher plant forms. Filamentous bacteria are more or less distinctly segmented, and the segments may be enclosed in a common sheath. The modes of reproduction and a certain specialization of function of different parts of the filaments which is frequently present indicate affiliations with higher forms. By this specialization of function is meant the attachment of the threads at one end to the substance on which they grow, and the formation at the free ends of structures which appear to be concerned in the reproduction. Several groups of these organisms have been named, but

¹ A. Fischer has estimated that the cholera spirillum may undergo complete fission at intervals of about twenty minutes so that a single organism might give rise under favorable conditions, could these be secured, to 1600 trillions in twenty-four hours.

² Bacteria in masses embedded in and held together by a more or less abundant homogeneous material which they elaborate are called *zooglaea*.

few of them have as yet been adequately studied. The groups *streptothrix*, *cladothrix*, *crenothrix*, *leptothrix* may be named. Among these the streptothrix (nocardia) is of the most significance here, since pathogenic forms are known.¹ The *Streptothrix actinomyces*, and closely related species, and the lesions which they induce, will be described later. There are many reasons for the belief that the forms called streptothrix and actinomyces are more closely related to the moulds than to the bacteria, but the scope of this work does not permit the discussion of the subject, particularly difficult as it is on account of the confusion of terms and the lack of sufficient knowledge of the life history of the organisms involved (see Actinomyces, p. 231).

Variations in Forms.—Their apparently simple structure and the lowly position which bacteria occupy in the scale of living things have given rise to the conjecture that marked changes in form within the limits of the primary groups, or even changes from one primary group to another, may be brought about by alterations in environment, food, etc. In the early days of the exact study of bacteria this belief in *pleomorphism* in bacteria found ready currency. But the more exact study of separate forms, which the new technique has made possible, has led to the general acceptance of the view that variations do not occur except within comparatively narrow limits, and that what we are accustomed to call species of bacteria maintain their morphological characteristics with tenacity under the most varied changes in environment, even though these persist through the countless generations which may pass within the limits of a single experiment. The physiological characters of bacteria are, as we shall presently see, subject to wide and significant variation, but, so far as we can now see, *monomorphism* widely, if not exclusively, prevails.



FIG. 98.—BACILLI SHOWING SPORES.

The bodies of the bacilli are stained with methylene blue, the spores with fuchsin.

Spores.—Under a variety of conditions, the limitations of which are not very well understood, new bacteria are produced, and the species is perpetuated, not by simple division, but by the development of *spores*. The most common mode of spore formation is called *endogenous*. A small, shining mass makes its appearance within the protoplasm from which it is formed, grows more and more distinct, and finally appears as a sharply defined

spheroidal or oval, strongly refractile colorless body surrounded by a limiting membrane (Fig. 98), which can be separately stained and may remain within a cell membrane or may free itself by degeneration of the latter. Endogenous spore formation is common in bacilli, rare in spirilla and in cocci. The spores appear to be surrounded by a dense envelope, and are, as a rule, much more resistant to deleterious agencies, such as heat, drying, chemicals, etc., than are the vegetative forms of the bacteria themselves.

Spores, when placed under favorable conditions in the presence of

¹ Some organisms commonly called bacilli—tubercle bacillus for example—may belong in this group.

moisture and nutriment, swell, become less refractile, and develop into the usual vegetative form. The actual observation of this transformation is, in doubtful cases, the only absolute guarantee of the spore nature of these bodies, though staining methods are useful. Another method of sporulation—*arthrogenous*—has been described, but its nature is not well understood.

Motility.—Some bacteria are capable of performing rapid movements, others are not; and the same form may be at one time motile and at another immotile, depending upon external conditions. Movement is largely confined to the rod-like and spiral forms, but has been observed in the spheroidal.

It has been shown that certain of the motile bacteria, when suspended in fluids, are attracted toward, or repelled from, dissolved chemical substances. This is called chemotaxis (see p. 85), and it is termed positive or negative according as the organisms are attracted or repelled.

Conditions of Life, Growth, and Multiplication.—The bacteria require for their nutrition carbon, hydrogen, oxygen, and nitrogen, and certain mineral salts. These they can obtain from proteids and carbohydrates. Free oxygen is necessary for the growth and activities of some forms of bacteria and not for others.

Nitrogen may be obtained by some bacteria from inorganic salts of ammonia, from nitrites and nitrates. Bacteria grow best as a rule in an organic food medium, especially soluble albuminous material which is neutral or slightly alkaline. Most of these materials are rendered available as food by the action of enzymes—inverting, sugar-splitting, proteolytic, etc., often given off by the organisms and acting upon the albuminous materials.

Those bacteria which require free oxygen are called *aërobic*. Those which do not grow in its presence are called *anaërobic*. But between these extremes there are forms which make shift to grow without oxygen under favorable conditions, though they make use of it when present; others grow in its presence, though flourishing best in its absence: these are called *facultative aërobes* or *facultative anaërobes*, in distinction from those first mentioned, which we call *obligate aërobes* or *anaërobes*.

Bacteria are active only in the presence of moisture. When this and other conditions favoring their activity fail they do not necessarily die, but some forms may remain, either as spores or as fully developed organisms, for long periods dry and inert, but capable of resuming their activity whenever they are again restored to favorable conditions.

Effects of Temperature, Light, etc.—Some bacteria are and some are not very sensitive to changes of temperature. At a temperature below +5° C. they are incapable of marked activity or proliferation. At +7° C. a slow growth has been observed in various species. Many forms may remain alive for long periods frozen in ice, while some are not killed by a temperature of -250° C. As the temperature is raised their activities increase up to a certain point. It may be said in general that they are most active at about the temperature of the body, although species differ considerably in this respect. In fluids many bacteria are killed by a

prolonged exposure to a temperature of from 50° to 70° C. or even less. On the other hand, certain species grow at a temperature of from 60° to 75° C. Such are called *thermophilic* bacteria. When dry they resist much higher temperatures than when moist. All known bacteria, save a few very invulnerable spore-forming species, are killed by a short exposure in the presence of moisture to a temperature of 100° C. The spores are, as a rule, more resistant to high temperatures than the bacteria themselves, some having been exposed, dry, to a temperature of 140° C. without destruction of life. Fluids containing the spores of bacteria which resist very high temperatures may be sterilized by boiling for a short time, then being allowed to stand at ordinary temperatures for several hours, and then again boiling; this process being repeated several times. In this way, although the spores themselves are not killed by the heat, the bacteria into which, if the conditions be favorable, they develop during the intervals are killed, so that finally the medium is entirely freed from both living spores and adult bacteria. Strong light is in general inimical to the life and growth of bacteria, and by direct sunlight many forms are readily killed. Various forms of electricity, rapid and continued vibration, the action of radium, etc., may kill bacteria.

Germicides.—Certain chemical agents, when brought into contact with bacteria, greatly reduce their activities or destroy their life altogether; but different species differ greatly in their capacity of resistance to these agents. The spores of certain bacteria are exceedingly resistant, much more so than the bacteria themselves, to the action of disinfecting agents. Among the chemical substances commonly used as disinfectants may be mentioned formalin, carbolic acid, and especially solutions of corrosive sublimate, which is very inimical to the life of most bacteria and their spores, even in extremely dilute solutions.

Metabolism of Bacteria.—The metabolism of bacteria may be destructive or constructive. Their destructive or catabolic activities find expression in the fermentation of carbohydrates and in the cleavage of proteids and fats. Their constructive or anabolic activities are exemplified by their building up of nitrogenous compounds in the soil. We cannot here enter into the details of these processes, which must be sought in special treatises.

But it may be said in brief that a large number of complex chemical substances are elaborated during the growth of bacteria, their nature varying with the species of bacteria and the composition of their nutrient material. Some of the chemical compounds set free by the growing bacteria are bad-smelling or aromatic; some are inert and harmless substances; some are powerful poisons, and may, when they have accumulated in the fluids where they grow, inhibit activity and growth or even destroy the bacteria which have produced them.

Fermentations and putrefactions are due to the activities of micro-organisms, some to bacteria, some to yeasts, some to moulds. Putrefaction is a form of fermentation in which nitrogenous compounds are decomposed by micro-organisms setting free, especially in the absence of oxygen, bad-smelling substances.

Bacteria which induce fermentation are called *zymogenic*—and each species induces fermentation of a particular character in the presence of a special substance, as glucose, or members of a certain class of substances such as carbohydrates. Some of these fermentations are important in the arts; some are concerned in the changes which food products undergo under natural or artificial conditions, such as the development of koumyss from milk and the common butyric, lactic, alcoholic, and other fermentations.

The chemical changes which are induced by micro-organisms in the process of fermentation are extremely complex and little understood.

Bacteria may develop, in their metabolic activities, soluble ferments or *enzymes* of various kinds resembling diastase, pepsin, trypsin, rennet, etc. These may remain in the bacterial cell or may be diffused into the surrounding media. It is through these enzymes that the fermentations and proteid cleavages so characteristic of many phases of bacterial metabolism are carried on.

Many bacteria form pigments as they grow (*chromogenic* bacteria). This pigment may be developed in or upon the germs themselves or may be diffused through the surrounding media and may be developed only in the presence of light, oxygen, etc. Gas-producing bacteria are called *aërogenic*. Certain species when growing in masses emit a phosphorescent light—*photogenic* bacteria.

Bacterial Poisons.

Ptomains.—Certain basic chemical compounds resembling the vegetable alkaloids and which are formed by the action of bacteria upon various kinds of organic matter are called *ptomains*.¹ Some of the ptomains resulting from the breaking up of the protein molecule by bacteria in decomposing meat, fish, etc., are poisonous, though not apparently of as much importance as was believed in the earlier days of bacteriology. But ptomains should be clearly distinguished from the true toxins now to be considered.

Toxins.—True bacterial *toxins* are poisonous substances produced by bacteria whose exact chemical structure is as yet unknown. They seem to be analogous in nature to enzymes and may be given off in artificial culture, as in the infective processes, during the metabolic activities of bacteria, like secretory or excretory products. The poisonous substances elaborated in the growth of the diphtheria and the tetanus bacilli are typical toxins. These toxins are especially characterized by their capacity to stimulate the body-cells, when the latter are called upon to adapt themselves to their presence, to the formation of antibodies (see page 165).

Endotoxins.—On the other hand certain bacteria which develop toxic substances do not set these free as they are formed but store them in or build them into the structure of their bodies whence they are freed only after the death or disintegration of the bacterial cell through autoly-

¹ *Leucomains* are basic products produced in the tissues of living animals by cell metabolism.

sis or some external agency. Such toxic substances stored in the texture of the bacteria are called endotoxins and they do not appear directly to stimulate the organism to the formation of antibodies.

It may be doubted whether the fuller knowledge of the future will justify so sharp a distinction between bacterial toxins and endotoxins as is at the moment usually made.

But the distinction is useful at present and of greatest significance in forming our conceptions of the nature and phases of immunity.

The important thing to remember in this connection is that it is through the action of these toxins, whether soluble and eliminated during the life and functional activities of the bacteria or stored up in their bodies to be set free only upon their disruption, that the most striking damage is wrought in the organisms when body-cell and bacterial cell strive to adapt themselves to one another in the processes of infection which we are presently to study.

It is probable that there is still another group of toxic substances derived not directly from the bacteria but from the action of certain products of bacterial metabolism upon body proteids, so that it may be through these secondary toxic albumoses that some of the serious manifestations of infection and intoxication are induced.

The Rôle of Bacteria in Nature.—The bacteria play a very important rôle in nature in virtue of their power of feeding upon and decomposing dead organic material. A part of the new chemical compounds which are thus formed may be used by the bacteria for the purposes of their own nutrition and growth, while the rest are set free to serve, sooner or later, as food for other forms of plants or animals. In the decompositions which are brought about in nature by the bacteria those compounds of nitrogen and carbon dioxide are set free which are essential for the nutrition of the higher plants.

Without the activities of bacteria, life could not be long maintained upon the earth, since the necessary carbon, hydrogen, oxygen, and nitrogen would soon be permanently locked up in unavailable form in organized material. Through the action of the various nitrifying bacteria in the soil, ammonia is decomposed with the formation of water and nitrous acid; nitrous is converted into nitric acid. The so-called denitrifying bacteria reduce nitrates to ammonia and to nitrites. In these ways, among others, water percolating through the soil may be freed from objectionable organic compounds. There are certain soil bacteria which aid special groups of plants to fix nitrogen from the surrounding media and make it available for the uses of the plant.

Distribution of Bacteria.—Bacteria are widely distributed in the air, in water, and in the superficial layers of the soil, where they may be present in enormous numbers. They are especially abundant among the habitations of man, or wherever under favorable conditions of moisture and temperature animal or vegetable substances are undergoing decay. They cling tenaciously to moist surfaces, but when dried, and especially when dried upon comminuted material, they may float in the air as dust. In quiet air they gradually settle with other forms of dust on to horizon-

tal surfaces, and thus in closed, still rooms the bacteria-laden air may in a few hours almost wholly free itself of its living contaminations by a process analogous to sedimentation in water.

This wide-spread transportation of bacteria as dust by moving air, and the spontaneous cleansing of the latter by the settlement of the germs, are important factors in the sanitary problems which the complex conditions of modern life present.

While bacteria may live for long periods in the dried state in dust they do not in this condition multiply. But the upper three or four feet of the soil forms the great abiding, and when moist, the breeding place of the myriads of germs which are concerned in the salutary work of food preparation for higher plants. Large numbers of mould spores are frequently mingled with the bacteria in dust and soil.

Surface waters almost always contain bacteria, which may have entered by aerial dust or from the wash of adjacent soil or from direct human or animal contamination. Many bacteria find in water favorable conditions of life and flourish on what to other forms would be but scanty nutriment. Many pathogenic bacteria may remain alive for considerable periods in water, but they do not usually thrive there.

The water which in many places lies in hollows of the rocks, bathing the deeper layers of the soil or gathered in caverns and recesses beneath, is called *ground water*. This under favorable conditions is almost wholly free from micro-organisms; these, through the complex processes of filtration, germ metabolism, etc., which go on in the upper soil layers, having, together with inorganic contaminations, been largely retained or transformed as the surface water has slowly sought the lower levels.

The Relationship of Bacteria to Other Living Beings.—So far as we know, with few exceptions, the bacteria whose natural habitat is the soil or air or water are not, under usual conditions, harmful to man. On the other hand, it is germs from the bodies of men or animals who are the victims of infectious disease, gaining access in one way or another to these great reservoirs and sources of distribution, which occasionally render the bacterial flora of soil and air and water of direct personal significance to man.

It will be seen from what has been said about bacteria and their various modes of life that some live in or upon and at the expense of other living beings—the hosts—these are *parasites*. Others which live and grow apart from a living host are called *saprophytes*. In either class there are forms which, through the capacity of adapting themselves to their environment, can maintain at one time a parasitic, at another a saprophytic life. Such germs are called, respectively, *facultative* parasites or *facultative* saprophytes. Those, on the other hand, whose life is strictly limited to the parasitic or saprophytic condition are called *obligatory* parasites or saprophytes.

Not all the bacteria which live in or upon the bodies of men and animals are in the stricter sense parasites. The terms *messmates* and *commensals* have been applied to such organisms as simply live with, but do not necessarily derive nutriment from, the host.

In some cases parasitic life on the part of the micro-organism may contribute to the welfare of the host. This is the case in some bacteria which live upon the roots of certain leguminous plants, and to whose nutrition they contribute by rendering atmospheric nitrogen directly available for the host. This condition of life is called *symbiosis*.

Species and Varieties.—As has already been indicated, the morphological characters of bacteria are so little subject to permanent variation under the widest diversity in the conditions to which they are subject that we are justified in the belief in fixed species. But so susceptible to external conditions are the functional activities of many species that not only is the occurrence of what may be called varieties within specific limits frequent under natural conditions, but more or less permanent variations may be experimentally produced.

Modifications of Functional Characters.—Almost all of the functional activities of bacteria upon which we rely as descriptive characters may be experimentally altered; thus the color-producing capacity may be diminished, the peptonizing and fermentative activities lowered, the pathogenic powers reduced or exalted, and even the capacity for spore formation may be abolished.

These more or less permanent modifications of function in bacteria may be induced by artificial cultivation under adverse conditions of temperature and nutrition, by the presence of deleterious chemical agents, antiseptics, etc., or by association with the body-cells and juices in susceptible or insusceptible animals.

CLASSIFICATION OF BACTERIA.

The beginning of the systematic study of bacteria by exact and reliable methods is of such recent date, they are so minute, and our present optical apparatus reveals so few differential morphological characters, and so few, withal, of the many existing forms have as yet been studied that a satisfactory classification or nomenclature of the bacteria is not yet possible.

Outside of the limit of the primary classes above described and based upon the form, position of flagella, and motility, we are obliged to use for the purposes of identification and description the results of physiological activities which the special forms of bacteria display when placed under diverse and usually entirely artificial conditions of food, temperature, and general environment. It is evident from this condition of affairs that what in our attempts at classifications we are wont to call genera and species, are not such in the strict sense in which these terms are used in other domains of biology. That which corresponds to the generic name in the more exact vocabularies is in ours usually the growth form which indicates the primary class to which the germ belongs, as coccus, bacillus, or spirillum, or some growth modification of this, as diplococcus, streptococcus, streptobacillus, and the like. To this is usually appended a more or less distinctive specific name, which ordinarily indicates some noteworthy physiological capacity of the germ, such as its peptonizing

power, the pigment which it elaborates, some prominent chemical reaction which it initiates, some marked effect upon an artificial culture medium, its disease-producing power in men or animals, or some fact about its habitat, or the situation in which it was found. All of these and other heterogeneous characteristics, largely functional, which may be developed under natural or artificial conditions, constitute data in the life history of germs upon which the classification and nomenclature of bacteria are at present based.

Notwithstanding the value of this principle of grouping and nomenclature, its inadequacy even for temporary use is becoming painfully evident as research proceeds, partly because of the large variations to which physiological activities are liable, and partly because we cannot always sharply distinguish between races, varieties, and species.

Methods of Morphological Study of Bacteria.

The simplest mode of studying bacteria is to examine them either in the fluids in which they grow or in one-half-per-cent. salt solution. For the study of many of the phenomena of life this method is important.

This may be accomplished by the examination of a thin layer of the fluid under a cover-slip, in the usual way; or a small drop may be placed on the cover-slip and this inverted on a hollow slide so that the observation is made in the hanging drop. A streak of vaselin painted around the edge of the cover will prevent evaporation of the fluid.

STAINING.—By far the most important aid in the morphological study of the bacteria is derived from the use of staining agents. Most of the bacteria are stained more or less readily by one or more of the basic anilin dyes. The ease with which they are colored varies considerably in different species and with the different dyes. The tissue elements, and a variety of other materials with which the bacteria may be associated, also stain more or less readily at the same time; but most of these part with their color more readily than do the bacteria on being treated with alcohol or dilute acids. It is thus possible to obtain a differentiation in color between bacteria and other structures. The bacteria, moreover, differ among themselves in respect to the tenacity with which they hold their stain in the presence of decolorizing agents, and upon this fact is based one of the important methods of distinguishing between different species.

The anilin dyes more commonly employed for bacteria staining are fuchsin, gentian violet, and methylene blue. A saturated alcoholic solution of these dyes should be kept in tightly stoppered bottles, and from these the more dilute solutions required for staining may be prepared. For ordinary purposes one part of alcoholic solution of fuchsin or methylene blue, added to twenty parts of water, will give a staining solution of suitable strength.

Special stains and modes of staining, such as are necessary for some forms of bacteria—the tubercle bacillus, for example—will be described under the appropriate headings.

To Stain Bacteria in Fluids.—A small drop of the fluid is placed on a clean cover-glass, spread a little with a needle, and dried by gentle heat. The cover-glass is now held with the forceps, specimen side up, and passed moderately rapidly three times through the flame of an alcohol lamp or Bunsen burner. The material on the cover should not be burned. This heating not only fixes the contents of the fluid firmly on to the glass so that it will not easily soak off, but renders insoluble any albuminous materials which may be mixed with the bacteria, and which might otherwise interfere with subsequent examinations by forming granular precipitates.

A drop of the aqueous staining fluid is now put on to the dried specimen on the cover-glass, and if this be held in the forceps and tilted slightly up and down a few times so as to bring fresh portions of the staining fluid into contact with the bacteria,

the staining will usually be completed in two or three minutes. The stain is now washed off with a jet of water from the wash bottle, and the specimen is either mounted in a drop of water for temporary study, or the washing water is drained off and, after drying in the air, it is mounted directly in balsam. It is well to use balsam which has been softened, when this is necessary, with oil of cedar or xylol rather than with chloroform, since this is apt to decolorize the bacteria. Solid cultures of bacteria should be mixed with a little water and spread on the cover-glass before drying and staining.

Gram's method (see below) is often useful and in some cases almost indispensable for the differential staining of bacteria.¹

To Stain Bacteria in Tissues.—The tissues should be well hardened in alcohol. Thin sections are placed in the above-described aqueous coloring solutions, where they may remain from five to fifteen minutes. In some cases a much longer staining is necessary. Gentle warming (40° to 50° C.) will hasten the staining. The entire tissue as well as the bacteria is in this way deeply colored. The sections are rinsed with distilled water and then placed in alcohol. This, with varying degrees of rapidity with different stains and tissues, gradually extracts the color from the tissue, most slowly from the nuclei. The time required and the exact degree of decolorization to be sought for must be learned by experience in different cases. Sometimes five, sometimes thirty minutes are required, sometimes only a few seconds. It is often necessary, and the decolorizing of the tissue is thereby hastened, to add a few drops of acetic acid to the alcohol. When acetic acid is used it should be finally thoroughly washed out by alcohol. The specimens are now cleared up by oil of origanum and mounted in balsam. In specimens prepared in the above way, the nuclei of cells usually retain to some extent a color similar to that of the bacteria, but their size and shape serve for the differentiation.

Gram's Method.—This is a much more generally useful method of staining bacteria in the tissues than that just given, although not in all cases applicable. The sections are stained for from two to four minutes in *anilin-gentian-violet solution*, prepared by adding 1 c.c. anilin oil to 10 c.c. distilled water, shaking thoroughly, and filtering off the excess of anilin oil through a moistened paper filter. To the clear filtrate, saturated alcoholic solution of gentian violet is added, in the proportion of about 1 of the dye to 10 of the anilin solution.

From the staining solution the sections are transferred to a solution of iodine in potassium iodide and water (I 1.0—KI 2.0—H₂O 300.0), remaining from one to three minutes, when they are transferred to strong alcohol; this should be changed two or three times so as to dehydrate the specimen, which at the same time will lose much of its color. The section is cleared in oil of origanum to which a little eosin has been added, and mounted in balsam. In specimens prepared in this way the bacteria and some of the nuclei are violet, the remainder of the tissue is red.

In this as in other methods of staining bacteria in tissue the section is liable to shrivel and curl. This may in many cases be avoided by fixing the sections on to the cover-slip with albumen fixative (see p. 1034) before the staining begins, carrying cover-glass as well as section through the subsequent processes. Since some bacteria are decolorized by Gram's method it is not applicable to the staining of all organisms in tissues. It is often a valuable aid in the differentiation and identification of species with similar morphology—and in some instances, as in the staining of gonorrhœal pus, has an especial diagnostic value (see p. 222).

Weigert's Modification of Gram's Method.—The sections are laid for half an hour in the *anilin-gentian-violet solution* prepared as above, then rinsed off in three-quarter-per-cent. salt solution and spread on a slide. They are now dried with blotting-paper and covered for two minutes with the iodine solution. The iodine solution is now washed off in the water, the section dried with blotting-paper, and decolorized with anilin oil of a mixture of 2 parts of anilin oil and 1 part of xylol, several times renewed. Finally the sections are cleared in xylol and mounted in balsam.

In many cases it is well to accomplish a double staining by a preliminary contrast stain. Thus, before the use of Weigert's modification of Gram's stain the sections may

¹ For the methods of staining spores see special works on bacteriology.

be put for half an hour in a solution of picro-carmin, then rinsed in water and stained as above. By this modification of Gram's method, fibrin is deeply stained.

Löffler's alkaline-methylene-blue solution is a very valuable and powerful stain for bacteria, either in fluids or in tissues.

It consists of—

Saturated alcoholic solution of methylene blue, 30 parts
Aqueous solution of caustic potash 1 : 10,000, 100 parts

For staining bacteria in tissues the stain is allowed to act for a few minutes. The section is then put for a few seconds in one-half-per-cent. acetic acid, then rinsed in water, and the superfluous color removed from the tissue by repeated rinsing in alcohol, which at the same time dehydrates it. Then it is cleared with oil of cedar and mounted in balsam. Care should be taken not to remove too much color with the alcohol.

It should always be borne in mind in staining the bacteria that great exactness is not usually necessary either in the strength of the coloring solutions or in the time of exposure of the bacteria to them. We are seeking for certain effects—namely, the staining of the germs—and this depends not only upon the quality and strength of the dye, the time of exposure, etc., but also upon the nature of the bacterial species and its conditions at the time the staining is undertaken. Thus it not infrequently happens that bacteria which will stain readily and deeply with a given solution when they are in a condition of active growth, may be scarcely at all colored if they have been dead or inactive for a long time, although their outward shape appears to be unchanged. So it should be remembered that, while there is little difficulty in most cases in staining the bacteria, the operation is not one of mere routine, but requires intelligent attention to the particular conditions of the species in hand.

For the recognition and study of bacteria the best optical apparatus is requisite. An homogeneous immersion lens (at least one-twelfth) and the Abbe condenser are indispensable for ordinary work.

Artificial Cultivation of Bacteria.

For a consideration of the methods of Artificial Cultivation of Bacteria, we refer to special works on Bacteriology, ref. p. 319.

Collection of Material for Bacterial Cultures.

Material obtained from the human body which is to be subjected to bacterial examination should be collected with every precaution against accidental contamination.

A convenient mode of collection and transportation of small quantities of fluid or semi-fluid material, such as exudates, discharges, etc., for purposes of bacterial exami-




FIG. 99.—STERILIZED COTTON SWAB IN A STERILIZED TUBE, FOR COLLECTING FLUIDS CONTAINING BACTERIA.

nation is to twist a small wad of absorbent cotton on to the end of an iron or steel wire about five inches long, put this, swab end foremost, into the tube (Fig. 99), plug the mouth with cotton, and sterilize the whole in a dry oven for an hour at 160° C.

Several of these cotton swabs may be prepared at once and kept on hand. The swab, carefully removed and saturated with the material to be examined, is at once returned to the tube; this is plugged, and may be thus safely transported.¹

¹ For further suggestions for the collection and examination of specimens for micro-organisms, and for references to studies on the bacteria of the human body, see pp. 150 and 151. Consult for details of species, general works on bacteria, especially *Kolle and Wassermann's "Mikroorganismen"*

II. Yeasts.

These micro-organisms—larger than bacteria and mostly saprophytes—consist of oval or spheroidal cells with granular protoplasm and a thin membrane. They multiply by sprouts or buds from the parent cell (Fig. 100). The new individuals may separate from the old, or may cling to them so that chain-like combinations may occur. They sometimes form endogenous spores, known as ascospores. Some species develop bright colors in their growth.

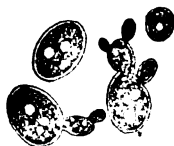


FIG. 100.—YEAST—
Saccharomyces.

There are many forms of yeasts which are concerned in various phases of fermentation. Some of these, alcoholic fermentation for example, are of great economic importance.¹ Certain forms of yeasts flourish in the stomach during digestive disorders and in the bladder in diabetes without inciting lesions. Various yeasts have been proven to be pathogenic in lower animals and in man.

*Blastomycotic dermatitis*² (Oidiomycosis) is a localized inflammation, papular and pustular in character, leading to warty outgrowths, to the

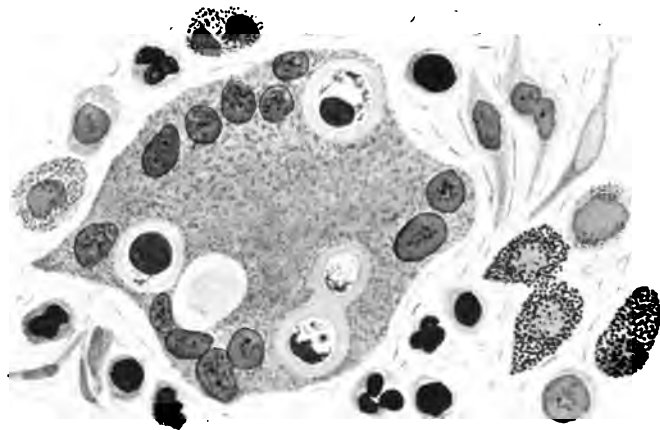

FIG. 101.—OIDIOMYCOSIS CUTIS—*Blastomycotic dermatitis*.

From skin lesions, showing giant cells containing the oidium with mast cells and eosinophilic cells in the adjacent tissue just beneath the epithelium.

formation of abscesses beneath the skin, and to ulcers. Deeper parts, such as bone, may be involved. Hyperplasia of epithelium and development of granulation tissue beneath with the formation of giant cells

¹ For a consideration of the relationship of micro-organisms to various forms of fermentation, with bibl., consult *Jorgenson*, "Micro-organisms and Fermentation," Eng. Transl. 1900.

² *Gilchrist*, Johns Hopkins Hospital Reports, vol. i., p. 269, 1896. For a *résumé* of pathogenic blastomycetes with experiments and bibliography, see *Foulerton*, Journal of Pathology and Bacteriology, vol. vi., p. 37, 1900; and *Sternberg*, Ziegl. Beitr., Bd. xxxii., 1902, p. 1; also *Ricketts*, "Blastomycosis of Skin," Jour. Med. Res., vol. vi., 1901, p. 377; also *Otis* and *Evans*, Jour. Am. Med. Assn., vol. xli., p. 1075, 1903; also *Bassoe*, Jour. Inf. Dis., vol. iii., p. 91, 1906; and *Irons* and *Graham*, *ibid.*, p. 666, 1906.

(Fig. 101), mast cells, and eosinophilic cells may be associated with the local growth of the blastomycetes and the formation of abscesses, the latter often intra-epithelial. The local lesion may extend to the involvement of large areas of skin and subcutaneous tissue.

The organism—*Oidium*—is present in the involved tissues as a rounded double contoured body (Fig. 102), varying in diameter from 10 to 20 μ . It sometimes buds and contains various rounded refractile or granular structures. These organisms may be enclosed in a homogeneous jelly-like mass. They are readily cultivated in artificial media and can be successfully inoculated into animals, such as the guinea-pig.

Generalization of the blastomycotic infection may take place and be fatal. In the systemic disease the lungs, spleen, and kidneys are especially involved in the formation of abscesses and local tissue hyperplasia containing the organism. There seem to be several forms of blastomycetes among the pathogenics already described, but their classification is unsatisfactory.

Thrush.—A micro-organism frequently found growing in the mouth and fauces and œsophagus of children, in the form of a whitish pellicle, is the so-called *Oidium albicans*, which consists of branching, jointed threads and spores which penetrate between the epithelial cells. This fungus may assume considerable importance, when in very feeble children it blocks the œsophagus, or when, as is rarely the case, from the surface of ulcers it penetrates the blood-vessels and gives rise to visceral metastasis. It is grouped with the yeasts, and the disease with which it is associated is to be regarded as an oidiomycosis.

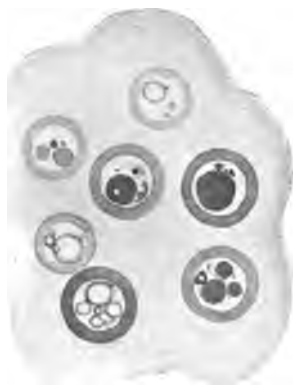

FIG. 102.—OIDIUM FROM A CASE OF OIDIOMYCOSIS CUTIS (Blastomycotic dermatitis).

III. Moulds.

The moulds are considerably more complex in structure than either the bacteria or the yeasts. Some of the forms are very common and universally known. In general, it may be said that the moulds consist of a series of delicate, translucent, branching jointed threads—*mycelium*—usually giving rise to *hyphæ*, from which, either directly or in more complex forms through the intervention of a special structure, the *sporangium*, the spores are developed (Fig. 103). The moulds which are apt to occur in the human body may be of the former, more simple, or of the latter, more complex, type.¹ Among the simpler forms of moulds which occur in the body may be mentioned the *Achorion Schönleinii*, *Microspo-*

¹ See *Renon*, "Etude sur l'aspergillose chez les animaux et chez l'homme," Paris, 1897; also *Leopold and Lévi*, *Gaz. des Hôpitaux*, June 26th, 1897, bibl.; also *Pierson and Ravenel*, *University Med Mag.*, August, 1900; also *Sayer*, "Pneumonomykosis aspergillina," Jena, 1900.

ron furfur, *Trichophyton tonsurans*. There is a close morphological resemblance between these forms.

The *Favus Fungus* (*Achorion Schönleinii*), is formed of a much-branching

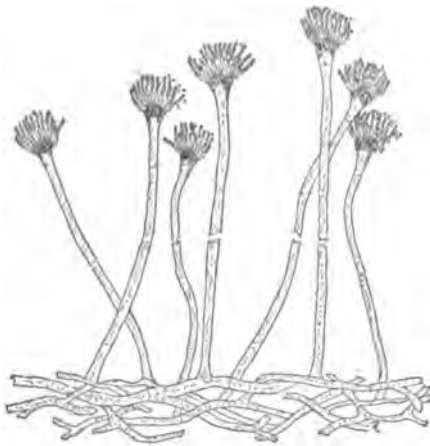

FIG. 103.—ASPERGILLUS GLAUCUS.

Showing mycelium, from which arise the spore-bearing structures, the sporangia borne upon the hyphæ.

mycelium from which the spores are directly developed (Fig. 104). It grows readily on artificial culture media, such as nutrient agar and gelatin, at the temperature of the body. This fungus is most apt to grow upon the hairy part of the head, where it forms small surface crusts and grows into the shafts and root sheaths of the hair, exciting inflammation in the adjacent tissue.

Ring Worm (*Tinea circinata*; *Herpes tonsurans*).—The inciting agents of this readily communicable disease are several species of *Trichophyton tonsurans* which develops in the form of a moderately branching mycelium, forming comparatively few spores. It grows

in the skin, either about or apart from the hairs, or in the nails, inducing the lesions of various phases of ring worm which differ considerably, depending upon the particular structures involved. At body temperature it grows readily on artificial culture media, differing markedly in appearance from *Achorion*.

Pityriasis versicolor.—*Microsporon furfur*, the mould fungus causing pityriasis versicolor, is more prone than the *Achorion* to the development of many spores, but otherwise considerably resembles it morphologically. It has not yet been cultivated on artificial media. By its infiltration of the epidermis, especially of the body and upper extremities, it causes larger and smaller yellowish or brownish patches.

The Higher Moulds.—The more complex types of moulds are only occasionally dwellers in the human body and appear to be but rarely the cause of disease, passing, rather, a saprophytic existence on dead material in parts of the body which are in communication with the air. Thus they may be found growing on accumulations in the external auditory canal, in dead tissue in the lungs, on walls of cavities, dilated bronchi, etc. Many cases have been reported, however, in which the moulds, especially

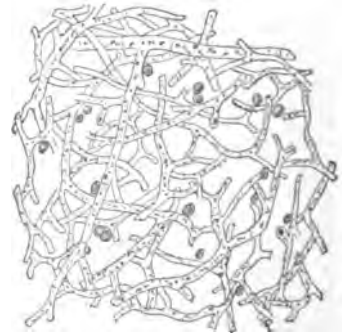


FIG. 104.—ACHORION SCHONLEINII—FAVUS.
From a culture.

aspergillus, have been the apparent excitants of serious lesions in men and animals.¹

Methods of Studying Yeasts and Moulds.

The yeast organisms are in general stained and cultivated by the same methods as those used in studying the bacteria. By treating unstained sections of tissue containing them with a solution of caustic potash the organisms may often be readily demonstrated.

The higher moulds may be simply teased and studied in glycerin or in glycerin and water. They may be stained with alkaline-methylene-blue solution (Löffler's solution, see p. 145). When spores have formed in considerable numbers on the more complex forms of moulds, these are not easily wetted by the usual staining fluids, because the air clings so closely among the spore masses. In a mixture of four parts of alcohol and one of aqueous solution of ammonia they are instantly wetted, and may then, with or without staining, be teased and mounted in glycerin. In studying the moulds in the above-described skin diseases it is well, when crust-like masses are to be teased apart, to allow them first to soak for a few minutes in a five-per-cent. solution of caustic potash. In this solution they may be studied, or they may be teased and mounted in glycerin for preservation. Most of the more common moulds are readily grown on the ordinary culture media.

¹For résumé and bibliography of relationship of yeasts and moulds to human diseases consult Ricker, Lubarsch and Ostertag's "Ergebnisse der allg. Aetiologie der Menschen- u. Thierkrankheiten," Abth. i., 1896, p. 892. See also Hektoen, *Journal of Experimental Medicine*, vol. v., p. 77, 1900; Plaut in "Kolle and Wassermann's Handbuch," Bd. i.

CHAPTER VIII.

THE RELATIONS OF MICRO-ORGANISMS TO DISEASE—INFECTION AND IMMUNITY.

THE PRESENCE OF BACTERIA AND OTHER MICRO-ORGANISMS IN THE BODY: ITS PROTECTIVE MECHANISM.

The Presence of Bacteria.—Bacteria are invariably present in greater or less numbers in the mouth, nose, upper air passages, gastro-intestinal and genito-urinary tracts of men and animals.¹ Into these places they are more or less constantly brought by the respired air,² by food and drink, and in other ways. They are always abundant upon the skin and about the hairs, and the sweat and sebaceous glands. But common and often abundant as are these germs upon the external and internal surfaces of the body, they do not often pass through the healthy mucous or cutaneous surfaces,³ so that under normal conditions the tissues, the viscera, and the circulating fluids are practically sterile.⁴

Except for certain pathogenic forms which may, under unsanitary conditions, have been set free and transported from men or animals suffering from infectious disease, the bacteria upon the cutaneous or mucous surfaces of the body are for the most part harmless; while certain intestinal forms may even be useful in promoting digestion.

Certain species of bacteria which do not often and some which never induce disease, find in or upon the human body such especially favorable conditions for their existence that they are commonly present there.

The Safeguards of the Body.—The body is guarded in various ways from the incursions of pathogenic and other bacteria, which may be commonly present or only occasionally lodged upon its surfaces. Among the protective agencies of the body may be mentioned the firm, dense skin which while intact protects the interior from the entrance of almost all known micro-organisms; the epithelial investment of the mucous membranes in several places swept by cilia; the protected situation of most of the mucous surfaces, the germicidal qualities of some of the secretions, such as the saliva, gastric juice, mucus, etc.⁵

¹ For a summary of facts concerning the bacterial flora of the body surfaces consult *Welch*, "Surgical Bacteriology," "System of Surgery by American Authors," *Dennis*. See also *Ford*, "The Bacteriology of Healthy Organs," *Trans. Assoc. Amer. Phys.*, vol. xv., p. 389, 1900, *bibl.*; also, "Bacteria in Healthy Bodies and their Portals of Entry," *Seller*, *Zeits. f. Hygiene*, etc., Bd. liv., p. 363, 1906.

² For a *résumé* of micro-organisms in the air see *Gottstein*, *Lubarsch and Ostertag's "Ergebnisse," Jahrgang iv.*, pp. 87 *et seq.*, 1897; also *Firth*, "Studies from the Department of Pathology," *Col. Phys. and Surg.*, Columbia University, vol. vii.

³ It should be remembered that the gastro-intestinal canal, the lungs, and other viscera which are in communication with the exterior, although within the limits of the body, still form, strictly speaking, its outside, in distinction from the intimate recesses of the tissues in which the life processes go on.

⁴ See p. 151.

⁵ For a *résumé* of the protective action of the skin, mucous membranes, etc., see *Metchnikoff*, "Immunity in Infective Diseases," *Trans.*, 1905.

See for summary of protective agencies of the lungs, p. 600. For a study of the action of saliva on bacteria see *Clairmont*, *Wiener klin. Wochenschr.*, Nov. 22d, 1906, *bibl.*

The Portals of Entry.—But notwithstanding the safeguards of the body against the access of micro-organisms, these do frequently enter; this may occur in severe injuries to the skin or mucous membranes or through very slight and unnoticed abrasions or other solutions of continuity. Entrance may be gained to the tissues through the minute ducts of the sebaceous or sweat glands; from the mouth, tonsils, gastro-intestinal canal,¹ and the respiratory passages and surfaces, either with or without obvious injuries to the investing epithelia. The rôle of insects in the conveyance of infectious agents is of great importance.² Micro-organisms may enter the body during intrauterine life.³

There is abundant evidence that even in health, through the pharynx, tonsils, and intestines, a small number of bacteria frequently enter the recesses of the body, but are safely disposed of through the protective mechanism presently to be considered. So that while we may, as above stated, consider the interior of the healthy body as *practically* sterile, it is still possible by careful and discreet searching to discover here and there bacterial detritus and bacteria on their way to destruction.⁴

The Protective Mechanism.—When in one way or another bacteria or other germs have entered the tissues, they may encounter a series of obstacles to their spread or continuance as well as to their proliferation there, even should the general nutritive conditions be favorable. In the first place the lymph-nodes filter out of the tissue fluids micro-organisms which have entered them, holding them back from the general circulation or destroying them.⁵ The power of certain of the body fluids and of living cells—phagocytes—under favorable conditions to kill and dispose of germs, is of great importance and will be referred to again.⁶ The elimination of micro-organisms from the body through its secretions,⁷ such as urine, bile, milk, sweat, saliva, etc., is a matter of great significance, but one upon which the scope of this book does not permit us to enter.⁸

¹ For bibliography concerning the permeability of the gastro-intestinal canal for bacteria refer to p. 681.

² *Nuttall*, Johns Hopkins Hospital Reports, vol. viii., p. 1, 1900. For studies of flies as carriers of typhoid see *Hamilton*, Jour. Am. Med. Assn., vol. xl., 1903, p. 576; also *Martin*, Public Health, August, 1903; also "Flies and Tuberculosis," *Lord*, Boston Med. and Surg. Jour., vol. cli., p. 651, 1904; and on spread of plague by insects, *Hunter*, Centralbl. f. Bakt., Orig. Bd. xl., p. 43, 1906, and "Economic loss by Insects," *Howard*, U. S. Dep. Agricult. Bureau of Entomology Bull., 78, 1909.

³ For a *résumé* of studies on the congenital transmission of infectious agents see *Wassermann*, in *Kolle and Wassermann's* "Handbuch der Mikroorganismen," Bd. i., p. 380, bibl.; also, *Balantyne's* "Antenatal Pathology," 1902 and *Lynch*, Johns Hopkins Hospital Bull., x., 283, 1902.

⁴ *Adami* on "Latent Infection and Subinfection," etc., Journ. of the Amer. Med. Association, December 16th and 23d, 1899; also *Wrzosek*, Virch. Arch., Bd. 178, p. 82, 1904; see also for an experimental study of the disappearance of bacteria from the blood, *Schwarz*, Zeits. f. Heilkunde, Abth. f. Path. Anat., Bd. xxvi., p. 295, 1905.

⁵ *Manfredi*, Virch. Arch., Bd. clv., p. 335, 1899, for a study of the germicidal and other action of lymph-nodes; also *Bezançon and Lubbé*, Arch. de méd. expérimentale et d'anat. path., t. x., p. 389, 1898.

⁶ For studies of the capacity of the living body to dispose of bacteria when these are injected into the blood, see *Werigo*, Ann. Inst. Pasteur, t. viii., 1894, also *Bail*, Arch. f. Hygiene, Bd. lii., p. 272, 1905; see also *Buxton and Torrey*, Jour. Med. Res., vol. xv., p. 5, 1906.

⁷ Consult *Sherrington*, "Experiments on the Escape of Bacteria with Secretions," Journal of Pathology and Bacteriology, vol. i., p. 258, 1893; *Biedl and Kraus*, Arch. f. exp. Path., Bd. xxxvii., p. 1, 1895, bibl.; *Hintze and Lubarsch*, "Ergebnisse der allg. Aetiologie der Menschen- und Thierkrankheiten," 1896, p. 287. For study of disappearance of bacteria from the body, see *Pavlovsky*, Zeits. f. Hygiene and Infect. Krankheiten, Bd. xxxiii., p. 261; see also ref. to *Aesch*, p. 755.

⁸ For a suggestive summary of the various factors which are or may be concerned in the protection of the body against the invasion and action of micro-organisms, see *Meltzer*, "Physiological Methods

ACTION OF BACTERIA AND THEIR PRODUCTS IN THE BODY.

The Bacteria.—When bacteria do enter and grow in the body, the cells and tissues near them may show very marked alterations, due to their influence. The cells may be swollen, or their nuclei may disappear, and the protoplasm may be converted into hyaline material or into a mass of transparent or coarsely granular particles, or may completely disintegrate. The intercellular substance near the bacteria may also soften and disintegrate. In a word, the tissue in their immediate vicinity is often found in a condition of necrosis of one kind or another. The walls of blood-vessels near which they lie may be damaged and the blood which these carry may form thrombi. The bacteria may themselves enter the vessels and proliferate in the blood; they may be swept away as emboli to remote parts of the body (Fig. 56, p. 89), and establish new foci of bacterial proliferation and tissue necrosis—*septicæmia*.

Some bacteria, instead of inducing a simple necrosis, incite at the same time, as we have already seen, a more or less intense inflammation (Fig. 57, p. 90). This inflammation may be of a simple productive form, similar in its effects to that incited by the presence of any irritating foreign body; or it may be active, progressive, and exudative in character; or the bacteria may determine, in some way as yet unknown to us, very peculiar and characteristic inflammatory changes, which result in the formation of new tissues of various kinds (see Tuberculosis). Some forms of bacteria find in the blood, others in the tissue spaces and lymph-vessels, the conditions most favorable for their proliferation.

Bacterial Poisons.—But the presence of micro-organisms themselves is not indispensable for the incitement of either local or general pathological processes. These may be induced by various chemical products eliminated or stored up in their protoplasm by the metabolism of the germs. These deleterious bacterial products may, as we have already seen, be those alkaloidal substances called poisonous ptomains, or *toxins*, or they may be albuminoid substances—*toxalbumins* or *toxalbumoses*. Stored up in the protoplasm of the germs themselves, this poisonous material has been called *bacterio-protein* and *endotoxin*.

It seems probable that the toxic effects of some bacteria may be due not to their immediate product but to the action of bacterial enzymes, whose action upon certain body proteids results in the development of the toxic albumoses which are the active damaging factors.¹

of Protection of the Body against Bacteria," Trans. of the Congress of Am. Phys. and Surg., vol. v., p. 12, 1900; see also ref. to Wassermann above.

See also for the importance of a lesion in animal tissues for the lodgment and multiplication of bacteria within it, *Cheesman* and *Meltzer*, Jour. Exp. Med., vol. iii., p. 533; and *Brewer* on unilateral infection of the kidney following injury, Surgery, Gynecology, and Obstetrics, vol. ii., p. 485, 1906; also on the significance of granulation tissue in wound infection, *Afanassieff*, Ziegler's Beiträge, Bd. xxii., p. 11, 1897; also *Cobbett* and *Melsome*, Centralbl. f. Path., Bd. ix., p. 827, 1898, bibl.; also *Jürgelinas*, Ziegler's Beiträge, Bd. xxix., p. 92, 1901, bibl. For the rôle of the spleen in infection and intoxication see *Courmont* and *Duffau*, Arch. de Méd. exp., May, 1898, p. 431, and *Nicolas* and *Beau*, Jour. de phys. et path. gén., t. iii., 1901, p. 68.

¹ Much of the literature on this subject has been brought together by *Vaughan* and *Novy*, "Cellular Toxins." See also *Vaughan*, Trans. Assn. Am. Phys., vol. xx., 265, 1905. The general chemical relationship of bacterial products to other organic compounds is set forth in *Halliburton's* "Text-Book of Chemical Physiology and Pathology"; see also *Oppenheimer* on "Bacterial Poisons" in *Kolle* and *Wassermann's* "Handbuch der Mikroorganismen," Bd. i., p. 344.

AGGRESSINS.—It has been found by Bail that when one injects into animals sterilized exudates induced by the action of various pathogenic micro-organisms—tubercle, typhoid, and dysentery bacilli, pneumococcus, staphylococcus, etc.—together with sublethal doses of cultures of the organisms themselves, the death of the animal is brought about much sooner than when the bacteria alone are introduced. Bail, as the result of many experiments, assumes that under these conditions the exudate contains substances which foster the deleterious effects of the living organisms by interfering in some way with the protective agencies of the body. These hypothetical substances he has called *aggressins*, and he believes them to be formed by the bacteria as they grow in the body.¹ This aggressin theory has not found general acceptance and much experimental data has been brought forward to controvert it.²

Intoxication—Toxæmia.—Some of the poisons act locally at or near the seat of their manufacture by the growing germs. Others gain access to the body at large and are widely distributed, inducing what may be called the phenomena of septic *intoxication—toxæmia*.

The phenomena of septic intoxication may be induced by the products of bacterial growth outside of the body when these in considerable quantity are in any way taken into it. This is true not only of poisons elaborated outside the body by pathogenic bacteria, but also of many forms of bacteria usually harmless. Thus are caused many forms of food poisoning which simulate but are not actually infectious diseases, because there is no development within the body of the disease-inciting germs.

Similar local and general effects may be induced in the body by other poisons than those of bacterial origin. Ricin and abrin, for example, well-known vegetable poisons, and the venom of scorpions and of certain snakes are closely similar in their action to the toxins which the bacteria form either within or without the body.

It should be remembered in this connection that effects closely resembling those due to bacterial or allied poison may be induced by toxic agents developed within the body as a result of defective elimination or faulty cell metabolism—*auto-intoxication* (see p. 426).

Thus the deleterious effects of pathogenic bacteria upon the body are but in small measure simply mechanical. Local necrosis³ and inflammation, albuminous degeneration of cells, leucocytosis and other alterations of the blood, fever, structural lesions and functional disturbances in the nervous system, irregularities in the circulatory and respiratory mechanisms, hæmolysis and agglutination of the red blood cells and thrombosis,⁴ etc., may follow the distribution in the body of bacterial toxins.⁵

PROOFS OF THE INFECTIVE NATURE OF BACTERIA FOUND IN THE BODY.

It will be seen, from what has now been said of the bacteria, that in different parts of the system in health, and in a large number of abnor-

¹ For a discussion of the so-called aggressins see Bail and Weil, Cbl. f. Bak., Abth. I., Orig. Bd. xlii., pp. 51, 139, 241, 335, 437, and 443, 1906.

² See Sauerbeck, Arch. f. Hyg., lvi., 1907.

³ See Flexner, "The Pathology of Toxalbumin Intoxication," Johns Hopkins Hospital Reports, vol. vi., p. 259, 1897.

⁴ For bacterial hæmolysins see Pribram, Kolle and Wassermann, "Handb. d. path. Mik.," Ergänz. Bd., p. 291.

⁵ On the theory of bacterial infection see Radziewsky, Zeits. f. Hygiene, Bd. xxxvii., p. 1.

mal conditions, various forms of bacteria occur; but it is quite evident that the significance which we must attach to their mere presence varies greatly. In a large number of cases, especially when on parts exposed to the air or in the gastro-intestinal canal, they are evidently of no more importance than so much inorganic dust. When, however, special forms of bacteria are uniformly present in connection with well-defined diseases, or in their lesions, and especially if these largely preponderate, the conjecture is certainly justified that the micro-organisms may have something to do with their incitement. Yet in all such cases we have to consider the possibility that it is the abnormal state of the body or the character of a lesion, brought about perhaps in other ways, which affords conditions suitable for the growth of this form of bacteria, and that these may consequently be present in considerable numbers, while in the absence of such conditions they would be unable to develop. Even the constant presence in the body, in certain diseases, of bacteria which evidently produce well-marked local effects, either inflammatory or degenerative, does not absolutely prove their etiological relationship to the disease, although it renders it in a high degree probable.

It is desirable in every case in which the evidence of the etiological relationship of a specific micro-organism to a disease is to be set forth, that we should be able to demonstrate the constant presence in the body of the special form of micro-organism during some period of the disease, obtain this by culture in a pure condition unmixed with any other living thing or with any chemical substance not belonging to it, and finally, by the introduction of the purified organisms into a healthy animal, be able to induce the disease in some definite form. When all this is done, and not before, can we assert that the evidence establishing the causative relationship between a given form of bacteria and any special infectious disease, is entirely at our command.

But the fulfilment of these strict logical requirements is very difficult in many cases, and in some, apparently, almost if not quite impossible; for we must remember, in the first place, that the lower animals, upon which alone, for the most part, inoculation experiments are practicable, are apparently not subject to certain important diseases of man; and, second, that they present among themselves the most marked differences in the degree and manner in which they are affected by inoculation with pathogenic bacteria. Desirable as is the complete fulfilment of the above requirements in every case, it must be admitted that a reasonable certainty regarding the bacterial origin of a given disease may sometimes be arrived at without positive results from the inoculation of the bacteria associated with its lesions. The agglutination test and the tests for specific lytic substances or opsonins applied under proper conditions may afford valuable evidence of the nature of an infection (see pp. 186 and 193).

The complete demonstration which is desirable has as yet been furnished in but a moderate number of diseases. In many others, however, enough has been done in the way of study and experimentation to render it altogether certain that they are infectious and to establish beyond

reasonable doubt the identity of the micro-organism or micro-organisms involved.

CONDITIONS INFLUENCING THE OCCURRENCE OF INFECTIOUS DISEASES.

Conditions of the Body.—It has been learned as a result of a great deal of observation and experiment, that although certain diseases are always associated with the presence and growth in the body of particular species of micro-organisms, there are still various other accessory factors which have an important bearing upon the inception and course of the diseases. Thus, while the presence in the body of a particular species of micro-organism is the most significant and fundamental of the determining agencies in the infectious diseases, the numbers in which they are present—*i.e.*, the size of the dose—and the varying virulence which the same species under different conditions possesses, as well as the varying capacity of resistance to the incursions of the germs which the body-cells at different times and under differing conditions exhibit, are all factors of the greatest moment.

Malnutrition, mental or physical overwork, injuries, bad hygienic surroundings, the abuse of alcohol and other forms of intemperance, as well as many other conditions which lead to deterioration in the general health, are often decisive factors in determining the intensity or even the occurrence of the diseases due to bacterial incitement. It is thus clear that the action of a given germ in the living body depends only in part upon its intrinsic capacities—which in themselves are very variable—but also and in marked degree upon the capacities, also variable, which exist at the moment in the body-cells among which the lot of the germs is cast.

It should be always borne in mind that the human body is a great aggregate of groups of co-ordinated cells which, under normal conditions, all act in harmony for the maintenance of the life and functions of the individual. The cells and cell communities in health not only do this, but they have the power of resisting and to a certain extent overcoming various deleterious agencies to which the body is more or less constantly liable.

What we call hereditary or acquired predisposition to an infectious disease, such as tuberculosis for example, is simply a lack of the usual capacity of the cells of the body—whether through a structural or physiological fault we do not yet know—to cope with—that is successfully to adapt themselves to—the destructive tendencies of the living micro-organisms when once these gain a foothold in the body.

Conditions of the Micro-organisms.—On the other hand, the varying potencies of the bacterial species concerned in a given infection, which are linked especially to their toxins, and the influence of environment upon these, exalting or reducing them, as the germs adapt themselves to antagonistic or to congenial hosts; the origin of the strains and the numbers involved—these are all factors in virulence of supreme importance, but our space does not permit us to consider them further here.

We thus see that, in studying the conditions under which infectious

diseases occur, the work is by no means complete when the bacterial species which incites the disease has been discovered, but that then the more obscure determining and influencing agencies must be worked out in each case.¹

Infection and Immunity.

INFECTIOUS DISEASE AND THE NATURE OF INFECTION.

Infectious diseases are those which are incited by the entrance into the body and proliferation there of pathogenic micro-organisms. *Infection* is the act or process by which such diseases are incited. The process of infection is "the interaction between the organism and the micro-organism."

In the more exact usage of the words "infectious" and "infection" which our new knowledge demands, it is customary and convenient to limit the term "micro-organism" to the fungi—bacteria, yeasts, and moulds—and to the protozoa representing the animal kingdom, excluding altogether the entozoa and other animal parasites.²

The modern conception of infection implies the presence in the body of the *living* micro-organisms themselves; that is, of something capable of multiplication, or at least of reproduction and development, and not alone of the poisons which they may and usually do produce. It is customary to look upon the effects of the absorbed poison which micro-organisms furnish as *intoxications*, whether these poisons be formed inside the body in infectious diseases and in other conditions, or outside of it and subsequently introduced. That condition in which there is evidence of wide distribution of pathogenic micro-organisms and their products in the blood is called *septicæmia* (see p. 203).

It is evident from what has been said that infectious disease cannot exist without the presence in the body of micro-organisms. But, on the other hand, micro-organisms can and do frequently exist in the body without the incitement of infectious disease. Whether a micro-organism be pathogenic or not depends upon the variable susceptibilities of the host as well as upon its own—also variable—nature and qualities. No micro-organism is intrinsically pathogenic; the very conception implies a relationship. This obvious fact is overlooked by those who see in the micro-organisms alone the essential specific features of infectious diseases; who would classify these diseases exclusively by the nature of their excitants, and who look upon the latter as the true "causes" of the phenomena through which disease is manifested (see p. 5).

INCUBATION PERIOD.

It is characteristic of infection that a certain time elapses between the entrance of the infective agent and the manifestation of symptoms

¹ For a *résumé* of the nature and conditions of infection, see *Wassermann, Kolle and Wassermann's "Handbuch der Mikroorganismen,"* Bd. i., p. 223, bibl.; for a study of the general reaction of the body in infection see *Blumenthal, ibid.,* p. 326.

² With this somewhat arbitrary limitation, neither trichinosis nor scabies, for example, would be considered an infectious disease, although they are often, for the lack of a distinctive word, thus designated.

or the development of lesions. This interval is called the "incubation period" of the infection and varies with different infective organisms. This incubation period is that time during which the micro-organisms are increasing sufficiently in number or virulence in the body to induce symptoms and lesions or are passing through developmental cycles marking their adaptation to the environment furnished by the host.

FORMS OF INFECTION.

Mixed or Concurrent Infection.—It should be borne in mind that the body which is already the seat of an infectious disease is usually especially susceptible to the action of other pathogenic germs, should these once gain entrance; and also that the lesions which are associated with many of the infectious maladies afford portals of entry through the skin or mucous membranes to other micro-organisms, against the entrance of which the healthy body opposes most efficient barriers. In fact, we now know that the action of two or more pathogenic micro-organisms in the body at the same time is of very frequent occurrence, many of the so-called complications of the infectious diseases being due to secondary infection with a new germ species. Numerous examples of this "mixed" or, better, "concurrent," infection are noticed in other parts of this book.¹

Many important facts have been revealed by the study of bacterial association in cultures as well as in infectious diseases of men and animals which cannot here be considered.² It may be said in general that in animals as in man concurrent infection with a second micro-organism increases the gravity of the original situation. On the other hand, certain experiments seem to indicate that sometimes the concurrent action of a second germ—streptococcus, for example, with the anthrax bacillus—may render a virulent organism comparatively innocuous. But the conditions of the experiments are in either case so complex that the full significance of many curious phenomena is not yet apparent.

Congenital Infection.—Infection of the fœtus through such lesions of the placenta as permit of the passage of pathogenic micro-organisms from the blood of the mother to that of the child is of occasional, but not frequent, occurrence. While the barriers against such transmissions are, under normal conditions, effective, disturbance in the placental circulation, lesions of the vessel walls or of the tissues and covering of the chorionic villi favor it. But infection may occur without demonstrable evidence of such lesions. Thus fœtal infection is known to have occurred in various phases of suppurative inflammation, in tuberculosis, typhoid fever, anthrax, syphilis, the exanthematous fevers, etc. There is considerable evidence that rarely the tubercle bacillus may be transmitted

¹ For bibliography of mixed infection see *Bernheim and Gruber*, *Lubarsch and Ostertag's "Ergebnisse,"* Jahrg. 2, for 1895, p. 1; also *Wassermann*, in *Kolle and Wassermann's "Handbuch der Mikroorganismen,"* Bd. i., p. 307.

² Consult *Th. Smith*, *Trans. Assn. Am. Phys.*, vol. ix., p. 85, 1894; also *Moore*, "Pathology and Differential Diagnosis of Infectious Diseases of Animals," 1906.

from mother to offspring, and remaining for a time inactive may later induce the characteristic lesions.¹

Terminal Infection.—The victims of chronic disease of the heart, blood-vessels, kidneys, liver, etc., are particularly susceptible to the incursions of pathogenic micro-organisms and to infectious diseases of one kind or another. Such persons, with or without definite lesions, are in fact liable finally to succumb to the complicating disease. The phrase "*terminal infection*" has been applied by Osler and others to this concurrence of diseases of such different nature, in which the chance infection of a vulnerable organism is so apt to prove fatal.²

Great care is, however, necessary in determining the significance of the various forms of bacteria which may be present in the body after death. Not only may bacteria develop to a considerable extent in the body during the hours which precede death when the natural protective agencies are halting or abeyant, but this may occur without such a reaction on the part of the body cells as is necessary to constitute an actual infection. Furthermore, multiplication and distribution of bacteria in the body after death is of frequent occurrence and must in every case be taken account of in weighing the evidence for terminal infection.³

COMMUNICABILITY OF INFECTIOUS DISEASES.

It is important in practical dealings with the infectious diseases to consider them in the light of the relative liability of transmission of the actually known or assumed micro-organisms from diseased to healthy individuals.

In the first place, it should be borne in mind that the lower animals are insusceptible to the ravages of some of the micro-organisms which readily incite infectious disease in man. Thus the lower animals are, so far as we know, naturally immune to syphilis. To certain diseases of the lower animals, on the other hand, man is not subject. But to certain other infectious diseases, tuberculosis for example, both men and lower animals are susceptible, and both are, in fact, under the prevailing conditions of modern life, frequent victims.

So far as the liability to the transmission of the infectious agents from man to man is concerned, there is a very marked and significant difference between the infectious diseases. It is common usage to speak of the transmission or communication of disease, as if disease were a self-existent thing. This usage fosters much loose thinking. What we call disease is a process involving a departure from, failure in, or perversion of normal physiological action, either in the material constitution or in the functional integrity of the living organism. When, therefore, we speak of the transmission or communication of disease, what we really mean is not that the disease, but the agent capable under suitable conditions of inciting the disease, is transmitted or communicated. If we

¹ For bibliography and summary of foetal infection see *Lubarsch*, "Ergebnisse der allg. Aetiologie der Menschen- und Thierkrankheiten," Jahrg. i., p. 427, 1895; also *Fischl*, in *Grancher, Comby, and Marjan's* "Traité des Maladies de l'Enfance," t. i., p. 454, bibl.

² For a study of this class of cases see *Flexner*, *Trans. Assn. Am. Phys.*, vol. xi., p. 229, 1896.

³ Consult *Achard and Phulpin*, *Arch. de méd. expérimentale*, vol. vii., p. 25, 1895.

hold this obvious implication in mind, it is useful to group the infectious diseases of man into two great primary classes: 1st, *Those which under the usual conditions of life are not readily communicable.* 2d, *Those which under the usual conditions of life are readily communicable.*

But while, for convenience, we may speak of *non-communicable* and *communicable infectious* diseases, we should remember that these two classes merge into each other, and that in fact the agents of infection may at least artificially in all cases be conveyed from one individual to another. It is only when the conveyance under natural conditions occurs in a round-about way, or through intermediary agencies, such as the mosquito for example, in malaria or yellow fever, that one may advisably speak of non-communicable infectious diseases.

Among the communicable infectious diseases there exists the widest difference in the liability to transmission under ordinary circumstances. Thus the infectious agents in smallpox and scarlatina are given off from the body under such conditions as render possible and frequent their direct transmission through the air to another individual. In syphilis, tetanus, and rabies, on the other hand, transmission of the infectious material is rare or impossible without a direct inoculation.

Between these extremes the widest diversity exists in the liability to transmission of the infectious agents of the diseases of this class. In fact the liability to infection on the part of a healthy individual in the presence of a victim of infectious disease is largely dependent upon the intelligent care which is exercised in the disposition of the material containing the pathogenic micro-organism which in one way or another the infected body sets free.

So that while it may be useful to arrange the communicable infectious diseases in groups, or in such serial order as may indicate the degree of communicability of each under the ordinary conditions of life, it should always be borne in mind that this classification is not fundamental as is that by which the infectious diseases as a whole are set apart from other diseases, but is closely dependent upon the sanitary conditions under which each case may be placed. Thus tuberculosis, or diphtheria, or pneumonia may be high on the list as readily communicable if the patient be housed in a crowded tenement with ignorant or careless attendants, while if subjected to the intelligent ministry of sanitary science these diseases may be accounted as relatively slightly communicable.¹

Communicable infectious diseases sometimes affect a considerable number of persons in a community. This constitutes an *epidemic*, and the term *epidemic disease* is used. So also if an infection is constantly present in a certain locality it is said to be *endemic*. The term *pandemic* is used to indicate the involvement of persons all over a large territory in a particular infectious disease.

¹ Before the knowledge of pathogenic micro-organisms had become precise, readily communicable diseases were called contagious in a rather loose and ill-defined way, and the unknown excitant was called the *contagium*. The word "contagious" is still used, in various senses, to the detriment of science. We can get along well enough without it by the use of the word "communicable" as above indicated. But if it must still be cherished it might be wisely limited to the exanthemata, whose inciting agents are more readily and commonly transmitted through the air from the body of the patient than are those of any of the other infectious maladies.

IMMUNITY.

NATURE AND FORMS OF IMMUNITY.

We have seen that *an infectious disease is one incited by the entrance into the body and proliferation there of pathogenic micro-organisms, and that infection is the act or process by which such a disease is incited.*

The fact that all animals are not equally susceptible to the ravages of pathogenic micro-organisms, and that in man an individual and often a changing predisposition or invulnerability to the incursions of these organisms exists; the further observation that one attack of an infectious disease often protects the victim for a longer or shorter time against a recurrence; finally, the fact that recovery is ever possible when once self-multiplying disease-producing germs have obtained a foothold in the body—all these facts and observations are of such singular import and interest that, especially of late years, there has been much study on the nature of the agencies which the body brings into play in establishing immunity in the face of microbial invasion, and in coping with the various deleterious factors at work when once a foothold is obtained. The scope of this book does not permit us to enter in detail into this most fascinating and important field. We can give only a brief summary of some of the more important features.

Immunity is insusceptibility, or capacity for resistance on the part of the body to disease or, in the more limited sense, to infection or intoxication or their effects.

If we recall the ways in which bacteria damage the organism, it will be evident that immunity may be due to the fact that the micro-organisms in question simply do not proliferate in the body, failing, even should they gain entrance, to find the necessary conditions.¹ On the other hand, though the conditions be in general favorable, substances may exist or be formed in the body which destroy the invading germs. In other words these may at once or soon be disposed of by germicidal substances, either in cells or in solution in the body fluids.

Or, the toxic substances which micro-organisms set free, as in the process of their nutrition they decompose organic ingredients of the tissues or body fluids, may be rendered inert by further decomposition or combination with substances present or formed in the tissue fluids. Or, furthermore, the cells which are susceptible to the presence of the toxins may become less vulnerable by adaptation to the deleterious effects of the latter. Thus by a total unsuitability of the tissues or of the general conditions to bacterial growth; by destruction of the invading germs; by neutralization or destruction of toxins; or, finally, by a capacity of resistance or tolerance won through adaptation to a new and intrinsically harmful environment, we may conceive of conditions which in a measure account for the known phenomena of immunity.

¹ For a most suggestive and valuable paper on the adaptation of pathogenic bacteria to different species of animals see *Theobald Smith*, Philadelphia Medical Journal, May 5th, 1900.

Immunity from an infectious disease may be **natural** or **hereditary**.¹

The absolute or relative insusceptibility of turtles and fishes for tetanus, of rats for anthrax, and of the lower animals for syphilis and for scarlatina, are examples of hereditary or natural immunity which we need not further consider here. Immunity is variable and rarely absolute, and is subject to individual, as well as racial, variation.

On the other hand, immunity may be **acquired**. Acquired immunity may be secured by an attack of the disease from which the individual has recovered—*natural immunization*. Or, immunity may be acquired by the introduction into the body of some material which gradually diminishes susceptibility without inducing distinct disease—*artificial immunization*. Acquired immunity may be transmitted from parent to offspring.

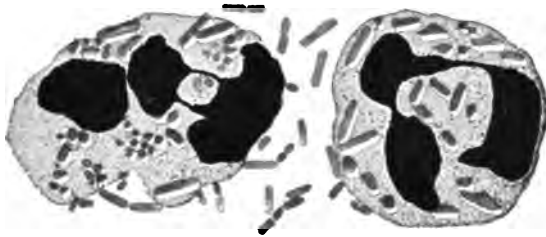


FIG. 105.—PHAGOCYTES.

In fluid from the peritoneal cavity of an immunized guinea-pig a few hours after the introduction of the bacilli of typhoid fever. Degenerative changes are seen in many of the bacteria within the cells.

Most of the infectious diseases appear to confer a certain degree of insusceptibility to subsequent attacks of the same disease, though this may be partial and temporary. But the exanthemata afford the most striking examples of acquired immunity after an attack of infectious disease.

Let us now look more closely at some of the ways in which the body may thus protect itself from the consequences of infection.

It is well known that bacteria artificially introduced into the blood of animals may, after a short time, wholly disappear from the circulating fluid, and be found in large numbers in leucocytes and other cells. We have already seen in the study of inflammation (see p. 98) that certain cells of the body are capable of taking up not only various kinds of alien substances, but also micro-organisms which enter the tissues, into their cytoplasm (Fig. 65 p. 100) and may there kill and destroy them (Fig. 105). This mode of destruction of micro-organisms, largely by leucocytes, but also by other mesodermal cells, which when thus engaged are called phagocytes (see p. 99), plays a most important part in the establishment of immunity. On the other hand, certain ingredients of the body fluids, formerly called *alexins* or "defensive proteids," acting outside of cells, have been shown to possess marked germicidal

¹ For a study of the theories of natural immunity see Müller, "Infection u. Immunität," 1904. For a study with bibl. of the protective processes in natural immunity, see Kisskalt, Zeits. f. Hyg. u. Infkr., Bd. xlv., p. 1, and *ibid.*, xlvii., p. 243, 1904. For a study of inherited immunity see Kleine and Möllers, Zeits. f. Hygiene, etc., Bd. lv., p. 179, 1906.

powers. While thus it might appear that two fairly distinct agencies are of importance in enabling the body to resist the incursions of pathogenic germs—cellular or “phagocytic,” and what may be called “humoral” or chemical—it is obvious that ultimately whatever destructive power the body possesses toward micro-organisms must be due, directly or indirectly, to cell activities. This phase of immunity has been characterized as *anti-microbial*, *anti-bacterial*, or *bacteriolytic immunity*, because it is a mode of protection in which bacteria are destroyed or their growth in the body is limited or prevented.

Not less important is another phase of immunity—*antitoxic immunity*—by which the body protects itself against the toxic substances through which, in many instances, the most serious manifestations of infection occur.

These two forms of immunity—antitoxic and anti-bacterial or bacteriolytic—will be considered in detail in a following section.

Furthermore, the microbial toxins which are set free by the micro-organisms, like other poisons, may be eliminated together with the waste products of body metabolism through the kidneys, skin, etc.

ARTIFICIAL IMMUNIZATION.

General Methods and Principles of Artificial Immunization.—It was not possible to gain a clear conception of the factors entering into the complex problems of immunity until animal experimentation had revealed a host of significant facts bearing directly upon questions which for a long time had seemed insoluble. It has been found as the result of experimental researches that artificial immunity can be secured by gradually rendering the body tolerant to the presence of the infective or toxic agencies without actually inciting the characteristic specific disease.

1. In one class of procedures artificial immunity is secured directly or indirectly through the action in the body of bacteria or other microbes or microbial poisons whose virulence has been in one way or another reduced but not rendered altogether inert; or by the action on relatively unsusceptible animals of microbes or microbial poisons of unimpaired virulence. Immunity induced in this way as the result of direct adaptation of the body cells to the new conditions is called ACTIVE IMMUNITY.

1. Active immunity to particular forms of infectious disease may be conferred by inoculation with cultures of the germ inciting the infection whose virulence has been artificially reduced—*attenuated cultures*. This reduction of virulence may be accomplished in various ways: by cultivation at temperatures above their optimum; by successive inoculations into unsusceptible animals; by prolonged artificial cultivation in the presence of oxygen; by exposure to certain inorganic chemical substances, as the diphtheria bacillus to trichlorid of iodine, anthrax to bichromate of potash, etc.; by exposure of cultures to organic extracts or products of animal or vegetable cell metabolism; by drying (hydrophobia), or by exposure to sunlight; by killing the germs by heat, using for injection emulsions of their dead bodies containing the so-called endotoxin; and in other ways.

With the virulence of the micro-organisms reduced in varying degrees in one or other of the ways just mentioned, the gradual habituation of the bodies of animals to

the presence of pathogenic germs may be pursued until cultures of full virulence are tolerated.¹

2. Active immunity may be conferred by the injection, in gradually increasing doses, of the *metabolic products of bacterial growth*, either with or without the dead bodies of the germs themselves—the bacilli of typhoid fever, for example. The primary virulence of these usually toxic products of microbic growth may be in various ways diminished, by heating, by mixing with organic extracts such as that of the thymus gland, or with an inorganic chemical substance such as trichlorid of iodine, or by small doses of the already prepared antitoxin—see below.

3. Active immunity may be secured in some cases by the inoculation of animals, which are but moderately susceptible to the species employed, with small but increasing quantities of *germs having unimpaired virulence*. Under these conditions the animal becomes less and less responsive to the germ, until finally it may display no reaction after a quantity of the virulent culture which at first would have been inevitably fatal.

Immunization in man by the direct use of dead bacteria or bacterial poisons or of virus of diminished virulence has been largely practised in typhoid fever, cholera, and hydrophobia.

In active immunity the protective material is elaborated by the immunized individual, the process requires considerable time, and the effect lasts for a considerable period.

II. *In a second class of procedures artificial immunity is secured by the direct mingling of the body fluids from an individual already immunized in some of the above ways, with those of the individual to be protected. Immunity secured in this way, in which the immunizing substance used has been elaborated by another individual, is called PASSIVE IMMUNITY.*

1. *Extracts of various organs and tissues of animals suffering from infectious disease rendered germ-free and injected into healthy animals, have been found in some cases to confer a certain degree of immunity.*

2. *The blood serum of animals naturally immune to a particular infectious disease has been found, on injection into those which are susceptible to the same disease, to impart in some cases a certain degree of insusceptibility.*

3. *The blood serum, finally, of animals which have been rendered in one way or another artificially immune to certain diseases, if introduced under proper conditions into another susceptible animal, has been found not only to confer a temporary immunity, but, if administered to an already stricken individual, to aid him in the most marked and efficient way to overcome the deleterious agencies at work.*

The use of blood serum of artificially immunized animals for this purpose is of far greater practical importance than either of the methods 1 or 2.

In passive immunity the protective material is furnished ready made, the effect is secured at once and is temporary.

Antitoxic Immunity.

It appears from a study of the results of artificial immunization, as well as of the immunity which is involved in the natural recovery from infectious disease, that one of the ways in which immunity is secured is

¹ On the contrary the virulence of a particular strain of pathogenic bacteria may be exalted by a series of "passages" through a susceptible animal. When the infection from inoculation has developed in the first animal, cultures derived from it are used to infect a second, and so on through a series of "passages."

In this way, it is assumed, the self-protective adaptations of the bacteria are made evident in the increasing potency of the toxins which they produce, the toxins being one of the important factors in virulence.

by the formation of substances in the body fluids which in some way neutralize or suspend the action of toxins—**antitoxic immunity**.

Thus in diphtheria and tetanus the antitoxic substances are largely developed, while in many other infectious diseases, such as cholera and typhoid fever, it appears to be, in part at least, through the bacteriolytic substances that protection is secured. While in many instances both of these types of protective substances may be formed during immunization, one or the other is usually preponderant.¹

The antitoxic substances are most closely related to the globulins, but beyond this their chemical nature has not been definitely ascertained.²

The effect of antitoxin in the blood in rendering harmless the toxic substances which they form apparently is accomplished, not by the destruction of the toxins, but by a chemical union of toxin with antitoxin, whereby the former is deprived of its capacity to injure cells.

The knowledge of this antitoxic immunizing action of specially endowed blood serum has been most fully developed in diphtheria and tetanus.

During the growth of the diphtheria bacillus in nutrient broth a toxic substance is developed which mingles with the broth. This is called diphtheria toxin, and subcutaneous injections of this toxin in animals—guinea-pigs, for example—prove fatal, in appropriate dosage, with symptoms and lesions similar to those caused by inoculation with the living germ. It has been found that by repeated injections of the diphtheria toxin in susceptible animals, at first with small, then with gradually increasing, doses, the animal may at length become so insusceptible to the action of the poison that many times the usually fatal dose is borne without sensible reaction. Similar immunity can be conferred in certain animals by the use of the living cultures of the diphtheria bacillus either fully virulent or with reduced virulence (see p. 163), administered at first in small doses which are gradually increased.

In whichever way immunity be conferred, it has been found that the blood of the artificially immunized animal contains a substance, or substances, called *diphtheria antitoxin*, which, on being introduced with the blood serum into other susceptible animals, may not only confer a quickly established immunity—passive immunity—but, without destroying the diphtheria germ, may protect against its toxic effects when the disease is already under way. Thus, through the artificial immunization of horses and the hypodermatic use of the serum of their blood in man, the so-called “serum therapy” has assumed a very important and beneficent rôle in the prevention and treatment of diphtheria.³

¹ The damage or destruction of bacteria by anti-bacterial, bactericidal, or bacteriolytic substances naturally limits or prevents the formation of toxic materials by the micro-organisms, although the cells of the body may be very susceptible to the action of these. So that the absence of evidence of the establishment of antitoxic immunity in an infectious disease may mean, not that the body is incapable of this, but only that no opportunity is offered for its development.

² See *Hiss and Atkinson*, *Journal of Experimental Medicine*, vol. v., p. 47, 1900.

³ The antitoxic value or power of each specimen of antitoxic serum is experimentally determined by finding the amount of the serum required to protect the test animal against the action of a definite amount of toxin of known strength. Various standards have been adopted, the value of the serum being expressed in terms of the “antitoxin unit.” For example, in the determination of antitoxin value made use of by the Department of Health of the City of New York, an antitoxin unit is the amount of antitoxic serum required to protect a guinea-pig weighing 250 grammes from death, when one hundred times

Results similar to those obtained in the study of diphtheria antitoxin have been realized in the investigations of tetanus. But the practical value of the tetanus antitoxin as a therapeutic agent is less obvious. It has been shown, further, that antitoxic sera may be developed in the body during immunization to snake venom, the poison of the spider and scorpion, vegetable poisons, such as ricin and abrin, and to other albuminous animal and vegetable materials. Thus, also, through experimental adaptation, the living body-cells may elaborate and set free into the serum substances which suspend the action of ferments, like rennet, pancreatin, fibrin ferment, etc.

Not all toxic substances, however, are capable of inciting the living body to the formation of antitoxic substances; nor are these apparently formed in such considerable amount in most of the infectious diseases, as is the case in diphtheria and tetanus.

The action of these antitoxic substances is, within certain limits, specific; that is, the antitoxin of diphtheria protects against diphtheria, that of tetanus against tetanus, etc.¹

EHRlich's "SIDE-CHAIN" HYPOTHESIS.

We have seen that a most remarkable series of facts is developed by our studies of infectious diseases illuminated by the results of animal experimentation. When the living body is invaded by a certain toxic complex organic material, not always of microbic origin, the body adapts itself to the new conditions by the elaboration of substances which protect it from the action of that poison. Each new protective substance is effective against the particular poison which induced its formation. Not only this, but if the blood serum containing these new protective substances be transferred to another individual they protect him also—passive immunity—against the special poison which called them forth in the body of the first.

How are we to conceive of this wonderful adaptive power of the living body under conditions which seem to be wholly new in the life of the individual; a power which at first appears to transcend the known capacities of the body-cells?

This singular capacity of the body-cells to develop in emergencies apparently new substances has naturally given rise to much study and to many speculations and hypotheses. The scope of this book does not permit even of enumeration of these. But it is necessary to bring forward at least in outline the so-called "side-chain" hypothesis of Ehrlich by which he strove to account for the phenomena of antitoxic immunity as exemplified with especial clearness in diphtheria and tetanus. Without his hypothesis we are to-day still practically at sea in our views of the nature of antitoxic immunity, while this remarkable capacity of the body to manufacture the greatest variety of potent specific antidotes to the most subtle and virulent poisons becomes, for the first time, comprehensible in the light of this ingenious conception. It is now several years since Ehrlich's hypothesis was enunciated, and, whatever may be its merit as a direct contribution to science, there can be no doubt that it has been, in a remarkable degree, an inspiration to the most fruitful research. It is practically impossible to follow the recent work on immunity without a knowledge of this hypothesis and familiarity with the nomenclature to which it has given rise.

the fatal dose of diphtheria toxin is mixed with the serum and the mixture injected subcutaneously into the animal. The usual dose for human administration may contain from three hundred to six thousand units.

¹ For a detailed consideration of the specificity of infectious agents see *Kolle* in *Kolle and Wassermann's "Handbuch der Mikroorganismen,"* Bd. i., p. 288.

The monograph by *Citron*, "Die Methoden der Immunodiagnostik und Immunotherapie," 1910, contains many facts of practical importance in the application of theories of immunity; while *Kraus* and *Leraditi's* "Handbuch der Technik und Methodik der Immunitätsforschung," I Enganz., 1911, furnishes a most valuable survey of the entire subject from the point of view of method.

For a summary of the results of serum therapy see *Park*, Harvey Lectures, 1905-06.

In order to comprehend the hypothesis of Ehrlich regarding the origin and nature of antitoxin, it is necessary for us to form with him a clear conception of cell assimilation.

We conceive of the cell as a mechanism for the storage of energy derived from without and for its release under definite conditions. This storage of energy is possible through the assimilation and building up by the cell of complex molecular combinations. These, owing to their instability, are readily stored into less complex and more stable combinations with the release of the stored-up energy. Thus is the life of the cell manifested.

This broad conception of the cell is a purely intellectual one, however, for the details of cell metabolism still elude the keenest scrutiny of the chemist. He cannot formulate protoplasm nor express its chemical changes by proportionate symbols.

Now, accepting this condition of affairs as for the moment inevitable, Ehrlich seeks to express his view of the character of the cell's performances in general terms, disregarding its morphological peculiarities, somewhat as follows: We may conceive of the cell as consisting of a central group of very complex molecular combinations which maintains the characteristics and special capacities of the cell as an organism under all




FIG. 106.—DIAGRAM ILLUSTRATING THE ACTION OF RECEPTORS IN THE NUTRITION OF THE CELL.
A, Portion of cell body; a, food molecule; b, c, d, receptors.

the vicissitudes of its existence. Associated with this central organic group are many and various subsidiary atom-complexes which by means of their unsatisfied affinities bring the central group into relationship with food material through those chemical combinations which in living protoplasm characterize assimilation.

These unsatisfied affinities by which assimilable material is fixed or united to the cell have been called "side chains," a term adopted from the chemist. Not to press too closely, however, the analogy between the chemical processes in lifeless substances and assimilation in living matter, these affinities or "side chains" of protoplasm are now commonly called *receptors*.

If we seek to illustrate Ehrlich's conception we shall be obliged to use graphic figures of extreme crudity. If the arc of a circle in Figure 106 represents a portion of the periphery of a cell, we may indicate the side chains or affinities or receptors by projections whose special shape shall indicate their special capacity to combine with any substance coming in contact with them under favorable conditions. Suppose in this figure we let *a* represent a nutrient molecule which is capable of combining with

the receptor *b*, belonging to the cell *A*. Through its union with *b*, and only through this, is it capable of entering into the metabolism of the cell. This molecule *a* cannot unite with the receptor *c* or *d*, but only with such receptors—to use the crude expression which our illustration requires—as it fits. Through the receptors *c* and *d* other forms of food molecules may enter into the metabolism of the cell.

Thus it is in Ehrlich's conception, which after all is only a graphic way of illustrating the preliminary phases of assimilation by living protoplasm, that the cell is capable of selecting, or "fixing," out of the host of various substances with which it comes in contact, just those and only those to which its receptors bear a definite chemical relationship.

The same thing is true of toxic as of nutrient substances. In order to be toxic to the cell they must enter into chemical combination with a suitable receptor of the cell. Then only can they lead to the forms of damage which we are here considering.¹

As the result of many studies on the nature and effects of toxins, Ehrlich is led to believe that the toxin molecule consists of two forms of affinities: one through which the chemical union with the cell is effected—called the haptophorous group; and the other—called the toxophorous group—by which the damage to the cell is brought about when once the toxin molecule is anchored to it.²

This conception may be illustrated as in Figure 107, in which the toxophorous group *a* of the toxin molecule can be effective in damaging the cell only when united to the latter by the haptophorous group *b*.

Having now conceived of the living cell as consisting of a central essential complex molecular group, brought into relationship with its food materials by means of a great number of the most varied receptors, through which, under normal conditions, assimilation is secured, let us see what may happen if toxins come in contact with living cells which are furnished with receptors capable of uniting with them.

The union of the toxin molecule with the living cell being effected, the cell is more or less damaged. If the damage be sufficient, the cell dies. But suppose the damage to be but slight, as may be the case in artificial immunization or in early stages of an infection. The cell is at least deprived of the useful offices of the receptor to which the toxin molecule is now united. This is in itself a loss to the cell, and through the regenerative impulses common to all living cells it proceeds to regenerate the lost parts, which in this case are the receptors. But as more receptors are thrown out of function by the continued action of the toxin, the necessity for compensation continues.

Now it is a fact long known to pathologists, and especially emphasized by Weigert, that the regenerative impulse is apt to be in excess of the obvious requirements and leads to overproduction of new cells, tissues, chemical substances, etc. This is what now happens to the cells, some of whose receptors have been rendered useless by combination with the toxin. New receptors are formed, more than the cell requires; so numerous may these become that many are at last cast off into the blood. Here is the point at last. *These receptors or substances, normal and useful to the body, but now formed in excess through over-compensation, and set free from the cells into the body fluids, are the antitoxin.*

¹ It is evident, from what has been said about the conditions under which substances can be toxic, that the natural immunity of one animal to a given agent which is toxic in another may be simply due to the fact that the cells of the former have no receptors with which this agent can unite, or, if this union does take place, that the cell is not thereby damaged. This consideration has an important bearing upon our conception of natural immunity.

This so-called "fixing" or "binding" of toxin to tissues may be demonstrated by mixing some of the potent tetanus toxin with fresh brain tissue of the horse or guinea-pig, whereupon the mixture, if made in suitable proportions, becomes innocuous.

² Ehrlich was led to this belief in the complex nature of the toxin molecule through the curious fact that diphtheria toxin may under a variety of conditions lose its toxicity, but still retain its capacity of neutralizing antitoxin and also of uniting with cells, and thus inducing the formation of antitoxin in the animal body. Such toxin molecules deprived of the toxophorous group are called *toxoids*.

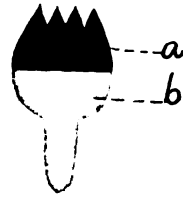


FIG. 107.—DIAGRAM ILLUSTRATING SUPPOSED CHARACTER OF THE TOXIN MOLECULE.

a, Toxophorous group;
b, haptophorous group.

For, set free in the body-fluids, these superfluous receptors still retain their combining power for the free toxin molecules, which, also, are in solution in the body-fluids, and unite with them. This union having been effected, the toxin molecules are no longer a menace to the cell, because the affinities are now satisfied through which they joined the receptors while these were still a part of the cell, and in this way became harmful. This now inert combination of toxin molecules and detached receptors is physiologically indifferent stuff, and may be removed from the body by the usual processes of excretion.

But the antitoxin which has not united with toxin in the body of the animal which produced it is still available on the transference of the serum to another in-

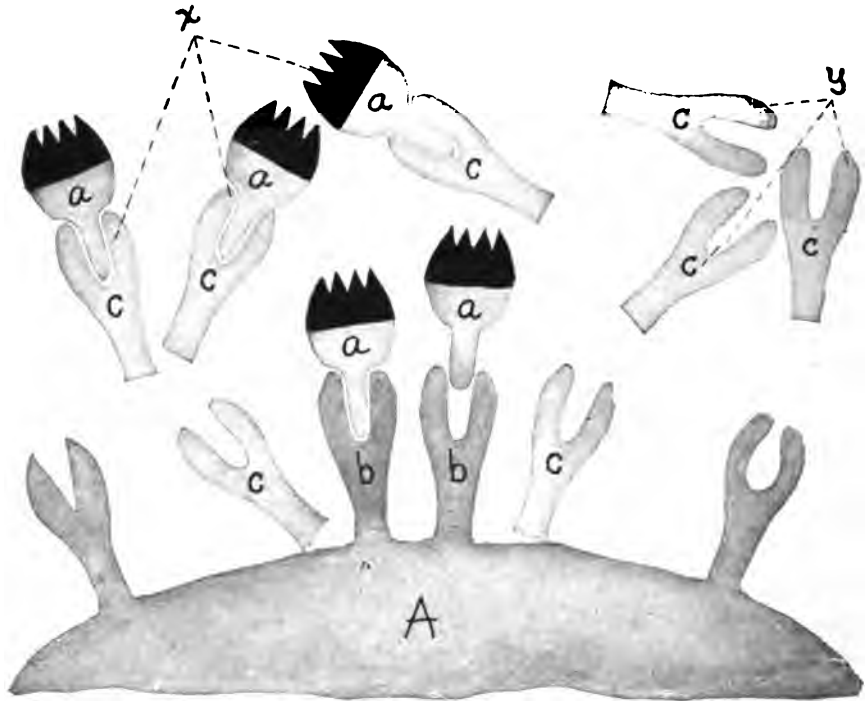


FIG. 108.—DIAGRAM ILLUSTRATING THE FORMATION AND ACTION OF ANTITOXIN IN ACCORDANCE WITH EHRLICH'S "SIDE-CHAIN" HYPOTHESIS.

A, Portion of cell-body; b, receptors combined with cell protoplasm; c, receptors separated from cell; a, toxin molecules; y, free receptors—antitoxin.

dividual whose blood contains diphtheria toxin, and who may thus secure passive immunity.

If we have recourse again to the graphic method, the hyperproduction of receptors by the damaged cell, their separation, and their action as antitoxin, may be indicated, as in Figure 108. Let A represent a portion of a cell-body. The toxic molecule a, uniting with the receptors b, leads through the injury to the cell, as well as by its deprivation of the normal use of b, to the production, and at length to the overproduction, of new receptors of the same kind. These superfluous receptors c are now set free into the body fluids,¹ where, as at x, they may freely unite with the toxin molecules, forming harmless compounds and preventing further access of the toxin to the cell,

¹ These receptors of various kinds, cast off into the body fluids under the most diverse conditions, Ehrlich has called "haptines."

where alone the damage can be done. Or, when free, as at *y*, the receptors may be transferred in the serum, becoming effective as antitoxin in another individual.

It is well to note that so long as the receptor maintains its connection with the cell it is not antitoxin, but an element of vulnerability to the cell. It is only when the receptor has been set free from the cell that it is antitoxin.

The antitoxin substance which neutralizes the action of the toxin molecule of diphtheria is not effective for the poison of tetanus, for example, simply because it does not combine with the molecule of tetanus toxin. It is specific for diphtheria, because it was the diphtheria toxin which excited its overproduction through a chemical union identical in character, whether this union takes place while the receptor is a part of the cell, in which case the toxin becomes harmful, or when the receptor is detached from the cell, in which case the combination is harmless.

In the light of this hypothesis the specific character of the antitoxic substances appears to be but the result of adaptation to unusual conditions of cell capacities evolved and fostered for the every-day maintenance of life. The specific relationship between the toxin and the antitoxin is not developed during immunization, but existed beforehand as a necessary condition of toxic action.

This hypothesis not only accounts for the formation, protective action, and specificity of antitoxin, but reveals, also, a special significance in the incubation period, during which the conservative forces are mustering. We can realize, furthermore, in the light of this hypothesis, how it is that the protection secured in active immunization is less immediate and also why it is more prolonged than in the passive, since in the latter the available antitoxin is limited to the dosage and is not replenished as in active immunity by the continued cell activities of the affected individual himself.

The conception of Ehrlich as to the nature of antitoxin is that of the chemist, and carries over to the performances of protoplasm the presumptions upon which chemical reactions in general are conceived and formulated. But this is not an easy matter, since our knowledge of the ultimate phases of protoplasmic metabolism is very incomplete. The physiological chemist presents to us as his final achievement in analysis an extremely elaborate complex which he calls the proteid molecule. This he does not yet venture to formulate. Thus it is that when we attempt to illustrate in graphic fashion our conception of the performances of proteid molecules, either in normal metabolism or in poisoning, we are forced to use the crudest of symbols. The use of such symbols is not without hazard, for these toxins and these receptors are, in truth, not histological structures, but molecular groups; they are not alone upon the surfaces, but through all the mass, of the protoplasm. They do not "break" off from the cell, but are set free as are other chemical substances which result from molecular transformations. Thus, if one cannot at last translate these uncouth symbols into the nice conceptions of the chemist, they will prove but stumbling-blocks.

There has been much discussion of Ehrlich's hypothesis, and it has withstood many assaults, mostly inspired by misconceptions of the fundamental claims. The scope of this book does not permit us to consider the many and ingenious experiments by which this view of antitoxic immunity has been sustained, nor is it practicable now to call attention to many of the phenomena not yet accounted for or seemingly inconsistent with the interpretations here set forth.

It is a working hypothesis which no doubt indicates but crudely the nature of the subtle processes concerned, as must indeed be the case while our knowledge of the phases of energy which sway and determine life is still very meagre; but it has already inspired much fruitful research which is an important feature of working hypotheses in whatever field, and whatever their ultimate fate.

Bactericidal or Antibacterial Immunity (Bacteriolytic Immunity.)

General Considerations.—An extended series of studies on artificial immunization has shown, as we have seen, that in relatively few instances, notably in diphtheria and tetanus, whose inciting bacteria set free in cultures, as in the body, soluble toxins of great potency, is the protection secured by the formation of antitoxic substances. Nevertheless, when

in some of the ways detailed above (p. 162) an animal has been gradually adapted to cultures of pathogenic bacteria either living or dead, or to their products, it has been found that the body fluids contain protective substances. The protective action in these instances in some cases has been shown to be associated with the induction of morphological changes in bacteria which indicate their damage or destruction—bacteriolysis. Active immunization in man with the dead bodies of their respective bacteria has been widely practised in typhoid fever, Asiatic cholera, and plague, with apparently favorable results, while the use of the serum of immunized animals, in these and certain other diseases, has not been thus far very encouraging in conferring passive immunity.

While, therefore, the data at hand in those artificial immunizations which are not antitoxic, point to the bactericidal and bacteriolytic action of substances developed in the body as the important, if not the dominant protective factors, there may be many other processes contributing to the same end, which are as yet not clearly defined. Thus, there may be increased phagocytosis; vulnerable body-cells may become less susceptible, the growth of bacteria may be inhibited though they be not destroyed, etc. But these possibilities cannot be discussed here.

Furthermore, it should not be forgotten that the antitoxic action of protective sera may often be associated with those agents which directly damage the infecting organism.

As regards the destruction of bacteria in the body, we have seen that this may take place directly through the action of phagocytes or by the action of the body fluids. But the details and exact nature of this destructive process have been extremely difficult of study, owing to their complexity and the minuteness of the micro-organisms. Quite recently, however, a series of remarkable studies in a related field have led to a clearer conception of the ways in which bacteria and many other alien organic substances are destroyed in the body, under ordinary circumstances as well as under the special conditions which infection involves.

“Pfeiffer Phenomenon.”—Several years ago, Pfeiffer¹ showed that the blood serum of a guinea-pig, artificially immunized against the cholera vibrio, was capable, under certain conditions, not only of immobilizing and killing cholera germs in a short time, but also of causing their disintegration and destruction. This significant capacity of immune serum was, after a long series of experiments, finally found to be due to two distinct substances. One of these appears to be formed in the body, as the result of the gradual adaptation of the animal to the cholera microbe, and was called the *immune substance*. The other seemed to be normally present in the serum of the warm-blooded animals, and to be identical with the substance which had long been regarded as in itself germicidal, and which had been called by Buchner *alexin*. It was presently found that lysis of the cholera microbe occurred only when these two substances act together, neither of them when separate having lytic power. If the two substances, the immune substance and the alexin,

¹ Zeits. f. Hygiene, Bd. xvii, p. 355, 1894.

lytic when together, are heated to 56° C., the lytic capacity is lost. But if a small amount of fresh blood serum containing alexin be now added, the lytic power is at once restored. These curious facts, set forth in part by Pfeiffer and further developed by Bordet and Metchnikoff, obviously have a significant bearing upon our conception of the processes by which those phases of immunity are secured, in which the destruction of micro-organisms plays an important part.

But the study of the effects of lytic sera upon bacteria is one of great technical difficulty, so that it is only since an important series of observations were made upon the lytic action of the body fluids on other and more easily studied forms of cells that our conception of the nature of bacteriolysis has become at all clear.

It is therefore necessary for us to look briefly at a new line of research bearing upon bacteriolytic immunity which has already led to most significant results and opened biological fields of great scope and complexity.

CYTOLYTIC SUBSTANCES—CYTOLYSIS.

Hæmolysins—Hæmotoxins.—It has been known for some time that the blood serum of one animal species, when injected into the vessels of another, may do serious damage and even kill the latter through a rapid separation of the hæmoglobin from the red blood corpuscles. This dangerous effect brought to a speedy end attempts which were at one time made to sustain the ebbing forces of life by the transfusion of alien blood. But the significance of this so-called "laking" of the blood by mixture with alien sera was overlooked.

Bordet, however, was recently led to inquire whether if the animal body be capable of adapting itself to toxic substances and to bacteria in such a way as to neutralize the effects of toxins and to destroy bacteria as had been shown by earlier experiments, it may not respond similarly to the introduction of other foreign substances such as alien red blood cells, for example.

The blood serum of the guinea-pig is not normally lytic for the red blood cells of the rabbit; that is, it does not cause the separation of the hæmoglobin from the stromata, with a partial destruction of the latter.¹ Now Bordet injected a few cubic centimetres of the whipped blood of the rabbit, containing the serum and red blood cells, into the subcutaneous tissue or peritoneal cavity of normal guinea-pigs. This operation, which does not markedly interfere with the well-being of guinea-pigs, was repeated five or six times with intervals of a few days. When now blood was drawn from the treated pig, allowed to clot, and the clear serum secured, it was found to have become markedly lytic for rabbit corpuscles. A very small proportion, mixed with rabbit's blood diluted with physiological salt solution, in a short time brought the hæmoglobin into a clear ruby solution in which the stromata or "ghosts" of the corpuscles floated as a pale and scarcely visible cloud. This process is

¹ While the serum of the guinea-pig is not normally lytic for the corpuscles of the rabbit, the serum of the rabbit is lytic for the corpuscles of the guinea-pig. Similarly, normal rabbit serum is not lytic for the beef corpuscles, but beef serum is lytic for the corpuscles of rabbits and guinea-pigs.

called *hæmolysis*; serum possessing this capacity is called *hæmolytic* or *hæmotoxic* serum.

This adaptation of one animal to the red blood cells of another species may be accomplished without difficulty with a great variety of animals.

But a most remarkable thing about this newly acquired lytic capacity of the serum is that it is limited to the red corpuscles of the species of animal whose blood was used for the injection—in Bordet's experiment to the corpuscles of the rabbit. Red blood cells of the dog, cat, sheep, bovines, fowl, etc., are no more affected by this serum of a guinea-pig which has been adapted to the blood of the rabbit than they were before. In other words, the adaptation to foreign corpuscles is specific.

The statement that this adaptation to alien blood is specific—that is to say, that the serum becomes active only for the corpuscles of the species injected—should be so qualified as to recognize the curious fact that a slight degree of lysis may often be induced in corpuscles of species of animals very closely related to those from which the injected blood is derived. For example, if a rabbit be adapted to human blood by intraperitoneal injections, the serum of this rabbit, now strongly lytic for the corpuscles of man, may be slightly lytic for the corpuscles of monkeys. Similarly, serum artificially lytic for the red cells of goats may be slightly lytic for those of sheep, but not for the corpuscles of cats, dogs, man, etc. See for technique of hæmolysis tests p. 194.

This form of test, delicate beyond anything hitherto known in physiological chemistry, may thus prove of value in defining the relationships and limitations of animal species.¹

This preliminary observation of Bordet was followed by a series of studies upon artificial hæmolysis, the results of which we can only briefly summarize. In the first place, to what is this remarkable acquired lytic capacity of the serum due? Bordet heated for half an hour to 56° C. some of the lytic serum secured by adapting the guinea-pig through subcutaneous injections to the red blood cells of the rabbit. He found that it had completely lost its new lytic power. Such serum is said to be *inactivated*. But when he now added to this inert serum a little fresh blood serum from a normal guinea-pig, which is not in itself lytic (see p. 171), the original dissolving power of the heated serum for rabbit corpuscles was at once restored—*reactivated*. The inference from this experiment is obvious. The dissolving capacity of this artificially lytic serum is due to two distinct substances. One of these, that one which results from the adaptation of the animal to the alien blood, is stable at 56° C.; the other, which is present in normal serum, is rendered inert at 56° C.; that is, it is very labile. These two substances were named early and have been often renamed. For the present we may speak of the stable substance resulting from the adaptation to the alien blood as the *immune substance* or *immune body*, and of the other, more sensitive to heat present in normal serum and not increased in the processes of immunization, as *alexin*, a name which was long ago applied by Buchner to a substance or substances in normal serum, to which its

¹ For further data on this subject see Nuttall, "Blood Immunity and Blood Relationship," 1904.

germicidal capacity, first clearly demonstrated by Nuttall, was attributed. But this alexin is now called complement for reasons given on page 177.¹

There now followed a series of important studies by Ehrlich and his associates which throw still further light upon these curious lytic agents.

Separation of Alexin and Immune Substance.—We have seen that in order to secure the immune substance free from the alexin one has only to heat the lytic serum to 56° C. for half an hour, when the alexin is destroyed. If one wishes to secure the alexin apart from the immune substance he makes use of a very curious property of the latter; namely, its capacity of uniting with the cellular element under whose influence it was elaborated. For example, if one places a small portion of the serum of a rabbit which has been adapted to beef blood in contact with beef corpuscles at a low temperature² for a few hours, he will find that the immune substance has formed so stable a combination with the corpuscles that on their separation from the fluid by centrifugation in the cold, none of the immune substance, but all of the alexin, will be left in the fluid.

That the corpuscles under these conditions actually contain the immune substance is readily shown by carefully washing them in salt solution and centrifuging them again in the cold and finally adding to them a little normal serum—containing alexin, but no immune substance—whereupon the lysis will at once take place, as shown by the red color of the fluid. This union of the immune substance with corpuscles, called “fixation” of the immune substance, is specific, occurring only with the corpuscles of the animal species used in the adaptation.

Many other points of extreme interest and significance have been revealed in these studies on artificial hæmolysis which the scope of this book does not permit us to touch upon.

Multiplicity of Immune Substances and Alexins.—The question of a multiplicity of immune substances and of alexins has been brought forward, and it seems probable, especially from the researches of Ehrlich, that in adaptation of each animal species to a single form of cell several immune bodies may be developed. It is possible, though not yet proven, that more than one alexin may be normally present in the blood serum of each animal species, and that a single immune body may be capable of uniting with several forms of alexin.³

Bacteriolysis.—It is evident that this artificial hæmolysis, secured by the adaptation of one species of animal to the red blood cells of another, is quite analogous to the process by which immunity is secured against pathogenic bacteria—those of cholera, for example, whose most obvious poisonous elements are endotoxins—and which is called *bacteriolysis*. Both are specific examples of the general process called cytolysis, meaning cell destruction. But this reaction of hæmolysis is not only one of

¹ It has been found that the hæmolytic capacity of the *normal* blood serum, which in many animals, as we have seen, is very marked for the corpuscles of alien blood, is also due to two substances which in character and action are similar to those which have been so carefully studied in the lytic sera of artificially adapted animals.

² It is necessary to reduce the temperature in this experiment in order to inhibit the action of the lytic agencies.

³ It has been shown that lecithin may act as alexin—complement—in this form of cell destruction.

extraordinary delicacy, but is easily observed under conditions quite within our control, and permitting such elaborations and variations as involve great technical difficulties when we are directly engaged with the phenomena of bacteriolysis.

Thus these studies of hæmolysis have a practical significance in their bearing upon our conceptions of bacteriolytic immunity quite apart from the interesting general biological field into which they have led the way.¹

Special Cytolysins—Cytotoxins.—The development of cytolytic capacities in the blood serum of the living animal as the result of adaptation to bacteria and to alien red blood cells being known, it was natural to extend the method to other cells. Thus it has been claimed that in the adaptation of one animal to the spermatozoa of another species by intraperitoneal injections, a serum is obtained which quickly brings to an end the movements of fresh spermatozoa of the species used—*spermolytic* serum.

Similarly, specific *leucolytic* sera have been described as procured by intraperitoneal injections of emulsions of lymph-nodes, spleen, and bone marrow. Such leucolytic sera may not only destroy the leucocytes outside of the body, but they are extremely toxic when introduced into the living species from which the tissues originated. The effects of these leucolytic—leucotoxic—sera in the body are most pronounced in the blood-forming organs. Here, as the studies of Flexner² show, a very significant impulse to new cell formation may be associated with the action of the leucotoxic sera.

Emulsions of kidney cells of one species injected into the peritoneum of another have led to the development of *nephrolytic* serum; that is, serum which on injection into the body of an animal of the same species as that furnishing the kidney cells induces noteworthy degenerative changes in the kidney. Thus, also, *hepatolytic*, *pancreolytic*, *thyreolytic*, *neurolytic*, and other analogous cytolytic substances have been described. But the earlier view of the specificity of toxic (lytic) substances developed by the injection of various body-cells—somatogenic cytotoxins—has been materially modified by later studies. Thus it has been found that in many of the earlier experiments red blood cells were injected with the special cells of liver, kidney, etc., and the hæmagglutinative sera induced thrombi which led to local necroses, confusing the results. Furthermore, it has been found by Pearce and others that even blood-free organ cells are capable of inducing hæmotoxins as well as the specific toxins. It appears, therefore, that specificity is not so much a matter of cell morphology as of molecular structure; that is, of receptors.

Thus Pearce found that the sera secured by the injection of washed liver, kidney, pancreas, and adrenal cells, all agglutinate and hæmolyze red blood cells; that some of them have no effect upon organs for which they were formerly believed to have a specific affinity; and, finally, that only the so-called nephrotoxin has a distinctly injurious effect upon the

¹ For technic of hæmolysis experiments and the adaptation of animals to alien substances see pp. 194 and 195.

² Flexner, Univ. of Penn. Med. Bull., vol. xv., 1902, p. 287; also Bunting, *ibid.*, vol. xvi., 1903, p. 200.

organ by the injection of which the alleged specific serum was derived. Pancreas and adrenal serum Pearce found to be devoid of special action in these organs, while the lesions of hepatotoxin are doubtful and may be produced by other sera.¹

So far as they have been studied, the nature of the active agents in these various cytolytic sera and their mode of action are analogous with those in hæmolytic sera. Here, as there, the action is due to two groups of substances: one, the "immune body," stable and increased by the adaptive process; the other, the alexin, occurring normally in the body, not increased in adaptation, and readily destroyed or rendered inactive by heat.

All of these last-mentioned forms of cytolytic sera require more extended study before far-reaching conclusions should be drawn from them. But it is now evident that the different functional types of cells in one animal are capable in the adaptation to the economy of another of inciting more or less definitely specific responses, as shown by the various types of cytolytic sera which are formed.

When one musters all the possible combinations in this form of adaptation and considers the probability that multiple immune bodies may develop in each instance, and that these, furthermore, may correspond to multiple alexins, the complexity of artificial cytotoxicity becomes evident.

Antigens—We have seen that the introduction into the living organism of alien proteid substances of many kinds, derived from animals or plants, some of them poisonous, many of them not, incites the formation of so-called antibodies of divers sorts. It has been found convenient to call these "antibody producers," or, more correctly, "antibody incitors," *antigens*.

Anticytolysins.—But now still another phase of this subject demands a word. These cytolytic or, as some prefer to call them, cytotoxic sera, when introduced into the living bodies of the species from which the cells inciting their formation are derived, act as toxins to which the organism responds, each after its kind, by the development of antitoxic substances. These are called *anticytolysins* or *anticytotoxins*.

Let us look at an illustration of this interesting point. The blood serum of the normal guinea-pig has, as we have seen, no lytic action on the red blood cells of the rabbit, but after the adaptation of the guinea-pig to the blood of the rabbit by repeated intraperitoneal injections, the guinea-pig serum is strongly lytic for the rabbit corpuscles in test-tubes outside the body. But this lytic serum is not less toxic when introduced into the body of the rabbit. Under these conditions the rabbit produces an antitoxin, an antihæmolytic substance, which is in solution in his serum. If a little of this antihæmolytic serum be mixed with some of the lytic serum from the adapted guinea-pig, it will be found, on the addition of rabbit corpuscles, that the lytic serum has lost its power, just as diphtheria toxin loses its harmful properties on mixture with diphtheria antitoxin. Thus may be formed a great variety of specific "anti-

¹ For further details on this subject see Pearce, Univ. of Penn. Med. Bull., xvi., p. 217, 1903; Jour. Med. Res., xii., p. 1, 1904; Jour. Exp. Med., viii., 1906.

bodies"—anticytolysins—from sera which are normally lytic or have become so through experimental adaptations.

Isolysins and Autolysins.—In view of the remarkable results of the adaptation of the body to alien cells from different animal species which we have reviewed, it was natural to ask how an animal would respond to the introduction into the recesses of his body of cells—red blood corpuscles, for example—from another individual of the same species. It was found, in fact, that under these circumstances lytic substances are sometimes, though not uniformly, developed. The possibility of the formation of *isolytic* substances was thus established. But if this be possible, why, it was asked, may not *autolytic* substances be formed by the adaptation of an animal to his own cells experimentally displaced? Such substances have, however, not been found under the experimental conditions thus far observed.¹

Still it is well known (see p. 98) that cells and tissues worn out from use, or dead as the result of injury, inflammatory exudates, etc., are constantly removed from the living body by processes apparently analogous to, if not identical with, those which can be experimentally evoked. So that autolysis in some form seems to be an important factor in the maintenance of the integrity of the body (see p. 106). Just what the agencies are under which normal living tissue cells are protected from the action of autocytolytic substances is not yet clear. But the multiplicity of known "antibodies" justifies the conjecture that such substances—anticytolytic—may be constantly formed and act as safeguards to living and useful cells (see p. 191).

The Application of Ehrlich's Hypothesis to Cytolysis.—If we now turn to the various hypotheses which have been advanced to account for the formation and action of these cytolytic substances, we find that an elaboration of Ehrlich's views as applied to antitoxin is here a source of great illumination. It is evident at once, however, that the matter is not so simple as in the case of antitoxin, because we have here two substances at work, the immune body and the alexin. Neither the immune body nor the alexin alone induces cytolysis. They must act together.

The phenomena are, in the main, accounted for if we assume that it is the alexin which, when the necessary conditions are fulfilled, exerts the destructive action upon the bacterial or animal cell. But the alexin cannot enter under ordinary conditions into direct chemical combination with the cell receptors. The union is effected only by the intervention of the substance which is increased in amount in the process of adaptation; namely, the immune body.

A long series of experiments has led to the belief that the immune body has two free atom complexes which enable it to form chemical unions. Through one of these atom complexes it unites with the cell or bacterium to be destroyed; through the other it is joined to the alexin. Then, and not until then, is the alexin so linked to the cell that its toxic or destructive action upon the cell occurs.

This conception may be illustrated, as in the case of antitoxin, by crude figures.

Here it should be remembered we are illustrating, not the production of the cytolytic substances, which we shall speak of later, but the action of them upon the cells to be destroyed.

Let *a*—Fig. 109, A—be the cell which is to be destroyed, with one of its receptors indicated at *d*. Let *b* represent the immune body with one atom complex *e* capable of uniting with the cell receptor *d*, and with another *f* capable of uniting with the alexin.

¹ Some observations are recorded in which, after profuse internal hemorrhage, hæmaturia has developed, indicating the possibility of autohæmolysis under special conditions.

c through *g*. Now the alexin which appears to be the effective agent in the destruction cannot unite directly with the cell receptor. When, however, it becomes linked to the cell by means of the immune body, *b*, its destructive capacity can come into play.

In a similar way one may indicate the action of anticytolytic substances which may be effective through union either with the alexin or with the immune body, as shown in Figure 109, *B* and *C*. In *B* the "antibody" *h* prevents the linking of the alexin *c* to the immune body *b* by itself uniting with the former. It then acts as an anti-alexin. In *C* the antibody "*i*" prevents the linking of the immune body *b* to the cell receptor *d*, and hence acts as an anti-immune body. We shall see in a moment why at present the substance here spoken of as anti-alexin is usually called the anticomplement.

The experimental evidence that the anticytolytic substances may be thus due to the formation of adaptive substances of two classes, anti-immune substances and anti-complements, cannot be entered upon here.

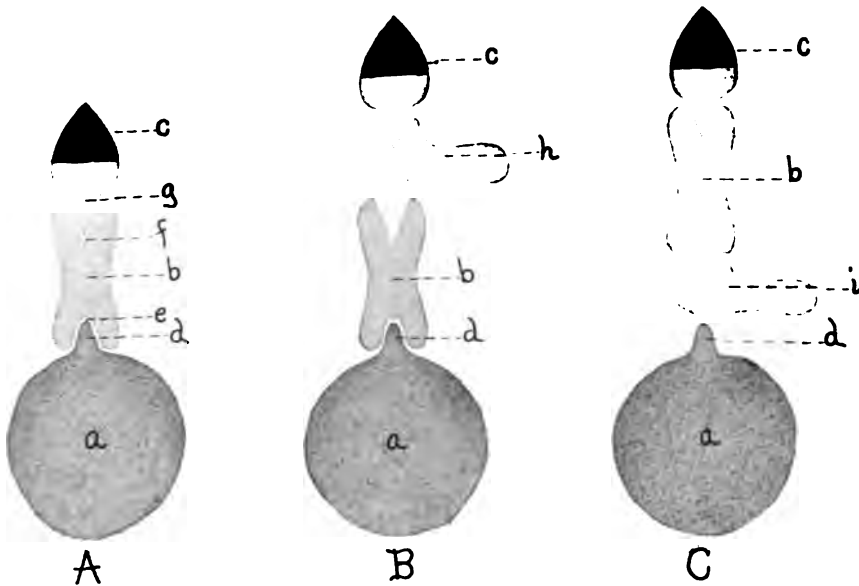


FIG. 109.—DIAGRAM ILLUSTRATING CYTOLYSIS IN ACCORDANCE WITH EHRLICH'S HYPOTHESIS.

A—*a*, Cell; *b*, immune substance (amboceptor); *c*, alexin (complement); *d*, cell receptor; *e*, atom complex of the amboceptor capable of uniting with the receptor; *f*, atom complex of the amboceptor capable of uniting with the haptophorous group, *g*, of the complement, *c*.

B—*a*, Cell; *b*, immune substance (amboceptor); *c*, alexin (complement); *d*, cell receptor; *h*, anti-alexin (anticomplement).

C—*a*, Cell; *b*, immune substance (amboceptor); *c*, alexin (complement); *d*, cell receptor; *i*, anti-immune substance (anti-amboceptor).

In view of the rationale of cytolysis, as just set forth, we may consider the immune substance to be an intermediary between the alexin and the cell to be destroyed; or, on the other hand, we may consider the alexin as the complement to the immune substance, since only through their union is the toxic action possible.

In fact, following Ehrlich, one sometimes speaks of the immune body as the *intermediary body*, or *intermediary substance*; but since it is furnished with two combining affinities, it is now usually called the *amboceptor*. Furthermore, since the experimental analysis of the lytic process by the new technique has shown that the germicidal and destructive action of blood serum, formerly supposed to be due to a single substance called alexin, is really due to the combined action of two substances, the use of the word alexin for one of them is misleading and has now been largely given up. The

substance present in the serum of both normal and adapted animals through which lysis is effected when it is linked to the cell by the amboceptor is called the *complement*. Other names have been applied to these hypothetical complexes or substances which we cannot consider here.¹

This, then, is the rationale in accordance with Ehrlich's hypothesis of the action of these cytolytic or cytotoxic substances, either existing naturally, as they do in some animals, or being called forth in larger quantities in the process of adaptation to the cells which they destroy. This view has been most fully tested upon hæmolytic sera, since here the reaction is most easily studied. But so far as one can see, it applies as well to the phenomena of bacteriolysis, whose direct study is much more difficult. It should, however, be borne in mind that the erythrocytes are very delicate and very peculiarly constituted cells, and it is possible that inferences drawn from hæmolysis are not applicable without qualification to other and less vulnerable cell types.

The origin of the amboceptors of these cytotoxic substances is accounted for in the same way as in the case of antitoxin. The alien cells or substances which are introduced into the animal, and to which it proceeds to adapt itself, lead, through union with such body-cell receptors as may be fitted to them, to the overproduction of these special complex receptors. These are presently cast off as superfluous to the body-cell producing them, and are then free as amboceptors in the body fluids.

As in the case of antitoxin formation, it is probable that the cell receptors which are thus increased are normally concerned in cell assimilation, and it is not unlikely that their complex character may have some relationship with the complexities of the "giant" protein molecules, which must suffer initial changes before becoming fit for assimilation. At any rate this hypothesis assumes that in the process of adaptation either to toxic substances or to foreign cells or other protein material, the body develops no new capacities, but only an exaggeration of those already existing.

As to the exact source of the amboceptors in artificially immunized animals we cannot yet speak with certainty.

The Action of Phagocytes in Cytolysis.—It was inevitable that the remarkable studies just summarized on cytolytic sera should have led to a clearer conception of the manner in which phagocytes destroy bacteria and other organic substances. It is no longer permissible to hold as distinct and unrelated processes the action of phagocytes and the action of the body fluids in the destruction of foreign substances in the body.

Metchnikoff, the learned and able advocate of the importance of phagocytosis in the protection of the body against micro-organisms, now recognizes the importance of the adaptive substances, some of which may be largely increased in amount in the processes of immunization. More strenuously than other observers, however, he insists upon the phagocytic cells, especially the leucocytes, as the originators of the substances concerned in cytolysis, and holds that under ordinary conditions it is only within these cells that these substances are effective. In artificially

¹ It was natural in the early studies on bacteriolysis, which were incidental to researches on immunity, that the new substance which was found in the serum as the result of the immunizing process should be called the immune substance or immune body. It was natural also, although less appropriate, to apply the same term, "immune substances," to the analogous substances which appeared in the serum as the result of the injection in the same fashion of cells and other materials which were not infectious, not disease-producing, and against which, therefore, the body is not, in the old sense, immunized.

But these new uses of the word are, I think, unfortunate because the word "immunity" has come to have a special and useful significance in relation to infection, intoxication, and other conditions of natural or acquired tolerance to obviously and seriously harmful agents. The process in both instances is, indeed, one of adaptation, and the newly acquired capacities of the serum are due to substances resulting from this adaptation. They arise from a functional modification of parts of the body, and hence may be appropriately called adaptive substances. It seems to the writer that it would be better to consider immunization as a special phase of adaptation, and so limit the application of the word that it shall still connote infection and intoxication in the traditional sense.

immunized animals, however, the intermediary substances, it is conceded by Metchnikoff, may be set free from the cells which produce them and mingle with the body fluids. The complement, on the other hand, which he, in common with others of the French school, calls *cytase*, in recognition of its ferment-like characters, Metchnikoff does not believe to be set free in the body fluids except through some damage to the leucocytes in which it is formed. Such a damage, for example, as befalls the leucocytes in the clotting of the blood; for in this process it is assumed that the setting free of the fibrin ferment involves the destruction—phagolysis—leucolysis—of the leucocytes.

The views advanced by Bordet and others of the French school regarding the union of the amboceptors with the cells to be destroyed are less precise than those of Ehrlich. Both, however, recognize the importance of an association of the amboceptor as a condition for the effective action of the complement (*cytase*). It is for this reason that the amboceptor is called by Bordet, Metchnikoff, and others, the sensitizing substance (*substance sensibilisatrice*) or the fixative (*fixateur*).

Finally, a long and ingenious series of experiments has led Metchnikoff and his associates to believe that there are two forms of *cytase*, one called *macrocytase*, formed by the macrocytes (large lymphocytes derived from the spleen, lymph-nodes, and certain endothelial and connective-tissue cells) and concerned in the destruction of animal cells, such as red blood cells, leucocytes, spermatozoa, various parenchyma cells, etc.; and *microcytase*, derived from the microcytes (polymorphonuclear leucocytes), which is active in the destruction of bacteria (see p. 104).

The greatest diversity of view concerning the cytolytic process between Metchnikoff and his followers and the observers of the Ehrlich school relates to the question whether the complement (*cytase*) does or does not exist free in the blood plasma, for upon the answer to this question depends largely our belief as to the relative significance of intra- and extracellular cytolysis. This is one of the points concerning which more data are urgently needed. But even now the views of Metchnikoff are not inconsistent with the hypothesis of Ehrlich.

There is reason to believe that bacteria are destroyed within phagocytes by the action of enzymes¹ in a manner analogous, at least, with that of their destruction in the bacteriolytic fluids which we have just considered. But just how these intracellular processes are fostered by protective sera is not clear.

AGGLUTINATIVE SUBSTANCES.

Agglutinins.—But there are important adaptive resources of the living body when called upon to deal with foreign material of special character introduced in unusual ways into its recesses in addition to those just considered.

The phenomenon of agglutination has been widely known for several

¹ See *Opie*, ref. p. 105.

years, especially on account of its practical application in diagnosis. The general fact is that as an individual adapts himself—that is, becomes immunized—to a special bacterium or its toxic products, either in the course of an infectious disease or as the result of artificial processes, his serum, if placed under suitable conditions in contact with cultures of this special micro-organism, may speedily immobilize the organism if it be motile, and, whether motile or not, lead to its clumping into irregular masses. This reaction has been used, not only as a clinical test of special infections,¹ but also as a means of differentiating species or varieties of bacteria.

GROUP AGGLUTINATION.—But the serum of an animal adapted to a particular bacterial species sometimes has the power of agglutinating closely related organisms, such, for example, as members of the colon-typhoid group.

However, the organism used for adaptation—the so-called “homologous” organism—usually agglutinates in so much greater dilutions than do the other organisms of this group—the heterologous organisms—that with due care, in spite of the group agglutination, the test is useful.

Recent studies have emphasized the fact that agglutination is a much more general phenomenon than has been commonly supposed, and is by no means limited to the sera of animals immunized against bacteria and bacterial products.

For example, in the adaptation of one animal to the red blood cells of another species, the serum of the adapted animal may become not only lytic but agglutinative also for the corpuscles used for the injections. This is true not only in adaptation to red blood corpuscles but to other cells as well. We have, then, to add agglutinative substances or agglutinins to the list of those which are developed in the body in this form of adaptation. (See Table, p. 188.) These also, within the limits already set forth, are specific.

Just as the specific red blood cells are capable of “fixing” the immune substance in lytic serum, so also the agglutinating substance may be “fixed” and removed from serum by placing in contact with the serum some of the corpuscles of the particular animal species or some of the bacteria under whose influence the agglutinative substances were formed.

While agglutinative substances are developed in the process of immunization, they are not, so far as we know, directly protective, though by the grouping of micro-organisms the action of phagocytes may be favored. The virulence of pathogenic bacteria is not reduced by agglutination.

The agglutinative seem to differ in many ways from the lytic substances. Thus their activities are not suspended by a temperature of 56° C. They become inert, however, at a higher temperature—70° to 78° C.—and their agglutinating capacity is not restored by the addition of normal serum. It is inferred from this fact that the receptors concerned in agglutination are of simpler character than those through which lysis is secured.

¹ For the general demonstrative test for agglutinin see p. 193. For details of special applications of the agglutination test see Wood's “Chemical and Microscopical Diagnosis,” or other works on clinical pathology.

The normal blood serum of some animals contains substances which are agglutinative for the red cells of other species. Thus, normal beef serum is agglutinative for the corpuscles of the cat and rabbit. This capacity of the normal serum sometimes is, sometimes is not, associated with marked lytic capacity.

The mode of action of these so-called agglutinins is not yet very clearly understood, but a great many interesting facts have been developed in the studies on the general phenomena of agglutination which we cannot mention here.

The specific character of the agglutination reaction has led to its use in determining the nature of many infections, the serum of the infected individual being used with cultures of known micro-organisms. On the other hand, the test is often useful in determining the specific character of closely related micro-organisms and their variations.¹

PRECIPITATING SUBSTANCES.

Precipitins.—There is still another way in which the body reveals adaptive alterations in the presence of foreign proteid substances. If a few cubic centimetres of the *blood-serum or exudate containing globulin* from one animal be injected into the subcutaneous tissue or peritoneal cavity of another species in repeated doses, it is found that, on adding a little of the blood serum of the adapted animal to a dilution of the fluid injected, a precipitate is formed. This reaction is also specific, save that in some instances body fluids from closely related species, such as man and monkey, fowl and pigeon, sheep and goat, horse and ass, dog and fox, may both afford a precipitate. But this precipitate is invariably much more marked in the fluid used for adaptation than in the similar fluid from the related species.

This reaction is extremely delicate, it having been possible to recognize human blood in a dilution of 1:50,000.

By the use of this test Nuttall, who has made very extensive observations, has been able to demonstrate in a most striking fashion phylogenetic relationships between animal species and groups of species, both warm and cold-blooded, which have an important bearing upon classification.²

THE PRECIPITIN TEST IN FORENSIC MEDICINE.—The use of this precipitation test has been urged in forensic medicine to reinforce the present unsatisfactory methods of distinguishing between human and other blood. For if one have a rabbit or other animal artificially adapted to human blood from which fresh serum can be secured (even the dissolved dried serum will answer), he has only to dissolve in a little salt solution a suspected blood clot, and, mixing the two, observe the result. If, under suitable conditions of dilution, cloudiness develops within a short time or if a precipitate be formed, it is claimed that the suspected material could have been derived from no other animal than man. Since, however, it has been found that the blood not only of monkeys but of some other of the lower animals may give slight precipitates under these conditions, and since other human fluids containing albuminous substances, such

¹ See for agglutination tests in classification *Park*, Jour. Inf. Dis., Suppl. No. 2, Feb., 1906, p. 1.

² See *Nuttall*, "Blood Immunity and Blood Relationship," 1904.

as saliva, pus, inflammatory exudates, etc., may also give precipitates, it is evident that the result of this test should be interpreted with great caution.¹ See technique of precipitin test, p. 194.

The *white of a hen's egg*, injected into the peritoneum of a rabbit, after a time gives rise to substances in the rabbit's serum which induce a precipitate in fresh solution of hen's egg albumen. No precipitate is produced by this serum in albumen solutions from the blood of the mammalia, and only a slight precipitate is formed in the egg albumen of related fowls, such as the duck, for example.

It has been stated that by the adaptation of the living animal to extracts of *muscle* tissue from another species, precipitating substances may be formed in the serum which are specific for the muscle used in the injection.

Milk of one animal thus introduced into the body of another gives rise to a substance in the adapted animal which causes a precipitate in the diluted milk used for injection, but not in the milk of another species, save sometimes in slight degree in milk from closely allied animals.

This reaction is also applicable to *plant albumens*. Thus, if an animal be adapted to a given species of *bacteria*, its blood-serum, on being added to the clear filtrate of the pure culture, throws down a precipitate which is in some instances light, in others voluminous. This reaction is again specific, except within the group limits of related species. Thus, as Norris has shown,² precipitating substances which are developed by the adaptation of the rabbit to the typhoid bacillus induce a slight precipitate in the culture filtrate of the colon bacillus, but not in the filtrate of *B. prodigiosus*, for example.

Numerous experiments have shown that other vegetable albumens call forth specific adaptive precipitins.

This precipitation test is so delicate that it appears possible not only to distinguish the albumens from different animal and vegetable species, but to differentiate also some at least of the various albuminous substances in the individual.

Anti-precipitin.—Finally, it is worthy of note that it has been possible, by the adaptation of a fresh animal of the appropriate species to these precipitating sera, to obtain "antibodies"; in the case of milk adaptation, for example, by the use of the so-called lacto-serum, to secure an antilacto-serum capable, when added to the test fluids, of preventing the formation of the specific precipitate.

Nature of Precipitin.—A great deal of most careful research has been devoted to the nature of the precipitating substances which the scope of this book does not permit us to touch upon. But it should be said that in their resistance to heat and in other ways the precipitating sub-

¹ For a study of the precipitation test for blood, bibliography, see *Graham-Smith*, *Jour. of Hygiene*, vol. iii., pp. 258 and 354; also *Ewing and Strauss*, *Med. News*, Nov. 7th and Nov. 14th, 1903, bibl.; also *Robin*, *N. Y. Med. Jour. and Phila. Med. Jour.*, March 5th and 12th, 1904; also *Nuttall's* book, ref. above, p. 181. For the suggestion of a new method of differentiating bloods by a hemolysis test see *Neisser and Sachs*, *Berl. klin. Wochenschr.*, 1905, p. 1388. For special details of the most recent methods, see *Uhlenhuth and Weidanz*, *Praktische Anleitung zur Ausföhrung des biologischen Eiweissdifferenzierungsverfahrens*, 1909; and *Leers*, *Die forensische Blutuntersuchung*, 1910.

² *Norris*, *Jour. of Infect. Dis.*, vol. i., p. 463, 1904.

stances appear to be more closely related to agglutinating than to lytic substances. It has been shown that the specific serum precipitates are capable of fixing complement and removing it from solutions as immune substances may be fixed and removed—red blood cells for example—by the specific elements which incite their formation, see p. 172.¹

The Adaptive Bodies not Permanent.—The effects of foreign cells and their derivatives upon whatever body cells produce the lytic, agglutinating, and precipitating substances are apparently not lasting, since if the injections be suspended they gradually disappear from the serum. The time of their disappearance, however, like that of appearance, is not regularly the same, even in the same animal.

OPSONIC SUBSTANCES—OPSONINS.

The importance of phagocytosis among the agencies protective against micro-organisms has been for some time fully recognized and many facts are known about their ingestion and intracellular destruction. But the exact processes by which this is secured and the effects of natural and artificial immunization upon phagocytosis are still obscure. It has been assumed that the protective substances in the plasma of immunized individuals stimulate the phagocytes to the ingestion and destruction of micro-organisms, and so-called *stimulins* have been the subject of much discourse. It has been claimed that through the germicidal power of the serum, bacteria are killed and are then, more readily than when living, engulfed by phagocytes. But the existence of stimulins has not been demonstrated, and it is now well known that living as well as dead germs are ingested and destroyed by phagocytes. It has been assumed by many that the promotion of phagocytosis by immune sera is due to a sensitizing substance (*substance sensibilisatrice*) which by action on either the leucocytes or the bacteria changes a negative chemotaxis into a positive.

In 1904 Wright and Douglas,² by the use of methods suggested by Leishman,³ discovered in normal human serum, and in larger amounts in the serum of persons who had been immunized to certain micro-organisms, substances which when placed in contact with the specific bacteria are capable, without inducing appreciable morphological changes, of so modifying them that they are more readily taken up by polymorphonuclear leucocytes than are the bacteria which have not been subject to this preliminary treatment (see Fig. 110). These substances Wright and Douglas called *opsonins*.⁴ Those opsonins tested by these observers were found to be rendered inert by heating for half an hour at 60° C.; but later studies of others have shown that some opsonins—the opsonin of immune sera, for example—are more thermostable, resisting temperatures above 70° C. It was shown by suitable experi-

¹ See Gay, *Centrbl. f. Bak.*, Bd. xxxix., p. 603, 1905. This capacity of precipitates to fix complement has an important bearing on the accuracy of the Wassermann and Noguchi tests, p. 278.

² Wright and Douglas, *Proc. Royal Soc.*, 1903, vol. lxxii., p. 357; also *ibid.*, 1904, vol. lxxiii., p. 128.

³ Leishman, *Brit. Med. Jour.*, 1902, vol. i., p. 73.

⁴ From the Latin *opsono*, I prepare food for.

ments that opsonins do not act upon the phagocytic cells, but only upon the bacteria.

Many studies of the serum of normal and immunized men and animals have been made by others since the announcement of Wright and Douglas. They are in general confirmatory and many new and interesting facts have been discovered relating to these protective substances—opsonins—present in the serum of normal individuals and markedly increased in the serum of those who have undergone natural or artificial immunization to special forms of bacteria.¹

Neufeld and Rimpau² found in the serum of artificially immunized animals, substances acting, not upon the phagocytic cells, but upon the bacteria in such ways as to promote their ingestion. These substances

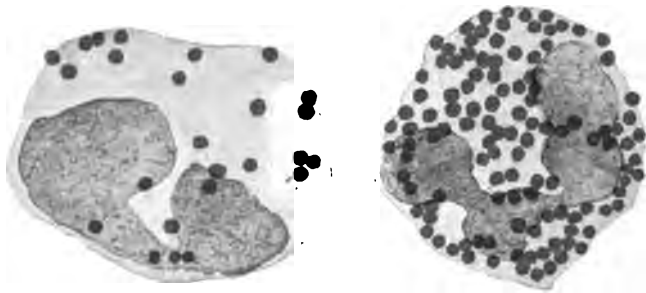


FIG. 110.—PHAGOCYTES, SHOWING THE EFFECT OF OPSONIC SUBSTANCES IN PREPARING BACTERIA FOR INGESTION BY LEUCOCYTES.

In the cell to the left the staphylococci were placed in contact with normal serum; in the cell to the right the cocci had been in contact with the serum of an animal artificially immunized to the micro-organism. The cocci thus sensitized by the opsonic substances in the serum of the immunized animal have been taken up much more abundantly than those not thus prepared.

Neufeld and Rimpau called *bacteriotropic* in distinction to bacteriolytic substances sometimes formed in immunization, but they are apparently identical with opsonins.

It has been shown by Hektoen and Ruediger³ that the opsonins in serum and plasma resemble toxins in that they apparently have toxophorous and haptophorous molecular groups (see p. 167), by which, on the one hand, they secure union with the bacteria, and, on the other, effect changes in these organisms which render them susceptible to phagocytosis.

The opsonic substances occurring normally or developing in immune serum are not alone capable of preparing bacteria for cell ingestion, but other formed elements as well, red blood cells, for example.⁴ Substances opsonic for red blood cells have been called *hæm-opsonins* or *erythrocyto-opsonins*, in distinction to the *bacterio-opsonins*. The relationship of opsonins to other immune substances—amboceptors and agglu-

¹ The substance or substances which Wright and Douglas called opsonins had apparently been previously described by Metchnikoff as *fixateurs*, of which there seem to be two forms, bacteriolytic and phagocytic; see Lohlein, Ann. Inst. Pasteur, t. xx., p. 939, 1906.

² Neufeld and Rimpau, Deut. med. Wochenschr., 1904, p. 1458; also Zeits. f. Hyg. u. Infkr., Bd. li., p. 283, 1905.

³ Hektoen, Jour. Inf. Dis., vol. iii., p. 721, 1906.

⁴ Neufeld and Topfer, Centbl. f. Bakt., Abth. I., Orig. Bd. xxxviii., p. 456, 1905.

tinins—formed in similar adaptive processes is not yet clear, but they appear to be distinct.

Phagocytosis of red blood corpuscles by endothelial and other cells in the lymph-nodes, bone marrow, spleen, etc., is common in various infections, notably in typhoid fever (see p. 239), as well as in toxic and anæmic conditions.

Hektoen¹ has found that normal serum may contain opsonins for heterologous as well as homologous erythrocytes, and that the adaptation of animals to alien blood commonly gives rise to the accumulation of hæmo-opsinins in the blood. He has shown, furthermore, that leucocytes in varying degrees may be phagocytic for opsonized red blood cells. An interesting example of spontaneous phagocytosis by leucocytes has been noted occurring after direct transfusion in a case of pernicious anæmia.²

Opsonins of immune sera appear to be specific, each uniting only with the formed elements under whose influence the special adaptation is secured. In this union—called “fixation” of the opsonin—the formed elements—bacteria or red blood cells—are said to be *sensitized*, and from a serum containing several specific opsonins each can in turn be removed by fixation to its special cells and the separation of these by centrifugalization, just as specific amboceptors may be separated from hæmolytic or bacteriolytic sera. (See p. 172.)

The nature of the alterations which bacteria and other cells undergo by their union with opsonins is not understood. The bacteria are not killed or their capacity for growth diminished by it. The opsonins of immune sera of the lower animals sensitize bacteria and erythrocytes to human leucocytes, and *vice versa*. Thus the leucocytes of animals as well as those of man may be used in the determination of the presence of opsonins in sera.

It is clear that opsonic action is of the highest importance in promoting phagocytosis. It is also evident from the numerous studies which have been made on the subject that in many instances this mode of destruction of bacteria by phagocytes is often effective under conditions in which extracellular bacteriolysis does not suffice for the protection of the infected individual.

The mere fact of phagocytosis, however, is not evidence of successful protection, since the ingested bacteria may destroy the phagocyte at once, may possibly gain in its interior by adaptation an exalted virulence, or may be transported to various parts of the body.

The virulence of bacteria has an important bearing upon the effectiveness of phagocytosis. It has been found that bacteria of high virulence are much less susceptible to phagocytosis than are the less virulent strains of the same species, both in normal and in immune sera. It would appear that virulent bacteria may be protected from phagocytosis both by their insusceptibility to opsonification and their capacity to produce substances harmful to the phagocytes.

¹ Hektoen, Jour. Inf. Dis., vol. iii., p. 434, 1906.

² Hopkins, Arch. Int. Med., 1910, vi., 270.

In the light of the new knowledge of opsonins and their relations to phagocytosis, the occurrence of leucocytosis in various infections becomes of special significance. For if either a local or general leucocytosis be fostered hand in hand with the effective production of opsonins, the conditions would appear to be most favorable for the control of the infectious processes.

Clinical Significance of Opsonins.—The determination of changes in the opsonic power of the blood serum is claimed by Wright and his followers to be of great practical importance as a guide to the administration of immunizing substances in the treatment of certain forms of infection. For a rise in the opsonic content marks, in accordance with this view, the successful development of those protective substances in the body which, by uniting with the bacteria, favor phagocytosis. If, on the other hand, after the administration of immunizing substances, the opsonic power falls, as is sometimes the case, and continues low, the indication is for a reduction or suspension of the dosage.

Remarkable curative results are recorded as the result of the administration of sterilized and standardized suspensions of the dead bodies of *Staphylococcus pyogenes aureus* in furunculosis and carbuncle, and of the tubercle bacillus in tuberculosis, especially in its local phases, as well as in other infections. But for success in these or other forms of artificial active immunization with the dead bodies of specific micro-organisms, great stress is laid by Wright on the control of the treatment by the constant observation of the opsonins. The dead bodies of cultures used in this way are called by Wright and his followers "vaccines."¹




FIG. 111.—GLASS CAPSULE FOR DRAWING A SMALL AMOUNT OF BLOOD FROM THE FINGER TIP.
As suggested by Wright.

OPSONIC POWER AND ITS DETERMINATION.—Studies of the effects of opsonins upon bacteria as marked by phagocytosis are readily made outside the body. The simplest form of observation may be made by mixing equal parts of defibrinated blood and a suspension of a bacterial culture in 0.85-per-cent. solution of sodium chlorid, keeping this for fifteen to twenty minutes at 37° C., staining smears made upon a slide, and then determining the average number of bacteria found in the polymorphonuclear leucocytes. Since, however, under these conditions, the leucocytes are too few to obtain readily the averages of a large number, it has been found desirable for most purposes to concentrate the leucocytes by the centrifuge. The blood is diluted as it is drawn with a solution of sodium citrate 1.0 per cent. in 0.85-per-cent. solution

¹ This use of the word vaccine is not altogether to be commended, since the analogy between these substances and those used in the traditional vaccination for smallpox is not close. For a summary of the methods of preparing vaccine, see *Hiss and Zinsser*, "Text-book of Bacteriology," p. 284, 1910.

of sodium chlorid. This prevents coagulation, and the performances of living leucocytes are not interfered with. This dilution can be effected by drawing blood from the finger tip into small glass capsules (Fig. 111) containing the sodium-citrate solution. This blood dilution may now be centrifugalized, and the leucocytes, which take a place above the red cells, may be drawn off by a pipette, washed with salt solution, and centrifugalized twice to remove the citrate, and then mixed with the bacterial suspensions and with the serum to be tested. This mixture is incubated for fifteen to twenty minutes; the smears are stained by the Jenner method (see p. 468).

In comparative studies it is necessary to free the leucocytes from their own serum by repeated washing in salt solution with centrifugalization, before testing their phagocytic power with bacteria exposed to an heterologous serum. Such washed leucocytes are found to be incapable of ingesting many forms of bacteria.

The determination of the opsonic power of sera in routine practice, following largely the suggestion of Wright, may be briefly outlined as follows.

This capacity of the serum is tested and measured by mixing three substances:

1. Washed living leucocytes from man, one volume.
2. A uniform suspension of a culture of the selected micro-organisms, one volume.
3. The serum whose opsonic power is to be tested, one volume.

These three substances are mixed in capillary tubes and kept for fifteen to twenty minutes at 37° C. A portion of the mixture is then smeared upon the slide and stained by the Jenner method¹ which stains both the phagocytes and the bacteria. Now under the microscope one examines the leucocytes as they come into the field, and counts the number of bacteria which each leucocyte has ingested. At least forty of these leucocytes should be examined. The average number of bacteria in the leucocytes obtained by dividing the whole number of bacteria found by the number of leucocytes examined, gives what is called the *phagocytic count*.²

OPSONIC INDEX.—If the phagocytic count obtained with the use of the serum of normal man be considered as the unit, the proportion which the phagocytic count of the special serum bears to the unit is called the *opsonic index*.

Thus, if the average number of bacteria ingested by the leucocytes after exposure to normal serum is 5, and if the average number ingested by the phagocytes after exposure to the special serum to be tested should be 4, then, reducing the figures to the basis of unity for the normal serum, the opsonic index would be 0.8.

The significance of the opsonic index in the treatment of infections and the value and mode of action of the bacterial "vaccines" are still *sub judice*. Many factors in the life and performances of the individual seem to modify the opsonic index; the variation in the number of bacteria ingested by phagocytes is so great that the validity of averages in determining the opsonic index must in each case be carefully judged. Variabilities in the characters of the leucocytes have not yet been fully investigated, so that altogether, while great theoretical and practical interest attaches to the bacteriotropic substances called opsonins, it remains for further and much more extended observation to determine their real significance³ and the practical value of the so-called "vaccines" in various infections. Finally, the importance of the opsonic index as a guide to immunization by "vaccines" has not yet been established.

¹ See p. 468.

² For the determination of the phagocyte count in opsonized tubercle bacilli the following procedure is recommended by Ross:

1. Fix smears of opsonized bacteria and leucocytes in a saturated aqueous solution of corrosive sublimate for one-half minute.
2. Rinse quickly in water.
3. Stain with Ziehl's carbolie fuchsin, heating the slide until the fluid barely steams (boiling injures the leucocytes).
4. Rinse quickly in water.
5. Decolorize quickly—a few seconds—in 2.5-per-cent. sulphuric acid.
6. Wash in five-per-cent. glacial acetic acid for one minute or less.

Counterstaining may be effected in the following solution: methylene blue, 0.5 gramme; sodium carbonate, 0.5 gramme; water, 100 c.c. Stain about one-half minute. Rinse in water.

³ For an excellent summary of phagocytosis and opsonins see *Hektoen*, Jour. Amer. Med. Assn., vol. xlv., p. 1407, 1906. For bibl. and summary of opsonins see *Potter, Diltman, and Bradley*, Jour. Amer. Med. Assn., vol. xlvii., pp. 1722 and 1793, 1906. Also see *Wright*, Studies on Immunization, 1909.

In his studies upon opsonins Wright has devised many delicate and clever technical procedures for collecting, measuring, standardizing, and mixing the various elements involved in the reactions, with which the worker in this field should make himself familiar.¹ Furthermore, much practice is required and many sources of possible error must be learned before one can be certain that his results are to be relied upon.

Although we have considered separately the development in the body of cytolytic, agglutinating, precipitating, and opsonic substances, it should be remembered that these may be and often are formed together in the same animal.

TABLE (AFTER ASCHOFF) SHOWING VARIOUS FORMS OF ADAPTATION PRODUCTS, WITH THEIR RELATIONSHIPS AND SYNONYMS.

A

The body-cells in adaptation to alien substances of protoplasmic origin may elaborate	Antitoxins, Antiferments,	Hæmolysins, Bacteriolysins— bacteriocidal substances. Special Cytotoxins: Spermatoxin, Nephrotoxin, Hepatotoxin, etc.	Formed of two substances.	Complement: Alexin, Addiment, Cytase.
	Cytolysins, (Cytotoxins),			Amboceptor: Immune body, Intermediary body, Substance Sensibilisatrice, Fixateur, Präparator, Copula, Desmon.
	Agglutinins, Precipitins, Opsonins?— <i>Fixateur?</i>			

B

The "antibodies"	Cytotoxins, Agglutinins, Precipitins,	may lead to the formation of "anti-antibodies."	Anticytotoxins, Anticomplements, Antiamboceptors (anti-immune bodies).
			Antiagglutinins, Antiprecipitins.

LEUCOCYTE EXTRACT.

We have seen that the phagocytes, particularly the polymorphonuclears are possessed of very subtle, and in the aggregate very powerful, capacities for bacterial cell destruction both in their interior, and through the substances which they may furnish to the body fluids.

It is apparent that, in the complex series of adaptations to one another in infection of the body cells on the one hand and the microorganisms on the other, the balance must often be very nice in this muster of opposing forces.

Hiss has proposed,² therefore, that the overtaxed or threatened phagocytes might be aided in an emergency if an extract of cells of their own

¹ For general technique of opsonic work see *Welker*, Jour. Med. Res., xix., p. 237, 1908.

² *Hiss*, Jour. Med. Res., xiv., 3, 1908.

kind in diffusible form such as might be secured by a sterile emulsion of dead cells were introduced into the body.

He has prepared such extracts and they have been administered both to men and to animals in divers infections with marked benefit in a large proportion of cases. Cases of cerebrospinal meningitis, lobar pneumonia, staphylococcus and streptococcus infection have been thus treated and in experimental animals the infective processes induced by the pyogenic bacteria, meningococcus, typhoid and dysentery bacilli, and others has been markedly modified.

Preparation of Leucocyte Extracts.—The exudates containing a large proportion of leucocytes are secured from rabbits by intrapleural injection of sterilized aleuronat (see p. 195). After twenty-four hours the copious exudate is withdrawn, the cells separated by the centrifuge. These cells are extracted with sterile distilled water and after careful control as to the freedom from bacteria of the final emulsion, this is introduced beneath the skin.¹

DIVERSION OF COMPLEMENT.

It has been shown that the relative proportions of amboceptors and complements present in bacteriolysis is not a matter of indifference.

Thus if one add increasing amounts of amboceptors, in the form of immune serum, to fixed volumes of bacterial emulsion and complement, *i.e.*, normal serum, it is found that, on the addition of a small amount of amboceptor, *i.e.*, immune serum, complete bacteriolysis may be secured. But if a greater amount of amboceptor be added than is necessary to secure complete lysis, the latter may fail to occur.

From such experiments it has been assumed, probably incorrectly however, that when in such mixtures amboceptors are present in considerable excess, while some of the amboceptors combine with complement, other free amboceptors may unite with the receptors of the bacterial cells more readily than the combination group of complement-amboceptor will do, and in this way the union of complement-amboceptor and cell receptor necessary for effective lysis is prevented. This has been called *diversion* or *deviation of the complement*. The phenomenon is much more probably due to the binding of the complement by other substances present in the mixture, and not to a union of the cell receptors with the excess of amboceptor.

FIXATION OF COMPLEMENT.

We have seen when considering hæmolysis (page 172), that when hæmolytic serum which contains amboceptors is heated to destroy its complement, the amboceptor, if placed in contact with the species of red blood cells to which it has been adapted, unites with them. Such blood cells are said to be "sensitized," because if now a small amount of complement in the form of fresh normal serum, "activating serum," be added, hæmolysis takes place.

Similarly when heated bacteriolytic amboceptor in the form of an immune serum is added to its homologous bacteria—antigens—the latter are sensitized and are thus capable of absorbing and using up complement if fresh normal serum be added.

This delicate hæmolytic reaction several years ago was made the basis of an ingenious method of testing for the presence of immune body by Bordet and Gengou.² The Bordet-Gengou test has been characterized as the method of *fixation of complement* for reasons which will be made clear through an example, as follows.

If one take bacteriolytic amboceptor in the form of, say, heated typhoid immune

¹ For a study of bactericidal substances in leucocyte extracts, see *Zinsser*, Jour. Med. Res., xxii., 397, 1910.

² *Bordet and Gengou*, Ann. de l'Inst. Pasteur, 1901.

serum and add to this, first, an emulsion of typhoid bacilli and, second, complement in the form of fresh normal serum, and allow these to stand for five hours, it is evident from what we have seen above that the complement, if this has been added in proper proportion, will have been all absorbed in the bacteriolytic reaction between itself, the amboceptor, and the typhoid bacilli. So that if we now add sensitized red blood cells, *i.e.*, heated hæmolytic serum and red blood cells, no hæmolysis will take place because the complement necessary for this was previously absorbed, that is "fixed," in the bacteriolytic reaction.

That this is actually the case may be shown by replacing in the above experiment the heated typhoid immune serum by heated normal serum. In this case on the addition of the sensitized red blood cells hæmolysis occurs.

This method assumes that in the activating serum the hæmolytic and bacteriolytic complement are identical at least in their combining capacities.

This "fixation of complement" has been brought more recently into practical use in testing for immune bodies in diagnosis (see Wassermann reaction), as well as in the determination of bacterial species and in the differentiation of proteins.

ANAPHYLAXIS—HYPERSENSITIVITY.

These terms are applied to a condition of extreme susceptibility which may be induced in the animal body by its adaptation to certain protein substances such as blood serum, white of egg, bacterial and vegetable proteins.

Attention was called to this condition of hypersensitivity in animals by Theobald Smith, and it was observed in man and discussed under the name of "serum-sickness," during the early days of serum therapy.¹ It is exemplified in the tuberculin and mallein reactions. But not until experimental studies were made on the subject did its great significance become evident.

The action of horse serum upon guinea-pigs has been most carefully followed.²

Briefly, it may be stated that the subcutaneous, intraperitoneal or intravenous injection of a large dose—say 5 c.c.—of an alien serum into an animal, as is frequently done in the ordinary processes of immunization, gives rise to no obvious, immediate effect upon the well being of the animal, and may again and again be repeated with impunity. But if, in the guinea-pig, the dose of 5 c.c. of horse serum be preceded ten or twelve days by a very small dose, even so little as 1/100,000 of a c.c. of the same horse serum, it will usually be found that the 5 c.c. dose will kill the animal within a few moments or a few hours. Death seems to occur as the result of a rapid intoxication. An animal in this vulnerable condition is said to be hypersensitized, and the transfer of its serum to another guinea-pig may induce in the latter a passive hypersensitiveness.

Visceral hæmorrhages in the gastro-intestinal canal, lungs, spleen, heart, etc., are found in animals which have succumbed from anaphylaxis. In cases of rapid death the lungs may be distended and do not

¹ See *Rosenau and Anderson*, U. S. Hygien. Lab. Bull., 29, 1906; also *Weaver*, Arch. Int. Med., iii., 485, 1909.

² See *Rosenau and Anderson*, U. S. Hygien. Lab. Bull., 29, 30, 36; and *Jour. of Infec. Dis.*, vol. v., p. 65, 1905; also *Sterling, Anderson and Rosenau*, *Jour. Med. Res.*, vol. xvi., p. 1, and *Gay and Southard*, *Ibid.*, p. 16, 1907.

For general summary with bibl., see *Anderson and Rosenau*, *Harvey Lectures*, 1908-9.

collapse. Auer¹ and Lewis have shown that the rapid death which occurs in highly sensitized guinea-pigs is due to asphyxia induced by a tetanic contraction of the smooth muscles of the bronchioles.

Many hypotheses have been advanced in elucidation of these singular and significant phenomena.

The studies of Vaughan and Wheeler² seem to show that this remarkable condition may be brought about through the peculiar way in which, as Vaughan has shown in a long series of studies, bacterial and other proteins may be broken up in the body.

These observers believe that there is in the animal body an enzyme, limited in amount, which breaks up alien protein into toxic and non-toxic components. Following the sensitizing injection, this molecular resolution proceeds slowly without obvious effects upon the organism. But during this gradual adaptation to the alien protein, in the interval between the sensitizing and the final injection, the protein splitting enzyme has been formed in such considerable quantity, that on the introduction of the second dose so much of the toxic component of the protein is speedily set free, that death follows.³

But while the data concerning anaphylaxis are large and increasing, it is doubtful whether any of the numerous current theories as to its nature are adequate.

The Bearing of the New Studies on Serum Therapy.—We have seen in an earlier section that the use of the blood serum of animals immunized against pathogenic micro-organisms for protective purposes in man has been of practical value in but few instances, and these mainly in cases in which the protective action was antitoxic. Protective sera for pneumonia and typhoid, streptococcus septicæmia, plague, tuberculosis, cholera, and many other infectious diseases whose chief toxic incitors seem to be endotoxins have been persistently tested and found to be for the most part of doubtful value in man.

But in the light of the new knowledge of cytolytic sera, and the conditions under which these may be effective, the promise of serum therapy, so long limited to antitoxic immunity, seems now to be more encouraging.

It is possible that the reason why the serum of an animal immunized against a given pathogenic micro-organism is not protective is that neither this serum nor the body fluids of the individual into whom it is injected for protective ends contain sufficient or suitable complements.

We have seen in our review of hæmolysis that hæmolytic serum heated to 56° C. loses its lytic power owing to the destruction of the very labile complements. We have seen, further, that this power is restored by the addition of a little fresh serum from a normal animal; that is, serum containing complement. Now it has been found that this "reactivation" of the serum, as it is called, can often be brought about by the sera of various animals. Thus, for example, the serum of the guinea-pig adapted to the erythrocytes of the rabbit is lytic for these cells of the rabbit. If such serum be heated to 56° C. it is no longer lytic, the activities of the complement are destroyed; but the serum can be reactivated by a little fresh serum, not only from a normal rabbit, but from the goat and the rat. The serum of many other animals, however, is ineffective under these conditions. The reason for this, of course, in accordance with Ehrlich's hypothesis, is that the complements of the reactivating sera have combining capacity with the special amboceptors, and so can become effective, while in other

¹ Auer and Lewis, *Journal of Exp. Med.* xii., 151, 1910.

² Vaughan and Wheeler, *Jour. Infect. Dis.*, vol. iv., p. 478, 1907.

³ For a conception of the phenomena of anaphylaxis in terms of Ehrlich's receptor hypothesis see Lewis, *Jour. Exp. Med.*, vol. x., p. 24, 1908.

sera, the linking of the complement to the red cells through the amboceptors being impossible, there can be no restoration of the lytic action.

It is not difficult to secure immune substances (amboceptors) by the adaptation of animals to various kinds of pathogenic bacteria. These may be formed in such abundance as to be out of proportion to the complements. But unless these immune substances, when injected into the body for protective purposes, either carry with them or find in the new environment an abundance and appropriate forms of complements, they are not wholly available in destroying bacteria. One of the great problems of the immediate future, then, so far as serum therapy is concerned, seems to be to secure suitable complements to act with immune substances if the former do not exist in the human fluids, or to reinforce these substances from the sera of suitable animals if the human stock be scanty. There is, however, much ground for believing that in order to be most effective the complements with which we may seek to reinforce the potency of bacteriolytic sera in man should come from species closely allied to him.

If the securing of an appropriate complement is thus of such importance in the attempt to prepare bacteriolytic sera for therapeutic purposes, the maintenance of sufficient complements in the human body must be of the utmost significance in its intrinsic protective mechanism against infection. That this consideration is not without support in fact is shown by the studies of Abbott, Longcope, and others,¹ who have found that after the continuous administration of alcohol and in various chronic as well as acute diseases, the amount of complement in the blood may be notably reduced. We have thus a definite contribution to our knowledge of one of those factors in predisposition to infection which, in a general way, are so fully recognized, but which are, for the most part, but ill-defined and little understood.

But the securing of effective bactericidal and bacteriolytic agents would not in itself be a satisfactory solution of this urgent problem in serum therapy. One can readily conceive that complete success in this respect might be an added source of danger to the victim of infection. For in case of those bacteria whose harmful effects in the body seem to arise largely through the setting free of endotoxins it is probable that if these were not at once and properly combined or otherwise cared for the wholesale destruction of the bacteria might prove a curse and not a blessing.

The Specific Character of Artificial Immunization.—It is not yet possible to say in many cases to what extent the immunization effected in any of the various ways indicated above is specific. In some cases it appears to be so. That is to say, the protection which is afforded, for example, by an attack of diphtheria or by the gradually increased administration of the diphtheria toxin, or by the use of the immunizing serum, is limited to this particular disease, and is not to be secured, at least in such marked degree, by the use of other bacteria or bacterial products. In some instances, on the other hand, immunization against one micro-organism or its toxins, or against special toxic substances, affords protection against infection or intoxication by entirely different agents. Thus animals may be immunized against anthrax by inoculation with *Bacillus pyocyaneus*.

It should be borne in mind, however much importance we may attach to the formation and action of the antitoxic substances, that these are not necessarily always present either in natural or acquired immunity to bacteria or their toxins. Tolerance to bacterial toxins may be established, as may tolerance to other kinds of poisons, without the intervention of antitoxic or other chemical agents.

The Complexity of the Processes Involved in Immunization.—It thus appears that while we know a great deal about the ability of the living

¹For a study of this subject see *Longcope, Jour. of Hygiene*, vol. iii., 1903, p. 28.

body to protect itself against the incursions of micro-organisms and the ravages of their poisons; while a field is opened for the study of artificial immunization which is of the highest promise, both for the advancement of science and for practical benefit to the victims of infectious disease; while illuminating and far-reaching hypotheses are current which account for many of the complex phenomena, we are yet very far from comprehending many of the details of the processes by which immunization is secured.

We do not know why the cells of certain animals or why different kinds of cells in the same animal are more susceptible than others to the presence of particular poisons; why, for example, the rabbit is less susceptible than man to morphine; why strychnine should affect the nerves while curare acts upon the muscles; why the common fowl should be extremely insusceptible to the tetanus toxin so powerful in many other animals. We are even ignorant as yet in most cases of either the chemical or structural changes in cells by which the deleterious action of poisons is effected. This is indeed not surprising when we reflect that the processes which are involved are of the most subtle and complex nature and that our knowledge of cell metabolism even under normal conditions is most crude and fragmentary, consisting largely in rather gross determinations of end-products and leaving out of the account the numberless molecular transformations and combinations through which the life processes of the cell are carried on.

The living body-cell is very nicely adapted to its normal environment; the living bacterium is almost equally sensitive to the conditions under which its metabolism takes place. Thus it is that, when these subtle organisms react upon each other, we are wholly unable with our present knowledge to follow the steps by which the more gross manifestations of disturbance which we call disease are reached.

But there seems to be abundant ground for the belief that the protective agencies which are evoked in both natural and artificial immunization are simply those which the body makes use of in its normal metabolism, exaggerated and diverted to different ends, it is true, in the face of emergencies and the establishment of new cell environments, but giving evidence of the birth of no new physiological capacities.¹

Technique.

Agglutination Tests.

FOR MICRO-ORGANISMS.—The serum to be tested is mixed in the proportion of 1 c.c. to 9 c.c. with 0.8-per-cent. sodium-chloride solution, making a dilution of 1 : 10, and cleared from red corpuscles, if necessary, by filtration. From this solution various

¹ The hypothesis of Ehrlich, which so closely correlates the action of toxins with the assimilation of nutrient stuff, has led to new conceptions of the details of the relationship of foods transformed by the preliminary digestive process to the material which is finally placed at the disposal of the cells. It seems not unlikely that through the action of the cell receptors the food material which arrives in the body fluids may not only be adapted to the specific uses of the cells, but that by the formation of countless varieties of substances analogous to the so-called "antibodies" of immunization, the cells are protected against equally various toxic substances. If this be true, the hope seems justified that, following the lines of research suggested by this new technique we may be able ultimately to understand more clearly the details of the so-called internal secretion and those disturbances of chemical adjustment which give rise to many important phases of auto-intoxication.

dilutions are prepared in a diminishing series, 1 : 20, 1 : 50, 1 : 100, etc. These solutions may be put into slender test-tubes, and to each is added an approximately equal quantity of a suspension in a 0.8-per-cent. NaCl solution of a twenty-four-hour-old agar culture of the micro-organism to be tested.

To secure these suspensions add 5 to 10 c.c. of the salt solution to the culture, distribute with a platinum needle, allow the larger lumps of culture to settle, and pipette off the turbid supernatant portion. This suspension of the culture in 0.8-per-cent. salt solution is now mixed with the diluted serum to obtain the requisite proportions. Thus, 1 c.c. of the 1 : 10 serum mixed with 1 c.c. of the suspension gives a 1 : 20 dilution; 1 c.c. of the 1 : 10 serum with 2 c.c. of the suspension, a 1 : 30 dilution. These suspensions of the culture in the series of tubes of diluted serum are now kept for from one to twenty-four hours at 37° C. The clumps of bacteria when agglutination has taken place may be seen by a hand glass. The clumps oftentimes sink in the tube and the fluid becomes clear. Microscopic study of agglutination is made by mixing the diluted serum and the bacterial emulsion on a cover-glass which is then inverted on a hollow glass slide and sealed with vaseline. For special and for diagnostic purposes more exact methods are required, for which see works on bacteriology or on clinical diagnosis.¹

FOR BLOOD CELLS.—A demonstration of the agglutinability of red blood cells may be made by adding to a 5-per-cent. dilution of defibrinated blood in 0.85-per-cent. salt solution, a small quantity of an aqueous emulsion of ricin. The blood cells soon clump and settle, leaving the fluid clear and colorless.

Precipitin Test.

While the precipitin or so-called biological test for human blood has been suggested and used in medico-legal cases of importance, its limitations are not yet fully determined and one should not enter upon its practical applications in cases of importance without large experience of the method and the possibilities of error.²

For demonstrative purposes, however, the technique is simple. A fragment of blood clot to be tested as to its human origin is dissolved in a small quantity of 0.5-per-cent. salt solution and passed through filter paper to secure a clear fluid. To this solution in a test-tube is added about twice the quantity of the serum of a rabbit or guinea-pig which has been injected with successive doses of human serum. This adaptive serum should have been tested with a known human serum to insure its reliability. Control tubes should be made containing mixtures of the several ingredients used without the clot solution to be tested. The tubes are now all kept for one hour at 37° C., when if the suspected clot is of human blood the tube which contains it will show a precipitate while the controls will remain clear. The characteristic precipitate should soon settle in the tubes, leaving the fluid clear.

Hæmolysis Tests.

In comparative observations on hæmolysis it is convenient to make a 5-per-cent. dilution of defibrinated blood with salt solution 0.85-per-cent. One may use narrow test-tubes, 5 mm. in diameter, putting into a series of these 1 c.c. of the diluted blood, adding to each the serum or other hæmolytic agent to be tested, and filling up with salt solution to, say, 2 or 2.5 c.c. The tubes are shaken and placed for an hour at 37° C., then in an icebox. A control tube of the blood in simple isotonic salt solution 0.85-per-cent. should accompany each series.

Following the suggestion of Wright, tests for hæmolysis may be made in capillary tubes, each long tube containing several tests or dilutions by the intervention of a bubble of air between each segment of the mixed test fluid and diluted blood.

¹ *Hiss and Zinsser*, "Text-book of Bacteriology," 1910, or *Wood*, "Chemical and Microscopical Diagnosis," 1909.

² For technical and other details of the precipitin test, see *Uhlenhuth and Weidanz*, *Praktische Anleitung zur Ausführung des biologischen Eiweissdifferenzierungsverfahrens*, 1909; *Leers*, *Die forensische Blutuntersuchung*, 1910.

To Secure Sterile Inflammatory Exudate Containing Leucocytes and other Living cells.

It has been found that the injection of wheat gluten into the pleural cavity of rabbits or dogs induces an exudative inflammation, the exudate usually containing, at the end of twenty-four hours, many living leucocytes. Leucocytes secured in this way have been largely used in determining the chemical character of their cytoplasm, as well as for experiments on phagocytosis. The most convenient preparation is the so-called *aleuronat*, a mealy food preparation. A convenient method is to inject into the pleural cavity 10 c.c. of a suspension of aleuronat in starch water (aleuronat 5 grammes; starch, 1.5 grammes; water, 100 c.c.). The exudate may be removed with a capillary pipette if small quantities only are required, or the animal may be sacrificed if larger quantities of the exudate are necessary.

Polymorphonuclear leucocytes may also be secured in considerable quantity by the injection of 10 grammes of sterile bouillon into the peritoneum of the rabbit. The exudate is removed at the end of twenty-four hours.

To secure an exudate containing a preponderance of mononuclear cells one may inject into the peritoneum of the rabbit a solution containing 1 mm. of pilocarpin, the exudate to be removed at the end of twenty-four hours.

The Study of Hæmophagocytosis.

If the serum of rabbits adapted by successive injections into the peritoneum to the blood of guinea-pigs be injected into the peritoneal cavity of guinea-pigs, after a time the peritoneal fluid as well as the spleen and other blood-forming organs are found to contain various cells which have ingested the erythrocytes. The peritoneal fluid may be secured for examination at various intervals by a capillary tube inserted into the peritoneal cavity.

Hæmophagocytosis *in vitro* may be studied by procedures similar to those employed in the study of bacteriophagocytosis. (See opsonins, p. 186.) The serum of an animal adapted to alien blood, if lytic, is deprived of this power by destroying the hæmolytic complement by heating for half an hour at 60° C. A small portion, say, 0.1 c.c. of this serum, is now mixed with an equal quantity of a 5-per-cent. suspension of washed red blood cells in 0.85-per-cent. salt solution. To this is added a small quantity of living leucocytes of man or of the guinea-pig or dog secured from citrated blood or, in animals, from fresh aleuronat exudates (see above), and the mixtures kept for an hour at 37° C. Smears are then made and stained with the Jenner or other double stain.¹

To Collect Small Samples of Serum for Agglutinative, Precipitin, or Hæmolysis Tests

The suggestions of Wright are most helpful in the technique of serum collection in small quantities. The finger is constricted by the handkerchief or a bandage, not tightly enough to stop the blood flow, but enough to induce marked congestion; and the puncture is made by a needle or a fine-pointed glass. The drop of blood as it exudes is drawn into a small capsule of the form shown in Fig. 111, held so that it will act as a siphon. When partly filled, the ends are sealed, first the larger end, then as the air here cools, the blood will be drawn back from the capillary end, when this is closed. The tube is set slightly aslant for clotting, after which the serum may be secured in capillary pipettes by breaking off the larger end of the capsule after scratching it with a file.

The Method of Adaptation of Animals to Alien Substances.

The adaptation, or immunization, as it is called, of animals to various alien substances, sera, red blood cells, etc., in order to secure lytic agglutinating and precipitating substances, is readily accomplished. For general demonstration purposes the rabbit is well suited. A simple and effective method is by intraperitoneal injection.

¹ See *Hektoen*, Jour. Inf. Dis., vol. iii., p. 434, 1906, and also Jour. Amer. Med. Assoc., vol. xlv., p. 1407, 1906.

The lower left abdominal region is shaved and disinfected with lysol. The skin is punctured with a scalpel and the slightly blunted needle of the syringe is introduced, care being taken not to puncture the intestine. Five c.c. of whipped blood or serum, warmed to body temperature, may be injected. On the withdrawal of the needle the part is dried and the opening is sealed with tincture of benzoin. There is apparently no discomfort to the animal in this procedure. The weight of the animal may fall slightly after the injection, but unless this is considerable the dose may be repeated at intervals of from five to seven days, until five or six injections have been given. The dosage in the later periods may be increased, even doubled, if the animal is in good condition. After the first three or four injections a small amount of serum may be secured for testing by opening one of the ear veins after cleansing the part. The blood may be drawn directly into a Wright capsule (see above), where it is allowed to clot, and the serum secured. If the animal is to be sacrificed to obtain a large quantity of the immune sera it may be bled into sterilized receptacles by a glass cannula tied into the carotid artery.

The above is only a rough and general description of the method of securing adaptive sera for general purposes of demonstration. For exact work one must carefully select animals, regulate and control dosage, etc. For details and many interesting data consult *Nuttall*, "Blood Immunity and Blood Relationship," 1904.

Bibliography of Recent Studies on Immunity.

For an early admirable *résumé* of immunity, consult article by *Weigert*, *Lubarsch* and *Ostertag's* "Ergebnisse" for 1897, p. 107; for a good later summary see "Infection and Immunity" by *Müller*, 1904, also *Rickett's* "Infection, Immunity, and Serum Therapy," 1906. Consult also *Metchnikoff*, "Immunity in Infectious Diseases," Transl., 1905, in which much lore is gathered and many ingenious points of view of the author are set forth. *Kolle* and *Wassermann's* "Handbuch der Mikroorganismen" contains excellent summaries of various phases of immunity; as does also in more compact form the "Experimentelle Bakteriologie" of *Kolle* and *Hetsch*, 1906.

The records of the recent researches just summarized in cytolysis and the application of Ehrlich's "side-chain" hypothesis are widely scattered through the German, French, and English technical periodicals. The most important of the studies of Ehrlich and his associates in this field are collected in the "Gesammelte Arbeiten zur Immunitätsforschung," *Ehrlich*, English Transl. by *Bolduan*, 1907, see also *Bordet*, *Studies in Immunity*, translated by *Gay*, 1909.

The summary of *Aschoff* ("Ehrlich's Seitenkettentheorie and ihre Anwendung auf die künstliche Immunisierungsprozesse," *Zeitschrift für allgemeine Physiologie*, Bd. i., Heft 3, 1902) is most complete and contains a full bibliography. The monograph of *v. Dungern* ("Die Antikörper," 1903) contains much valuable material.

In English, the Huxley Lecture by *Welch* ("Recent Studies of Immunity," reprinted in the *Medical News*, October 18th, 1902; and in *Science*, November 21st and 28th, 1902), is admirable, and deals with especial fulness with toxins and their relationship to various important pathological processes.

Ritchie's discussion of the subject (*The Journal of Hygiene*, vol. ii., Nos. 2, 3, and 4, 1902) treats in a clear and philosophical fashion the facts and hypothesis involved, and contains many valuable suggestions for further research. The excellent summary of *Ernst*, "Modern Theories of Bacterial Immunity," 1903, contains original suggestions for the graphic representation of the reactions.

See also *Nuttall's* book, "Blood Immunity and Blood Relationship," 1904; *Bolduan's* "Immune Sera," 1907, and *Hektoen's* "Résumé of Immunity," 1905.

For study of Transmission of Immunity to offspring see *Theobald Smith*, *Jour. Med. Res.* xvi., p. 359, 1907.

Hiss and *Zinsser*, "Text-book of Bacteriology," 1910, contains an admirable summary of immunity and the immunizing processes framed from the standpoint of modern biology. These authors also give compact and reliable directions for the various tests, which are but briefly outlined in the preceding pages.

CHAPTER IX.

THE INFECTIOUS DISEASES.

General Considerations.

IN the study of the infectious diseases it is especially important to bear in mind that the abnormal processes through which the disturbances incited by micro-organisms are manifested are processes of the body-cells and not processes of the micro-organisms. The micro-organisms do, indeed, incite the train of phenomena by which the disease is manifested, and the nature or "species" of the micro-organism may largely influence the character of the phenomena, but the stored-up energy which is released in this manifestation is body-cell energy and not that of microbial metabolism. The microbes are excitants of disease, but the disease is a performance of the body-cells. If these obvious considerations be held in view, it will be convenient, in considering certain of the infectious diseases, to use the familiar and much abused term "specific" as indicative of those phases of abnormal body-cell performance which are apt to occur in characteristic ways in response to special forms of microbial stimulus. Thus the poisonous substances which the tubercle bacillus builds up out of the organic material upon which it feeds are in part such as exert a peculiar influence upon connective-tissue cells, leading to their proliferation and the temporary formation of new tissue—the tubercle. This, together with associated action of the same or other metabolic products of the living bacillus, forms a group of lesions and disturbances which is characteristic of the action of the tubercle bacillus in the body. In this sense tuberculosis is a "specific" disease. On the other hand, the poisons eliminated by the tubercle bacillus may incite responses on the part of the body-cells which are practically identical with those which many other toxic substances, both of bacterial and of other origin induce—fever, degeneration, etc. These manifestations of the action of the tubercle bacillus upon the living body-cells are not "specific."

In our study of the individual infectious diseases we shall encounter many examples of this variety in the effects which pathogenic bacteria induce—the more characteristic, on the one hand, and, on the other, the more general responses which the body-cells make to deleterious agents.

Classification of the Infectious Diseases.—It is common to group diseases either from the clinical or the morphological or the etiological standpoint. But a complete rational classification of disease is not at present possible, because in very few diseases have we even an approximately complete knowledge of the symptoms, the excitants, or the morphology of the lesions.

In the infectious diseases as we now define them, the excitant is definite and in many cases known, but a classification based upon the character of the excitants alone would be, as Martius has urged, a classification of the micro-organisms and not a classification of the diseases. If every micro-organism capable of exciting disease always met in the body a similar response, the matter would be comparatively simple. But the fact that the responses of the body-cells to bacterial invasion are exceedingly varied, and that dissimilar organisms may evoke similar responses, renders a simple etiological classification even of the infectious diseases unsatisfactory, if not impracticable. Thus it is that it is convenient to consider the infectious diseases in part together, in part in connection with the special organs in which their more common and characteristic lesions are manifested. Such a classification of the infectious diseases as is here made is based in part upon similarity of lesions, in part upon the relationships of the micro-organisms concerned, and may wisely be regarded only as a convenient form of catalogue.

Groups of Bacterial Disease-Excitants.—One of the interesting results of the later studies of bacteria and their associations with the infectious diseases is the discovery that many micro-organisms which have been proved to be excitants of disease in men or in lower animals are closely related to forms which are not pathogenic. So that we now recognize many bacterial groups which we are wont to characterize by the name of the pathogenic representative. Thus there are staphylococcus and streptococcus groups of closely similar organisms, most of them harmless to man. There is the colon-bacillus group, embracing many closely related forms difficult to identify. The tubercle-bacillus group, the diphtheria-bacillus group, the actinomyces or streptothrix group, are other examples of this relationship. The more these related forms are studied, the more evident it becomes that in very slight physiological variations may lie the difference between pathogenic and non-pathogenic forms, and that equally slight variations in the susceptibility of the host may be of corresponding significance.

In the arrangement and associations of the infectious diseases considered in this section, the existence of these bacterial groups will be frequently recognized .

SUPPURATIVE AND ALLIED FORMS OF INFLAMMATION.

We have seen in an earlier part of this book that in various kinds of injury in the living tissue there may be a series of responses on the part of the body-cells which constitute or give rise to the phenomena and lesions of inflammation. One of these forms of tissue response to injury is called *suppuration* or *suppurative inflammation*.

We have seen that the characteristic feature of suppurative inflammation is the collection at or near the seat of injury of leucocytes, mostly of the polymorphonuclear type. These leucocytes, attracted through chemotaxis, emigrate from the smaller vessels and gather in the tissues. Here through their phagocytic powers they may directly or indirectly de-

stroy living micro-organisms; by lytic substances which they elaborate they may soften and remove dead tissues (see p. 103); or they may themselves succumb to the action of poisons or other local conditions inimical to their life. While, to a limited extent, a suppurative inflammation can be incited by chemical agents, such as ammonia, turpentine, etc., in most cases it is incited and sustained by micro-organisms or by poisons which these micro-organisms set free as the result of their own metabolism or by the decomposition of substances in the tissues or the tissue fluids.

Before considering in detail the characteristics of the various forms of micro-organisms which may act as excitants of suppurative inflammation, it is necessary for us to survey the various phases which this process presents under different conditions.

Phases of Suppurative Inflammation.—In the first place while the emigration, proliferation, and gathering of leucocytes are the most characteristic features in this form of inflammation, these are always associated with the accumulation of more or less fluid transudate from the blood-vessels and often with the formation of fibrin. These, the leucocytes, the serum, and the fibrin, constitute the *exudate*. Furthermore, associated with the accumulation of the exudate there may be albuminous degeneration and necrosis of cells and tissue of the affected part or of the formed elements of the exudate itself. Finally, a proliferation of the fixed cells of the affected region, connective-tissue cells, endothelium, etc., frequently accompanies the exudative phases of inflammation and may dominate the processes when regeneration and repair are under way (see p. 73).

Although the processes involved are essentially the same, it has been found convenient to attach special names to various topographic forms of suppurative inflammation, the differences depending largely upon the origin, situation, extent, and complications of the primary lesion, somewhat, however, upon the qualities, fixed or variable, of the infecting micro-organism. Thus a suppurative inflammation involving the serous surfaces and resulting in the accumulation of a purulent exudate in the serous cavities, such as the pleural and the pericardial, is called *empyema*. An exudative inflammation of the mucous membranes with a marked emigration of leucocytes from the vessels of the submucosa is called a *purulent catarrh* or *blennorrhœa*.

Pustules are superficial collections of purulent exudate in the skin.

Furuncle.—A *furuncle* is an acute, circumscribed, suppurative, and necrotic inflammation of the skin, the necrosis commonly involving a central plug or core. Furuncles are usually incited by *Staphylococcus pyogenes aureus*, rarely by *Streptococcus pyogenes*. They are common on the neck, back, buttocks, perineum, and axilla. Diabetes, marasmus, and obscure nutritional disturbances, often associated with worry and overwork, seem to predispose to this form of infection. The invasion of the staphylococcus is usually through the sebaceous glands and hair follicles. Furuncles may be experimentally induced by rubbing cultures of staphylococcus over the intact skin.

From the seat of infection the inflammation extends outward and in depth to a varying extent. The tissue becomes hard from infiltration of the tissue interstices with fluid and leucocytes, by the swelling of the stroma and connective-tissue cells (Fig. 112). The vessels are congested and the central portions become more or less necrotic, with gradual liquefaction of the tissue and the development of pus. Lymphangitis and hyperplasia of the associated lymph-nodes may accompany furuncles.

Carbuncle.—If the infection of several contiguous hair follicles, either immediately or in rapid succession, takes place, so that several centres of necrosis, with surrounding areas of exudative inflammation,

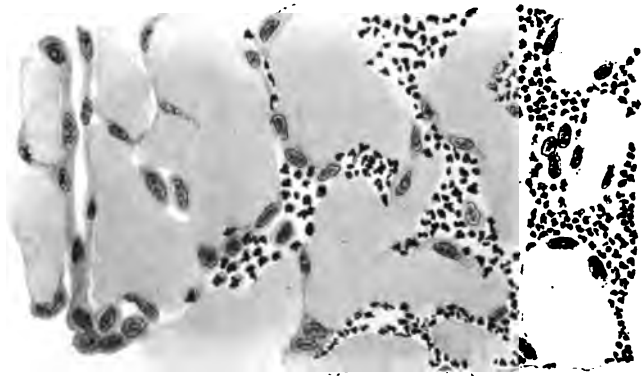


FIG. 112.—SECTION OF A BOIL—FURUNCLE. SHOWING THE RED AND SWOLLEN AREA.

On the left the connective-tissue cells are swollen and proliferated and the lymph-spaces are distended with fluid. Nearer the centre of the boil the connective-tissue spaces are infiltrated with pus and the fibrils of the stroma swollen.

merge, the resulting lesion is called *carbuncle*. The process is essentially similar to that involved in furuncle, but usually more severe and extensive. Carbuncle is common on the neck, back, and face.

A diffuse infiltration of the subcutaneous or deep fibrous tissue, muscle tendon, periosteum, or of the interstitial tissue of the viscera, with exudate, is called *phlegmon*. If in this phlegmonous inflammation there be much serous fluid associated with the cell accumulation, as is commonly the case in the earlier stages of the process, the condition is often named *purulent œdema*. When, on the other hand, there is a more or less circumscribed collection of purulent exudate in the depth of the tissues or organs, associated with necrosis and fluidification of the tissues involved, it is customary to call the result of the process an *abscess*.

In some cases of exudative inflammation, particularly those involving the serous surfaces, the exudates often occur together in the most variable proportions; they are formed under the influence of the same agents, and frequently an exudate at first simply serous in character becomes fibrinous or purulent or both together.

Pus and Pus Cells.—It will thus be seen that the exudate which is formed in suppurative inflammation varies considerably in its composition and structure. Primarily, pus consists of an albuminous fluid containing leucocytes, some mononuclears, most of them polymorphonuclears (Fig. 113). While the exudate is in the tissue and the conditions are favorable, these cells may be alive and without structural abnormalities. But often, and especially in accumulations, they present various phases of degenerations—albuminous or fatty—or of necrosis and disintegration. It is on account of their relative frequency and abundance in purulent exudates that the leucocytes are regarded *par excellence* as pus cells. But other cells, as we have seen, may be present in pus; thus in inflammation of the serous membranes, such as the peritoneum, pleura, etc., the exfoliated and proliferated mesothelial cells may furnish no small part of the cellular content of the exudate. Red blood cells, detached and young connective-tissue cells formed from the old and capable of emigration, and endothelial cells

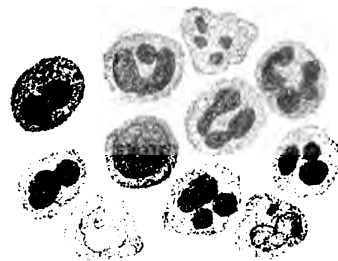


FIG. 113.—PUS CELLS IN SUPPURATIVE INFLAMMATION.

Some of the cells show the marks of necrosis and disintegration with fragmentation of the nuclei, etc.

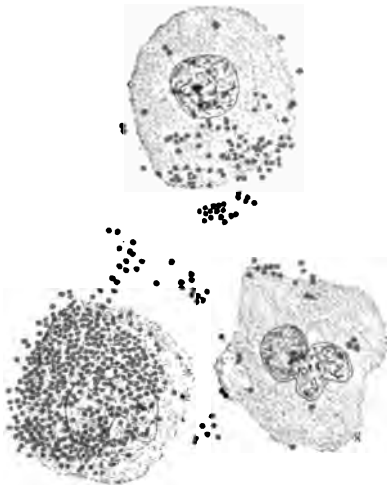


FIG. 114.—STAPHYLOCOCCUS PYOGENES AUREUS, IN AND AMONG THE PUS CELLS, FROM AN ABSCESS OF THE KIDNEY.

may be present in considerable number. In inflammation of the mucous membranes, also, the epithelial cells, either new-formed or simply exfoliated, may be abundant. Furthermore, pus may contain a variety of chemical substances and formed elements depending upon the place of its formation or accumulation. Thus mucus, fibrin, cell and tissue detritus, fat, and microorganisms may be intermingled with the pus cells.

Ulcers—in whatever way originating (see p. 58)—may be the seat of suppuration, the exudate passing off upon the free surfaces.

The bacteria which are found in the various phases of suppurative inflammation may lie free in the interstices of the tissue with the exudate, or they may be in part within the cells which have gathered about them (Fig. 114).

Both within and without the cells the bacteria may present those structural alterations which denote their death and degeneration in the struggle for existence to which the two forms of living beings, the microbes and the body-cells, are subjected under the conditions which

mark infection. The local and systemic reaction, on the other hand, and the cell necrosis which so frequently follows the growth of microbes in the body are expressions of an unfavorable environment to which the body-cells as individuals and the body as a composite organism are subjected, and to which they may successfully react or under unfavorable conditions may succumb.¹

In the softening of tissue involved in the development of abscesses, as well as in the removal of exudates by absorption it is probable that the solution of the formed elements of the tissues is accomplished by the development of lytic—autolytic—substances (see p. 106).²

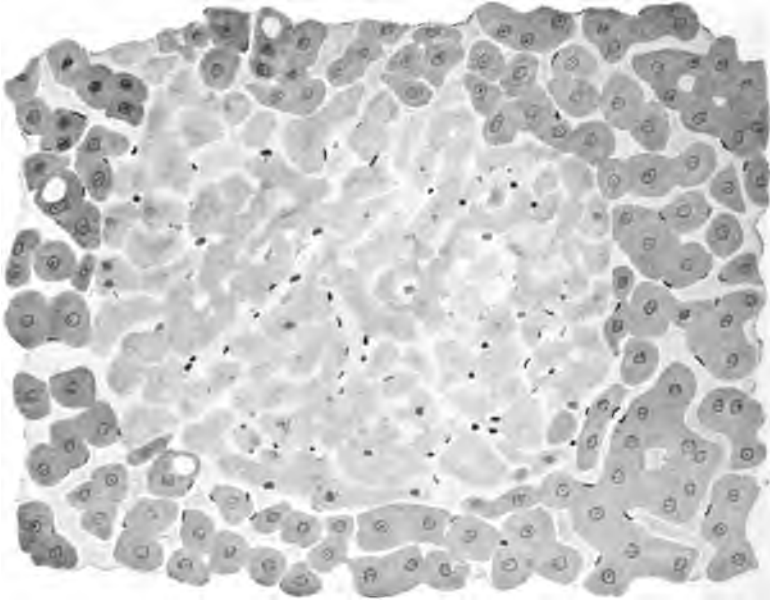


FIG. 115.—FOCAL NECROSIS IN THE LIVER IN PNEUMONIA.
Showing the local effect of a toxin circulating in the blood in *toxæmia*.

Toxæmia.—While the various forms of exudative inflammation are more or less circumscribed, the soluble toxins which are formed at the seat of local bacterial growth may, without the dispersion of the germs themselves, be diffused through the blood and the other fluids of the body, giving rise to the symptoms and lesions of *toxæmia*—fever (see p. 440) and various other forms of functional disturbance, albuminous degeneration of the viscera, focal necroses, petechial hæmorrhages, hæmolytic,³ thrombosis, leucocytosis, chromatolysis of the ganglion cells, etc.

Of these alterations in the body, which are of frequent occurrence in many forms of *toxæmia*, whether induced by bacterial or other kinds of

¹ For an exhaustive review of suppurative inflammation from the modern standpoint, with bibliography, consult *Janowski, Ziegler's "Beiträge zur path. Anatomie,"* etc., Bd. xv., p. 128, 1894.

² For a fuller reference to removal of exudates by autolysis see p. 106.

³ For a summary of facts relating to the hæmolytic power of various species of bacteria see *Pribram,* foot-note, p. 206.

poisons,¹ the only ones which demand special notice here are the *focal necroses*. These usually small, often sharply circumscribed areas of dead tissue² may be present in any of the viscera, but are often most abundant and conspicuous in the liver (Fig. 115). They vary considerably in appearance, depending upon the stage of the tissue involvement. The cells in the affected area may be swollen, the cytoplasm more transparent than normal, while the nuclei may remain unstained with the usual dyes or show various phases of fragmentation or disintegration; or they may disappear altogether. Again, the cells in the involved areas may become more coarsely granular than is normal, may undergo a change similar to that seen in coagulation necrosis, and with destruction of the nucleus may form deeply staining, irregular clumps or masses, or may disintegrate.

Associated with or following these changes there may be a gathering of leucocytes about and within these necrotic areas, so that the foci may present the appearance of little abscesses or masses of lymphoid tissue. Finally, these necrotic areas may undergo repair and be replaced by small, spheroidal, young connective-tissue cells, granulation tissue, or finally by small masses of cicatricial tissue.³

Septicæmia and Pyæmia.—Bacteria as well as their toxins may be distributed from a local portal of entry or an infected region throughout the body, not only inciting general functional and structural changes, but, when the bacteria lodge in various situations, giving rise by new local proliferation to fresh foci of inflammation.

It is customary to designate a pathological condition in which bacteria as well as their toxins are distributed through the body by the blood- and lymph-channels, as *septicæmia*.⁴ When fresh suppurative foci develop as the result of this distribution, the condition is called *pyæmia*.

The terms *septicæmia* and *pyæmia* are survivals of a nomenclature adapted to the period before the nature of the excitants of infectious disease was definitely known. The manifestations of septicæmia were then attributed to the presence of putrid material in the blood. *Pyæmia* expressed the belief that the lesions characterizing this condition were due to the presence of pus in the blood. The term *bacteriæmia* is sometimes and more correctly used to indicate the presence of bacteria in the blood, but the old words with their new implications and limitations are still commonly employed.⁵

¹ See for effects of abrin and ricin intoxication, *Flexner*, *Journal of Exp. Med.*, vol. ii., p. 197, 1897; also *Muller*, *Ziegler's "Beiträge,"* Bd. xxvii., p. 331, 1900, bibl.

² It seems probable that this marked localization of the action of a soluble poison in the tissue fluids may be due to some local vulnerability or susceptibility induced, perhaps, by limited vascular disturbance or by nutritional defects otherwise induced. In some instances local necrotic foci may be due to agglutinative thrombi (see p. 26).

³ For a comprehensive study of focal necrosis and other associated lesions in certain forms of toxæmia consult the excellent study of *Flexner*, "The Pathology of Toxalbumin Intoxication," *Johns Hopkins Hospital Reports*, vol. vi., p. 259, 1897, bibl.

⁴ The mere presence of a moderate or even of a large number of bacteria in the blood does not of itself indicate septicæmia, since the protective mechanism of the body suffices, under usual conditions, for the disposal of such an invasion. See ref. to Subinfection, foot-note, p. 151, and to *Schwarz*, foot-note, p. 151.

⁵ It has long been known that persons who have received injuries or wounds may suffer from constitutional symptoms, among the most marked of which may be fever, and develop local or disseminated

The term *pyæmia*, as will be seen, indicates a clinical and anatomical phase of septicæmia.

The new foci of suppuration in pyæmia are called metastatic abscesses, and in distribution these may bear an obvious relationship to the seat of the primary lesion. Thus, in suppurative processes in the intestinal tract, metastatic abscesses are liable to occur in the liver. From suppurations in the skin, bones, muscles, etc., infectious emboli may be transmitted to the lungs and lead to infarction and abscess; or, passing these organs, the germs may induce multiple abscesses in the kidneys and in other viscera.

It should be remembered that the point of introduction into the body of the offending germs may be wholly concealed and not associated

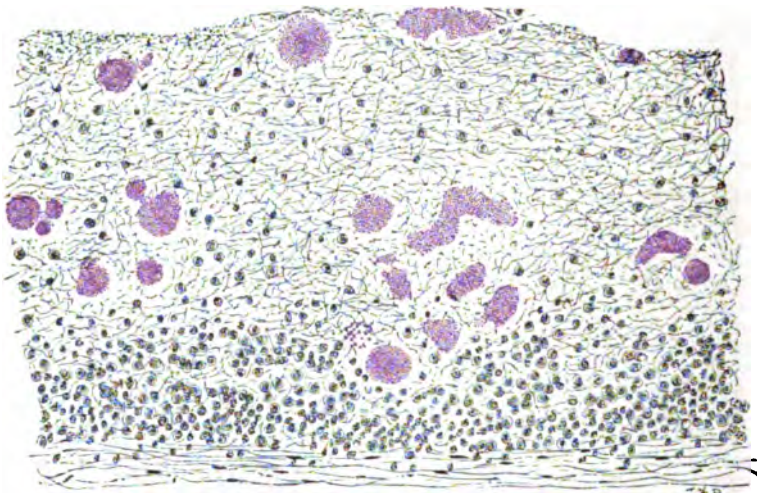


FIG. 116.—MICROCOCCHI IN MASSES IN THE FIBRINOUS EXUDATION OF PYÆMIC PLEURISY.

with any form of demonstrable external lesion. This is often called *crypto-genetic pyæmia* or *septico-pyæmia*.

After death from septicæmia and pyæmia there is a considerable variety in the post-mortem appearances.

There are cases in which there are no recognizable gross lesions.

There are cases characterized by early post-mortem decompositions; post-mortem staining of the tissues; congestion of the lungs, stomach, intestines, and kidneys; extravasations of blood in the serous membranes; swelling of the solitary and agminated lymph-nodules in the small intestine; swelling of the spleen and albuminous degeneration of the liver and kidneys; chromatolysis of the ganglion cells of the brain and cord.

There may be localized inflammations. The joints and the tissue about them, the pleura, the pericardium, the endocardium, the perito-

lesions. To designate the condition of these patients the terms *pyæmia*, *septicæmia*, *septico-pyæmia*, *pyo-septicæmia*, *ichoræmia*, *inflammatory fever*, *surgical fever*, *traumatic fever*, *suppurative fever*, *puerperal fever*, and *purulent infection* have been used.

neum, the pia mater, and the connective tissue in different parts of the body may be inflamed. These local inflammations are usually purulent, except in the serous membranes, where the principal inflammatory product may be fibrin (Fig. 116). The veins in the neighborhood of the wound may contain softened, purulent thrombi, without infarctions in the viscera, while there may be inflammation of the joints and serous membranes. On the other hand, with the venous thrombosis there may be infarctions and abscesses in the viscera; local inflammations of the joints and serous membranes may be present or absent. While thrombi are often formed in the veins near the wound, they may be situated in veins at a distance, and sometimes, although infarctions and abscesses be present, no thrombus can be discovered. The veins may be distended by the thrombi or contain only small coagula. The different kinds of thrombi, and the varieties of emboli and infarctions which they produce, are described in the section on Thrombosis, p. 24. Leucocytosis usually accompanies pyæmia and septicæmia as well as the suppurative process with which they are associated. Studies of the blood in various forms of septicæmia are numerous and instructive, but we cannot consider them here.¹

Various lines of research on minute changes in cells which bacterial and other poisons may induce, justify the expectation that more and more we shall be able to associate characteristic groups of symptoms in toxæmia and septicæmia for which there is now no morphological basis, with well-defined cell alterations. Among the most striking of the toxic cell lesions thus far studied in septicæmia and bacterial toxæmia are those involving the cytoplasm of the ganglion cells (see Nervous System).

THE PYOGENIC BACTERIA.

While many species of microbes are capable under favorable conditions of inciting suppuration and other forms of exudative inflammation and may, when they or their toxins are disseminated in the body, give rise to toxæmia, septicæmia, and pyæmia, there are two forms which, on account of their early discovery and their relative frequency, are commonly considered as *par excellence* "pyogenic" bacteria. These, which are called *Staphylococcus* and *Streptococcus*, we shall consider first.



FIG. 117.—STAPHYLOCOCCUS PYOGENES AUREUS.
From a beef-tea culture.

CHARACTERS OF STAPHYLOCOCCUS PYOGENES.

The *Staphylococcus pyogenes aureus* (*Micrococcus pyogenes aureus*) (Fig. 117) is a relatively small coccus, the individuals varying, however, considerably in size (0.4 to 1.2 μ in diameter). In its growth it does not show a characteristic grouping, but grows in irregular masses and heaps (the somewhat crude resemblance, when studied under a cover-glass, to a bunch of grapes gave rise to the generic name); sometimes,

¹ Consult White, Jour. of Exp. Med., vol. iv., p. 425, 1899; also Adami, Jour. of the Am. Med. Assn., Dec. 16th and 23d, 1899. Both have bibliography. See also Kolle and Wassermann, "Mikroorganismen."

however, pairs and groups of four or short rows of the cocci are seen. The germ is readily stained by the anilin dyes, and does not lose its color in Gram's method of staining. It does not show spontaneous movement, and, like other spheroidal forms, does not appear to develop spores. It is quite tenacious of vitality, surviving long drying and degrees of heat and cold and an exposure to chemical bactericides to which many pathogenic germs readily succumb. It grows well at ordinary room temperature in such artificial culture media as nutrient-gelatin, agar, beef-tea, and milk, and on potatoes, forming somewhat voluminous masses of culture. It rapidly fluidifies gelatin through the formation of a ferment, it coagulates milk, and in the various media develops a yellowish white or a deep golden yellow color, whence its specific name, *aureus*, and its common name, "golden coccus." Its color-producing capacity is subject to wide variation. *Staphylococcus pyogenes aureus*¹ forms in old cultures a hæmolytic substance which may be demonstrated in plate cultures mixed with red blood cells (Fig. 121) or in tubes containing the washed corpuscles to which filtrates of old bouillon cultures have been added.

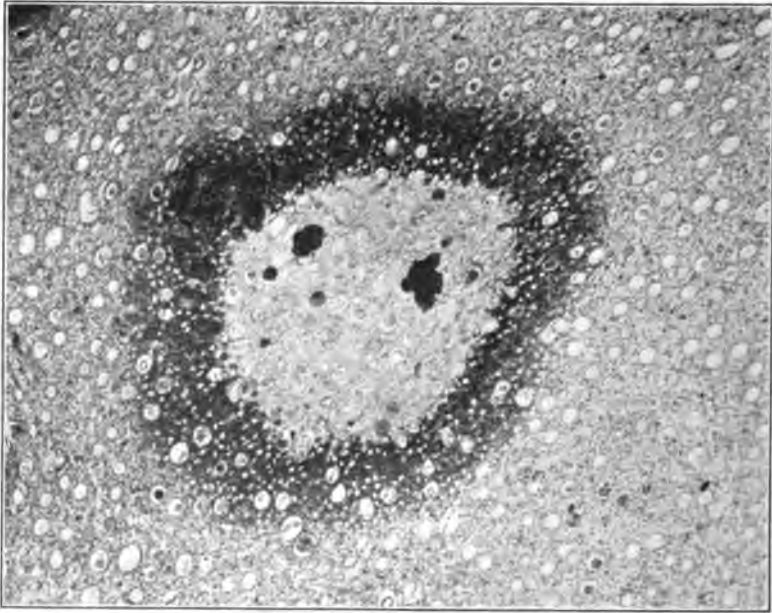


FIG. 118.—INFECTIVE EMBOLUS OF STAPHYLOCOCCUS PYOGENES AUREUS IN THE KIDNEY. RABBIT—EXPERIMENTAL.

Effects of *Staphylococcus Pyogenes* in the Body.—The virulence of cultures of *Staphylococcus pyogenes* obtained from different sources varies considerably, but, in general, suppuration is not readily induced in the lower animals by its subcutaneous injection. Liability to suppuration is greatly increased by mechanical or chemical injury to the tissues with which the germ is brought in contact. Injection of a virulent culture into the ear vein of the rabbit is usually followed by multi-

¹ For a study of the bacterial hæmolysins see *Pribram, Kolle and Wassermann, "Mikroorganismen" Ergänzungsheft, p. 291, 1906.*

ple abscesses in the kidneys and muscles, by suppuration of joints, etc. (Fig. 118).

In man this coccus grows readily and rapidly, and may induce necrosis and exudative inflammation, especially the suppurative phases (Fig. 119). The lesions which it induces are apt to be circumscribed, but it may induce septicæmia and pyæmia. It may induce pustules, boils, and abscesses, and various suppurative inflammations of the visceral and serous membranes, joints, bones, endocardium, etc. These effects may be induced by the staphylococcus alone or by it in association with other species of germs. It is frequently associated with *Streptococcus pyogenes*.

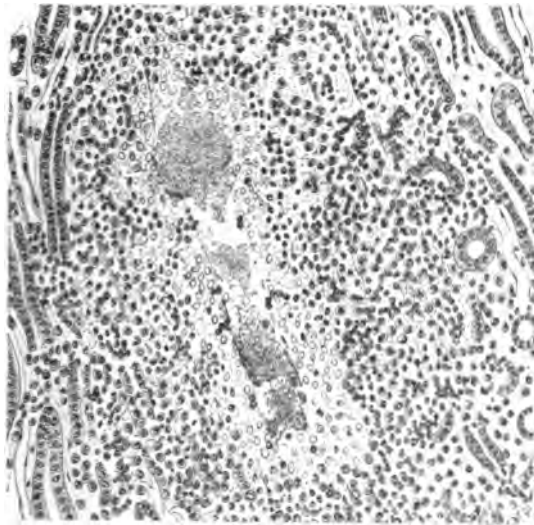


FIG. 119.—MASSES OF MICROCOCCI IN A BLOOD-VESSEL OF THE KIDNEY, INDUCING A SMALL ABSCESS. From a case of pyæmia. Around the dilated and partially necrotic blood-vessel in which the bacteria lie is an area of necrotic tissue and a small-celled infiltration or zone of pus.

Staphylococcus pyogenes aureus incites these changes in the body in virtue of certain toxins or toxalbumins which are produced as the result of its metabolism, and which are either at once set free or stored up in the body of the germs—endotoxins—until their release by disintegration after the death of the germs. The special power of the staphylococcus to cause the gathering of leucocytes is apparently due to the marked chemotaxic powers of some of the protein substances in its protoplasm. In its growth in the body staphylococcus may lead to the development of hæmolytic, agglutinative, leucocidal, leucolytic, and opsonic substances.

Portals of Entry.—It may enter the body through wounds, small or large, of the skin or mucous membranes, through sweat and sebaceous glands and hair follicles, and sometimes through uninjured surfaces.

In many cases its mode of access is not evident.¹ While usually this germ dies in the body, it may remain for a long time alive.

Sources.—It is widespread in inhabited regions, especially in towns, being frequently found on the surface of the body, and in the saliva, particularly of those with acute or chronic catarrh of the upper air passages. As the result of the filthy habit of indiscriminate public spitting and unguarded sneezing, it is common in the dust of hospitals, houses, towns, public conveyances, and places of public assembly.² It is probable, however, that the larger part of the acute staphylococcus infections are incited by organisms derived directly or indirectly from others already infected.

Susceptibility.—In man there may be a susceptibility to *Staphylococcus pyogenes* associated with a general disease, diabetes for example. On the other hand, local susceptibility in man is of frequent occurrence. In the so-called furunculosis and in carbuncle, local areas of inflammation may develop and persist for long periods, fresh foci developing as the older ones heal. In some instances this local vulnerability is apparently associated with minor local injuries, such as the friction of garments at the back of the neck or pressure and friction in the gluteal regions. Sometimes, however, the local vulnerability appears to arise from disturbances in the sebaceous and sweat glands and hair follicles, leading to stagnation of secretions in which the bacteria long persisting on the surface find lodgment and conditions favorable to their development.

The studies of Wright have indicated that in cases of carbuncle and furunculosis the opsonic index³ for the special strain of staphylococcus concerned may be low, and, further, that the raising of this by the injection of emulsions of the dead bodies of these organisms—vaccines of Wright—may lead to a rapid immunization of the individual, marked by a rise in the opsonic index of his serum and the speedy decline of the local inflammatory reaction.

Other Forms of *Staphylococcus*.

Not all the yellow staphylococci found in dust and on the person are pathogenic. These may be indistinguishable from the infective forms by the usual culture methods. They may, however, be differentiated not only by their innocuousness to animals, but in their failure to develop in these either agglutinative or leucolytic substances.

Staphylococcus pyogenes albus.—This appears to be a variety of the *Staphylococcus pyogenes* which does not develop the yellow color in cultures. It is of frequent occurrence both in connection with the aureus and alone. Its action on the body is similar, but it has seemed to many observers to be in general less virulent.

Staphylococcus epidermidis albus.—This coccus has been described by Welch as of frequent occurrence in the epidermis, and, although of rather feeble pyogenic power, yet seems frequently to cause small stitch-abscesses and moderate suppuration along drainage tubes. Welch regards it as possibly a variety of *Staphylococcus pyogenes albus*.

Other forms of staphylococcus have been described—*S. salivarius pyogenes*, *S. cereus albus* and *flavus*—but they are apparently of little pathological significance.

¹ For a résumé of the rôle of *S. pyogenes aureus* in the skin disease, with bibl., see White, Bost. Med. and Surg. Jour., vol. cxli., p. 235, 1899.

² For bibliography of *S. pyogenes aureus* consult article by Neisser and Lipstein in Kolle and Wassermann's "Handbuch der Mikroorganismen," Bd. ii., p. 105.

³ See p. 187.

CHARACTERS OF THE STREPTOCOCCUS PYOGENES.

The *Streptococcus pyogenes* (*Micrococcus pyogenes*) is distinguished morphologically from the cocci just described by the marked tendency which the individuals exhibit, when growing, to hang together in longer or shorter chains (Fig. 120). It is, like the *Staphylococcus pyogenes*, immobile, and stains easily in the same way. By a special method Hiss has demonstrated a capsule on streptococci.¹

It grows readily, but more slowly than *Staphylococcus pyogenes*, on the ordinary culture media. It does not fluidify gelatin, on which it grows as small, inconspicuous, grayish white colonies. On the surface of agar plates kept in the thermostat at 37° C. for twenty-four hours, the small grayish colonies usually show, under the microscope, loops and fringes of the chain-like cocci extending off from the borders. The growth on potatoes is inconspicuous. In nutrient broth it usually forms delicate, flocculent masses, which cling to the sides of the tubes, leaving the fluid clear. Occasionally the masses of streptococci are dense and compact. Not infrequently the growth is diffused through the nutrient broth, rendering it turbid. When in vigorous growth it coagulates milk and develops hæmolytic substances in its growth.²

The hæmolytic powers of growing streptococci may be shown by mingling red blood cells with the nutrient medium on a Petri plate culture. Under these conditions around the growing colonies a clear, colorless area in the medium is formed, which indicates the occurrence of hæmolysis in the immediate vicinity of the colonies (see Fig. 121).

There is considerable difference in the tenacity with which, in broth cultures of streptococci from different sources, the individual cocci cling together, so that in one set of cultures the chains may be very long, in another short. It has been thought by some observers that this difference is so constant as to justify special names for these growth variants of the streptococcus, and they have been called, respectively, *Streptococcus longus* and *Streptococcus brevis*. The growth in small dense masses has given rise to the name *Streptococcus conglomeratus*. It is doubtful whether these names indicate more than rather inconstant growth varieties depending upon variations in the culture media.

Effects of *Streptococcus Pyogenes* in the Body.—Streptococci which give evidence of little virulence in animal inoculation are very common in the mouths of healthy persons. The significance of these germs in healthy mouths is not yet clear.

The results of animal inoculation with the *Streptococcus pyogenes* are in general similar to those with the *Staphylococcus pyogenes aureus*. The streptococcus is very frequently associated with the staphylococcus both in its distribution outside the body, in healthy persons, and in disease. In general it may be said that the streptococcus incites those forms of suppuration and fibrino-purulent inflammation which tend to spread both locally and through metastasis.

Streptococcus pyogenes has been found either alone or in association with staphylococcus in a large number of suppurative and other inflammatory processes in various parts of the body; the condition in some cases receiving special names, in others not. Thus, in boils and carbuncles, in abscesses and phlegmons, in herpes, impetigo, and panaritium,



FIG. 120.—STREPTOCOCCUS PYOGENES.

From a broth culture.

¹ Hiss, Science, March 7th, 1902, p. 367; Jour. Exper. Med., 1901-05, vi., 317.

² For hæmolysis of streptococcus see Schlesinger, Zeit. f. Hyg. u. Infkr., Bd. xlv., 1903, p. 428.

in phlebitis and lymphangitis, in erysipelas, in suppurative inflammation of various mucous and serous membranes, especially of the throat and the gastro-intestinal canal, and of the bones and joints, in some forms of bronchitis and pneumonia, in puerperal and other forms of septicæmia, in the pustules of smallpox, one or other or both of these germs are frequently concerned.¹

One of the most important features of the relationship of *Streptococcus pyogenes* to man is the frequency with which it enters as a concur-

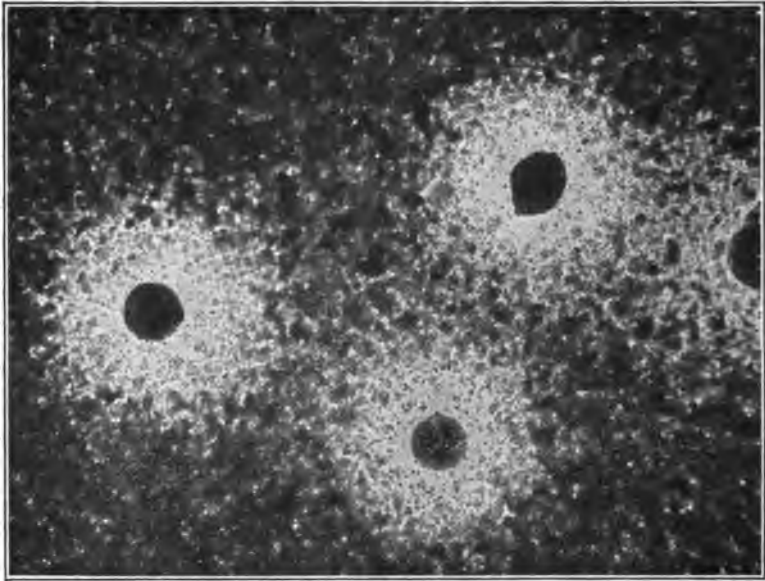


FIG. 121.—HÆMOLYSIS BY *STREPTOCOCCUS PYOGENES*.

The streptococcus was cultivated in a culture medium—gelatin—with which red blood cells were mixed. Around each colony the color has left the red blood cells and is diffused through the plate.

rent pathogenic agent in already established infectious diseases due to other forms of micro-organisms. Thus, some of the most serious complications to which the victims of scarlatina, diphtheria, typhoid fever, and pulmonary tuberculosis are liable are due to the action of the streptococcus in the body rendered unusually vulnerable by the existence of another form of infection.

The serum of individuals adapted (immunized) to streptococci may agglutinate the homologous micro-organisms.²

Streptococci, which upon their isolation from the body in suppurative or other infectious processes are very virulent, usually, and sometimes

¹ Anaërobic streptococci have been found by various observers in abscesses and other forms of suppuration of which they are apparently the excitants.

² For a study of agglutination of streptococci see Moser and v. Pirquet, *Centrbl. f. Bak., Abth. I.*, Bd. xxxiv., 1903, pp. 560 and 714; also Neufeld, *Zeitsch. f. Hyg. u. Infkr.*, Bd. xlv., 1903, p. 161; also Weaver, *Jour. of Inf. Dis.*, vol. i., 1904, p. 91.

very quickly, partially or wholly lose this virulence under artificial cultivation. On the other hand, cultures of streptococci which have largely lost virulence under artificial cultivation, or whose initial virulence was slight, may experience a great exaltation of virulence by a long succession of inoculations from animal to animal.¹

In streptococcus infections hæmolytic, agglutinating, and opsonic substances may be formed in the body.

Artificial Immunity.—The metabolic products formed by virulent streptococci growing in nutrient broth have been found to induce in animals the symptoms of toxæmia. The results of preliminary experiments on immunization with these toxic products, and the dead and living bodies of the germs and the use of the blood serum of the immune animal for therapeutic purposes, are complex, and along the present lines of work apparently not very promising. But though the antitoxic value of the so-called *streptococcus antitoxin* has not been definitely established bactericidal opsonic powers have been demonstrated.

It has been found that normal human serum has no, or but slight, streptococcidal power. The studies of Ruediger² show that in rabbits and guinea-pigs the destruction of streptococci is effected, largely at least, by phagocytes. In man also, in whom recovery from the invasion of the tissues as well as the blood is of frequent occurrence, Ruediger³ has shown that phagocytes play an important rôle, and that opsonins which are increased during the course of a streptococcus infection—erysipelas—act upon the bacteria before phagocytosis takes place.

There are several non-pathogenic forms of streptococci.

ERYSIPELAS.

Erysipelas is a diffuse inflammation of the skin and subcutaneous tissue which tends to spread, and is characterized locally by swelling of the tissue and a bright red color of the integument. It is usually accompanied by constitutional disturbances, the most marked of which is fever. The morphological changes at the seat of lesion, as we see them after death, vary considerably in different cases and in different stages of the disease. The redness of the skin usually disappears after death. But the tissues may be swollen by the accumulation of serous fluid. This fluid may be nearly transparent, or turbid from admixture with pus cells (Fig. 122). Pus cells may infiltrate the tissues either sparsely or in dense masses. Fibrin may be present, abscesses may form. Sometimes vesicles or scabs are found on the surface, or the affected region may become gangrenous. Aside from the local lesions, there may be toxæmia marked by petechiæ in the serous membranes, swelling of the spleen, focal necroses, and albuminous degeneration in the kidneys and liver.

¹ For bibliography of streptococcus consult the article by v. Lingelsheim, in Kolle and Wassermann's "Handbuch der Mikroorganismen," Bd. iii., p. 303; for a study of the action of streptococcus toxin on various parts of the body see *Homén* and others, Ziegler's "Beiträge," Bd. xxv., 1899.

² Ruediger, Jour. Amer. Med. Assn., vol. xlv., p. 198, 1905.

³ Ruediger, Jour. Inf. Dis., vol. iii., p. 156, 1906.

The most common excitant of erysipelas is *Streptococcus pyogenes*.¹ This organism may be present in large numbers in the lymph-vessels, especially in the borders of the inflamed region. The reasons for the clinical peculiarities of this phase of inflammation are not yet very clear.

INFECTIOUS PSEUDO-MEMBRANOUS INFLAMMATION OF MUCOUS MEMBRANES. (Pseudo-Diphtheria; Diphtheroid Angina; Membranous Angina.)

Under a variety of conditions, as during scarlatina and measles, whooping-cough, typhoid fever, etc., or entirely apart from any complicating disorder, an acute exudative inflammation of the mucous mem-

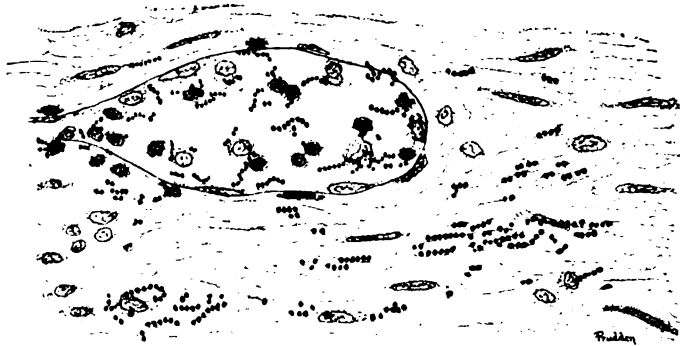

FIG. 122.—ERYSIPELAS OF THE SKIN.
Showing streptococci in the lymph-spaces.

branes, especially of the upper air passages, occurs, which is associated with and is apparently induced by the growth of *Streptococcus pyogenes*.² There may be much or little fibrinous exudate; there may in early stages, or even throughout, be none at all. The pellicle when formed may be loose or adherent, sharply circumscribed or tending to spread. The submucous tissue may show little change, or may be congested and œdematous, or may be the seat of suppurative inflammation (see Fig. 123), necrosis, or gangrene. The process may be confined to the tonsils. While under these varying conditions the inflammatory process is usually a local one and runs its course with or without the symptoms of septicaemia, occasionally the streptococcus which enters the blood may induce the lesions of pyæmia. On the other hand, it may by aspiration gain access to the lungs and induce varying phases of complicating bronchopneumonia. The *Staphylococcus pyogenes* is not infrequently associated with the streptococcus in these lesions, but is not apparently of primary significance.

Simulating very closely, as it does in many cases, both the local and

¹ In the early days of modern bacteriology the "chain" coccus which was discovered in the exudate of erysipelas was thought to bear a peculiar relationship to this clinical form of phlegmonous inflammation and was called by *Fehleisen* *Streptococcus erysipelatis*, but it has now been definitely identified with the *S. pyogenes*.

² *Prudden*, *Med. Record*, 1891; *Baginsky*, *D. Med. Zeits.*, 1900.

general phenomena of diphtheria, this disorder has formerly been confounded with it, and has only recently been recognized as a distinct phase of disease. It is now most frequently called pseudo-diphtheria. It seems in part to cover the condition formerly known as croup, in part those cases formerly thought to be mild diphtheria. In many phases of acute angina, and in many cases of follicular tonsillitis, streptococci




FIG. 123.—PSEUDO-MEMBRANOUS INFLAMMATION OF TRACHEA.

In this case there is purulent infiltration of the mucosa and submucosa, and of portions of the mucous glands. *a*, False membrane; *b*, portion of intact epithelium; *c*, infiltration of the mucosa with fibrin; *d*, portion of mucous gland infiltrated with pus.

have been found in large numbers. Other bacteria, either alone or in association with the pyogenic cocci, may be excitants of pseudo-membranous as well as simple angina.

OTHER BACTERIA WHICH ARE FREQUENT EXCITANTS OF SUPPURATION.

While the *Staphylococcus pyogenes* and *Streptococcus pyogenes* are the most common excitants of local suppuration with and without toxæmia and septicæmia, such conditions, as we have seen, are not infrequently due to other micro-organisms. Among these we may mention here as the more common and important:—*Diplococcus pneumoniae*, the gonococcus, *Micrococcus tetragenus*, *Bacillus pyocyaneus*, the colon and the typhoid bacillus, the bacillus of glanders, the tubercle bacillus, the pneumo-bacillus of Freidländer, the diplococcus of cerebrospinal meningitis, *Bacillus pyogenes fœtidus*, and *Actinomyces* with its related forms.

In some of these organisms the pyogenic qualities in their relationships to human infections are most conspicuous; in others, the reaction of the body to their presence is such as to justify a special name. The

latter is particularly noteworthy in the case of the pneumococcus, the gonococcus, glanders, typhoid, and tubercle bacilli, diplococcus meningitidis, and actinomyces.

Many other micro-organisms may be excitants of suppurative inflammation in man as well as in the lower animals under experimental conditions, but this exceptional reaction of living tissues does not fall within the scope of this work, which deals primarily with such tissue reactions as may occur under the usual conditions of life.

THE *BACILLUS COLI COMMUNIS* AND THE COLON GROUP.

The *Bacillus coli communis* is an organism so commonly present in the intestines under normal conditions as to be usually called the "colon bacillus." It is motile, facultative, aërobic, asporogenous, considerably resembling in general form the typhoid bacillus (see p. 235). It grows readily in artificial cultures and does not fluidify gelatin. It has been repeatedly found under such conditions in connection with suppurative processes as to justify the belief that it is often their excitant.

It has been found in various forms of peritoneal suppuration, both with and without such lesions of the intestine as would obviously permit of its egress; in appendicitis; in suppuration about the gall-ducts; in hæmorrhagic pancreatitis; in inflammatory processes in the genito-urinary apparatus; frequently in the bladder, in the pericardium and pleura, and it is believed to be concerned in certain types of diarrhœa. It is often concerned in terminal infections.

Local infection with this organism is often associated with serious toxæmia and septicæmia. Intravascular injections of virulent cultures in rabbits are usually followed by symptoms and lesions of septicæmia. Introduced subcutaneously and intraperitoneally, it may excite local suppuration or sero-fibrinous inflammation, often hæmorrhagic in character, terminating fatally.¹

It is not possible to indicate very definitely all the conditions under which the colon bacillus, an ordinarily harmless intestinal saprophyte, may gain access to the tissues and become actively pathogenic. Whether it is special strains of the bacillus coming in from without which are pathogenic, or whether the ordinary forms assume virulent capacities under unknown conditions, we cannot tell to-day. It appears in any event that very slight damage to the mucous membrane of the intestinal tract which may permit the exit of the germs, or the existence of damaged tissues elsewhere in the body—in the kidney, ureter, peritoneum, etc., for example—favor infection with this organism. To what extent a reduction in efficiency of the protective fluids of the body may determine infection we cannot say with certainty. Shortly after death the colon bacillus may pass from the intestine into the tissues. The possibility of this post-mortem invasion should be borne in mind

¹ For details concerning *B. coli*, with bibliography, see *Lartigau*, "Studies from the Dept. of Path., Col. of Phys. and Surg., Columbia Univ., vol. viii., 1902; also *Escherich* and *Pfaundler* in *Kolle and Wassermann's "Handbuch der Mikroorganismen,"* Bd. ii., p. 334.

in cultures from the dead body, since it may readily and doubtless often has given rise to errors in diagnosis.

The Colon Group.—There are so many organisms so closely resembling the colon bacillus in their morphological and biological characters that it has been found convenient to consider them as possible variations of one form and to speak of them collectively as the “colon group.” The differentiation between the individual members of this group and between these and the typhoid bacillus has presented many difficulties to bacteriologists and given rise to much technical finesse. It is now possible to differentiate between members of the colon group and the typhoid bacillus and to separate them in cultures (see ref. to Hiss, p. 246.)

THE BACILLUS PYOCYANEUS.

This has been known for several years as an organism occasionally found in pus to which in its growth it imparted a greenish color. Charin in 1889 established the significance of the organism as an excitant of suppurative inflammation and various manifestations of septicæmia to which he gave the name “*Maladie pyocyaneue*.” Since this time many cases have been reported in which the *Bacillus pyocyaneus*, either alone or in association with other organisms, has been found; for example, in purulent otitis media, angina, endocarditis and pericarditis, suppurative inflammation of the urinary tract, meningitis, bronchopneumonia, gastro-intestinal disturbances in infants and adults, and in lesions of the skin as well as in systemic infections arising from primary local suppurative inflammation. The green color is not always present in the lesions, being first developed in the cultures or in experimental animals.

The occurrence of the organism is on the whole infrequent. It was found by Jadowski twice in systematic cultures of the exudate from two hundred cases of suppurating wounds. Barker found it in eleven out of eight hundred cases in which systematic cultures from autopsies were made. It was found in three out of one hundred cases examined by Lartigau. Among the more marked lesions which may be present in cases of pyocyaneous infection, we may mention albuminous degeneration in the viscera, focal necroses, hæmorrhages, local hyperplasiæ (Oertel's lesion) in the lymph-nodes and -nodules throughout the body, and especially superficial, circumscribed or diffuse necrosis and ulceration in the intestinal mucous membrane.¹

Characters of the Organism.

This organism is a slender bacillus, sometimes grows in short chains, is motile, and decolorizes by Gram's method. It grows readily on artificial media, usually developing a greenish pigment. It liquefies gelatin. Subcutaneous injection of cultures in rabbits may be followed by local suppuration, by hæmorrhagic œdema, and by septicæmia.

¹ For a critical summary of the cases, with original studies and bibliography, consult *Lartigau*, *Phila. Med. Jour.*, Sept. 17th, 1898; also *Jour. of Exp. Med.*, vol. iii., p. 595, 1898.

BACILLUS MUCOSUS CAPSULATUS (*Friedländer Bacillus*).

In a small proportion of cases of lobar and lobular pneumonia, and in a few cases of exudative inflammation of the pleura, pericardium, meninges, nose, throat, and middle ear, this short encapsulated bacillus has been found. It is sometimes found alone, but in pneumonia is often associated either with the pneumococcus or with the pyogenic cocci. It has been found in the nasal secretion and mouths of healthy persons. While belonging definitely among the bacilli, it so frequently occurs in the form of very short rods or ovals or short chains that it was formerly thought to belong among the cocci. It is readily cultivated on artificial media and is slightly pathogenic for certain animals.

It seems highly probable, rather than proven, that it may be at least partially responsible for the lesions with which it is infrequently associated in man. This germ was formerly believed to be of great importance in connection with acute lobar pneumonia, and for a time was generally spoken of as the pneumococcus of Friedländer. It is now known not to be a coccus, and is certainly of subordinate, though occasionally serious, importance in inducing inflammation of the lungs.¹

MICROCOCCUS TETRAGENUS.

This organism has been many times found about the mouth and respiratory tract, especially in connection with suppurative processes, tuberculous cavities, etc. It has been found also in metastatic abscesses. While not very virulent it is apparently an occasional excitant, either alone or with other organisms, of suppuration.²

Characters of the Organism.

It is a coccus about 1 μ in diameter, usually occurring in groups of four. These tetrad groups may be encapsulated. It stains by Gram's method, and is readily cultivated on artificial media. It forms a dense whitish growth on gelatin, which it does not fluidify. Septicæmic lesions with local suppuration may be induced in guinea-pigs by subcutaneous injection with cultures.

THE PROTEUS GROUP OF BACILLI.

This is a large and in the economy of nature an important group of bacilli much concerned with the putrefactive processes.

Characters of the Group.

The bacilli of this group may be aërobes or facultative anaërobes. They are of medium size, asporogenous, and while staining readily with ordinary dyes are apt to be decolorized by the Gram method. While the organisms of this group are bacilli, they often present considerable variation in form as they grow, sometimes being very

¹ *Howard*, Philadelphia Medical Journal, vol. i., p. 336, 1898; *Stuhlern*, Cbl. f. Bak., Abt. I., Orig. Bd. xxxvi., p. 493, 1904; *Perkins*, Jour. Infec. Dis., vol. i., p. 241, 1904.

² For résumé of the significance of *M. tetragenus* and for bibliography consult *Lartigau*, Phila. Med. Jour., Apr. 22d, 1899.

short so as to resemble cocci, sometimes forming threads which may be so bent as to suggest spirals. Their growth on solid media is especially characterized by the tendency to send runners from the central growth out into the surrounding media, thus establishing secondary growth centres. They are particularly sensitive to environment, so that physiological as well as morphological variations are frequent. It is for these reasons that the name *Proteus* has been given to the group and to various species. The limitations of the named species are, however, in many cases quite ill defined.

One of the most common forms has been called *Proteus vulgaris*. While this bacillus is very widespread, it is only occasionally the excitant of pathological processes in man, and then almost always in concurrence with other organisms, usually the pyogenic cocci. Under these conditions a suppurative inflammation with foul exudate is apt to develop. Thus it has been found in purulent peritonitis and endometritis, in pleurisy and in phlegmonous inflammation in various parts of the body. Although this bacillus is not apt to grow in the human body, except in association with other micro-organisms which may damage the tissues or in tissues already vulnerable from injury, it may in the bladder independently incite an exudative inflammation. In animals, subcutaneous injection of the pure culture in considerable quantity may lead to abscess, while the soluble products of broth culture may induce toxæmia.

Several other forms of *Proteus*, as well as closely related species, have been found in human lesions for the most part suppurative and necrotic in character, and these, in some cases, have been conclusively shown to be the excitants of the pathological processes, but the scope of this work does not permit further details.

OTHER PYOGENIC BACTERIA.

Among the other bacteria which commonly induce local suppuration, with or without toxæmia and septicæmia, some are of frequent occurrence as excitants of such well-marked and more or less characteristic forms of disease as have long been recognized clinically and have received special names, such as pneumonia, gonorrhœa, cerebro-spinal meningitis, etc. The tubercle bacillus may also induce suppurative inflammation. These will be in part considered in the section dealing with the organs in which their more characteristic lesions are manifested.

ACUTE LOBAR PNEUMONIA AND OTHER INFECTIOUS DISEASES INDUCED BY THE DIPLOCOCCUS PNEUMONIÆ (*Pneumococcus Lanceolatus*).

Diplococcus pneumoniæ is sometimes spoken of as the "pneumococcus of Fränkel," because its significance and life history in connection with acute lobar pneumonia were first demonstrated by him.¹ It is commonly called simply the "pneumococcus."

¹ It was discovered by Sternberg in saliva, and its pathogenic power demonstrated some years before its full significance in connection with pneumonia was understood.

Characters of the *Diplococcus Pneumoniæ*.

During their development these germs are distinctly spheroidal; but in their mature condition they are apt to become slightly elongated or oval and are often a little broader at one end than at the other, assuming a lanceolate form. They are very apt to occur in pairs, and frequently are seen in short chains, rarely in long chains. Very frequently, when growing in the living animals, the pneumococcus is surrounded by a distinct, homogeneous capsule of varying thickness (see Fig. 124). Except in certain media capsule development is not readily seen in artificial cultures. The coccus itself is readily stained by the anilin dyes and retains the stain by Gram's method; the capsule is not easily demonstrated except by special staining methods.¹

The pneumococcus has no spontaneous movement and grows but feebly at ordinary room temperature. It grows much better at blood heat, forming on the surface of blood-serum or on very slightly alkaline glycerin-agar plates faint grayish, dewdrop like, inconspicuous colonies, somewhat similar to those of *Streptococcus pyogenes*, but usually more delicate. In beef-tea it forms at body temperature a delicate shimmering turbidity and a faint whitish sediment. As a rule, the cultures are prone to lose soon their virulence and to die off early, but the virulence may be maintained by successive inoculations in the rabbit. The pneumococcus may remain viable and virulent for many days when dried in sputum but in the form of small particles such as are distributed in coughing and sneezing it remains alive, as Wood² has shown, for from one to one and a half hours. In direct sun-light it may die in a few moments.

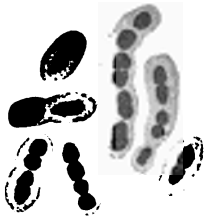

FIG. 124.—*DIPLOCOCCUS PNEUMONIÆ*.—*PNEUMOCOCCUS*.

Showing the stained capsules.

The serum of persons suffering from acute lobar pneumonia, as well as the serum of lower animals artificially immunized to the *Diplococcus pneumoniæ*, induces agglutination of the organism in broth cultures. Wadsworth has shown that by the use of centrifugated cultures of the organism, the reaction of agglutination can be obtained in much greater dilution than by the usual method.³ Precipitins are also found in immune sera.

Cultures which have been reduced in virulence, so as not to cause early death by septicæmia, may, when introduced into the trachea of rabbits, induce circumscribed pneumonic lesions, especially if these animals are made vulnerable by cold or by other agencies which impair the integrity of the blood or other tissues. Wadsworth has shown that by partially immunizing rabbits to the pneumococcus, so that they do not speedily die from septicæmia, and then introducing the virulent organism into the lungs through the trachea, diffuse pneumonic lesions comparable to the lobar pneumonias of man may be induced.⁴ Lesions of lobar pneumonia are readily induced in the dog by intratracheal injections of the pneumococcus. Different animal species vary in vulnerability to the pneumococcus.

This germ is the exclusive incitant of typical lobar pneumonia in man, and in a large proportion, if not in all, cases it is present in the blood.⁵ It induces locally in the lungs an acute exudative inflammation associated with an enormous and rapid multiplication of the germ and a toxæmia due to the distribution of soluble toxic products through the blood.

¹ See Wadsworth, *Jour. Inf. Dis.*, vol. iii., p. 610, 1906.

² Wood, *Jour. Exp. Med.*, vii., 592, 1905.

³ For details of this method see Wadsworth, *Jour. Med. Research*, vol. x., p. 228, 1903.

⁴ See references to experimental pneumonia, p. 614.

⁵ See Rosenow, *Jour. Inf. Dis.*, vol. i., p. 280, 1904.

For a more detailed description of these lesions of pneumonia, and an account of other bacteria which may be present, see page 603.

In addition to its more common effect in inducing lobar pneumonia, the pneumococcus is frequently the excitant of exudative inflammation in other parts of the body, either in connection with or without a primary lobar pneumonia. Thus it has been repeatedly found in pleuritis, otitis, meningitis, empyema, pericarditis, endocarditis, and in peritonitis. It has been found in abscesses of the viscera and in exudative inflammation of the joints. It may induce pseudomembranous inflammation of the mucous membranes.¹ Leucocytosis usually accompanies infection with the pneumococcus.

Sources of Pneumococcus.—The pneumococcus has been found in the mouths of a large proportion of healthy persons examined. The forms present in the mouths of healthy persons are apparently usually less virulent than the strains concerned in the incitement of pneumonia.² It is thrown off in the sputum in lobar pneumonia, and no doubt from this source to a certain extent in the dried condition, as dust, but more often in the droplets of sputum ejected in the coughing of pneumonics or in the fine spray formed in sneezing,³ furnishes the infectious agent which in favoring conditions of the body lights up the inflammatory process in the lungs.⁴

Toxic Products of the Pneumococcus.—Although clinically pneumonia bears many marks of toxæmia, investigators have not thus far succeeded in finding evidence that, either in artificial cultures or in the infected body, very potent soluble toxins are given off through the metabolic activities of the pneumococcus. There is evidence, on the other hand,⁵ that the toxic effects may be induced by endotoxins which are set free when in the course of the disease the organisms die and suffer lysis.

The Crisis in Pneumonia.—The dramatic character of the crisis in many cases of pneumonia has led to much conjecture as to the changes in the body fluids or the bacteria which may occur at this time. There appears to be no marked development of bactericidal power of the serum alone; antitoxic substances are not demonstrable. It has been conjectured that the new lore of the opsonins might throw light upon the rôle of phagocytes. But in spite of much research no very decisive data have as yet been elicited.⁶

Rosenow⁷ has shown that neither normal nor pneumonic sera are pneumococidal; that while non-virulent pneumococci are susceptible

¹ See *Cary and Lyon*, *Trans. Assn. Amer. Phys.*, vol. xvi., p. 379, 1901, bibl.

² For a consideration of the pneumococcus of the mouth in healthy persons, and for a study of varieties or strains of pneumococci, see studies carried on under the auspices of the Medical Commission for the Investigation of Acute Respiratory Diseases of the Department of Health of the City of New York, by *Park and Williams*; *Collins*; *Longcope and Fox*; *Norris and Pappenheimer*; *Duval and Lewis*; *Buerger*; *Hiss*; and *Longcope*: *Jour. Exp. Med.*, vol. vii., pp. 401–826, 1905; also *Eyre and Leatham*, *Jour. of Path.*, vol. ii., p. 246, 1906.

³ See *Wood*, *Jour. Exp. Med.*, vol. vii., p. 592, 1905.

⁴ For study of communicability see ref. *Edsall and Ghiskey*, p. 606. For a study of disinfection of the mouth and of sputum, see *Wadsworth*, *Jour. Inf. Dis.*, iii., 1906.

⁵ See *Macfadyen*, *Brit. Med. Jour.*, 1906, ii., p. 776.

⁶ See for study of pneumococcus infections relating to the crisis, *Strouse*, *Jour. Exp. Med.*, xi., 743, 1909.

⁷ *Rosenow*, *Jour. Inf. Dis.*, vol. iii., p. 683, 1906.

to phagocytosis, virulent strains are not, but may become so when under artificial cultivation they lose their virulence. With the restoration of virulence by passage through a series of animals, resistance to phagocytosis returns.

Rosenow has also determined that pneumonic leucocytes are more actively phagocytic than normal leucocytes. He finds the pneumococco-opsin quite resistant to heat, and that it may fall below normal in fatal cases of pneumonia, while, during or after crises in cases which recover, it may rise above the normal. He states that pneumococci when first isolated from the blood of pneumonia patients, whether before, during, or after crisis, usually refuse phagocytosis.

Rosenow calls attention to the significance of leucocytosis, in pneumonia as well as other infections, in fostering phagocytosis, and, while attributing considerable importance to the rôle of the phagocytes in the destruction of pneumococci *in vitro*, considers that as yet experimental proof is lacking that the crisis and recovery in pneumonia are to be attributed to opsonification and phagocytosis alone.¹

The studies of Wolf² on the opsonic power of the blood during the course of pneumonia call attention to the significance of leucocytosis in sustaining the pneumococcal capacities of the blood above the degree indicated by the opsonic index (see p. 187). Although his observations are confined to a few cases, he concludes that "in pneumonia the pneumococco-opsonic index is first decreased, but rises in favorable cases, reaching its height soon after crisis, while in fatal cases it remains persistently low. The estimated total antipneumococcal index (estimated from the leucocytic index and the opsonic index) is early increased and remains high until crisis is complete in cases with favorable termination."

A few observations of Wolf¹ on cases treated with the dead bodies of pneumococci—"pneumococcal vaccines"—seem to him to indicate that these exert a favorable influence upon the course of the disease.

Staining Reactions.—For staining the pneumococcus with its capsule the following method of Hiss³ gives good results. Mix the exudate or culture containing the organism on the cover-glass with a drop of blood-serum spread thin, dry and fix by heat. Add a few drops of the following stain: Five- or ten-per-cent. solution of gentian violet (5 c.c. saturated alcoholic solution of gentian violet plus 95 c.c. distilled water). Heat gently until steam rises. Wash off the stain with a twenty-per-cent. solution of cupric sulphate. Dry and mount in balsam.

If the material containing the organisms already contain serum, the preliminary mixing with this is unnecessary. Pneumococci in sputum, which without the addition of serum are often stained, with it not infrequently give better results.

The method of Welch⁴ gives good results, but annoying precipitates often form. After drying and fixing the specimen upon the cover-glass in the usual way, it is treated with glacial acetic acid, which is at once drained off and replaced by anilin-gentian-violet solution (p. 144), this being drained off and renewed several times until

¹ For a study of the virulence of pneumococcus during pneumonia see *Jürgens, Zeit. f. exp. Path., Bd. iii., p. 236, 1906.*

² *Wolf, Jour. Inf. Dis., vol. iii., p. 731, 1906.*

³ See on methods of staining encapsulated pneumococci *Hiss, Jour. Exp. Med., vol. vi., p. 317, 1901*; also *Wadsworth, Jour. Inf. Dis., vol. iii., p. 610, 1906.*

⁴ *Welch, Johns Hopkins Hospital Bulletin, vol. iii., p. 128, 1892.*

the acetic acid is displaced. The specimen is now washed with a two-per-cent. solution of sodium chlorid, in which it may be covered and studied. The pneumococcus may be stained in sections by Weigert's modification of Gram's method with preliminary contrast stain (see p. 144). By this method the fibrin in pneumonic exudate is also stained.¹

Streptococcus Mucosus Capsulatus.

In pneumonic and other exudates and in the normal throat one occasionally finds a capsulated organism growing in short chains and forming about the colonies a mass of mucus-like material. It is virulent for mice, less so for rabbits. After growth through several generations on artificial culture media it loses its capacity for forming the mucous material and its virulence diminishes. This organism is regarded by some as a variety of the pneumococcus, by others as a separate species.²

GONORRHOEA AND OTHER INFLAMMATORY LESIONS INDUCED BY THE MICROCOCCUS GONORRHOÆ (Gonococcus).

The *Micrococcus gonorrhœæ* (gonococcus) is most commonly found in the exudate of gonorrhœal inflammation of the mucous membranes, especially of the urethra. It may be free or enclosed in leucocytes or other cells (Fig. 125), within or between the epithelial cells. The organism may be distributed from the seat of primary lesion, giving rise to gonorrhœal arthritis, to malignant endocarditis, to exudative inflammation of the pleura, and to inflammatory processes in other parts of the body.³

The gonococcus may in the primary as well as in the secondary lesions be associated with the "pyogenic cocci," the colon bacilli, or other micro-organisms. These associations have been observed in cases of pyæmia following gonococcal infection. The gonococcus is usually most abundant in the urethra during the acute stage of the inflammation. But long after the organisms have disappeared from the urethral discharge they may be present in small numbers in the deeper portions of the urethra or in the prostatic secretions whence, under favoring conditions, a fresh infection may arise. In the female the inflammation develops in the urethra and cervix, and, through the transportation of the gonococci, may extend along the mucous membrane to the uterus and into the Fallopian tubes. The germs may

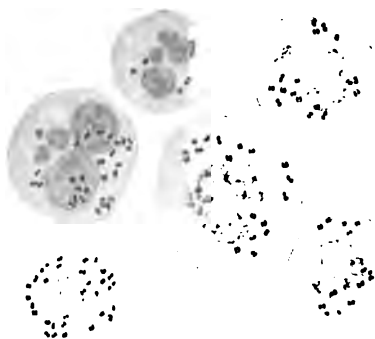


FIG. 125.—MICROCOCCUS GONORRHOÆ IN CELLS.—SPECIMEN FROM THE URETHRA.

¹ For a full *résumé* of the studies on the *Diplococcus pneumoniae* see *Weichselbaum* in *Kolle and Wassermann's "Handbuch der Mikroorganismen,"* Bd. ii., p. 189.

² See *Schottmüller*, *Münch. med. Woch.*, July 25th, 1905; also *Buerger*, *Cbl. f. Bakt., I. Abth., Orig.* Bd. xli., p. 314, 1906.

³ Consult, for cases and bibliography, *Young*, "Welch Anniversary Contributions to the Science of Medicine," p. 677, 1900; also, *Elting*, *Albany Med. Ann.*, Mar., 1900, bibl.

enter the peritoneum, inducing exudative inflammation. Hyperplasia and suppuration of lymph-nodes near the inflammatory region may occur. Gonorrhœal conjunctivitis is similar in origin and character to the inflammation of the urethra.

Characters of the Gonococcus.

The gonococcus is apt to occur in pairs, the apposed sides being more or less distinctly flattened (Fig. 126). It stains readily with the anilin dyes, and differs from most known cocci which might be mistaken for it in that it is decolorized by the iodine solution in the Gram method of staining. It is well after the decolorization by this method, and before mounting in balsam, to make a contrast stain with a dilute aqueous solution of Bismarck brown. Then the gonococci will be of light-brown color, while most other germs will retain the violet color.



FIG. 126.—MICROCOCCLUS GONORRHOÆÆ (GONOCOCCLUS).

From culture.

The gonococcus is non-motile and does not grow at ordinary room temperatures nor on the ordinary solid or fluid culture media. It may, however, be cultivated at the temperature of the body on human blood-serum or on a combination of this with agar.

In serum-agar the surface growth of the gonococcus is in the form of small circular, sharp-edged, slightly raised, nearly transparent colonies, coarsely mottled in the central portion, finely granular toward the borders. The life of the colonies under artificial culture is short, but by frequent transference to fresh media it may be maintained indefinitely and gradually adapts itself to the artificial environment.

The gonococcus is readily killed by heat and light and drying and is very vulnerable in the presence of many common disinfectants.

It is probable that the organism has no natural habitat outside the bodies of human beings. The lower animals are not, as a rule, susceptible to inoculations of the mucous membranes with the gonococcus, but suppurative inflammation has been induced in mice and guinea-pigs by intraperitoneal injections.

Inoculations of pure cultures of the gonococcus upon the urethral mucous membranes of man have been repeatedly made and were followed by a characteristic catarrhal inflammation. Thus the evidence is complete that the gonococcus is an excitant of the inflammation with which it is so constantly associated. But in what measure this germ, in what measure others, are responsible for the complicating inflammations when both germs occur together, is yet to be determined. The gonococcus appears to act rather through its endotoxins than by soluble substances set free in its growth.

Inasmuch as one or more forms of cocci and diplococci occurring in the normal and in the inflamed urethra are morphologically similar to the gonococcus, great caution should be exercised in doubtful cases in deciding upon the nature of suspicious micro-organisms in urethral discharges or other exudates. But the pronounced tendency of the gonococcus to gather within cells; the sometimes conspicuous but often ill-defined flattening of the apposed sides of the gonococci; the decolorization by Gram's method, which leaves most other germs apt to be associated with the gonococcus still stained, and whenever practicable

the artificial-culture characters—these all should be considered in the summary of evidence.¹

ACUTE CEREBRO-SPINAL MENINGITIS.

This is an acute infectious process of which the characteristic lesion is an exudative inflammation of the pia mater of the brain and cord.

As a rule the inflammation of the pia mater results in the production of serum, fibrin, and pus, which infiltrate the pia mater and accumulate in the ventricles, so that the gross appearance of the brain is characteristic. The exudation is often especially abundant at the base of the brain and over the posterior surfaces of the cord. In children the distention of the lateral ventricles with purulent serum may be a marked feature, while in adults the quantity of serum is apt to be small. (For details of the lesions in exudative meningitis see Nervous System.)

While the above are characteristic lesions of this disease, there are a number of secondary or associated septicæmic or toxæmic lesions in different parts of the body. There may be subserous punctate hæmorrhages in the endocardium; petechiæ in the skin; acute arteritis; hyaline and granular degeneration in the voluntary striated muscle; occasional multiple abscesses in various parts of the body; suppurative inflammation of the joints; albuminous degeneration of the heart, liver, and kidneys; and hyperplasia of the gastro-intestinal lymphatic apparatus and of the spleen.

Cerebro-spinal meningitis may occur by itself or in connection with some other acute infectious disease, such as acute lobar pneumonia, mycotic ulcerative endocarditis, pyæmia, multiple suppurative arthritis, otitis media, puerperal fever, typhoid fever, etc.

It may be *epidemic*, the lesions, however, being essentially similar to those in the simple acute form.

The *bacterial excitants* of simple sporadic cerebro-spinal meningitis are most commonly the pneumococcus and *Streptococcus pyogenes*. Of less frequent occurrence in the lesions are the influenza bacillus, the typhoid bacillus, and the gonococcus. Other bacteria have been recorded.

Epidemic Cerebro-Spinal Meningitis.—This form of exudative inflammation of the meninges of the brain and cord is induced by an organism named by Weichselbaum *Diplococcus intracellularis meningitidis* (*meningococcus*) because of its form and its frequent presence within cells of the exudate (Fig. 127). While often occurring in epidemics, infection with the meningococcus may be sporadic.



FIG. 127.—DIPLOCOCCUS INTRACELLULARIS.—MENINGOCOCCUS.

From fluid obtained by spinal puncture in case of epidemic cerebro-spinal meningitis.

¹ Von Hübner, *Centralbl. f. Bakt., Abt. I.*, Bd. xix., p. 120, 1896. For summary of studies on the gonococcus with bibliography consult Neisser and W. Scholtz in Kolle and Wassermann's "Handbuch der Mikroorganismen," Bd. ii., p. 148.

A comprehensive bibliography may be found in an article by Elling, *Albany Medical Annals*, March, 1900.

The lesions are in general similar to those above described in exudative inflammation of the meninges with other excitants, but, in distribution and type, present some moderately characteristic appearances. The exudate, which is purulent, sero-purulent, or fibro-purulent, is usually most marked at the base of the brain and on the posterior surface of the cord. In death at an early period there may be simple hyperæmia with little exudate. The purulent exudate consists largely of polymorphonuclear leucocytes, but there may be large polyhedral

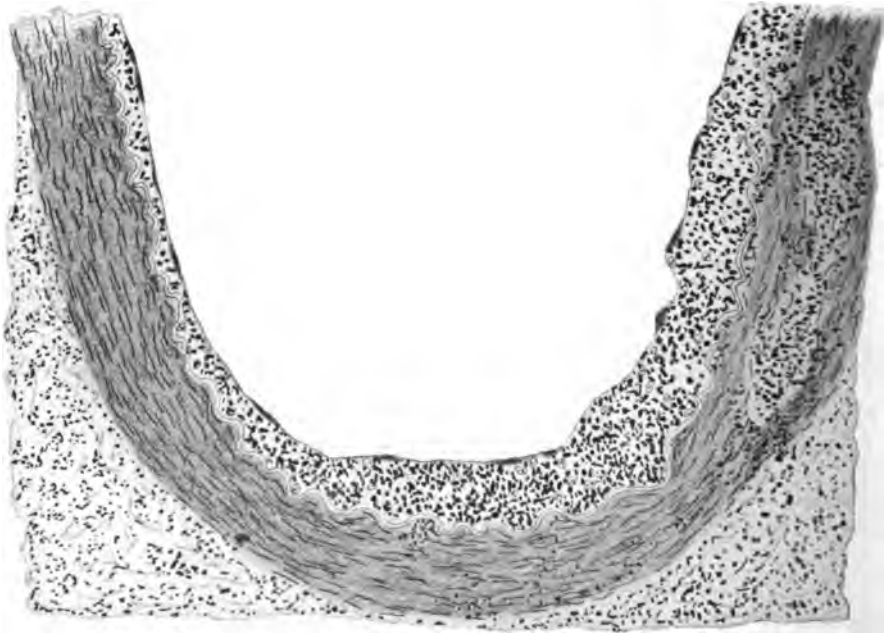


FIG. 128. —ACUTE ENDARTERITIS AND ARTERITIS IN EPIDEMIC CEREBRO-SPINAL MENINGITIS.

The endothelium is raised from the membrana elastica by an accumulation of cells—shown in the next figure. The muscularis is also involved.

cells mingled with them. These large cells, apparently derivatives of endothelium, are phagocytic and may contain leucocytes, red blood cells, etc. At later periods these large cells may preponderate in the exudate. The exudate may be present in the superficial layers of the brain and may involve the cranial nerves and the spinal nerve roots. There may be proliferation of neuroglia cells.¹ Acute arteritis with the accumulation of leucocytes and the formation of new cells beneath the endothelium of the small arteries of the brain and cord (Figs. 128 and 129) is often present in this disease.

In the prolonged, so-called chronic cases there may be œdema and thickening of the pia mater and degeneration of the pus cells.

¹ For an epitome of lesions see *Councilman, Jour. Amer. Med. Assn.*, vol. xliv., p. 997, 1905.

Characters of *Diplococcus Intracellularis Meningitidis*.

It is a diplococcus, considerably resembling the gonococcus, the pairs and tetrads being often flattened on the apposed sides. It is non-motile, not staining by Gram's method. It grows readily though not voluminously on appropriate culture media at body temperature. It is readily killed by exposure to sunlight, and by drying as well as by heat, cold, and the common disinfectants.

While the meningococcus is most abundant in the meningeal exudate, and is obtained on lumbar puncture, it has been found in the blood¹



FIG. 129.—ENDARTERITIS IN CEREBRO-SPINAL MENINGITIS—EPIDEMIC. Leucocytes and polyhedral cells have gathered between the endothelium and the muscularis in this small artery.

and in the nasal passages. Agglutinative substances are formed during the infection.

Pathogenicity.—Inoculations of cultures into various animals, mice, rabbits, guinea-pigs, etc., show that it is moderately pathogenic, the effects seeming to be largely due to an endotoxin. Flexner has induced in monkeys lesions almost identical with those of man.²

Source.—The frequent occurrence of the meningococcus in the nasal passages both in those suffering from epidemic cerebro-spinal meningitis at an early period and in those closely associated with them,³ while it is usually absent in well persons not exposed to the disease, leads to the conclusion that the infectious material may be transmitted by the nasal secretion directly, or through the air in the spray caused by sneezing. There is reason for believing that entrance is gained through the naso-pharyngeal mucous membrane,⁴ and through the pharyngeal tonsil. This is obviously possible through the direct connections which exist between the meninges and the nasal mucosa by lymphatics which pass the cribriform bone with branches of the olfactory nerve. But the possibility of origin through the blood is to be held in mind.⁵

¹ *Elser and Huntoon*, Jour. Med. Res., xx., 377, 1910, bibl.; also, *Davis*, J. Inf. Dis., iv., 558, 1907.

² See *Flexner*, Trans. Assn. Am. Phys., vol. xxi., p. 378, 1906; also, Jour. Exp. Med., vol. ix., pp. 105 and 142, 1907.

³ See *Weichselbaum and Ghon*, Wiener klin. Wochenschr., June 15th, 1905, p. 625; also *Goodwin and v. Sholly*, Jour. Inf. Dis., Suppl. No. 2, Feb., 1906, p. 21; also *Hasslaufer*, Cbl. f. Bakt., Abth. I., Orig. Bd. xli., pp. 633, 723, 796, 1906; also *Elser and Huntoon*, l. c. supra.

⁴ *Westenhoeffer*, Berl. klin. Wochenschr., June 12th, 1905, p. 737.

⁵ For a study of cases with bibl. consult *Councilmann, Mallory, and Wright*, "Special Report of the State Board of Health of Massachusetts," 1898; also *Elser*, Jour. Med. Res., vol. xiv., p. 89, 1906. For agglutinative reaction see *Jaeger*, Zeitsch. f. Hygiene u. Infkr., Bd. xlv., 1903, p. 225.

Serum Therapy.—By the immunization of horses with dead and living cultures of meningococcus, and with extracts of the bodies, curative sera have been prepared.¹ The Flexner serum injected intraspinously has been found after critical tests on a large number of cases to be an extremely valuable curative agent.²

Micrococcus Catarrhalis.

Diplococci resembling the meningococcus and called *M. catarrhalis* have been found on respiratory mucous membranes. Their cultural characters are quite similar to those of the meningococcus, for which they may be easily mistaken. They are believed to be incitants of catarrhal inflammations. They are often associated with pneumococcus and the influenza bacillus.

GLANDERS.

Glanders is an infectious disease incited by the presence and growth in the body of the *Bacillus mallei*.

It is most common in the horse, affecting the mucous membrane of the nose (when involving the skin the disease has been called *farcy*), and can be communicated to man and to certain other of the domestic animals by direct or accidental inoculations.

Man is quite susceptible to glanders infection, and the disease is most frequent in those who come much into direct contact with horses. The seat of primary local infection is most often the skin, more rarely the mucous membranes about the nose and mouth.

The local lesions are similar in man and the lower animals. In the presence of the *Bacillus mallei* there is usually a circumscribed or more rarely a diffuse infiltration of the tissue with leucocytes and young connective-tissue cells. These whitish foci of cell accumulation may be small and to the naked eye resemble miliary tubercles, or they may be larger and nodular. The tissues about them may be infiltrated with blood. But the accumulated cells are apt, in the presence of the bacilli, to become necrotic and disintegrate and thus lead to smaller and larger abscesses, or, if near the surfaces, to ulcers. If they occur on mucous membranes these lesions are often accompanied by intense diffuse catarrhal inflammation.

As the glanders nodules soften, the bacilli are apt to diminish in number or in the capacity to stain, so that it may be possible to detect their presence only by inoculation or culture methods.

The disease may begin at a single point, so that it may be mistaken for a carbuncle or gangrenous erysipelas. But the infection is apt not to remain local; the bacilli, finding their way along the lymph-channels into various parts of the body, set up fresh foci of inflammation and necrosis. Then the skin may be covered with a pustular eruption; furuncles, carbuncles, and abscesses may form beneath the skin and in the muscles. Nodules are found in the nasal mucous membrane, the

¹ *Wassermann*, Deut. Med. Woch., xxx., 1287, 1907; *Flexner and Jobling*, Jour. Exp. Med., x., 141, 1908.

² *Flexner*, Jour. Am. Med. Assn., liii., 1443, 1909.

lungs, kidneys, testes, spleen, and liver. The joints may be inflamed, and there may be osteomyelitis. Leucocytosis may accompany infection with the *B. mallei*.

The glanders infection may, however, pursue a more chronic course, with hard, persistent nodules and sluggish ulcers. Under these conditions the detection of the bacillus in the tissue by a simple morphological examination may be difficult.

While some forms of glanders nodules somewhat resemble in gross and microscopic appearance certain forms of miliary tubercles, the absence in the former of coagulation necrosis and of giant cells, and the tendency to rapid disintegration and softening in the latter, will usually suffice for the distinction between the two sets of lesions. But the demonstration of the bacilli characteristic of each is in all cases decisive.

Characters of the *Bacillus mallei*.—The *Bacillus mallei* is a slender bacillus proportionately thicker than the tubercle bacillus, with rounded ends, occurring singly or in pairs (Fig. 130). It stains easily with the anilin dyes, but readily gives up the color in presence of even feeble decolorizing agents such as dilute alcohol or acids. It is left decolorized by Gram's method.

It is non-motile, does not form spores, and frequently shows vacuoles and various involution forms.

In the tissues the bacilli may be stained with Löffler's alkaline methylene blue.

The glanders bacillus grows readily on almost all of the ordinary artificial culture media, and best at blood heat. The growths on solid media are apt to be viscid. On potatoes it forms in two or three days an abundant yellowish pellicle which in a few days darkens and finally becomes brown in color. It gradually loses its virulence in successive generations of artificial cultures. The germ is easily killed by moist heat, by sunlight, drying, and the several germicidal chemicals.¹

Field mice and guinea-pigs are very susceptible to infection with the *Bacillus mallei*, and develop highly characteristic local and general lesions.

Toxic Products and Immunity.—The toxic product of *B. mallei* is chiefly stored in the body of the organism as an endotoxin. On extraction by methods similar to those used in the preparation of tuberculin, (p. 261), the product called *mallein* has been found useful as a means of diagnosis in glanders, affected animals showing local reactions and a sharp rise of temperature, and marks of toxæmia.

Immunity is not apparently secured by glanders infection and while antibodies—agglutinins—are formed, effective curative sera have not been prepared.

DIAGNOSIS.—In cases in which an early diagnosis is imperative it is well, in addition to the morphological examination and cultures of the suspected exudate, to inject a small amount into the peritoneal cavity of a male guinea-pig. If the virulent glanders bacilli be present, within two or three days the testicles will swell and develop an intense suppurative inflammation.

Other Bacilli Related to *Bacillus Mallei*.

Several bacilli, apparently related to the *B. mallei*, have been found in various lesions in men and lower animals. Thus an organism called *Bacillus pseudotuberculosis* has been found in certain nodular lesions somewhat resembling tubercles which are especially frequent in rodents. *B. pseudotuberculosis liquefaciens* has been described in a series of cheesy nodules of the peritoneum, pancreas, and liver in man. In this group also belong organisms which have been found in noma.

¹ For a résumé of characters of the glanders bacillus see *Wladimiroff* in *Kolle and Wassermann's "Handbuch der Mikroorganismen,"* Bd. ii., p. 706.



FIG. 130.—*BACILLUS MALLEI*.

Chancroid (Soft Chancre).

Soft chancre or chancroid is an acute inflammatory lesion usually of the genital regions, at first pustular then ulcerative. The infective agent is communicated by contact. Neighboring lymph-nodes are apt to suffer an acute hyperplasia passing into abscess.

In the lesion of *soft chancre* and the discharge from it a small oval bacillus ("Ducrey's bacillus") has been frequently found either clustered or in chains. It stains readily with methylene blue, although it easily loses the color. It usually occurs with other micro-organisms, and has been found, though not commonly, in the buboes. It has been obtained in pure culture, in rabbit-blood agar and in human blood, and inoculation experiments in man and in monkeys indicate its pathogenicity.¹

ANTHRAX. (Splenic Fever; Malignant Pustule; Charbon; Carbuncle.)

This disease, which is much more common in the lower animals, especially the herbivora, than in man, is widely prevalent in Europe. It is comparatively rare in the United States, but in certain regions is more common than formerly.

It is induced in man by accidental inoculation with the *Bacillus anthracis*, which also incites the disease in the lower animals. Inoculation may occur through the skin by the agency of flies and other

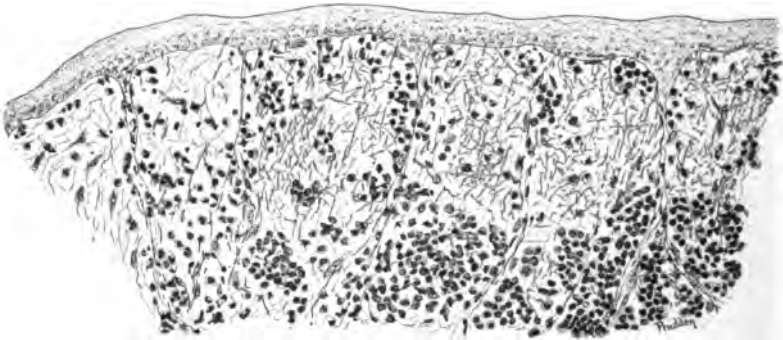


FIG. 131.—ANTHRAX—MALIGNANT PUSTULE—OF THE SKIN.
From a man who had been handling foreign hides in New York. Bacilli stained.

insects which have been feeding on animals infected with this disease, through abrasions or slight wounds on the hands of those handling their carcasses or hides, or in other ways. Following this skin inoculation a pustule is apt to develop—"malignant pustule"—and varying phases of an acute exudative inflammation, which may be hæmorrhagic, sero-fibrinous, purulent, or necrotic, accompany the local proliferation of the germs (Fig. 131). Anthrax bacilli in large numbers may be present in the local lesion. From this local source a general infection may ensue. General infection may occur without evident external lesion.

Infection with anthrax may occur through the lungs, most often among those who handle infected wool or hides, the dust from which is inhaled ("wool-sorter's disease"). Under these conditions there may

¹ See *Davis, Journal of Medical Research*, vol. ix., 1903, p. 401, bibl.

be œdema, lobular pneumonia with involvement of the pleura, mediastinum, and other adjacent structures. Infection through the gastrointestinal canal takes place by the ingestion of food containing anthrax spores, and is apt to be accompanied with inflammatory and necrotic changes, which are described in detail among lesions of the intestine. This is a common mode of infection in animals.

When general anthrax infection occurs the post-mortem appearances vary. Decomposition, as in other acute infections, generally sets in early. The blood is frequently not much coagulated and dark in color. Hæmorrhages and ecchymoses are frequently found in the serous and mucous membranes and in various other parts of the body.

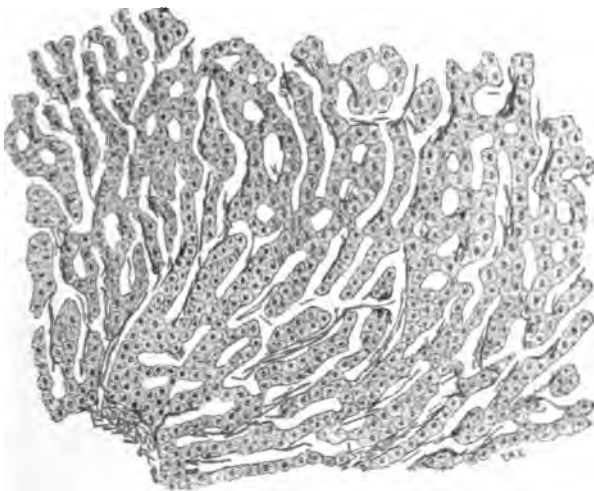

FIG. 132.—BACILLUS ANTHRACIS GROWING IN THE BLOOD-VESSELS OF THE LIVER OF A MOUSE INOCULATED WITH A PURE CULTURE OF THE BACILLUS.

The lungs may show small hæmorrhages and œdema, and the bronchi may be deeply congested. The pleural cavities may contain serum. The intestines may exhibit the lesions of the so-called *intestinal mycosis*. The bronchial and other lymph-nodes may be swollen. The spleen may be swollen, very dark in color, and soft, sometimes almost diffuent.

The bacillus may be found, usually in large numbers, in the spleen and in the capillary blood-vessels, especially in the liver (see Fig. 132), lungs, kidneys, and intestine.¹

Characters of the Bacillus Anthracis.

The Bacillus anthracis is from 5 to 20 μ long and about 1 to 3 μ broad, and is often uneven along the sides. The ends of the bacilli are square or slightly concave, and the bacilli often hang together end to end, forming thread-like structures (Fig. 133). While the bacilli in the vegetative condition are easily killed, they develop spores outside the body only, and these are very invulnerable to the ordinary germicidal

¹ For bibliography and résumé of anthrax see Sobernheim, Kolle and Wassermann's "Handbuch der Mikroorganismen," Bd. ii., p. 1.

agents and to heat, resisting often for many days the action of from 2- to 5-per-cent. carbolic acid and defying for some minutes the action of live steam. Anthrax bacilli are immobile, sometimes capsulated, and are easily stained by the anilin dyes. They grow readily on artificial culture media at ordinary room temperatures, fluidifying gelatin.

Subcutaneous inoculation of cultures of the anthrax bacillus into various species of animals induces characteristic lesions. White mice and guinea-pigs are especially susceptible, usually succumbing to the anthrax septicæmia in from two to four days. Serous exudations, often bloody and with many bacilli, develop at the seat of inoculation, while in the blood multitudes of the bacilli are found.

IMMUNIZATION.—If cultures of the anthrax bacillus be made at a temperature of about 42° C., growth occurs, but it is meagre. Spores are not formed as they are at body temperature, and the virulence of the germ diminishes day by day, so that at last the most susceptible animals are not affected by large inoculations of the living organisms. If fresh cultures of these organisms be made in various stages of their diminishing virulence and maintained at their optimum temperature, spores will again form, the growth will become vigorous, and in morphology quite characteristic; but the physiological qualities which determine virulence will remain more or less in abeyance.

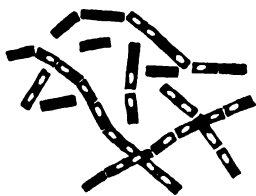


FIG. 133.—BACILLUS ANTHRACIS
CONTAINING SPORES.
From a culture.

By inoculation of animals with anthrax cultures, first with those which had been kept at 42° C. for from fifteen to twenty days, and thus had but feeble virulence, and passing to those cultivated at 42° C. for a shorter time and which were thus more virulent, Pasteur secured immunity from anthrax in a series of the lower animals (see p. 162). Based upon these experiments a method of protective inoculation has been practised on a large scale among sheep and other animals in some parts of Europe which has been of great economic value. The death rate from anthrax has by these methods been reduced in sheep from 10 per cent. to about nine-tenths of 1 per cent., and in cattle from 5 per cent. to less than four-tenths of 1 per cent.¹

Little is known of soluble toxins or endotoxins of the anthrax bacillus.

ACTINOMYCOSIS.

This disease, which is of occasional occurrence in man, but is more common in the domestic animals, especially in cattle and in horses, is most frequently characterized by a slow suppurative and proliferative process, often leading to the formation of large fungous masses which may become calcareous.

In cattle, the new-formed tissue, which develops with especial frequency in the jaw, is apt to extend beyond the original site and to slough, so that not only may the tissues of the tongue, pharynx, larynx, etc., be involved, but secondary nodules of similar character may form in the lungs, gastro-intestinal tract, and skin.

In man, suppuration with necrosis and the formation of abscesses, ulcers, and fistulæ, are the most marked lesions in parts near the surface of the body. In the *lungs* the lesions may be essentially those of an acute general bronchitis or in the form of broncho-pneumonia (Fig. 134), with the formation of new tissue.²

¹ For a study of opsonic substances in dog serum favoring phagocytosis of anthrax bacilli see *Hektoen, Jour. Inf. Dis.*, vol. iii., p. 102, 1906.

² For a detailed description of the lung lesions in actinomycosis, with general bibliography, see *Hodenpfl.*, "Actinomycosis of the Lung," *New York Medical Record*, Dec. 13th, 1890.

Abscesses and cavities may form which extend into adjacent parts. In intestinal actinomycosis nodular masses of new tissue with ulceration may develop in the mucosa and submucosa. Metastases have been described. The excitant of this disease—now most commonly called *Actinomyces bovis*—is a micro-organism which seems to be more closely related to the moulds than to the bacteria. It is, however, considered here because its botanical position is not yet clearly established, and it is still commonly regarded as one of the so-called pleomorphic or “higher bacteria” (see p. 135).

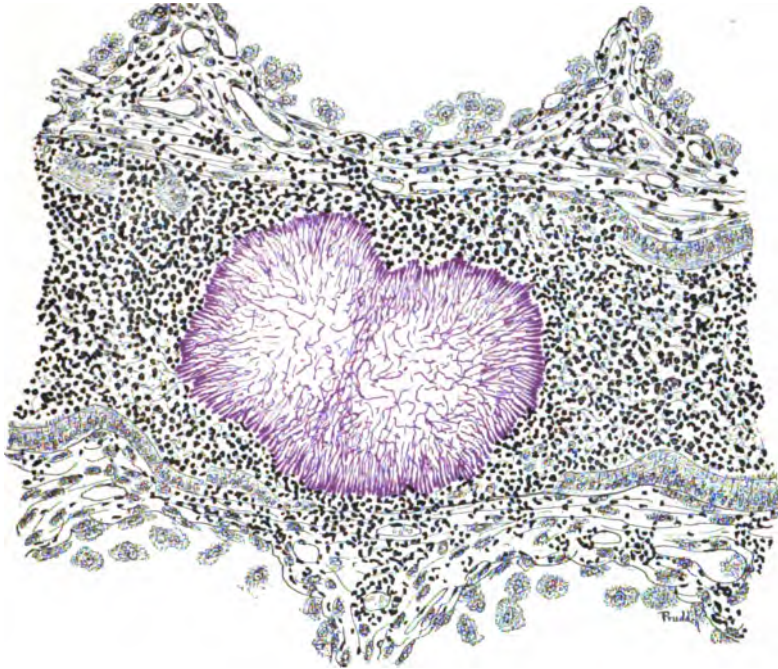


FIG. 134.—ACTINOMYCES GROWING IN HUMAN BRONCHUS.
(The bulbed ends of the filaments are seen in the borders of the colony. The bronchus, cut lengthwise, contains purulent exudate, and its wall is becoming involved.)

The organism often grows in the tissues in the form of little rounded masses from a size so small as to be invisible to that of a pin's head. They may be transparent or grayish white or yellow or dark in color. Under the microscope these masses often appear in the form of a dense group of radiating filaments with more or less bulbous ends; hence the common name “ray fungus.”

Characters of Actinomyces.

The organism when freed from other bacteria is readily cultivated at 37° C. It grows in delicate branching threads which show segments resembling bacilli and cocci besides bulbous or club-shaped forms, probably “involution forms”. Successful inoculations of cultures have been made in animals.

The organism is usually conveyed from one animal to another by inoculation or by contact of the growth with a wound or an abrasion of the mucous membrane.¹

In the examination of sputum, fæces, pus, etc., for the presence of actinomyces the naked-eye appearances may be of value, since the yellowish white granules are often quite visible, especially on a black background. Suspicious masses may be teased and studied unstained, or stained by Gram's method. Sections of tissue may be hardened in alcohol, and sections stained by Gram's method with contrast eosin stain.

Other Organisms Resembling Actinomyces.

Many forms of micro-organisms of similar general characters to actinomyces have been described, some occurring in connection with infective processes in man and the lower animals of which they seem to be the excitants, others living as saprophytes in various situations. Among the apparently pathogenic forms we may mention the following:

An organism somewhat resembling actinomyces and found in connection with a disease commonly called mycetoma or "Madura foot," frequent in the tropics and characterized by new nodular growths associated with suppuration and necrosis most often affecting the foot.²

Another form has been described in connection with a peculiar form of erysipelalous inflammation of the skin; another in the so-called *farcin de bœuf*, a disease of cattle in Guadeloupe; this has been called *Streptothrix* and now *Nocardia*.

Several times organisms of this general character, but differing considerably from actinomyces, have been found in inflammatory and necrotic lesions of the lungs. Whether these are variants of that species or independent species, and how many such there are it is impossible at present to say.³ Many attempts have been made to classify these organisms but knowledge of them is still too incomplete to permit accurate distinctions.

Pharyngo-Mycosis Leptothrix.

Certain filamentous micro-organisms called *Leptothrix*, whose botanical affiliations are not yet clear, are of common occurrence in the mouths of healthy persons. Occasionally, however, a persistently recurrent attack of "sore throat," with local tenderness and sometimes cough and fever, is associated with the growth of masses of leptothrix in the crypts of the tonsils, at the base of the tongue, on the walls of the pharynx, or in the nose or superior portion of the œsophagus. The leptothrix masses or colonies form thick whitish pellicles or patches which may be superficial, or in tonsils may extend deep into the crypts. These masses are usually firmly adherent, often leave bleeding surfaces when removed, and the growth is apt persistently to recur.

Microscopic examination of removed portions of the growth show tufts and bundles of the thread-like micro-organisms, growing among or directly out from flat epithelial cell masses and mingled with various other forms of micro-organisms, mostly cocci and short bacilli. There may be overgrowth of epithelium and collections of leucocytes in and about the leptothrix masses. In sections of the tissue or in teased fragments treated with iodine (Lugol's solution) the leptothrix threads are readily differentiated from the tissue elements and from other micro-organisms, by their dark color.⁴

¹ For a study of the biology of actinomyces with bibl. see *Wright*, Jour. Med. Res., vol. viii., p. 349, 1905.

² Consult *Wright*, Journ. Exp. Med., vol. iii., p. 421, 1898, bibl.; also in Jour. Med. Res., viii., 349, 1905 and *Osler's*, "Moderna Medicinæ," I., 327, 1907.

³ For a description of two such cases, with a selected bibliography, see *Norris* and *Larkin*, Journ. Exp. Med., vol. v., p. 155, 1900; also case by *Tuttle*, Med. and Surg. Rep., Presby. Hosp., N. Y., vol. vi., p. 147, 1904.

For a critical summary of this group of organisms, with a full bibliography, see monograph by *Lachner-Sandoval*, "Ueber Strahlenpilze," Strasburg, 1898; see also *Petruschky*, Kolloid- und Wassermann's "Handbuch der Mikroorganismen," Bd. ii., p. 832.

For a full treatment and bibliography consult the monograph on "Aktinomycose" by *Schlegel* in *Kolle* and *Wassermann's* "Handbuch der Mikroorganismen," Bd. ii., p. 861; see also *Musser*, *Pearce*, and *Gwynn*, Trans. Assn. Am. Phys., vol. xvi., p. 208, 1901.

⁴ For further details and bibliography consult *Campbell*, Medical News, Apr. 4th, 1896; also *Pearce*, Bull. Univ. Penn., vol. xiv., 1901, p. 217.

INFLUENZA. Epidemic Catarrhal Fever; La Grippe.

This is an infectious disease characterized by fever, physical and mental prostration, and exudative inflammations in different parts of the body. Thus there may be exudative inflammation in the respiratory, digestive, and nervous systems, either singly or together. Sometimes, however, these local inflammations may be absent, when the disease may be marked by the characteristic prostration and symptoms of toxæmia. None of the lesions appear to be characteristic. The lesion of the lungs is usually of the broncho-pneumonic type and is apt to involve the interstitial tissue. The cut surface is smooth, the exudate is soft and contains relatively little fibrin. The lung resembles that of "purulent infiltration."

The numerous bacterial studies which up to 1892 had been made on epidemic influenza had failed to reveal any micro-organism which could fairly be regarded as of etiological significance, although some of the complicating inflammations of the lungs had been shown to be very frequently associated with the pyogenic cocci—*Staphylococcus pyogenes* and *Streptococcus pyogenes* and the *Diplococcus pneumoniae*.

Early in 1892, Pfeiffer, Kitasato, and Canon described the occurrence in the bronchial exudate and in the blood of influenza patients of a very small bacillus, hitherto unknown or possibly noted earlier by Babes. This bacillus—*B. influenzae*—was sometimes present in the bronchial exudate in enormous numbers, and often with little or no contamination with other germs. It was found at the seat of other local lesions, and the pus cells often contained many bacilli. It has been found to persist in the body long after the active processes have ceased.¹

Characters of the Influenza Bacillus.

The influenza bacillus is very small—about 0.5 μ long by 0.2 by 0.3 μ in width—with rounded ends, non-motile and does not form spores. It stains with some difficulty with simple anilin dyes; but by Ziehl's solution (p. 258), or by warmed Löffler's methylene blue (p. 145), it is readily colored. It does not retain the stain well by Gram's method. The organism apparently dies after a few hours' drying in the air and soon in water and is readily killed by heat or cold or chemical germicides.

This bacillus grows best at body temperature, on glycerin-agar whose surface has been smeared with blood—human, rabbit, or pigeon. It forms very small, scarcely visible, dewdrop-like colonies, which, although growing close together, do not tend to coalesce, as many micro-organisms do. It has been cultivated through several generations, but usually dies soon.

Animal inoculations have given diverse and not very marked results, most of the lower animals being apparently quite insusceptible except to very large doses of cultures which may have a toxic action upon them. In monkeys, however, influenza-like symptoms have been induced by application of cultures to the nasal mucosa.

The evidence that the organism described above is the excitant of epidemic influenza rests largely upon its apparently constant presence, especially in the exudates of the nasal and bronchial mucous membranes,

¹ For a full résumé of the characters of the influenza bacillus and its relation to various forms of the disease, with bibliography, see the articles by Beck in Kolle and Wassermann's "Handbuch der Mikroorganismen," Bd. ii., p. 359.

where it may be present in enormous numbers and almost free from admixture with other germs.

Cases of sporadic influenza are of frequent occurrence, especially in towns. These are often mixed infections, the influenza bacillus being associated with pneumococcus, streptococcus, etc.

That the organism should have been occasionally found under other conditions,¹ as in chronic pulmonary tuberculosis, does not at all militate against its significance in inciting the manifestations of influenza, since many parallel instances are known in other infectious diseases. The frequent discrepancy between the clinical and bacterial diagnosis in influenza is largely due to its varying and often obscure clinical manifestations which render possible and convenient the use of the name for many phases of catarrhal and other forms of inflammation.

Immunity in any marked degree does not appear to be conferred by influenza.

Source.—Material containing the influenza bacillus is readily and doubtless frequently conveyed from the victims of influenza or from those harboring the organism to the well in droplets and spray dispersed through the air by unguarded coughing and sneezing, as well as by direct personal contact and the use of contaminated utensils for food and drink.

Other Organisms of the Influenza Bacillus Group.

There are several organisms in the influenza bacillus group which considerably resemble it, some of which appear to be pathogenic, others not so. Thus several observers have found in exudates from various sources, but especially in the respiratory passages, small immobile asporogenous bacilli growing best under conditions similar to those favorable to the influenza germ, the colonies being similar. They are somewhat larger than the influenza bacillus, and tend to form threads. This organism has been called the pseudo-influenza bacillus—*B. pseudo-influenzæ*. Its pathogenic capacities are not clear, but it evidently differs in this respect from the genuine influenza bacillus. In stained specimens of exudate the pseudo-bacillus may be mistaken for its relative. It seems probable that there may be several forms of organisms not distinguishable at present from each other and from the influenza bacillus, which have been grouped under the name *B. pseudo-influenzæ*, so that the use of the name is of doubtful value.²

Another bacillus of this group, *B. conjunctivitis*—Koch-Weeks bacillus—has been found in conjunctival catarrh by several observers in various countries and is doubtless the inciting factor in a readily communicable form of conjunctival inflammation. This bacillus, resembling the influenza bacillus, is somewhat longer and grows on blood-free media. It may be differentiated by cultural characters. Animal inoculations have been negative.

TYPHOID FEVER.

Typhoid fever is an acute infectious disease incited by the *Bacillus typhosus*. The reaction of the body to this bacillus is usually manifested by characteristic lesions, especially by hyperplasia and necrosis

¹ See Park, "Pathogenic Bacteria and Protozoa," Second ed., 1905, p. 324; see also for studies of this organism Lord, Bost. Med. and Surg. Jour., vol. clii., pp. 537 and 574, 1905, also Auerbach, Zeits. f. Hygiene u. Infkr., Bd. xlvii., p. 259, 1904; also Davis, Jour. Inf. Dis., vol. iii., p. 1, 1906.

For a study of the influenza bacillus in inflammations of the respiratory tract in infants see Wollstein, Jour. Exp. Med., vol. viii., p. 681, 1906.

² See ref. Wollstein above.

in the lymphatic structures of the intestines and the mesenteric lymph-nodes, and in the spleen, as well as by the more general alterations incident to toxæmia and septicæmia; but the infection is occasionally of the septicæmic type without characteristic local lesions in the intestines, or mesenteric nodes, or other viscera.

THE BACILLUS OF TYPHOID FEVER.

The presence of a bacillus, called *Bacillus typhosus*, in various parts of the body in typhoid fever, in a considerable proportion of the cases examined, has been well established. This bacillus does not occur in the body, so far as is known, except in connection with this disease.

Characters of the *Bacillus Typhosus*.

The typhoid bacillus is usually about three times as long as broad, being about one-third as long as the diameter of a red blood cell. It is rounded at the ends, motile, aërobic, facultative anaërobic, and asporogenous. It grows readily at room temperature on the ordinary media. In cultures the bacilli often cling together end to end, forming threads (Fig. 135). It is readily killed by heat, is fairly resistant to chemical germicides, and remains alive for some time frozen in ice.

The inoculation of lower animals with the typhoid bacillus may result in various lesions, and prove fatal, but typical typhoid fever is not induced.¹

The typhoid bacillus in its growth in cultures does not seem to produce soluble toxins of marked potency in very considerable amount though there is evidence that some such poison is formed.² On the other hand, there is stored up in the bodies of the bacilli a virulent endotoxin which has been largely used in artificial immunization.

It is probable that the more characteristic symptoms and lesions of typhoid fever are largely due to the absorption of toxic substances which are produced as the result of the life processes of the bacteria at the point of their greatest accumulation and activity. It should be borne in mind that the typhoid bacillus, as is the case with many other bacteria, may induce local changes by means of its endotoxins, which are set free as the organisms disintegrate after their death in the body.³

PRIMARY CHARACTERISTIC LESIONS.

We shall first consider the lesions which are most common and characteristic of typhoid fever.

The Intestines.—The lesions of the intestines consist of an inflammatory enlargement (hyperplasia) of the solitary lymph-nodules and of the agminated lymph-nodules (Peyer's patches). Necrosis of the nodules with ulceration frequently follows the hyperplasia.

¹ For a study of experimental typhoid see *Atlassoff*, *Ann. Inst. Pasteur*, t. xviii., p. 701, 1904, bibl.

² For a study of the soluble poisons of the typhoid bacillus see *Rodet, Lagriffoul, and Aly Wahby*, *Arch. de méd. exp.*, t. xvi., p. 397, 1904.

³ For a study of the typhoid bacillus, with reference to the pathology, diagnosis, and hygiene of the disease, see *Hiss*, *Med. News*, May 11th, 1901.



FIG. 135.—BACILLUS TYPHOSUS.

The process appears to begin with a catarrhal inflammation of the mucous membrane, accompanied or immediately followed by changes in the lymph-nodules. The lesions in the lymph-nodules begin early; they have been observed in persons who have died forty-seven hours after the commencement of the disease. The increase in size of the agminated and solitary nodules may be rapid or gradual. The nodules may be only slightly enlarged, or may project far into the lumen of the intestine. The enlargement is usually more marked in the agminated than in the solitary nodules. Usually the whole of a Peyer's patch is enlarged, but sometimes only a part of it. If the enlargement be gradual the different nodules which make up a Peyer's patch may enlarge, while the septa between them remain but little changed, thus giving the patch an uneven appearance.

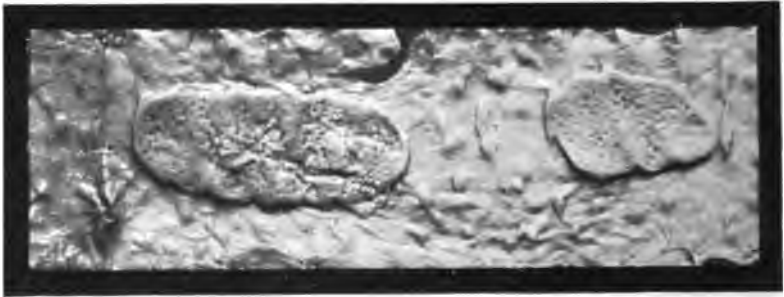


FIG. 136.—HYPERPLASIA OF PEYER'S PATCHES IN TYPHOID FEVER.

The patches which are only moderately enlarged are of reddish or reddish gray color, and soft and spongy, and their edges blend gradually with the adjoining mucous membrane. The patches which are more markedly affected are of grayish color, of firm consistence, and rise abruptly from the surrounding mucous membrane (Fig. 136) or even overhang it like a mushroom. The largest patches are sometimes more than three-eighths of an inch thick.

The enlargement and infiltration may spread from the patches to the surrounding mucous membrane, so that the patches appear very large; a number of them may become fused together, and there may even be an annular infiltration entirely around the lower end of the ileum. The infiltration, limited at first to Peyer's patches, may extend outward into the muscular coat, and appear in the peritoneal coat as small, gray, rounded nodules. This condition is usually found only with a few patches in the lower end of the ileum; sometimes in the cæcum and appendix vermiformis.

The solitary nodules are affected in the same way as Peyer's patches. They may be hardly enlarged at all, or be quite prominent, or may be affected over a larger portion of the intestine than are the patches. Very rarely the solitary nodules are enlarged, while the patches are not at all or but slightly affected.

The inflammation and enlargement of the agminated and solitary nodules may be followed by a healing process. The character of this process varies according to the intensity of the previous inflammation.

If the reaction be slight and the enlargement of the nodules moderate, the enlargement gradually disappears, and they resume their normal appearance (resolution). In moderate enlargements of Peyer's patches resolution proceeds first in the nodules, leaving the septa between them for a time still swollen and prominent. This gives to the surface of a patch a reticulated appearance. After a time, however, the entire patch becomes flattened and uniform. On the other hand, the solitary nodules or the separate nodules of a patch may soften, break down, and their contents be discharged with some attendant hæmorrhage. This leaves a bluish gray pigmentation, due to altered hæmoglobin, in the situation of each nodule, and this may remain for years.

In more severe types of the disease the enlargement of the nodules and Peyer's patches ends in ulceration. This takes place in two ways:

(a) The enlarged nodules or patches become necrotic, soften, break down, and discharge into the intestine. In this way are formed small ulcers (Fig. 137). These ulcers increase in size by the same softening process, which gradually extends at their edges, and in this way ulcers of large size may be formed.¹ The ulcers may extend outward to the muscularis or to the peritoneal coat, or they may involve the peritoneal coat also and perforate.

(b) In the severest forms of the disease considerable portions of the enlarged patches may slough and become detached, leaving large ulcers with thick, overhanging edges (Fig. 138). The slough may involve only the nodules, or it may involve also the muscular and peritoneal coats, and perforation may occur. These ulcers also may afterward increase in size, and several of them may be joined together. When the ulceration leads to perforation, peritonitis and death are the usual result. In rare cases, however, the patient recovers and the perforation is closed by adhesions.

If the patient recover, the ulcers are covered by granulation tissue, their edges become flattened, the granulation tissue becomes firmer and denser, and this new connective tissue is gradually covered with cylindrical epithelium.

The minute changes which take place in the development of the intestinal lesion are as follows:



FIG. 137.—HYPERPLASIA OF PEYER'S PATCH IN TYPHOID FEVER, WITH SMALL ULCERS. The separate small ulcers are extending and have in part coalesced.

¹ Owing to the frequent involvement of Peyer's patches, the larger intestinal ulcers in typhoid fever are apt to have their longest diameter lengthwise of the gut in contrast to spreading tuberculous ulcers, which, owing to the extension of the local inflammation along the encircling lymph channels, are apt to have the longest diameter crossing the gut. But exceptions to this general rule are common.

At first the blood-vessels around the nodules are dilated and congested, while the nodules are swollen and the epithelium may fall off. Then the nodules increase in size, largely from a growth of new cells.

This cell growth is essentially a hyperplasia of normal elements of




FIG. 138.—ULCERATION OF PEYER'S PATCHES AND SOLITARY LYMPH-NODULES IN TYPHOID FEVER. The swollen patches and nodules are necrotic except at their edges, the central portions forming a ragged slough.

the lymphatic tissue, namely, the lymph cells and the endothelium of the trabeculæ and sinuses. There are thus two main types among the new-formed cells: first, small cells with relatively large and deeply staining nuclei; and second, larger polyhedral or rounded cells with more or less vesicular nuclei. The larger cells may contain foreign substances,

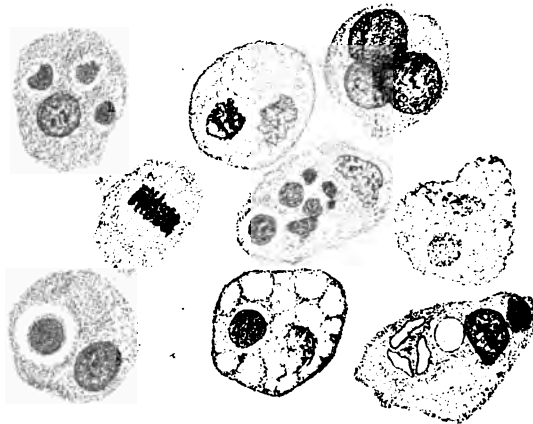


FIG. 139.—ENDOTHELIAL CELLS IN HYPERPLASIA OF PEYER'S PATCH IN TYPHOID FEVER.

These exfoliated and newly formed cells contain various foreign substances—leucocytes, red blood cells, fragments of nuclei, etc. Some of them are necrotic and are degenerating. A mitotic figure is seen in one.

such as red blood cells or leucocytes (Fig. 139). The occurrence of mitotic figures in the endothelial cells while these are *in situ*, and the position and grouping of the large cells, appear to prove their endothelial origin. The production of new cells is not confined to the nodules, but

extends also to the adjacent mucous membrane and underlying tissue. In many cases also little foci of similar new-formed cells are found in the muscular, subserous, and serous coats.

In this stage resolution may take place; then the new-formed cells degenerate and gradually disappear. In severer forms of the disease necrotic changes are apt to supervene, leading to the larger and small ulcers above described. The factors which determine the death of the hyperplastic tissues are not yet fully understood. It is believed by some to be directly due to toxic substances formed by the typhoid bacilli which kill the tissue cells; others are inclined to attribute it to the pressure which the new-formed cells exert on the nutritive blood-vessels.

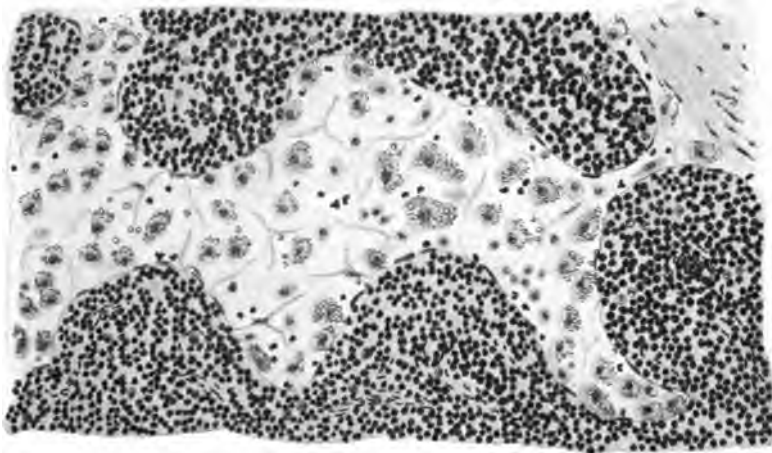


FIG. 140.—PHAGOCYTES IN THE PERIFOLLICULAR SINUSES OF A MESENTERIC LYMPH-NODE IN TYPHOID FEVER.

The large cells in the sinuses contain red blood cells and blood pigment.

The conclusions on this point which Mallory draws from a long and interesting series of studies would indicate that a proliferation of the endothelial cells of the blood-vessels may lead to their occlusion. This observer describes the formation of occluding thrombi in the lymph-vessels and smaller veins. These are composed of the proliferated endothelial cells which have degenerated, together with fibrin whose formation these degenerating cells induce. The accumulation of serous and fibrinous exudate about these thrombi, and the necrosis of tissue which may now ensue may soon be followed by necrosis of the superficial epithelium and the development of ulcers. The accumulation of polymorphonuclear leucocytes may, according to Mallory, now occur, and, in cases which go on to recovery, healing follows by the formation in the usual way of granulation tissue with the ultimate restitution of the surface epithelium. Mallory lays great stress upon the phagocytic nature of the new-formed cells of the veins and lymph-vessels (Fig. 140

and Fig. 141). For the significance of this process and other interesting details we refer to the original paper.¹

The lesions which we have described are found most frequently and are most pronounced in the lower part of the ileum. They are not always, however, confined to this situation. Enlarged and ulcerated nodules may be found over the entire length of the ileum and even in the jejunum. They may also extend downward and be found in the colon, even as far down as the rectum. Similar changes may take place in the appendix vermiformis.² A few cases are recorded in which local nodular foci of new cell production, necrosis, and ulceration are limited to the colon. Clusters of typhoid bacilli may be found in these nodules. These are usually irregularly scattered, are not limited to a hyperplasia of the lymph-nodules, and should be distinguished from simple nodular hyperplasia with ulceration.³

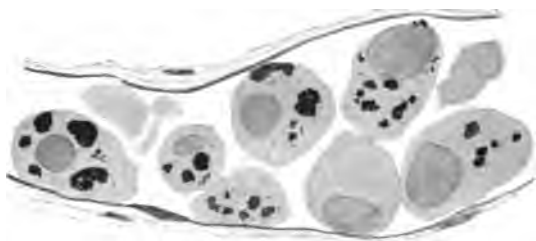

FIG. 141.—PHAGOCYtic AND NECROTIC CELLS IN LYMPH-VESSEL NEAR PEYER'S PATCH IN THE WALL OF THE INTESTINE IN TYPHOID FEVER.

Mesenteric Lymph-nodes.—The mesenteric nodes undergo changes similar to those in the nodules of the intestines, and are usually affected in a degree corresponding to the intensity of the intestinal lesion.

The nodes are at first congested and succulent; then there is a production of lymphoid cells and large cells as in the intestinal nodules, and the node becomes enlarged. When the enlargement has reached its full extent, congestion diminishes, and the cells begin to degenerate. The degeneration may take place slowly, and then the node gradually returns to its normal condition; or more rapidly, and then little foci of necrotic, purulent material are formed. If the patient recover the small foci are absorbed, leaving a fibrous cicatrix; the larger foci may become dry, necrotic, and enclosed in a fibrous capsule. Intense exudative inflammation may occur in the nodes, which may be densely infiltrated with serum, fibrin, and pus.

The Spleen.—In nearly every case of typhoid fever the spleen is enlarged. This enlargement begins, as a rule, soon after the commencement of the disease, increases rapidly until the third week, remains stationary for a few days, and then diminishes. The organ is congested,

¹ Mallory, *Journal of Experimental Medicine*, vol. iii., p. 611, 1898.

² For a study of the distribution of typhoid ulcers see Baer, *Am. Jour. Med. Sci.*, vol. cxxvii., p. 787, 1904.

³ See Whipple, *Johns Hopkins Hosp. Bull.*, vol. xvii., p. 281, 1906.

of dark red color, and of firm consistence while it is increasing in size. After it has reached its maximum size, its consistence becomes soft, and there is a considerable deposit of brown pigment. The enlargement appears to be due to congestion and hyperplasia.

Mallory describes proliferation of endothelial cells, especially in the blood-vessels and pulp spaces, and the formation of venous thrombi.

In rare cases the softened spleen ruptures, with an extravasation of blood into the peritoneal cavity. There may be infarctions of the spleen, which sometimes soften and may apparently lead to peritonitis.

The Liver.—The liver may present no apparent lesion. It is, however, frequently large, pale and flabby, and in this condition the liver cells may be the seat of simple albuminous degeneration.

Less frequently there are present in the liver very small, soft, grayish nodules (Fig. 142). These focal lesions are sometimes too small to be distinguished by the naked eye. They may be situated about the branches of the portal vein or within the lobule. Some of these nodules consist of masses of small spheroidal cells, which may form a diffuse infiltration along the small veins. Mallory distinguishes two distinct varieties of these focal lesions: one

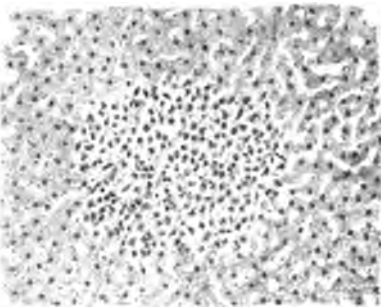


FIG. 142.—FOCAL AREA OF ENDOTHELIAL-CELL PROLIFERATION IN THE LIVER IN TYPHOID FEVER.

formed in the lymph spaces and vessels in the capsule of Glisson by a proliferation of the endothelium (Fig. 143); the other due to obstruction of liver capillaries, in part by the proliferation of endothelium on the spot, in part by emboli of endothelial-cell origin, which are derived through the portal circulation from the vessels of the spleen and intestine. Necrotic changes may develop in and about these focal cell accumulations.

Simple focal necroses of the liver and of other viscera, due to the action of toxic substances in the body fluids, may occur in typhoid fever as in many other infectious diseases.¹

While small foci of cell proliferation may be present in the *kidneys* as well as in other viscera, their occurrence is neither so frequent nor so characteristic as in the liver.

In typhoid fever as in other infectious diseases toxæmia may be manifested by disturbances in the circulatory, respiratory, and heat-regulating mechanism, and in general metabolism, as well as by manifest lesions, such as albuminous or other degeneration of parenchyma cells throughout the body, and alterations leading to leucocytosis.

¹For fuller details of studies on these focal lesions in typhoid and other infectious diseases, consult Mallory, *loc. cit.* Reed, Johns Hopkins Hosp. Rep., vol. v., p. 1895. Flechner, *ibid.*, vol. vi., p. 259, 1897.

Secondary Lesions.

In addition to the more characteristic lesions of typhoid fever which we have described, there are several of secondary or complicating nature. These are of sufficiently frequent occurrence in the disease to require brief mention. They are in part due to the direct action of the typhoid bacillus or its soluble poisons; in part, however, are brought about by secondary bacterial infections.¹

THE DIGESTIVE ORGANS.—In the *intestine* there may be gangrene, sometimes involving the tissues about the ulcers, sometimes apart from these. There may be croupous inflammation of the intestinal mucous membrane of either the large or small intestine. A slight peritonitis sometimes accompanies the intestinal lesion. A severe peritonitis is usually due to perforation, less frequently to ulcers which reach the serous coat, but do not perforate. When there is infiltration of the serous coat with the new cell growth, described above, peritonitis may be associated with a production of little gray nodules of the same character throughout the peritoneum. In-

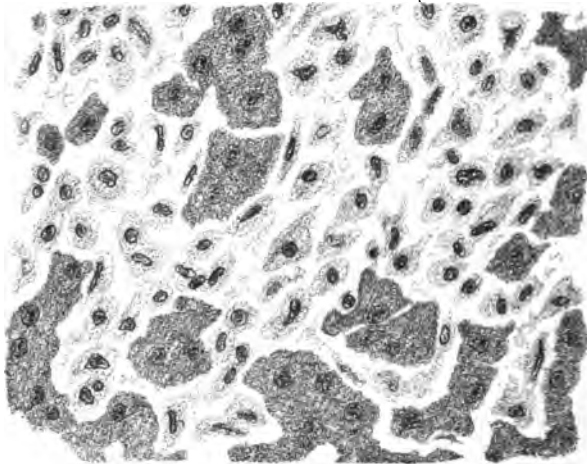


FIG. 143.—HYPERPLASIA OF ENDOTHELIUM IN THE LIVER IN TYPHOID FEVER.
This cut shows a more highly magnified portion of the focal lesion in Fig. 142.

farctions of the spleen, inflammation of the ovaries, and perforation of the gall-bladder are sometimes the inciting factors in peritonitis.

Hæmorrhage from the intestines may be slight and due to the inflammatory swelling and congestion of the mucous membrane; or it may be due to the ulceration of the follicles and opening of the blood-vessels, and is then often profuse.

There may be hyperplasia of the tonsils and of the lymphoid tissue at the base of the tongue. Gangrenous ulcers of the sides and floor of the mouth may be present. Catarrhal and croupous inflammation of the pharynx may be associated with superficial or deep ulceration. Inflammation of the *parotid* leading to suppuration is not infrequent. The *submaxillary gland* may be similarly affected. Enlargement and induration of the *salivary glands* and of the *pancreas* in typhoid fever have been described and are believed to be due to hyperplasia of the gland cells with accumulation of their secretion. This may be followed by degeneration.

THE CIRCULATORY ORGANS.—The *heart* in many cases is the seat of albuminous, fatty, or hyaline degeneration, or of pigmentation. Myocarditis, endocarditis, and pericarditis are of occasional occurrence. Thrombi may form upon the valves or in the

¹For bibliography of the extra-intestinal lesions induced by the typhoid bacillus, see *Howard*, Philadelphia Monthly Med. Jour. vol. i., No. 7. p. 402, 1899.

heart cavities, and detached fragments of these may be lodged as emboli in various parts of the body. The *arteries* may be the seat of acute inflammation. If this involve the intima, an occluding thrombus may be formed which may lead to gangrene of the part supplied by the vessel. Thrombosis of the *veins* is common, and especially frequent in the femoral vein late in the disease.¹

THE RESPIRATORY ORGANS.—The *larynx* is frequently the seat of catarrhal inflammation, with or without superficial erosions. Less frequently there is croupous inflammation, followed in some cases by destructive ulceration; œdema of the glottis occasionally occurs.

The Lungs.—Catarrhal inflammation of the large bronchi is very common. Broncho-pneumonia occurs in two forms. There may be a severe inflammation of most of the bronchi of both lungs, with cellular infiltration of the walls of the bronchi and zones of peribronchitic pneumonia; or there may be an intense general bronchitis, with lobules of the lung corresponding to obstructed bronchi, either collapsed or inflamed, or both.

From the long-continued recumbent position of the patients, the posterior portions of the lungs become congested, dense, and unœrated. Sometimes, in addition to this, irregular portions of the lungs become hepaticized. Less frequently there is acute lobar pneumonia. Infarctions are not uncommon, and gangrene occasionally occurs, either associated with lobular pneumonia or with infarctions, or as an independent condition. Fibrinous pleurisy and empyema are not infrequent.²

THE GENITO-URINARY ORGANS.—The *kidneys* are occasionally the seat of an acute inflammation. Catarrhal and croupous and nodular inflammation of the *bladder* may occur. Hæmorrhage and gangrenous inflammation in the *ovaries* have been recorded; the uterus may be involved.³ *Orchitis* and *epididymitis* may develop during convalescence.⁴

THE NERVOUS SYSTEM.—In addition to chromatolytic changes in the ganglion cells which are common to many infectious diseases,⁵ there may be thrombosis of the venous sinuses and obliterating endarteritis. Acute meningitis is rare.⁶ Degeneration and inflammation of the peripheral nerves may occur.

SUPPURATIVE INFLAMMATION may occur in almost any part of the body in typhoid fever. This may be in the form of boils or of deep abscesses. Post-pharyngeal supuration is often one of the most serious of these complications. Post-typhoid bone lesions are often important.⁷

SEPTICÆMIC FORMS OF TYPHOID FEVER WITHOUT CHARACTERISTIC LOCAL LESIONS.

Typhoid fever may occur without the characteristic intestinal and associated lesions. In this septicæmic type of the disease there may be no demonstrable lesions other than those which are due to the toxæmia.⁸ On the other hand, inflammatory processes in the viscera—lungs, kidney, spleen, etc.—may be dependent on the presence of the typhoid bacillus. The lesions in such cases are not, so far as we yet know,

¹ See an analysis of forty-two cases of venous thrombosis in typhoid fever, *Thayer*, Trans. Assn. Am. Phys., vol. ix., p. 164, 1904.

² For pulmonary complications see *Robinson*, Proc. Phila. Path. Soc., vol. viii., p. 141, 1905

³ *Lartigau*, New York Med Jour., vol. lxxi., p. 944, 1900, bibl.

⁴ See *Kinnicull*, Trans. Assn. Amer. Phys., vol. xvi., p. 145, 1901.

⁵ For a study of ganglion cells in cases of typhoid fever see *Nichols*, Jour. of Exp. Med., vol. iv., p. 189, 1899, bibl. See also *Ewing*, "Studies on Ganglion Cells," Archives of Neurology and Psychopathology, vol. i., p. 263, 1898.

⁶ For study of typhoid meningitis see *Cole*, Johns Hopkins Hosp. Reports, vol. xii., p. 379, 1904.

⁷ *Parsons*, Johns Hopkins Hosp. Rep., vol. v., p. 417, 1895. For a study of bone-marrow in typhoid and other infections see *Longcope*, Proc. Phila. Path. Soc., vol. viii., p. 49, 1905.

⁸ Consult in this connection, for cases and bibl., *Chiari*, Zeitschrift f. Heilkunde, 1897; *Lartigau*, New York Med. Jour., vol. lxx., p. 158, 1899; also Johns Hopkins Hosp. Bull., April, 1899; *Ophuls*, N. Y. Med. Jour., May 12th, 1900.

characteristic, and the post-mortem diagnosis depends largely upon the identification of the bacillus.¹

DISTRIBUTION OF THE TYPHOID BACILLUS IN THE BODY IN TYPHOID FEVER.

In the early stages of the disease the bacillus may be found in the lymphatic structures of the intestines and in the mesenteric lymph-nodes and the spleen. It may be present in lesions involving the bone-marrow, kidney, liver, lungs, pleura, uterus, testicle, and in the rose spots of the skin,² as well as in the blood, where it may be found in a large proportion of cases.³ Typhoid bacilli have been found in the urine in about 20 per cent. of cases in the third and fourth weeks, and in the bile, and may persist in both of these and in the fæces long after the establishment of convalescence.⁴ They may be found, though not in such abundance as was formerly assumed, in the intestinal contents after the disease has become well established.⁵

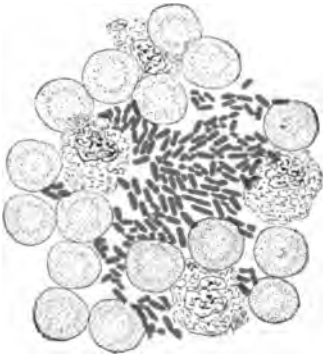


FIG. 144.—CLUSTER OF TYPHOID BACILLI IN THE SPLEEN.

Their abundance here appears to depend somewhat upon the degree of intestinal ulceration. In the viscera they are apt to occur in larger and smaller masses or clusters (see Fig. 144). The typhoid bacillus may be transmitted through the placenta to the fœtus.⁶

Typhoid bacilli may be present alone or in association with other germs in the foci of suppuration which so frequently complicate typhoid fever, also in the exudate in inflammations of the serous membranes and in the endocardial vegetations.⁷

Mixed Infection.—Some of the inflammatory complications which occur in typhoid fever are due to the growth of the bacillus in unusual places in the body; but many of them are due to a secondary infection with other germs, notably with the pyogenic cocci,⁸ also with the colon bacillus and the pneumococcus.⁹

¹ For summary of studies on the typhoid bacillus and typhoid fever, with bibliography, consult *Dunbar*, "Ergebnisse der allg. Aetiologie der Menschen- u. Thierkrankheiten," Jahrg. I., Abth. 1, p. 605, 1896.

² See *Pratt*, *Jour. Bost. Soc. Med. Sci.*, vol. iii., p. 170, 1899.

³ See *Coleman* and *Buxton*, *Jour. Med. Res.*, xvi., 83, 1909.

⁴ *Gwyn*, *Johns Hopkins Hosp. Bull.*, vol. x., p. 109, 1899; also *Curschmann*, on typhoid cystitis, *Münchener med. Wochenschr.*, October 16th, 1900.

⁵ *Hiss*, *Med. News*, May, 1901.

⁶ Ref. *Lartigau*, *New York Med. Jour.*, vol. lxxi., p. 944, 1900.

⁷ See *Flexner*, *Jour. of Path. and Bact.*, vol. iii., p. 202, 1895, and *Johns Hopkins Hosp. Reports*, vol v., p. 343; also *Macé*, "Traité de Bactériologie," 1901.

⁸ For full consideration of the pyogenic powers of the typhoid bacillus, consult *Dmochowski* and *Janowski*, *Ziegler's Beitr. z. path. Anat.*, etc., Bd. xvii., p. 221, 1895.

⁹ *Keen*, "Surgical Complications of Typhoid Fever," 1898. *Hare*, "The Medical Complications of Typhoid Fever," 1899.

MODES OF INFECTION WITH THE TYPHOID BACILLUS.

Infection with the typhoid bacillus seems usually to occur through the gastro-intestinal canal. In very many cases the bacilli are conveyed by means of food, especially of milk and drinking-water, which have been polluted with the excretions—fæces and urine—of persons suffering or convalescent from the disease. Many serious epidemics of typhoid fever have been traced to pollutions of milk and drinking-water from such sources.¹

Oysters which have been taken from grossly polluted waters, as near sewer openings, have been the means of conveying the germs.² There is abundant evidence that flies convey the infectious material from undisinfected discharges.³

In milk the typhoid bacillus not only remains alive for long periods, but undergoes active multiplication. It may remain long alive in water but in steadily diminishing numbers.⁴ In the soil and when dried it may remain alive for months. Frozen in ice it has been found alive after more than three months, but here also the bacilli are gradually reduced in number and finally die out. It is readily killed by exposure to strong sunlight.

Typhoid Carriers.—While the presence of typhoid bacilli in the bile and gall-bladder has been recognized for some time, it is only comparatively recently that it has become definitely and widely known that the typhoid bacilli may remain in the gall-bladder for many years. Park states that from 1 to 5 per cent. of typhoid convalescents may continue to pass typhoid bacilli for years.⁵ In these cases the bacilli may be continually discharged in the fæces. Such persons are called "typhoid carriers" and if they are of uncleanly habits or are engaged in handling foods as cooks, milkmen, etc., may lead to the infection of many persons.

IMMUNITY AND PREVENTIVE INOCULATIONS.

One attack of typhoid successfully overcome gives a certain measure of protection, though this is not absolute, against another. Animal experiments have shown that it is possible to secure immunity against deadly doses of typhoid bacilli, either by the inoculation in increasing amounts with living typhoid-bacillus cultures, or by the injection of suspensions of the bodies of the dead bacilli. The type of immunity thus secured seems to be the bactericidal and bacteriolytic. While antitoxic substances are formed they do not appear to be of great practical significance.⁶

Preventive inoculations have been practised on a large scale in man by the method

¹ *Freeman*, New York Med. Rec., Mar. 28th, 1896, bibl.; also *Vaughan*, Jour. Amer. Med. Assn., Apr. 19th, 1902, p. 979. For résumé with bibl. of viability of typhoid bacillus under various conditions see *Wheeler*, Jour. Med. Res., vol. xv., p. 269, 1906.

² *Freeman*, Albany Med. Annals, vol. xviii., 1897, bibl.; *Mooney*, Revue d'Hygiène, t. xxii., pp. 12, 102, 193, 1900; *Herdman* and *Boyce*, Thompson Yates Laboratories Report, vol. ii., supplement, 1899.

³ See reference, p. 151; also report on typhoid fever in U. S. Military Camps during Spanish War of 1898, by *Reed*, *Vaughan*, and *Shakespeare*, 1900; also experimental study by *Ficker*, Arch. f. Hygiene, Bd. xlvi., 1903, p. 274.

⁴ See *Jordan*, *Russell*, and *Zeit*, Jour. Inf. Dis., vol. i., p. 641, 1904; also *Russell* and *Fuller*, *ibid.*, Suppl. No. 2, Feb., 1906, p. 40.

⁵ For an account of an interesting example of a typhoid carrier, see *Park* and *Williams*, Pathogenic Bacteria," p. 237, 1910.

⁶ For a suggestive study of the problems of immunity in typhoid fever see *Ewing*, Proc. Phila. Path. Soc., vol. viii., p. 65, 1905.

of Haffkine with apparently favorable results. In this method cultures of the bacillus are killed by heat and an emulsion in salt solution is injected subcutaneously.¹

There is a slight and temporary local and general reaction which may be manifested with diminished intensity on the subsequent injections made after a few days' interval.

As the result of this method it has been found both by the English and by the German observers of the effects in the army and among attendants upon typhoid cases, that considered in a large way and comparing over a hundred thousand cases injected with dead bacilli with equal numbers not injected and exposed to similar conditions, there were fewer cases of typhoid among the inoculated than in the other group, and the disease when occurring in an inoculated subject was likely to be less severe in type than among the others.

In the United States more recently this method of preventive inoculation has been practised on a large scale in the army with favorable results.²

AGGLUTININS, PRECIPITINS, AND OPSONINS.

We have seen in an earlier section of this book (p. 179) that in the adaptation of a living body to certain alien organic substances, among which are bacteria and their toxins, the serum of the adapted—or in the case of micro-organisms, of the immunized—individual may contain substances which are *agglutinative* for the particular species of micro-organism involved. By the use of this phenomenon of agglutination, a method of clinical diagnosis of considerable value has been devised and much employed especially in typhoid fever.³

Specific *precipitins* also are formed in the adaptation of the organism to the typhoid bacillus.⁴

Opsonins are formed in animals artificially immunized to the typhoid bacillus and also in man during typhoid fever. But determination of the opsonic index is difficult owing to the rapid lysis of the bacilli in the serum and in the phagocytes.

The Typhoid and Colon Bacillus.

Much difficulty has been encountered in distinguishing between the typhoid bacillus and various forms of the colon bacillus when they occur together, as may be the case in contaminated water or in the dejecta of persons suffering from typhoid fever. As a result of this difficulty a very close relationship has been assumed between typhoid and colon bacilli. This assumption is not wholly justified by the facts, since many of the biological as well as some of the morphological characters of the two are quite dissimilar.

The difficulty in distinction is largely limited to the identification of colonies on the common media usually employed in the gelatin and agar plates. Hiss has shown how by a slight modification of the common methods the growth of each form is quite characteristic, so much so that pure cultures may be made from the first mixed plates without difficulty.⁵ When once the two forms are separated, distinguishing characters are readily demonstrable.⁶

Method of Staining the Typhoid Bacillus.

The bacilli from artificial cultures stain readily with the ordinary anilin dyes, such as fuchsin and methylene blue. In sections, however, they do not stain so readily.

¹ See for a review of this method, *Wright*, Practitioner, Mar., 1904, and Brit. Med. Jour., Nov. 12th, p. 1433, 1904.

² See *Russell*, Johns Hopkins Hosp. Bull., 1910, xxi., 83.

³ For further details of agglutination we refer to the works on clinical pathology, and for bibliography to *Craw*, Jour. of Hygiene, vol. v., p. 113, 1905. For a summary see *Wells*, "Chemical Pathology."

⁴ *Norris*, Jour. Inf. Dis., I., 463, 1904; .

⁵ *Hiss*, Jour. Exp. Med., vol. ii., p. 677, 1897; Jour. Med. Research., vol. viii., 1902, p. 148; also *Hiss* and *Russell*, Med. News, Feb. 14th, 1903.

⁶ For a study of agglutinative reactions of the colon-typhoid group see *Bruns* and *Kayser*, Zeitsch. f. Hyg. u. Infkr., vol. xliii., 1903, p. 401, bibl.

They are decolorized by Gram. They may be stained by *Ziehl's solution* (see p. 258). Stain for half an hour, decolorize in alcohol, clear in oil of cedar, mount in balsam. The decolorization in alcohol should be carefully done to avoid the removal of too much color. Flexner recommends the staining in *Löffler's methylene-blue solution* for two hours; then put in acetic-acid solution 1:1,000 for several minutes; dehydrate in absolute alcohol; clear and differentiate in oil of cloves; mount in balsam. The aim in both of these methods is to leave the nuclei faintly colored, but not so much so as to conceal the clusters of more deeply stained bacilli.

BIBLIOGRAPHY OF TYPHOID.—For a *résumé* of the studies on the typhoid bacillus and its relationship to this disease see *Neufeld, Kolle and Wassermann's "Handbuch der Mikroorganismen,"* Bd. ii., p. 204. For studies on various phases of typhoid infection see *Johns Hopkins Hosp. Rep.*, vol. viii., 1900.

Paratyphoid.

Recently a group of cases of continued fever has been recognized which gives the general clinical picture of typhoid fever, but in which the serum does not agglutinate the typhoid bacillus, and cultures reveal a bacillus in some respects resembling but not identical with the typhoid bacillus, and apparently intermediate between this and the *B. coli communis*. This bacillus has been called the paratyphoid bacillus, and it is agglutinated by the serum of the cases in which it occurs. The intestinal and other lesions of this disease, which is called paratyphoid, so far as they are known, are not those characteristic of typhoid fever. The reports of autopsies are not yet numerous enough to furnish reliable data as to lesions which thus far have been slight and apparently insignificant.¹ The limitations of this book do not permit us to enter in detail into the subject of paratyphoid and its bacillus, in which considerable uncertainty still prevails.² Regarding the value and significance of the agglutination test the reader should consult works on clinical diagnosis.

DYSENTERY.

This form of infectious colitis is regularly associated with and doubtless incited by bacilli of the colon-typhoid group, *Bacillus dysenteriae* or *Shiga's bacillus*. It is a short rod, rounded at the ends, staining easily, decolorized by Gram's method, growing readily in cultures. There are several types of dysentery bacilli having somewhat different biological characters.³

For the lesions of this disease see page 677.

ASIATIC CHOLERA.

Asiatic cholera is a disease incited by the growth and proliferation in the intestines of a slightly curved or spiral-shaped bacterium, which is called the cholera spirillum—*Spirillum cholerae Asiaticæ* (*Vibrio cholerae Asiaticæ*). This organism in the early and active stages of the disease may be present in enormous numbers in the contents of the small intestine, often penetrating the mucosa. It is usually confined to this situation. Its deleterious effects upon the body appear to be largely due to the production of toxic substances, which in addition to

¹ See *Wells and Scott, Jour. of Infec. Dis.*, vol. i., 1904, p. 72; also *Pratt, Bost. Med. and Surg. Jour.*, vol. cxlviii., p. 137, 1903.

² For a *résumé* of this subject, see *Libman, Jour. of Med. Research*, vol. viii., 1902, p. 168; also *Fox, Bull. Univ. Penn.*, vol. xviii., p. 52, 1905, and *Proescher and Reddy, Arch. Int. Med.*, v., 263, 1910, bibl.

³ See *Hiss and Zinsser, Text-book of Bacteriology*, p. 433, 1910.

serious intestinal irritation or lesion may on absorption incite those systemic disturbances which characterize profound toxæmia.

LESIONS OF ASIATIC CHOLERA.

In some cases of cholera there are no marked changes to be found after death, and in no case are the lesions distinctive of this disease.

If death occur during the invasion of the disease or in the stage of collapse, the appearances in the more marked cases may be summarized as follows:

The bodies may remain warm for some time, and the temperature may rise for a short time after death. The rigor mortis usually begins early and lasts for an exceptionally long time. The muscles sometimes exhibit a peculiar spasmodic twitching before the rigor mortis sets in, especially the muscles of the hand and arm.

The skin is of a dusky gray color; the lips, eyelids, fingers, and toes are of a livid purple. The ends of the fingers are shrivelled, and the cheeks and eyes sunken.

The Brain.—The sinuses of the dura mater are filled with dark, thick blood. The pia mater may be normal, or œdematous, or ecchymotic, or infiltrated with fibrin. The brain is usually normal, but may be dry and firmer than usual.

The lungs are retracted and anæmic, the pleura may be dry or coated with fibrin. **The heart** is normal. **The peritoneum** may be dry or coated with a layer of fibrin.

The stomach is usually unchanged, but may be the seat of catarrhal inflammation. **The Small Intestine.**—There may be ecchymoses in the mucous membrane; the mucous membrane may be soft and œdematous; there may be general congestion, or the congestion may be confined to the peripheries of the solitary and agminated nodules, and these nodules may be swollen; or there may be croupous inflammation and superficial necrosis. All these changes are usually most marked at the lower end of the small intestine. There is apt to be post-mortem desquamation of the epithelium. The characteristic rice-water fluid may be found in the intestines after death, or, instead of this, dark-colored, bloody fluid. **The large intestine** is usually normal, but in some epidemics croupous inflammation occurs in a considerable number of cases.

The spleen may be soft. **The liver** may show small areas of granular or fatty or hyaline degeneration.

The kidneys are often increased in size, with white and thickened cortex and congested pyramids. The epithelium of the cortical tubes may contain coarse granules and fat globules, or be necrotic. The tubes may contain casts and disintegrated epithelium. **The uterus and ovaries** may be congested and contain extravasated blood.

If the patient do not die until the stage of reaction, the body does not present the same collapsed appearance, and there are often inflammatory changes in different parts of the body, especially in the larynx, the lungs, the stomach, and the intestines.

Characters of the Cholera Spirillum.

The cholera spirillum, which was discovered by Koch in 1885, is a curved rod with rounded ends, from 0.8 to 2.0 μ long, asporogenous, aërobic, and motile. When growing under suitable conditions these rods are apt to cling together by their ends, forming S-shaped structures or spirals, often of considerable length (Fig. 145). The organism stains readily and grows abundantly on the ordinary culture media. The life period is short and various degenerative "involution" forms are apt to be present in old cultures. It grows best at about blood heat; growth ceases at about 16° C., but may survive a reduction of the temperature to -10° C. It is quickly killed by drying or by the temperature of boiling water. Acids are inimical to its growth. It may retain its vitality for a considerable time in water. On moist surfaces, such as damp linen, earth, vegetables, or in milk, it may rapidly proliferate.

PATHOGENESIS.—The results of animal experiments with the cholera germ are not in themselves decisive in determining its relationship to this disease, since animals do not react in its presence as man does. However, the constant occurrence of this organism in Asiatic cholera, its absence from the body under other conditions, and the accidental laboratory infections which have several times occurred in men handling pure cultures of the germ, leave no doubt as to its significance as the excitant of this disease.

BACTERIAL DIAGNOSIS.—It is often of the highest importance to determine, at the earliest possible moment, whether or not a suspected case be one of Asiatic cholera or some other form of acute intestinal disorder, so that in the former case the proper measures may be instituted to prevent the spread of the disease. The characters which are developed in cultures of the cholera bacillus enable an expert bacteriologist to distinguish this organism from all other known forms. But the scope of this work does not permit a detailed description of the cultural peculiarities of the germ. Nor should the responsibility of such determinations be assumed without adequate preliminary laboratory experience. By taking together the morphological and biological characters, it is possible, usually on the second or third day, to determine whether the intestinal contents of a suspected case do or do not contain the bacillus of Asiatic cholera.¹

Communicability.—Through milk or water or other uncooked food, contaminated with the dejections of those suffering from Asiatic cholera, epidemics are lighted up and maintained. After drying, there appears to be relatively little risk from cholera discharges. Individual susceptibility plays an important rôle in this as in many other infectious diseases. For during cholera epidemics the spirillum has been found in many instances in the stools of apparently healthy persons. Such "cholera carriers" seriously complicate the problems of public sanitation and quarantine. The elements of susceptibility to Asiatic cholera are not yet understood, though it is commonly assumed that dietetic indiscretions and gastrointestinal disorders may be significant factors in the acquired disposition to the disease.

A certain degree of temporary immunity is acquired through recovery from the disease.



FIG. 145.—SPIRILLUM CHOLERA ASIATICAE.
From a culture.

¹ For a summary of characters of the cholera organism, methods of diagnosis, etc., see *Kolle*, in *Kolle and Wassermann's "Handbuch der Mikroorganismen,"* Bd. iii., S. i., 1903.

TOXIC PRODUCTS AND PREVENTIVE INOCULATION.

Toxic Products.—The toxic substances formed by the cholera spirillum are apparently set free to some extent in soluble form, but are largely such as are stored in the bacterial cell itself—*endotoxins*.

Pfeiffer has shown that the spirillum of Asiatic cholera, put into the peritoneal cavity of an artificially immunized guinea-pig, is quickly immobilized, swells and becomes granular, and soon disappears. A similar effect can be secured in tubes by a mixture of the immune serum and fresh serum to which the spirilla are added. This lytic effect of the immune serum upon the bacteria may be used as a test, on the one hand, of the specific character of a suspected spirillum; and, on the other, with a definitely known spirillum the lytic action of the serum in a suspected case of disease may be valuable as a diagnostic test.

This bacteriolytic action of specific sera is not peculiar to the so-called anti-cholera serum, but has been observed in other cases—for example, in typhoid serum with the typhoid bacillus. Its nature and its bearing on immunity have been considered in an earlier section of this book (see p. 170).

Agglutinative substances are also developed in Asiatic cholera which may be of value in diagnosis.

Preventive Inoculation.—A large amount of work has been done looking toward artificial immunization of man against Asiatic cholera in the East, and preventive inoculation practised by the method of Haffkine appears to have given encouraging results. This method consists in the subcutaneous injection of cultures of the cholera bacillus; first, those whose virulence has been diminished, and then, those in which the virulence has been exalted by artificial means.

But the Haffkine preventive inoculation with living cultures has been in a large measure superseded by the injection of a small amount of a fresh agar culture killed by heat. The dose is repeated after a few days. There is moderate local and general reaction to the injections. The serum of persons thus twice injected, after two or three weeks, may show the development of bactericidal substances exceeding in efficiency those present during convalescence from the disease. Such an active, artificial immunity may last for many months. The practical result of this form of preventive inoculation on a large scale in Japan has been a considerable reduction in the proportion of cases in the protected groups, as compared with others similarly exposed, as well as a reduction in the mortality of those who in spite of the protective attempt contracted the disease.¹

Other Spirilla Resembling the Cholera Spirillum.

There are several fairly distinct forms of spirilla, some of which appear to be related to the cholera organism, which have been occasionally found in various situations. One of these is the so-called *Vibrio proteus* or spirillum of Finkler and Prior. This organism was found by these observers in the dejecta of persons suffering from

¹ For a study of protective inoculations against Asiatic cholera see *Strong*, Bureau of Govt. Laboratories, Dept. of the Interior, Biological Laboratory, No. 16, Sept., 1904.

cholera nostras, shortly after the discovery by Koch of the cholera spirillum, which at first it was thought closely to resemble. The cultural characters, however, abundantly suffice to differentiate the organisms. The *Vibrio proteus* is slightly pathogenic for certain lower animals, but not for man.

Several forms of spirilla of somewhat similar general characters have been found in various situations; thus in cheese, by Denecke, *S. tyrogenum*; in a chicken epidemic and in sewage, by Gamaleia and by Pfuhl, *Vibro Melschnikovi*; in the dejecta during a cholera epidemic at Massawah, *Vibrio Massawah*, etc. *Spirillum sputigenum*, of frequent occurrence about the teeth and in the saliva of healthy persons, is not pathogenic.

TUBERCULOSIS.¹

Tuberculosis is an infectious disease characterized by inflammatory and necrotic processes in the body and incited by the presence and growth of the *Bacillus tuberculosis* (tubercle bacillus). The most distinctive morphological feature of tuberculosis is the development under the influence of the tubercle bacillus of larger and smaller, gray or white or yellow, firm or friable masses of tissue called *tubercles*.

The effect on the body-cells of the presence and growth of the tubercle bacillus varies considerably, depending upon the number and virulence of the germs present, the character of the tissue in which they lodge, and the vulnerability of the individual. In general, it may be said that tubercle bacilli may stimulate the connective-tissue cells in their vicinity to proliferation; or they may excite emigration of leucocytes from blood-vessels and lead to the production of other exudates; or they may cause death of tissue. Thus the phases of inflammation which are excited by the tubercle bacillus are *productive*, *exudative*, and *necrotic*. The tubercle bacillus may incite these changes separately or simultaneously, in the sequence just indicated or in some other; and now one, now another of them may preponderate.

MORPHOLOGY OF THE LESIONS OF TUBERCULOSIS.

Tuberculosis manifests itself most often in the form of an inflammation affecting some one part of the body, as the lungs and bronchial lymph-nodes (the parts most frequently involved in adults), the gastrointestinal tract or the skin—"localized tuberculosis." In a considerable proportion of cases the local lesions induced by the tubercle bacillus are in the form of circumscribed nodules or masses of new-formed cells or tissue which are called *tubercles*, or, if small, *miliary tubercles*.²

Such a localized tuberculosis may retain throughout the characters

¹ Some authors are disposed to class together, under the name *Infectious Granuloma*, lesions induced by micro-organisms, certain phases of which are characterized by a localized, usually slow, nodular growth tending to necrosis. The more important of these are tuberculous, leprosy, syphilitic, and actinomycotic. It may be doubted whether it is wise to group together, under a name suggesting tumor relationships, which do not exist, lesions of such diverse origin and clearly of infectious character.

² The term *miliary tubercle*, which arose from the coincidence in size between small foci of tuberculous inflammation and some forms of millet seed, is now very liberally applied to tubercles which are very much larger as well as to those which are very much smaller than millet seeds. It is convenient to designate a small mass of new tissue formed under the influence of the tubercle bacillus, whatever its minute structure, as a *tubercle granulum* (see Fig. 146). Very frequently two or more tubercle granula are joined together by a more diffuse formation of tubercle tissue to form larger or smaller miliary tubercles—*conglomerate tubercles* (see Fig. 147).

of a local inflammation, or it may be accompanied by the clinical evidences of systemic infection. It may give rise through metastasis to the successive development of tuberculous inflammations in other parts of the body, or to a sudden development of small foci of tuberculous inflammation in many parts of the body at the same time—*general miliary tuberculosis*.

A general infection may occur by the diffusion through the body of bacilli derived from a local tuberculosis, such as tuberculous phlebitis or arteritis, tuberculous inflammation of the thoracic duct, or from the breaking into a vessel of a tuberculous lymph-node. It is probably seldom that a sufficient number of tubercle bacilli enter the blood channels at once to account for the enormous numbers of tubercles which are sometimes found in acute general miliary tuberculosis; but it is not unlikely that, from the newly formed tubercles which develop in the walls of the smaller blood-vessels, new distributions of bacilli may take place from time to time as the tubercles mature. This probability is sustained by the frequent occurrence of miliary tubercles on the intima of the small arteries in the lung for example, as well as by the evidence of differences in age of the individual tubercles in generalized miliary tuberculosis.¹

Diffuse Tuberculosis.—In many cases, however, the lesion is not focal or circumscribed but diffuse, and more or less widely infiltrates or replaces the tissues involved. This is called *diffuse tuberculous inflammation*.

Miliary Tubercles.—Miliary tubercles are small nodules of irregular shapes (Plates IV., VI., and VII.), the smallest hardly visible to the naked eye. The smaller tubercles are gray and translucent; the larger are usually, especially in the central parts, opaque and white or yellow on account of the necrosis which is apt to commence here.

In studying the reaction of the living tissues to the tubercle bacillus it should be always borne in mind that while, as a whole, the lesions produced are quite characteristic, there is still no one structural feature or combination of features of tubercles or tuberculous inflammation which is absolutely distinctive of the action of this bacillus. In doubtful cases the demonstration of the presence of the germ itself may be necessary for the establishment of the character of the lesion.²

The experimental studies in animals, as well as the morphological data gathered from the examination of tuberculosis in man, show that when tubercle bacilli in moderate numbers lodge and develop in the living body one of the early local effects is a proliferation of the connective-

¹ It is well, in the endeavor to understand the occurrence of general miliary tuberculosis or of the less striking instances of distribution of the bacilli, to remember that two varying factors are constantly active and significant: first, the virulence of the bacilli, which may be slight or extreme; and, second, the vulnerability of the infected individual—*i. e.*, his "predisposition"—which also may be slight or extreme. Thus the distribution of bacilli, be these few or many, from an infective focus, may be in different individuals or at different times in the same individual of quite different significance. For a *résumé* of the discussion as to the sudden or gradual origin of miliary tubercles see *Ribbert*, *Deut. med. Woch.*, p. 5, Jan. 4th, 1906.

² The term *tubercle tissue*, which is in common use, indicates a tissue formed under the influence of the tubercle bacillus rather than a tissue which is morphologically characteristic of tuberculosis in distinction from other forms of new tissue.

tissue and endothelial cells.¹ These become larger and polyhedral, with conspicuous nuclei (Fig. 146).

A new reticulum or stroma may form hand-in-hand with the growth

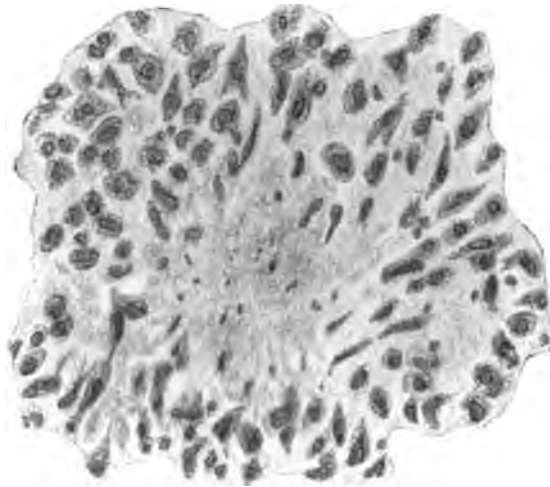


FIG. 146.—A SMALL MILIARY TUBERCLE.

This is growing in the liver; is composed mostly of new-formed polyhedral cells closely packed with little intercellular stroma. At the center, coagulation necrosis is commencing.

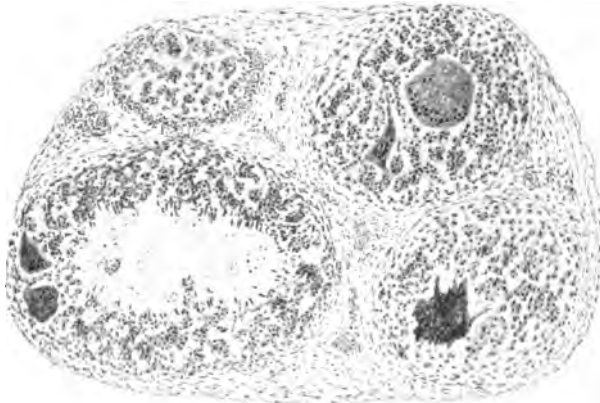


FIG. 147.—A MILIARY TUBERCLE WITH GIANT CELLS.

This tubercle is of the conglomerate type, made up of four granules, the larger one showing coagulation necrosis in the central portion. From the peritoneum.

of these new cells, or the old stroma may persist, adapting itself in form and arrangement to the new conditions.

¹ The studies of *Wechsberg* indicate that in some cases, at least, the first effect of the tubercle bacillus upon the living tissue is destructive, so that the characteristic cell proliferation which follows may not be altogether due to a direct formative stimulus to cell proliferation furnished by the bacillus. See *Wechsberg*, "Beiträge zur Lehr. v. d. primären Einwirkung des Tuberkelbacillus," *Ziegler's Beiträge zur path. Anat.*, Bd. xxix., p. 203, 1901. See further *Herzheimer*, *Ziegler's Beitr.*, Bd. xxxiii., p. 363, 1903, bibl.

Either after the connective-tissue cell proliferation or hand-in-hand with it, or preceding it, or altogether independently of it, emigration of leucocytes and extravasation of serum may take place from blood-vessels in the vicinity of the germs. During the more or less active cell proliferation which occurs under the influence of the tubercle bacillus, multinuclear cells—giant cells—may be formed (Fig. 147), either by persistent nuclear division in growing protoplasmic masses which do not divide into separate cells, or by the coalescence of the bodies of cells already formed.

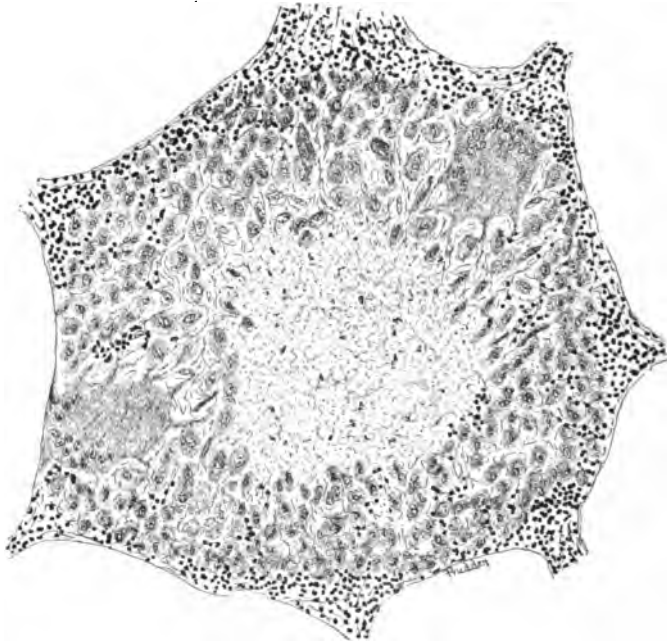


FIG. 148.—A MILIARY TUBERCLE IN THE LUNG.

Showing polyhedral cells, small spheroidal cells, and giant cells, with coagulation necrosis at the centre.

More or less new tissue with numerous small spheroidal mononuclear cells and little stroma may form in and about the tuberculous foci. Blood-vessels are not apt to develop under the influence of the tubercle bacillus. Old blood-vessels are, on the other hand, usually obliterated as the new tissue forms.

Sooner or later under the influence of the tubercle bacillus, there is usually a damage of cell and tissue, which may lead to coagulation necrosis in the new-formed as well as in the old tissue of the infected region. This necrosis is more apt at first to manifest itself in the central portions of the tuberculous foci (Fig. 148) and may progress outward; the nuclei become fragmented or disappear, or fail to stain in the usual way, the protoplasm becomes more homogeneous, and cells and stroma

form at last an irregularly granular mass of tissue detritus which tends to disintegrate (coagulation necrosis, cheesy degeneration, caseation), forming cavities or, if on free surfaces, ulcers.

As coagulation necrosis progresses, the tubercle masses lose the gray translucent appearance which in their early stages they are apt to present to the naked eye and become more opaque and of yellowish white appearance at the centres.

Finally dense fibrous tissue may form in and about foci of tuberculous inflammation, encapsulating or sometimes entirely replacing the more characteristic new-formed structures. It is in this way—by the formation of connective tissue—that such repair as is possible after local tuberculous inflammation, is brought about (Fig. 396, p. 623).

Forms of Tubercles.—Before the discovery of the tubercle bacillus and while knowledge of the lesions of tuberculosis was largely limited to their morphology, it was natural that much stress should be laid upon the variety in structure which the nodular growths called tubercles present, and that elaborate classifications and groupings of tubercles were often deemed important.

With an exact knowledge of the excitant of the new growths and of the varying phases of their development in the body, the morphological peculiarities of tubercles are not now to be regarded as of such extreme significance, since they for the most part indicate simply variations in the local effect of a definite poison. These variations are due, as we have seen, to differences in the amount and intensity of the poison, to the degree of susceptibility of the individual, to the structure of the particular tissue or organ involved, and to the extent and variety of local complications caused by other agencies.

It is, however, usually convenient and sometimes important to recognize structural types in miliary tubercles. Thus they may be composed wholly of small spheroidal cells—“*lymphoid tubercles*,” or of larger polyhedral cells¹—“*polyhedral-celled tubercles*,” or of both forms of cells together and with or without a new-formed stroma; or of any of these combinations with giant cells. Then coagulation necrosis, which may occur in tubercles of any type; development of new dense connective tissue; association with various phases of simple exudative inflammation—all of these contribute to the variety in the structural types of miliary tubercles.

Diffuse Tuberculous Inflammation (Diffuse Tubercle).—1. If the infection with tubercle bacilli be extensive, or if step by step the bacilli are distributed in the tissues about the primary seat of infection, considerable amounts of tubercle tissue of one or other form may develop and pass into the condition of coagulation necrosis, so that at length large necrotic masses, with a comparatively small amount of well-defined tubercle tissue, either diffuse or in the form of granula, may alone remain to indicate the character of old and slowly progressive local infection. This form of lesion is found in the large tuberculous masses in the brain, in the mucous membrane of the bronchi, in large flat masses

¹ Some of the larger cells are regarded by many as so-called “plasma cells” (see p. 74).

on the serous membranes, and in the diffuse, cheesy infiltration of the lymph-nodes, kidneys, ureters, bladder, prostate, testicle, and uterus.

These large areas of tuberculous inflammation are apt to be white or yellow in the central and necrotic portions, which are sometimes dense, compact, and hard, sometimes soft and friable. These areas are not infrequently surrounded by an irregular gray zone of tubercle tissue or by a dense fibrous-tissue capsule.

2. In marked contrast with the phase of diffuse tuberculous inflammation just described, though often associated with it, is that in which the formation of inflammatory exudates is a prominent feature. This exudative form of tuberculous inflammation is best exemplified in the

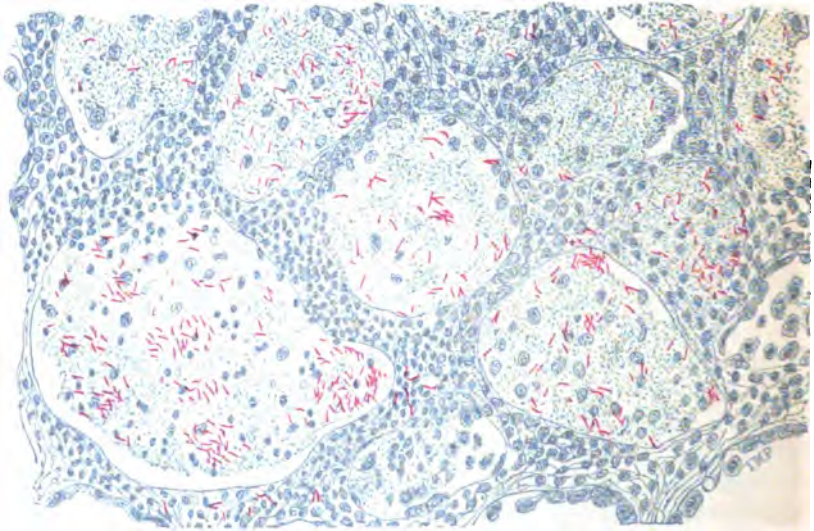


FIG. 149.—EXUDATIVE FORM OF TUBERCULOUS INFLAMMATION SHOWING TUBERCLE BACILLI. From the lung of a child. The size of the bacilli has been slightly exaggerated in the cut.

lungs by some of the forms of acute phthisis (see p. 627). The tubercle bacillus is under certain conditions markedly pyogenic, and when it rapidly develops in the air spaces of the lungs or suddenly gains access to them in large quantities pus, serum, fibrin, and exfoliated or proliferated epithelial cells may collect in and largely fill the air spaces, and then the whole new exudate and the old lung tissue may, over larger or smaller areas, rapidly undergo coagulation necrosis. (Plates VIII. and X.)

Thus in one phase of tuberculous inflammation the intensity and rapidity of the local poisoning by the bacillus do not permit of the formation of organized new tissue at all, but only of exudative products which are apt soon to become necrotic (Fig. 149). Less intense degrees of exudative inflammation are liable to develop in the vicinity of miliary tubercles anywhere in the body.

Characters of the Tubercle Bacillus.

The *Bacillus tuberculosis* is a long, slender bacterium varying in length from 2 to 4 μ (from one-quarter to one-half the diameter of a red blood cell) and in breadth from 0.2 to 0.5 μ . It is frequently more or less curved, and the individual bacilli may cling together end to end, forming threads or chains. It may occur in branching forms.¹

The bacillus (Fig. 150) is stained with difficulty by the anilin dyes (see below), and when stained often presents an irregular beaded or knobbed appearance, due to an unevenness in the coloring of the protoplasm, or to involution changes. It is immobile, and spores have not been demonstrated in it.

At the temperature of the body it can be grown on many of the artificial culture media. The growth of the tubercle bacillus in cultures is very slow in comparison with that of most of the pathogenic micro-organisms. After several weeks' growth it forms

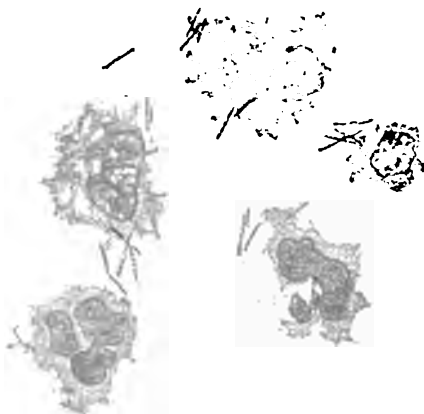


FIG. 150.—TUBERCLE BACILLI IN SPUTUM FROM A CASE OF PULMONARY TUBERCULOSIS Showing the bacilli stained with fuchsin, and pus cells stained for contrast with methylene blue.

dry, scaly masses or thin, wrinkled pellicles on the surface of the media (Figs. 151 and 152.) It requires a certain amount of oxygen for its growth, and thrives best in the dark.

When brought in direct contact with various chemical disinfectants it is readily killed, but when enclosed in mucus, as in sputum, it may be quite resistant. It is killed by an exposure of a few hours to direct sunlight, or if moist is killed by an exposure of from ten to fifteen minutes to 70° C. On the other hand, it may long retain its vitality in the dried condition.²

Cultures can be continued indefinitely from generation to generation with a slowly diminishing virulence which finally is largely lost. Under certain conditions the virulence may be restored or enhanced by successive inoculations into susceptible animals.

The tubercle bacillus does not, so far as we know, grow in nature outside of the

¹ Branching forms of the tubercle bacillus have been frequently seen, and while their significance is not yet altogether clear, the tendency at this time is to separate this organism with the diphtheria bacillus and the so-called streptothrix or actinomyces forms into a group called higher bacteria. Whether, as many think, they are more closely allied to the moulds than to the bacteria, or whether, they should be considered in a class by themselves, is a problem still unsolved. For the present, we may wisely consider the tubercle bacillus as one of the bacteria.

For studies and bibliography on this subject consult *Schulze, Zeitsch. f. Hyg. u. Inf. Krank.*, Bd. xxxi., p. 153, 1899; and *Lubarsch, ibid.*, p. 187.

² For a study of the viability of the tubercle bacillus see *Rosenau, Hyg. Lab. U. S. Mar. Hosp. Ser. Bull.*, 57, 1909.

bodies of men and certain warm-blooded animals. It is thus apparently strictly parasitic.

Inoculation of various animals, especially of guinea-pigs, rabbits, and monkeys, may be followed by lesions similar to those of man.

Methods of Staining the Tubercle Bacillus.

IN FLUIDS.—For the examination of fluids, such as sputum,¹ etc., the material should be spread in a thin layer on a cover-glass, dried in the air, and then passed thrice through the flame (see p. 143).

While, as has been said above, the tubercle bacillus is stained much less easily with the anilin dyes than are most bacteria, it can be deeply colored by the use of accessory

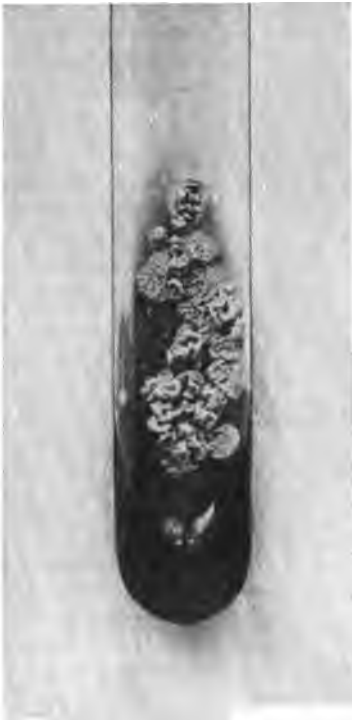

FIG. 151.—CULTURE OF TUBERCLE BACILLUS ON GLYCERIN AGAR.

From tuberculosis in man.

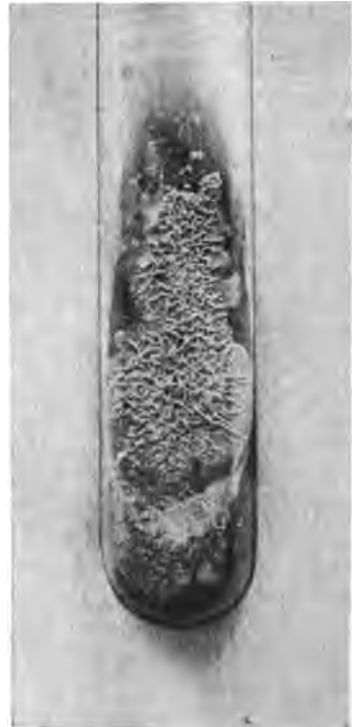


FIG. 152.—CULTURE OF TUBERCLE BACILLUS ON GLYCERIN AGAR.

From tuberculosis in bird.

agents which intensify the stains or render the protoplasm of the bacilli more accessible to them. But when once stained the tubercle bacillus clings with great tenacity to its color in the usual decolorizing agents.

A variety of methods are in vogue for staining the tubercle bacillus, most of them being more or less unessential modifications of the original process formulated by Koch and Ehrlich. Ziehl's solution is among the most useful. This is made by adding to a five-per-cent. aqueous solution of carbolic acid about one-tenth its volume of saturated alcoholic solution of fuchsin. This carbolic fuchsin will keep unchanged for a long time.

¹ It is well in obtaining sputum for examination in cases of suspected pulmonary tuberculosis to secure that which has been raised during several hours, including the early morning discharge.

The prepared cover-glass is floated in a watch-glass or porcelain capsule—specimen side down—on this coloring fluid, and gently heated almost to boiling for from three to five minutes.

The entire specimen is thus completely stained, tubercle bacilli, tissue elements, and other bacteria which may be present, all in the same way. The next step is to remove the color with acid from all the structures which may be intermingled with the tubercle bacilli; the latter, owing to the tenacity with which they retain the color, being but slightly affected. This is done by dipping the cover-glass into an aqueous or alcoholic solution of five-per-cent. sulphuric acid, and shaking it about for a few seconds. Under the influence of the acid the specimen on the cover-glass loses its red color and becomes gray or colorless. It is then thoroughly rinsed in three or four successive portions of alcohol, and finally in water. By this manipulation the red color may be to a slight extent restored.

Care should be taken not to expose the specimen too long to the action of the acid, because then the bacilli may be also partially or completely decolorized. A little experience will enable the experimenter to judge of the proper time for the action of the acid. The specimens may be studied in water with the use of an oil immersion lens and the Abbe condenser, or they may be dried in the air and mounted in balsam before examination.

Inasmuch as not infrequently some other bacteria besides the tubercle bacilli retain a slight red color, it is well, after the specimen is rinsed in water, to float the cover-glass for a few minutes in a dilute aqueous solution of methylene blue, which will replace the red color in all of the bacteria except the tubercle bacilli, which might be mistaken for it, forming a marked color contrast between them. The contrast stain should not be intense.

Pappenheim's Method.—After staining in the hot carbol-fuchsin as above, immerse the specimen without washing in the following solution: 1 per cent. alcoholic solution rosolic acid saturated with methylene blue, adding 20 per cent. of glycerin. In this method of staining the tubercle bacilli are red, while smegma bacilli (see p. 267), are blue.

IN SECTIONS.—Thin sections of tuberculous tissue which has been hardened in alcohol are stained in the same way, except that instead of drying and fixation by heat the sections should be fixed to the cover-glass by means of the albumen fixative (see p. 1034), and then cover-glass and section are manipulated together.

When differentiation is complete, the section is cleared in oil of origanum and mounted in balsam.

For purposes of simple recognition of the bacilli in sections it seems to the writer usually better to have no color in the preparation other than that which the tubercle bacilli possess. But it is often convenient to demonstrate the nuclei of the cells at the same time, and this may be accomplished by staining lightly afterward with a dilute solution of some color which will contrast with that of the bacilli, such as methylene blue.

In the examination of *urine* for the presence of the tubercle bacillus it is well to collect the sediment by means of a centrifugal machine. In the examination of milk or other fat-containing fluids for tubercle bacilli, it is well, after the film has been formed upon the cover-glass and before staining, to rinse with chloroform followed by alcohol, and this by water.

Occasionally one finds in urine acicular crystalline bodies considerably resembling the tubercle bacillus in size and shape, and retaining a red color after the decolorization of the specimen. A careful study of the form, however, will suffice to prevent mistakes.

The only other bacilli which are liable to be mistaken for the tubercle bacilli are the bacillus of leprosy and the so-called smegma bacillus which sometimes occurs beneath the prepuce. The lepra bacillus may be distinguished from the tubercle bacillus by the following differential staining process: If the lepra bacillus be stained for ten minutes in a dilute alcoholic solution of fuchsin (five drops of saturated alcoholic solution of fuchsin to 3 c.c. of water), and then rinsed for a few seconds in a solution of nitric acid (one part) in alcohol (ten parts), it will retain a red color, while under the same treatment the tubercle bacillus remains uncolored. For differential stains for the smegma bacillus see p. 267.

ANTIFORMIN IN SPUTUM EXAMINATIONS.—Antiformin is a patented preparation containing sodium hydroxide and sodium hypochlorite. When mixed with sputum in such proportion that the antiformin is present in about 15 per cent. the sputum is softened and most bacteria except the tubercle bacilli are killed. After the softening of the sputum it is diluted with water or alcohol and spun in the centrifuge, the sediment gathered and respun, the final sediment is used for smears and stained in the usual way. By the use of antiformin and centrifugation a "concentrate" of the bacilli from sputum may be secured for diagnostic inoculation of guinea-pigs.

Varieties of Tubercle Bacilli.

While many of the lower mammalia are susceptible to inoculations with tubercle bacilli derived from man, the bacilli obtained from spontaneous tuberculous lesions in the lower animals may present noteworthy variations in form and growth from the human type. Thus Theobald Smith and others¹ have pointed out marked peculiarities of the bovine bacillus which would lead to the conjecture that though not a separate species it is probably a distinct variety of the organism. Although the cultural characters of the bovine bacillus seem to suffice for its distinction from the human variety, man, especially children, appears to be susceptible to the bovine organism.² Theobald Smith has determined that the bovine bacillus is in general more highly pathogenic for mammals than is the human variety.

Still more marked are the differences between mammalian and avian, or bird tubercle bacilli, and the tubercle bacilli of fish. Whether in this case also the differences are to be regarded as specific or within the limits of variational sway is not yet clear. Although the subject is important from the standpoint of prophylaxis and interesting from the point of view of the variations of bacteria under changes of environment, the attempts by experimental means to convert one form into the other have thus far been too few to lead to definite conclusions.

TOXIC PRODUCTS OF TUBERCLE BACILLI.

While there is evidence that some soluble toxic substances are given off from the tubercle bacillus in its growth and activities, it is to its endotoxins that its chief poisonous capacities seem to be linked.

It has been found that tubercle bacilli which have been killed by boiling or otherwise, when introduced into the body of the rabbit either beneath the skin, or into the serous cavities, or into the blood-vessels and the air spaces of the lungs, are capable, as they slowly disintegrate, of stimulating the cells of the tissues where they lodge to proliferation, and to the production of new tissue morphologically similar to tubercle tissue in its various phases³ (Fig. 153). Necrosis of the new-formed cells may occur, but this differs in some respects from the coagulation necrosis induced under the usual conditions. Dead tubercle bacilli are also markedly chemotactic and capable of causing local suppuration and abscess.

¹ See *Smith*, Jour. Med. Res., vol. xiii., p. 253, 1905; also *Wolbach and Ernst*, Jour. of Med. Research, vol. x., 1903, p. 313, bibl.; also *Ravenel*, Medicine, July and August, 1902; see also reference to *Ravenel*, p. 266.

² See ref. 1, p. 266.

³ For further details concerning the effects of dead tubercle bacilli in the body see *Prudden and Hadenpfl*, N. Y. Med. Jour., June 6th and 20th, 1891, and *Prudden*, *ibid.*, Dec. 5th, 1891. For summary of later work, with bibliography, see *Herrheimer*, Ziegler's Beitr., Bd. xxxiii., p. 363; also *Miller*, Jour. Path. and Bact., vol. x., p. 351, 1905, bibl.

It would seem probable then that while the power of the tubercle bacillus to induce necrosis and the fever which in many cases indicates a systemic intoxication may be due to metabolic products of the living germ, the local lesions characteristic of exudative and productive inflammation may be due to a peculiar bacterial proteid which is set free by the disintegration of the bacilli in the tissues. But the products of autolysis in the necrotic tissue cells may contribute to the toxæmia.

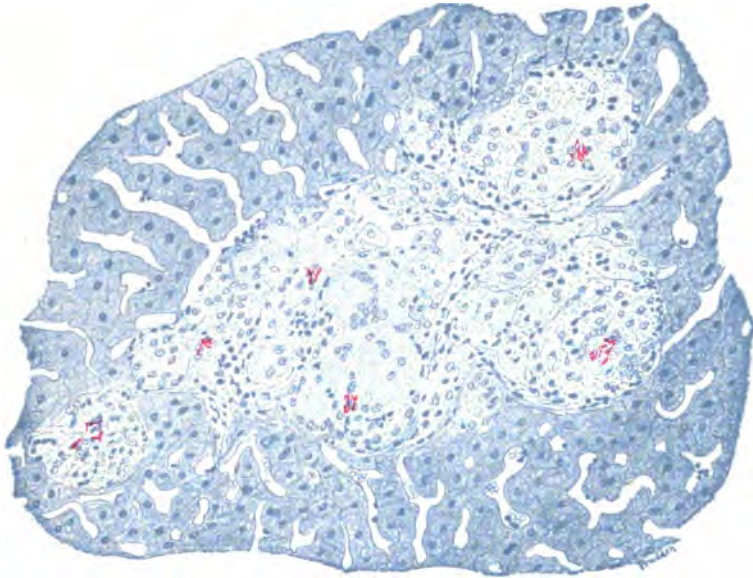


FIG. 153.—INFLAMMATORY NODULE (PSEUDO-TUBERCLE) IN THE LIVER OF THE RABBIT INDUCED BY THE INTRAVENOUS INJECTION OF DEAD TUBERCLE BACILLI. Most of the dead bacilli have disintegrated, setting free the bacterial proteid which has stimulated the new cell growth. A few fragments of the bacilli, however, still remain.

Agglutinating Substances.

The serum of tuberculous animals and men may contain agglutinating substances. The reaction, however, frequently fails and is not at present of much diagnostic value.

Tuberculin.

When the tubercle bacillus is grown on glycerinated nutrient broth certain metabolic products are formed and pass into solution in the fluids. If after some weeks of vigorous growth the germs are separated by filtration and the broth is concentrated by evaporation, a dark brown fluid results which is called *tuberculin*. This substance—at one time believed by many, and still by a few observers, to possess distinct curative properties in certain forms of tuberculosis—has assumed great economic importance on account of its value as a diagnostic agent in bovine tuberculosis. For if administered subcutaneously in small quantity to cattle a marked temperature reaction follows in tuberculous animals, while those which are sound are unaffected. The existence of even very slight lesions may be detected in this way. In man also tuberculin has proved of value in cases in which the efforts to establish a diagnosis

by the usual method have failed. The new tuberculin "T. R." contains the dead bodies of tubercle bacilli.¹

Immunity and Therapeutic Use of Tuberculin in Tuberculosis.

The fact that so large a percentage as from sixty to ninety of human beings dying from all causes have been shown by autopsies to have been at some period and in some measure affected with tuberculosis, while the mortality from tuberculosis as compared with death from all other causes is not far from fourteen per cent. indicates that man enjoys a marked degree of natural immunity to the incursions of the tubercle bacillus. The clinical data are not very convincing as to the acquirement of increased immunity after successfully coping with the disease. However, experiments on animals, those of Trudeau and others, have shown that by the repeated inoculation of small doses of tubercle bacilli of attenuated virulence, rabbits may be largely protected, though not rendered wholly immune, from the full effect of later injections of virulent bacilli. Behring has apparently succeeded by intravenous injections into young cattle of some product or derivative of the tubercle bacillus in rendering them highly, and it is claimed permanently, immune. Similar results have been obtained by others.²

Many attempts have been made to secure artificial immunity in man either by the injection of products of the growth of the tubercle bacillus, or by the use of the dead bodies of the bacilli. Wright and his followers have reported marked success in the use of a form of tuberculin called new tuberculin or "T. R.,"³ which contains the bodies of the dead bacilli, especially in localized tuberculosis. This is administered in accordance with the indications of a rise or fall of the "opsonic index" of the serum (see p. 187), determined by the degree of phagocytosis, the opsonic index marking the immunizing effect of the injection. Trudeau seems also to have obtained favorable results from the artificial immunization with the dead bodies of the bacilli, "T. R.," controlling the administrations of the very potent agent by careful clinical observations.

Altogether, then, it appears that a certain measure of active artificial immunity to tuberculosis may be secured in man. Attempts to secure passive immunity in tuberculosis by alleged antitoxic sera do not seem to have been notably successful.⁴

Complex Factors in the Tuberculous Process.

It is well in studying the characters of tuberculous inflammation to remember that in its progressive phases there are two factors at work: first, those which lead to cell proliferation and new tissue formation, which is apparently a reparative and conservative process; second, those which are inhibitory or damaging or destructive; and, finally, that both sets of factors are commonly active together. It may still be considered doubtful whether the tubercle bacillus furnishes a direct formative stimulus, or whether such is furnished by damaged cells, or whether the cell proliferation may not be an expression of reparative activity in the presence of damaged tissue made possible by disturbed organic control (see p. 351). In any event the new tissue which forms under the influence of the tubercle bacillus apparently owes its morphological as well as biological characteristics to impulses toward tissue formation which are exerted in the presence of agencies—doubtless poisons—restraining within narrow bounds the new connective-tissue growth, no matter how extensive or persistent this may be, and tending constantly to its destruction.

¹ For *résumé* of forms of tuberculin and details of diagnostic tests see *Hiss and Zinsser, Text-Book of Bacteriology*, p. 485, or works on clinical diagnosis.

² See review of animal immunization against tuberculosis, *Pearson, Second Ann. Rept. of the Phipps Inst.*, p. 311, 1905.

³ For a *résumé* of various tuberculin preparations, see *Hiss and Zinsser, "Text-book of Bacteriology,"* 1909, p. 485.

⁴ See for the bearing of the parasitism of the tubercle bacillus on infection and immunity *Th. Smith, Jour. Am. Med. Assn.*, Apr. 28, 1906.

It is interesting in this connection to note that when lesions in many respects similar to those of the ordinary tuberculosis are induced experimentally in animals with dead tubercle bacilli (see above), the poisonous substances leading to necrosis are not produced continually and for indefinite periods, as is the case in infection with living bacilli, but are soon exhausted, so that after a certain amount of initial necrosis the new tissues go on to develop in the usual reparative way, blood-vessels are formed, and healing by a cicatrix under favorable conditions regularly takes place. It is probable that effective healing in tuberculosis in man takes place only after the local production of destructive poison ceases through the death and completion of the lysis or the diminished virulence of the tubercle bacilli present.

On the other hand, it is important to bear in mind that while the formation of new cells and tissue on the part of the body in tuberculosis marks a protective adaptation to new and harmful conditions, the tubercle bacilli themselves are also subject to adaptive changes which on their side are protective. Thus through what has been called selective adaptation of both host and microbe a condition of balanced parasitism may be brought about in which there may be a reduced mortality, but not a reduced morbidity, since in the processes of adaptation the microbe has won capacities for harm which may be very potent and significant in individuals not adapted to it.¹

THE NUMBER OF TUBERCLE BACILLI IN LESIONS.

The number of bacilli which are present in the lesions of tuberculosis is subject to great variation. They are usually abundant in the walls and contents of phthisical cavities, and in tubercle tissue which is undergoing cheesy degeneration and disintegration. In these situations they may be found in myriads, forming sometimes a large part of the disintegrated mass. They are found in cells and scattered among them. Sometimes they are present in considerable numbers in the giant cells of miliary tubercles. In the acute general tuberculosis of children they are often present in large numbers, particularly in the lungs (Fig. 149). They may be found in tuberculous inflammation in any part of the body, and have been seen in the blood. The bacilli are almost constantly discharged in the sputa of patients suffering from pulmonary tuberculosis, often in enormous numbers—from one to four billion in twenty-four hours, according to Nuttall's estimate—and their presence sometimes affords valuable diagnostic aid in early stages of obscure forms of the disease.

Under a variety of conditions, especially in the older tuberculous lesions, the bacilli may not be demonstrable. This apparent occasional absence of the bacilli is probably due either to their disappearance as the process grows older or to some unknown changes which interfere with the ordinary staining procedures.

FREQUENCY OF TUBERCULOSIS IN MAN AND THE LOWER ANIMALS.

Tuberculosis is a very common disease not only of man² but also of many of the lower animals,³ especially of cattle, and inasmuch as the

¹ For a consideration of the mutual relationship of microbe and host see *Th. Smith*, Jour. Amer. Med. Assn., April 28th., p. 1247, 1906.

² Carefully prepared statistics show that tuberculous lesions are present in the body in more than ninety per cent. of the cases examined at autopsies. See for a thorough and suggestive analysis of five hundred autopses *Naegeli*, Virchow's Archiv, Bd. clx., p. 426, 1900; also *Necker*, Verh. Deutsch. Path. Ges., viii., p. 129, 1904. For a study of frequency of tuberculosis in children see *Winkler*, Verh. Deut. Path. Ges., viii., p. 129, 1904.

³ For bibliography of animal tuberculosis see *Eber*, Lubarsch and Ostertag's "Ergebnisse," Jahrg. iv. for 1897, p. 859.

victims of this disease, both men and animals, are apt, as stated above, to throw off enormous numbers of the bacilli in the sputum and other excreta, the germ is widely dispersed in inhabited regions, especially in buildings frequented by uncleanly tuberculous persons or by infected cattle.

Among the lower animals, guinea-pigs, rabbits, monkeys in confinement, and cattle are particularly susceptible to the action of the tubercle bacillus. Although tuberculosis is widespread in man, he is not, as compared with some of the lower animals, particularly susceptible. While the tuberculous process presents some differences in different animal species in rate of development, amount of necrosis, tendency to softening, calcification, etc., the fundamental effects are similar in man and in the lower animals.

PORTALS OF ENTRY, DISTRIBUTION OF LESIONS, AND SOURCES OF THE TUBERCLE BACILLI.

Portals of Entry and Distribution.—The question of the chief portals of entry of the tubercle bacillus has given rise to much discussion and much experiment. So far as the lungs are concerned, in which tuberculosis is common, it has been assumed that infection is most frequently direct, the bacilli gaining access through the respiratory passages to the alveoli. Others have contended that lung infection is most often secondary to the entrance of the bacilli through the gastro-intestinal canal with or without local lesions. Still others believe that tuberculosis of the lung is commonly secondary to tuberculous lesions of the bronchial lymph-nodes, or that the bacilli may enter through the tonsils, or that they often enter through the placenta. To the advocates of the latter views the blood-vessels and lymphatics play a predominant rôle in the distribution of the infective agents.¹

While it is probable that all of these portals of entry are of importance, it would seem well established that direct inhalations are the most frequent occurrence, while entrance through the intestinal mucosa is very common, especially in infancy.²

We may assume, then, that the tubercle bacillus most frequently enters the body through the respiratory organs, including tonsils and pharynx, and through the gastro-intestinal canal. Traumatic infection

¹ For a study of tubercle bacilli in the blood see *Anderson*, Hyg. Lab. U. S. Mar. Hosp. Ser. Bull., 57, 1909.

² For a full discussion of this subject see *Lubarsch*, Fortschr. d. Med., Bd. xxii., pp. 669, 701, 1904. Consult for his views on the intestine as portal of entry for the tubercle bacillus, *Behring*, Deutsch. med. Wochenschr., 1903, p. 689; 1904, p. 193. For experimental tuberculosis in young guinea-pigs with reference to portals of entry see *Bartel* and *Spieler*, Wiener klin. Woch., p. 155, 1905 and p. 25, 1906. For a résumé of studies on the tubercle bacillus and its portals of entry, *Baumgarten*, Verh. Deut. Path. Ges., Bd. ix., p. 5, 1905; *Aufrecht*, "Pathologie und Therapie der Lungenschwindsucht," Wien, 1908; *Ravenel*, Am. Jour. Med. Sci., cxxxiv., 469, 1907. For mode of tubercle-bacillus infection in young see *Westenhoeffer*, Berl. klin. Woch., 1904, pp. 153 and 191. For intestinal origin of pulmonary tuberculosis see *Calmelle* and *Guerin*, Ann. Inst. Pasteur, vol. xix., p. 601, 1905 and *Calmelle*, Medical Record, 1908, lxxiv., 741. For a study of mode of infection of the lungs by way of the mouth and pharynx see *Beitzke*, Virch. Arch., Bd. clxxxiv., p. 1, 1906.

through the skin is of relatively infrequent occurrence, as is apparently the congenital transmission.¹

In adults the lungs, in children the bronchial lymph-nodes, are the most frequent seat of tuberculous lesions.²

Many observations on the occurrence of tuberculous bronchial, cervical, and mesenteric lymph-nodes in persons exhibiting no appreciable tuberculous lesions elsewhere would indicate the frequency of access of the bacilli to the lymph channels without primary lesion at the portal of entry in the pharynx, tonsils, respiratory passages, intestinal mucosa, or elsewhere.³ A considerable percentage of persons dying from other diseases have been found to have tuberculous lesions often healed in the lungs or bronchial lymph-nodes.

Sources of Tubercle Bacilli.—Tubercle bacilli are frequently transmitted to the well from the victims of tuberculosis by means of the sputum which is cast off, allowed to dry, and becomes pulverized and is then inhaled as dust.

But this source of infection is perhaps not as significant as was formerly believed from analyses of material gathered from walls and floors of contaminated rooms. For it has become clear that not all the infectious material which may be cast out of the body as sputum is always readily and speedily transformed into dust. In the drying of the mucus with which much of this material is mingled, a process ordinarily rather slow, the bacteria are closely imprisoned so that only under certain conditions, such as the rubbing and beating of soiled clothing, the shuffle and tread of feet over contaminated floors, dry sweeping, and the like, is the excretion sufficiently comminuted to float in the air as dust. Even when this is the case, it has been found that a large part of such pulverized excreta is still in too large particles to remain long suspended on the air.

This condition of affairs was not appreciated in the earlier studies on dust infection, and in many instances the material called dust, collected in various places for analysis, was evidently not in such form as would have remained long in suspension. Thus it is that while the earlier identification of various pathogenic micro-organisms in the dust of rooms was correct, the inference as to the constant risk of dust infection in such places was frequently at least somewhat overestimated.

On the other hand, Flügge and others⁴ have found that not only in sneezing and coughing, but also in ordinary speech, the secretions of the nose, mouth, and throat may be cast forth in considerable quantity for a distance of several feet, not only in the form of visible droplets, but as a more or less abundant, invisible spray, which may remain sus-

¹ For a study of placental and congenital tuberculosis see *Warthin and Cowie, Jour. Inf. Dis., vol. i., p. 140, 1904.*

² For studies in the frequency, localization, and modes of dissemination of tuberculosis, with special reference to its occurrence in the lymph-nodes and during childhood, see *Harbitz, Jour. Inf. Dis., vol. ii., p. 143, 1905, bibl.* For a study of localization in infants and young children see *Wollstein, Arch. Int. Med., iii., 221, 1909.*

³ See ref. foot note, p. 592.

⁴ For the studies of *Flügge* and his assistants see *Zeitschr. f. Hygiene u. Infkr., vol. xxx., 1899, and vol. xxxviii., 1901.*

pended for from half an hour to several hours, and may be carried for long distances on such slowly moving air currents as are common in inhabited rooms.

Thus, fully virulent, infectious material may be transmitted directly through the air in coughing and sneezing; indirectly through dried infectious sputum ground to dust and floating in the air. Less frequent is the conveyance of tubercle bacilli through soiled utensils. The transmission of this germ through contaminated milk¹ and the meat of tuberculous cattle² is a mode of infection of great importance, especially the use of contaminated milk by young children.³

Whichever way the tubercle bacilli enter the body, whether directly into the lungs, or by the pharynx or tonsils, or through the intestinal mucosa, or in rarer cases through wounds or through the placenta, they are transported by the blood- and lymph-vessels to lymph-nodes or to the tissues, where they lodge and grow and incite the formation of tubercles. These again if in the blood- or lymph-vessels, when they soften and set the bacilli free by ulceration into the channels, afford fresh foci of distribution. So that in cases of disseminated tuberculosis the process of distribution is more or less gradual. In the meantime the progress of the lesions dependent in their topography upon the fortuitous character of the distribution of the infective agent is marked by the protective adaptation of the body-cells expressed by the formation of the tubercles and the development of immunizing substances; while, on the other hand, the bacillus itself is undergoing these adaptative modifications of its own biological characters which are expressed in what we call its virulence.

Statistics show, as we have seen, that in the majority of cases in man the protective agencies of the body suffice to localize the lesions, surround the bacilli by necrotic masses in which they do not flourish, or enclose them in a fibrous envelope. Thus it appears that it is largely the chances of a wide or a continued distribution of the infective agent, or an unusual susceptibility of the host or exalted virulence of the bacilli, or the occurrence of fresh infection, that makes tuberculosis now and then so formidable a malady to man.

While it is not impossible that future research may lead to the development of effective methods of artificial immunization to tuberculosis, it is to preventive measures that we must look for the largest success in the suppression of this scourge of the human race. By proper disposal of the sputum; by providing against aerial dispersion of infective material through unguarded coughing and sneezing; and by such intelligent methods of cleaning and disposal of dust as shall safeguard the respiratory organs; together with an enlightened supervision of the supplies of meat and milk, it should be possible even in crowded communities largely to reduce both the morbidity and the mortality of tuberculosis.

CONCURRENT INFECTION IN TUBERCULOSIS.

A concurrent infection with the tubercle bacillus and the pyogenic micro-organisms is of extreme significance in that phase of tuberculous

¹ Many cases of infection of human beings, especially children, with bovine bacilli, have been reported and in children abdominal tuberculosis and tuberculosis of the cervical lymph-nodes is most frequent. Park estimates that about 10 per cent. of tuberculosis in children under five years is due to bovine infection. See for tables of observations, *Park and Williams*, "Pathogenic Bacteria," p. 323, 1910, and for comprehensive study of bovine and human types of tubercle bacilli, *Park and Krumwiede*, *Jour. Med. Res.*, xxiii, 205, 1910; see also *Lewis*, *Jour. Exp. Med.*, xii., 82, 1910.

² See *Kober*, *Amer. Jour. Med. Sc.*, vol. cxxvi., 1903, p. 684, bibl. For the intercommunicability of human and bovine tuberculosis see *Ravenel*, *Proc. Path. Soc. Philadelphia*, May, 1902; also *résumé* by *Bovaird*, *Med. Record*, vol. lxxvii., p. 283, 1905.

For a study of tubercle bacilli on books see *Mitulescu*, *Zeitschr. f. Hygiene u. Infkr.*, Bd. xlv., p. 397, 1903.

³ For a study on flies and tuberculosis see *Lord*, *Bost. Med. and Surg. Jour.*, vol. cli., p. 651, 1904.

inflammation of the lungs commonly called phthisis.¹ While the so-called cold abscesses may be caused by the tubercle bacillus alone, this germ is not infrequently found under these conditions to be associated with other pyogenic micro-organisms, especially the streptococcus and staphylococcus.²

Bacteria Resembling the Tubercle Bacillus.

There are several species of bacteria which after deep staining resist the decolorizing action of dilute acids. These have been called, collectively, "acid-resisting" or acid-proof bacteria.³ We shall consider only two of these.

THE SMEGMA BACILLUS.—This organism is often present and sometimes in large numbers in the preputial smegma and elsewhere about the external genitals. It so closely resembles the tubercle bacillus in size, shape, and staining reactions that it is liable by morphological examinations alone to be mistaken for it. It has been cultivated on artificial media and is not pathogenic. The smegma bacillus, when stained as above recommended for the tubercle bacillus, resists the decolorizing action of the acid; but it is usually decolorized by prolonged exposure to alcohol, thus differing from either the tubercle bacillus or the leprosy bacillus. But this color reaction is not certain; individual bacilli not infrequently remain unstained. Various special methods for differentiation have been suggested.⁴ In doubtful cases, and when serious operative procedures are dependent upon the bacterial diagnosis, recourse should be had to animal inoculations.

THE "HAY BACILLUS."—This resembles the tubercle and smegma bacilli in form and staining peculiarities. It is called the "hay bacillus" or "grass bacillus" because of its common occurrence upon grass-heads in the fields. It is not pathogenic and is readily cultivated.

Similar organisms have been frequently found in milk and butter, also in the sputum in gangrene of the lung.

Lupus and Other Forms of Tuberculosis of the Skin.

Local tuberculous inflammation of the skin may occur in the form of small nodules or wart-like thickenings, as the result of accidental inoculation. Local skin infection may occur about the orifices of the body in tuberculous persons from contact with secretions or excretions containing the tubercle bacilli, or about sinuses leading to tuberculous abscesses, joints, etc., or in the vicinity of tuberculous lymph-nodes.

A chronic form of tuberculous inflammation which presents special clinical features has long been known under the name of *lupus*.

Lupus.—This form of inflammation most frequently occurs in the skin of the face, but also in the mucous membrane of the mouth, pharynx, conjunctiva, vulva, and vagina. The lesion consists of small, multiple nodules of new-formed tissue, in the cutis or mucosa and submucosa. By the formation of new nodules and a more diffuse cellular infiltration of the tissue between them the lesion tends to spread, and by the confluence of the infiltrated portions a dense and more or less extensive area of nodular infiltration may be formed. There may be an excessive production and exfoliation of epidermis over the infiltrated area, or an ulceration of the new tissue.

Microscopical examination shows the lesion to consist of small spheroidal cells intermingled with variable numbers of larger, polyhedral cells and cell masses, and in

¹ See *Spengler*, *Zeitschr. f. Hygiene, etc.*, Bd. xviii., p. 343, 1894, bibliography. See reference to *Prudden*, p. 631.

² For a study of the simultaneous occurrence of tuberculosis and cancer see *Weinberg*, *Munch. med. Wochenschr.*, p. 1473, 1906.

³ See for *résumé* and bibliography *Abbott and Gilderleeve*, *Trans. Assn. Amer. Phys.*, vol. xvii., p. 37, 1902; also *Rosenberger*, *Proc. Path. Soc. of Phila.*, January, 1904.

⁴ Critical review, with bibl., *Dahms*, *Jour. Am. Med. Assn.*, vol. xxxiv., pp. 983 and 1045, 1900. Consult also *Courie*, *Jour. Exp. Med.*, vol. v., p. 205, 1900.

For the method of *Pappenheim*, which is said to be more reliable than the alcohol decolorization, see p. 259.

many cases giant cells (Fig. 154). In some cases a well-marked reticulum is present between the new cells, and these are often grouped in masses around the blood-vessels. In some cases there is, without previous ulceration, a formation of new connective tissue in the diseased area, and a well-marked cicatrization; in other cases the cells and intercellular substance undergo a disintegration which leads to ulceration. Tubercle bacilli in small numbers may be found in these lesions. In the clinical group of diseases called lupus there are other forms of lesion which are not incited by the tubercle bacillus.

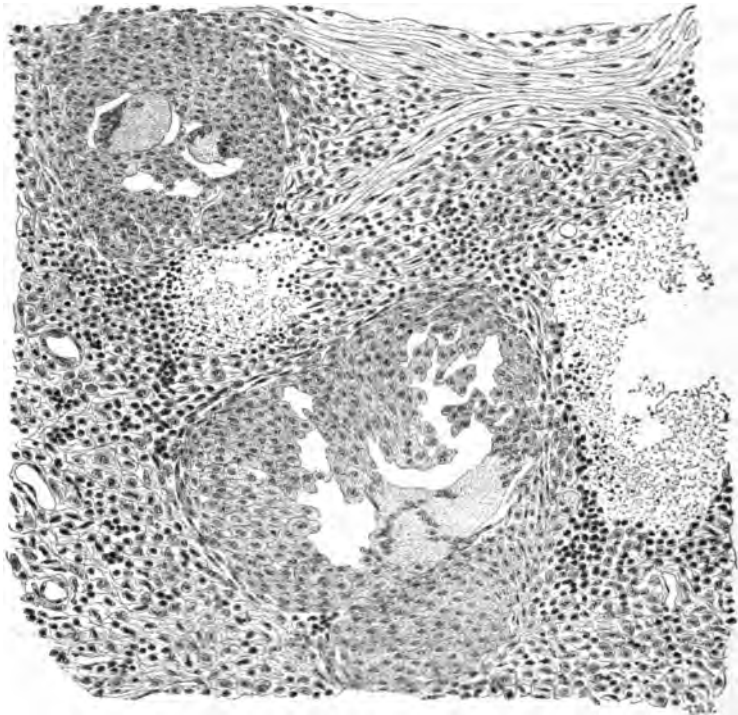


FIG. 154.—LUPUS OF FACE.

Bibliography of Tuberculosis.

The announcement of the discovery of the bacillus tuberculosis by *Koch* was made in the *Berliner klin. Wochenschrift*, 1882, No. 15. A most elaborate and valuable article on the same subject by *Koch* is contained in the "Mittheilungen aus dem Kaiserlichen Gesundheitsamte," vol. ii.

The abundant literature on the subject of the tubercle bacillus which has accumulated since 1882 is for the most part scattered through the German, English, and French journals.

An excellent critical *résumé* of the subject by *Lartigau*, with selected bibliography, may be found in the "Twentieth Century Practice," vol. xx.

In the large work of *Straus*, "La Tuberculose," 1895, the experimental aspects of the subject are fully considered.

In the work of *Cornet*, "Die Tuberculose," together with the general and clinical consideration of the disease, the modes of infection and prophylaxis are set forth, with bibliography. See also *Cornet* and *Meyer*, *Kolle* and *Wassermann's* "Handbuch der Mikroorganismen," Bd. ii., p. 78, 1902. An excellent summary of the tubercle bacillus and its biological characters is in *Kolle* and *Hetsch*, "Experimentelle Bacteriologie und die Infektionskrankheiten," 1906.

LEPRA (Leprosy).

Leprosy is characterized by the development of nodular and sometimes diffuse masses of tissue, consisting of larger and smaller cells of various shapes—spheroidal, fusiform, and branched, with a fibrous stroma—the whole somewhat resembling granulation tissue. The new tissue is most frequently formed in exposed parts of the skin, as the face, hands, and feet, but it may occur in the skin of any part of the body. It is formed more rarely in the subcutaneous connective tissue, in intrafascicular connective tissue of nerves, in the viscera, and in the mucous membranes. The mucous membranes most frequently affected are those of the eye, nose, mouth, and larynx. The nodules may be very small or as large as a walnut, and may be single or joined together in groups or masses. The tissue of the part in which the new formation occurs may be atrophied and replaced by, or may remain intermingled with, the leprous tissue, or it may be hyperplastic. The nodules may persist for a long time without undergoing any apparent change, or they may soften and break down, forming ulcers; but ulceration, except in the mucous membranes, is said usually to occur as the result of injury or unusual exposure. The leprous tissue may change without ulceration into cicatricial tissue, or cicatrization may follow ulceration.

Various secondary lesions and disturbances of nerve function are associated with the formation of leprous tissue in the nerves and central nervous system, but these we cannot consider here.

In all the primary lesions of leprosy, bacilli are said to be present, mostly in the cells, and particularly in the larger transparent spheroidal forms, but sometimes free in the intercellular substance. The bacilli have been found in the skin, mucous membrane of the mouth and larynx, in peripheral nerves, in the cornea, in cartilage, in the testicles, kidney, liver, and in the blood and lymph-nodes. Sometimes the cells contain but few bacilli, but they are frequently crowded with them.

Characters of the Lepra Bacilli.

The bacilli are from 4 to 6 μ long and very slender. They are sometimes pointed at the ends and sometimes present spheroidal swellings (Fig. 155). In their comportment toward staining agents, as well as in general morphological characters, they considerably resemble the *Bacillus tuberculosis*, but they are more readily stained. They may be stained with fuchsin or gentian violet by the ordinary method, or by the method employed for staining the tubercle bacillus (see p. 258).

Cultures and Pathogenesis.—Various reports of success in the artificial cultivation of the lepra bacillus have been made but confirmation has not followed. Quite recently, however, Clegg¹ and others have apparently succeeded in securing cultures with *amœbæ*, and their symbiotic bacteria. Finally Duval² records his success in pure cultures and his confirmation of the work of Sugai in securing positive results by the inoculation of cultures in the Japanese dancing mouse.



FIG. 155.—THE BACILLI OF LEPROSY. From a nodule in the skin, showing the bacilli free and within cells.

¹ Clegg, *Phillipine Jour. Sci.*, iv, 403, 1909; also Currie, Brinckerhoff, and Hollman, *Public Health Reports*, U. S. Mar. Hosp. Ser., xxv., 1173, 1910.

² Duval, *Jour. Exp. Med.*, xii., 649, 1910.

The structure of the new tissue growth, the absence of coagulation necrosis, and the peculiar grouping of the bacilli in the large transparent cells are characters which usually clearly distinguish the lesions caused by the leprosy bacillus from those of tuberculosis.

Leprosy is common in India and in other hot countries. It is infrequent in America, but in the Gulf States, in Mexico, among the Norwegians in the Northwest, and in the eastern British provinces a considerable number of cases are grouped. Isolated cases are, however, encountered now and then in various parts of the United States.¹

Communicability.—So long as the leprosy tissue is intact the bacilli are closely enclosed by it. But when necrosis and ulceration occur, as on the skin or the mucous membranes, the bacilli may be widely distributed; from ulceration nodules in the nose and pharynx, for example, in sneezing and coughing. But even persons exposed to infective exudates are so seldom infected that one is forced to assume special predisposing factors which we do not understand when infection does occur. Under proper sanitary conditions leprosy is not to be regarded as readily communicable.²

SYPHILIS.

It has been found convenient to consider the lesions of syphilis as occurring in three stages, *primary*, *secondary*, and *tertiary*. These stages may perhaps mark epochs in the development of the infective agent or phases in the protective action of the body-cells in the course of their adaptation to the parasitic organism. Or, finally, the stages of syphilis may bear some relationship to the adaptive processes of the infective organism itself.

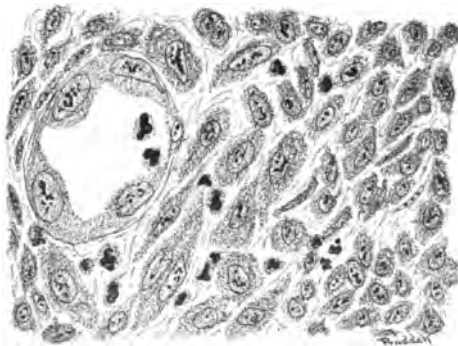


FIG. 156.—NEW-FORMED TISSUE IN SYPHILITIC INFLAMMATION.

From a "hard chancre," showing swollen endothelium in a small blood-vessel.

It may be said in general that the characteristic lesions of syphilis consist in a more or less circumscribed formation of new tissue. This may be made up largely of small spheroidal cells or of these with polyhedral cells (Fig. 156), and of occasional giant cells. The new tissue, which may be diffuse or

in more or less clearly circumscribed masses, contains, as a rule, few blood-vessels, and is prone to undergo coagulation necrosis. This tendency is most pronounced in the circumscribed masses.

The endothelial cells of the blood-vessels in and near the inflammatory

¹ For a study of leprosy in the United States, see *Brinckerhoff*, *Public Health and Marine Hospital Service*, vi., 1909.

² For bibliography of leprosy consult *Morrow*, "Twentieth Century Practice," vol. xviii.

foci in this form of inflammation are not infrequently swollen and may proliferate (Figs. 156 and 157, *B*). The vessels may otherwise undergo extensive changes.

Primary Lesions.—At the point of inoculation in a few weeks a focus of inflammation develops—the initial sclerosis. This may be in the form of a papule or a vesicle, and in either case erosion of the surface is apt to occur and a hardening of the deeper tissues, leading to the so-called *chancre*. In this primary lesion, in addition to more or less

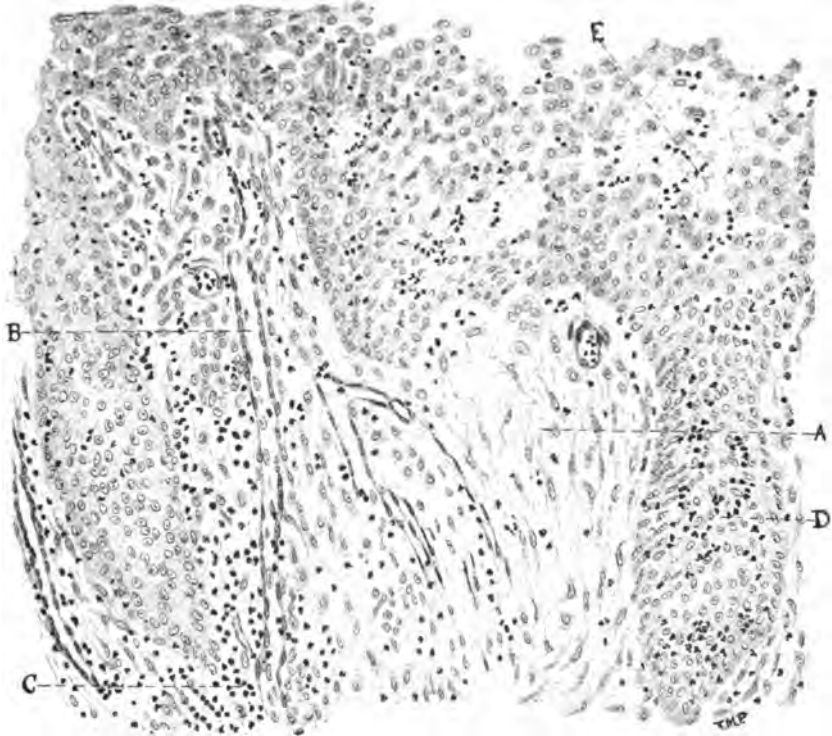


FIG. 157.—SECTION OF A PORTION OF A SYPHILITIC CONDYLOMA OF THE MUCOUS MEMBRANE.

A, Edematous papilla; *B*, swollen endothelial cells in small blood-vessels of a papilla; *C*, pus cells in the submucous connective tissue; *D*, pus cells in the epithelium; *E*, disintegration of the epithelium in the superficial portion of the mucous membrane.

fluid and cellular exudate, there may be obliterating endarteritis, a small spheroidal-cell infiltration of the connective tissue, proliferation of connective-tissue cells, especially near the blood-vessels (Fig. 158), swelling of the vascular endothelium, and an occasional development of giant cells. This new tissue may become fibrous and the initial lesion heal.

Usually in connection with, or following the development of, the initial lesion there is a hyperplasia of the lymph-nodes belonging to the anatomical district of the lesion. These become hard and swollen.

These hyperplastic lymph-nodes, called *buboes*, are not apt to suppurate except as the result of concurrent infection with pyogenic bacteria, but the swelling gradually subsides.

Secondary Lesions.—After six or seven weeks the so-called secondary stage of syphilis, now called constitutional syphilis, is entered upon. This is characterized by various forms of eruption on the skin and

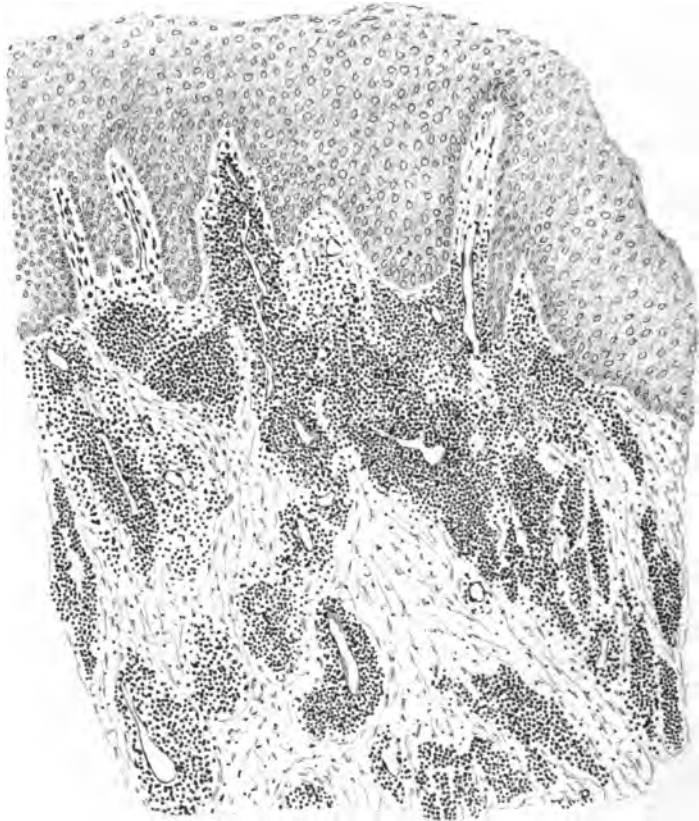


FIG. 158.—SECTION FROM A PRIMARY SYPHILITIC NODULE OF THE MUCOUS MEMBRANE OF THE MOUTH.

Showing collections of cells about the blood-vessels in the submucous tissue.

mucous membranes—macules, papules, and pustules. Periostitis is not infrequent. At this period there often develop on the mucous membranes or where these join the skin, circumscribed areas of exudative and productive inflammation of the papillary layers with necrosis and exfoliation of the epithelium. The papillæ are enlarged, the epithelium swollen and opaque. These local areas of inflammation and necrosis are called *mucous patches*. Of similar character are the elevated areas of the skin common about the generative organs in secondary syphilis, called *condylomata*. Here also there is at the base the characteristic cell prolifer-

ation with swelling of the papillæ, thickening and exfoliation of the epithelium, and there may be an abundant infectious exudate from the surface.

Tertiary Lesions.—One of the most characteristic phases of the tertiary inflammations of syphilis is the formation in the periosteum or in the viscera, especially in the liver, lungs, heart, brain, and kidney, of masses of new tissue called *gummata*.

The smaller gummata consist of a mass of small spheroidal and epithelioid cells (see Fig. 159). As these cell masses grow larger they are apt to become necrotic and caseous at the centre, and we may then

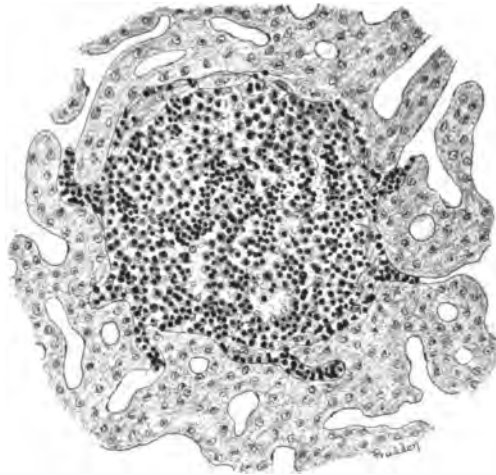


FIG. 159.—SMALL NODULE OF SYPHILITIC INFLAMMATION (MILIARY GUMMA) IN THE LIVER.

have, as seen by the naked eye, a grayish white, usually firm mass, with a more or less dense and irregular granular centre and a translucent, often radially striated border of dense fibrous tissue (see Fig. 160).

Gummata vary in size from those invisible to the naked eye to those several centimetres in diameter; they are usually single, but may be multiple, and occasionally several coalesce. The border zone of the gumma usually consists of granulation or fibrous tissue and may be regarded as due to the reparative reaction of the surrounding tissues. The necrotic portions of gummata may be absorbed and the whole replaced by a mass of cicatricial tissue; or strands of fibrous tissue enclosing irregular islets of caseous material may long persist at the original seat of the gummata. In some instances the syphilitic inflammation may be diffuse, with or without marked necrosis. In the lungs, the liver, and the walls of the arteries the later stages of syphilitic infection may be marked by the diffuse formation of fibrous tissue.

Congenital Syphilis.—The lesions of congenital syphilis are those of the secondary and tertiary stages, and may be present at birth or develop at a later period. Various phases of malnutrition are often obvious.

There may be pemphigus of the hands and feet or elsewhere, with vesicles or blebs containing variously colored or bloody fluid. Pustules, usually about the buttocks; various erythematous rashes; coryza; inflammations of the bones, joints, and cornea, etc., are frequent. Irregularities in the ossification of the long bones (see p. 889), gummata and cirrhosis of the liver, enlargement of the spleen, various inflammatory and degenerative lesions of the kidney, and obliterating endarteritis are among the more common marks of congenital syphilis.

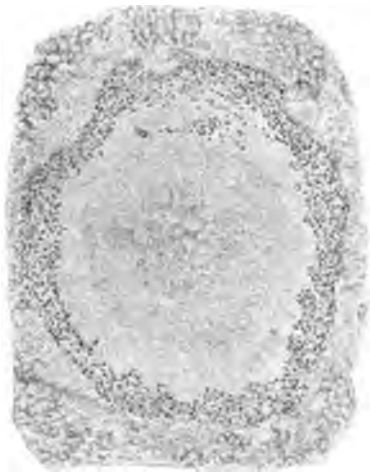

FIG. 160.—SYPHILITIC GUMMA IN THE LIVER.

Showing necrotic caseous centre merging into the new-formed cellular and fibrous tissue in the periphery. This gumma was much larger and is much less magnified in the cut than Fig. 159.

Diagnosis.—The nodular lesions of syphilis are in many respects structurally similar to those of tuberculosis, so that it is sometimes difficult to distinguish them on morphological examination alone. But the greater variety in the developmental stages of the tuberculous foci which may be found in a single individual, the grouping of the lesions in a manner indicative of local infections, and in the last resort the demonstration of the presence of the tubercle bacillus, will usually suffice to distinguish the tuberculous from the syphilitic lesion, even without recourse to the clinical history.

For further details regarding syphilitic lesions of the viscera see Part II. For many details regarding syphilis, its symptomatology and lesions, its effects

upon gestation and the infant, etc., reference is made to special works on the subject.¹

Animal Inoculations.—It has been shown by Metchnikoff and Roux² and by Neisser,³ that successful inoculations of apes may be made with the virus of syphilis. It has been found that while cutaneous inoculation with material from primary and secondary lesions gives positive results, subcutaneous and intraperitoneal introduction of similar material does not. Rabbits have also been successfully inoculated.⁴

Treponema pallidum (Spirochæte pallida).—In 1905 Schaudinn and Hoffmann⁵ described the occurrence in primary lesions of syphilis of a slender, spiral organism (Figs. 161, 162, 163) of about the length on the average of the diameter of a red blood cell, which they called *Spirochæte*

¹ For critical summary of syphilis with recent bibliography see Lang and Ullmann in Lubarsch and Ostertag's "Ergebnisse," Jahrg. v. for 1898, p. 481.

For a study of blood-vessel changes in syphilis with bibliography see Abramow, Ziegler's Beiträge, Bd. xxvi., p. 202, 1899.

² Ann. Inst. Pasteur, t. xvii., p. 809, 1903.

³ Deut. med. Woch., xxx., pp. 1369 and 1431, 1904; and Neisser and Baermann, *ibid.*, xxxi., p. 48, 1905.

⁴ Bertarelli, Central. f. Bak., xli., 320, 1906.

⁵ Arbeiten a. d. Kais. Gesundheitsamte, Bd. xxii., p. 527, 1905; also Deut. med. Woch., p. 711, 1905.

pallida. It is sharply curved, corkscrew like, having from three to ten or more curves, and is pointed at the ends. It is mobile, rotating on the long axis, and moving in both directions. This organism at first called Spirochæte was afterward renamed *Treponema*.

The *Treponema pallidum* is stained with difficulty by the ordinary reagents and is thus frequently difficult of detection. It may be mixed, especially when on the ulcerating surfaces of syphilides, with coarser and more readily stained spiral organisms, particularly *Spirochæte refringens*, and with various other saprophytic bacteria. It is most readily detected in material from the depths of such lesions as condylomata and mucous patches.

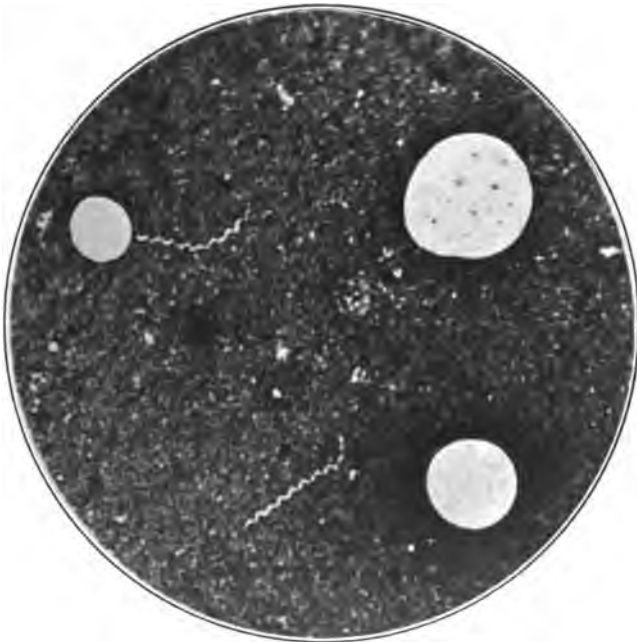

FIG. 161.—TREPONEMA PALLIDUM
(Spirochæte pallida). India ink stain.

Since the announcement of its discovery *Treponema pallidum* has been found by many observers in condylomata and in the primary macules, papules, and pustules. It has been found in the internal organs, in the lymph-glands of involved regions, in the spleen, and in the blood.

The organism has also been found in the secondary lesions of syphilis, even at a late period, and in tertiary lesions. It also occurs, sometimes in large numbers, in the lesions of the skin and in the internal organs of the victims of congenital syphilis.

The observations of Metchnikoff, Flexner, and Kraus have shown that in the experimental primary syphilitic lesions of the monkey the treponema is present.

The attempts to cultivate the organism on artificial media have thus far been unsuccessful.¹

The evidence appears to be abundant that the *Treponema pallidum* is the inciting agent in syphilis even though artificial cultures have not yet been made. This organism, resembling morphologically in many respects the spiral bacteria, was believed by Schaudinn to belong among the protozoa, and the evidence of its affiliation with these organisms is now commonly regarded as valid. It appears to be closely related to the trypanosomes (see page 119).

Communicability.—The infective agent of syphilis is readily and most frequently conveyed by direct inoculation with the exudate from

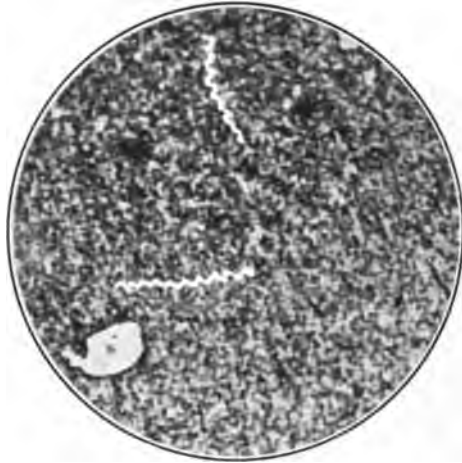

FIG. 162.—*TREPONEMA PALLIDUM*
India-ink stain.

some lesion of a victim of the disease. This most frequently occurs during sexual intercourse, but may take place in many other ways, either through direct or indirect transmission to abraded or wounded surfaces of the infective exudate.

Syphilis may also be congenitally transmitted, apparently, either from the father or the mother. But the transmission of the infective agent through the placental blood is the more common.

Immunitization.—Though many attempts have been made to secure active and passive immunity, none has been successful.

Demonstration of *Treponoma Pallidum*.

The material is most readily obtained from the primary ulcerated lesions by gently scraping with a platinum loop after a preliminary cleansing of the surface, or from mucous patches by a deep scraping with a sharp spoon. From papules, pustules, and roseolæ one may obtain material by expressing fluid through a superficial incision; from lymph-nodes by the hypodermic needle.

¹ For a *résumé* of the etiology of syphilis with bibl., etc., see *Fleener*, *Medical News*, vol. lxxxvii., p. 1105, 1905; see also for an excellent review of recent work on syphilis, *Ewing*, *N. Y. State Jour. of Med.*, vii., 177, 1907, bibl.; also *Lerdati and Roché* *La Syphilis*, Paris, 1909.

Living Organisms.—By the use of the special condenser for dark field illumination in a fresh preparation, by the arc light one may see the refractile unstained spiral organisms in rapid motion across the dark field.

Staining.—Smears of the material should be made very thin. Many stains are effective. After fixation in alcohol and ether the treponema may be stained with gentian violet, or by the Giemsa method, the latter being especially recommended by the discoverers of the organism. For the general use of the Giemsa stain see p. 1037. For the *Spirochæte pallida* it is recommended to stain from sixteen to twenty-four hours, but a shorter time will usually suffice.

In sections the spirochæte is well demonstrated by the silver impregnation method

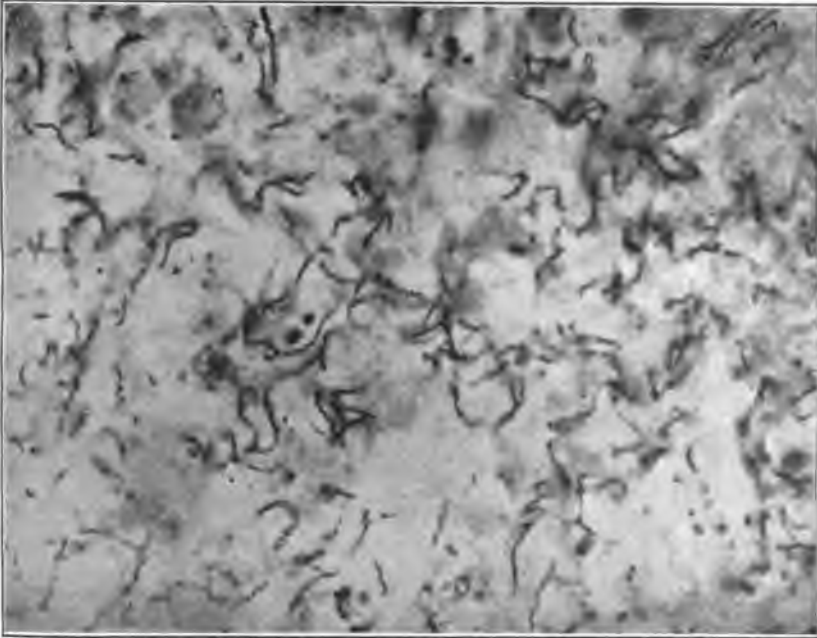


FIG. 163.—*TREPONEMA PALLIDUM*.

Stained by the silver method. Preparation of Dr. Noguchi. Showing enormous numbers of spirochetes in the smear of material from syphilitic lesion.

of Cajal, as suggested by Bertarelli, Volpino and Bovero,¹ and later modified by Levaditi and Manouélian² (see Fig. 163).

A later and more rapid method of silver-staining recommended by Levaditi and Manouélian³ as especially valuable in the examination of specimens of syphilitic tissue removed during life, is as follows:

1. Pieces of tissue, 1 or 2 mm. thick, are fixed by twenty-four to forty-eight hours' sojourn in 10-per-cent. formalin solution.
2. Wash in alcohol (96-per-cent.) for twelve to sixteen hours.
3. Soak in distilled water till pieces sink.
4. Impregnation with silver as follows: 1-per-cent. silver-nitrate solution to which is added when ready for use 10 per cent. of pyridin (Cogit or Billaut). The tightly closed flasks containing this mixture in considerable quantity are kept for two to

¹ See *Cbl. f. Bak.*, Abth. I., Orig. Bd. xl., p. 56, 1906.

² See *Ann. Inst. Pasteur*, vol. xx., p. 41, 1906.

³ *Levaditi and Manouélian*, *Comptes Rend. Soc. de Biol.*, t. lviii., p. 134, 1906.

three hours at room temperature, then for from four to six hours at about 50° C. (The time required for impregnation depends upon the permeability of the tissue.)

5. Wash quickly in a solution of pyridin, 10 parts to 100.

6. Reduction in solution of pyrogallic acid, 4 per cent., to which is added when ready for use purified acetone, 10 parts to 100; and pyridin, 15 parts to 100 of the total volume. The reduction is completed in a few hours.

7. Pass through alcohol, xylol, paraffin sections.

8. Stain with Unna's blue or toluidene blue and differentiate with the glycerin-ether mixture of Unna.¹

By this method the spirals are more or less definitely black, the tissues pale yellow. Double staining reveals the relationships of the organism to the tissue cells.

India Ink Stain.—An effective method of demonstrating the syphilis organism in smears is as follows:

The fluid squeezed from a syphilitic lesion on to a slide with as little blood as possible is mixed with a drop of India ink (Chin-Chin waterproof ink manufactured by Günther Wagner), and the mixture spread as in making blood smears. After drying, which is almost immediate, the specimen examined directly with an oil immersion lens shows the organism, if present, as unstained in a black field (see Figs. 161 and 162).

WASSERMANN'S TEST IN THE DIAGNOSIS OF SYPHILIS.

General Considerations.—The principles on which this test is based have been considered on page 189 under the heading *Fixation of Complement*. We have there seen that when a substance capable of inciting the body-cells to the formation of antibodies, *i.e.*, an antigen, is mixed with its corresponding heated serum, *i.e.*, antibody or amboceptor, in the presence of complement, the latter is so "fixed" in combination with the antigen that it is no longer free to enter into any other combination. This is shown by the fact that if such a mixture be placed in contact with the sensitized red blood cells, no hæmolysis is produced.

If, in the above reaction, the heated serum contained no antibody, the complement would not be fixed and hæmolysis would take place on the addition of the sensitized red blood cells.

In this way one may determine the presence in given fluids of specific antibodies, on the one hand, or of antigens on the other, if he have at hand the homologous antigens or antibodies as the case may be. For antigens one may use bacteria or bacterial extracts.

In Wassermann's test it was assumed that syphilitic organs might contain uncombined portions or products of Spirochæte (*Treponema*) pallidum, *i.e.*, free syphilitic antigens, and thus extracts in salt solution or alcohol were made of organs—spleen, liver, etc.—of a syphilitic fœtus. But it was discovered later that specific antigens are not necessary for the reaction; that extracts of normal organs, liver, spleen, heart, human or animal, or lecithin in solution can act as antigens in the tests.

It has been urged that it is lipid substances which in all these conditions act as antigen, but this has not yet been clearly established.

Details of the Test.—Five elements enter into the Wassermann test—antigen, hæmolytic serum, complement, blood corpuscles, and the serum to be tested for syphilitic antibody.

The following account of the technique is derived from the admirable résumé of Hiss and Zinsser in their Text-book of Bacteriology.

I. *The Antigen.*—This is prepared as follows (Noguchi):

"Fresh finely chopped normal liver or spleen is covered and thoroughly macerated with five times its volume of absolute alcohol. This is allowed to extract in the incubator for six to eight days, being thoroughly stirred up at least once a day. It is then pressed through cheese-cloth and filtered through paper. This alcoholic extract is evaporated to dryness at room temperature by a current of air. The sticky.

¹ This preparation, which can be obtained from the Grüber house, is a mixture of glycerin and glycerine-anyhydride with one-third its weight of absolute alcohol, used as a differentiating agent for basic dyes.

brownish residue resulting is taken up in a small quantity of ether and the solution poured into four times its volume of C. P. acetone. A heavy flocculent precipitate forms which settles to the bottom as a sticky brown mass. This is retained as antigen and may be preserved under acetone. The acetone-soluble fraction is thrown away. For use, about 0.2 gram of the sticky paste is dissolved in about 5 c.c. of ether and 100 c.c. of salt solution added. This is shaken until the ether has evaporated. The resultant antigen, ready for use, is a slightly opalescent greenish fluid from which nothing settles out on standing.

Before an antigen can be used for the actual test, it is necessary to determine the quantity which will furnish a valid result. The substances which are used as antigens often have the power, if used in too large quantity, of themselves binding complement. It is necessary, therefore, to determine the largest quantity of each given antigen which may be used without exerting an anti-complementary action, *i.e.*, which will not inhibit in the presence of normal serum, but which will at the same time inhibit hæmolysis when syphilitic serum is used. This is done by mixing graded quantities of the antigen with a constant quantity of complement (0.1 c.c. of fresh guinea-pig serum), in duplicate sets, adding to each tube of one set 0.2 c.c. of a normal serum, and to the other 0.2 c.c. of a known syphilitic serum. These substances are allowed to remain together for one hour and then red blood corpuscles and inactivated hæmolytic serum are added. The quantity which has given complete inhibition with the syphilitic serum, but absolutely no inhibition with normal serum, is the one to be employed in subsequent reactions. Before actual use, it is convenient to make a dilution of antigen in salt solution in such a way that 1 c.c. shall contain the amount required. Thus if 0.05 c.c. is wanted, mix 0.5 c.c. with 9.5 c.c. salt solution. Then 1 c.c. of this can be added to each tube in the test.

II. *The Hæmolytic Serum.*—The hæmolytic amboceptor, for the reaction, is obtained by injecting into rabbits the washed red blood corpuscles of a sheep. A 5-per-cent. emulsion of the corpuscles is made and of this 5 c.c., 10 c.c., and 15 c.c. are injected at intervals of five or six days. Three or four graded injections of this kind are usually sufficient to furnish a serum of adequate hæmolytic power. The injections may be made intraperitoneally, subcutaneously, or intravenously. About nine or ten days after the last injection of corpuscles, the rabbit is bled from the carotid artery and the serum obtained by pipetting it from the clot.

It is best to have a hæmolytic serum of high potency in order that the quantities used for the reaction may be as small as possible. This is desirable because of the fact that the serum may contain small amounts of precipitins for sheep's serum, due to insufficient washing of the corpuscles employed in the immunization. If such precipitins should be present in any quantity in the serum used for the reaction, precipitates might be formed, and these, as we know, have a tendency to carry down complement from a mixture.

While the quantitative relations of the complement and antigen in the Wassermann reaction are important, they are vastly more so in the case of the hæmolytic amboceptor. For the actual reaction most observers make use of two hæmolytic units. A hæmolytic unit is the quantity of inactivated immune serum which, in the presence of complement, suffices to cause complete hæmolysis in 1 c.c. of a 5-per-cent. emulsion of washed blood corpuscles." This must be accurately determined.

"For this purpose a number of mixtures are made in test-tubes, containing each 0.1 c.c. of complement (fresh guinea-pig serum), 1 c.c. of a 5-per-cent. emulsion of sheep's corpuscles, and diminishing quantities of the inactivated hæmolytic serum, thus:

0.1 c.c. of complement fresh guinea-pig serum	}	+	{	1 c.c. of 5 per cent. emulsion sheep's corpuscles.	}	+	{	Inactivated hæmolytic serum	}	{	.01 c.c. = complete hæmolysis .009 c.c. = complete hæmolysis .005 c.c. = complete hæmolysis .003 c.c. = complete hæmolysis .001 c.c. = complete hæmolysis .0009 c.c. = partial hæmolysis .0005 c.c. = no hæmolysis .0003 c.c. = no hæmolysis ¹
---	---	---	---	--	---	---	---	-----------------------------------	---	---	--

¹ In each tube the volume of the mixture should be made up to 5 c.c. with 0.85 per cent. salt solution.

In the given case, 0.001 c.c. of the serum represents one unit, and 0.002 c.c., two units, is the quantity to be used for each test.

III. *The Complement*.—The complement for the Wassermann reaction is used in the form of fresh guinea-pig serum. This may be obtained in the following way: A guinea-pig may be killed by an incision in the throat and the blood allowed to flow into a large Petri dish or centrifuge tube. This is set away in the ice chest until the clear serum has separated from the clot. After twelve to twenty-four hours the serum is carefully removed with a pipette.

IV. *The Sheep Corpuscles*.—The sheep corpuscles for the actual reaction are obtained by receiving the blood of a sheep in a small flask containing a sterile solution of a 1 per cent. sodium citrate and 0.85-per-cent. sodium chloride, or into one containing glass beads or short pieces of glass tubing. In the former case, the citrate solution prevents clotting and the corpuscles may be washed free from the citrate solution and emulsified in salt solution before use in the test. In the latter case, it is necessary to shake the blood in the flask immediately after taking, and to continue the shaking motion for about ten minutes. At the end of this time, the blood will be defibrinated and the corpuscles are washed free from serum by centrifugalization in salt solution. A 5-per-cent. emulsion of the corpuscles in salt solution is employed for the test, made by measuring the bulk of centrifugalized corpuscles and adding nineteen parts of sterile salt solution. Thorough washing of the corpuscles is essential to preclude the occurrence of precipitates.

V. *The Serum to be Tested for Syphilitic Antibody*.—The serum of the patient upon whom the test is to be made is best obtained in the same way that blood is obtained for blood cultures. After surgical precautions as to sterilization, a needle is plunged into the median basilic vein and 3 or 4 c.c. of blood are removed. Whenever circumstances do not permit such procedure, blood may be obtained from the finger or the ear, always in sufficient quantity to furnish at least 1 c.c. of clear serum. Before use for the test, the patient's serum must be inactivated by heating in a water-bath to 56° C. for twenty minutes to half an hour. As, according to some observers, 56° C. destroys the syphilitic antibody in part, Noguchi advises inactivation at 54° C.

The Test.—The actual test for antibody in a suspected serum is carried out in the following way: In a test-tube of suitable size, 0.1 c.c. of complement, 0.2 c.c. of the inactivated suspected serum, and the antigen in quantity determined by titration, are mixed, and the total volume brought up to 3 c.c. with normal salt solution. This mixture is thoroughly shaken, and placed for one hour in a water-bath or in the incubator at 37.5° C. At the end of this time there is added 1 c.c. of a 5-per-cent. emulsion of sheep's corpuscles, and 1 c.c. of hæmolytic amboceptor, determined by a titration of the inactivated hæmolytic rabbit serum, as described above. The volume is brought up to 5 c.c. with salt solution. This mixture is again placed at 37.5° C. for one or two hours. If the antibody is present in the suspected serum, no hæmolysis takes place. If absent, hæmolysis is complete.

No test is of use unless suitable controls are made. The controls set up should be as follows:

Control 1.—For each serum tested the mixture described above, omitting antigen.

Controls 2 and 3.—The mixture made as in the test but with *known* syphilitic serum (2) with and (3) without antigen.

Controls 4 and 5.—The mixture made as in the test, but with normal serum (4) with and (5) without antigen.

Control 6.—Antigen and complement alone, left together for an hour before the addition of blood cells and amboceptor in order to preclude the possibility of the antigen itself fixing complement. When working with a well-controlled antigen this control may be omitted.

Control 7.—The hæmolytic system: complement, blood cells and amboceptor, set up in order to show that the system is in working order. It is convenient to set the tubes in two rows in a rack, the front row containing antigen, the back row containing the same mixture without antigen.

In a positive test, the test itself, and Control 2, alone, should show inhibited hæmolysis. The other tubes should show complete solution of the hæmoglobin.

Noguchi's Modification.—Noguchi¹ has much simplified the test by making use of an anti-human hæmolytic amboceptor instead of an anti-sheep amboceptor. In this way he avoids the necessity of procuring fresh sheep corpuscles for each test by using the corpuscles of the patient himself. He has determined empirically that human serum contains, normally, no amboceptor active against the human red corpuscles. This fact is extremely important and has a decided advantage over the original Wassermann test, in that in any reaction in which sheep corpuscles are used as an indicator with human serum, the actual amount of hæmolytic amboceptor used in the test is uncertain. For, as we have mentioned above, human serum normally may contain a variable quantity of amboceptor for sheep corpuscles. In Noguchi's test, therefore, the actual quantity of amboceptor is exactly known by previous titration. The hæmolytic amboceptor for Noguchi's test is obtained by four or five injections of washed human corpuscles into rabbits. These corpuscles may be obtained from the heart's blood at autopsies, or, better, if possible from placenta at childbirth. The unit for this amboceptor is obtained by titration as in the case of the sheep-blood amboceptor for the original Wassermann test. In setting up Noguchi's test, the following substances are used:

a. Patient's serum. Obtained in small glass capsule. About 2 c.c. should be taken.

b. Complement. Fresh guinea-pig serum: 0.1 c.c. of a 40 per cent. fresh guinea-pig serum in salt solution is used in the test. Obtain by adding 1 part of guinea-pig serum to 1 1/2 parts of salt solution.

c. Antigen. Substance prepared as in the Wassermann test by extraction of syphilitic or normal organ.

d. Human corpuscles. Normal corpuscles or those of the patient himself may be employed. If the patient's red cells are chosen, these should not be used for other tests than that on the patient's own serum; 1 c.c. of a 1 per cent. emulsion of washed corpuscles is used for the test.

e. Anti-human amboceptor prepared by the injection of washed human corpuscles into rabbits and titrated against human corpuscles. Two units are used in the test.

The test itself is set up as follows:

Tube 1.—One drop patient's serum + complement (0.1 c.c. of 40 per cent. guinea-pig serum) + antigen.

Tube 2.—One drop patient's serum + complement (no antigen).

Tube 3.—One drop known syphilitic serum + complement + antigen.

Tube 4.—One drop known syphilitic serum + complement (no antigen).

Tube 5.—One drop known normal serum + complement + antigen.

Tube 6.—One drop known normal serum + complement (no antigen).

Tube 7.—Complement alone (for hæmolytic system control).

To each tube then add 1 c.c. of the 1 per-cent. emulsion of human corpuscles. Shake mixtures thoroughly and incubate or place in water-bath at 38–40° C. for one hour. Then add to each tube two units of amboceptor and replace in water-bath for one hour. At the end of this time in a positive test there will be no hæmolysis in tubes 1 and 3 while all the other tubes will show hæmolysis.

Noguchi has simplified the technique of complement fixation further by drying measured amounts of antigen and amboceptor upon small squares of blotting paper. These may be dropped into the tubes directly, obviating the necessity of preparing fresh dilutions of the concentrated substances for each test. The substances in the dried state, moreover, may be preserved for longer periods than when kept in the liquid form."

Rhinoscleroma.

This disease, which occurs especially in eastern Europe and occasionally in other parts of the world, is a chronic inflammation of the nasal, pharyngeal, and laryngeal mucous membrane. In this inflammation a diffuse or nodular formation of new tissue somewhat resembling granulation tissue, occurs, which tends to assume a dense cicatricial character.

¹ *Noguchi, Jour. of Exper. Medicine, 1909. Also Serum Diagnosis of Syphilis, 2d ed., 1911.*

Constantly associated, it is said, with this lesion is a bacillus called *Bacillus rhinoscleromatis*. This bacillus in most of its morphological and biological characters closely resembles the pneumobacillus of Friedländer (*B. mucosus capsulatus*), growing readily on the common culture media and developing a capsule, and it may be identical with it.

The relationship of this bacillus to the lesions of rhinoscleroma does not appear to be as yet definitely established, since inoculations in men and animals have not given positive results.

DIPHTHERIA.

Diphtheria is an acute infectious disease incited by the *Bacillus diphtheriæ* (Löffler), and usually characterized by a pseudo-membranous inflammation on some of the mucous membranes or occasionally on the surface of wounds, and by immediate or remote effects of absorbed toxic substances. The mucous membranes which are the most frequently affected in diphtheria are those of the tonsils, pharynx, soft palate, nares, larynx, and trachea; less frequently those of the mouth, gums, conjunctiva, œsophagus, and stomach.

MORPHOLOGY OF THE LESIONS.

The local lesions in mucous membranes may present various phases, which represent clinical types of the disease. Thus there may be a simple redness of the affected surfaces which leaves no trace after death, or there may be a simple catarrhal inflammation. On the other hand,




FIG. 164.—FIBRIN IN DIPHTHERITIC MEMBRANE UNDERGOING COAGULATION NECROSIS.

in the more marked forms of the lesion there may be a fibrinous exudate which infiltrates the mucous membrane, or, intermingled with pus cells, epithelial cells, red blood cells, bacteria, and granular material, forms a thick or thin pellicle on the affected surfaces (see Fig. 123, p. 213). This pellicle may undergo coagulation necrosis (Fig. 164), and hand-in-hand with this there may be superficial or deep necrosis of the mucous membrane. The false membrane in diphtheria is thus formed by a combination of inflammatory products and necrotic tissue, the extent of the necrosis and the amount of inflammatory products varying in different cases.

The membrane may disintegrate or exfoliate, with or without loss of tissue in the underlying mucous membrane. Phlegmon, abscess, and œdema are liable to occur as local complications.

Adjacent and distant lymph-nodes are apt to be swollen, and often show, on microscopical examination, endothelial-cell hyperplasia with small foci of cell necrosis and disintegration.¹ Similar foci of cell hyperplasia with necrosis with small spheroidal-cell accumulation and fatty

¹ Consult *Waschkewitch*, *Virch. Arch.*, Bd. clix., p. 137, 1900.

degeneration may be found in the kidney, spleen, and liver. Albuminous degeneration in the kidney and acute nephritis are not infrequent. Small hæmorrhagic foci may be present in the liver and kidneys. Degeneration of the heart muscle may occur.¹ The exact nature of the nerve lesions which may be associated with the late paralyses of diphtheria is not yet clear, but degeneration of the peripheral nerves and chromatolysis of the ganglion cells occur, indicating the action of an absorbed toxic substance in the body fluids. Leucocytosis may be present.

Catarrhal bronchitis and broncho-pneumonia or simple lobular pneumonia frequently complicate diphtheritic lesions of the upper air passages and fauces.

BACTERIOLOGY OF THE DISEASE.

Although bacteria of various forms are commonly present in the false membrane, and some of them penetrate deeply into the underlying tissue, the primary and specific excitant of this disease is the *Bacillus diphtheriæ* of Löffler.

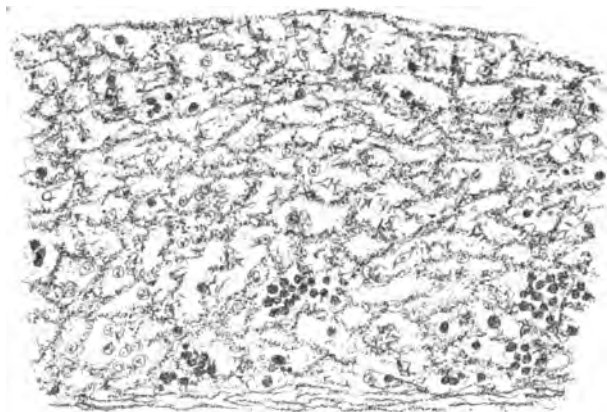

FIG. 165.—DIPHTHERITIC INFLAMMATION OF THE TONSIL.
Showing Löffler's bacilli in the pseudo-membrane.

In man the diphtheria bacilli are largely confined to the seat of local lesion, and sometimes occur here in enormous numbers, especially in the older layers of the pseudo-membrane (see Fig. 165). But they may become widely distributed through the body. This appears to be especially the case when the pyogenic cocci are associated with the diphtheria bacillus at the seat of local lesion. The systemic effects in diphtheria appear to be largely due to the absorption into the body of toxic material

¹ For studies of the lesions of the myocardium in diphtheria consult *Scagliosi*, *Virch. Arch.*, Bd. cxlvi., p. 115, 1896; also *Thomas and Hibbard*, *Reports of Boston City Hosp.*, 1900, p. 204, bibl.; for a study of nerve lesions with bibl. see *Batten*, *Pediatrics*, vol. vii., p. 97, 1899; also *Rainy*, *Jour. Path. and Bact.*, vol. vi., p. 435, 1900. For a comprehensive study of the bacteriology and pathology of two hundred and twenty fatal cases of diphtheria see *Councilman, Mallory, and Pearce*, *Jour. Boston Soc. Med. Sci.*, vol. v., p. 139, 1900.

elaborated locally by the germs. Septicæmia or acute visceral inflammations, particularly of the kidney, may occur without evidence of an external local lesion or of the portal of entry of the bacillus.¹

CONCURRENT INFECTIONS.

The very frequent association of the pyogenic cocci and other bacteria with the diphtheria bacillus gives rise to a series of changes which make the clinical picture and the lesions of diphtheria sometimes very complex. Thus the complicating bronchitis and broncho-pneumonia, as well as pyæmic symptoms and lesions, may be due to the diphtheria bacillus alone. But these secondary lesions may be due to the presence in the pseudo-membrane, and the entrance into the deeper air passages and the blood, of *Streptococcus pyogenes*, *Staphylococcus pyogenes*, *Diplococcus lanceolatus*, *Bacillus coli communis*, and other bacteria, or of these together with the diphtheria bacillus.²

Characters of the Diphtheria Bacillus.

This organism, first described and definitely associated with this disease by Löffler, is a slender rod, in general about 3μ long, but sometimes shorter and sometimes growing into threads. It occasionally grows in branching forms,³ and is characterized morphologically by marked irregularities in its form (Fig. 166). While the typical form is that of a round-ended, straight, or slightly curved bacillus, it is very apt—perhaps as a result of degeneration—to appear club-shaped or pointed at the ends, irregularly segmented, and to develop at the ends or elsewhere a strongly refractile material which stains more deeply than the rest of the protoplasm.



FIG. 166.—BACILLUS DIPHTHERIÆ.

From exudate in the throat of a case of diphtheria; showing irregularities of the bacilli in shape and size and coloration.

The diphtheria bacillus is immobile, asporogenous, grows best at blood heat, and thrives on most of the artificial culture media. In fluids it may be killed by an exposure of ten minutes to a temperature of 58°C. ; or of one minute to boiling, but it may remain alive for weeks, or even months, in fragments of dried membrane. It may be stained

with Löffler's alkaline methylene-blue solution or by Gram's method.

It is subject to extreme variations in virulence, forms occurring which with all the usual cultural characteristics are not at all virulent.⁴

Action of the Bacillus in Animals.

Inoculations of virulent cultures subcutaneously in guinea-pigs are followed by a localized hæmorrhagic œdema with a variable amount of whitish exudate. Death

¹ For a résumé and bibliography of studies relating to diphtheritic septicæmia see *Brown and Thiry*, *Gazette des Hôpitaux*, May 2d, 4th, and 9th, 1899.

² For a study of the presence and action of the diphtheria bacilli in the lungs see *Fleznar and Anderson*, *Johns Hopkins Hosp. Bull.*, vol. ix., p. 72, 1898.

³ For a summary of the association of diphtheria and tuberculosis see *Councilman, Mallory, and Pearce*, reference p. 283.

⁴ The branching forms which are occasionally observed in the diphtheria as well as in the tubercle bacillus, together with certain other characters, have led some observers to the belief that these organisms are related to streptothrix and to the moulds rather than to the bacteria. But, for the present at least, it seems wiser to consider them in their more generally acknowledged relationships.

⁵ For a study of varieties of the *B. diphtheriæ*, see *Williams*, *Jour. Med. Res.*, vol. viii., 1902, p. 83; see also for full summary of studies on the diphtheria bacillus and its toxins; *Beck, Kolle and Wassermann's "Handbuch der Mikroorganismen,"* Bd. ii., p. 754.

usually occurs in from two to five days. In addition to the local lesions there may be—but this is not constant—swelling of the adjacent and of the abdominal lymph-nodes, serous effusions into the pericardial, pleural, and peritoneal sacs: swollen spleen, albuminous and fatty degeneration in the liver, kidney, and heart muscles; congestion and sometimes hæmorrhage of the suprarenals. Microscopical examination shows, in a considerable proportion of cases, fragmentation of nuclei and other evidences of cell death at the seat of inoculation and in the viscera, as well as chromatolysis of ganglion cells in the anterior horn. Animals which survive the inoculations may later develop paralysis, and a similar result may follow the injection into rabbits of culture fluids. The bacilli do not usually gain access to the body at large, but may be found at the seat of inoculations. Inoculation into the mucous membranes of rabbits, pigeons, and certain other animals may result in the development of a pseudo-membrane somewhat resembling that of the disease in man.

Diphtheria Toxin and Antitoxin and Diagnosis.

In its growth under artificial culture some strains of the diphtheria bacillus develop and set free in the culture media toxic substances whose chemical composition is as yet unknown. It is this toxic material which is used in the production of diphtheria antitoxin (see p. 164).

We have already considered the action of antitoxin on page 164 and need not dwell upon it here. For methods of the manufacture and tests of antitoxin, consult *Park and Williams*, "Pathogenic Bacteria and Protozoa," 1910.

For details of bacterial diagnosis consult works on bacteriology or clinical pathology.

The agglutinative reaction of the diphtheria bacillus is not sufficiently definite to permit of its use in diagnosis.

COMMUNICABILITY.—While the possibility of the transmission of the diphtheria bacillus by domestic animals to man cannot be doubted, the usual source of infective material is the exudates of victims of the disease, or virulent bacilli from the mouths of healthy persons to those disposed to the infection. This conveyance may take place directly by contact, or by coughing and sneezing, or through contaminated clothing, bedding, or various utensils. The susceptibility to diphtheria is greatest in the young.

It is important from the prophylactic standpoint to remember that the *Bacillus diphtheriæ* may remain alive in the mouth of the human subject for many weeks after recovery from the local lesions of the disease, and also that healthy persons when the disease is prevalent may harbor the virulent bacilli in their mouths.¹

Other Bacteria of the Diphtheria-Bacillus Group.

While the diphtheria bacillus varies greatly in the physiological capacities which determine its virulence, its general morphological and cultural characteristics are fairly constant. There are, however, non-virulent bacilli occurring on mucous membranes under normal as well as abnormal conditions which considerably resemble this, but which differ somewhat in both morphological and biological characters from the true diphtheria bacillus and its variants. Such organisms have been called *pseudo-diphtheria bacilli* (*Bacillus Hoffmani*). These non-virulent forms may be regarded as attenuated varieties of the diphtheria bacillus.²

The so-called *Xerosis bacillus*, which has been repeatedly found in xerosis conjunctivæ, is apparently a member of the diphtheria-bacillus group.³

¹ See for a study of the diphtheria bacillus in the mouths of healthy persons and those exposed to the disease *Graham-Smith*, *Jour. of Hyg.*, vol. iii., p. 216, 1903, bibl.; also *ibid.*, vol. iv., p. 258, 1904.

² For a study of virulent "pseudo-diphtheria" bacilli see *Hamilton and Horton*, *Jour. Inf. Dis.*, vol. iii., p. 128, 1906.

³ *Graham-Smith*, *Jour. of Hygiene*, vol. iv., p. 306, 1904.

TETANUS. (Lockjaw.)

This disease, which is especially marked clinically by muscular spasm, is due to infection by the *Bacillus tetani*. This organism is rather widespread and in some places very abundant, occurring with other germs in the soil, especially in manured soil, and gaining entrance to the body through wounds, which are often very slight. The soil in certain regions appears to harbor in especial abundance the tetanus organism or its spores. Thus in certain districts on Long Island and in New Jersey slight injuries are frequently followed by tetanus. The liability to infection from the spores is greatly enhanced by their association with other organisms or with dirt, splinters, etc., in the wound.

THE LESIONS OF THE DISEASE.

The local lesion in tetanus is usually slight and not characteristic, often consisting only in a slight suppuration.

The morphology of the lesions of the nervous system to the existence of which the symptoms of tetanus so directly point is yet obscure. Overfilling of the blood-vessels, cellular exudate into the perivascular spaces, chromatolysis of the ganglion cells of the spinal cord are common. The bacillus remains for the most part at the seat of local lesion and induces its effects by the elaboration of most intense poisons or toxins, called *tetano-toxins*. The action of this toxic substance appears sometimes to continue in the body after the death of the organisms which have elaborated it. This infectious disease affords a most typical example of toxæmia.

Characters of the Bacillus Tetani.

It is 2 to 5 μ long, slender, and motile, often growing in pairs or threads and prone to develop a spore in one end (Fig. 167), in which condition the bacillus is larger at this end, being club- or racket-shaped. It is readily stained. At the room temperature it grows on artificial culture media, and is strictly anaërobic, flourishing in an atmosphere of hydrogen, but may be artificially adapted to other conditions.



FIG. 167.—*BACILLUS TETANI*.
From a culture; showing club-shaped ends with spores.

The spores of the tetanus bacillus are very resistant to drying, to heat, and to various chemical disinfectants.

Characteristic tetanic symptoms followed by death may be induced in mice, guinea-pigs, and rabbits by subcutaneous inoculation of cultures. Man and the horse are markedly susceptible to tetanus; birds are as a rule insusceptible. If the tetanus bacillus be grown in nutrient broth at blood heat out of contact with oxygen the toxin is developed and mingles with the fluid. This toxin when freed from living germs is capable of inducing the symptoms of the disease. Broth cultures may, after some weeks, have acquired such an extreme intensity that the dried poisonous material, separated from the inert fluids and partially purified, may be fatal to a mouse weighing 15 gm. in a dose of 0.00000005 gm. Estimating according to the relative weights of the subjects, the minimal fatal human dose would be about 0.00023 gm. This toxin is rendered inert by a temperature above 65° C. and by light.

TETANUS ANTITOXIN.

By procedures similar to those described in diphtheria immunization (p. 164), the tetanus toxin has been used to secure artificial immunity in dogs, goats, and horses, and here also the blood serum of the immunized animals has been prepared and employed in man for therapeutic purposes with some degree of success.¹

The tetanus toxin induces its effects in the body chiefly by its action on the central nervous system. It has been shown to reach the nerve centres from the seat of growth of the bacillus, by way of the axis cylinders of the motor nerves. The tetanus antitoxin, on the other hand, which may be injected for protective purposes, is not taken up by the nerves, but passes into the blood- and lymph-vessels and tissue fluids. The power of the antitoxin to neutralize toxin is apparently limited to that portion of the latter which has not been absorbed by the nerves, but is still free either at the seat of production or in the blood or lymph.

The theoretical promise of the tetanus antitoxin for therapeutic purposes in man is thus in practice rendered in a large measure futile, because the existence of the disease is not recognizable until the toxæmia is sufficiently marked to produce the nervous symptoms, at which time, union of the toxin with the nerve tissues having been effected, the usefulness of the antitoxin is limited to the neutralization of the unabsorbed toxin. Statistics are as yet too meagre to justify a final opinion as to the practical value of tetanus serum therapy, but it appears to be definitely useful, especially when applied directly to the nerve tissues.

Diagnosis.

For purposes of diagnosis it may be necessary to inoculate a white mouse at the base of the tail with suspicious material at the same time that morphological examination and anaërobic cultures are made. Should tetanus develop in the mouse within a few days, control cultures may be made from the exudate at the seat of inoculation.²

Other Bacilli of the Tetanus Group.

Several bacterial species are already known which may be classed in the tetanus group. While varying in size, these bacilli are in general rather large; spores form in their thickened ends; they are facultative anaërobes; some do, others do not fluidify gelatin; and they retain the stain by Gram's method. They are mostly saprophytes and have been found in milk and milk products, in excrement and sewage, etc. None is known to be pathogenic in man. The most noteworthy among these is *Bacillus pseudo-tetanicus*, Sanfelice, which in morphology and growth characters resembles the *Bacillus tetani*, but does not form the toxin.

Malta Fever.

This disease, which has been most frequently observed along the shores of the Mediterranean and in India, and occurs in South America and the West Indies is characterized by prolonged pyrexia with irregular remissions. In the rather rare

¹ For a critical résumé of tetanus and its treatment with the antitoxic serum, with bibliography, see Moschowitz, *Ann. of Surg.*, vol. xxxii., p. 219, 1900.

² For résumé of characters of the tetanus bacillus and its toxin see von Lingelsheim, Kolle and Wassermann's "Handbuch der Mikroorganismen," Bd. ii., p. 566.

fatal cases there may be considerable enlargement of the spleen, albuminous degeneration in the liver and kidneys. Acute nephritis may occur.

It is said that there are constantly present in the spleen in this disease small bacilli so short as to have been mistaken for cocci, stained by Gram, readily cultivated on artificial media. The result of inoculations of pure culture into monkeys and other animals tends to confirm the pathogenic significance of the organism, which has been called *Micrococcus melitensis*.¹

BUBONIC PLAGUE. (Oriental Plague; Black Death.)

Types of the Disease.—This disease presents three main types—the bubonic, pulmonary, and septicæmic.

The most common is the *bubonic*, which is characterized by an intense inflammatory hyperplasia of the lymph-nodes, most frequently the inguinal or axillary. The surrounding tissue may be involved; hæmorrhage, necrosis, or suppuration in the nodes may occur. Coincident with these local reactions there may be albuminous degeneration, focal necrosis, and leucocytosis from toxæmia, or secondary foci of inflammation in the spleen or lungs or liver. A second type of the infection is the *pulmonary*, in which larger or smaller areas of the lungs are involved in broncho-pneumonia with associated secondary involvement of the bronchial lymph-nodes. In the *septicæmic* type of bubonic plague there may be a general involvement of the lymph-nodes and -nodules of the body with the marks of toxæmia, without an indication of the point of primary infection.²

In all these various phases of the disease the plague bacillus may be present often in enormous numbers in the primary buboes and in the secondary lesions and in the viscera; in the consolidated areas and in the sputum in the pulmonary type, and in the septicæmic phases in the blood.

Characters of the Plague Bacillus.

The plague bacillus was discovered in 1894 by Kitasato and Yersin, and its rôle as the excitant of the disease was soon established. It is a short, thick, motile, rounded bacillus, often staining more deeply at the ends than in the middle. It sometimes grows in chains and may be capsulated, not forming spores; it is decolorized by Gram's method. It grows readily though not voluminously on the ordinary culture media at blood heat.³ This organism is killed by drying for a few days and by exposure to sunlight for a few hours. Subcutaneous inoculations in guinea-pigs and rabbits is followed by local hæmorrhagic and serous inflammation with typical involvement of the regional lymph-nodes and by septicæmia. Death may follow in from one to five or six days, with albuminous degeneration of the viscera, hyperplasia of the spleen, and petechial hæmorrhages.

Portals of Entry.—The chief portals of entry in man are abrasions or wounds of the skin, the lungs, and the intestines. The spread of the infectious material in overcrowded and unsanitary districts may readily take place by rats, which are very susceptible to the disease and may

¹ Consult *Birt and Lamb*, *Lancet*, 1899, ii., p. 701, bibl.

² For a *résumé* of lesions of plague see *Flechner*, *Trans. Assn. Am. Phys.*, vol. xvi., p. 481, 1901.

³ See article by *Dieudonné* in *Kolle and Wassermann's "Handbuch der Mikroorganismen,"* Bd. ii., p. 475.

be infected by feeding.¹ Through mosquitoes and flies also the bacilli may be conveyed from man to man or from dead rats or their dejecta to man.²

Preventive Inoculation has been largely practised in the East by the Haffkine method. This consists in the subcutaneous injection of beef-tea cultures of the plague bacillus, which have been killed by heating. Moderate local inflammatory reaction and slight fever may follow the injection. The statistics seem to indicate that among exposed persons the mortality may be considerably reduced by this preventive inoculation.³

An anti-plague serum, prepared by the immunization of horses, has been used by Yersin with at least promising results.⁴

HÆMORRHAGIC SEPTICÆMIA.

Many of the lower animals are victims of acute infections, septicæmic in character, often with petechial hæmorrhages in the viscera and serous membranes and marked intestinal disturbances. These are called "hæmorrhagic septicæmias."

Associated with these and doubtless their inciting agents are several bacilli which may be classed, as is done by Hueppe, Kruse, and others, with the plague bacillus under the designation, the *hæmorrhagic septicæmia group*. These are mostly small, short, sporeless forms growing readily on the ordinary media as facultative anaërobies, not fluidifying gelatin and decolorizing by Gram. Some of these are motile, others not. Among these may be mentioned the bacillus of mouse typhus (*B. typhi murium*), the bacillus of chicken cholera (*B. cholerae gallinarum*), the bacillus of swine plague (*B. suisepiticus*). Several species related to these and to the plague bacillus are pathogenic in man; thus the *B. hæmorrhagicus septicus* of Babes, the *B. hæmorrhagicus* of Kolb, the *B. hæmorrhagicus velenosus* of Tizzoni and Giovanni.

The recognition of these and related species may be of especial significance in connection with the diagnosis of bubonic plague by cultures and animal inoculations.⁵

BACILLUS AËROGENES CAPSULATUS (BACILLUS WELCHII, GAS BACILLUS).

This bacillus was described in 1891-92 by Welch and Nuttall. Later studies of Welch and Flexner and many others have confirmed the original belief that the bacillus is a frequent excitant in man of a serious infectious disease, characterized by a local widespread serous and emphysematous phlegmonous inflammation, frequently associated with gangrene and general symptoms of a profound toxæmia.

The *Bacillus aërogenes* is rather large, on certain media spore-forming, is often encapsulated, and occasionally forms chains. It retains the stain by Gram's method. It is anaërobic, growing readily in a variety of artificial culture media.

Rabbits are not susceptible to even large intravenous injections of

¹ The ground squirrels along the Pacific Coast are widely infected with plague bacilli and are a menace to that region, see Pub. Health Repts., U. S. Mar. Hosp., xxv., 27, 1910.

² On insects as plague-carriers see Herzog, Am. Jour. Med. Sci., vol. cxxix., p. 504, 1905.

³ For summary of result of the Haffkine method see Forsyth, Lancet, vol. ii., p. 1646, 1903; also Slaughter, Johns Hopkins Hosp. Bull., vol. xiv., 1903, p. 307.

⁴ Critical summary and bibl., Netter, Arch. de méd. exp., t. xii., p. 86, 1900.

⁵ For studies on various forms of hæmorrhagic infection see Babes, Verh. d. deutschen path. Gesellsch., Bd. ii., p. 262, 1900; also Kitt, Kolle and Wassermann's "Handbuch der Mikroorganismen," Bd. ii., p. 559.

pure cultures. But if they be killed soon after such inoculation, within a few hours, at room temperatures, an abundant development of gas occurs throughout the body. On the other hand, the subcutaneous injection of a very small quantity of the fresh œdematous exudate is followed by the typical local and general marks of infection. Guinea-pigs are more susceptible than rabbits to inoculation, either with cultures or fresh material, and develop characteristic lesions.

While infection may occur without gas, in most cases before death and especially after, there is an abundant formation of gas in the tissues. This is largely hydrogen formed through the splitting by the bacillus of either sugar or proteins. While the gas may be present in any of the tissues, in the body cavities, and in the blood-vessels, it is especially in the liver after death that the marks of gas accumulation are most striking. This organ may be riddled with small holes, presenting an appearance which has been characterized as "foamy liver" (Fig. 485, p. 738).

Infection may occur through wounds or injuries in any part of the body. It has been frequently observed in pregnant and puerperal women.¹ Ulcers of the stomach and intestine or of the urinary tract may be portals of entry. One of the more common forms of local infection is the so-called gaseous phlegmon or emphysematous gangrene. Pulmonary and pleural lesions, appendicitis, and peritonitis are described, as well as gaseous abscesses and purulent meningitis. While the usual action upon the tissues is the induction of bloody œdema and necrosis, this bacillus is also occasionally pyogenic.

The natural habitats of the organism are the soil and the intestinal canal. This accounts for the relative frequency of infection through the intestinal and genito-urinary tracts and through wounds contaminated with dirt.

Infection, especially from the intestinal canal, may apparently occur during the later hours of life, with or without symptoms and with a post-mortem formation of gas. It is often difficult to determine, since gas formation occurs so early and so extensively after death, whether the entrance has or has not been effected during life. It seems fair to infer, as the result of animal experiments, that when the gas formation, even after death, is widespread, ante-mortem infection has occurred.

Concurrent infection with other organisms, especially the pyogenic cocci, is frequent.

Welch and Nuttall early called attention to the importance of recognizing the possibility of infection with this bacillus in judging of a certain class of cases of alleged air embolism.

It is probable that the *Bacillus aërogenes capsulatus* is identical with forms which have been described under various names in connection with cases of gaseous phlegmon, or so-called malignant œdema.²

¹ For a study of *B. capsulatus* in puerperal infections see *Little*, Johns Hopkins Hosp. Bull., vol. xvi., p. 136, 1905.

² For an excellent critical *résumé* of this subject, with bibliography, see *Welch*, Johns Hopkins Hosp. Bull., vol. xi., p. 185, 1900; also *Ghon* and *Sachs*, Cbl. f. Bak., Abth. I., Orig. Bd. xxxv., p. 665; Bd. xxxvi., p. 1, 1904.

Malignant Œdema.

This disease is of occasional occurrence in man and certain domestic animals, horses, cattle, sheep—usually following some form of traumatism. It is a septicæmia with local, often hæmorrhagic œdema, visceral degeneration, etc.

The bacillus of malignant œdema, *Bacillus œdematis maligni*, which is frequently present in dust, in putrefying substances, and in soil, considerably resembles the *Bacillus œrogenes capsulatus* in both its morphological and biological characters. It is, however, more slender, and more apt to form threads; spore formation occurs readily in the ordinary media. It decolorizes partially by Gram's method. Other differential characters are to be made out in cultures. It is an excitant of hæmorrhagic œdema in animals, but with slight if any development of gas.

Other Bacteria which may Induce Hæmorrhagic Septicæmia.

Nearly related to the *Bacillus œrogenes capsulatus* and to the bacillus of malignant œdema are several other spore-forming anaërobic bacilli occurring especially in the earth, in excrement, and in various rotting substances. Some of these appear to be of pathogenic significance in the lower animals under both natural and experimental conditions.

Thus the *Quarter-evil* (Rauschbrand; charbon symptomatique), especially in Europe, is a serious infectious disease of sheep, goats, and cattle. At the seat of infection, often in the legs, there is a hæmorrhagic œdema with gas formation, the involved region often becoming much swollen and black in color ("black leg"). The bacillus which is the excitant of this disease is known, and preventive inoculation has been practised.

Howard has described a group of cases of *hæmorrhagic septicæmia* characterized by hæmorrhages into the skin, serous membranes, and viscera, in which capsulated bacilli apparently related to the above-described bacillus of Friedländer (p. 216) have been found. For the details of these cases and their relationship to other forms of septicæmia we refer to the original paper.¹

Meat Poisoning.

Meat poisoning may be due to some strain of *Bacillus enteritidis* which infects various animals. The meat of these diseased animals is not abnormal in appearance or taste but may contain the organism, and if not thoroughly cooled may induce serious gastrointestinal disorders in man. The meat of diseased cows and calves most frequently has been the source of infection. The infection is most common in summer and the infective agent may apparently be conveyed from man to man through excreta.

Several other forms of meat poisoning, some resembling typhoid fever, others involving a mild or violent gastro-enteritis, others especially characterized by toxæmic symptoms have been attributed to the presence of various bacterial organisms which we cannot consider further here.²

Botulism.

This is a toxæmia characterized by chills, giddiness, trembling, headache, and sometimes vomiting followed by symptoms such as loss of accommodation, dilated pupils, ptosis, aphonia, etc., referable to the action of some toxic substance. Death

¹ Howard, *Jour. of Exp. Med.*, vol. iv., p. 149, 1899; also Blumer and Laird, *Johns Hopkins Hosp. Bull.*, vol. xii., 1901, p. 45. See also Typhus and Rocky Mountain Spotted Fever.

² For a brief résumé of this group see Hiss and Zinsser "Text-book of Bacteriology," p. 428, 1910, and rel. therein.

may follow general motor paralysis and dyspnoea. Visceral hyperæmia, petechial hæmorrhage, and albuminous degenerations may be found. The disease has been shown to be due to an anaërobic, readily cultivated bacillus, *B. botulinus*, first isolated by van Ermengem from a contaminated ham which had poisoned many persons.

It is believed that the toxins inducing this condition are formed in the contaminated meats—ham, canned meat, and sausages—before their ingestion.

RELAPSING FEVER. (Typhus Recurrens; Famine Fever; Spirillum Fever; Seven-Day Fever.)

This disease is common in India, Africa, and many tropical countries, and has occurred in Russia and in the United States. It is characterized, apart from the fever and associated symptoms, by the presence in the blood at certain periods of a spiral organism discovered by Obermeier in 1873. Two cases occurring in this country have been recently reported by Carlisle.¹

THE LESIONS OF THE DISEASE.

There may be albuminous degeneration in the viscera, leucocytosis, catarrhal or croupous inflammation of the mucous membranes of the respiratory and digestive organs, ecchymoses in the skin and in the mucous and serous membranes. There may be pneumonia and pleurisy, degeneration of the cardiac muscle, hyperplasia of the mesenteric lymph-nodes.

The *spleen* may be large and flabby, this change being so extreme that rupture has occurred during life; it may also be the seat of infarctions, and these have given rise to peritonitis.

Characters of the *Spirochæta Obermeieri*.

In the blood of all parts of the body during the febrile attacks may be found, in very large numbers, a long, slender spiral called from its discoverer *Spirochæta Obermeieri* (*Sp. recurrentis*) (Fig. 168). The organisms disappear from the blood during the afebrile intervals, and it has been shown that at this time they accumulate in the spleen, where they are destroyed in large numbers, apparently through the action of phagocytic cells. The organism is in general from 7 to 9 μ in length, sometimes longer, and performs rapid, undulating movements.




FIG. 168.—SPIROCHÆTE OBERMEIERI.

The inoculation of healthy men and of monkeys with the blood of relapsing-fever patients which contains the organism induces a similar disease. Norris and Pappenheimer have made successful inoculations of white rats with a spirochæta believed to be of this species.² Pure cultures of these organisms through several generations have not as yet been made, but for the reasons indicated, and since the organism has never been found except in connection with the disease, there is every reason for believ-

¹ Carlisle, Jour. Inf. Dis., vol. iii., p. 233, 1906, bibl.

² Norris, Pappenheimer and Flournoy, Jour. Inf. Dis., vol. iii., p. 266, 1906.

ing that the *Spirochæta Obermeieri* is the excitant of relapsing fever.¹ The organisms are considered to be protozoa by many observers, though Novy regards them as definitely bacterial in nature.

TICK FEVER.

This is a disease of Uganda, Abyssinia, and the Congo region in Africa. The parasite has been studied by Novy and Knapp,² and designated by them *Spirochæta Duttoni*. The pathological changes induced in the body by the parasite are the same as those caused by the presence of the *Spirochæta Obermeieri*. The organism is transferred by the bite of the *Ornithodoros moubata*, a tick in which it can live for a long time.

Dutton and Todd³ have been able to induce the disease in monkeys by causing these animals to be bitten by the infested ticks.

Morphologically the parasite resembles very closely the *Spirochæta Obermeieri*, except that the organisms are somewhat thicker.

VINCENT'S ANGINA.⁴

This is an inflammation of the mouth, pharynx, and tonsils, often associated with a pseudo-membrane and sometimes leading to ulceration. There is usually but moderate systemic disturbance. While in the lesions there are frequently many bacteria, two forms usually associated are most commonly found, one spindle-shaped resembling a bacillus, the other spiral-shaped, longer than the first, with shallow irregular curves, and staining with difficulty.

These two organisms, formerly thought to be bacteria living in symbiosis, are now commonly regarded as representing different phases of one organism,⁵ probably protozoan, and related to the spirochætas.

The organisms have been cultivated artificially under anaërobic conditions. But their relationship to Vincent's angina and to each other may wisely be considered as not yet fully determined.

YAWS (FRAMBCESIA TROPICA).

This disease of tropical and subtropical countries is characterized chiefly by a papular eruption, with ulcerations suggestive of a relationship to syphilis. In the lesions, Castellani in 1905 demonstrated spirochætas resembling *Treponema pallidum*; and the observation has been repeatedly confirmed. The infective agent can be transmitted to monkeys and to rabbits by inoculation of material from the lesions.⁶ It

¹ See for résumé, Novy and Knapp, *Jour. Inf. Dis.*, vol. iii., p. 291, 1906; also *Wladimiroff* in *Kolle and Wassermann's "Handbuch der Mikroorganismen,"* Bd. iii., p. 75, 1903, bibl.

² Novy and Knapp, *Jour. Inf. Dis.*, 1909, iii., 379.

³ Dutton and Todd, *Brit. Med. Jour.*, 1905, ii., 1259; Ross and Milne, *Brit. Med. Jour.*, 1904, ii., 1453.

⁴ Vincent, *Ann. de l'inst Pasteur*, xiii., 606, 1899, and *ibid.*, *Lancet*, 1905, vol. i., p. 1260.

⁵ Tunnickliff, *Jour. Inf. Dis.*, iii., 148, 1906.

⁶ See for a study of experimental yaws in the monkey and rabbit, *Nichols*, *Jour. Exp. Med.*, xii., 616, 1910.

seems clear that though the inciting agent of yaws, *Spirochæta pertenuis* (*Treponema pertenuis*) resembles the syphilis organism, the diseases are entirely distinct.

HYDROPHOBIA. (Rabies.)

MORPHOLOGY OF THE LESIONS.

This is an infectious disease occurring most frequently in the carnivora, and especially common in dogs and wolves and usually communicated to man by bites of the rabid animals.

The lesions are not constant nor are they characteristic. Though well marked in some cases, in others they are but very slightly developed. Changes, when present, are apt to be most pronounced in the medulla oblongata and pons, but they may be present in the spinal cord. They

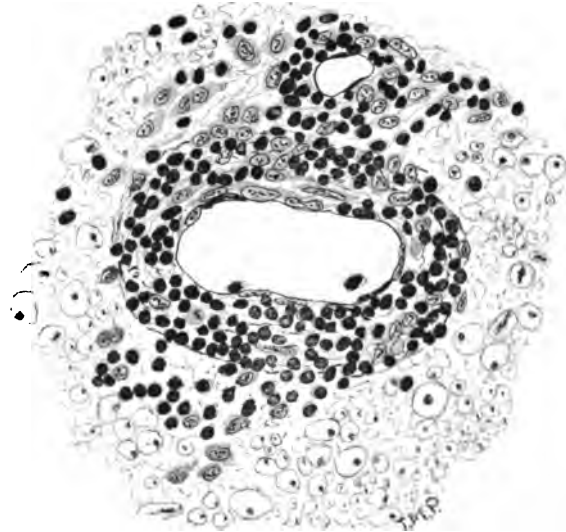

FIG. 169.—HYDROPHOBIA. TRANSVERSE SECTION OF SMALL BLOOD-VESSELS IN THE SPINAL CORD. Showing accumulation of leucocytes and proliferation of connective-tissue cells in the adventitia of the vessels.

consist of small hæmorrhages, accumulation of leucocytes in the perivascular lymph spaces about the blood-vessels (Fig. 169) and around the ganglion cells, of thrombi in the smaller blood-vessels, and finally of chromatolysis of the ganglion cells.¹

Changes have been described in the intervertebral ganglia and in the plexiform ganglia of the pneumogastric nerve, which, although not limited to rabies, are yet so frequently present as to be apparently of value in diagnosis. The lesions consist in degeneration or atrophy or destruction of the ganglion cells with a proliferation of the endothelial cells lining the capsule.²

¹ Bailey, Jour. Exp. Med., vol. v., p. 581, 1901.

² See Ravenel and McCarthy, University Med. Mag., vol. xiii., p. 766, 1901.

ANIMAL INOCULATIONS.

Since the infective agent of rabies is present in the central nervous system of victims of the disease, this material, *i.e.*, brain and spinal-cord tissue, especially from the cord, is used in experimental work. This is called the "virus" of rabies. Rabbits and guinea-pigs, as well as various other animals, are susceptible to subdural injections, after trephining, of a small amount of emulsion of the infective nerve tissue. After an incubation period varying in different animals, these succumb with characteristic symptoms and lesions.¹

THE EXCITANT OF THE DISEASE.

The infective agent appears to be carried especially along the nerves from the point of inoculation to the central nervous system, where it seems to develop. It is not present in considerable quantity in either blood or lymph.

It is known that the infective agent is in the saliva and salivary glands of rabid animals, and that it may be present in the saliva of the dog from three to five days before the symptoms of the disease appear. It seems to be especially concentrated in the central nervous system. It is readily rendered inert by corrosive sublimate and other germicides. It resists cold even to -20° C. but loses virulence after one hour's exposure to 50° C. It is preserved for some time in glycerin.

It has been found that the rabic virus may pass the pores of an unglazed porcelain filter not pervious to ordinary bacteria, so that some form or developmental phase of the organism must be extremely minute.

Negri Bodies.—In 1903 Negri announced that he had seen in sections of the central nervous system of rabic animals within the ganglion cells, rounded bodies from $1\ \mu$ to $23\ \mu$ long, containing vacuoles and granules often grouped around a larger central structure. These bodies he regarded as parasites belonging among the protozoa and believed them to be the specific inciting factors in hydrophobia. These intracellular structures, now called "Negri bodies," have been the object of many careful researches, and the observations of Negri have been in general confirmed and extended.

The "Negri bodies" are, as a rule, most abundant in the large ganglion cells of the Hippocampus major (Ammon's horn), but occur in ganglion cells of the cerebral cortex and elsewhere. They are readily stained and appear to consist of a rounded or oval, homogeneous basement substance containing a central body surrounded by variously shaped granules (Fig. 170). They occupy central or peripheral positions in the ganglion cell and vary greatly in number in different cases of rabies.

Similar cell inclusions have been found in animals inoculated with "fixed virus" (see below), but they are smaller and more difficult of detection than in street rabies and in animals inoculated with the street-rabies virus. Negri bodies have been found in nearly all cases of street

¹ For further data see epitome in *Kolle and Hetsch*, "Bakteriologie," 1906.

rabies examined for them, and in no infective or other disease than rabies. Their constancy in street rabies has led workers in this field to regard them as of the utmost diagnostic value. While their nature is not yet definitely established, their morphology and staining qualities seem to be consistent with the assumption of their protozoan character. They have indeed been named by Williams *Neuroryctes hydrophobia*. Their uniform presence in street rabies and the frequent presence of

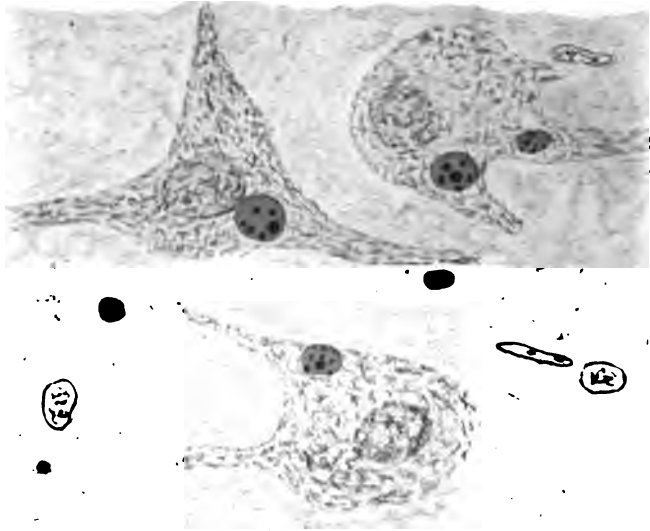


FIG. 170.—NEGRI BODIES.
In smears from Ammon's horn of rabid dog.

smaller similar structures in fixed virus and in animals inoculated with this, together with their absence in diseases other than rabies, seems to justify the tentative assumption of a specific etiological relationship to hydrophobia.¹

Preparation and Staining of "Negri Bodies."

Williams-Lowden Method.—While the earlier studies were made on sections, Williams and Lowden² have shown that in stained smears of the nerve tissue made upon slides, which is much simpler than sectioning, the "bodies" are more clearly demonstrated, and that this method for diagnostic and other purposes is to be preferred. The technique of making and staining smears as devised by Williams and Lowden is in outline as follows:

On a clean slide a small bit of the gray matter is placed, and a cover-glass is lightly pressed upon it, spreading it into a thin layer, then moved along the slide, leaving a uniform thin smear of the substance. The smears are dried in the air.

Staining may be done by the Giemsa solution (p. 1037) or by the eosin methylene-blue stain of Mallory. The latter is effected as follows:

¹For an excellent *résumé* and study of "Negri bodies" with bibliography see Williams and Lowden, *Jour. Inf. Dis.*, vol. iii., p. 452, 1906.

²*Ibid.*, p. 459.

Fix smears in Zenker's fluid for one-half hour; rinse and place in iodized, 95-per-cent. alcohol for fifteen minutes; in 95-per-cent. alcohol and absolute alcohol, successively, one-half hour each; aqueous eosin solution, twenty minutes; rinse in water; place in Unna's alkaline methylene-blue solution (methylene blue, 1; carbonate of potash, 1; water, 100) diluted 1-5 or 1-10 for fifteen minutes; differentiate in 95-per-cent. alcohol from one to five minutes; dry with filter paper; balsam. By this method the cytoplasm of the Negri bodies is magenta in color, the central bodies and associated granules dark blue, the ganglion cell-body light, and its nucleus a darker blue.¹ The red blood cells are a brilliant eosin pink.

Frothingham's Impression Method.—To avoid the distortion of the ganglion cells and the disturbance of their relationships inevitable in the "smear" method, and to enable the operator to recognize the topography and thus select for examination the larger cells lying just outside the hilus in which Negri bodies are more commonly found, Frothingham recommends the following procedure for rapid diagnosis.² Dissect out the Ammon's horn, removing extraneous tissue from the edges. With scissors cut out a small disc at right angles to the long axis of the organ from any part desired and place it upon a board near its edge so that one of the flat surfaces of the disc rests upon the board, the other being exposed. The grouping of nerve cells may now be seen in distinct white lines.

Place a thoroughly cleaned slide upon this disc of tissue, press it gently and lift suddenly. The disc adheres to the wood, and an impression of its upper surface is left upon the glass. Repeat, using a new portion of the slide and a little more pressure. A third impression is made, using still more force, and a fourth using sufficient pressure to flatten the disc almost completely.

Before these impressions have dried, place in methyl alcohol for 1/2 to 2 minutes or longer. Remove from the alcohol and cover with Van Gieson stain. Warm gently for 1/2 to 2 minutes till a light vapor rises. Wash in water, dry with filter paper, and examine without cover, first with low power to locate best cells, then with oil immersion.

Frothingham slightly modifies Van Geison's stain, using water 20 c.c.; saturated alcoholic solution of fuchsin, 3 drops; saturated aqueous solution of methylene blue, 1 drop, prepared fresh each day. The Negri bodies are stained pale pink to pinkish red, the ganglion cells are bluish.

PREVENTATIVE INOCULATION.

Notwithstanding his total ignorance of the micro-organisms concerned in inciting hydrophobia, his genius in wise experiment enabled Pasteur to establish a method for artificial immunization against the disease which has proved most beneficent.

He first obtained a virus of high and definite intensity. This was accomplished by a series of inoculations beneath the dura mater in rabbits of portions of the spinal cords of rabid animals. This was called "*virus fixé*"—fixed virus. It was found that by drying in the air, spinal cords of rabbits having definite and high virulence—fixed virus—with due protection against aërial contamination, the virulence diminished day by day. With virus thus obtained of virulence ranging from that which is practically inert to that of the utmost potency, it has been found possible, by subcutaneous injections, safely to accustom both animals and men to the presence of amounts of hydrophobia virus contained in the spinal cord emulsion, which under ordinary conditions

¹ For the details of the Giemsa staining and a new and promising stain for Negri bodies suggested by Van Gieson, see *Williams and Loudon, Jour. Inf. Dis.*, vol. iii., p. 452, and foot-note p. 461, 1906.

² See *Frothingham, "The Rapid Diagnosis of Rabies," Jour. Med. Res.*, vol. xiv., p. 471, 1906; also *Am. Jour. Pub. Hygiene*, Feb., 1908.

would prove speedily fatal. In other words, it has been found possible to confer artificial immunity against the disease.

This process occupies several days, and immunization must be completed before the disease has begun to manifest itself; but as the incubation period in hydrophobia is fortunately a long one—the average is about forty days—it has been possible, in a large and increasing number of cases, to save the lives of persons bitten by rabid animals.¹

This work is now done in laboratories maintained for the purpose and requires care and experience in the preparation of the virus as well as in diagnosis.

DIAGNOSIS.

In view of the importance of diagnosis in animals which have died or have been killed under suspicion of rabies, the brain, spinal cord, medulla, and ganglia should be saved.

The presence of Negri bodies is believed to be diagnostic for rabies, so that these should be sought for in the fresh tissue by the methods indicated above. But considerable experience is required for this work.

The examination of the plexiform and other ganglia, and of the perivascular tissue and ganglion cells in hardened tissue for possible changes, may be useful in cases of doubt, though not in themselves positively diagnostic. Finally, it may be necessary to have recourse to the so-called biological test by the subdural inoculation of susceptible animals with fresh material from the medulla of the suspect. Portions of the fresh medulla in watery emulsion are inoculated beneath the dura mater of three healthy rabbits or guinea-pigs, and the development of rabic paralysis and other symptoms awaited. This operation for diagnostic purposes should be done only by one experienced in this subject.²

It is always wise *not* to kill animals suspected of rabies, but to keep them under observation in confinement. Rabies being always fatal, recovery from a suspicious disease excludes it, so that further protective measures may be clearly unnecessary. On the other hand, the carefully observed symptoms of a suspected animal may even in the event of a fatal termination afford valuable evidence. If the laboratory for diagnosis be accessible, it is well, if the suspected animal should die or be killed, to send the whole animal or the head cut off low down, packed in ice. Cold does not rapidly diminish the virulence of the rabic virus. If the material is to be transmitted for a long distance, after the preparation of impressions or smears from the gray matter of Ammon's horn, the brain of the animal with the medulla, carefully removed to avoid contamination, may be sent in a sterilized bottle containing a mixture of equal parts of glycerin and water, which has been sterilized by boiling and cooled.

¹ See, for details of preventive inoculations, *Park and Williams*, "Pathogenic Bacteria and Protozoa," 1910; also for general summary and bibl. *Stimson*, Pub. Health and Mar. Hosp. Ser., Bull. 65, 1910.

² For further details of diagnosis, see ref. to *Williams and Lowden*, p. 295; *Frothingham*, ref. p. 296; and *Park and Williams*, *l. c.*

It has been found that by the cauterization of the wounds, made by rabid animals, with fuming nitric acid, the infective agent may be destroyed even after the lapse of several hours.

ACUTE ANTERIOR POLIOMYELITIS. (Infantile Paralysis.)

Acute anterior poliomyelitis is an infectious disease occurring in epidemic and sporadic forms, affecting especially young children, and definitely, though apparently not readily, communicable.

While before 1907 epidemics of this disease were infrequent in the United States, since that time it has widely prevailed. In Europe also within the past few years the disease has been of frequent occurrence and widespread.

It is characterized by an exudative inflammation of the meninges, especially of the spinal cord, but often involving both the brain and the cord, which often leads, probably by compression of the blood-vessels, to destructive changes in the ganglion cells, particularly of the anterior horns, and to paralysis and atrophy and contracture of the associated muscles.

The infective agent is not yet known, but many of its characters have recently been established through animal experiments. Although a series of earlier studies had shown that the disease could be incited in monkeys by the intraperitoneal injection of emulsion of nerve tissue from fatal cases of infantile paralysis, it was not until 1909 that Flexner and Lewis succeeded in carrying the infective agent from a human case on through several monkeys in series, by the intracranial inoculation of nerve tissue of infected animals.¹ It was then discovered that experimental infection can be secured by inoculation in the subcutaneous tissue, blood-vessels, and nerves. These observers found further that the infective material may be present, not only in the brain and cord of infected animals, but also in the blood, spinal fluid, naso-pharyngeal mucous membranes, and lymph-nodes. It has also been found in the salivary glands.

It has been shown that the infective agent can pass the pores of a Berkefeld filter, but it is so exceedingly minute that no optical or cultural tests reveal its presence. Its virulence is retained after drying or preservation in glycerin for several days, and it is readily killed by heat—45° to 50° C. for 30 minutes, but sustains prolonged cold.

There is at present no definite clue to the nature of the ultramicroscopic organism thus shown to incite the disease.

In infected monkeys the symptoms and lesions of the disease in man are fairly reproduced. The lesions in the monkey are primarily and chiefly cellular infiltrative changes in the perivascular lymph spaces of the arteries entering the nerve tissues. This leads to temporary occlusion of the vessels, focal hæmorrhage and œdema and degeneration of the nerve tissues with necrosis and disintegration. While the brain may

¹ Flexner and Lewis, *Jour. Exp. Med.* xii., 227, 1910; see also for general review of poliomyelitis, Flexner, *Jour. Am. Med. Assn.*, lv., 405, 1910, bibl.

be involved, the lesions are especially marked in the spinal cord and medulla.

For details of the lesions in man, see page 967.

Communicability.—Clinical evidence of the communicability of epidemic poliomyelitis is abundant. Since it has been shown by Flexner and Lewis, not only that the naso-pharyngeal mucosa in animals artificially infected by intracranial injections may contain the infective agent, but that on rubbing the virus from an infected animal over the scarified naso-pharynx of monkeys characteristic paralysis may follow, one is at present led to assume that the discharges from the mouth and nose of victims of the disease should be properly cared for.¹

Immunity.—Flexner and Lewis have shown that a certain immunity is secured in monkeys by a successfully weathered artificial infection. But the nature of this immunity is not yet quite clear, nor are the preliminary studies on the production of immunizing sera sufficiently advanced to justify very confident prediction of success in the immediate future.²

TYPHUS FEVER. (Hospital Fever; Spotted Fever; Jail Fever; Ship Fever, etc.)

This highly contagious, infectious disease has not, so far as we know, any characteristic lesion save the petechial skin eruption; but after death the body may present lesions common to many of the infectious diseases. It may be classed among the hæmorrhagic septicæmias.

The body has a tendency to rapid putrefaction, and the *blood* is often darker and more fluid than is usual in other diseases.

The *voluntary muscles* may be the seat of waxy and albuminous degeneration. The *brain* and its membranes may be congested; the *mucous membrane of the pharynx and larynx* may be the seat of catarrhal or croupous inflammation. There may be bronchitis, broncho-pneumonia, or hypostatic congestion of the *lungs*. The walls of the *heart* may be soft and flabby.

The *agminated nodules* of the ileum and the *mesenteric nodes* may be swollen. The *spleen* is often large and soft from hyperplasia. The *kidneys* and *liver* are frequently large and pale, and the seat of albuminous degeneration.

It was shown in 1909 by Nicolle that³ the infective agent of European typhus may be conveyed from man to monkeys by the blood, a typical eruption characterizing the infection and that it was transmissible by bodylice. But the attempt to infect monkeys in series was not successful.

MEXICAN TYPHUS.

There occurs in Mexico a febrile, apparently infectious and communicable disease characterized by a petechial eruption and resembling typhus fever. Its identity with the latter has, however, not been posi-

¹ For a consideration of the naso-pharyngeal mucosa as a portal of entry, see *Flexner*, ref. p. 299.

² For an interesting *résumé* of the nature, prevalence, and prevention of the disease, see *Frost*, *Pub. Health Repts. U. S. Mar. Hosp. Service*, xxv., 1663, 1910.

³ *Nicolle*, *Compt. rend. Acad. Sc.*, cxlix., 157, 1909.

tively established. It is called *Tabardillo*, or Mexican typhus. Like typhus, it seems to belong to the group of hæmorrhagic septicæmias.

Anderson and Goldberger¹ in 1909 found that the infective agent of Mexican typhus could be conveyed by the infected blood to monkeys.

Ricketts and Wilder in 1910² confirmed the susceptibility of monkeys by the incitement of fever and other symptoms through injections of the blood of human cases. They also secured infection in monkeys by the bites of body lice, *Pediculus vestimenti*, infected from man and from other monkeys, and by the fæces of infected lice introduced into the skin. Immunity is secured in monkeys by even mild infections.

In Giemsa stained preparations of the blood of infected patients from the seventh to twelfth days, short bacilli were found by Ricketts and Wilder and by McCampbell³ but could not be cultivated. These were non-motile and in general resembled those of the hæmorrhagic septicæmia group. No trace of protozoa was discovered.

ROCKY MOUNTAIN SPOTTED FEVER. (Tick Fever.)

This infectious febrile disease, occurring chiefly in the spring in Montana and adjacent Rocky Mountain States, is often fatal, not communicable, and without obvious characteristic lesions save petechial and other spots of the skin which mark it as one of the groups of hæmorrhagic septicæmias.

In 1902, Wilson and Chowning described the occurrence of ovoid bodies in the red blood cells of the victims of the disease, which they regarded as protozoa, and believed were conveyed through the bite of ticks.⁴ Later observations have failed to confirm the presence of the alleged protozoa in the blood. But it has been found by Ricketts and Gomez⁵ that guinea-pigs, rabbits, and monkeys are susceptible to the disease on inoculation with the blood of patients. The disease was maintained in the laboratory by alternate passage of the virus in blood or organ emulsion through monkeys and guinea-pigs. It was found that the infective agent may be conveyed by the bite of infected male or female ticks, *Dermacentor occidentalis*; that it is transmitted by the infected female tick to its young through the eggs. The larvæ of these eggs feeding on susceptible animals may incite the disease.

Ricketts⁶ found in the blood of fever patients and of infected guinea-pigs and monkeys small bodies resembling short bacilli. These are believed to be bacteria, though attempts at culture have not been successful, and are conjectured to be allied to the hæmorrhagic septicæmia group. They are agglutinated with specific serum. It was found that after the infection guinea-pigs and monkeys acquire definite immunity and that their serum is protective.

¹ Anderson and Goldberger, Jour. Med. Res., xxii., 469, 1910.

² Ricketts and Wilder, Jour. Am. Med. Assoc., 54, 463; 1304, 1373, 1910.

³ McCampbell, Jour. Med. Res., xxiii., 71, 1910.

⁴ Wilson and Chowning, Jour. Inf. Dis., i., 31, 1904.

⁵ Ricketts, Jour. Inf. Dis., iv., 141, 1906.

⁶ Ricketts, Jour. Am. Med. Assoc., lii., 379, 1909.

YELLOW FEVER.

LESIONS OF THE DISEASE.

Yellow fever is endemic in tropical America, occurs on the west coast of Africa, and occasionally invades the temperate zones of America and Europe.

This infectious disease of man is without characteristic lesions save for the hæmorrhages and pigmentation in the skin. Such other lesions as commonly exist are those common to toxæmia. The following conditions are, however, frequently present after death:

Rigor mortis is marked and occurs early.

The *brain* and its meninges are usually congested. *The skin* is of a yellow color from the presence of the bile pigment, and may be mottled by ecchymoses. Ecchymoses are frequent in the mucous and serous membranes.

The heart is of a pale or brownish yellow color. Its muscular fibres may be the seat of fatty degeneration. *The lungs* may be congested.

The stomach often contains a characteristic dark fluid, due to altered blood pigment, similar to that which is vomited during life—black vomit. Its mucous membrane may be congested, softened, and is sometimes eroded. *The intestines* are dark-colored, often distended with gas, and sometimes contain blood. *The liver* in the earlier stages of the disease may be intensely congested. More frequently it contains but little blood, is of a light yellow color, and the hepatic cells show the changes of an intense albuminous degeneration, often much more marked than are found in any other disease except acute yellow atrophy of the liver. Areas of focal necrosis may be present. The gall-bladder is apt to be contracted.

The spleen shows no marked changes. *The kidneys* present an intense albuminous degeneration. The tubules usually contain masses of hyaline material.

THE EXCITANT OF THE DISEASE.

While its mode of occurrence and the characters of its symptoms and lesions indicate that yellow fever is an acute infectious disease, none of the various studies which have been made upon its etiology has as yet revealed the presence of any micro-organism which can be confidently accepted as its excitant.¹

THE MODE OF INFECTION.

It has been shown by Reed and his colleagues, Carroll and Agramonte, that the infectious agent in yellow fever may be transmitted by the subcutaneous injection into a healthy individual of a small quantity of blood drawn from a patient in the early stage—first three days—of the disease.

¹ The various studies of Sternberg, who isolated a bacillus which he called "Bacillus x," and of Sanarelli, who found a bacillus which he named *Bacillus icteroides*, are the most noteworthy earlier contributions to the subject. A later study and references to the bibliography of this subject may be found in an article by Reed and Carroll, Jour. Exp. Med., vol. v., p. 215, 1900.

It has, furthermore, been shown by repeated and abundantly confirmed experiments that yellow fever may be induced in a non-immune individual by the bite of the mosquito—*Stegomyia calopus*—which has previously—at least twelve days—bitten a patient in an early stage of the disease. Practical sanitary procedures, based upon the hypothesis that this mosquito acts as an intermediate host in which the (unknown) yellow-fever parasite passes one of its developmental cycles, have furnished strong evidence that it is through the intervention of this mosquito, and thus only, that the disease is conveyed. For it has been possible, by the prevention of access of this mosquito to yellow-fever patients through the use of netting and other precautionary measures, practically to suppress the disease in Havana, where it was formerly endemic, and to stifle epidemics elsewhere.¹ It has been further demonstrated in the most conclusive way that the infectious agent in yellow fever is not conveyed directly through the air or by fomites.² That it is an extremely minute organism is shown by the fact that it can pass through the pores of a Berkefeld filter.

VARIOLA. (Smallpox.)

Smallpox is an acute, readily communicable, infectious disease, especially characterized anatomically by an inflammation of the skin which passes through a series of more or less distinctive phases of papule,

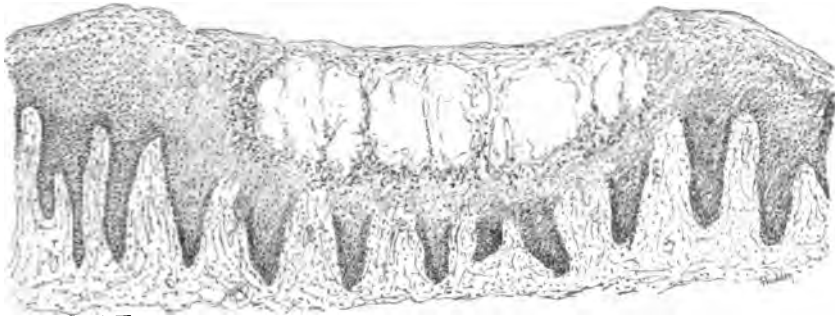


FIG. 171.—A SMALLPOX VESICLE OF THE SKIN.

vesicle, pustule, with a final drying of the exudate and necrotic tissue constituting the crust.

Various phases of the exanthem are used to designate forms of the disease.

¹ For a summary of observations relating to the mosquito as an intermediary host of the infectious organism in yellow fever, see *Reed, Carroll, and Agramonte*, Phila. Med. Jour., October 27th, 1900; also *Jour. Am. Med. Assn.*, vol. xxxvi., p. 431, 1901; *Amer. Med.*, vol. ii., p. 15, 1901; *Guiteras*, *Amer. Med.*, vol. ii., p. 809, 1901; *Durham, Thompson Yates' Laboratories Report*, vol. iv., 1901, p. 485; *Reed and Carroll*, *Amer. Med.*, vol. iii., p. 301, 1902; also *Carroll*, *Jour. Am. Med. Assn.*, vol. xl., p. 1429, 1903. A summary and bibliography by *Goldberger* is in *Bull. No. 16 of the Yellow Fever Institute, 1907.*

² For a brief résumé of the reasons for the belief that the mosquito is the sole agent in the conveyance of the infectious agent in yellow fever, see *Carter*, *Bull. of the Yellow Fever Institute*, No. 10, July, 1902, Bureau of Public Health and Marine Hospital Service, U. S. A. For a description of the mosquito *Stegomyia calopus* and modes of prevention in yellow fever see *Reed and Carroll*, *Med. Record*, vol. lx., p. 641, 1901. For the bearing of this subject upon quarantine regulations see *Doty*, *Med. Record*, vol. lx., p. 649, 1901.

Secondary lesions are diffuse suppurative inflammation of the skin, congestion, inflammation, and ulceration of the mucous membranes, hæmorrhages in various parts of the body, swelling and ulceration of the lymphatic tissues, albuminous degeneration of the kidney, liver, and spleen, and leucocytosis.

The skin lesion shows in general at first circumscribed areas of inflammation above the ends of the papillæ, with the development of a fluid-filled reticulum, so that vesicles more or less umbilicated are formed (Fig. 171). These at first contain a clear fluid, but by the gathering of pus cells the fluid becomes turbid and accumulates to form a pustule. Hand-in-hand with these changes the papillæ and adjacent layers of the corium may become infiltrated with cells. The contents of the pustules and the necrotic tissue above dry and form the crusts. When the changes are largely confined to the epidermis, the lesion may leave no deformity. But if the changes in the cutis are considerable, cicatricial tissue may form, leaving scars. The association of local hæmorrhage with the above changes gives rise to the hæmorrhagic form of exanthem.

ARTIFICIAL IMMUNIZATION IN SMALLPOX.

Smallpox affords one of the most striking examples of positive and prolonged acquired immunity conferred by a successfully weathered attack of an infectious disease.

In the early days attempts were made to mitigate the virulence of smallpox acquired by exposure in the usual ways by artificial inoculation of material—virus—taken from a smallpox pustule. The usually relatively mild form of the disease induced in this way also conferred immunity. But the individual was during his immunization a source of danger to others. The great discovery of Jenner that by inoculation with virus from cowpox, immunity was secured against smallpox need not be considered in detail here. The immunity secured in this way, while not absolute, is usually effective and involves as a rule but slight indisposition. By revaccination after an interval of a few years practical protection is secured, so that the occurrence of smallpox epidemics to-day is possible only through neglect of simple and positive protective measures.

The more recent view of the immunity conferred by vaccination against smallpox is based upon the demonstration that the disease variola in man and the disease vaccinia in the bovine species are of the same nature and not different, as was formerly believed. This has been established by numerous inoculation experiments. The disease in the cow is a modified form of the human disease. The effect of the passage of the unknown micro-organisms through the insusceptible bovine—thus runs the rationale in the new light—is so to diminish the virulence of the germ that by its subsequent inoculation in man immunity is secured without the profound disturbance which infection with a germ of unmitigated virulence would involve.¹

¹ In *diphtheria* the perfection of the process of artificial immunization and the establishment of a precise and successful curative method are the direct results of a long, patient, logical series of animal

THE EXCITANT OF SMALLPOX.

Bacteria.—The large number of studies which have been made of the skin lesions of smallpox and of vaccine lymph have shown that bacteria of various kinds are frequently present.¹ Streptococci and staphylococci are especially common in the pustules and may be present in the blood in later stages of severe or fatal cases.² It is probable that the pyogenic cocci are of great importance as complicating factors in the disease. But there is no evidence at hand that these or any other bacteria are its primary excitants.

Protozoa.—While it was natural that the most painstaking search should be made for bacteria in the lesions of smallpox, there have been from the first many obvious reasons for the conjecture that this disease as well as the other exanthemata might be incited by organisms of a different nature. In fact, as early as 1886 and 1887 bodies were found in the pustules by Van der Loeff and L. Pfeiffer, which they conjectured to be protozoa. It was not until 1892, however, when Guarnieri undertook a series of noteworthy experiments in animals, that the nature of the suspected structures in vaccine lymph became clearer. Guarnieri inoculated vaccine lymph into the cornea of rabbits and noted the appearance after a few days in increasing numbers in the epithelial cells of the structures which had been previously discovered in the contents of smallpox pustules. In some of these bodies he believed that he saw amœboid movements. These bodies, which were called "vaccine bodies," he regarded as protozoa and named the species *Cytoryctes vaccinæ*.³

These observations of Guarnieri on the vaccine bodies found in the lesions of both vaccinia and variola were confirmed by Wasielewski⁴ and many other observers.

The vaccine bodies of Guarnieri are spheroidal, oval, or irregular structures from 1 μ to 4 or even 8 μ in diameter, staining readily with various dyes, the central portion giving in general the staining characters of nuclear substance, a peripheral zone being sometimes differentiated by cytoplasmic stains. The bodies often lie close upon the border of the nucleus of the epithelial cells, sometimes lying in a depression of the nuclear border. They may, however, lie in other parts of the epithelial cytoplasm. They are frequently surrounded by a clear space, which may become of considerable size. They have not been found in the nucleus.

experiments with a definite end in view, and by the use of the absolutely identified and well-known germ which induces the disease. On the other hand, it is not a little curious that in *smallpox* and in *hydrophobia* effective methods of immunization should have been perfected without precise knowledge of the micro-organisms which incite the diseases, and yet by procedures which, though somewhat empirically hit upon, are nevertheless in close accord with those which the most recent studies on immunity in general have shown to be effective. Thus in both smallpox and hydrophobia the material used for protective inoculation is that which has been artificially reduced in virulence; in the one case—smallpox—by its passage through the body of a relatively insusceptible animal; in the other—hydrophobia—by drying in the air.

¹ See *Huguenin*, Lubarsch and Ostertag's "Ergebnisse," Jahrg. iv., p. 387, bibl.

² See report by *Ewing*, Trans. Assn. Am. Phys., vol. xvii., 1902, p. 213; also *Perkins* and *Pay*, Jour. Med. Res., vol. x., 1903, p. 180.

³ This name was given because the bodies frequently lay in small spaces in the cell protoplasm, which he assumed to have been formed by the destructive action of the parasite.

⁴ Consult for a most admirable summary of the subject, with original studies, photographs, and bibliography, *Wasielewski*, Zeitsch. f. Hyg., Bd. xxxviii., 1901, p. 212.

Hand-in-hand with the increase of these bodies there are progressive degenerative processes in the epithelium of the inoculated region, with the formation of various structures characteristic of the degeneration of protoplasm under a great variety of conditions.

While many observers following Guarneri have felt justified, largely on morphological evidence, in the belief that the vaccine bodies are protozoa, others have been led to the conclusion that many, if not all, the appearances presented can be accounted for by protoplasmic degenerations induced by other agencies. Several experimenters, indeed, by the introduction into the rabbit's cornea of chemical and other substances not at all related to the vaccine virus, have been able to induce degenerative protoplasmic structures resembling the vaccine bodies. The studies of Ewing on this subject are of especial significance.¹

It is evident that the proof on morphological grounds alone of the protozoan nature of such minute structures is a task of extreme difficulty, associated as they frequently are with the readily stained products of protoplasmic degeneration.

In April, 1903, Councilman announced the results of a long series of studies by himself and his associates, Magrath, Brinckerhoff, and Tyzzer, on the excitant of smallpox.² The observations of Guarneri, Wasilewski, and others, on the vaccine body, were in the main confirmed. These observers found the vaccine bodies in the lower layers of skin epithelium before the production of the vesicles and in the advancing edges of the young vesicles. They found morphological evidence of the segmentation of the bodies and the formation of round, spore-like structures about 1μ in diameter. Councilman further announced the discovery of other bodies, not before described, within the nucleus of the epithelial cells in the infected region in man. These intranuclear structures are circular, ring-like, with a central dot, and may be seen singly or in clusters. They are from 1 to 1.5μ in diameter. These intranuclear bodies Councilman regards as a further stage and as representing a second complex cycle of development of the smallpox parasite. The intranuclear structures he believes to be developed from the spore-like bodies, resulting from the segmentation of the intracellular vaccine body, which penetrate the nucleus. Councilman finds the vaccine bodies both in the epithelial cells of the smallpox lesion in man and in the lesion induced by vaccination of the rabbit and calf. But the intranuclear forms have not been found in the latter animals. After inoculation of the monkey with the contents of smallpox pustules, both the intracellular and the intranuclear forms were found. He believes it to be probable that in smallpox the parasite undergoes complete development, passing through two cycles, an intracellular and an intranuclear, while in vaccinia only one, the primary, cycle is achieved.³

¹ See Ewing, *Jour. Med. Res.*, vol. xii., p. 509, 1904; also *ibid.*, vol. xiii., p. 233, 1905.

² "Studies on the Pathology and on the Etiology of Variola and Vaccinia," *Jour. of Med. Res.*, vol. xi., 1904; see also summary by Councilman, *Am. Med.*, vol. x., p. 689, 1905.

³ For studies on experimental variola and vaccinia in monkeys see Brinckerhoff and Tyzzer, *Jour. Med. Res.*, vol. xiv., p. 209 *et seq.*, 1906. See also, for studies on reaction of variola virus to external conditions, *ibid.*, p. 352.

Calkins, from an independent study of the material furnished by Councilman, is convinced of the protozoan nature of the organisms in question and now groups them among the rhizopods.¹

It is clear that final judgment upon the nature and significance of these minute structures must be suspended until further experiments upon suitable animals shall have furnished fuller biological data than are yet at hand, which may sustain the evidence, still largely morphological, on which these suggestive conclusions are based.²

SCARLET FEVER. (*Scarlatina*.)

This is an infectious, readily communicable disease characterized by a diffuse skin eruption, and frequently accompanied by inflammation, either catarrhal, or croupous, or gangrenous, of the tonsils, pharynx, and larynx. Focal necroses, albuminous degeneration in the viscera, and leucocytosis with moderate eosinophilia may occur.

There may be acute hyperplasia or suppuration of the cervical lymph-nodes. There is very frequently an acute exudative or an acute diffuse nephritis.³ The spleen may be enlarged. Broncho-pneumonia, endocarditis, and pericarditis may complicate the disease.

The exanthem or skin eruption in scarlatina is a simple dermatitis, as the result of which the papillæ and subpapillary stratum become infiltrated with fluid or leucocytes, or both, the leucocytes being gathered especially about the blood-vessels. There may be small hæmorrhages, and the acute phase of the inflammation is followed by an increased production of epithelium and an exfoliation of the superficial layers. These lesions of the skin may be, excepting the hæmorrhages, very slightly marked after death.

The Excitants of Scarlatina.—That the disease is due to some form of micro-organism there can be no doubt. The exact nature of this organism is not yet known. The acute nephritis and the marks of degeneration and focal necrosis so often present appear to be due to some poison formed in the body during the disease.

Mallory⁴ has described bodies in and between the epithelial cells of the epidermis and free in the superficial lymph-vessels and spaces of the corium in scarlet fever which he believes to be protozoa and to bear an etiological relationship to the disease. Most of these bodies are from 2 to 7 μ in diameter and stain with methylene blue. A series of forms are found, including rosettes, which are said to resemble the series in the asexual development of the malarial parasite. Further studies will be required to establish the protozoan nature as well as the significance of these structures.⁵

¹ *Calkins, Protozoology*, 1909, 308.

² Consult for general bibliography *Freeman*, article on vaccination in "Cyclopedia of the Diseases of Children," vol. v., suppl., p. 263; or *Moore*, in "Twentieth Century Practice," vol. xiii.

³ For a special study of kidney lesions in scarlatina see *Chapman*, *Jour. of Path.*, vol. xi., p. 276, 1906, bibl.

⁴ *Mallory, Jour. of Med. Res.*, vol. x., 1904, p. 483. On the demonstration of the alleged parasites of scarlatina in blister fluids see *Duval*, *Univ. Penn. Med. Bull.*, Nov., 1904; also *Williams and Lowden Studies from the Research Lab. of the N. Y. City Health Dept.*, iii., 42, 1907.

⁵ Consult for observations not confirming the conclusion of Mallory, *Field, Jour. Exp. Med.* vii., 1905.

One of the most marked features of the disease is the predisposition which it entails to the incursions of pathogenic germs other than that which we believe to be its excitant. Thus an infectious croupous inflammation of the mouth, tonsils, pharynx, larynx, and trachea, due to a streptococcus (see p. 212), is a frequent complication. True diphtheria due to the Löffler bacillus is also prone to establish itself upon the vulnerable inflamed mucous membranes. So also the frequently associated pneumonia, the inflammatory hyperplasia and suppuration of the lymph-nodes, suppurations in various parts of the body, the endocarditis and pericarditis which are not uncommon, may all be due to a secondary infection with the pyogenic cocci.

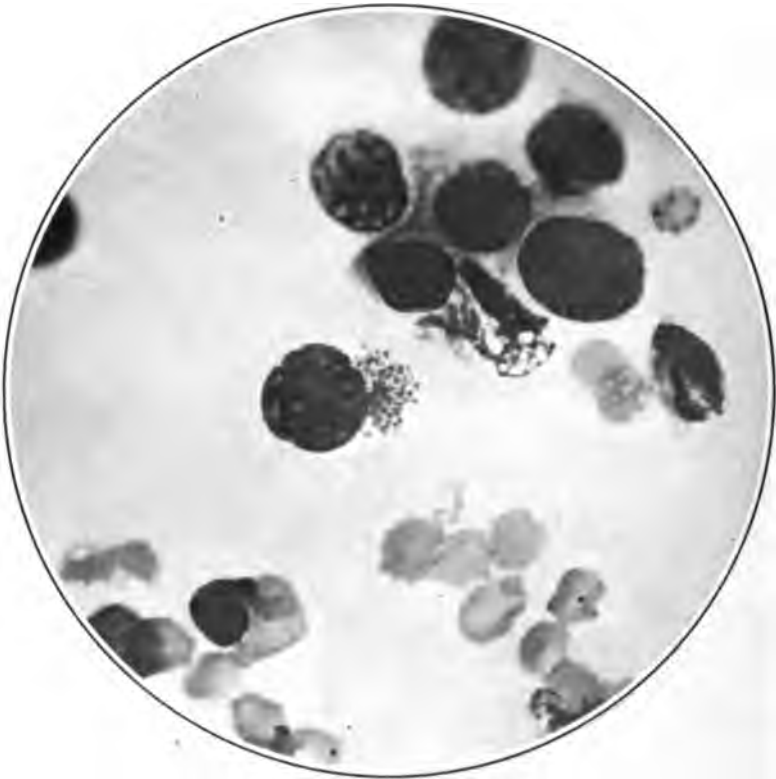


FIG. 172.—TRACHOMA BODIES.

Conjunctiva. From a preparation of Dr. Noguchi. The bodies are in a small cluster near the nucleus of the cell near the centre of the cut. The outline of the cell-body has been lost in the reproduction of the photograph.

TRACHOMA.

The inflammation of the conjunctiva, known as trachoma, has long been suspected to be of infective nature. But it was not until 1907 that Halberstaedter and v. Prowazek,¹ and Greff² described the occurrence in

¹ Halberstaedter and v. Prowazek, Deut. Med. Wchnschr., xxxiii., 1285, 1907.

² Greff, *Ibid*, 914, 1907.

the epithelial cells of the conjunctiva in the early stages of the disease of extremely minute, rounded or oval bodies, smaller than the smallest cocci, not staining with Gram, but reddish or violet with Giemsa.

These bodies are surrounded by a clear mantle, staining blue with Giemsa, and are often paired. They are called *Trachoma Granules or Bodies*. The trachoma granules are found chiefly in the epithelial cells, often grouped in concentric masses, close to the nucleus (Fig. 172). They sometimes fill and distend the cells (Fig. 173). They vary con-

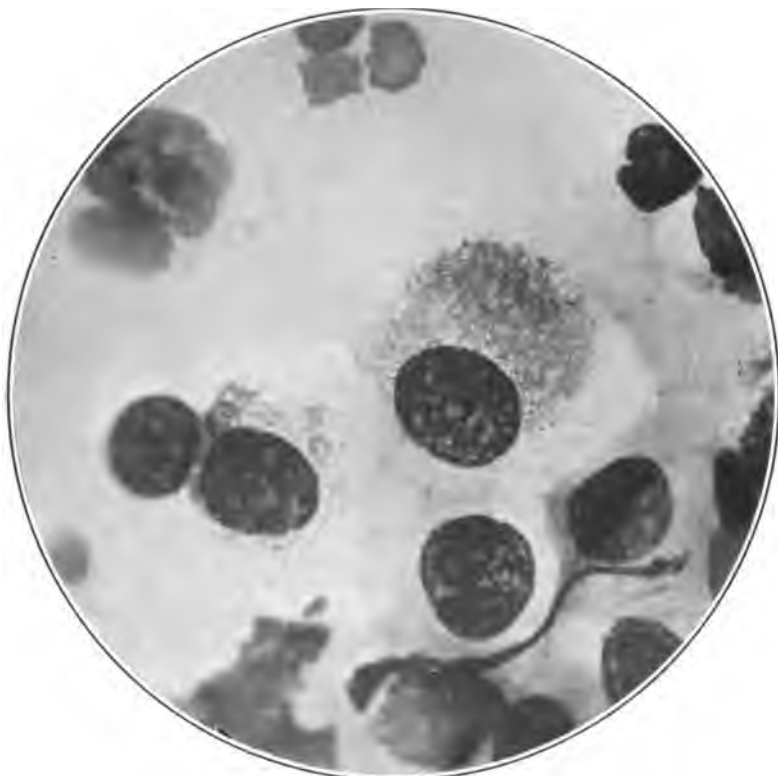

FIG. 173.- TRACHOMA BODIES.

Conjunctiva. From a preparation of Dr. Noguchi. The "bodies" nearly fill the cell near the centre of the cut and partly surround the nucleus.

siderably in size. They increase rapidly within their mantles which presently they replace.

These bodies were called *Chlamydozoa* because of the surrounding mantle. They are not very abundant and may soon disappear. Their significance and nature do not seem at present clear.¹

MEASLES.

A readily communicable infectious disease, the most prominent features of which are an intense hyperæmia with inflammation of the

¹ For a study and bibl. see *Noguchi and Cohen*, Proc. N. Y. Path. Soc., x., 20, 1910.

skin, associated with catarrhal inflammation of the mucous membrane of the air passages. The inflammation of the skin is anatomically of the same general type as that in scarlatina.¹ Albuminous degeneration of the kidney or acute exudative nephritis may occur. Focal necrosis in the liver and kidneys have been described by Freeman.²

The more common secondary lesions are broncho-pneumonia, pseudo-membranous inflammation of the pharynx and larynx, suppurative inflammation in various parts of the body, and diphtheria. These complications, as in scarlatina, are doubtless, in part at least, due to secondary infection with other germs than those causing the disease itself.

The excitant of measles is not known.

Canon and Pielicke in 1892³ recorded the discovery in the blood in fourteen cases of measles of very small bacilli, about as long as the radius of a red blood cell, but varying considerably in size. These bacilli were sometimes abundant, sometimes scanty in the blood, lying singly or in heaps. Meagre cultures were obtained in three cases in beef tea. They did not seem to grow on the ordinary solid media. Bacilli similar in form were found in the exudate from inflamed mucous membranes in measles. The observations of these writers are interesting and suggestive, but until they shall have been confirmed by others and greatly extended nothing can be assumed as established regarding the etiological significance of the germs.

Inoculation of Measles.—Although readily conveyed in natural ways from one human being to another predisposed individual, the attempts at experimental inoculation of the infectious agent in measles in man have not led to very definite conclusions. Hektoen succeeded in two cases in inducing typical measles by the injection of material derived from the blood at an early stage of the disease.⁴

MALARIA.

THE LESIONS OF MALARIA.

The characteristic lesions of *acute* malarial infection are found in the blood, the liver, spleen, kidneys, and brain.

The alterations in the *blood* are chiefly confined to the diminution in number of the red corpuscles, due to their destruction by the parasites developing in them and to a reduction in the hæmoglobin content of those which do not contain parasites. These changes are apparently due to some toxic agent, for which there is additional evidence in the polychromatophilia and granular degeneration of the body of the red cell so often present in severe malarial infections. The evidence of some poison acting on the protoplasm of the red cells is found, not only in those cells in which the organism is developing, but more abundantly in those cells in which no plasmodia are present.

The leucocytes show slight qualitative changes, there being usually present a relative increase in the large mononuclear cells. Pigmented leucocytes are often seen, and in very severe infections large macrophages

¹ For a study of epithelial cell changes in measles, see *Ewing, Jour. Inf. Dis.*, vi., 1, 1909.

² *Freeman, Arch. of Pediatrics*, February, 1900.

³ *Berliner klin. Wochenschr.*, Apr. 18th, 1892.

⁴ For a *résumé* of earlier attempts at inoculation of measles and his own experiments see *Hektoen, Jour. Inf. Dis.*, vol. ii., p. 238, 1905.

loaded with pigment may be seen in the circulating blood. In severe cases the pigment, which is derived from the hæmoglobin of the blood corpuscles and forms the granules in the body of the parasite, may be found free in the general circulation, but is usually soon removed by the leucocytes and the phagocytic cells of the liver, spleen, and bone marrow. The *brain* in cases of pernicious æstivo-autumnal fever is often much congested, and the smaller capillaries may be filled with enormous numbers of the plasmodia in various phases of development; there may also be small punctate hæmorrhages in the white matter. The deposition of the malarial pigment in the cortex may give to the latter a dark reddish brown color, or it may be almost black. The *spinal cord* shows similar changes.

The *liver* in acute cases may show focal necroses resembling those present in other infectious diseases. The endothelium of the liver capillaries may contain much pigment (see Fig. 473, p. 721), while the lumina of the capillaries may be stuffed with plasmodia in various stages of development. The *kidneys* may show albuminous degeneration, and while the intertubular capillaries may be filled with pigmented leucocytes there is not, as a rule, a great accumulation of plasmodia in the vessels. A moderate diffuse nephritis is occasionally seen. The capillaries of the mucosa of the *stomach* and the *intestines* may be filled with parasites in cases with choleraic symptoms, and there may be a considerable amount of necrosis in the epithelium of the mucosa of the intestines. The *bone marrow* usually contains large numbers of the plasmodia, chiefly segmenting forms. A good deal of pigmentation is present, and an active phagocytosis is carried on, mainly by the giant-cell macrophages present in the marrow. Crescentic organisms may be present in the marrow even if these have not been present in the blood during life.

The *spleen* is increased in size, the pulp is softened and very dark, the Malpighian bodies are not well marked. Microscopically, the organ is greatly congested; many of the red cells are invaded by the plasmodia which are often in the segmenting stage. There is a very active phagocytosis by the macrophages present, often so extensive as to include the red cells with their contained parasites.

In the *chronic cases* the patient may become extremely anæmic with nucleated red cells in the blood and a great reduction in the number of erythroblasts. The spleen is greatly enlarged, the capsule thickened and adherent to the surrounding tissues. The cut section of the organ is of a dark brown or slaty black from the deposit of pigment. The Malpighian bodies are well marked. The fibrous-tissue trabeculæ are thickened, as is the reticulum of the pulp; the pulp cells are pigmented. The liver shows a marked pigmentation, especially in the endothelium of the capillaries and in the so-called perivascular cells described by Kupffer, while occasionally there is a moderate amount of new connective tissue, which, however, does not follow, as a rule, the anatomical distribution of the connective tissue in the usual atrophic cirrhosis. In chronic poisoning the kidneys may show a chronic diffuse nephritis. The

bone marrow may remain fairly normal except for the deposition of pigment, or there may be seen a marked hyperplasia with replacement of the normal fatty marrow of the shafts of the long bones with red marrow containing normoblasts or even megaloblasts if the disease has been long-continued and severe.

THE EXCITANT OF MALARIA.

The excitant of the disease long known clinically as malaria is a small animal parasite, the *Plasmodium malariae*, which enters the red corpuscles of the blood and in the course of its development destroys them. The destruction of each cell is coincident with the maturation of its contained parasite, which segments into a variable number of spores, or, more properly, merozoites, a phenomenon which is also coincident with the clinical appearance of the chill and its accompanying rise of temperature.

These parasites of the red cell are protozoa belonging to a special sub-group, the *hæmosporidia*. For purposes of description these hæmosporidia of human malaria may be classified into three species or types, each of which incites a different clinical form of disease and each of which also differs from the other types in its morphology. These types are the tertian, the quartan, and the æstivo-autumnal parasites.

Tertian and Quartan Types.—If the blood of a patient suffering from tertian fever be examined shortly after a chill, a number of the red cells will be found to contain small, highly refractile, actively amœboid bodies which are the early forms of the plasmodia or merozoites. The latter often take the form of small rings surrounding a central clear space. This is especially well seen in stained specimens (Plate I., Figs. 1-4). If the blood be again examined some hours later, these very small forms have grown to a considerable extent, and small brown or black granules will be noted in the body of the plasmodium. This pigment has a very rapid motion inside the body of the parasite. If the blood be examined at intervals for forty-eight hours the organism may be seen to have grown so large as to occupy nearly the whole of the red cell (Plate I., Figs. 5-12), which becomes somewhat swollen and pale the latter effect being due to the destruction of the hæmoglobin of the cell by the parasite, which thus produces the pigment granules of melanin with which it is filled. At the end of forty-eight hours the pigment has collected in the centre of the organism, which has ceased its active amœboid motion. Now small pale spots, which are the nuclei of the segmenting mature form, become easily visible (Plate I., Fig. 16), and finally the red cell bursts, and the small merozoites, each containing a nucleus, are set free to enter other red cells and to repeat the cycle in another period of forty-eight hours. A certain portion of the free merozoites are destroyed by the phagocytic leucocytes and other cells. The free pigment left after the segmentation of the mature forms is also collected by these phagocytes. Thus after severe and prolonged attacks of malaria the leucocytes are frequently filled with pigment.

The *quartan* organism goes through a cycle similar to that of the tertian, except that the time required is seventy-two instead of forty-eight hours. There are also a few minor differences in the morphological appearance of the two organisms. Thus the small early amœboid forms of the plasmodium are much more active in their movements in the tertian than in the quartan. The pigment in the tertian is very fine; in the quartan it is often in small blocks or rods and is much coarser (Plate I., Figs. 22-25). The mass of segmenting merozoites in the tertian organism is quite irregular in shape and contains from fifteen to twenty individuals, while that of the quartan is a regular rosette in shape and the merozoites average from six to twelve (Plate I., Figs. 26-28).

Æstivo-autumnal Type.—The parasite of the æstivo-autumnal fever develops in the blood in much the same way as the other forms, with the exception that the amœboid rings are, as a rule, smaller. The signet-ring shape is more marked, and the pigment is less abundant (Plate I., Figs. 31-34). Another peculiarity of this organism is that the development of the larger amœboid forms takes place chiefly in the bone-marrow and the spleen, while that of the tertian and quartan is to be seen in the blood. Thus as soon as the plasmodium of the æstivo-autumnal type has grown sufficiently to occupy about one-fourth of the red cell, it disappears from the peripheral blood and can be found developing in the blood obtained by puncture of the spleen, or, in fatal cases, from the bone-marrow (Plate I., Figs. 35, 36). In such preparations the mature plasmodia may be found and the segmenting process followed (Plate I., Figs. 37-39). The organism is not as large as the tertian, as the segmenting form usually occupies only about one-half of the somewhat shrunken red corpuscle. The number of merozoites formed is about fifteen. The time of the developmental cycle in the blood is forty-eight hours.

In the blood of a patient infected with the æstivo-autumnal parasite, there are always found within a few days after the beginning of the disease a moderate number of crescent-shaped bodies with pigmented centres and the remnant of a red cell about them (Plate I., Figs. 43, 44). They are devoid of amœboid motion. The exact nature of these crescentic bodies was quite unknown until very recently, when it was discovered that they are cells with sexual capabilities, whose function seems to be the prolongation of the species in a cycle outside of the human body. It had long been known that certain of the large mature amœboid forms of the tertian and quartan organisms and the crescents of the æstivo-autumnal species did not undergo segmentation into merozoites, but remained circulating in the blood. When, however, the blood containing these forms was examined in a fresh condition on a slide, and especially if the blood before being covered was allowed to remain in a moist chamber for a few minutes, changes could be seen to take place which had not been observed in perfectly fresh preparations. Certain of the mature organisms set free long, actively motile flagella which entered other mature forms. In stained preparations it could be

seen that each flagellum contained some of the nuclear chromatin of the organism from which it arose, and that this flagellar chromatin united with the chromatin of the body which the flagellum entered. The crescentic forms under suitable conditions go through the same process, the male crescent giving off flagella, one of which in turn fertilizes another crescent of slightly different morphology.

Evidently this is a sexual process, and its occurrence only in blood which has been drawn from the body suggested the probability that under ordinary circumstances it takes place outside the human host. The truth of this conjecture has recently been established, and the process of fertilization and maturation of the fertilized organism has been found to occur in the stomach of a particular genus of mosquito, the *Anopheles*. No other type of mosquito is capable, according to our present knowledge, of acting as host to the plasmodium of human malaria, though the organism which induces malaria in birds can develop in a mosquito of the genus *Culex*. Whether the plasmodium can carry out its sexual cycle under other conditions than in the stomach of the *Anopheles* is as yet unknown. If an *Anopheles* bites a patient with malaria, the blood with its contained organisms is drawn into the stomach of the mosquito, the flagella are given off from the gametes and enter other mature forms and fertilize them. The fertilized organism goes through a complicated development, and the resulting sporozoite finds its way in the course of a few weeks to the salivary glands of the mosquito host, to be injected into the blood of the next person bitten. The sporozoites enter the red cells, becoming the small amœboid forms or merozoites already described.¹

The details of the process of fertilization and the formation of the sexual cells which are capable of carrying on the cycle in the mosquito have been best observed in the æstivo-autumnal fevers, so that the stages will be here described in connection with the development of the crescent gametes. These crescents are formed chiefly in the bone marrow from the small ovoid, intracellular bodies, which can early in their development be distinguished from the ordinary amœboid forms by their more abundant coarse pigment and oval outline.

The adult crescents are quite constantly present in well-developed cases, and are often found in the blood after treatment with quinine has caused the disappearance of the amœboid bodies, the power of resisting the action of drugs being much more marked in the crescents than in any other form of the plasmodium. Two types may be distinguished, both of which begin as small amœboid forms and gradually mature into oval or crescentic organisms. One of these, the microgametocytes, or the cells producing the male elements, develops and gives off the flagellum (microgametes); the other, the macrogametes (female elements), neither form nor give off flagella. According to Marchiafava and Big-nami² the microgametocytes are distinguished from the macrogametes by the fact that in the former (the male form) the pigment is gathered

¹ For details of the process see *Schaudinn*, *Arbeiten aus dem Kais. Gesundheitsamte*, 1902, p. 169.

² Other observers claim that the pigment in the male forms is scattered throughout the plasmodium.

1. of
2. of
3. of
4. of

5. of
6. of
7. of
8. of
9. of
10. of
11. of
12. of
13. of
14. of
15. of
16. of
17. of
18. of
19. of
20. of
21. of
22. of
23. of
24. of
25. of
26. of
27. of
28. of
29. of
30. of
31. of
32. of
33. of
34. of
35. of
36. of
37. of
38. of
39. of
40. of
41. of
42. of
43. of
44. of
45. of
46. of
47. of
48. of
49. of
50. of
51. of
52. of
53. of
54. of
55. of
56. of
57. of
58. of
59. of
60. of
61. of
62. of
63. of
64. of
65. of
66. of
67. of
68. of
69. of
70. of
71. of
72. of
73. of
74. of
75. of
76. of
77. of
78. of
79. of
80. of
81. of
82. of
83. of
84. of
85. of
86. of
87. of
88. of
89. of
90. of
91. of
92. of
93. of
94. of
95. of
96. of
97. of
98. of
99. of
100. of

DESCRIPTION OF PLATE I.

Hæmatozoa of Tertian Malaria.


- Figs. 1 to 4.... Small ring-shaped merozoites of tertian malaria; 2 and 3, multiple invasion of a single red cell.
“ 5 to 12.... Amœboid forms of gradually increasing size.
FIG. 13..... Large amœboid form in which the pigment is beginning to collect as a preliminary to segmentation.
“ 14..... Pigment still more clumped, and the pale areas representing nuclei begin to be marked.
“ 15..... Segmenting form with an irregular mass of merozoites.
“ 16..... More symmetrical type of segmentation with central block of pigment.
“ 17..... Free merozoites after leaving the red cell.
“ 18..... Gamete.
“ 19..... Microgametocyte with flagella or microgametes.

Hæmatozoa of Quartan Malaria.

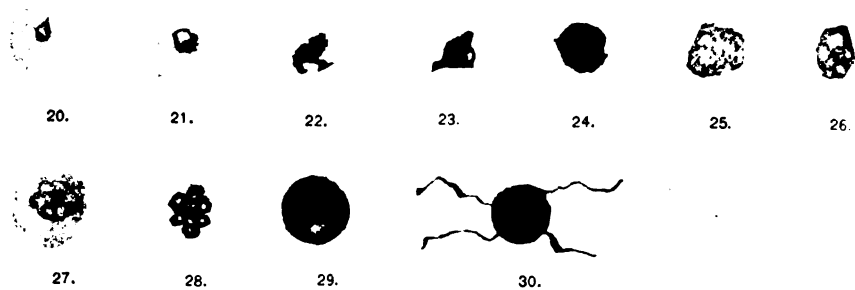
- Figs. 20 and 21... Small ring form of merozoites.
“ 22 to 25.... Amœboid forms with coarse pigment.
“ 26 to 28.... Segmenting forms.
“ 29..... Gamete.
“ 30..... Microgametocyte with microgametes in the process of formation.

Hæmatozoa of Æstivo-Autumnal Malaria.

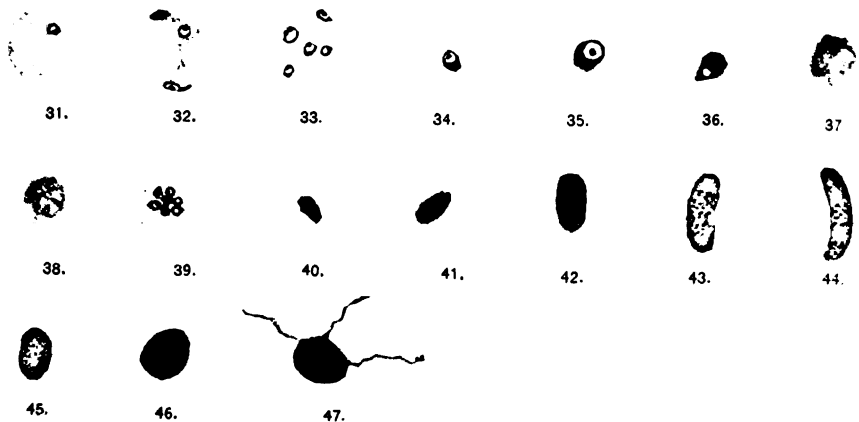
- Figs. 31 to 34... Small ring forms, some of them on the surface of the corpuscle; 32 and 33, multiple invasion of the red cell.
“ 35 and 36... Amœboid forms found in the peripheral circulation.
“ 37 to 39... Large amœboid forms and segmenting parasites found only very rarely in the peripheral circulation, but abundantly in the spleen and bone marrow.
“ 40 to 42... Young crescentic forms not found in the peripheral circulation, but chiefly in the bone marrow.
“ 43 and 44... Adult crescents or gametes, found abundantly in the peripheral blood.
“ 45 and 46... Microgametocytes becoming oval and preparing to give off microgametes.
FIG. 47..... Microgametocyte giving off microgametes.




Hæmatozoa of Tertian Malaria.



Hæmatozoa of Quartan Malaria.



Hæmatozoa of Aestivo-Autumnal Malaria.



in a fairly compact mass in the middle of the crescent, the chromatin is more abundant, and the entire body stains faintly; while in the female form, the pigment surrounds the rather scanty nuclear chromatin in a ring form, the cell body stains deeply, and no flagella are given off. The crescents in the fresh blood show no amoeboid motion, and even the pigment is motionless. They are either crescentic in form with the pigment collected at the centre, or they may be spindle-shaped with somewhat scattered pigment, or finally short, thick ovoid bodies with pigment irregularly scattered or more frequently gathered into a ring about the nucleus. They are all contained in red blood cells (endoglobular), the faint remnant of the red cell often being seen as a delicate line stretching between the two horns of the crescent.

The formation of flagella (microgametes) does not take place in the circulating blood; it begins only after the blood has remained on a slide for a few minutes or has remained for some time in the stomach of the mosquito. These flagella, usually about four in number, bud out from the periphery of one of the microgametocytes, which has assumed a spherical instead of a crescent shape, and grow to a length of three to five times the diameter of the red cell. They are either pointed or bulbous at their extremities, or they present swellings at irregular intervals. Their motion in warm-stage preparation is rather rapid, and they finally become detached and move about free in the serum (Plate I., Figs. 45, 46, 47). The pigment during this process usually remains at the centre of the spherical microgametocyte and is actively motile, but in preparations stained to show the nuclear chromatin the latter may be seen to penetrate the flagella in the form of long thin rods which remain after the flagella become detached. The shell of the red cell in which the crescent has developed can rarely be seen in fresh preparations of the flagellate forms. These flagella penetrate the body of one of the macrogametes present on the slide and fertilize it.

This process, which we have followed in an artificial preparation, seems necessary for the continuance of the race, and is normally carried out in the middle intestine of the mosquito of the genus *Anopheles*. The actual entry of the microgamete (spermatozoon) into the macrogamete has been observed by MacCallum¹ and others in fresh-blood preparations.

If a patient in whose blood mature crescents are present is bitten by the mosquito, the parasites develop in the intestine of the insect, and at the end of two days the fertilized forms may be found adherent to the wall of the intestine as small pigmented oval bodies quite similar to the early forms of the crescents developing in the human bone marrow. Two days later the parasites or oöcysts are much larger and have a distinct capsule, while by the sixth day they may measure from 60 to 80 μ in diameter. They contain numerous small particles which are nuclei due to the frequent division of the original nuclear material, and the capsule is much thicker. At the end of a week the parasite contains a

¹ *MacCallum*, "On the Hematozoan Infections of Birds," *Jour. of Exp. Med.*, vol. iii., 1898, p. 117

large number of slender thread-like rods with pointed extremities, each one of these rods having nuclear chromatin. The parasite or oöcyst projects through the wall of the intestine into the cœlom cavity of the mosquito host, and when it ruptures these minute rods or sporozoites are carried by the lymph currents to the salivary glands, from which they may be injected with the saliva when the female *Anopheles* bites another subject.

The sporozoites, after entering the circulation of man, attack the red cells, and become the small amœboid forms described above. In two or three weeks the formation of the gametes takes place, and the crescent forms appear in the blood.

That the infection of man in this way is possible has been abundantly proven by allowing mosquitoes infected with æstivo-autumnal organisms to bite healthy persons, who, after a period of incubation of about ten days, are seized with an æstivo-autumnal type of fever, and the characteristic organisms, though not present previously, are now to be found in the blood. The mature forms of gametes of the tertian and quartan fevers undergo a course of development very similar to that of the æstivo-autumnal fever, and are derived from the blood of the infected patient by the female of the same genus of mosquito, the *Anopheles* (Plate I., Figs. 19 and 30). The sporozoites find their way to the salivary glands of the mosquito and enter the blood of the person infected while the *Anopheles* is biting. These sporozoites then enter the red cells as the small amœboid forms and carry on the sexual cycle in the blood until either the tissues of the body finally overcome the parasite, or treatment with quinine destroys the merozoites by means of its toxic action on these immature forms.¹

Methods of Examination of the Blood in Malaria.

There are two methods of examining the blood for plasmodia, in fresh preparations and in stained smears. Both require considerable training, as the artefacts produced by imperfect technique have often been mistaken for organisms.

THE EXAMINATION OF FRESH BLOOD.—To examine the fresh blood, a puncture is made in the pulp of the finger and a perfectly clean cover-glass just touched to the top of the drop of blood which exudes from the puncture. The cover is then dropped without pressure on a clean slide. The diameter of the drop on the cover-glass should never exceed 2 mm., because if more be taken the corpuscles cannot spread out in a perfectly thin layer, but will overlap each other and the preparation will be useless. The search for the organism should be made with a one-twelfth oil-immersion lens and a moderate illumination. The organisms are best recognized by the actively motile pigment in the clear, highly refractile cell body.

THE EXAMINATION OF BLOOD AFTER FIXATION.—If the examination cannot be made at once, stained preparations may be made. The smear should be made on a slide or large cover-glass. It is best fixed in strong methyl alcohol for three minutes.

¹ A general bibliography of malaria to 1895 is contained in the excellent monograph of *Thayer and Hewitson*, "The Malarial Fevers of Baltimore," Johns Hopkins Hosp. Rep., vol. v., 1895. The more recent literature, especially that relating to the development of the organisms in the mosquito, is in *Marchiafava and Bignami*, article "Malaria" in "Twentieth Century Practice," New York, 1900, and also *Luke*, "Neuere Sporozoenforschung," Centralbl. f. Bakt., Bd. xxvii., pp. 367 and 436, and Bd. xxviii., p. 384, 1900. For a study of structure and biology of *Anopheles* see *Nuttall and Shipley*, Jour. of Hyg., vol. I., p. 4, 1901. For practical directions for the study of mosquitoes, see *Berkeley*, "Laboratory Work with Mosquitoes," 1902.

The organisms are most satisfactorily demonstrated by stains which color the chromatin as well as the protoplasm. For this purpose a very satisfactory stain is that devised by Giemsa.¹ The staining solution contains azure eosin and azure II dissolved in glycerin and methyl alcohol. It is difficult to prepare and had best be bought from Grüber. It must be kept in tightly stoppered bottles.

In order to stain a fixed blood smear, a dilution of the stock solution is made by adding 1 drop of the dye to 1 c.c. of distilled water. If the smear is on a cover-glass, 10 c.c. of the dilution should be placed in a shallow dish and the cover floated, blood side down, on the mixture. For staining slides a Coplin jar is convenient. As this holds about 50 c.c., 50 drops of the concentrated stain should be added slowly to the water with constant stirring with a glass rod. The slides are left for an hour, then washed with a strong stream of water, dried in the air without heat, and mounted and examined. If intended for permanent preservation they should be embedded in a neutral gum dammar dissolved in xylol. Slides more than a few days old do not stain well. After a year it is necessary to use a more dilute stain and afterward decolorize with distilled water or even methyl alcohol, as the blue component overstains all the cells.

By adding an equal volume of pure methyl alcohol to the stock solution of the Giemsa stain, it is possible not only to shorten the time, but also to avoid separate fixation of blood smears.²

The blood smear is placed in a Petri dish and 10 to 15 drops of this new mixture are placed on the slide and allowed to act for half a minute. About 10 to 15 c.c. of distilled water are poured into the Petri dish and the whole is agitated until the stain is thoroughly diffused through the entire fluid. The slide remains in this mixture for five minutes. A longer period increases the intensity of the stain.

A simpler method has recently been published,³ which is better adapted for clinical work. The smear is fixed for two minutes or more in methyl alcohol, then stained for ten seconds with a 1 : 1,000 aqueous eosin solution, the latter allowed to run off the slide, and the smear again covered with a few drops of a 1/4-per-cent. solution of methylene azure I. In about from fifteen to thirty seconds the staining is complete. The slide should be washed in distilled water, dried, and examined directly with an oil-immersion lens, no cover-glass being necessary.

WHOOPING-COUGH. (*Pertussis*.)

Whooping-cough is a readily communicable, infectious disease usually associated with catarrhal inflammation of the upper respiratory passages. It may be complicated by bronchitis or pneumonia. Hyperplasia of the lymph-nodes of the laryngeal and bronchial districts may occur. Immunity is usually secured by an attack.⁴

It has recently been found possible to transfer the disease to young dogs, a fact which will undoubtedly lead to important experimental results in the near future. Several observers have isolated bacilli closely resembling the influenza bacillus in form and culture, from the sputum of patients with the disease. Of these organisms that described by Bordet and Gengou⁵ seems most probably to be the specific agent. This organism is a small, ovoid, short bacillus showing irregular staining. It is somewhat larger than the influenza bacillus and is more regularly ovoid in shape. It stains with some difficulty, requiring the use of dilute carbol-fuchsin or other strong stains to color it satisfactorily.

¹ Giemsa, *Centralbl. f. Bakt., I Abt. Orig.*, 1904, xxxviii., 308.

² Giemsa, *München. med. Wehnschr.*, 1910, lvii., 2476.

³ Wood, *Medical News*, vol. lxxxiii., p. 248, 1903.

⁴ For a *résumé* of studies on the excitant of whooping-cough see Davis, *Jour. Inf. Dis.*, vol. iii., p. 1, 1906. For studies on agglutination with bacilli from this disease see Wollstein, *Jour. Exp. Med.*, vol. vii., p. 335, 1905.

⁵ Bordet and Gengou, *Ann. de l'Inst. Pasteur*, 1906, xx., 731.

The poles often stain more deeply than the centres. The bacillus is negative to Gram. The organism is grown only with difficulty and upon a special medium of glycerinated extract of potato to which has been added an equal volume of sterile defibrinated rabbit or human blood. The organism is strictly aerobic and in ascitic broth may remain alive for some months.¹ Bordet and Gengou report that a specific complement fixation can be obtained in the serum of patients suffering from the disease.

BERI-BERI.

Beri-beri is a disease of warm climates, believed by some observers to be infectious in character, by others to be due to unsuitable diet. The lesions are often not well defined. There are in some cases subcutaneous œdema and dropsy. There is often degeneration of the peripheral nerves and of the heart and voluntary muscle. The bacterial studies which have been made upon beri-beri have not led to definite results.²

ACUTE RHEUMATISM.

While the excitant of acute rheumatism is unknown, there is much reason to believe that some phases of it at least should be classed among the infectious diseases. There are no characteristic lesions; but various joints are frequently the seat of slight exudative inflammation, serous or fibrinous in character. Albuminous degeneration of the visceral cells with hyperplasia of the spleen has been noted. The disease is not infrequently complicated by endocarditis or pericarditis, by exudative inflammation of the lungs or pleura. Various micro-organisms have been found in the body in acute rheumatism; of these the pyogenic cocci have been most frequently isolated, but these are probably to be regarded only as excitants of the suppurative or other complications. It is possible that more than one form of infection is embraced under the designation rheumatism.³

INFECTIOUS DISEASES OF UNKNOWN ORIGIN.

PROTOZOA.—Notwithstanding the great increase in our knowledge of the infectious diseases made possible within the past few years by the new methods of cultivation of micro-organisms and by animal experimentation, there are still several diseases obviously of this class whose inciting factors are wholly unknown to us. We are now beginning to realize that we must not confine our search in this class of diseases to the bacteria alone; but that among the protozoa may be found most important infective agents. In this latter group of organisms the culture methods applicable to the bacteria do not furnish the necessary data for the establishment of etiological relationships. While the pathogenic significance of the malarial protozoan has been determined without cultures, and has become probable on morphological grounds in several other diseases, the desirability of artificial culture methods in the study of protozoa is daily becoming clearer. But it is well to remember that many protozoa pass through complex life cycles so that simple cultures cannot be expected to yield as illuminating results as do cultures of the more lowly organized bacteria and yeasts.

ULTRA-MICROSCOPIC MICRO-ORGANISMS.—In the search for the inciting agents of infectious diseases which have as yet baffled investigation, it should be borne in mind

¹ *Wollstein*, Jour. Exper. Med., 1909, xi., 41.

² For bibliography of beri-beri see *Sodre*, "Twentieth Cent. Practice," vol. xiii.

³ For summary and studies of etiology of acute rheumatism see *Cole*, Jour. Inf. Dis., vol. i., p. 714; 1904; *Beattie*, Jour. Med. Res., vol. xiv., p. 399, 1906; *Frissell*, Med. Record, vol. lxix., p. 737, 1906; *Meakins*, Med. and Surg. Repts. Presbyterian Hospital, N. Y., viii., 1905.

that it is quite possible that bacterial and other micro-organisms may exist which are ultra-microscopic; that is, so small as to be invisible with such microscopic resources as we at present possess. In one instance, the infectious peripneumonia of cattle, Nocard and Roux by a special technique¹ have been able to isolate an organism so small that its morphological characters could not be learned even with the highest available magnification. Experiments with the filtration of infectious material, especially from certain communicable diseases of animals, through porcelain filters whose pores are so fine as to retain ordinary bacteria, have shown that the infective agent may pass these filters and, though revealing no morphological elements, is still virulent. Among the more important of the ultramicroscopic infective agents which have been found to pass the pores of porcelain filters are those inciting contagious pleuro-pneumonia of cattle, anterior poliomyelitis, yellow fever; foot-and-mouth disease and rinderpest of cattle. The possibility of the existence of ultra-microscopic organisms must then be held in mind in our summaries of infectious diseases whose inciting factors, though persistently sought, are still unknown.²

THE INFECTIOUS DISEASES OF ANIMALS.

The study of comparative pathology is of great and increasing importance, and already much light has been thrown on the nature of human diseases by the study of the diseases of the lower animals.

While this is true of pathology in general, it is of especial significance in the study of the infectious diseases of the lower animals, not only as they occur spontaneously, but also in fields of experimental research.

The scope of this book does not permit of more than an occasional reference to animal diseases, but the reader may consult: *Moore*, "The Pathology of the Infectious Diseases of Animals," 1906; *Nocard and Leclainche*, "Les Maladies Microbiennes des Animaux," Paris, 1898, and *Frieberger and Frohner*, "Lehrbuch der speciellen Pathologie und Therapie der Hausthiere," 1896; also *Kill*, "Text-book of Comparative General Pathology," Eng. Trans. by *Smith and Cadbury*, 1906.

Consult also the files of *Lubarsch* and *Ostertag*, "Ergebnisse der allgemeinen Aetiologie der Menschen- und Thierkrankheiten."

BIBLIOGRAPHY OF THE INFECTIOUS DISEASES.

For a fuller treatment of the themes considered in this chapter the reader may consult among the larger works:

Kolle and Wassermann, "Handbuch der Mikroorganismen," 1902-06.

Kolle and Hetsch, "Experimentelle Bakteriologie u. d. Infectioskrankheiten," 1906. Gives excellent summaries.

Among the smaller works may be mentioned:

Hiss and Zinsser, "Text-book of Bacteriology," 1910. This admirable work presents a concise but comprehensive epitome of modern bacteriology, especially in those aspects which are of practical value to students and practitioners of medicine.

Park and Williams, "Pathogenic Bacteria and Protozoa," 1910. Presents important hygienic and public-health aspects of the subject.

Muir and Ritchie, "Manual of Bacteriology," American Ed. 1905. This is an excellent epitome.

Abbot, "Principles of Bacteriology." Especially good as a working laboratory manual.

Lubarsch and Ostertag's "Ergebnisse der allg. Aetiologie der Menschen- u. Thierkrankheiten" contains valuable *résumés* and bibliography, issued yearly.

A large part of the record of recent study is widely scattered in monographs and journals.

¹ For a description of colloidum sacs used in the study of ultra-microscopic organisms, agglutination, and for other purposes see *McCrae*, Jour. Exp. Med., vol. v., p. 635, 1900; also *Rosenau*, "Laboratory Technique," Bull. No. 7, Hygienic Labty., U. S. Marine Hosp. Ser., 1902.

² For a most interesting and suggestive summary of recent investigations on infectious diseases of unknown origin see *Hektoen*, Jour. Am. Med. Assn., vol. xli., pp. 405 and 493, 1903; see also *Roux*, "Invisible Microbes," Bull. de l'Inst. Pasteur, tome i., 1903, pp. 7 and 49, bibl.; see also *Dorsel*, Twentieth Report, Bureau of Animal Industry, p. 139, 1903.

CHAPTER X.

MALFORMATIONS.

General Considerations.

THE classification of malformations is difficult, both because of the complexities of development not yet wholly understood, and because of our ignorance of many subtle phases of nutrition and inheritance in general. We shall here attempt little more than a catalogue of some of the more striking or common developmental defects, with a suggestion of grouping for convenience rather than for scientific accuracy.¹

The individual may be subject to abnormal conditions during embryonic life which lead to changes analogous to those which the body may suffer from injuries after birth. But these various lesions are complicated in the embryo by the fact that it is in a state of active growth and development, so that even slight injuries to the embryo may result in malformations of the most extreme character, especially when the injuries are inflicted in the earlier periods of its life.

Among the abnormal and harmful conditions to which the embryo may be subjected may be mentioned first those which relate to the mother, such as infectious or other diseases, disturbances of nutrition, psychic impressions, etc. To these may be added local interference with development, such as pressure upon the uterus, circulatory and other disturbances of the placenta and membranes, an abnormal accumulation of amniotic fluid, adhesions between the embryo and the membranes of the placenta, as well as various forms of trauma.

On the other hand, there are many abnormalities in development which must be referred back to inherited defects transmitted through the maternal or paternal cells.

While one may catalogue in a general way many of the conditions leading to malformations, the rationale of the process in many instances is still obscure. In recent times much light has been thrown on the subject by a host of experimental studies on the ova of the lower animals by shaking, dissection, and other mechanical interferences. But into this field the scope of this book does not permit us to enter.

Many malformations are so extreme or involve such vital organs that extrauterine life is impossible. Such are some of the malformations of the nervous system or of the circulatory apparatus, occlusions of the

¹ The reader is referred for details to *Thoma*, "Pathology and Pathological Anatomy," Eng. Trans., bibl., or to other special works, such as *Marchand*, "Missbildungen," in *Eulenburg's Real Encyclopädie der gesamten Heilkunde*, Bd. xv., 1897, and *Schwalbe*, "Die Morphologie der Missbildungen des Menschen und der Tiere," 1906 and 1907; *Ballantyne*, *Manual of Antenatal Pathology*, 1902 and 1904.

For résumé and bibl of experimental work see *Bailey and Miller*, "Text-book of Embryology," 1909.

gastro-intestinal canal, etc. Some of the abnormalities of development, on the other hand, while not fatal, predispose to disease. Such are the embryonal displacements of groups of cells which predispose to tumor formation. It is customary to speak of the lesser defects as congenital anomalies. Such are congenital angiomas, nævi, and certain dermoid cysts.

Malformations may involve a single individual or embryo or they may concern two or more, which are variously united.

Malformations Involving Single Individuals.¹

The types of such malformations are various. Thus, there may be a failure to develop a part or organ. This is called *aplasia* or *agenesia*. For example, the upper or lower extremities may be absent (Fig. 174).

When an organ or part is formed, but remains small or undeveloped, we speak of *hypoplasia*. A common example of this is the hypoplasia of the aorta in the status lymphaticus (see p. 439).

Sometimes a part of the body remains at an early developmental stage. Under these conditions, however, the developmental arrest may not involve cessation of growth. Examples of this form of lesion are the various fissures and clefts which occur in the median line or other parts of the body, due to some interference with the closure of the invaginations of the germinal layers which should take place at an early foetal period—the medullary groove, intestinal groove, facial and branchial clefts.

From fissures in the facial region arise such malformations as absence of the whole or parts of the face (Fig. 175), various forms of harelip (Fig. 176), etc. Defects of closure in the cervical and thoracic region lead to many forms of fissures, fistulæ, cysts, etc., of the neck and chest, such as the so-called branchial cysts, branchial fistulæ, auricular appendages, tracheal fistulæ. The lower jaw may be absent (*agnathia*). Under these conditions the mouth may be represented by a small opening and the ears are placed low down and near the median line (*synotia*)



FIG. 174.—*ABRACHIUS*.
The arms are absent.

¹ Many of the developmental defects occurring in a single foetus are considered somewhat more in detail in the part of this work dealing with the special organs, to which the reader is referred.

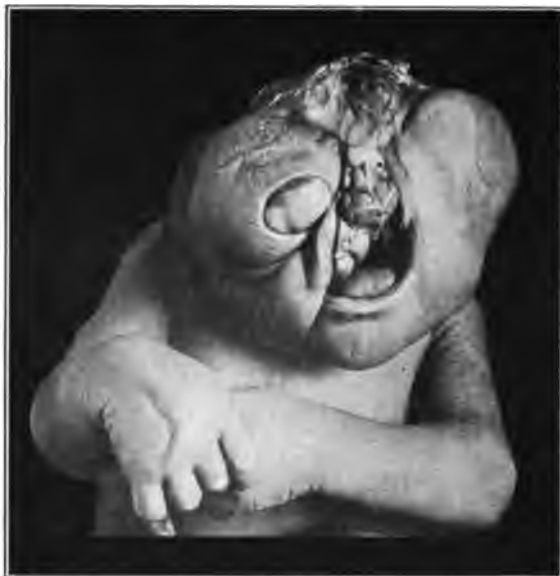

FIG. 175.—FACIAL FISSURE.

Owing to imperfect union in the anterior median line of the body, in the facial region the larger irregular cleft persists. There is also absence of the vault of the skull—cranioschisis.

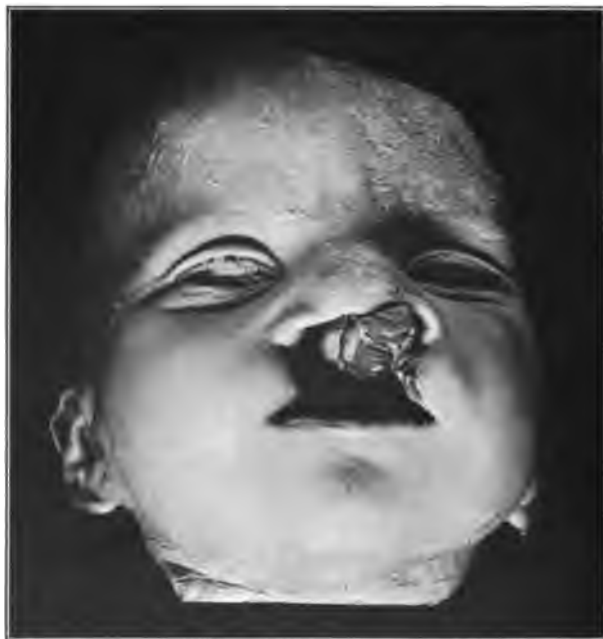

FIG. 176.—DOUBLE HARELIP.

There is bilateral fissure extending into the hard palate.

(Fig. 177). There may be fissure of the sternum, sometimes with protrusion of the thoracic viscera, among others the heart—*ectopia cordis*. Fissure of the diaphragm may occur with that of the sternum and permit displacement of the abdominal and thoracic viscera. The imperfect closure of the *abdominal wall* leads to various forms of lesions. Thus

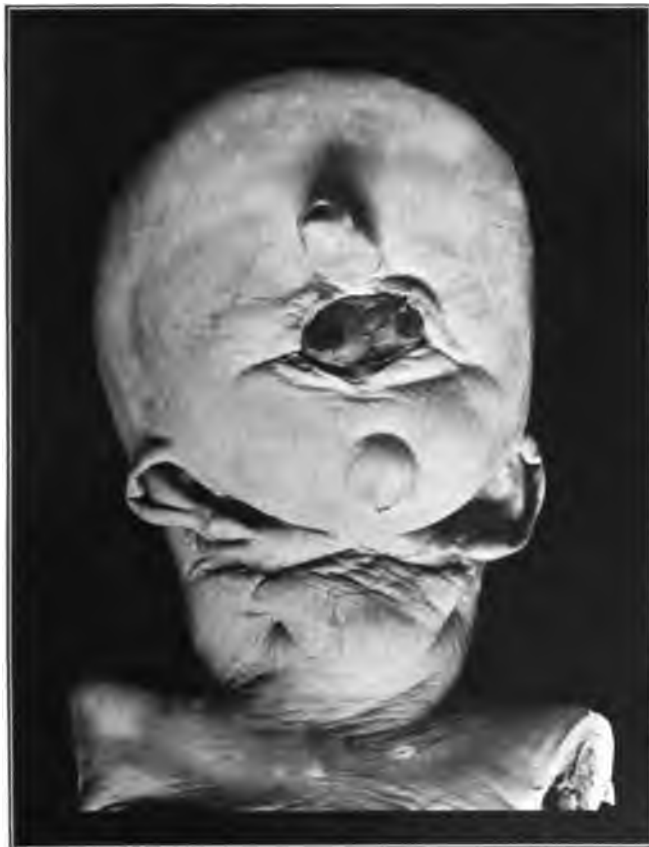

FIG. 177.—SYNOPHTHALMIA, AGNATHIA, AND SYNOTIA.

The rudiments of two eyes are fused and occupy a common orbit. A wart-like process lies above the orbit. The lower jaw is absent—agnathia. The mouth is small. The ears are low and near the middle line between the upper jaw and the neck—synotia.

there may be a patent urachus, the formation of a *Meckel's diverticulum* (see p. 667), umbilical hernia, or, when there is large deficiency of the abdominal wall—complete abdominal fissure—there may be prolapse of the abdominal viscera (Fig. 178). Fissure of the lower portion of the abdominal wall may lead to prolapse of the bladder, and the bladder itself may be fissured so that the interior of the prolapsed organ is

exposed—*inversio vesicæ*. Such fissures in the anterior median line may involve the urethra, leading to *epispadias* or *hypospadias*.

A failure of the walls of the medullary groove in the posterior median line of the body to fuse properly leads to significant malformations of the central nervous system. This failure may be complete—*craniorhachischisis totalis* (Fig. 179). There is a wide irregular groove involving the dorsal aspect of the head and trunk. In this condition, however,



FIG. 178.—ABDOMINAL FISSURE.

Prolapse of the abdominal viscera through imperfect closure of abdominal wall.

the anterior portions of the brain, with the nose and eyes, may be formed, though distorted.

But there may be only a partial failure in the closure of the medullary groove, limited to longer or shorter segments, especially in the cervical and sacral regions. Thus arise various forms of *myelomeningocele*, in which, the pressure from within not being sustained by vertebral arches, often forces the skin and underlying soft parts outward in the form of a pouch or sac (Fig. 180).

A local failure in the closure of the anterior portion of the medullary groove may lead to many malformations of the brain—*cranioschisis*, *hemicephalia*, *acrania*—and to various forms of *meningocele*. Thus in

fissures of the skull there may be prolapse of parts of the brain and its membranes, forming with the enclosing skin pendent pouches of various forms—*encephalomeningocele* (Fig. 181). The vault of the skull may be absent, and on the base there may be small amounts of brain substance, or this may be entirely absent—*anencephalia* (Fig. 182). For the details of these lesions we must refer to the chapter on the Nervous System and to special works on malformations.

In many of the developmental lesions of the brain, the anterior parts, especially the optic vesicles and the olfactory bulbs, are often

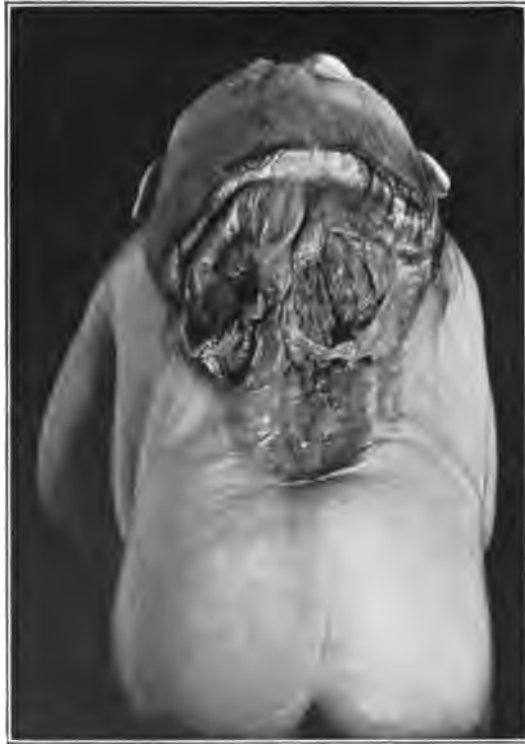

FIG. 179.—CRANIORRHACHISCHISIS.

A failure to close of the medullary groove along a portion of the posterior median line.

but little affected. But we may note here one of the striking malformations which results in the fusing of the eyes into one placed in the forehead near the median line. This condition is called *synophthalmia* or *cyclopia* (see p. 927).

Finally, there may be an arrest of development, more or less complete, of the brain or some of its parts—*micrencephalus*.

In one phase of malformation involving single individuals, paired organs may be grown together, for example in the so-called "horse-

shoe kidney" (Fig. 183). Or single organs may retain lobular forms belonging to an early period of life—*lobulated kidney*.

There may be supernumerary parts, such as fingers, toes, etc., or organs—spleen, adrenals, lungs, pancreas. There may be fusion of fingers and toes, frequently involving all of the extremities. Various congenital malformations commonly due to arrest of development are exemplified in the diverse phases of "club-foot"—*talipes*—and "club-hand"—*talipomanus*.

Fœtal structures which in the normal development should make way



FIG. 180.—MYELOMENINGOCELE SACRALIS—SPINA BIFIDA.

From a partial failure in the closure of the medullary groove, this sac is formed containing fluid and the lower portion of the spinal cord.

for adult organs may persist. Thus the urachus, the Wolffian ducts, parts of the branchial clefts, may remain.

Through adhesions of the membranes or by abnormal winding of the umbilical cord about the neck or the extremities (Fig. 184), partial decapitation or amputation of a limb may take place (Fig. 185). So also by adhesions of the surface of the embryo and the placenta or the membranes, various disturbances of growth may occur.

Normal and Pathological Conditions in which Two or More Individuals Develop Together.

Two or more individuals may develop together, the bodies being separated as in normal twins, triplets, etc., or the individuals being more or less closely joined or merged. This duplication may be evident, so that the nature of the complexity is clear; or one of the individuals may develop greatly in excess of the other.



FIG. 181.—ENCEPHALOCLE.

There is a fissure on the posterior aspect of the skull, out of which the imperfect brain and its membranes protrude, filling the pouch of the scalp.

Twins, Triplets, etc.—Pregnancies may be complicated by the development in the uterus of two or more embryos. These are called twins, triplets, etc. This duplication may arise by the development of separate ova or the formation of more than one embryo from one ovum.

Twins and triplets developed from one ovum—homologous twins—are always of the same sex; and if both develop normally they usually

closely resemble each other. But the individuals, if born alive, often do not develop equally; one may be less well nourished than the other, from a disturbance of the vascular supply, for example.

One of the twins may die early in pregnancy and suffer varying degrees of degeneration into a shapeless mass, or may die later and be born prematurely or at the delivery of the living twin (Fig. 186). Some of these abortive forms are without a heart or have only a rudiment of that organ. These are called acardiac monsters (*fœtus acardiacus*). They may consist of connective tissue, rudimentary bones, and portions of intestine, and are covered by skin with hair—*acardiacus amorphus*. Or there may be a more or less distinctly formed head without a corre-

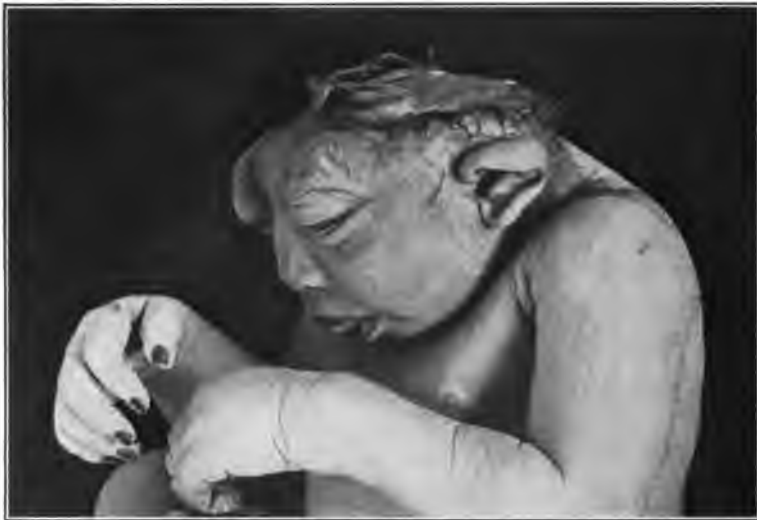

FIG. 182.—CRANIOSCHISIS.

The vault of the cranium is absent. There is a small reddish mass at the base representing the rudiment of a brain.

sponding trunk—*acardiacus acormus*. There may be a fairly well developed trunk with viscera and a rudimentary heart, but no head—*acardiacus acephalus*. Finally, there may be a relatively well developed trunk with defective extremities and a rudimentary heart—*acardiacus anceps*.

In all of the above duplications the fusion is confined to the placenta and its appendages, the bodies of the twins being separate.

Double Monsters (*Monstra duplicia*).—The union to any considerable extent of the embryos themselves is pathological, and the malformations are classified as double monsters.

In these unions of twins there may be: 1, complete duplication of the axis of the germinal area, so that there is a double development of the central nervous system, while the remaining parts are more or

less fused; or, 2, there may be only a partial duplication of the axis, so that either of the head or in the sacral region there may be double development, while at the other extremity the body is single.¹

We shall now look briefly at some of the forms of double monsters in which the individuals are more or less symmetrically united.

There may be fusion of the bodies in the thoracic region. The ensiform processes are united by cartilage, union of the soft parts extending over the umbilical region. The thoracic and abdominal cavities

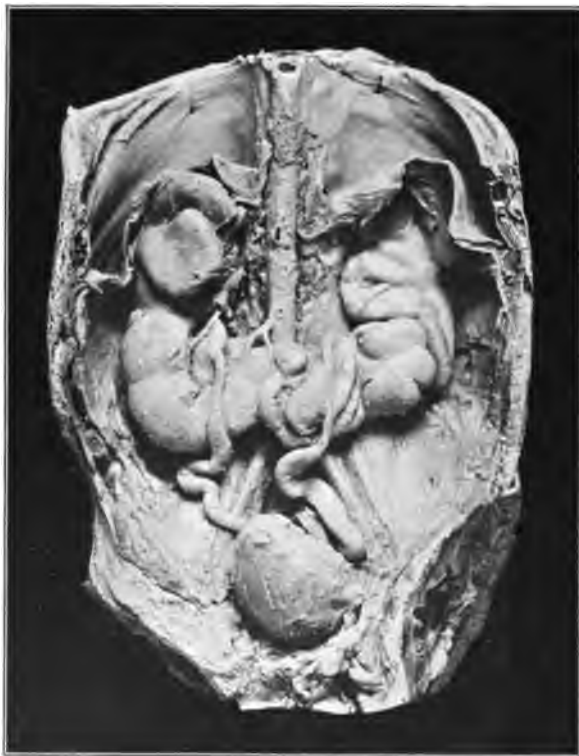


FIG. 183.—HORSESHOE KIDNEY.

The kidneys are in place in the body of the young child. They are lobulated with the large adrenals above them.

are separate. This malformation is called *xiphopagus*. Such were the celebrated Siamese twins who lived to the age of sixty-three. In other cases there is a common thoracic cavity, usually with two hearts and two pairs of lungs more or less malformed (Fig. 187 and Fig. 188). The abdominal cavities may also be united. Parts of the intestine may be common to both twins. These monsters are called *thoracopagus*. They do not long survive birth. The fusion may, however, extend

¹ See *Thoma, l.c.*, foot-note, p. 320.

upward so that two upper extremities may fuse—*thoracopagus tribra-
chius*; or two of the lower extremities may fuse—*thoracopagus tri-
pus*; or, finally, the fusion may embrace the head so that the faces are more
or less united—*prosopothoracopagus*. The cephalic and thoracic regions
may remain separate while fusion takes place from the umbilicus to the
pelvic region. The spinal column is duplicated while there is a common
pelvic ring—*ischiopagus*.

There may be fusion of the otherwise separate twins in the cranial



FIG. 184.—FÆTUS, WITH UMBILICAL CORD COILED AROUND THE NECK AND LEG

region—*craniopagus*. The union is usually only of the scalp and cranial
bones.

The head and the upper part of the body may be single, or the head
alone may be single, while the abdomen and pelvis are separate. There
may be four or less lower extremities. Such malformations are called
dipygi.

There may be union of the head, neck, or chest, so that there are two
faces more or less symmetrical looking in opposite directions—*janiceps*
or *janus*.

In cases in which there is only a partial duplication of the axis, this may be most marked at the cephalic or caudal extremity. Thus may be formed an individual with duplication of the face—*diprosopus*. Thus, depending upon the degree of duplication, arise *diprosopus distomus*; *d. diophthalmus*; *d. triophthalmus*; *d. tetraophthalmus*. But this anterior duplication may extend to the whole head. Thus arise the two-headed monsters—*dicephalus*—which according to the degree of duplication

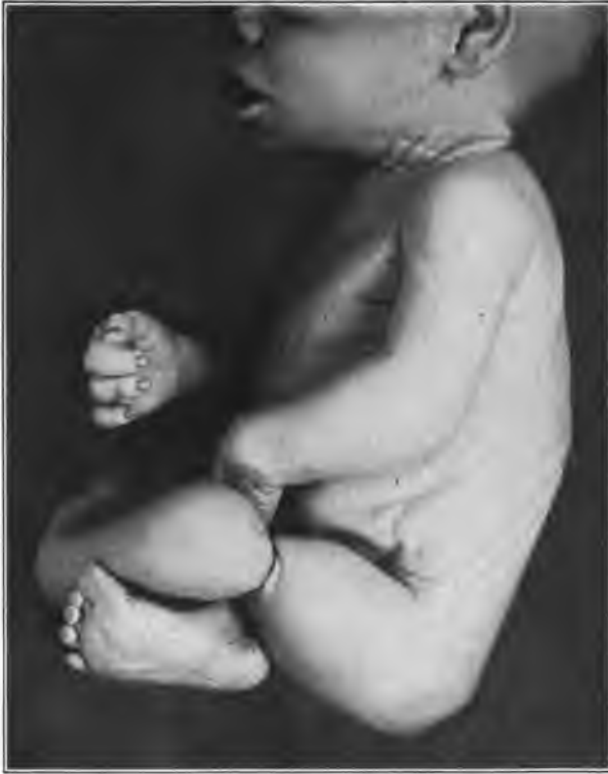

FIG. 185.—PARTIAL INTRÀ-UTERINE AMPUTATION OF THE LEG.

of the upper extremities are called *dicephalus tribrachius*; *dicephalus tetrabrachius*.

Finally, the bodies are united posteriorly in the region of the sacrum and coccyx. This malformation is called *pygopagus*. The individuals may live for years.

In the double malformations which we have thus far considered there has been a more or less symmetrical development of the physically joined twins. But for various reasons it often happens that one of the individuals is arrested in its development, while the other continues. This condition is analogous with that already considered in which the

arrest of development involved an independent acardiac individual which was not viable. But in the present case the arrested twin is joined to the other as a part of a living organism, and its life is thus maintained by the more favored relative. Under these conditions the more completely developed twin is called the *autosite*, the arrested embryo, the *parasite* (Fig. 189).

The rudimentary structure, the *parasite*, may be variously developed. It may have extremities, various forms of tissue, nerve, muscle, intestine,

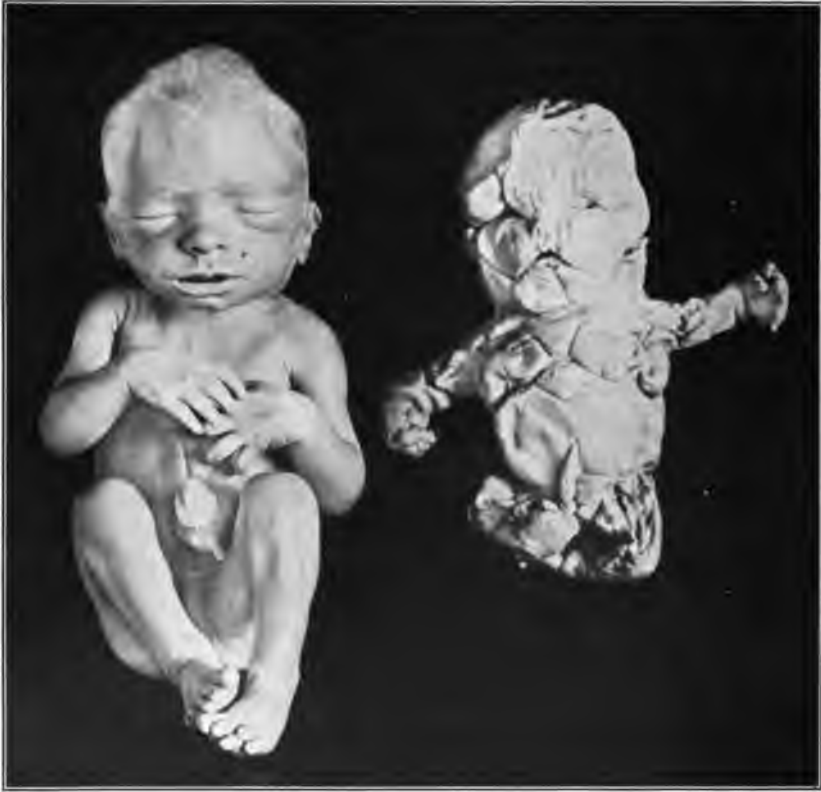

FIG. 186.—TWINS.

The individuals are separate. One died early *in utero* and is only partially developed and mummified

etc. It may be formed of a jumble of tissues with cystic cavities which may be lined with epithelium. Its size varies; it may be as large as the body of the autosite. Thus may be formed the parasitic *thoracopagus*, attached to the sternum, or the *parasitic ischiopagus* and *parasitic craniopagus*. So also are formed the *epignathus*, in which an acardiac parasitic rudiment is attached to the autosite in the facial region. The

rudimentary embryo may be attached in the sacral region, forming sacral appendages or tumors—*sacral teratomata*.

Finally, the second individual may be much less developed than in the cases which we have thus far surveyed, and may be represented



FIG. 187.—THORACOPAGUS.

only by formless appendages or by inclusions in different parts of the body, which are made up of various and often complex tissues—fibrous tissue, nerve tissue, bone, teeth, cartilage, muscle, glands. These are called *teratoids*, *dermoids*, *fetal inclusions*, *congenital teratomata*. They may occur in the ovaries, or testicles, or about the head, in the medias-

tinum, or in the sacral region, and elsewhere. They often become cystic and may give origin to various forms of tumors.

The teratomata are apparently derived either from impregnated polar globules or more probably from a portion of the blastoderm separated at an early period from the cell complex which goes to form the



FIG. 188.—SKELETON OF THORACOPAGUS—FIG.

developing foetus. The separated cells may long remain latent, finally beginning to grow with the power to form complex tissue and structure, but only in a jumbled mass, embraced within or attached to the developed individual. Some of the teratomata are comparatively simple in structure. Their nature is often revealed by the heterologous character of their component structures. The ectodermal elements are often most conspicuous (see p. 358).

We thus see in summary of this brief survey of complex malformations in general that under normal conditions two or more individuals may develop together in the uterus—twins, triplets, etc. Under pathological conditions the individuals may be more or less united, forming double monsters. The duplex individuals may develop more or less



FIG. 189.—CHILD WITH ACARDIAC PARASITE ATTACHED POSTERIORLY. One of the twins, the autosite, has developed; the other only partially.

symmetrically with independent cerebrospinal axes and various degrees of union. Or the development may be very unequal, so that one is a more or less obvious appendage to the other. Finally, one of the individuals may exist as a mere complex rudiment attached to or within its more favored mate.

CHAPTER XI.

TUMORS.

The Nature and Characters of Tumors in General.

THE word *tumor*, which was originally applied to any swelling, has become more and more strictly limited in meaning until it is now commonly used to designate certain more or less circumscribed new tissue growths or neoplasms. But the formation of new cells and new tissues is of such common occurrence under normal as well as under various abnormal conditions that it is desirable for us to fix, if possible, upon some features by which the tissue growths called tumors may be distinguished from other normal or abnormal new-formed tissues. In the first place tumors, like all tissues formed in the body after embryonic life, are produced by the proliferation of cells of normal types, each of its kind.

It would be well in this connection to remember that a given cell of whatever type, be it of connective tissue, muscle, gland, or nerve, can fully maintain the characters of its type only so long as the conditions of its life do not greatly differ from those under which by adaptation to environment the type was finally fixed. The characters of cells are largely shaped by heredity, and these characters are maintained with great tenacity, but both in form and function cells may be largely swayed by external influences. The marks of departure from the type in cells subjected to an unusual environment may be evident when expressed in form or structure, and sometimes in function, but it is well not to forget that even our most refined methods of study of cells leave by far the greater part of their metabolic performances wholly in the dark, while we seem as yet to be only on the threshold of knowledge of their structural details.

These considerations are especially important in the study of tumors as of all new tissue formations, because the key to our understanding of these lies largely in the appreciation of the fact that every cell in the differentiated tissues comes from a cell of the same type. But this, which is sometimes called the principle of legitimate succession in cells, assumes that the conditions under which the life of the new cell is maintained shall not depart too widely from the normal, that is, the usual. The bearing of this limitation will be evident as we proceed in our study of tumors.

The capacity for cell proliferation is most marked in the embryo and during the earlier periods of individual life. When the body attains its development, the power of cell reproduction, as we have seen (see *Regeneration*, p. 64), is largely limited to special forms of tissues, such as connective tissue, the blood, and certain kinds of epithelium. This constant normal regeneration makes good the wear and tear of normal cell life. But here the capacity for multiplication in the cells is closely confined to the requirements of the body. A definite physiological control is evident, similar in character to that under which in normal develop-

ment the amount of new tissue is limited and its adaptation to the organism as a whole secured.

Under normal conditions, furthermore, there may be a very large new formation of tissue under special physiological excitation, as in the mammary gland and the uterus in pregnancy. But here also the character and amount and the functional capacity of the new tissue are strictly limited and subservient to the welfare of the individual.

Let us now turn from these normal new tissues to those which are abnormal. We have already seen, especially in our study of inflammation, that new tissues may form even in considerable amount under abnormal conditions, such as injury with subsequent repair; degenerations and destruction of parenchyma, prolonged hyperæmia, and in compensatory hypertrophies. But under these various conditions also the tissue growth is local, approximately typical in structure, usually limited in amount, and in most cases appears measurably to accord in nature and distribution with the maintenance of the structural integrity and general welfare of the individual. The new tissue, in other words, maintains under these varied conditions a definitely co-ordinated relationship to the body as a whole.

While it is as yet impossible to define tumors in such a way as absolutely to distinguish them from such other new tissue formations as we have just cited, they are in general characterized by such independence and by such irregularity in growth both in structure and extent; by such a lack of relationship to the functional requirements of the individual;¹ by such an emancipation from that subtle physiological restraint which limits cell growth and proliferation in the normal body, and in the new tissue formation in repair, that their distinguishing character is perhaps best indicated by the word *autonomy*, or by the more striking suggestions of the term *cell-anarchy*.

The autonomous or independent character of tumors, as has been very clearly formulated by Thoma, is especially manifested in the distinct limitation of the growth at the start; in the tendency to variation in the structural type; in various functional aberrations of the new cells; in their interference by compression or otherwise with adjacent parts; in their proneness to multiply through local or distant transplantation of cells; and finally, in their liability to various forms of degeneration and necrosis. Furthermore, the independent character of tumors is marked by the fact that the characteristic cells forming the tumor are the progeny of the earlier cells in which the tumor starts, so that the tissues in which the tumor may be placed share only in a secondary way in its structure. But tumors are of course dependent for their nutrition upon the general blood supply and upon the suitable conditions for growth which their situation among other tissues alone makes possible.

The reason why we cannot more accurately characterize tumors in distinction from other new tissue formations is chiefly because we do not

¹ An example of a certain physiological independence in tumors is seen in lipomata, in which a large amount of fat tissue may persist in an ill-nourished individual whose fat has otherwise almost wholly disappeared; or in myomata of an extremely atrophied uterus.

yet know what are their immediate excitants. To this subject we shall presently return, but we must first look at the general characters of tumors.

Tissue Types in Tumors.—Tumors, as we have seen, are composed of the same types of tissue as those normally existing in the body, and from the latter they are derived by a proliferation of pre-existing cells. Thus, tumors of the connective-tissue type originate in connective-tissue cells, of the epithelial-tissue type in epithelium, of muscle in muscle, etc.

While the general types of tissue are maintained in tumors, there are many more or less well-defined departures from these. It should be remembered that the formation and maintenance of typical cell forms, and of typical topography in organs, are closely dependent upon many factors, for example upon mechanical pressure, nutritive conditions, relationship to surrounding parts, nerve relations, and many others. But under the conditions in which tumors grow, all these factors may suffer most significant disturbances, so that the shape, size, structure, and mutual relationship of cells, their grouping, gland types, and various functional characters, may suffer such modifications that great difficulties are often encountered in the attempt to classify tumors in accordance with the established tissue types. Tumor cells also depart from the type in that they often represent embryonic or reversion forms.

Tumors are not only analogous to the normal tissues of the body in structure, but their life history is manifested under the same general laws of nutrition, growth, reproduction, etc. They are supplied with blood-vessels which grow into them from adjacent healthy parts, just as these do, for example, into granulation tissue, so that they may finally possess a more or less independent vascular system.

The blood-vessels, however, especially of rapidly growing tumors, are in many respects atypical and not as sharply differentiated into arteries, veins, and capillaries as are the vessels of normal tissues. Many vessels with wide lumina have thin walls, with few muscle or elastic fibres in them. Thus the blood-vessel system of such tumors is often made up of an irregular meshwork of vascular trunks, which in their branchings, anastomoses, width of lumen, and thickness and structure of their walls are quite abnormal, and in which the blood is conveyed in most unsystematic fashion from its diverse entrance channels to its irregular exits. The cells, especially of malignant tumors, often grow much more rapidly and are larger in the vicinity of blood-vessels than elsewhere (Fig. 203). Tumors have lymph-vessels, and some of them nerves.¹

The intercellular framework of tumors may be in a measure furnished by the connective tissue of the part in which they grow. The tissues by which tumors are connected with surrounding parts or are more or less definitely encapsulated, most commonly originate from without. The tumor in many instances bears the relationship of a foreign body to its surroundings, and a reaction to its presence is incited, quite analogous with that which we have already seen in the case of alien substances in an earlier chapter.

¹ For a study of nerves in tumors see *Young, Jour. Exper. Med.*, vol. ii., p. 1, 1897, bibl.

While the cell divisions by which tumors grow exhibit in general the same minute phenomena as does cell division in normal tissues (see p. 66), abnormal mitosis is frequent. Thus it may be multipolar; the chromatic substance may present great irregularity in form and amount (Fig. 42, p. 67); there may be incomplete nuclear division, or the new nuclei may vary in size and form. While all these abnormalities may occur in other new tissue formations and may be experimentally incited, they are unusually frequent in certain tumors and mark one of the ways in which the lawlessness of tumor growths is manifested.



FIG. 190.—MULTIPLE NODULAR SARCOMATA OF THE SKIN

Degenerative and Destructive Processes in Tumors.—Tumor tissues are subject to the same degenerative changes as other tissues; they may become fatty or calcified, ulcerated, gangrenous, pigmented, etc. By

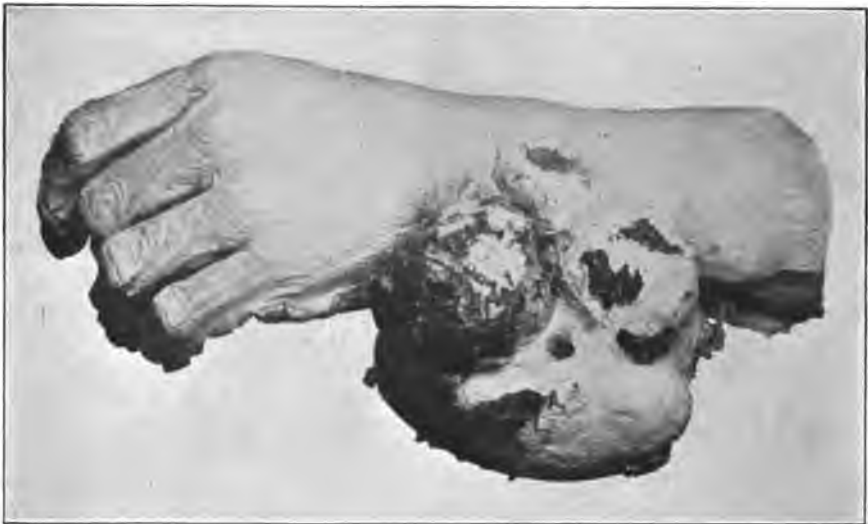

FIG. 191.—SARCOMA OF THE FOREARM.
A tumor of the lobulated type.

necrosis a tumor may be largely destroyed, though complete obliteration rarely occurs in this way. They are liable to undergo the ordinary inflammatory changes, granulation tissue may form in them, and abscesses and cicatrices.

The rapidity of growth of tumors varies greatly; some grow very slowly indeed and may change but imperceptibly in size and appearance for years, while others grow so fast that they do not acquire solidity, and their elements remain in an incompletely developed condition and are thus more liable to destructive changes than are normal tissues. In healthy tissues the blood-vessels are supported by surrounding elements,

which aid them in sustaining the blood pressure from within. In rapidly growing tumors this external support is often lacking, and, as the walls of the blood-vessels are themselves often badly formed, the result is that the walls are apt to become pouched or aneurismal, and they often burst, giving rise to larger or smaller interstitial hæmorrhages.

Shape, Size, and Modes of Extension of Tumors.—Tumors have various shapes: nodular, tuberos, fungoid, polypoid, papillary, dendritic, lobulated, etc. (see Figs. 190, 191, 192).

Tumors may occur singly or in greater or less numbers in the same or in different parts of the body. If they be multiple they may have occurred simultaneously or at different times as independent structures. Or, multiple tumors may occur as the result of the dissemination in the body, from a primary tumor, of cells which form a starting-point for new tumors. Many tumors are sharply circumscribed, may be even encapsulated, and influence surround-

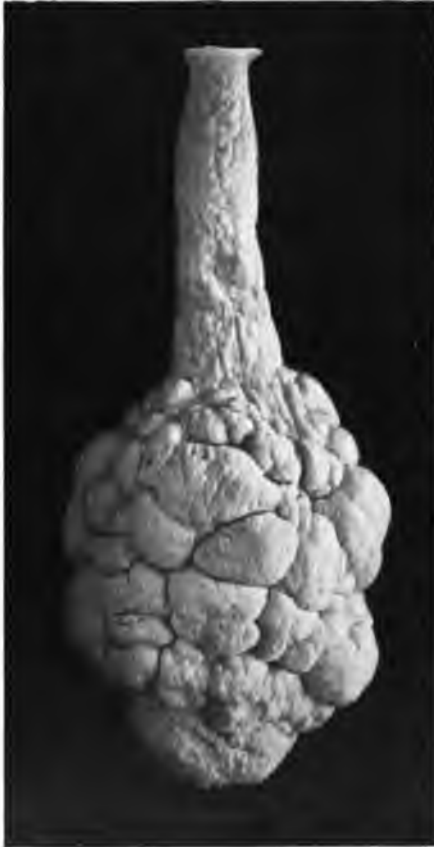

FIG. 192.—A NODULAR POLYPOID TUMOR—FIBROMA—HANGING FROM THE VULVA.

ing parts only by the pressure which they exert upon them. In this way they may cause displacement, atrophy, or necrosis; they may, by pressure on neighboring vessels, induce œdema, thrombosis, etc.; they may in the same way lead to dislocation and caries of bones. But tumors may damage their surrounding tissues by the phagocytic action of their cells, by the products of their perverted metabolism, imperfect secretions or degenerative material, or directly as foreign bodies. Thus various phases of inflammation and tissue destruction may occur in the neighborhood. Leucocytes may enter the tumor from without,

and through these and other phagocytes the tumor tissue itself may suffer damage.

Tumors may grow largely by increase of elements within them, thus simply expanding; this is called *central* or *expansive growth*. They may grow in part or largely at the surface—*peripheral growth*. In this case the growth may be a direct, continuous enlargement of the mass at or near the periphery, the tumor tissue growing in among the surrounding parts. In this case certain tumor cells, especially those of the connective-tissue type, may “emigrate” and may act as phagocytes. This is called *infiltrating peripheral growth*. On the other hand, peripheral growth may take place by the formation of secondary nodules near the primary growth, which, gradually enlarging, finally coalesce with the latter, forming a part of the nodular tumor. This mode of enlargement is called *discontinuous peripheral growth*, and is due to the dissemination of cells from the mother tumor into the adjacent tissue through the blood- or lymph-channels and their proliferation at the points of lodgment. This dissemination may occur by the agency of blood or lymph currents or by the amœboid movements of the cells. Those new cells formed in tumors which are characteristic of the growth are, it should be remembered, all descendants of the cells in which the neoplasm starts and maintain their general type. But the old tissue of the part in which the tumor grows may remain with its vessels and form a matrix whose interstices are filled with the new tumor tissue; or the old tissue may furnish the starting-point for a new growth of a fibrous and vascular nutrient and sustaining stroma.

Metastasis of Tumors.—All tumors are not limited, as we have seen, to that part or region of the body in which they first occur. Sooner or later secondary nodules resembling the first may be found in distant parts of the body, sometimes singly, sometimes in great numbers. These may grow like the parent tumor, and themselves form foci for new disseminations.

This dissemination of tumors is one of the important elements of malignancy, and is called *metastasis*, the secondary tumors being called *metastatic tumors*. Metastasis usually occurs by the transportation of tumor cells through the blood or lymph channels (Fig. 193). Since the tumor itself may contain new and badly formed blood- and lymph-vessels, and its structures be in close contact with the vessels of the tissue in which it grows, the cells of the primary tumor may, by ulceration through or by atrophy of the walls, readily find their way into the lumen of the vessels and be swept away by currents as emboli, and, finding lodgment, proliferate and grow, forming secondary tumors; or the proliferation may occur in the vascular endothelium itself, when the

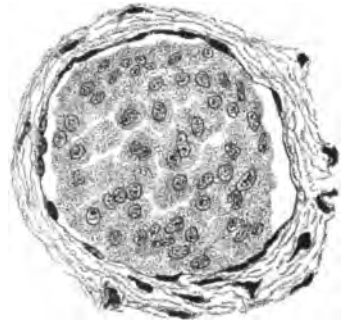


FIG. 193.—A TUMOR-CELL EMBOLUS GROWING IN A BLOOD-VESSEL AT A DISTANCE FROM THE PRIMARY CARCINOMA IN THE MAMMA.

formation of emboli is easy to understand. When carried through the lymph-vessels the tumor cells may for some time be kept from the larger channels and from general dissemination by lodgment in the lymph-nodes, where they may establish independent tumors.

The tumors in which metastasis most frequently occurs are, as a rule, those which grow rapidly, are vascular and succulent, and contain many cells in proportion to their sustaining connective or indifferent tissues. The parts of the body in which metastatic tumors are most apt to form depend, of course, upon the situation of the primary tumor and the distribution of the vascular channels through which dissemination occurs in accordance with the general principles of embolism. Another form of metastasis is seen in the dissemination of tumors over serous surfaces, the peritoneum for example, in which the mode of distribution from a primary ulcerating tumor may be obvious. An interesting example of this type of metastasis is the frequent bilateral occurrence in the ovary of metastatic carcinomata originating from the mucous membrane of the stomach. In many of these cases no macroscopic growths can be found on the surface of the peritoneum and the tumor in the gastric mucous membrane may be very small, although the ovary shows extensive involvement. The possibility of implantation of tumor cells upon the skin or mucous membranes should also be mentioned.

Metastasis affords one of the most noteworthy examples of the great proliferative capacity of the cells of malignant tumors. For in the metastasis of normal tissue cells, such as not infrequently occurs after injuries to the bones or the liver, for example—the so-called parenchyma-cell emboli—the transported cells usually soon die and are disposed of as foreign bodies. But the exalted proliferative capacity of detached tumor cells enables them, in spite of adverse conditions, to establish and maintain fresh foci of vigorous tissue growth.¹

The Malignancy of Tumors.—Not less variable than the size, mode of growth, and structure of tumors is their significance in the organism. It is customary to classify tumors, for practical purposes, as *malignant* and *benign*, and for a long time *malignant tumor* and *cancer* or *carcinoma* were synonymous terms. Now we know that other tumors as well as carcinomata are malignant, and, furthermore, contrary to the former belief, that malignancy does not depend upon any specific extracellular agent in the tumor. By the malignancy of a tumor is not meant merely the gravity of its presence, for a simple fat tumor, by pressing on the trachea, may lead to suffocation, and any tumor may secondarily cause death by hæmorrhage. The more obvious marks of malignancy in a tumor are: 1. *Invasion of adjacent tissues by eccentric or peripheral growth.* 2. *The tendency to local recurrence after removal.* 3. *The formation of metastases.* 4. *An interference with the nutrition and general well-being of the body, which may give rise to a condition known as cachexia.*

The modes of invasion of surrounding tissues and the formation of

¹ For a study of metastasis in histologically benign tumors see *Borrmann, Ziegler Beitr.*, Bd. xl., p. 372, 1906.

metastases have been considered above. The tendency to local recurrence after removal is probably, in most cases, due to the incomplete removal of the peripheral infiltrating cells. These may be very few in number and lacking in characteristic structural features, but they are none the less endowed with the capacity of proliferation and development into a new and similar tumor at or near the seat of the one extirpated. The infiltrating peripheral cells may remain dormant for a long time after an operation, or may immediately commence to grow. But the mere fact that a second tumor develops in the place of one removed does not imply malignancy, since this may result from a continuance of the conditions which induced the first.

The drain upon the system by the rapid growth of a tumor, together with the absorption from it into the body of deleterious materials, from sloughing, ulceration, and degeneration, or the occurrence in it of local infection with various micro-organisms may give rise to fever and other constitutional disturbances. Or, the tumor may induce feebleness, anæmia, and that general impairment of the nutritive functions of the body known as cachexia. This condition is frequently rendered worse by the mental status of the patient in the presence of such a traditional object of alarm.

It should be remembered, however, that so long as they are localized and have not undergone degenerative changes, even the most malignant tumors do not usually give rise to a cachexia, since the drain upon general nutrition by their simple growth is not, under ordinary conditions, very great. When the system is deteriorated by the absorption of septic materials from tissue degeneration, however, this may become a very important factor.

This condition of cachexia, with our present knowledge, so evidently secondary to the growth and degeneration of the tumor, was formerly termed a dyscrasia or diathesis, and was supposed to precede and induce the growth of malignant tumors, particularly cancers.

It will be seen from what has been said about malignancy in tumors that the distinction between the malignant and the benign, while of great practical importance, is not fundamental, since the elements of malignancy are largely factors of the mode and extent of growth, and all tumors at an early stage are in a clinical sense benign. It is in the last analysis by their apparently almost unlimited potency of growth that the malignancy of tumors is marked.¹

It is finally to be noted that the fragments of tumors which have found access to the vessels may act as simple emboli leading to immediate death, or, if infected, may incite metastatic abscesses.

It was formerly supposed that the cells of malignant tumors, particularly of carcinomata, had a characteristic structure and appearance, and that by the examination of single or of a few separated cells the nature of the tumor could be determined. From the above considerations it will be evident, since all tumor cells have their prototypes in the normal body, that there is nothing pathognomonic in the appearances of single cells. It is by a study of the general structure and of the topography of

¹ See potency of growth in transplanted tumors, p. 354.

tumors as well as of the characters of the individual cells, that we are enabled to determine their nature. And even then we must often bring to our aid the clinical history and gross appearances of the growth before a definite conclusion can be reached. We may indeed sometimes, aided by the clinical history or gross appearances, be able, by microscopical examination of scrapings from a tumor or of fluids from an internal cavity in which it is growing, to form a reasonable conjecture regarding its nature. As a rule, the peripheral portions of the more rapidly growing tumors are best adapted for microscopical examination, because here secondary degenerative changes are less likely to have occurred than in the central parts.

Etiology of Tumors.

The etiology of tumors is one of the most complex and in many ways difficult subjects in general pathology, and with the limitations which the character of this work imposes we can touch only briefly upon some of its more important aspects, referring to more extended works and to monographs for a vast amount of statistical and experimental data.

General Conditions Relating to the Occurrence and Growth of Tumors.

—We shall first consider some of the general conditions which seem to have a bearing upon the occurrence of tumors.

Age.—While it may be said in general that tumors are most frequent in adult and advanced life, it is noteworthy that tumors of the connective-tissue type are apt to develop earlier, while the epithelial tumors are more frequent in the later periods. Thus, in one thousand and sixty-three cases of epithelial tumors analyzed by Gallard, only six occurred in the first ten years of life. The most common situation of tumors differs also in the young and in the old. Thus, in the earlier years, as statistics show, the most frequent seat of tumors is the eyes and their adnexa, the kidneys, bones, and testicles; whereas in adults and the aged, the stomach, uterus, liver, and mamma are most commonly involved. Carcinoma of the rectum, however, is an exception, for it is relatively frequent in early life.

Sex.—Sex is also a significant factor in the development of tumors, especially of those which are malignant. Thus, in general, it may be said that the statistics indicate malignant tumors to be about twice as frequent in females as in males. This proportion, however, does not hold good for tumors of the individual organs. For example, tumors of the stomach and of the tongue and lips are more frequent in men than in women. On the other hand, tumors of the breast are far more common in women than in men.

Heredity.—While the influence of heredity is difficult to estimate accurately, there are a few recorded instances of the remarkable prevalence of malignant tumors in families within a few generations. The general facts, however, are not so striking. The statistics of Williams showed that in two hundred and thirty-five cases of carcinoma of the uterus or breast, about nine per cent. gave a history of carcinoma in father or mother, while in nearly twenty per cent. there was evidence of carcinoma in the family. In the estimates of other observers, the hereditary influence seemed evident in about one-third or one-fourth of the cases. It is, however, instructive in this connection to note that in a

study by Snow of seventy-eight healthy persons there was evidence of carcinoma in the family in about one-fifth of the cases. On the other hand, it has been shown by breeding experiments that carcinoma is no more frequent in the descendants of carcinomatous mice than in the descendants of normal mice.

It is clear, therefore, that while such statistics are suggestive and on the whole indicate that a hereditary predisposition to the development of tumors may exist, this does not in any way account for the immediate incitement of the growth of tumors, and is indeed, as Menétrier has urged, but one of many examples of hereditary predisposition which is observed in many forms of disease, such as infections, cerebral apoplexy, etc.

The influence of *climate, food, race, and social condition* has been invoked as bearing upon predisposition to the growth of tumors; but the evidence is not convincing that these are very significant in etiology.

Local Predisposing Factors in the Development of Tumors.—When we turn from the general to the local conditions bearing upon the origin of tumors, we find an imposing array of instances in which tumors, and especially malignant tumors, follow *local injuries*, either mechanical or toxic, or are associated with chronic inflammatory processes. Bruises or contusions, particularly those involving the bones, are not infrequently followed by malignant tumors, and it is noteworthy that these tumors are most apt to be of the connective-tissue type—sarcoma, osteo-sarcoma, chondroma, etc. Epithelial tumors, on the other hand, are more frequently developed at the seat of repeated injury or long-continued irritation. Thus, epitheliomata are common in the mouth, near a rough ulcerated tooth, on the lips of pipe smokers, and on the abdomen in Hindus owing to irritation produced by fire baskets which they wear about the body, at the edges of chronic ulcers, on the skin of workers exposed to various chemical or mechanical irritants, in cicatrices, at the orifices of the stomach and at the anus. Finally, the frequent occurrence of carcinoma of the liver with cirrhosis, though less easy of interpretation than many instances of the association of tumors with chronic inflammation, is worthy of notice in this connection.

Before concluding this brief survey of the relationships of tumors to trauma, prolonged irritation, and chronic inflammation,¹ it may be wise to remind the reader that undue significance should not be attached to this occasional association, since in the great majority of cases these conditions are not followed by tumors, nor, furthermore, has it ever been possible to induce genuine tumors experimentally under these readily secured conditions in animals. The bearing of trauma upon the origin of tumors is to be held in mind in estimating the influence of sex, since males are in general more liable to injuries than females.

The relatively common development of tumors in pigmented and other *nævi* of the skin illustrates the significance of *local malformations* as predisposing factors in the origin of tumors.²

¹ For an interesting study of the relationship of trauma to malignant tumor formation see *Brosch, Virchow's Arch.*, Bd. clxii., p. 32, 1900, bibl.

² It should be remembered that many of the complex tissue growths often reckoned among tumors and called *teratomata* are really embryonic rudiments of another individual. While such rudimentary

Several cases have been recorded in which through injury there has been a mechanical displacement of cells—*heterotopia*—from which in their new situation tumors have developed. These cases, which have been in a measure paralleled by experiments in animals, illustrate an important class of congenital tumors, often cystic in character, which arise from embryonal cell displacement, or, as is the case in many of the tumors of the neck at the site of the branchial clefts, from an imperfect closure of embryonal openings.

Cohnheim's Hypothesis of Superfluous or Displaced Embryonal Cells.—

We have seen that such evident malformation as the *nævi* of the skin may form the starting-point of malignant tumors. We know that in many cases cells or tissues or parts of organs displaced during embryonal life, as in the branchial clefts or in the kidney, may later develop into tumors. Cohnheim has gone further than this and framed an hypothesis to the effect that all true tumors arise in faulty embryonal development. In accordance with this hypothesis, cells which in the course of the development of the body may be displaced or become superfluous or do not undergo the usual differentiation, may remain for long periods unaltered but liable in later life, from whatever reason, to commence growing with all the potencies of lowly organized cells, in the midst of the mature tissues. The apparent influence of heredity in the occurrence of some tumors, the congenital nature and early development of others, their atypical structure in general, the formation in one organ of tumors of types belonging to another, for example adrenal tumors in the kidney, and the tendency of many forms to occur in situations in which during the development of the embryo considerable complexity exists, as well as their frequent primary multiplicity—all of these characters of tumors lend considerable plausibility to Cohnheim's hypothesis, and it appears to be applicable in certain cases. But it still lacks a morphological basis, since no one has seen the postulated, strayed, or dormant embryonic cells; again, it by no means follows because tumors often develop at the seat of malformations or may arise in embryonal heterotopias that all tumors are thus associated; and finally, the frequent origin of epitheliomata in cells which have been formed in adult life, in cicatrices, for example, is evidence that this hypothesis is not in any event of universal application.

We have now reviewed a series of conditions which appear more or less directly to bear upon the development of tumors: general conditions, such as age, sex, hereditary influences, etc.; local conditions, such as congenital or acquired malformations, injuries, long-continued irritation, inflammatory processes, surplus or displaced embryonal cells with foetal potencies of growth. But when all these are taken into the account, we do not appear to have gained a definite clew to the immediate actual excitant of the new growths. Given any or all of the varied predisponents, why do the cells, which under any of these favoring con-

embryos may be large and present such diversity and arrangement of tissue as to render the character of the growth obvious, they may, on the other hand, be very simple in character, as in some of the so-called dermoid cysts. These are all to be regarded rather as malformations than as genuine tumors.

ditions may have remained long inactive, and indeed usually do so, presently begin to proliferate and continue this new activity beyond the limitations of structural types or physiological correlation? It would appear that either there are external excitants of cell growth, as yet unknown to us, which suddenly become active, or else we are face to face with the fundamental problem as to the nature of the normal physiological impulses to cell growth and proliferation¹ and the restraining influences to which these are subject.

The Excitants of Tumors.—If now we turn from the various general and local factors which appear to influence the occurrence of tumors to the views which are held as to the actual excitants, we find that these may in general be grouped in two classes. The first class of views involves the assumption of some form of living micro-organism capable, under suitable conditions, of inciting the body-cells to the proliferative capacities which are the chief characteristic of tumors. This is called the theory of the *parasitic origin of tumors*. Those who hold this view regard the processes by which tumors are formed as analogous with those involved in the infectious diseases.

On the other hand, those who hold the second class of views regarding the excitants of tumors do not believe that tumors of any kind, even the most malignant, are induced or perpetuated by processes analogous with those involved in infection, but that the excitants to tumor formation are to be sought in the inherited and inherent potencies of the body-cells themselves set free from their normal physiological restraints under a variety of external conditions. This is called the theory of the *biological origin of tumors*, or the theory of *intrinsic excitants of tumors*.

Micro-organisms as Excitants of Tumors. Bacteria.—It is not surprising that micro-organisms should have been thought of as possibly direct excitants of tumors, especially in view of a certain crude analogy between some phases of tumor growth and metastasis and some forms of infection with metastasis. Bacteria of many kinds have, in fact, been frequently found in tumors of many sorts; but there is no conclusive reason at hand for the belief that they are ever of any direct significance save as chance contaminations of vulnerable tissues or as incitants of secondary and complicating lesions.

Protozoa.—A great deal has recently been written about certain structures which are not infrequently found in or between tumor cells, especially in the carcinomata, which have been hastily assumed to be parasites and supposed to be *protozoa*. These cell "inclusions" ("cancer bodies," "Plimmer bodies," "Russell bodies," etc.) are for the most part larger or smaller rounded bodies (Figs. 194 and 195); with or without nuclei; sometimes with double contours, sometimes not; usually sharply outlined against the cell protoplasm in which they lie; often crowding the nucleus to one side, often situated within the nucleus, or apparently replacing it. Some of them are cell secretions or degeneration products, some are invaginated epithelial or other cells, or cell

¹ See Regeneration, p. 64.

nuclei which have undergone various degenerative metamorphoses, fragmentation, etc. Some of the questionable structures appear to be the metamorphosed nuclei of the tumor cells themselves. They may be single or there may be several in a cell. They are especially common in gland-celled carcinomata. Similar objects are to be found in other than tumor tissues. They are not present in some forms of carcinoma. They are readily stained, with varying degrees of intensity, by hæmatoxylin, eosin, safranin, or fuchsin. There is, in the writer's opinion, no evidence either that these are living organisms or that they have anything to do with the origin of tumors.

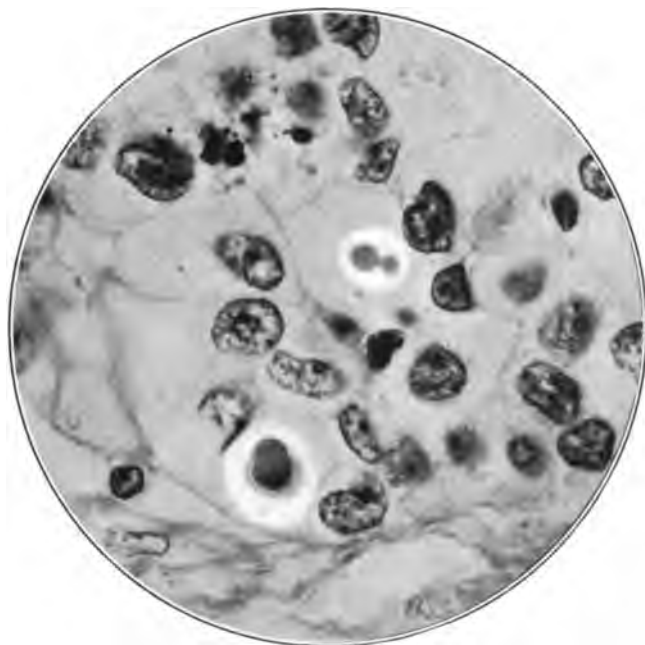


FIG. 194.—"PLIMMER'S BODIES" IN CARCINOMA MAMMÆ.

While coccidia or allied organisms, with which these "cancer bodies" have been compared, are capable of inciting the growth of a small amount of new connective tissue and sometimes lead to hyperplasia¹ of epithelium, such growths are apparently inflammatory in character, as are those other new tissue formations incited by the tubercle bacillus, the lepra bacillus, etc., which have sometimes been improperly classed with tumors and called *infectious granulomata*. The reader is referred to the sections dealing with the nature of the inflammatory process in general (p. 81), and to the introductory section in the present chapter for a review of the differences in the conception of the inflammatory processes and tumor formation.

¹ See Tyzzer, *Jour. Med. Res.*, vol. vii., p. 235, 1902.

Yeasts.—Attention has been called, in connection with tumors, to certain forms of yeasts or blastomycetes as excitants of new tissue growths, but these also appear to be inflammatory. The cultivation of yeasts from the tissues of malignant or other tumors is of no more significance than the cultivation of bacteria under similar conditions.

The nearly uniform failure in the attempts to transplant tumors from one species of animal to another, although the morphological characters of such tumors occurring spontaneously appear to be identical, and the absolute failure to cultivate, either directly or by inoculation, any constant organisms from them which are capable of inducing experimental tumor growths; the difference in the nature of metastases; the failure

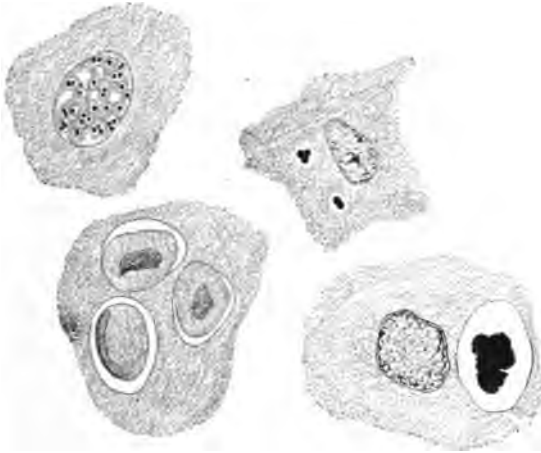


FIG. 195.—EPITHELIAL-CELL "INCLUSIONS" IN TUMORS.
Showing various forms. From carcinoma.

of statistical data to substantiate the claims made for the increase of cancer and its endemic occurrence, all speak with much force against the notion of the parasitic origin of malignant tumors. Moreover, the great diversity in the character and in the inconstancy of occurrence of the objects which have been regarded as of possible significance in tumors, as well as their occurrence elsewhere, greatly diminishes the plausibility of the claims which have been made for them.¹

It is much to be regretted that most of those who advocate the parasitic nature of tumor excitants should be so engrossed with the alleged parasites that they largely ignore the dominant characters and the life history of the tumors themselves, especially of malignant forms, and the fundamental distinctions between these and such inflammatory growths as may superficially resemble tumors and which are undoubtedly often incited by various kinds of micro-organisms.

One does not, of course, assert that tumors cannot be incited by para-

¹For an interesting critical study of the so-called infectious lympho-sarcoma of dogs see *Beebe and Ewing, Jour. Med. Res., vol. xv., p. 209, 1906.*

sites, but at present no adequate reason appears to exist for believing that they are.¹

It is indeed not improbable that a local predisposition to tumor formation akin in nature to that which now and then is attributable to trauma occasionally may be induced by micro-organisms. But this it remains for future researches to demonstrate.

The Intrinsic Excitants of Tumors.—“Biological Origin.”

The Complexity of the Problem.—It seems to the writer that to seek for a single external excitant or group of excitants for the aberrant tissue growths which we call tumors is to ignore the many still obscure influences which are at work in all tissue growth, especially those physiological agencies which foster cell proliferation and tend, under the influence of heredity, to specialization in form or function. On the other hand, not to be ignored are those influences, whether of nutrition or pressure or exposure, which mould the cell growth under normal conditions into fixed and useful forms. It is rather a matter for surprise that ever-changing, self-regenerating living tissue does not oftener go astray in its activities than that it should only now and then do so. This latter somewhat inverted point of view may be useful in calling away the attention, in discussing the etiology of tumors, from a too close regard to extraneous factors, and directing it to the many still unexplored fields in cell physiology with which we must perhaps become familiar before we can with fair hope of success attack the serious problems of both the excitation and the prevention of tumors.

No adequate conception can be gained of the complexity of the problem involved in the origin of tumors or of the directions in which the highest promise of experimental research lies without a recognition of the new cell lore derived from a study of the lower and simpler forms of life.

The more commonly accepted and time-honored view of the immediate excitation of tumors is that they are due to some stimulus—“formative stimulus”—by which the proliferative capacity of the cells is increased. What the nature of this postulated stimulus may be, where it comes from, and how it is brought to bear upon the transformations of energy which, through the subtle mechanism of the cell, are manifested in proliferation, is in no wise clear.

The Relation of Abnormalities in Mitosis to Tumors.—It has become evident from the many illuminating studies which have been made during the last few years upon the phenomena of mitosis, that through the character and performances of the chromatic substance of nuclei and in the chromosomes many of the potencies and peculiarities of cells may find expression. It is natural, therefore, that studies should have been made upon the nuclear characters of rapidly growing tumors.

Thus, v. Hansemann² records observations upon the mitotic figures

¹ For a study of the nature of the cell inclusions of cancer see *Greenough*, Jour. Med. Res., vol. xiii., p. 137, 1905.

² v. Hansemann, Biol. Centrbl., Bd. xxiv., No. 5, 1904.

of malignant tumors which led him to assume that they have suffered modifications characterized by a loss of differentiation, a condition which he calls *anaplasia*. It is assumed that the cells of malignant tumors have acquired embryonic characters expressed by their independence and increased power of proliferation and of destruction of surrounding tissues. But this view, even if sustained, does not throw light upon the inciting factors in tumors.

Similarly Farmer, Moore, and Walker,¹ studying the phenomena of mitosis in malignant tumors, have asserted that there is in this mitosis a reduction in the numbers of chromosomes similar to that occurring in the maturation of sexual cells, the reduced cells having half the number of chromosomes of the somatic cells. Thus in accordance with this view, malignant tumors arise from the metamorphosis of differentiated somatic tissues into a special form of reproductive tissue to which these observers attribute the independence and proliferative capacity marking malignancy. But this conception of the nature of the departure from the normal in malignant tumors, even if the alleged facts upon which it is based were established—which does not seem to be the case since reduced numbers of chromosomes may not be present in parts of such tumors—does not reveal the inciting factors in these growths.

Cohnheim's Hypothesis.—The hypothesis of Cohnheim, which we have considered above, while in accord with many facts bearing upon the morphology, clinical manifestations, and experimental observations of tumors, really relates to the predisposing conditions of tumor formation rather than to the actual excitants. It was, in fact, necessary for Cohnheim to assume, as possible final excitants of tumor growth from his displaced or belated cells, a local hyperæmia or a diminished resistance to their growth on the part of surrounding tissues.²

Ribbert's Hypothesis.—A more subtle and perhaps more comprehensive view of the agencies which must be taken into the account in the excitation of tumors is that especially advocated by Weigert³ and Ribbert.⁴ These observers and those in sympathy with their views do not admit a new formative stimulus into their conception of the origin of tumors, but regard the usual potencies of the cells in this respect to be sufficient if the natural restraints to over-proliferation be in any way diminished.

Ribbert has, perhaps more definitely than any other, framed a working hypothesis along these lines which is at least suggestive. He lays stress in his conception of the origin of tumors upon the intimate associations of the cells of the normal body as parts of an organism, whose varied capacities are normally held in some fashion under mutual restraint in subservience to their common welfare. This mutual relationship, however, once destroyed, for example, by the separation of cells or cell groups from their organic associations, they assume less highly

¹ See Farmer, *Nature*, Feb. 4th, 1904; also Bashford and Murray, *Proc. Roy. Soc.*, January 21st, 1904.

² For a further discussion of these various views see Nichols, *l. c.*, foot-note, p. 354.

³ Weigert, "Neue Fragestellungen in path. Anat.," *Deut. med. Wochenschr.*, 1896, p. 635.

⁴ Ribbert, "Geschwulstlehre," 1904; or "Lehrbuch d. allg. Pathologie," 1905.

differentiated characters, their physiological capacities are no longer held in leash, and these, if the nutritive and other conditions be favorable, may express themselves in exaggerated fashion by excessive growth and proliferation.

Ribbert explains the way in which he conceives that the process of cell disassociation and release from restraint may occur. Since he does not admit a primary increase in the inherent proliferative capabilities of the cells, he cannot assume, as is commonly done, that the process is initiated, in carcinoma for example, by the epithelial cells. He assumes that the process may start in the connective tissue, which is liable to increase in amount in response to a variety of influences, notably those which involve trauma, or simple inflammation, or replacement hyperplasia. In the starting of carcinoma of the stomach or intestine, for example, Ribbert asserts that, in many cases at least, the new-formed connective tissue cuts off cells or cell groups from their organic connections, and claims that in this way alone we may account for the required release from the restraints of the organic association and the exuberant aberrant growth which follows.

This view is interesting in connection with the frequent association of carcinoma with chronic inflammation, which has been already noted. Ribbert also insists upon the embryonic displacements or superfluous cells of Cohnheim as important predisposing factors in the release of tissues from organic control.

It is assumed by those who adopt the hypothesis of Ribbert that the localized groups of cells, in which tumors originate during their growth under the conditions associated with their emancipation from organic control, have so adapted themselves to abnormal nutritive and other adverse conditions that the transportation to a new site as tumor cells can more readily be endured than by cells which have not enjoyed this preliminary adaptation to nutritive and environmental hardships—parenchyma-cell emboli for example.¹

Ribbert's views on this subject are summarized by himself substantially as follows:

All tumors originate in cells which have been separated from their normal relationships.

This separation occurs either by a disturbance of the embryonal or post-foetal developmental processes, or by trauma, or by processes of growth which are the ultimate results of inflammation.

¹ Fischer has recently shown that the injection beneath the skin of the ear of the rabbit of a mixture of oil and Scharlach R is capable of inciting a downward growth of epithelium in branching plugs resembling in structure the epithelial reticulum of epitheliomata. These structures maintain their characters and growth for a considerable time, but when the colored oil is extracted the epithelium passes on to its mature condition, and becomes cornified, and the growth ceases.

The structures formed are limited in growth and are not, therefore, to be properly classed with malignant tumors. Fischer assumes that the injected colored oil is chemotactic and postulates for malignant tumors the presence in the body of some substance which he names *atrarine*, which through its persistent action incites the continuous cell growth marking malignancy. But this opinion has not stood criticism, the incitation to growth being due largely to increased blood supply. When Scharlach oil is injected with tumor material it diminishes the percentage of positive inoculations because it incites an excessive tissue reaction which causes absorption or destruction of the tumor cells. We refer for further details of these experiments to the original article, Münch. med. Woch., 1906, p. 2041.

The dissociated cells grow independently and in limitless fashion, because the organism has lost control over them.

The differences in the types of tumors are accounted for by the character of the originally separated cells and the conditions under which these have grown.

The Ultimate Problems in Tumors.—When all has been said about general and local predisposing factors in tumors; when through observation and experiment all possible light has been thrown upon the nature of their immediate excitants, we are still face to face with a host of problems relating to tumors as organized entities showing complex tissue adjustments and revealing specific inherited qualities and powers.¹ These all in the end carry us back to the fundamental questions in biology and the mechanism of development with which students of all forms of life are more or less directly engaged; back even to the potencies which dominate and characterize life itself, and are handed on from cell to cell through the long line of inheritance. It may be that from the chromosomes and their abnormalities with which the cytologist is so eagerly engaged to-day is to be derived the knowledge through which we shall arrive at a more definite comprehension of tumors. Thus it is evident that here as elsewhere in pathology we are dealing, not with independent problems, but with specific outlooks only on the wider field of general biology.

The Need of New Research in Tumors.

It has become evident of late that much of the statistical lore of tumors, especially of malignant types, which has been handed on from one writer to another, is in need of a critical revision, and that many of the current opinions regarding malignant tumors are based upon alleged observations of doubtful validity and upon inferences hastily and illogically drawn. Among these opinions needing revision may be mentioned the alleged relative rapid increase in the frequency of cancer, which rests upon data obviously faulty; the contention that metastases in malignant tumor are closely analogous with metastases in infective processes and indicate the infective nature of the former; the view that carcinoma has been in many instances directly conveyed by contact from a victim of the disease to a well person; the successful inoculation of carcinoma of man into the lower animals. None of these points has been sustained by reliable data.

It has become evident that a new departure is necessary in the study of tumors and that this is especially urgent along two lines: first, in the collection of more reliable statistics,² which shall embrace not only man, but the lower animals as well; and, second, the initiation of careful and extended experimental studies of the tumors, especially the

¹ For a suggestive study of this subject see *Albrecht*, "Entwicklungsmechanische Fragen der Geschwulstlehre," *Verh. Deutsch. Path. Ges.*, Bd. viii., p. 89, 1904.

² For a study of the statistical investigation of cancer see *Bashford and Murray*, Report of Imp. Cancer Research Fund, No. 2, Part I., 1905.

malignant tumors, of the lower animals, in which such growths frequently occur spontaneously.

When along these lines the data relating to the biology of tumors shall have been gathered on a large scale the outlook will be brighter for the study of the fundamental problems of the inciting factors in tumors and of promising measures for their treatment.

The Transplantation of Tumors.

We have seen in an earlier part of this book (p. 77) that it has been possible to transplant living tissues from one animal to another of the same species; that when this is done there may be at first a slight cell proliferation at the new site and, in the case of epidermal structures, a considerable growth, so that new epidermis may form in skin grafts, while cyst-like structures may develop when epidermal tissues are embedded in the tissues of the host. It has even been possible to transplant whole organs, ovary, testicle, and kidney, which have maintained for a short time their structural and functional qualities on the new site. But in general the fate of transplanted normal tissues is sooner or later to undergo necrosis or to fall under the sway of the protective agencies of the host, and either by the action of lytic fluids or by phagocytes to disappear. Transplantation of normal tissue to animals of another species is not successful.

Turning now to tumors, we find that a great deal of most important and illuminating work has recently been done in the way of tumor transplantation in animals, especially of the malignant type, carcinoma.¹ Tumors of nearly all kinds known in man may occur in domestic or wild animals, even in cold-blooded animals such as fish. But it is to tumors spontaneously and occasionally occurring in mice and rats, especially carcinoma, adeno-carcinoma, and sarcoma, that attention has been particularly directed. It has been found that if small particles of such spontaneous mouse tumors be inserted under the skin of healthy mice of the same race, in a certain varying proportion of cases the implanted cells will grow and produce new tumors similar in character to the original. Thus, from animal to animal through long series the tumors may be propagated to an extent which, so far as is now known, is without limit. The most striking feature of these transplantations is the apparently boundless capacity for proliferation of the cancer tumor tissue. It will readily be seen if, as is sometimes the case, a few small fragments of such a tumor in new hosts within a few days grow to an aggregate bulk equaling that of the original tumor, and if the transplantations were continued, that in a few generations the amount of new living tissue which would result would be prodigious almost beyond belief.²

With the recent development of this form of experimental study of carcinoma a very large and promising field of observation is open, and already many most significant facts have been brought to light.

It is now possible to demonstrate that the characteristic cells of the new tumor are not furnished by the host, but are the progeny of the transplanted cells and, carried through however many generations, the lineal descendents of the cells of the original spontaneous tumor.

While the researches of Bashford³ have shown that in general the sustaining connective-tissue stroma and the blood-vessels of the transplanted tumor tissue disappear and are replaced by the connective tissues of the host at the new site; this is not always the case, for in certain transplanted tumors observed by Ehrlich,⁴ the

¹ For a *résumé* of the earlier phases of tumor transplantation see *Nichols*, Third Report of the Croft Cancer Commission, Jour. Med. Res., vol. xiii., p. 187, 1905. For later studies see *Ehrlich* and *Apolant*, Berl. klin. Woch., 1905, p. 871; *ibid.*, 1906, p. 37, also Arb. a. d. Königl. Inst. f. exp. Therapie, Heft 1, 1906; also *Bashford*, Rep. Imp. Cancer Res. Fund., No. 2, Part II., 1905.

² For a calculation of the possibilities of such a growth see *Apolant* and *Ehrlich*, Berl. klin. Woch., 1905, p. 871; *ibid.*, 1906, p. 37.

³ *Bashford*, Reports of the Imp. Cancer Research Fund, No. 2, Part II, 1905.

⁴ *Ehrlich*, "Exp. Carcinom Studien an Mäusen." Sep. Abdr., Arb. a. d. Königl. Inst. f. exp. Therapie, Heft 1, 1906.

connective-tissue stroma gradually outgrew the epithelial elements originally dominant in the tumor and the final result after many transfers was the alteration of a carcinoma into a sarcoma.

Flexner and Jobling¹ observed the reverse process, in which a tumor of a white rat originally regarded as a sarcoma from its morphological appearance altered gradually into an adenocarcinoma, and finally into a pure carcinoma of remarkable vitality and virulence. In the original tumor, it is true, there were a few epithelial areas, so that the epithelium only overgrew the connective tissue. Such changes in tumor types have not been noticed in man, but probably would occur if transplantation through a long series could be carried out. The phenomenon is probably of the same order as that observed in man when a carcinoma or sarcoma develops from normal cells in an otherwise healthy person following trauma or chronic irritation. As a rule, such variations in the general morphology of the tumor and in the histological characters of the cells are more frequently noted than are alterations in purely biological qualities, if the experimental transplantation is carried out in a constant environment; that is, by inoculating a series of animals originating from the same stock and of the same age, weight, etc. This power of histological variability appearing while external influences are excluded, suggest that the phenomenon may be similar in its nature to those variations from the normal which have given the cancer cell its peculiar biological qualities of independent and progressive reproduction. In other words, the changes observed in the transplanted tumors of animals are no greater from the quantitative point of view than the changes from the normal to the tumor cell.

It has been found, furthermore, that the virulence, marked by the proportion of "takes" in the transplantations may be greatly enhanced as the successive implantations succeed, so that while at first implants of the original spontaneous mouse tumor may be successful in a ratio of not more than two or three in a hundred, after several generations of transfers, success is obtained in over 90 per cent. or even 100.

The factors influencing this increase in virulence are: 1. The selection of a suitable locality for the implantation, usually the axilla. 2. The implantation of tumors which have grown for a long period, rather than beginning tumors. 3. The selection of material from those series of transplants giving the highest percentage of takes. 4. Preliminary heating of the tumor to 45° C. which in some cases increases the virulence. 5. Growing the tumor in a particularly suitable variety of the animal species from which the original growth was obtained.²

Artificial Immunity to Tumors.—The early claim that by the adaptation of animals to the killed cells of malignant tumors of the same animal introduced beneath the skin, an active immunity can be secured, so that the animals thus protected give negative results in attempts to implant virulent strains of tumor cells, has not been substantiated. Neither has it been possible to obtain an immunity by the injection of serum from other animals of the same species having a natural or acquired immunity against a similar tumor. Nor has it been possible to obtain immunity by the inoculation of the unaltered juice obtained by expressing the cancer cells at high pressure or by extracting the proteids of the cells by various solutions, or by altering their quality by chemical or physical methods, though such immunity has been claimed. Many similar claims are vitiated by lack of care in obtaining suitable experimental conditions as to a pure strain of animals, size of dose of tumor cells used to test the hypothetical immunity, etc. Apparently nothing short of the living tumor cell is capable of producing a true immunity. Ehrlich has, by injecting mice with living cells of slightly virulent strains of mouse carcinoma, produced an active immunity, and has further determined that this immunity is not strictly specific but may protect against mouse sarcoma also.

Regression of tumors already inoculated, which is quite a different phenomenon from immunity, may be obtained by a number of procedures. Among these may be

¹ Jour. Am. Med. Assn., 1907, xlviii., 420.

² It has been repeatedly observed that mice and rats of different strains or from different parts of a country show marked differences in susceptibility to inoculation with the same tumor under precisely similar conditions.

enumerated (a) preliminary inoculation of the animal with embryonic tissue of various organs or the blood of homologous species; (b) treating the tumor cells before injection with serum from a recovered animal; (c) inoculating the animal and then re-inoculating with a fresh tumor after the first growth has started; (d) transfusion of large quantities of blood from an animal which has recovered from inoculation into an animal with actively growing tumors.

In this case there is an actual immunization produced in the original tumor host by transfusion of immune blood; but a similar transfusion into a suitable animal free of tumors at the time the transfusion is made confers no immunity to subsequent inoculation. Apparently there must be some interaction between the tumor and the body fluids by which the regression is started, and then an immunization of the animal results, owing to the live tumor cells already present in the body. The interesting results obtained by Hodenpyl¹ in causing temporary regression of tumors by injecting large quantities of serum from a case of active carcinoma are to be placed in this category.

It would be premature to assume that because inoculated tumors can be checked by the introduction either of tumor or of normal tissue cells, a similar procedure would be successful in the cases of spontaneous cancer, the type with which we have to deal in the human being. Here the problem is quite different. Animals in whom immunity has been induced may develop spontaneous and rapidly fatal tumors. Again, animals in whom spontaneous tumors have developed show no such immunity as may be developed against inoculated growths, in fact can often be successfully inoculated with their own tumor, a condition not infrequently observed in the contact transplantation seen on adjacent mucous surfaces. In man also instances have been noted in which after the removal of a small tumor, say an epithelioma of the lip, a virulent carcinoma of some organ has developed later. Such examples show that we still are far from being able to produce a sufficiently high degree of immunity to check the growth of spontaneous tumors. That such a possibility is not beyond reach, however, is suggested by the prolonged period, even years, of quiescence occasionally observed in metastases after removal of the primary growth, and in the rare but undoubted instances of a spontaneous cure.

The Method of Transplantation of Carcinoma and Sarcoma in Mice.

The method adopted by Ehrlich is essentially as follows:

The mouse in which a spontaneous tumor is found is beheaded with stout shears, and the whole body is placed for several minutes successively in strong alcohol, then in a 1 : 1,000 and afterward in a 1 : 2,000 sublimate solution. The animal is then washed in alcohol, stretched on a sterile board, and the tumor is dissected out with sterile instruments. The tumor is now cut into as small fragments as practicable by the use of scissors and forceps. These fragments are put in a sterile mortar and, without the addition of any fluid, rubbed with a glass rod into a thick pulp.

The implantation is made with glass tubes drawn at one end to a stout capillary and protected from the mouth above with a cotton plug. Other forms of cannulae may be used. The seat of implantation is the axillary fossa, but the point of the cannula is carried beneath the skin in the abdominal region—at a place which has been shorn and washed with alcohol—and then thrust along into the axilla, where a small amount of pulp is deposited.

The entire performance should be carried on with strict asepsis. The operator must be prepared to find that with the best technique transplantations of spontaneous carcinomata or adeno-carcinomata of mice will give a large proportion of failures. Thus Ehrlich found that in attempts to transplant ninety-four spontaneous tumors, he was successful in only about 2.8 per cent. In those strains of tumors which were successfully transplanted successes ranged from three to fifty per cent. of all the animals tried. However, it will be found, according to the experience of Ehrlich and others, that in a certain number of tumors the transplantation having been once achieved, the successes in later transfers may become proportionally far more numer-

¹Hodenpyl. Medical Record, 1910, lxxvii., 359.

ous, so that the tumor may be said to increase in virulence by its adaptation to new successive hosts.

This end is most readily attained by transplanting the entire mass of the spontaneous tumor in small portions in different animals, and selecting for further transfer the tumors which have developed earliest in the different mice. In this way it is possible to achieve a virulence far exceeding that of any spontaneous malignant tumor of the mouse.

Classification of Tumors.

It is not possible to-day to make a satisfactory scientific classification of tumors; but the fact that they are composed of structures which resemble the various morphological types of tissue found in the normal body suggests a grouping of the various forms which may be regarded as a useful and suggestive catalogue.

It should be remembered that the usual separation of the normal tissues into groups is useful, rather because it facilitates their study than because it expresses absolute and fundamental distinctions; and the same may be said of all the classifications of tumors. An increase of our knowledge concerning their structure and genesis will doubtless lead to a more accurate grouping of tumors; but for the present such an arrangement as that indicated below will be found of practical value for the purposes of study.¹

CONNECTIVE-TISSUE TYPE.

<i>Normal Tissue.</i>	<i>Tumors.</i>
Fibrillar connective tissue.	Fibroma.
Mucous tissue.	Myxoma.
Embryonal connective tissue.	Sarcoma.
Endothelial cells.	Endothelioma.
Fat tissue.	Lipoma.
Cartilage.	Chondroma.
Bone.	Osteoma.
Neuroglia. ²	Glioma.

MUSCLE-TISSUE TYPE—MYOMATA.

<i>Normal Tissue.</i>	<i>Tumors.</i>
Smooth muscle tissue.	Leiomyoma.
Striated muscle tissue.	Rhabdomyoma.

¹ The attempt has often been made to classify tumors with reference to the developmental history of the tissues represented, and it has been generally believed that cells once differentiated in the primary embryonic layers cannot again be merged in type. While this principle holds good in general, especially for highly differentiated forms, certain recent studies have seemed to indicate that even this distinction may not be inflexible. However this may be, it is certain that the cells derived from one embryonic layer may under special conditions come so closely to resemble in morphology those of another layer that a structural differentiation, with our present resources at least, is not always possible. While, therefore, this, which is called the *histogenetic principle of classification*, is most suggestive and may be useful in connection with other data in the study of tumors, it seems to the writer that it is wiser for the present not to base our classification too largely upon embryological data in several particulars still subject to controversy.

Consult in this connection the *résumé* of *Marchand* on "The Relationship between Pathological Anatomy and Embryology," *Verh. d. deutschen path. Gesellschaft.* Bd. ii., p. 38, 1900.

See also the admirable address by *Minot* on "The Embryological Basis of Pathology," *Science*, March 29th, 1901. In this paper, p. 487, the tissues are classified in accordance with their genetic relationships.

² The neuroglia, as well as the tumors derived from it, presents marked peculiarities in structure. While the neuroglia is closely related in genesis to the nervous system, being of ectodermal origin, its structural and functional alliance with the connective tissues of the mesoderm seems to the writers to justify for the present purpose its grouping among the latter. See ref. to *Mallory*, foot-note, p. 388.

NERVE-TISSUE TYPE—NEUROMATA.**VASCULAR-TISSUE TYPE—ANGIOMATA.**

<i>Normal Tissue.</i>	<i>Tumors.</i>
Blood-vessels.	Angioma.
Lymph-vessels.	Lymph-angioma.

EPITHELIAL-TISSUE TYPE.

<i>Normal Tissue.</i>	<i>Tumors.</i>
Glands.	Adenoma.
Various forms of epithelial cells and associated tissues.	Carcinoma.

Tumors Formed by Various Combinations of Tissue Types.—Mixed Types.

In a considerable proportion of tumors more than one type of tissue is present, and it is customary to indicate this by compound names, such as *osteo-sarcoma*, *adeno-carcinoma*, etc. Discrimination is necessary in the use of such names, however, and one should be clear as to what he wishes to express in this way. All tumors have a certain amount of fibrous stroma which carries the blood-vessels and forms a sustaining framework. In the early stages of tumor growth this matrix may be the tissue in which the tumor starts, which is either not increased in amount or is hyperplastic. Thus in carcinoma of the stomach, the stroma may be fibrous in the mucosa or composed of smooth muscle if the stomach wall be involved; but such growths would not be called either fibro-carcinoma or myo-carcinoma. It is only when the new tissue assumes the characters of an independent growth that it can be justly indicated in the compound name. This may not be easy or always possible to determine, but the desirability of doing so should be held constantly in mind. Unfortunately the compound name is by some writers used to indicate simply the seat of a tumor growth; in this sense *osteo-sarcoma* means simply sarcoma of the bone and not an association of osteoma and sarcoma.

It should also be remembered in this connection that a tumor of mixed types does not always, perhaps not often, start as such, but may assume this character by metaplasia (see p. 62) within the limits of a tissue group. Thus the establishment in fibroma of bone or cartilage growth and the assumption by the adenomata of the carcinomatous type are common. Furthermore, although these mixed forms of tumors may arise secondarily by metaplasia, the more or less distinct forms of tissue may finally become so independent of one another that some of the metastases from such a mixed tumor may show only one tissue type. The possibilities in tissue metaplasia should be taken into the account before assuming, as is too often done, that the multiplicity of related tissue forms in a tumor point toward embryonal origin.

Complex Congenital Growths—Teratoma.

These are tumors which frequently contain a great number of different forms of tissue, such as various forms of fibrillar connective tissue,

cartilage, bone, teeth, hair, skin, muscle, and glands. They are formed in the ovary, testicle, mediastinum, brain, in the sacral region,¹ about the neck, in the retroperitoneal tissue, etc. They arise by an inclusion of portions of another foetus, and are thus rather malformations than tumors in the limited technical sense. But they may give rise to tumors, some of them malignant: such are chorion-epitheliomata and sarcomata. Among these are sometimes classed other and simpler congenital anomalies, such as dermoid cysts, congenital angiomata, and the so-called pigmented nævi or moles.²

Special Tumor Types.

There are types of tumors which are not readily brought into the usual general classifications, since they are formed of special kinds of tissue. These have received distinctive names. Thus there are peculiar tumors formed of placental tissue called *chorion-epithelioma* or *deciduoma*; of tissue resembling the adrenals, *hypernephroma*, etc.

Lubarsch's Grouping of Tumors for Practical Purposes.

Lubarsch has suggested the following grouping of tumors for practical purposes, without special reference either to their histogenetic or histological characters:

1. Tumors which, although differing from the tissues in which they originate in the arrangement of their elements, usually increase in size but slightly or temporarily. In this group are the teratoid growths and those originating in embryonic displacements, such as congenital nævi, certain gland-like tumors, myoma, fibroma, lipoma, chondroma, and osteoma. Such tumors are usually of little practical importance.

2. Tumors which, although conforming in general to the normal tissue type in growth and structure, still reveal a considerable independence of their surroundings; such are larger myomata, adenomata, angiomata, lipomata, which may grow slowly and with interruptions, and may when growth ceases through degenerative processes or necrosis undergo retrogression or even disappear altogether.

3. Tumors which seem to be largely emancipated from the usual physiological control of normal tissues, both in the rapidity and extent of growth and in the fixity of the cell type in form and function. In this class are the tumors which are destructive and invasive in their growth, especially the sarcomata and carcinomata.

These three classes may in reality be considered to represent only stages in the growth of tumors in general; since the more destructive forms may in early stages conform to the characters of the other groups, while, on the other hand, tumors of the less aggressive types may assume the autonomy and significance of the malignant forms. These classes of tumors are not of course distinct, and many intermediate types may occur, but this grouping seems to the writer fairly to indicate a real difference in character and significance in tumors as a whole which it is of practical advantage to recognize, and which is often lost sight of in the more technical classifications.

Cysts.

These structures, for the sake of convenience, are often classed among the tumors, although in general characters, structure, and genesis they are usually of entirely different nature.

¹ For a critical summary, with bibliography, of tumors of the sacral region see *Borst*, *Centralbl. f. Path.*, Bd. ix., p. 449, 1898.

² For the relationship of teratoma to other malformations see p. 334.

They may be divided into two classes:

- I. Cysts which develop from pre-existing cavities.
- II. Cysts which originate independently as the result of pathological changes.

I. CYSTS WHICH DEVELOP FROM PRE-EXISTING CAVITIES.

1. **Retention Cysts.**—These are chiefly formed by the accumulation in glands or their secretory ducts of the more or less altered secretion of the gland. They usually occur as the result of a hinderance to the normal discharge, as from inflammatory contractions, pressure, etc. The contents of such cysts are usually mucous, sebaceous, serous, or of a mixed character. Their walls are the more or less altered walls of the original structure. To this class belong comedones, milium, atheroma, chalazion, ranula, the ovula Nabothi, milk cysts, and certain serous cysts of the ovaries, Fallopian tubes, gall-ducts, and uriniferous tubules.

2. **Transudation Cysts.**—These arise usually, though not always, as the result of a chronic inflammatory process in lymph-spaces or serous sacs, and among them are to be classed the so-called ganglia, hydrocele, etc. Certain of the so-called hæmatoceles, in which blood is extravasated into closed cavities, form a variety of the cysts of this group.

II. CYSTS WHICH ORIGINATE INDEPENDENTLY AS THE RESULT OF PATHOLOGICAL CHANGES.

1. **Cysts Formed by the Softening and Disintegration of Tissue.**—Such cysts may at first be small and have very meagre contents and no well-defined wall. A wall may finally be present either as an entirely new-formed structure, or the more or less modified capsule of the organ in which they occur may partly or entirely form the wall. The contents of such cysts are usually the more or less altered detritus of the tissue by whose disintegration they are formed. Such cysts are very apt to occur within true tumors, particularly those which are succulent and of rapid growth, since these, as above stated, are very liable to degeneration. Old abscesses may change into well-defined cysts of this kind.

2. **Cysts Formed around Foreign Bodies.**—The inflammatory reaction induced by the presence of foreign bodies of various kinds, parasites, masses of extravasated blood, etc., frequently results in the formation of well-defined encapsulated cysts.

3. **Cysts Formed by a New Growth of Tissues in Whose Spaces Various Kinds of Fluid Accumulate.**—These spaces may or may not be lined with epithelium and have something of the glandular character. Such forms are exemplified in some of the compound ovarian cysts—the so-called ovarian cystomata; but these are really adenomata.

4. **Congenital Cysts.**—These are of various forms, and their mode of origin is in most cases but imperfectly understood. Some of them are properly grouped among the teratomata. The so-called dermoid cysts of the subcutaneous tissue (Fig. 196) and ovary are marked examples of this class. The dermoid cysts of the skin are probably all formed

from an embryonal displacement of the epidermal structures. The simplest forms, called *epidermoid* cysts, are lined with epithelium of the squamous type and largely filled with a mass of flat desquamated cells. In the more complicated forms, hair follicles, and sebaceous and sweat glands are present in the lining epidermal membrane. Certain congenital cysts of the kidney and other internal organs are conveniently grouped here, although it is probable that some of them at least originate during

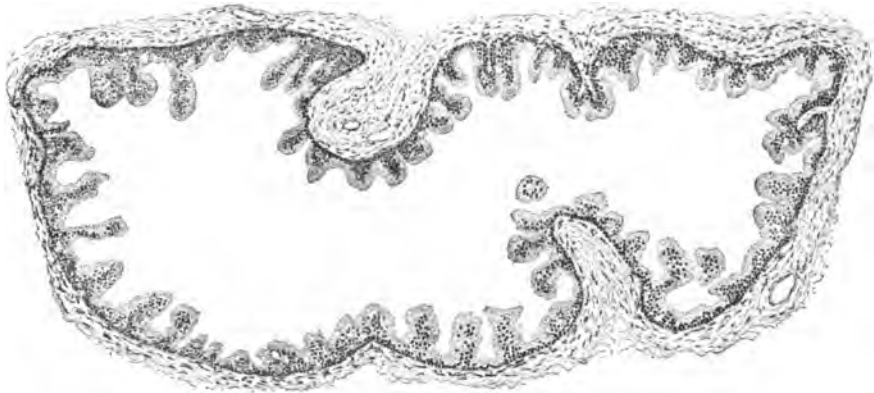


FIG. 196.—DERMOID CYST OF THE SKIN.

This small cyst beneath the skin above the eyebrow is lined with epithelial cells, in places cuboidal in form, but mostly merged into an irregular cell mass. The fibrous-walled cyst contained a clear fluid and a little granular cell detritus.

fœtal life in one or the other of the above-described ways, and hence are not essentially different in nature from some of the cysts of other classes. For the mode of formation of certain cysts of the neck see page 647.¹ For cysts of the viscera see Special Pathology.

Various Lesions Sometimes Described as Tumors.

There are certain enlargements of the lymph-nodes which are in reality hyperplasias, sometimes inflammatory in character and sometimes not, and which are often grouped among the tumors as *lymphomata*. They are not true tumors, and will be considered under the lesions of the lymph-nodes. In the same group are often classed the enlargements of the lymph-nodes in leukæmia and in other general diseases, which are considered in another part of this book.

Another group of tumors sometimes called lymphomata are in reality sarcomata, and these will be described under the latter heading.

There is also a group of nodular new formations, the so-called "*infective granulomata*," which in earlier days were classed among the tumors. These are found in tuberculosis, lupus, leprosy, syphilis, glanders, actinomycosis, and probably include the nodes of Hodgkin's disease. They are, however, inflammatory new formations, and as our knowledge regarding them has increased, many of them have proven to be incited by plant parasites (see section devoted to Infectious Diseases).

¹ Consult for consideration of ciliated and other cysts Hess, Ziegler's Beitr. zur. path. Anat., Bd. vii., p. 98, 1890; also Zahn, Virch. Arch., Bd. cxliii., p. 170, 1896. For later general bibliography of cysts see Aschoff, Lubarsch and Ostertag's "Ergebnisse," Jahrg. ii. for 1895, p. 456.

Technique of Fixation and Hardening.

In general, tumors, like all tissues for microscopical study, should be cut into small pieces before immersing them in the preservative fluids, and the sooner they can be placed in these after removal the better will be the preservation. For study of the finer details with Zenker or other special fixatives the material must be preserved within an hour after removal at operation. In some cases much may be learned from large sections of tumors together with their surrounding tissues. In this case the suitable portion of the tumor must be preserved whole, and is best fixed in 5-per-cent. formaldehyde followed by alcohol.

It is often important in the study of tumors to examine not only the fully developed or mature tumor structures, but also those portions in which the new growth is forming and in which it is encroaching on adjacent parts.

So that in selecting portions of tumors for preservation and study, it is not wise to snip off a small piece at random, but a careful selection should be made, liberal portions being saved from the centre, from the periphery, and from such surrounding tissues as are available. For the ordinary routine hardening of tumors, Orth's or Zenker's fluid followed by alcohol may be recommended.

Special Forms of Tumors.

FIBROMA.

The fibromata are composed of fibrillar connective tissue, which, as in the physiological type, is sometimes dense and firm, *Fibroma durum*, and sometimes loose in texture and soft, *Fibroma molle*. They are usually sharply circumscribed and are frequently encapsulated, but they may be diffuse and merge imperceptibly into the surrounding tissue. They are frequently small and insignificant, but occasionally grow to an



FIG. 197.—DENSE FIBROMA OF ABDOMINAL WALL—FIBROMA DURUM.

Some of the bands of connective-tissue fibres are cut across, others are cut lengthwise.

enormous size. Some fibromata consist almost entirely of intercellular substance, containing but few flattened or spindle-shaped cells (Fig. 197); others contain very many variously shaped cells (Fig. 198). The cells are often more abundant in one part of the tumor than in another. The denser varieties usually contain but few blood-vessels, although they are occasionally quite vascular. Many of the softer varieties are very vascular. Nerves are occasionally present.¹ The course and arrangement of the fibres in these tumors are usually irregular; they often cross and interlace in a most complex manner. The fibromata are usually of slow growth, but exceptionally they grow rapidly. They are benign tumors, but by pressure on important organs, by ulceration, or by changing into other varieties of tissue they may become of serious import. Pure fibromata do not form metastases, but they are often multiple, and when so are frequently congenital. They may recur when not fully removed.

It seems probable that in the multiple fibromata of the skin (*Fibroma*

¹ For a study of elastic and reticular tissue in tumors see Baldwin, "Vaughan Anniversary Contributions," 1903, p. 495. For fibroglia fibrils see Mallory, Jour. Med. Res., vol. xiii., p. 113, 1905.

molluscum) the new growths occur in some special form of connective tissue, as that of the nerves, blood-vessels, or glands. Some of them are




FIG. 198.—FIBROMA MOLLE; FROM THE SUBCUTANEOUS TISSUE.
The stroma is oedematous, and in gross appearance the tumor resembled myxoma.

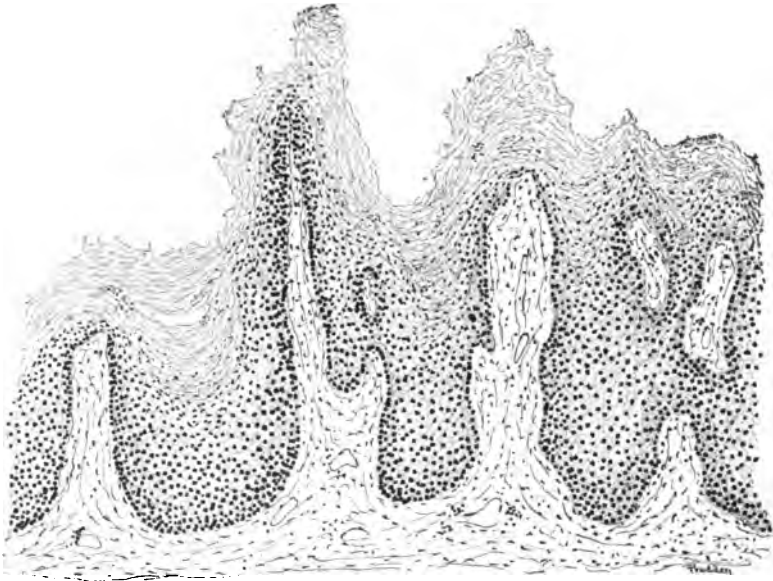


FIG. 199.—SMALL PAPILOMA OF THE SKIN.

congenital. There is often a growth of very cellular tissue just beneath the epithelium. Such tumors resemble sarcoma.¹

While the fibromata are commonly nodular in form, when they

¹ See *Gilchrist*, Johns Hopkins Hosp. Rep., vol. i., p. 349, 1896.

develop on the skin or mucous membranes they frequently form papillary outgrowths covered more or less thickly with epithelium, and are then called *papillomata* (Fig. 199). Common warts of the skin are papillomata with excessive production of surface epithelium. To the papillomata also belong some of the so-called condylomata.

The so-called *cheloid*, composed of very dense fibrous tissue with few cells, often develops rapidly in old cicatrices, or elsewhere, in the skin, forming flat or slightly lobulated tumors. It is not in all cases clear whether cheloids should be regarded as tumors or as inflammatory new formations.

Fibromata are frequently combined with other kinds of tissue to form complex tumors. The looser, softer varieties not infrequently become

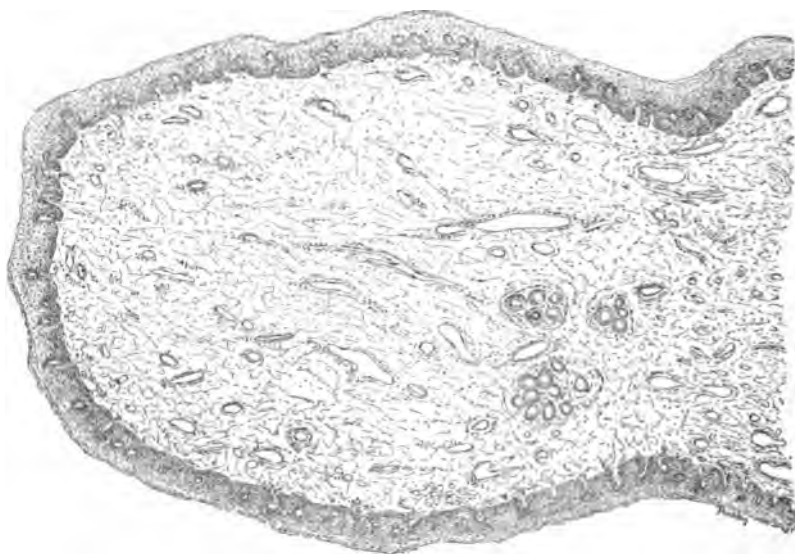


FIG. 200.—MUCOUS POLYP OF THE NOSE.

The section shows the epithelial covering of the new growth, as well as its numerous blood-vessels and a few mucous glands.

œdematous, when they may closely resemble myxomata (Fig. 198). Fibromata are liable to calcification and to fatty and mucous degeneration. By metaplasia they may partially change to form fibro-chondroma, fibro-lipoma, fibro-sarcoma, or fibro-osteoma. The latter transformation frequently occurs when they form in the periosteum.

Developing, as they do, in the connective tissue, fibromata occur in the various parts of the body: in the skin and subcutaneous tissue; in intermuscular tissue and fasciæ; in periosteum; in the nerve sheaths and intrafascicular connective tissue; in the dura mater; the interstitial tissue of organs; and in the mucous membranes. Some of the so-called polypi of the mucous membranes (see Fig. 200) and some psammomata are forms of fibroma; the former are often soft and œdematous. A type of

hard encapsulated fibroma occurring in the abdominal wall has received the clinical name of *desmoid*.

Occasionally, in the ducts of glands, fibrous polypi grow to an enormous extent, their epithelial covering keeping pace in growth with their development, until they form very large, irregular, loose-textured tumors, which often finally ulcerate. Such forms are seen in the mammary gland, where they are sometimes mistaken for carcinomata. They are called *intracanalicular fibromata*, or perhaps more correctly *fibro-adenomata* (see Fig. 587, p. 847).

It is often very difficult to distinguish between genuine fibromata and inflammatory or other connective-tissue hyperplasias, such as elephantiasis; and perhaps the fuller knowledge of the future will show that the distinctions are not as definite as our classifications indicate.

MYXOMA.

Mucous tissue is essentially an embryonic tissue, for in the normal adult it is present only in a very imperfect and atypical form in the vitreous of the eye, and perhaps exceptionally in small amount about the heart, kidneys, and medulla of bone.

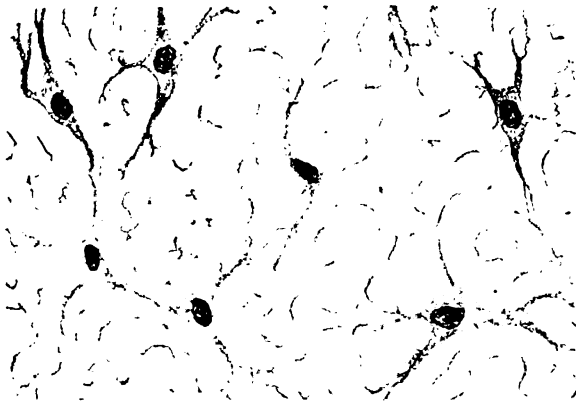


FIG. 201.—MYXOMA OF THE LARYNX.
Showing the diffuse staining of the mucin-containing stroma with hæmatoxylin.

The myxomata are thus essentially embryonic-tissue tumors. These tumors consist, in their most typical forms, of a homogeneous or finely fibrillated, soft, gelatinous basement substance, in which are embedded a variable number of spheroidal, fusiform, branching, and often anastomosing cells (Fig. 201). They may contain few or many blood-vessels and sometimes nerves. By the addition of acetic acid, mucin may be precipitated from the basement substance. In sections it is usually stained with hæmatoxylin. The very soft forms which contain comparatively few cells and much translucent basement substance are called *Myxoma gelatinosum* or *M. molle*. The presence of many cells renders

them more consistent and gives them a whiter and more opaque appearance; such forms are called *M. medullare*.

Pure myxomata are very rare. The myxomata are very apt to be combined with fibrillar connective tissue as *fibro-myxoma*; or with fat tissue, *lipo-myxoma*; or take part in the formation of very complex tumors. Most of the tumors regarded as myxomata are really of a sarcomatous nature, but such structure may only be evident in small areas of the tumor and therefore is frequently overlooked. The myxomata may be diffuse or encapsulated with fibrillar connective tissue; they are frequently very large, and may be multiple. Owing to the character of the basement substance, the blood-vessels not infrequently rupture, giving rise to larger or smaller hæmorrhages within the tumor, or to the formation of cysts. The cells are liable to undergo fatty degeneration.

In the fibrous tissue of many tumors, in chronic inflammation of the mucous membranes, variously shaped small cells occur whose bodies contain few or many well-defined basophile granules which are not infrequently mistaken for cocci. Such cells, called "clasmatoocytes," occur in various parts of the normal body and resemble in some aspects the "mast" or basophile cells of the circulating blood but they are probably not identical. The nature of the granules has not been definitely determined. Eosinophile and plasma cells are also very frequent in the mucous tissue of nasal polypi.

Composed, as they are, of a type of tissue from which fat tissue is developed in the embryo, the relations of myxomata to fat tissue are very intimate. They are most frequently developed in, and probably directly from, fat tissue. They are also found in the subcutaneous, submucous, and subserous tissue, in the marrow and periosteum; in the brain and cord; in the sheaths and intrafascicular tissue of peripheral nerves; in intermuscular septa; and in the interstitial tissue of glands, such as the mamma and parotid.

The pure myxomata are in general benign; yet they are very prone, especially the lipomatous forms, to local recurrence. They sometimes grow very rapidly, and sometimes, though very rarely, form metastases. In the very frequent combination with sarcoma they may exhibit the most marked malignancy. Some of the polypi of mucous membranes are apparently myxomata or fibro-myxomata. On the other hand, many of the so-called mucous polyps, those of the nose for example, are simply oedematous hyperplasiæ of the mucosa.¹

Oedematous, loose, and cellular forms of fibrillar connective tissue so closely resemble some of the forms of mucous tissue that certain observers consider them identical. So prone are many tumors to undergo mucous degeneration, and so frequent are the combinations of the myxomata with other forms of tumors, that it is often difficult, sometimes impossible, to say whether the mucous tissue in a given composite tumor is primary or secondary.

SARCOMA.

These tumors are formed on the type of connective tissue, but they are, as a rule, largely composed of cells with well developed cytoplasm;

¹ See reference to *Wright*, p. 580.

the basement substance, though a constant and important factor, being much less conspicuous than in adult connective tissue. They more closely resemble, in general, the developing connective tissue of the embryo or the granulation tissue of inflammation.

The cells of the sarcomata are most varied in size and shape. They may be flat, fusiform, spheroidal, or branched, and even cuboidal or cylindrical; they may be multinuclear and very large, or they may be very small and spheroidal, resembling leucocytes. The fibrillar basement substance may be present in such small quantity as entirely to escape a superficial observation, covered as it may be by the abundant cells; or it may be so abundant as to give the tumor the general appearance of a fibroma. It may be intimately intermingled with the cells in

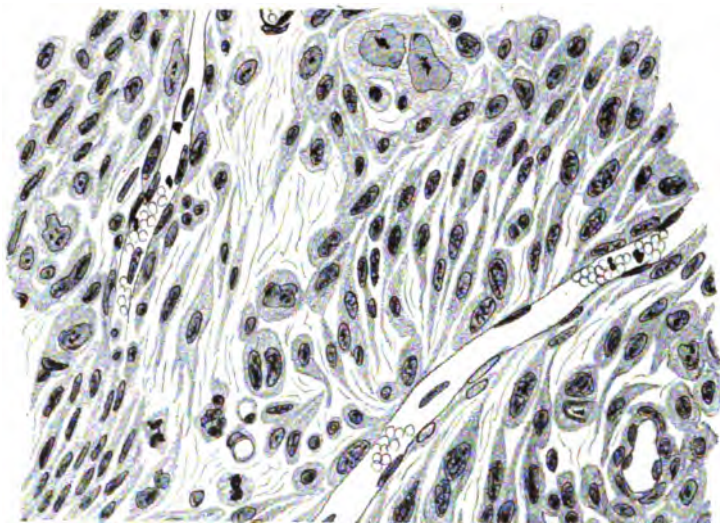


FIG. 202.—LARGE SPINDLE-CELLED SARCOMA.

fascicles, or it may be in large open-meshed networks, giving to the tumor an alveolar appearance. The cells, however, always stand in an intimate relationship to the basement substance, which they sometimes reveal by fibrillar processes continuous with it. Blood-vessels also form a constant and important structural element in these tumors, being in some of them so predominating a factor that they give structural outline and general character to the growth. They, too, as in the normal connective tissue, are intimately associated with the basement substance and with the tumor cells.

Sarcomata are most frequently found in the skin, subcutaneous tissue, fasciæ, subserous connective tissue, the marrow or periosteum, and in the choroid. They may also occur; though more rarely, in the dura mater; brain and cord; lymph-nodes; in the adventitia of blood-vessels, and in nerve sheaths; in submucous tissue; in the uterus and

ovary, and in the kidney. In the liver, pancreas, lungs, and heart they may occur, but usually by metastasis.

They are most common early in life. The cellular character, the rapid growth, the vascularity and succulence of many forms, the marked tendency to local recurrence, and the formation of metastases, stamp the sarcomata as malignant tumors. But in this they vary greatly; while some of the forms belong in every sense to the most malignant of tumors, others grow slowly, are very dense, and may remain localized and harmless for years. Their tendencies in this respect will be mentioned under the special forms.

Intimately related as they are to the blood-vessels, metastasis is more apt to occur through the blood than through the lymph channels, and consequently adjacent lymph-nodes are much less apt to be involved than in some other forms of tumor, notably the carcinomata. The richly cellular and vascular forms of sarcoma are especially prone to hæmorrhages, degeneration, and ulceration.

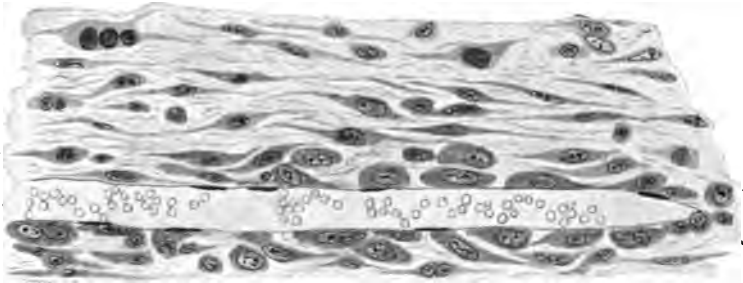


FIG. 203.—SPINDLE-CELLED SARCOMA.
Showing abundant cell growth near a blood-vessel.

A single form of cells is often so predominant as to furnish a suitable qualifying name for the tumor, but in many cases the cell form varies greatly in the same growth. It may be said, in general, that there is a tendency to reproduce in these tumors some of the special characteristics of the tissues in which they originate. Thus, sarcomata of the bones are apt to be osteo-sarcomata; those of pigmented tissue, like the choroid, are apt to be pigmented sarcomata. It will be more convenient for our present purpose to describe briefly the more common forms one after another than to attempt any systematic classification of them. It should be remembered, however, that the various forms are not sharply defined, but are apt to merge into one another and to intermingle in various ways.

Spindle-celled Sarcoma.—The cells in these tumors may be large—*large spindle-celled S.* (Figs. 202 and 203); or they may be small—*small spindle-celled S.* (Fig. 204). They may consist largely of cells, or may contain so much intercellular fibrous tissue as to be appropriately called *fibro-sarcoma*. The cells are frequently arranged in fascicles, which surround the blood-vessels, and these fascicles may cross and interlace,

while great variations may also occur in the relative proportions between cells and intercellular tissue in different parts of the same tumor. The spindle-celled sarcomata, especially the small-celled forms, are, as a rule, denser and firmer and less malignant than other forms of sarcoma, but to this there are many exceptions. They may be encapsulated or infiltrating. To this class belong the growths formerly described as

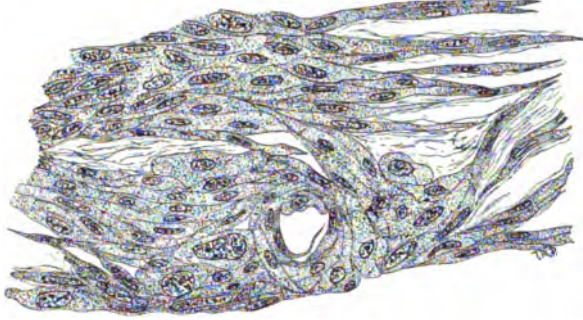


FIG. 204.—SMALL SPINDLE-CELLED SARCOMA OF FOREARM.

fibro-plastic tumors and recurrent fibroids. They most frequently occur in the periosteum, subcutaneous tissue, and muscle; but are also seen in the uterus, and in various glands, notably in the mamma, testicle, thyroid, etc. These forms are among the most frequent of the sarcomata.

Round-celled Sarcoma.—Of these there are two classes—1, *small round-celled sarcomata* and, 2, *large round-celled sarcomata*.

1. The small round-celled sarcomata consist of cells of about the size and appearance of mononuclear leucocytes (Fig. 205), and may have

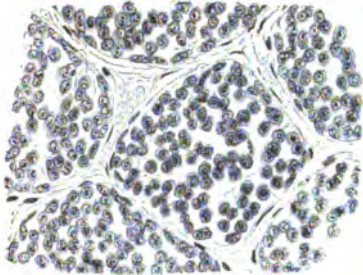


FIG. 205.—SMALL ROUND-CELLED SARCOMA.
From a metastatic tumor in the lungs.

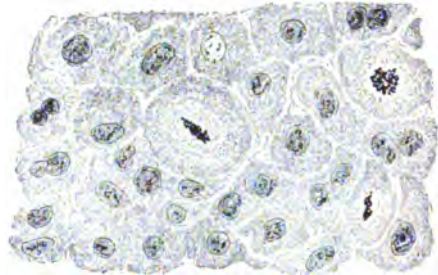


FIG. 206.—LARGE ROUND-CELLED SARCOMA.
A tumor of the mamma. Mitotic figures
in some of the cells.

much or little intercellular substance, which may be irregularly disposed or arranged in large meshes resembling alveoli. In many cases, so small is the quantity of intercellular substance that it is difficult of detection without special modes of preparation. These tumors often contain many blood-vessels, and may be very soft and succulent. Their growth is sometimes rapid and they are often very malignant.

They most frequently occur in the connective tissue of the muscles and fasciæ, in bone, and in lymph-nodes (*lympho-sarcoma* or *lympho-cytoma* [Ribbert]).¹ They also occur in the internal organs, not infrequently in the brain and retina, associated with cells of the glia type. Whether all the small round cells are glia cells or whether there is a

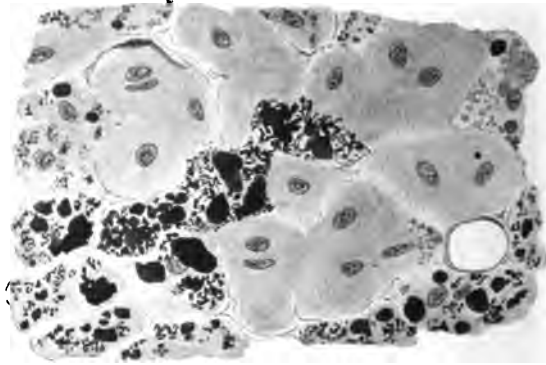


FIG. 207.—MELANO-SARCOMA.
Tumor from foot.

mixture of cells is not yet fully determined. Such tumors are generally designated *glio-sarcoma* (see p. 388).

2. In the large round-celled sarcomata (Fig. 206) the cells vary in size, but are usually very much larger than in the last variety. Their nuclei are usually large and contain prominent nucleoli. They, too, are

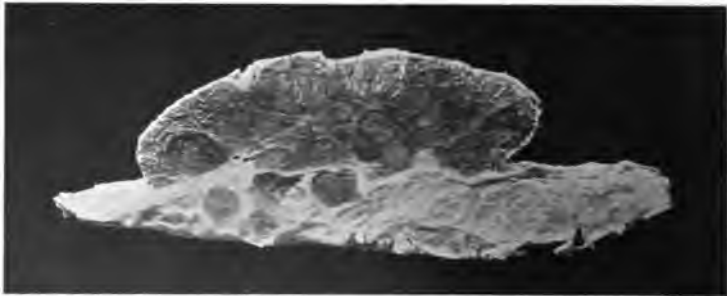

FIG. 208.—MELANO-SARCOMA OF THE SKIN, FUNGOID IN SHAPE.
A small nodule showing local extension is seen in the subcutaneous tissue beneath.

often very vascular, and contain a variable quantity of basement substance. They are occasionally alveolar in character. They are, as a rule, less soft and malignant than the small-celled varieties.

Melano-sarcoma.—These tumors consist most frequently of polyhedral cells of various sizes. They are characterized by the presence in

¹ For a study of so-called infectious lympho-sarcoma of dogs see *Beche and Ewing, Jour. Med. Res.*, vol. xv., p. 209, 1906.

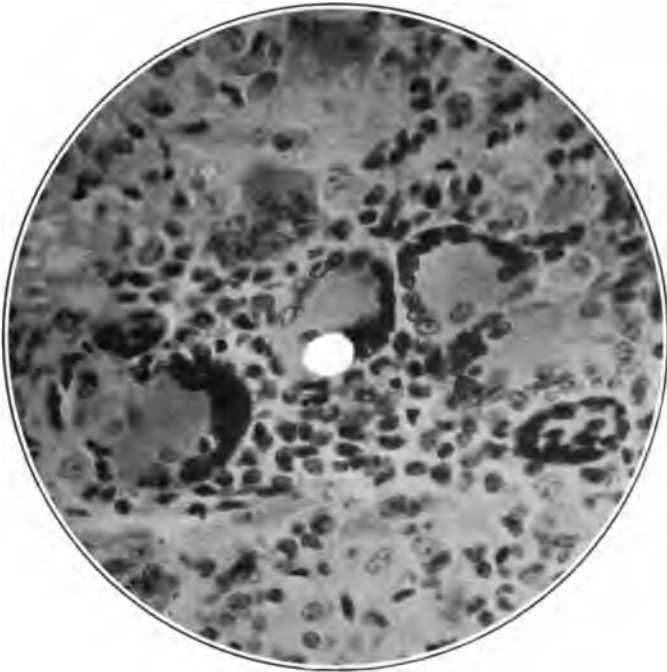


FIG. 209.—GIANT-CELLED SARCOMA OF FINGER.
Periosteal type.

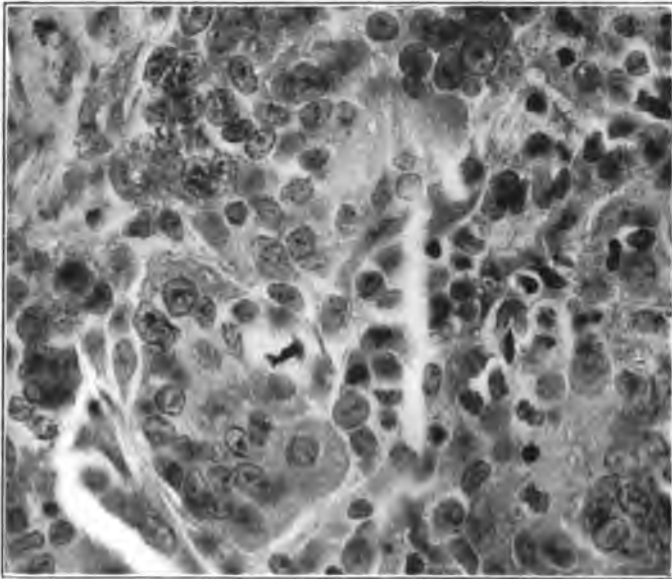


FIG. 210.—GIANT-CELLED SARCOMA OF SUPERIOR MAXILLA.
Fifth recurrence. Mitosis in giant cell.

the cells, and less frequently in the intercellular substance, of larger and smaller particles of brown or black pigment (Fig. 207). The pigment is usually quite irregularly distributed in patches or streaks. They arise most frequently in the skin (Fig. 208) and in the choroid. Pigmented moles of the skin often form their starting-points.¹ They belong to the most malignant of tumors. They very readily form metastatic tumors in various parts of the body, which are, like the parent tumor, pigmented.²

Various forms of tumors may contain brownish or yellowish pigment deposited in them by the degeneration of the hæmoglobin from extravasated blood; these should not be mistaken for melanotic sarcomata. The blood pigment is not as a rule so dark as that of the tumors and is generally included in phagocytic cells lying in the stroma of the tumor. Careful search will usually reveal crystal or needle forms, and occasionally an iron reaction can be obtained by heating sections with acid and potassium ferrocyanide.

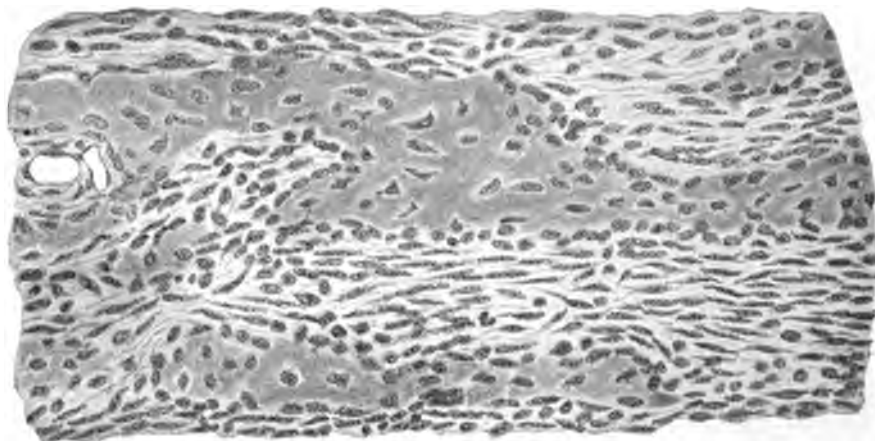


FIG. 211.—OSTEO-SARCOMA OF THE LEG.

Myeloid or Giant-celled Sarcoma.—Tumors of this class are usually formed chiefly of spheroidal or fusiform cells of variable size, but their characteristic feature is the presence of larger and smaller multinuclear cells, called giant cells. These are closely intermingled with the other cells, and may be very abundant or very few in number (Fig. 209). Giant cells may occasionally occur in other tumors, but are most abundant and characteristic in these. Mitotic figures may occasionally be seen in the nuclei of giant cells from the more rapidly growing and recurrent forms (Fig. 210). These tumors are chiefly formed in connection with bone, and may originate in the marrow or in the periosteum. They are sometimes very soft and vascular, and subject to interstitial hæmorrhages. Some of these vascular sarcomata were formerly classed

¹ For bibl. of multiple melano-sarcomata of the skin see *Wilson and Kaltefler*, *Amer. Jour. Med. Sci.*, vol. cxxvi., 1903, p. 751.

² On the occurrence of melanuria in cases of melano-sarcoma consult *Thacher*, *Trans. New York Path. Soc.*, 1893, p. 105.

together with other kinds of vascular tumors as fungus hæmatodes. Some of the forms of *epulis* are giant-celled sarcomata (Fig. 212).

When these tumors originate in the marrow of the long bones, which is a favorite place for them, they are apt to cause resorption of the bone; and although the tumor may be for a long time enclosed by a shell of new-formed bone, which enlarges with the enlarging tumor, it usually, sooner or later, breaks through this and infiltrates adjacent tissues. They may form metastases and frequently grow to a very great size, though relatively much more benign in nature than the other types of sarcoma. The giant celled sarcomata arising in the maxillary borders

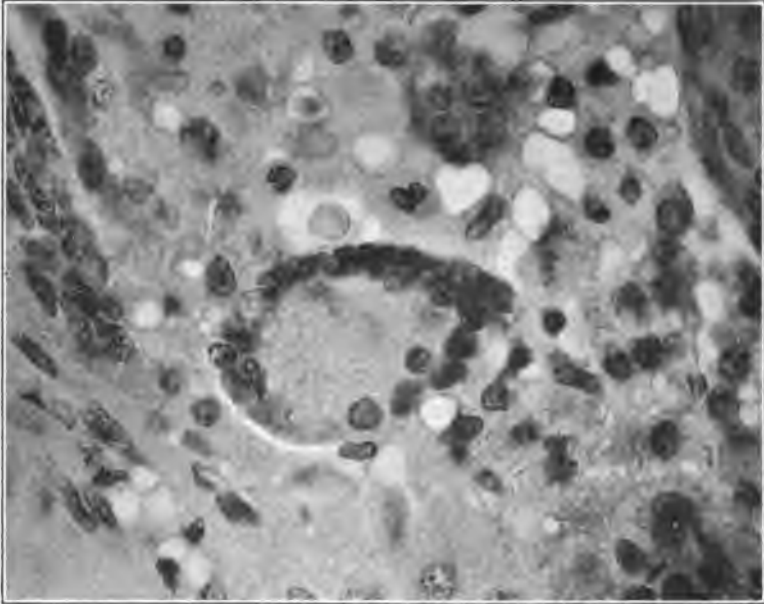


FIG. 212.—EPULIS OF THE GUM.

Showing the Langhans' type of giant cell as seen in these growths. Also the spongy soft connective tissue in which the cells lie. Numerous leucocytes and red blood cells are seen in the section.

(epulis) are generally quite innocuous if carefully removed. In one series only two recurrences were noted in seventy cases. If the excision is imperfect, repeated local recurrences may take place without metastases forming elsewhere in the body. The periosteal forms are apt to be firmer in texture, and are prone to the development of irregular masses of new bone within them, thus forming one of the varieties of osteo-sarcoma.

Osteo-sarcoma.—These are spindle- or round-celled tumors, usually, but not always, connected with bone, in which irregular masses of bone tissue are present. The bone is usually of irregular atypical structure, the regular lamellation and typical Haversian canals being usually absent (Fig. 211). Not infrequently calcification is very imperfect or

absent. The osteo-sarcomata are prone to form metastases, especially in the lungs, in which are present all the characters of the original growth.

Angio-sarcoma.—In many of the sarcomata in various parts of the body the blood-vessels form so prominent and important a feature as to give special character to the growth, not alone by their size and

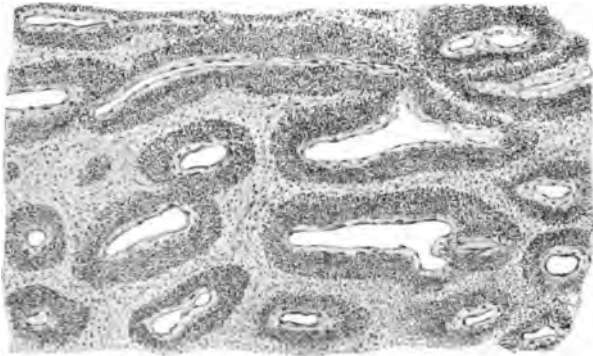


FIG. 213.—ANGIO-SARCOMA.
Tumor from the arm. Sometimes called perithelial sarcoma.

general prominence (Fig. 213), but sometimes by the peculiar arrangement which their presence gives to the cells. While in most of the sarcomata the blood-vessels have a very important influence in determining the topography of the tumor, in most of the denser and in many of the softer varieties this influence is not easily traced. In many forms, however, particularly those which are soft and very cellular, the cells are closely grouped around the vessels, developing in their adventitia

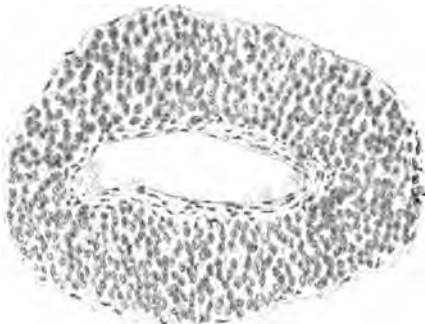

FIG. 214.—ANGIO-SARCOMA.
One of the blood-vessels with its cellular sheath
from the tumor shown in Fig. 213.

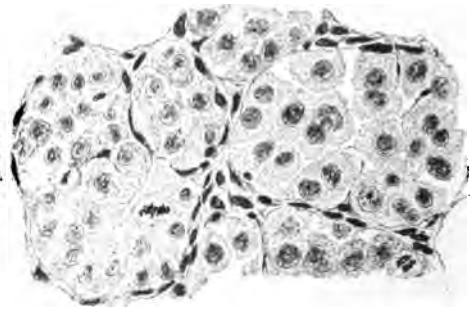


FIG. 215.—ANGIO-SARCOMA. ENDOTHELIOMA?
Tumor of lymph-node.

and forming sheaths around them (Figs. 213 and 214). The masses of cells thus formed, with a blood-vessel for a centre, may be closely packed together in long strings with more or less frequent anastomoses or they may be arranged in rounded groups, giving to the tumor an alveolar appearance (Fig. 215). Such tumors are called angio-sarcomata.

Simple vascularity, although this be extreme, does not make of a tumor an angio-sarcoma.

Alveolar Sarcoma.—Sometimes, as above stated, the basement substance of the sarcomata, particularly in some of the round-celled varieties, is quite abundant and arranged in a wide-meshed net, in the meshes of which the cells lie. These spaces are called alveoli, and this variety of structure has acquired importance from the general resemblance which these tumors have to the well-defined and characteristic alveolar structure which many of the carcinomata exhibit. It is true that occasionally the resemblance is very close indeed, but usually the sarcomata present a more or less intimate relation between the cells and basement substance. The cells usually do not simply lie in the cavities, but are often attached to the intercellular substance, which not seldom sends finer trabeculæ into the alveoli between the cells. A careful study of sections especially prepared to show the finer connective-tissue fibrils, by silver impregnation for example, may be required and sometimes a careful shaking of sections in water is necessary to reveal the characters



FIG. 216. — MYXO-SARCOMA OF THE PAROTID.

of the reticulum. The cells, moreover, are usually, though not always, distinctive in character. This form of tumor is, in some cases at least, determined, as above stated, by the new formation and peculiar arrangement of the blood-vessels. Tumors of this kind are not common, but may occur in the skin, lymph-nodes, bone, and pia mater. They are usually very malignant. Many of these tumors are doubtless more properly classed among the endotheliomata, while some, especially those from the skin and from the lymph-nodes of the neck are not improbably derived from epithelium left during embryonic development.

Mixed Forms of Sarcoma.—In addition to the above more or less well-defined forms of sarcoma, there exist various modifications which have received special names. The sarcomata in which cysts form, either by the softening of tissue by degeneration, or by the dilatation of gland ducts by pressure, or by the new formation of tissue in gland ducts or alveoli which dilate with the growth of the tumor, have received the name of *cysto-sarcomata*.

Mucous degeneration is frequent in the various forms of sarcoma. A combination of myxoma and sarcoma—*myxo-sarcoma*—is common (see Fig. 216).

Combinations of sarcoma with fat tissue, *lipo-sarcoma*; with glandular structure, *adeno-sarcoma* (Fig. 217); with cartilage, *chondro-sarcoma*; with muscle tissue, *myo-sarcoma*; and with various other tissues, are of frequent occurrence. Usually these accessory forms of connective or epithelial tissue structures play a subsidiary part in the metastatic activities of the growth, but in rare instances muscle fibres seem to obtain some of the powers of indefinite multiplication generally observed only in the less specialized forms of connective tissue, and tumors made up

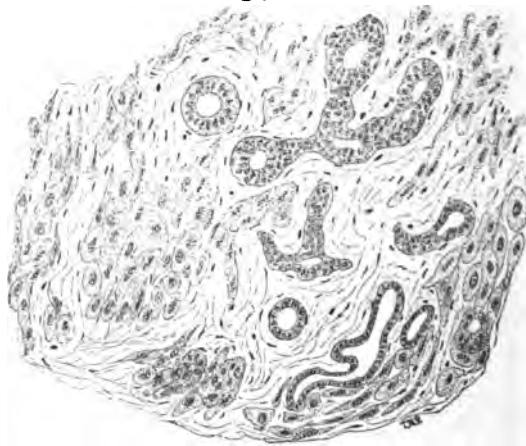


FIG. 217.—ADENO-SARCOMA OF PAROTID.

almost wholly of such fibres have been reported. This form of new growth is sometimes termed a malignant myoma but generally is classified as a myo-sarcoma.

Some forms of *psammoma*, or "brain-sand," found chiefly in the dura mater, are *fibro-sarcomata* or *endotheliomata*, which have undergone calcification, the lime being deposited in lamellated masses of various shapes within them.

Some of the soft papillomata and warts, and occasionally the polypi of the mucous membranes, belong to the type of sarcoma or myxo-sarcoma.

The so-called *chloroma* is a small round-celled growth characterized by its greenish color; it occurs with especial frequency in bone and is often multiple. The nature of the coloring material is uncertain (see p. 478).¹

A special type of sarcoma is one arising from the cells of the bone marrow, known as *myeloma*. The growth is usually multiple, occurring

¹For a discussion of the relationship of chloroma to blood pictures simulating certain types of leukaemia see Dock, Amer. Jour. Med. Sci., vol. cvi., p. 152, 1893, bibl., Sternberg, Lubarsch and Ostertag's "Ergebnisse d. allg. Path.," Jahrg. 9, Abth. 1903, p. 360; and Lehndorff, Ergebnisse d. inner. Med., 1910, Bd. vi., p. 221.

most frequently in the skull, vertebral column, and thorax, and leads to absorption of the bone. As a rule, in contrast to chloroma, no marked changes are seen in the circulating blood. For further details see p. 902.

ENDOTHELIOMA.

An endothelioma is a tumor derived from endothelium. It most commonly originates in the endothelium of the blood- or lymph-vessels or the lymph-spaces.

Tumors originating in the mesothelium of the great serous cavities, the pleural, pericardial, and peritoneal, are in many respects similar to those arising from the blood- and lymph-vessel endothelium, and we may therefore for the present group them among the endotheliomata, though it might, on some accounts, be better to call them mesotheliomata.¹ A certain proportion of the gelatinous tumors covering the surface of the peritoneum have been shown to arise from small primary growths of the ovary, the mucous membrane of the gall-bladder, or the gastro-intestinal tract; it is therefore important to exclude this particular group from the endotheliomata.

Endothelial cells are normally elongated and thin, forming a mosaic over the surfaces which they line. Under various abnormal conditions, however, in hyperplasia, in inflammation, and in the reparative processes, these cells may become thicker than normal, even cuboidal in shape.

So also in the endotheliomata, the cells seldom resemble the normal endothelium, but are cuboidal, polyhedral, or even cylindrical in shape, or on pressure may assume elongated, fusiform, or other bizarre forms. The cells in endotheliomata may form more or less distinct tubular structures, recalling their original function as lining cells, but they may be piled in several layers over one another with an open lumen here and there, or finally they may form solid reticular masses, scarcely to be distinguished on morphological grounds, with our present knowledge, from certain forms of epithelial-cell tumors—carcinoma.

The cell masses in endothelioma are enclosed by a varying amount of fibrous tissue, either old or new-formed. This stroma is often vascular and sometimes appears in places to consist almost wholly of vessels

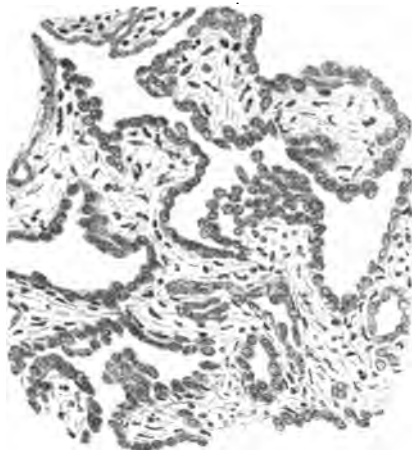

FIG. 218.—ENDOTHELIOMA OF THE THYROID GLAND.

Showing an early phase of cell proliferation in the lymph-spaces.

¹ For a study of the relationship between endothelium and mesothelium see *Minot*, *Science*, Mar. 29, 1901.

around which the tumor cells are packed, the whole resembling some of the forms of angio-sarcoma.

These tumors developing from the endothelium of the vessels or

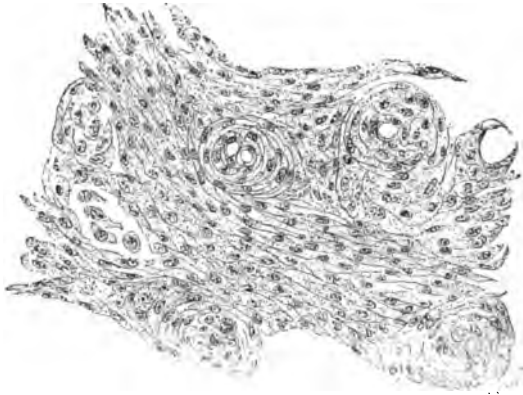


FIG. 219.—ENDOTHELIOMA (ENDOTHELIAL SARCOMA) OF DURA MATER.

lymph-spaces sometimes exhibit a structure closely simulating that of tubular glands lined with more or less cuboidal epithelium (Fig. 218). When originating in the blood-vessels these tumors are called *hæmangio-*

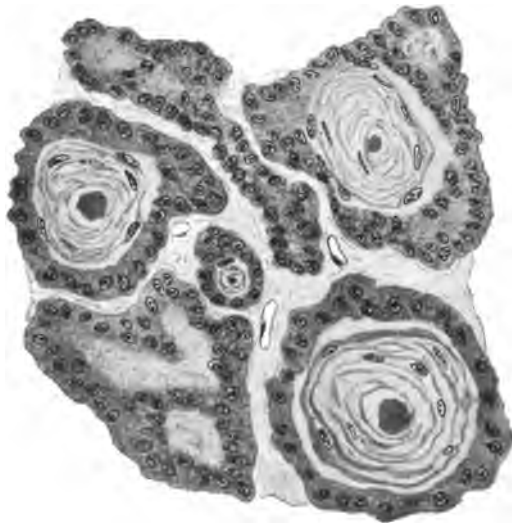


FIG. 220.—ENDOTHELIOMA OF DURA MATER.
Psammomatous form.

endotheliomata; when derived from the lymph-vessels they are called *lymphangio-endotheliomata*.

Sometimes the cells of the endotheliomata are packed together in dense concentric masses, which may have a glistening appearance, and

such tumors are sometimes called *cholesteatomata*.¹ Although, for the most part, the peculiar glistening appearance of these tumors is due to the closely packed thin cells which compose them, they not infrequently contain crystals of cholesterin, which may share in producing this characteristic appearance. But the cholesterin may be absent, or present in small amount.

In the dura mater endotheliomata are formed of densely packed masses of flattened cells (Fig. 219); or the cells, often polyhedral or cuboidal in shape, are grouped around blood-vessels (Fig. 227); or, finally, they develop in closely packed concentric masses forming one of the types of psammoma (Figs. 220 and 221).

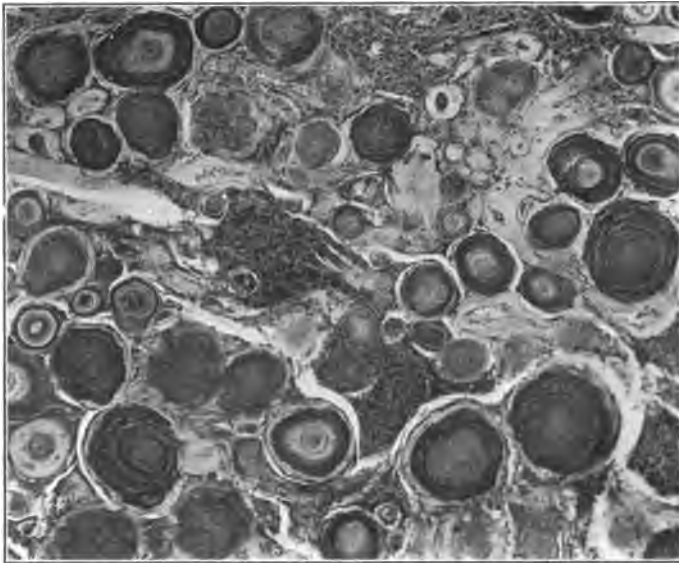


FIG. 221.—ENDOTHELIOMA OF DURA MATER.
Psammomatous form.

The stroma of the endotheliomata may undergo various forms of alteration, developing hyaline, myxomatous, or cartilaginous, or very dense fibrous characters (Fig. 222); or it may atrophy, leaving the proliferated endothelium and the blood-vessels as the chief structural elements. On the other hand, hyaline and mucous degeneration of the endothelial cells may occur (Fig. 223), and considerable collections of these materials, free from the cells but surrounded by the cell masses, may give a cystic character or lend a glandular appearance to the growth.

Such tumors—in which homogeneous or striated cylinders of hyaline or mucoid material (Fig. 224), often closely surrounded by layers of cuboidal or flattened cells (Fig. 225), form a striking feature—have

¹ It is believed by Bostroem, Ribbert, and others that the cholesteatomata are dermoid structures formed from displaced epidermal tissue. See *Bostroem*, *Centbl. f. allg. Path.*, Bd. viii., p. 1, 1897; *Ribbert*, "*Lehrb. d. allg. Path.*," p. 560, 1905

sometimes been called *cylindromata*. It is probable that some of the tumors included here belong more properly among the so-called basal-celled carcinomata (see p. 408).

The stroma of the endothelioma may become sarcomatous and thus a mixed tumor—a sarcomatous endothelioma—may be formed.

The endotheliomata may be single, nodular, and of considerable size; or they may be multiple, numerous small tumors being scattered over the surface of the part in which they grow. They may even form a thick or thin pellicle over surfaces, or cause adhesions between adjacent organs. They may form metastases.

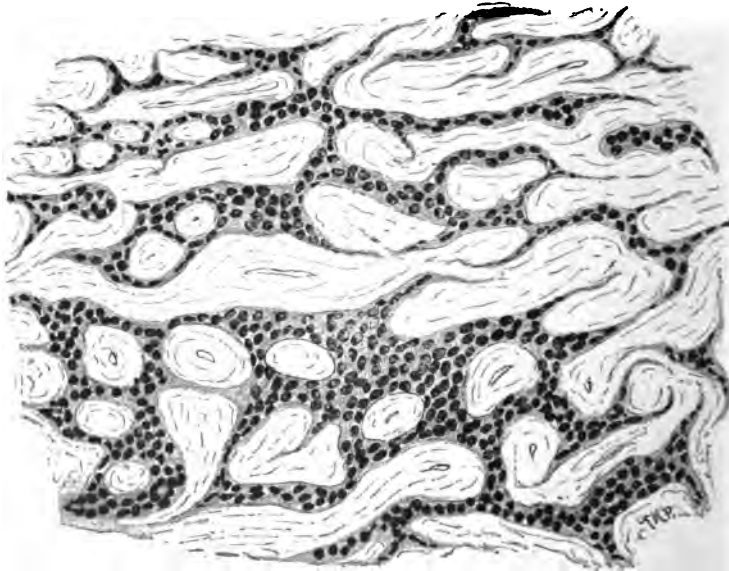


FIG. 222.—ENDOTHELIOMA OF UPPER JAW.

Showing dense connective tissue surrounding the blood-vessels between the reticular endothelial-cell masses.

They occur in the dura mater and pia mater, in the pleura and peritoneum, and tumors thus named have been described as occurring in the skin, bone, gums, lymph-nodes, ovary, liver, brain, testicle, glandula carotica, and salivary glands.¹

It is probable, however, that a considerable number of these tumors, especially those of the salivary glands, should be grouped among epithelial growths arising in some congenital anomaly. See Tumors of the Salivary Glands, p. 700.²

¹ For a discussion of the endotheliomata consult:
v. *Volkman*, "Ueber endotheliale Geschwülste," *Deutsch. Zeits. f. Chir.*, Bd. xli., p. 1. *Lubarsch*, "Ergebnisse d. allg. Path.," Jahrg. i., Abth. 2, p. 366; also "Endotheliom.," *ibid.*, Jahrg. ii., p. 592.

For embryological consideration bearing on the subject see:
Glockner, *Zeits. f. Heilkunde*, Bd. xviii., p. 209, 1897; *Marchand*, *Verh. der Deutsch. path. Gesellsch.*, Bd. ii., p. 38, 1900.

On the occurrence of giant cells and cells with very large nuclei in endothelioma see *Glockner*, *Ziegler's Beitr.*, Bd. xxvi., p. 73, 1900.

² For a study of tumors of the salivary glands and their alleged nature see *Wood*, *Annals of Surgery* vol. xxxix., p. 57, 1904.

The difficulty of diagnosis in certain of the endotheliomata depends upon the fact that the cells in the developed tumors assume forms so entirely different from the normal endothelium, and upon the impossibility in many cases of detecting the origin of the tumor. In many instances one is forced to rely in a measure upon the probabilities of origin as indicated by the seat of the tumor.

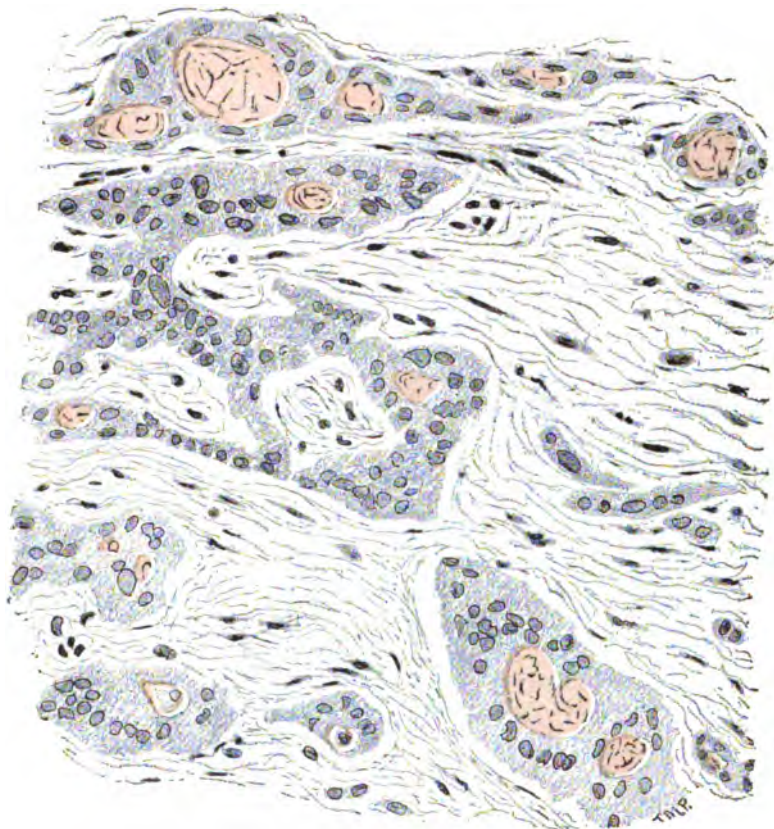


FIG. 223.—ENDOTHELIOMA OF PLEURA.
Showing the formation of mucus within the endothelial-cell masses; the mucus is stained with hæmatoxylin.

The alleged transition forms of cells which may be found in the periphery of such tumors between the tumor cells and the endothelium of blood- or lymph-vessels must be accepted with caution as evidence, since we have reason to believe, as we have seen above (p. 337), that the characteristic cells of a tumor are the direct descendants of those in which the growth started and are not derived from a later growth of the cells of the part in which the tumor is situated.

One may be able to differentiate between carcinoma and endothelioma by the discovery of definite epithelial characters in the cells, such as secretion products, spines, and corneous transformations. Or, on

the other hand, one may discover a more intimate relationship between the cells and the stroma which characterizes the endotheliomata as tumors of the connective-tissue type. Thus in some endotheliomata one may discover that the external layers even of cuboidal cells send processes out among the surrounding fibrils of the stroma. One may furthermore discover a small amount of fibrillar tissue among the cell masses in the endotheliomata which otherwise resemble epithelium.

LIPOMA.

Lipomata are tumors formed of fat tissue. The fat tissue (Fig. 228) occurs in lobules and is similar to normal fat, except that the cells and lobules are usually larger and less regularly arranged. Occasionally a

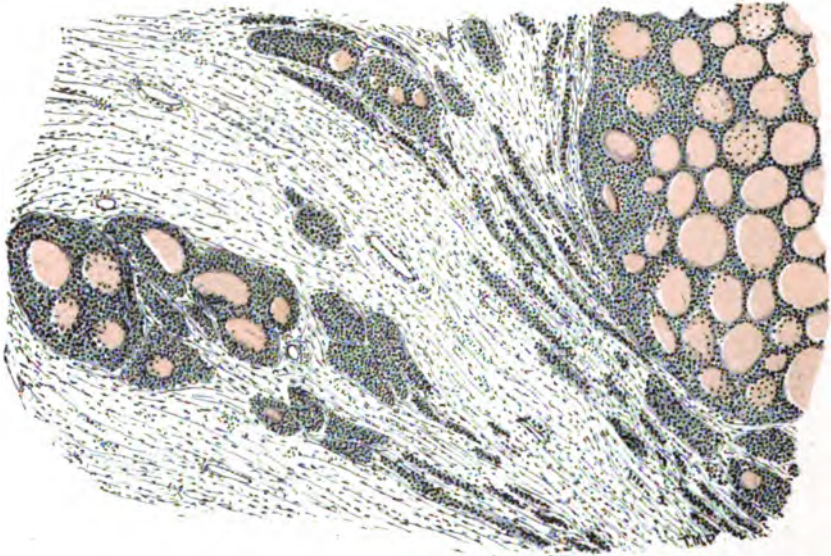


FIG. 224.—ENDOTHELIOMA OF UPPER JAW.

Showing formation of mucus in the gland-like endothelial-cell masses. This form of tumor is often called "cylindroma."

considerable number of the cells resemble those of embryonic or rapidly growing fat tissue. There may be little connective tissue in the tumors, when they are very soft, almost fluctuating—*lipoma molle*—or there may be so much as to give the tumor considerable firmness—*fibro-lipoma*. They may be in part transformed into mucous tissue—*myxo-lipoma*. Cartilage not infrequently develops in them, or they may undergo partial calcification.

Occasionally the blood-vessels are very abundant and dilated—*angio-lipoma*. They are usually sharply circumscribed, but may infiltrate surrounding tissues. They are not infrequently pedunculated. They sometimes grow to enormous size and may ulcerate.

They are usually isolated, but may be multiple, and are occasionally

symmetrically arranged in relation to the median dorso-ventral plane of the body. They are common tumors, occurring usually in the subcutaneous or other fat tissue. They may occur in the mucous membrane of the gastro-intestinal canal, in the peritoneum, more rarely in the dura mater, kidney, liver, and lungs. They are benign tumors, not forming metastases; but they may be deleterious by ulceration or gangrene, and when not fully removed may exhibit local recurrence. They may become sarcomatous.

CHONDROMA.

These tumors, composed of either of the forms of cartilage, are usually hard, but sometimes quite soft. The cells do not present the same uniformity in size, shape, number, and relative position that they do in

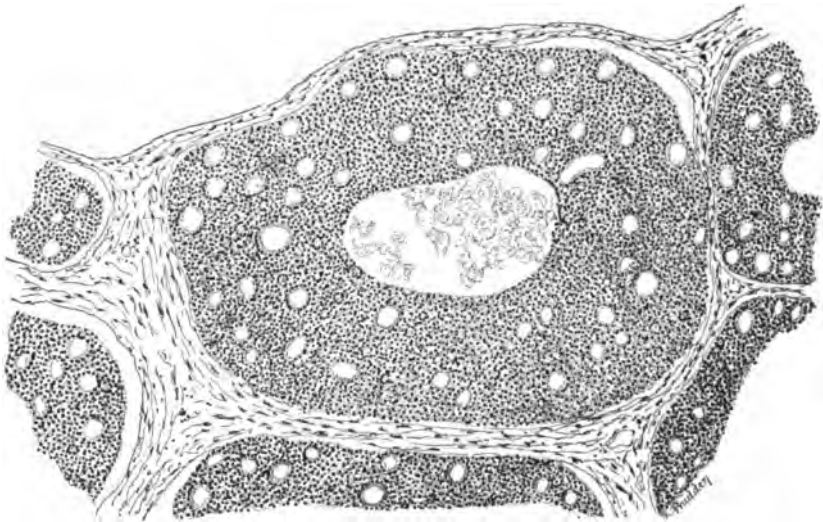


FIG. 225.—BASAL-CELLED EPITHELIOMA OF ANTRUM.
This complex form of tumor is often considered as endothelial in nature.

normal cartilage (Fig. 229). Sometimes they are very large, spheroidal, and grouped in masses, and again small and far apart. They are frequently fusiform or branching. Fibrillar connective tissue in varying quantity is usually present in the chondromata, either as a perichondrial capsule or running in bands between the nodules of cartilage, or passing in fascicles into them.¹

The cartilage may change to mucous tissue, forming *myxo-chondroma*, the cells may undergo fatty degeneration or they may calcify or ossify—*osteo-chondroma*. Chondromata frequently form a part of mixed and complex tumors.

They may form in connection with bone or cartilage usually at an epiphyseal line or in subcutaneous connective tissue and fasciæ. They

¹ For a study of the minute structure of cartilage tumors see *Ernst, Ziegler's Beitr.*, Bd. xxxviii., p. 67, 1905.

may occur in soft parts where cartilage is not normally present, as in the parotid, testicle, mamma, and ovaries, where they are apt to be mixed with other tissue. Under these conditions they doubtless arise from developmental anomalies. They may form in the lungs in connection with the bronchial cartilages or from embryonal displacement of portions of these.

Chondromata are in general benign tumors. Sometimes, however, they assume malignant characters, encroaching largely upon adjacent tissues, growing into and along the lumen of blood-vessels and forming metastases, especially in the lungs and heart.¹ The malignant chondro-

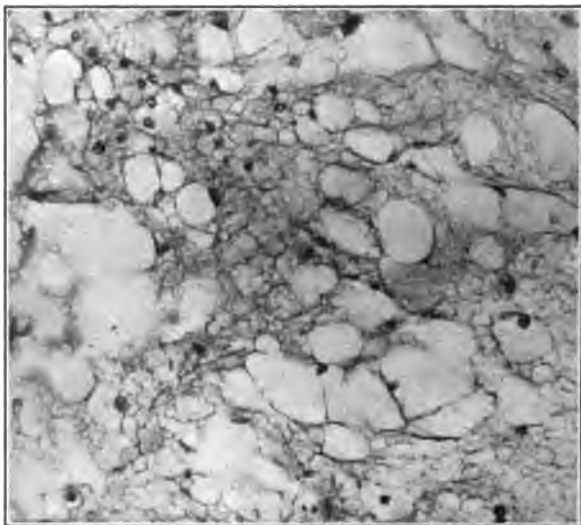


FIG. 226.—SACROCOCYGEAL CHORDOMA.

mata are softer than others and may be even of gelatinous consistence. A critical re-examination of some of the reported metastases has shown that the phenomenon has occurred in the mixed types rather than in the pure chondromata in which recurrence is apt to be local only.

Small hyperplastic growths on the surfaces of cartilages are called *ecchondroses*.

CHORDOMA.

The chorda dorsalis, an important structure in the embryo, persists in the adult only as a small remnant in the intervertebral discs. The tissue consists of large cells with swollen cell bodies lying in a homogeneous, jelly-like stroma. The extremely rare tumors of this tissue are found most frequently at the base of the brain on the clivus just behind the sella turcica. They may, however, occur anywhere along

¹ For a study of metastases in chondroma see *Ernst, Ziegler's Beitr.*, Bd. xxviii., p. 255, 1900, bibl.

the spinal cord or grow from the sacrum and coccyx. The small tumors occurring at the base of the brain are often quite benign, but a considerable number are now on record in which the tumor developed into a large mass infiltrating the brain substance¹ or grew into the roof of the pharynx.²

Both benign and malignant growths have been described as derived from the sacrum.³

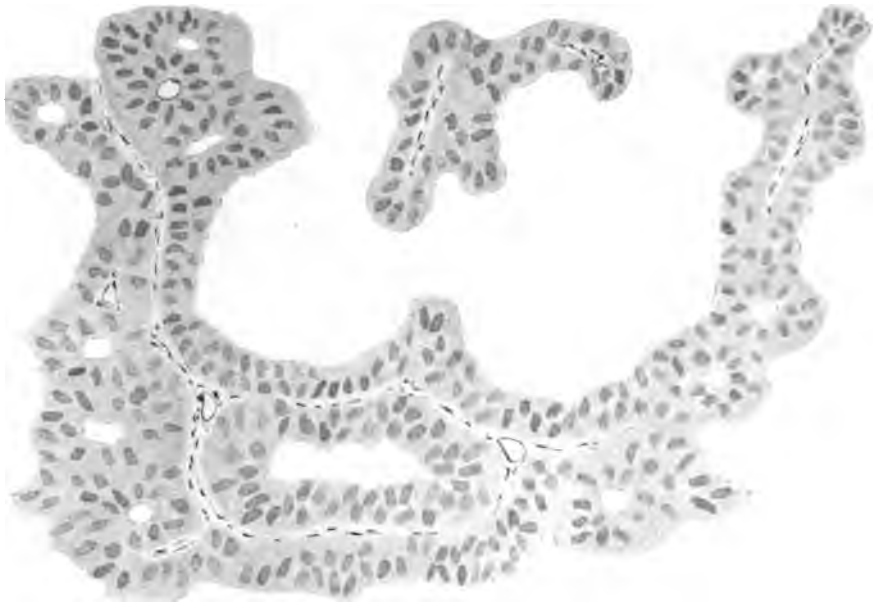


FIG. 227.—ENDOTHELIOMA OF HUMERUS.
Type resembling angio-sarcoma.

In those tumors which reach a large size and show evidence of malignancy the cells vary considerably from the original type of the chorda tissue (Fig. 226).

OSTEOMA.

The formation of bone in the body in abnormal places occurs quite frequently and under a great variety of conditions. It is on this account not easy to define the term osteoma, and it is frequently difficult to decide whether or not a given mass of new-formed bone should be thus designated. Bone tissue often occurs in tumors of the connective-tissue group as a secondary or complicating structure—*osteo-fibroma*, *osteo-chondroma*, *osteo-sarcoma*, etc. It may occur in muscles or fascia as a result of the repeated trauma of certain exercises, or as a result of a

¹ Jelliffe and Larkin (to be published shortly).

² Linck, Ziegler's Beitr., 1909, xlvi., 573.

³ Feldmann, Ziegler's Beitr., 1910, lxviii., 630.

For a full bibliography see Ribbert, Geschwulstlehre, Bonn, 1904, p. 149; also Frenkel et Bassal, Arch. de med. expér., 1910, xxii., 703.

peculiar inflammatory process, *Myositis ossificans*, or it may occur in connection with chronic inflammation in a variety of tissues. A circumscribed mass of abnormal bone, not of inflammatory origin, may be called an osteoma. Small masses of new-formed bone of various shape, pro-

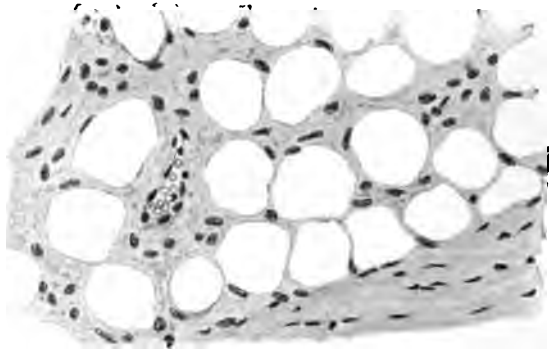


FIG. 228.—LIPOMA.

The section shows a small portion of the tumor near the surrounding fibrous tissue.

jecting from a bony surface and frequently of inflammatory origin, are usually called *osteophytes*. Bony tumors projecting from the surface of bones are frequently called *exostoses*.

An osteoma may be loose in texture, consisting of bone tissue similar to cancellous tissue; or it may be very hard and dense like ivory, so

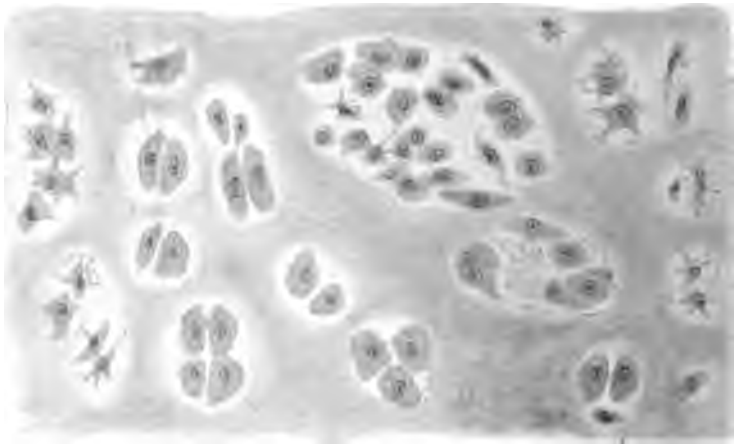


FIG. 229.—CHONDROMA OF FEMUR.

called *ivory exostoses*. The difference between these forms lies chiefly in the varying number and size of the vascular and medullary spaces which they contain. The growth of the osteomata is, as a rule, slow. They are benign tumors, and are not infrequently multiple.

Osteomata may develop in connection with the bone or periosteum, which is most frequently the case, or, independently of bone, in soft parts.

New-formed bone has been found in the soft parts of the body; in the brain substance, dura mater, and pia mater; in the pleura, diaphragm, and pericardium; in the skin, choroid, air passages, lungs, kidneys, aorta, and penis, and in other places.

To what extent some of these bone formations may have been due to inflammatory action it is not possible to say, but it seems probable that in many of the cases cited above an inflammatory or degenerative process preceded the bone formation.

Odontoma.—Tumors are sometimes formed from the pulp during the development of the teeth. When these contain dentin they are called odontomata.

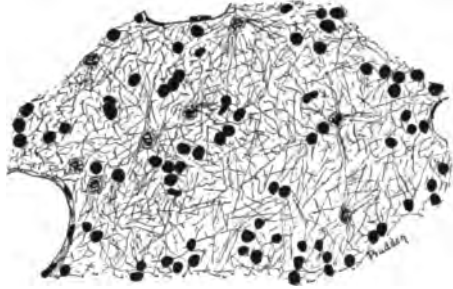


FIG. 230.—GLIOMA OF BRAIN.

GLIOMA.

The gliomata are developed from the characteristic framework of nerve tissue, the neuroglia, which in structure many, though usually not all, of its cells closely resemble. Small cells with inconspicuous bodies and numerous delicate branching processes are most characteristic; but in connection with these there is usually a greater or less number of

small spheroidal cells with proportionally large nuclei (Fig. 230). It is usually necessary to shake sections in water or carefully tease fragments of the tumor in order to see the characteristic neuroglia or so-called "spider" cells (Fig. 231). It is held by Weigert and others that the so-called branches of the neuroglia cells are rather fibrils lying close beside the cells than actual branches.¹ Certain gliomata are marked by an alveolar arrangement of their cells which

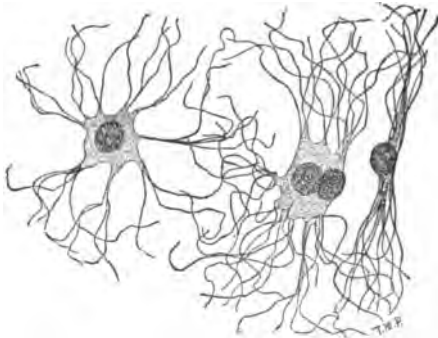


FIG. 231.—NEUROGLIA OR "SPIDER" CELLS FROM GLIOMA OF THE BRAIN. Teased specimen.

resemble the ependymal cells and may line small cavities or present a rosette-like arrangement; one side of the cells being free, the others sending prolongations into the surrounding tissues. Such tumors most clearly reveal their ectodermal origin.

Gliomata may contain very numerous and frequently dilated thin-

¹ See ref. Mallory, foot-note, p. 388.

walled blood-vessels. They may be very soft or moderately hard; and, especially when occurring in the substance of the brain, are frequently not sharply outlined against the adjacent normal tissue. They usually occur singly, and are comparatively slow in growth.

They are frequently associated with other tumor tissue, forming *glio-myxoma*, *glio-sarcoma*, etc. Owing to the abundance of thin-walled blood-vessels and the softness of the growth, they are liable to interstitial hæmorrhages, and may then, when occurring in the brain, readily be mistaken for ordinary apoplectic clots. They are liable to fatty degeneration. They usually occur in the brain, spinal cord, and in the optic and other cerebral nerves. Some of the so-called gliomata of the retina are apparently small spheroidal-celled sarcomata; others arising through embryonal defects from the external retinal layers are called *neuro-epitheliomata*.

Pure gliomata are benign tumors, though in their most common combination with sarcoma they may be very malignant. Their usual situation, however, is such as to make them almost always significant, although technically they are benign tumors.¹




FIG. 232.—MYOMA OF THE UTERUS.

This is of the smooth-muscle type—leiomyoma—and shows one bundle of muscle cells cut lengthwise, others across.

MYOMA.

Tumors composed of muscle tissue are of two kinds, following the two normal types of muscle, the non-striated and the striated.

I. Leiomyoma, Myoma Levicellulare.—The characteristic elements of these tumors are fusiform, smooth muscle cells, with elongated or rod-shaped nuclei. These are packed closely together, frequently interlacing and running in various directions, and are intermingled with a variable quantity of more or less vascular fibrillar connective tissue (Fig. 232). When, as is not infrequently the case, the connective-tissue elements are present in large amount, the tumor is called a *fibrous*

¹ Our knowledge of the normal neuroglia is still too meagre to permit us to understand very thoroughly this class of tumors, and to separate it as precisely as could be wished from certain of its allies among the abnormal connective-tissue growths. For a study of "neuroglia fibrils" and the classification of the gliomata see *Mallory*, Jour. Med. Res., vol. xiii., p. 113, 1905; Jour. Exp. Med., vol. x., p. 575, 1908.

myoma. In such tumors it should be remembered that the muscle, not the connective tissue, is still the essential characteristic feature (Fig. 233).

It is not always easy to distinguish leiomyomata from certain connective-tissue tumors, small spindle-celled sarcoma, cellular fibromata. In normal smooth muscle tissue the characteristic cell is spindle-shaped, sharply outlined with rod-shaped nuclei. The tapering cells are placed with overlapping ends, in clusters and bundles surrounded by more or less fibrillar connective tissue which bears the vessels and nerves. In addition to certain fibrils within the cells, the smooth muscle cells are furnished with delicate fibrils lying along the periphery of the cell parallel with its long axis, and extending along the overlapping cell columns. These are called *myoglia fibrils*.

In leiomyomata the muscle cells as well as their nuclei vary considerably in shape. They both may be long and slender, or short and plump, the latter forms with mitotic figures prevailing especially in the more rapidly growing forms. The myoglia fibrils are present in the tumors also and may present considerable variations in size, arrangement, etc.¹

These tumors may become oedematous, and, owing to their density and lack of blood-vessels, they not infrequently degenerate; forming cysts or becoming gangrenous. They frequently undergo hyaline degeneration and calcification. They may occur singly or be multiple, are usually of slow growth, may be large or small, and are, for the most part, benign. But, especially in the uterus, they may become large, and being often multiple may lead to serious disturbance. On the other hand, a few instances are recorded of myomata in the uterus and gastro-intestinal canal which have been rapidly growing, locally invasive, and have metastasized. These are called *malignant leiomyomata*. Leiomyomata may occur wherever smooth muscle tissue exists. They are most frequently found in the uterus, where they are often multiple. They may occur in the wall of the gastro-intestinal canal, and have been seen in the kidney, in the bladder, and in the skin. A certain proportion of the so-called hypertrophies of the prostate, so frequent in advanced life, are sometimes considered leiomyomata of the interstitial muscle tissue of that gland. For a description of glandular myomata of the uterus see p. 813.



FIG. 233.—FIBRO-MYOMA OF UTERUS.
The muscle cells are crowded apart by dense fibrous tissue.

¹ See, for methods of staining myoglia fibrils, *Mallory, Jour. Med. Res.*, vol. xiii., p. 124, 1905.

II. Myoma Striocardiale, or Rhabdomyoma.—In these rare tumors striated muscle fibres are the characteristic elements. They very rarely compose a great part of the tumor, but are intermingled with other elements, fibrillar connective tissue, spindle-shaped and spheroidal cells of various forms, which often appear to be incompletely developed muscle cells. They are not infrequently associated with sarcomatous tissue. Blood-vessels and sometimes nerves are also present. The muscle fibres differ, as a rule, from normal striated muscle fibres in their arrangement, which is usually quite irregular, and also in size, being in general smaller than normal fibers, although varying greatly. The sarcolemma is either absent or incompletely developed. These tumors are usually small or of moderate size, and are supposed to originate from inclusions of cells destined to form muscle tissue in places where they do not belong.

In the heart and certain other muscular parts, small circumscribed masses of striated muscle tissue have been described, and are sometimes called *homologous rhabdomyomata*. But genuine *heterologous rhabdomyomata* are, in almost all cases thus far recorded, confined to the genito-urinary organs, kidney, ovary, and testicles. The writer has described an exceptional case of rhabdomyoma occurring in the parotid gland.¹

These tumors, when not associated with other and malignant tumors, are benign and are of much greater theoretical than practical interest.

NEUROMA.

A true neuroma is a tumor containing new-formed nerve tissue. Such tumors are comparatively rare. Tumors developed in the connective tissue of nerves and composed usually of fibrous or mucous tissue are common, and are frequently called neuromata, but they should be called fibromata or myomata, etc., of the nerves, or *false neuromata*. The true neuromata are of two kinds, *ganglionic* or *cellular neuromata* and *fibrillar neuromata*, depending upon the character of nerve tissue which they contain. The ganglionic neuromata—*neuroma ganglioniforme*—in which new-formed nerve cells are present

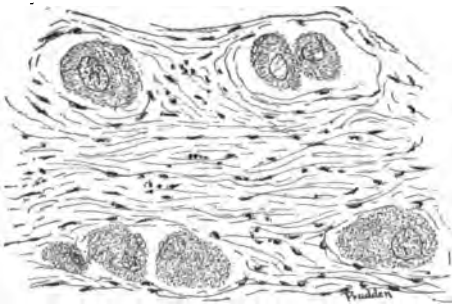


FIG. 234.—NEUROMA GANGLIONIFORME.
Section from a tumor of the adrenal.

(Fig. 234), are found associated

with other structures in certain of the teratomata in the ovaries, testicles, and in the sacral region; they also occur in the gray matter of the brain. They have been found in the adrenals and may also contain sarcomatous elements.

¹ Prudden, Amer. Jour. Med. Sci., vol. lxxxv., p. 438, 1883. For later bibl. consult Helbing, Centralbl. f. Path., Bd. ix., p. 433, 1898.

The fibrillar neuromata are, according to Virchow, of two kinds, *myelinic* and *amyelinic*, depending upon whether the nerve fibres which they contain are medullated or not. The *neuroma myelinicum* is the more common and the better understood. The medullated nerve fibres in these tumors are associated with fibrillar connective tissue, and are usually curled and intertwined in a most intricate manner. They are




FIG. 235.—FALSE NEUROMA—FIBROMA OF LUMBAR NERVE.

The fibrous tissue is loose in texture and in places œdematous, so that many of the nerve fibres pass through the tumor with little structural alteration.

either single or multiple on the peripheral nerves. They may occur in considerable numbers as nodular tumors on the branches of a single nerve trunk, or they may form an irregular, diffuse, nodulated enlargement of the nerve branches—*plexiform neuroma*. These neuromata may or may not be painful. They not infrequently form at the cut ends of the nerves in amputation stumps. They are benign tumors, never forming metastases.



FIG. 236.—MULTIPLE FIBROMATA (FALSE NEUROMATA) OF PNEUMOGASTRIC NERVE.
One-quarter natural size.

From the same case as that from which the photographic reproduction of Fig. 237 is made.

The false neuromata are myxomata, or fibromata (Fig. 235), or sometimes myxo-sarcomata of the nerve sheaths or intrafascicular connective tissue, and may be single or multiple. In the latter case they may affect the branches of a single nerve trunk (Fig. 236), or they may be found on nearly all the cerebro-spinal peripheral nerves. The writer has described a case (Figs. 236 and 237), in which more than eleven hundred



FIG. 237.—MULTIPLE FIBROMATA (FALSE NEUROMATA) OF THE PERIPHERAL NERVES OF THE ARM AND LEG.

A, Nerves of the right arm; B, the left sciatic with its branches; C, the left anterior crural with its branches. From the same case as Fig. 236. The nerves of the other extremities were similarly involved.

and eighty-two distinct tumors were found distributed over nearly all the peripheral nerves of the body.¹

The nerve fibres in these tumors may be crowded apart by the new growth and considerably atrophied; or, in cases in which the tumor is composed of soft tissue, as in myxoma or the soft fibroma, they may pass through or around the tumor entirely unchanged. The multiple false neuromata are in many cases congenital.²

ANGIOMA.

Angiomata are tumors consisting in large part or entirely of new-formed blood- or lymph-vessels or cavities. In many tumors of various kinds the new-formed or the old blood- and lymph-vessels may be very abundant or prominent by reason of their dilatations; the vessels of otherwise normal tissues may also be largely dilated, thus simulating vascular tumors. These are, however, not true angiomata, although sometimes reckoned among them, and in many cases closely allied to them. Such are the so-called arterial varix, or cirroid aneurisms, and

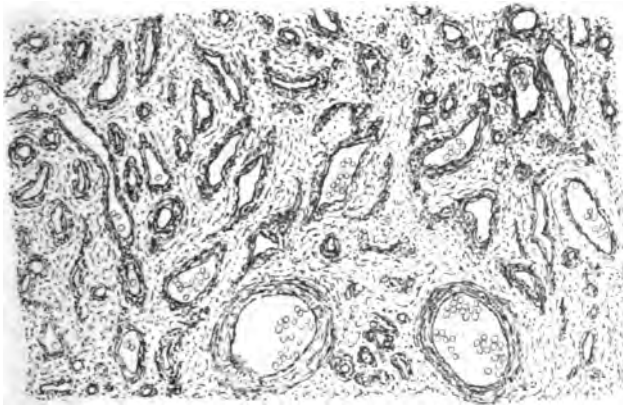


FIG. 238.—ANGIOMA TELANGIECTOIDES FROM THE SKIN.
This section is from a vascular naevus, "strawberry mark," of the skin

hæmorrhoids, and various lymphectasiæ. True angiomata are of two kinds—I. Hæmangioma, and II. Lymphangioma.

I. Hæmangioma.—These tumors are of two types: 1. Those formed largely of capillary blood-vessels with either thin or thickened walls, embedded in a more or less abundant connective-tissue stroma. These are called *simple angiomata* or *angioma telangiectoides* (Fig. 238). The walls of the vessels in these tumors are frequently dilated or pouched, and usually form a tangle of curled and intertwined vessels. They

¹ *Prudden*, Amer. Jour. Med. Sci., vol. lxxx., p. 134, 1880. Consult also *Preble and Hektoen*, Trans. Assn. Am. Phys., vol. xv., p. 470, 1900, bibl.

² For association of these tumors with sarcoma see *Larkin*, Jour. Med. Res., vol. ix., p. 217, 1903.

occur most frequently in the skin or subcutaneous tissues, usually about the face, and may project above the general surface or be on a level with it. Such are the so-called *vascular nævi*, or *strawberry marks*, which are usually congenital. They are sometimes sharply circumscribed, and

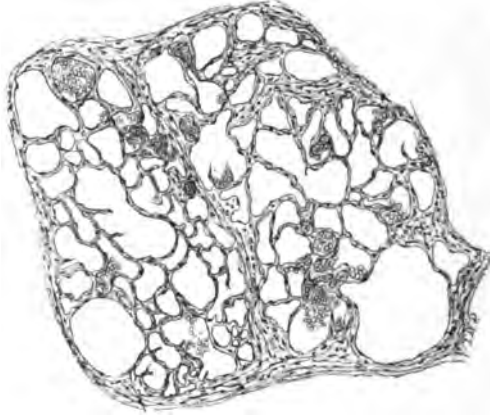


FIG. 239.—ANGIOMA CAVERNOSUM OF LIVER.
This section shows the entire small tumor.

sometimes merge imperceptibly into the surrounding skin. They sometimes occur in the mucous membranes, in the mamma, bones, and brain. They are benign tumors, never forming metastases, but may be associated with sarcomata.

2. The second form of hæmangioma, called *angioma cavernosum* (Fig.

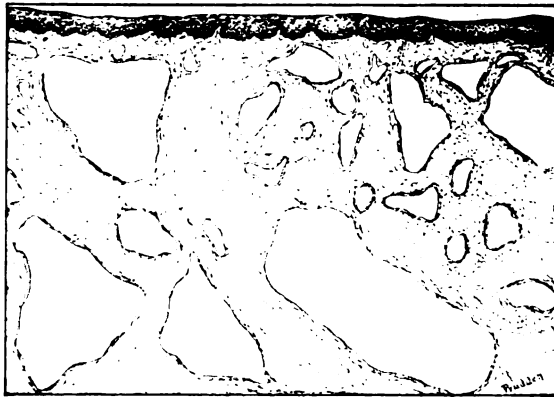


FIG. 240.—CONGENITAL LYMPHANGIOMA FROM ARM OF CHILD.

239), consists largely of a series of intercommunicating, irregular-shaped, larger and smaller blood-spaces lined with endothelium, and surrounded by a variable quantity of fibrillar connective tissue, which may contain smooth muscle cells. They resemble the erectile tissue of the corpora

cavernosa of the penis and clitoris. They are apparently formed by a dilatation of old and new-formed capillaries and veins. They are sometimes erectile and sometimes pulsating, and are not infrequently multiple. They may be seated in the skin and subcutaneous tissue, forming the so-called projecting *nævi*, or in internal organs. They are often found in the liver and less frequently in bone, the brain, spleen, uterus, kidney, intestines, bladder, and muscles. They are usually of little significance, though they may give rise to hæmorrhages.

II. Lymphangioma.—These tumors consist of dilated lymph channels which either preserve approximately the general shape of the original lymph-vessels, or are distinctly cavernous in character (Fig. 240) or even cystic. They probably originate in part in new-formed, in part in old lymph channels. A strict distinction between tumors formed by a dilatation of pre-formed and new-formed lymph channels is not possible, owing to the very primitive character of some of the ultimate lymph-spaces and our lack of knowledge of their exact relations to adjacent parts.

In the lymphangiomata there may be much or little connective tissue between the dilated channels, which are usually filled with a translucent or milky fluid resembling normal lymph. These tumors are usually congenital, but are sometimes acquired. They usually occur in the skin as soft, sometimes considerably, sometimes but slightly elevated growths, and may occur in the tongue—some forms of so-called macroglossia. They are benign tumors, but may rupture, giving rise to serious lymphorrhœa.

Tumors in Which Epithelial Cells are Predominant or Characteristic Elements—Epithelial Tumors.

I. ADENOMA. II. CARCINOMA.

General Considerations Regarding Epithelial-cell Tumors.

While in the main, in the normal body, the general distinctions between epithelial and other tissues are fairly well marked, there are instances, especially those in which epithelial tissues are in process of physiological growth or rejuvenation, in which the distinctions are quite ill-defined. When we remember the rapid growth of many tumors, the tendency to incomplete formation of their cells, their diverse seats, and the various complicating conditions under which they originate and develop, it does not seem strange that the exact limitations of this class of tumors are not easy to fix, nor that they seem sometimes to merge into one another and into tumor tissues belonging to other classes. If epithelial cells, under all circumstances, had a definite and characteristic structure, or if, on the other hand, we could always know whether a given cell group originated in epithelium or not, the matter of distinguishing between tumors of this and other classes would be simple and easy enough. As it is, in some cases both morphological and histogenetic

criteria fail us, and the clinical history and gross appearance are not characteristic. Such instances—which are indeed rare—suggest the possibility that the facts at our command do not justify such definite distinctions between epithelial and certain other tumors as on both theoretical and practical grounds we should like to command. While these difficulties in special cases must be acknowledged, the distinctions are in the main definite enough, and very useful both for clinical and scientific purposes.¹

Epithelial tumors always contain, in addition to the more or less characteristic cellular elements, a connective-tissue stroma which gives them support and carries the vessels (Fig. 241). This stroma may be sparse or abundant, may contain few or many cells, is sometimes arranged in irregular fascicles or bands, and very frequently forms the walls of well-defined, variously shaped spaces or cavities called *alveoli*, in which the epithelial cells lie.

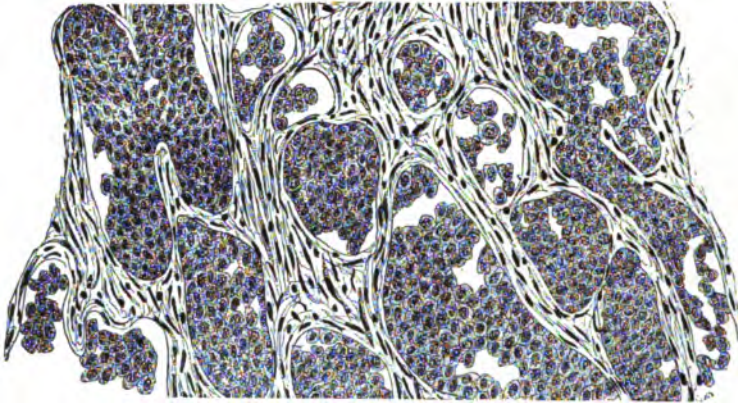


FIG. 241.—CARCINOMA OF THE STOMACH—MEDULLARY CARCINOMA OR CARCINOMA MOLLE.

In tumors of the adenomatous type the epithelium and the connective tissue grow co-ordinately, producing structures in which the relative proportions of cell and stroma correspond approximately to those seen in the organ from which the tumor is derived. For this reason, Ribbert prefers to designate the adenomata as fibro-epithelial tumors, in distinction to the carcinomata where the epithelium forms the real mass of the tumor. The epithelial cells, in most cases, lie along the walls of the alveoli without an intimate connection with them. They are, moreover, packed together without more intercellular substance than the usual cementing material common to epithelial-cell masses. In this lack of fibrillar intercellular substance within the alveoli, and in the loose relationship between the cells and the alveolar walls, lie in many cases the chief morphological distinctions between certain carcinomata and alveolar sarcomata.

¹ For a study of the relationships between epithelium, endothelium, and connective tissue see *Krompecher, Ziegler's Beitr.*, Bd. xxxvii., p. 28, 1905.

In certain of the epithelial tumors there is a reproduction of typical gland tissue of various kinds, depending upon the seat and conditions of growth of the tumor. Such tumors are called *adenomata* or *fibro-adenomata* (Fig. 243). A simple hypertrophy of a gland, or an increase in its size by excessive growth of its interstitial tissue, does not constitute an adenoma. There must be an actual new formation of more or less typical

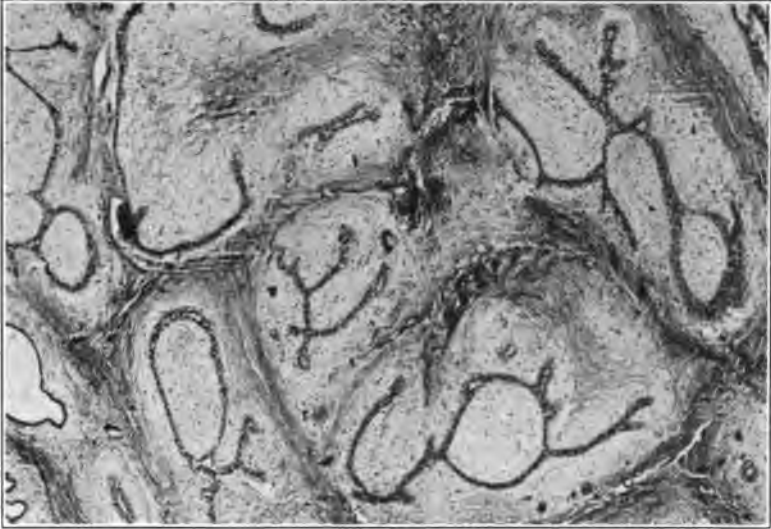


FIG. 242.—INTRACANALICULAR FIBRO-ADENOMA OF BREAST.

mata (Fig. 243). A simple hypertrophy of a gland, or an increase in its size by excessive growth of its interstitial tissue, does not constitute an adenoma. There must be an actual new formation of more or less typical

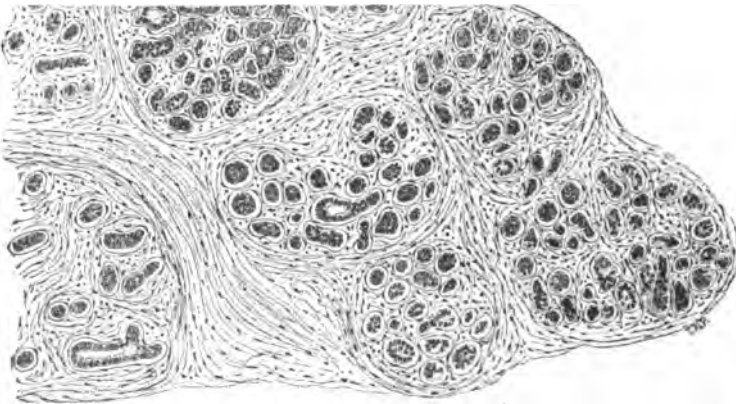


FIG. 243.—ADENOMA OF THE MAMMA.

gland tissue. This is not always or frequently of exactly the same character as the gland tissue in which it originates, and always exhibits a certain lack of conformity to the type in structure and mode of growth.

The alveoli and ducts usually have a lumen and sometimes a *membrana propria*, but the cells may differ in shape from one another and from those of the gland from which they spring. Occasionally the connective tissue may quite outgrow the epithelium as in the so-called intracanalicular fibro-adenomata of the breast (see Fig. 242).

Epithelial tumors in which there is no close conformity to a glandular type, but an independent and atypical growth of epithelial cells in the meshes of an old or new-formed connective-tissue stroma, are called *carcinomata* (Fig. 241).

It will readily be seen that there must be a border region between the adenomata and carcinomata, where conformity to the glandular type merges into the lawlessness of growth characteristic of carcinomata. In this border region a certain degree of individual bias must be permitted in assigning a name to the new growth. In some cases a sharp distinction cannot be made; or the tumor may share in the characteristics of both, and then we very properly make use of the term *adeno-carcinoma* or *carcino-adenoma*.

I. ADENOMA.

The structure of the cellular elements of these tumors, and their arrangement into acini and ducts, vary even more than do those of the

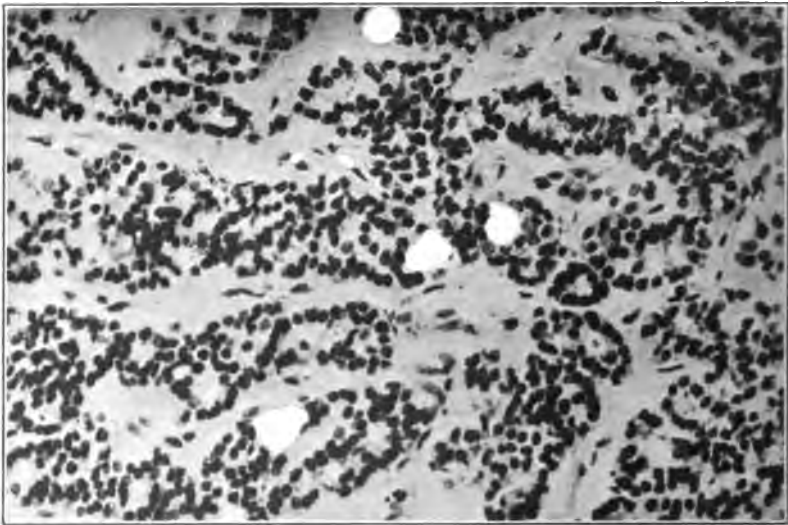


FIG. 244.—HYPERPLASIA OF THYROID TISSUE WITHOUT THE FORMATION OF COLLOID. OFTEN CALLED "FETAL ADENOMA OF THE THYROID."

normal glands whose types they follow. The acini usually have a more or less well-defined lumen and *membrana propria* (see Fig. 246). The adenomata sometimes merge into the surrounding tissue, or are continuous with the gland tissue in which they originate; sometimes they

are distinct in outline and encapsulated. The interstitial tissue is sometimes abundant, sometimes sparse, and may contain few or many cells. The irregularities of their growth often lead to the stoppage of the lumina of their ducts and the formation of cysts. They may undergo mucous metamorphosis and may become sarcomatous.

Adenomata occur in the mamma, ovary, liver, kidney, adrenal, thyroid (Fig. 244), salivary and lachrymal glands, and in the caruncle; in the mucous membrane of the nose, pharynx, stomach, intestine, and

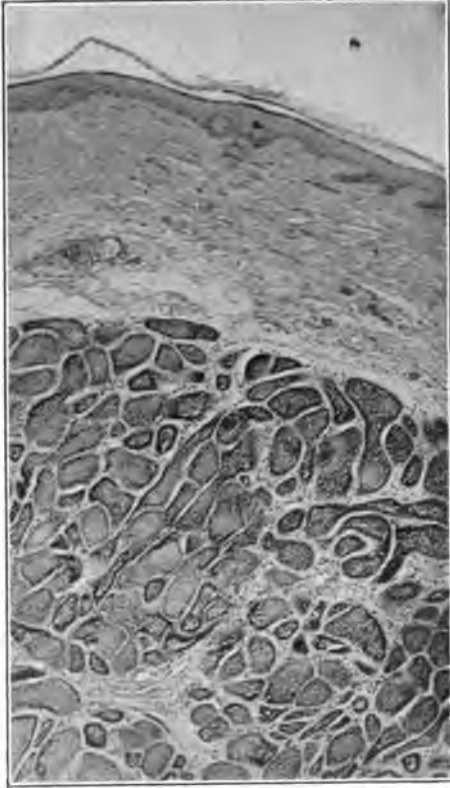


FIG. 245.—SEBACEOUS ADENOMA FROM SKIN OF FOREHEAD.

uterus; and occasionally in the sebaceous and sweat glands¹ of the skin (Fig. 245). The so-called multilocular cystomata of the ovary are among the most frequent of the adenomata, and not only have a great clinical importance but are also interesting because of their peculiar morphology, which has led some observers to consider them of a teratological origin, and their power to give rise to extensive transplantation metastases on the surface of the peritoneum.

¹ For a study of sweat-gland adenoma see *Landsteiner, Ziegler's Beitr.*, Bd. xxxix., p. 316, 1906, bibl.

There are numerous papillary and polypoid growths, in gland ducts and on mucous membranes, in which there is an actual new formation of gland epithelium; but this is usually secondary to a primary growth, beneath the epithelial layer, of some other tissue, such as fibrous or mucous tissue, and the new growth of gland epithelium simply keeps pace with the growth of the stroma which it covers. Such growths are sometimes classed among the adenomata, but do not, strictly speaking, belong there.

Many of the adenomata are benign tumors, being slow of growth and localized, but there are very important exceptions. Some of the adenomata of the stomach and intestines belong to the most malignant

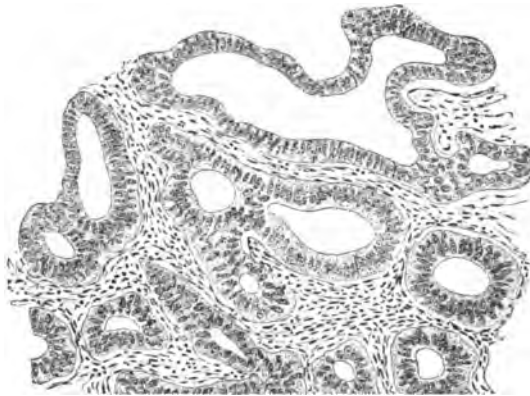


FIG. 246.—ADENOMA OF STOMACH.

A form of tumor which is on the border line of carcinoma and might be called adeno-carcinoma.

of tumors in rapidity of local extension, in the formation of metastases, and the development of cachexia. Certain of the adenomata of the uterus, mamma, and thyroid are also very malignant. It should be remarked, however, that, as a rule, the malignant adenomata are those which, in structure, lie close upon the border line between tumors of this class and carcinomata (see Fig. 246), and by such observers as incline to lay more stress upon clinical than upon morphological distinctions they are usually classed among the latter.

II. CARCINOMA.

The carcinomata are formed of variously shaped, usually elongated, and often anastomosing masses of cells derived from epithelium. These epithelial-cell masses which constitute the characteristic and more essential feature of these tumors are surrounded by more or less fibrillar connective-tissue stroma which carries the blood-vessels and may form with the tumor or may be, in part at least, a remnant of the tissue in which the tumor is growing.

The characteristic epithelial cells of the carcinomata are all the descendants of those in which the tumor started; and while they often resemble these in type, they usually differ considerably from them in appearance, owing to vicissitudes of pressure, nutrition, functional performance, reversion, etc. The reticular masses of epithelial cells are not intermingled with the fibrous stroma, but lie against it in the manner

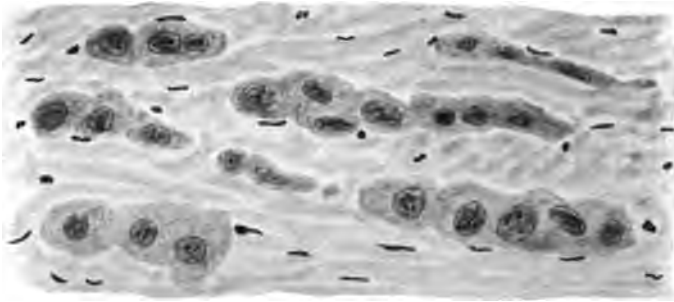


FIG. 247.—CANCER CELLS INFILTRATING THE TISSUE SPACES IN THE VICINITY OF A TUMOR OF THE MAMMA.
From carcinoma mammae.

characteristic of epithelium in general. In sections of such tumors the elongated cell masses are cut across at various angles so that the cells frequently appear to be lying in more or less rounded spaces which have been called *alveoli* (Fig. 241).

A great practical difficulty in the description, and, to beginners, in the recognition, of the carcinomata and their varieties lies in the great diversity in shape which their

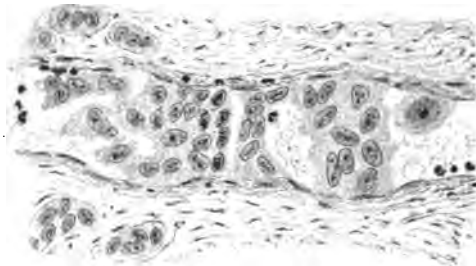


FIG. 248.—A GROWTH OF CARCINOMA CELLS IN A LYMPH-VESSEL NEAR A TUMOR.
Such cell masses are liable to be detached and carried along the vessel, forming metastases.

cells present. It should be always borne in mind that the shape of cells depends in part upon their inherited tendencies in growth, which we cannot see under the microscope; but to a greater degree upon the varying conditions of nutriment and pressure in which they are placed during life. In the normal body these conditions conform to a certain standard, so that cells of a given kind at a given stage of development are approximately similar.

In tumors, however, the lawlessness and lack of fixed conditions in growth are such that we may have many young and atypical so-called indifferent forms of cells;

while even the adult forms may depart widely from normal shapes. Thus, in cylindrical-celled carcinomata there are many fully developed cells which are never cylindrical; there are many others not fully developed which are quite indifferent in form, looking just like many other young cells. Finally, there may be in such tumors inflammatory processes through which young connective-tissue cells are formed, not to be distinguished individually from the atypical forms of epithelium. Thus it is that there is no morphologically characteristic "cancer cell," as was formerly supposed. Some of them are typical and some not, and the more typical may resemble normal epithelial cells, and the atypical may look like young connective-tissue cells or even lymphocytes. It is in the topography, together with the general characters of the cells and the situation of the growth, that we must seek for the evidences of the nature of such tumors.

The carcinomata are very prone to local extension, the advancing tumor cells in the periphery making their way through the lymph-spaces in solid or more or less tubular masses (Fig. 247). As the epithelial-

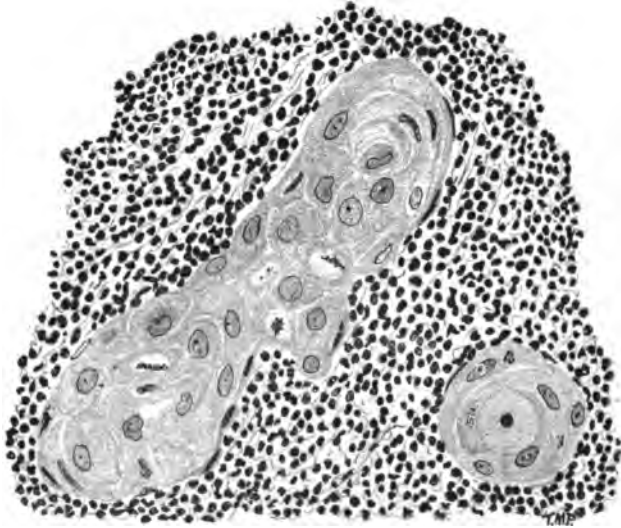


FIG. 249. METASTATIC CARCINOMA (EPITHELIOMA) IN A LYMPH-NODE.

The primary tumor was in the vagina. The section shows at the right a small "epithelial pearl."

cell masses advance into the surrounding parts, the latter may suffer resorption and disappear, or the connective tissue may adapt itself to the encroaching tumor-cell masses, or new connective-tissue stroma may form. Metastasis is of frequent occurrence in some forms of carcinoma, and takes place chiefly, though not exclusively, through the lymph-vessels. Masses of the new-formed epithelial cells may fill and distend the lymph-vessels (Fig. 248), or detached cells or cell clusters may be swept along the lymph-vessels to lodge in the next lymph-nodes where secondary tumors may develop (Fig. 249). Mitotic figures (Fig. 250) are frequently abundant in carcinomata, but bear but little numerical relation to the rate of growth of the tumor as a whole. Numerous

mitoses may occasionally be found in slow growing tumors. The reason for this seems to be that the actual number of mitoses in a tumor varies from day to day, so that it is not an infrequent experience to find an enormous number of mitoses in a fragment excised for diagnosis and



FIG. 250.—MITOSIS IN CARCINOMA.

then to discover only a few in sections taken from the same portion of the tumor when removed even twenty-four hours after the diagnostic excision. The same phenomenon may be observed by close study of the rate of growth of a tumor so situated that its dimensions can be accurately determined. Periods of rapid increase alternate with stationary or even

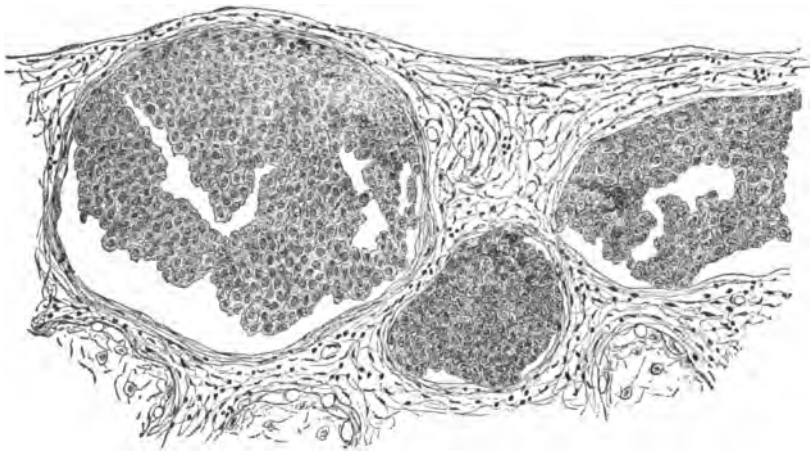


FIG. 251.—METASTATIC CARCINOMA IN LYMPH-VESSELS OF THE PLEURA. The primary tumor was in the liver. The subpleural lymphatics are widely distended with the tumor-cell masses.

regressive phases, a fact which has led to serious error in judging of the supposed therapeutic effects of so-called cancer cures.

The growth of the tumor cells in the lymph-vessels, either in the immediate vicinity of the original tumor or following metastasis in a distant part of the body, may distend these so that on free surfaces like

the pleura and peritoneum they form a whitish, elevated network. Transverse sections of such distended lymph-vessels are shown in Fig. 251. Secondary tumors are in the main similar in general structure to the primary foci, but may differ from them in vascularity and the abundance of the stroma, or in the shape of the cells. The carcinomata are, as a rule, malignant tumors, but the different forms vary widely in this respect.

Carcinomata are liable to fatty, gelatinous, mucous, and amyloid degeneration, and are especially prone to ulceration (see Fig. 252), to

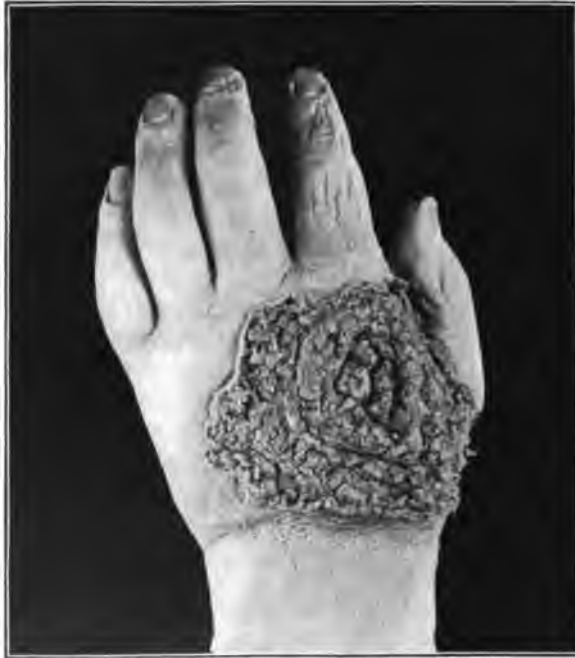

FIG. 252.—CARCINOMA OF THE HAND.

This tumor is of the epitheliomatous type and presents a large, rough, ulcerated surface.

hemorrhage and inflammation (Fig. 253). They may become partially calcified, and are not infrequently combined with other forms of tissue in the mixed tumors.

They are more frequent in the middle-aged and elderly than in the young, but they may occur at any age.¹ Multiply primary carcinomata have been occasionally reported.²

When carcinomata, either in the primary or the secondary growths, extend and encroach upon adjacent tissues, they bring about in greater or less degree the destruction of these, as we have seen, either by pressure atrophy or through phagocytosis or

¹ For a statistical summary of carcinoma cases, with bibl., see *Riechelmann*, *Berl. klin. Wochenschr.*, pp. 728 and 758, 1902; see also ref. to *Bashford* and *Murray*, foot-note, p. 353.

² See *Warthin*, *Jour. Amer. Med. Assn.*, vol. xxxii., p. 963, 1899, bibl.

lysis. It frequently occurs that the tumor cells are closely apposed to or infiltrate epithelial structures similar to those in which the tumor originates, so that one may see side by side tumor epithelium and tissue epithelium having an almost identical appearance. The adjacent tissue cells may also show evidence of proliferation in mitotic figures. These two features, contiguity and mitosis, have led many observers to the conclusion that the epithelium adjacent to a growing tumor may assume exalted power of proliferation and share in the growth of the tumor, of which it may

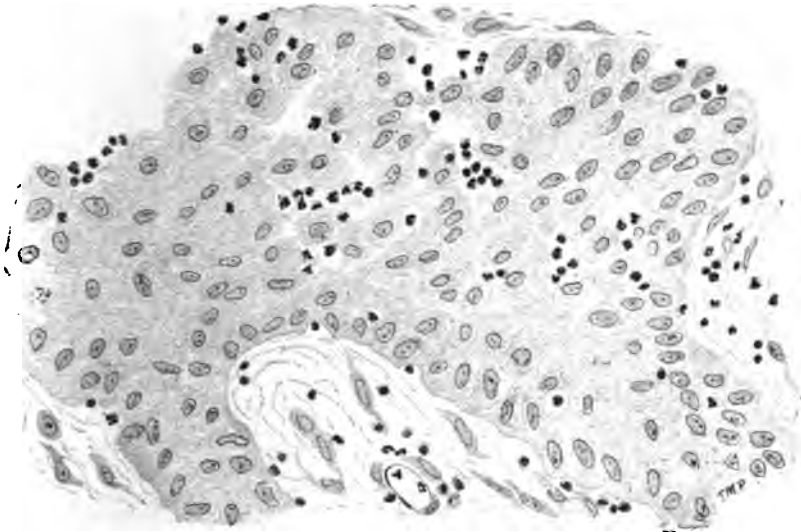


FIG. 253.—EXUDATIVE INFLAMMATION IN CARCINOMA.

Showing leucocytes in the stroma and in the epithelium. The epithelium is disintegrating, and in the small region shown in the cut the leucocytes are apparently acting as phagocytes in the softening and removal of the disintegrating epithelium.

become a part. This view is erroneous, and the student of tumors should constantly remember that the characteristic cells of a tumor are the direct descendants of those cells in which the growth starts. For example, one often sees, at the edges of an ulcerating epithelioma of the skin, tumor-cell masses infiltrating the subcutaneous tissue and in close apposition to the cells of the rete Malpighii, the latter often in a condition of hyperplasia. But, however close or however intermingled, in such cases tumor epithelium and skin epithelium are quite distinct in origin and potency.

FORMS OF CARCINOMA.

In certain carcinomata of the skin and mucous membranes, the cells, following the type of epithelium from which they arise, as they grow older are apt to become flattened or squamous; these tumors are called *squamous* or *flat-celled carcinomata*, or simply *epitheliomata*. In another class of tumors, such as frequently occur in the gastro-intestinal canal and uterus, the cells are more or less cylindrical in shape, forming a palisade-like lining to the irregular alveoli; such tumors are called *cylindrical-celled carcinomata*, although here again many of the cells are not cylindrical at all, but may have a great variety of forms. There is a third and very common form of tumor, often derived from cuboidal

epithelium, in which the tumor cells have no constant characteristic shape, but vary as much as do the cell forms in the various glands of the body. Such tumors are conveniently classed together as *carcinoma simplex*.

In addition to these forms there are several others which depend for their characteristics upon various metamorphoses or degenerations, or upon the preponderance of one or other of the anatomical constituents of the growth, such as *gelatinous carcinoma*, *melano-carcinoma*, *fibrous carcinoma*, etc. It will be most convenient to give a brief description of these various kinds, one after another, with the understanding that they are not specific forms, but are simply varieties which it is convenient to recognize for clinical as well as anatomical purposes.

Epithelioma.—These tumors occur in the skin and in the mucous membranes which are covered with squamous epithelium. The cells present all of the various forms which normally exist in these parts.

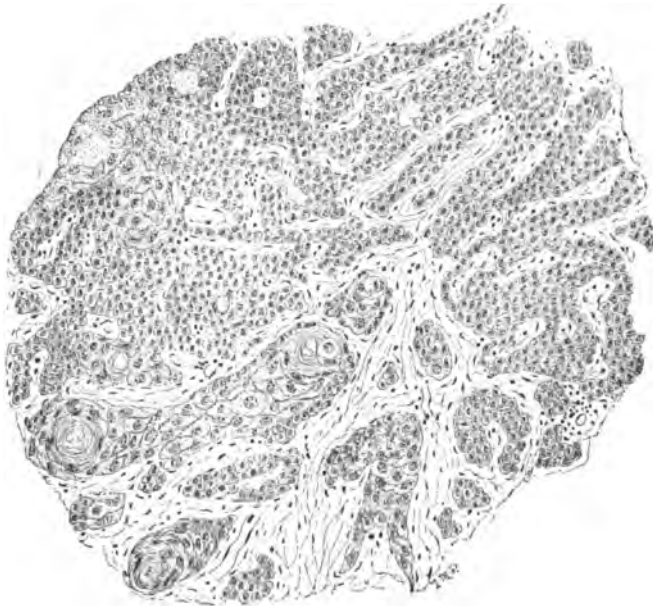

FIG. 254.—EPITHELIOMA OF THE NECK.

Shows epithelial pearls, spined cells, and reticular masses of variously shaped epithelial cells.

In order to understand the various appearances which epitheliomata present in microscopic sections, one should bear in mind the structural and functional characters of the normal squamous epithelium. The cells of the deeper layers, the rete Malpighii, are cuboidal and polyhedral; upon these are more or less flattened cells; while upon the surface the cells are thin and in the epidermis are also horny. Some of the cells are joined by the so-called "intercellular bridges"—"spinal cells," "prickle cells." This epithelium rests upon a fibrous basement substance from which its nutriment is derived.

The various forms of the cell in squamous epithelium represent regular phases of development as the younger, more succulent cells beneath are pressed outward and flatten and finally pass off upon the surface. In epitheliomata the cells have in a measure the same life history; but as they are no longer growing on free surfaces, but in enclosed, elongated spaces, they become packed in masses, the older cells being forced toward the centres. So that at length there are formed concentrically arranged cell masses, which when cut across present the dense whitish, lamellated rounded structures which have been called "epithelial pearls" (Figs. 254, 255, and 256). These epithelial pearls are not confined to these tumors, since any lesion which involves the growth of squamous epithelium into limited spaces may lead to their formation. Nevertheless their

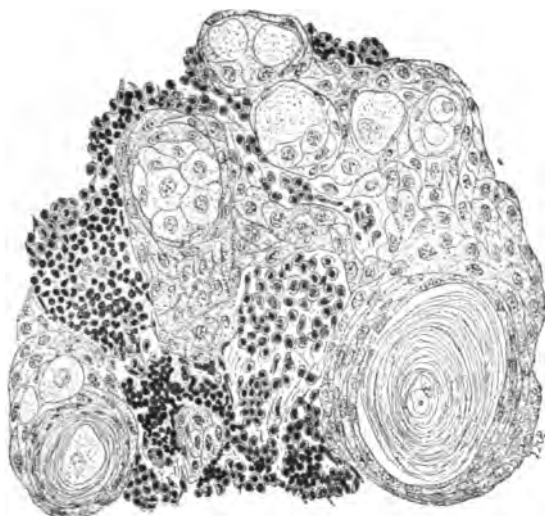

FIG. 255.—EPITHELIOMA OF AXILLARY LYMPH-NODE.

This metastatic tumor was secondary to a large epithelioma of the back of the hand. The small cells with darker nuclei are the cells of the lymph-node. It shows the epithelial pearls in various stages of formation.

occurrence in doubtful cases, as well as the presence of the intercellular bridges and marks of cornification may afford valuable diagnostic evidence of the origin of a tumor in squamous epithelium.

The new epithelial-cell groups in epithelioma may be large or small, may be separated by much or little stroma; they often form reticular masses (Fig. 257), and may infiltrate the tissues deeply or remain near the surface; or they may project above the surface, forming wart-like or papillary growths. These tumors frequently ulcerate on the surface (Fig. 252), and the skin about them is apt to become thickened (Fig. 258). The actual thickening of the skin with hyperplasia of the papillæ and of the overlying epithelium, as well as the raising of the skin at the edges of the ulcer by the tumor growth beneath, lend to such ulcerating

epitheliomata, especially of the mucous membrane, their characteristic appearance.

Epitheliomata are most apt to occur in the skin, especially in those parts in which it becomes continuous with mucous membranes—lips, external nasal openings, eyelids, labia, and glans penis—and are frequent in the mouth, œsophagus, vagina, and about the cervix uteri. They may develop in congenital nævi of the skin, such as that shown in Fig. 259. This occurrence illustrates a congenital local predisposition to tumor formation. Simple congenital nævi are sometimes mistaken

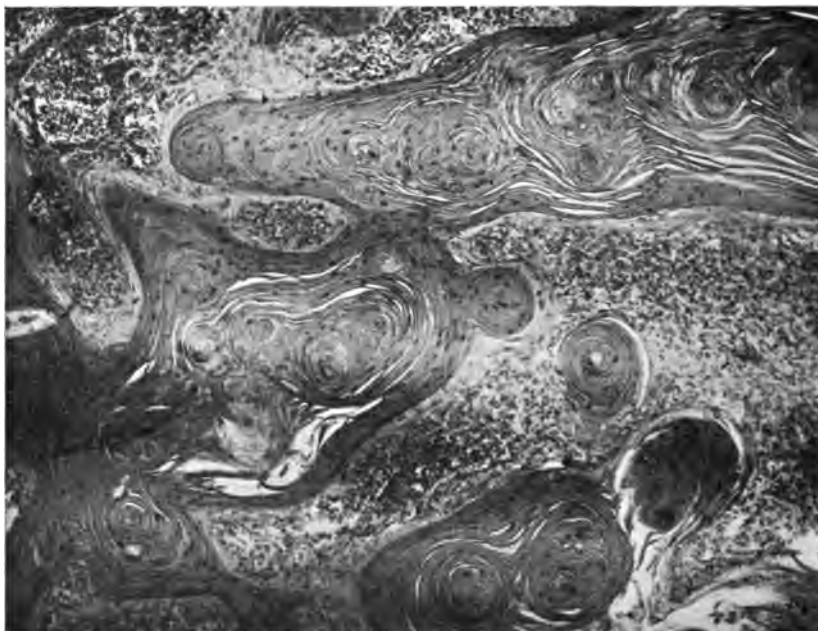

FIG. 256.—EPITHELIOMA OF THE SKIN, SHOWING MASSES OF EPITHELIAL PEARLS.
Reproduced from photograph.

for epitheliomata because of similarity in the gross appearance of certain forms.

Krompecher and others have described tumors arising in the skin and in the mucous membranes formed of squamous epithelium, or in glands which open upon these, which differ both clinically and morphologically from the epitheliomata which are in part formed from cornified cells. These tumors are made up of cells which resemble those of the rete Malpighii, or certain glands with cuboidal epithelium, such as the sweat glands, mammary glands, etc. They have been called *basal-celled epitheliomata* (see Figs. 225 and 260).

In this group are tumors of the face and nose (see Figs. 261 and 262), of the mamma, ovary, and prostate, and perhaps some of the complex

tumors of the salivary glands which have been called endothelioma, cylindroma, plexiform sarcoma, myxo-sarcoma, etc.

In these tumors the proliferated basal cells form sometimes solid

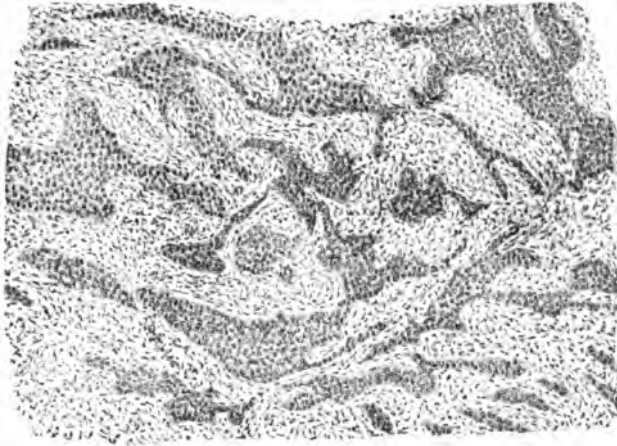


FIG. 257.—EPITHELIOMA OF SKIN.

Showing reticular masses of epithelial cells with fibrous stroma.

masses of varied shapes, sometimes gland-like or cystic structures lying in a connective-tissue stroma with which they sometimes appear to merge, and then resemble sarcoma. Various forms of degeneration of

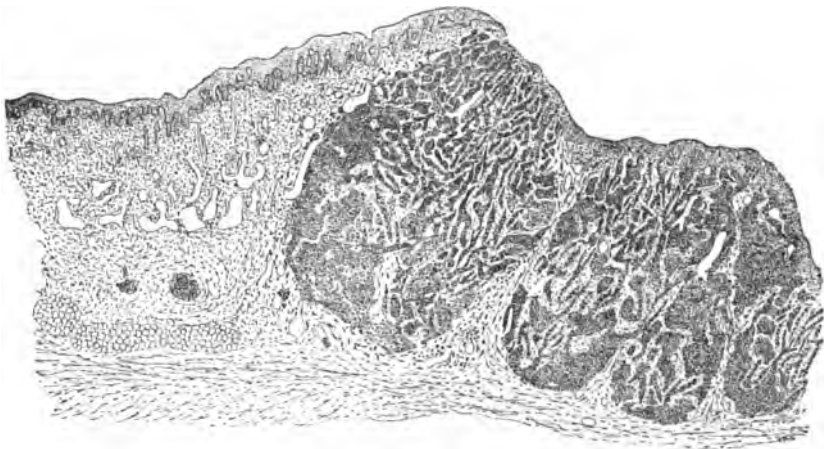


FIG. 258.—EPITHELIOMA OF BACK OF HAND.

The flat tumor occupied nearly the entire back of the hand, and was ulcerating at the surface. The figure shows the edge of the tumor and a portion of the ulcer. The papillæ of the skin over the edge of the growth are hypertrophied, and the tissue about is infiltrated with small spheroidal cells. Fig. 255 shows a section from a metastatic tumor of the axillary lymph-node in this case. This tumor presented the gross appearance shown in the photographic reproduction in Fig. 252.

the stroma occur, and this with metaplasia and the appearance of embryonal characters contribute to their complex character.¹

Giant-celled Epithelioma.—Sometimes certain of the cells in an epithelioma appear to coalesce, forming a large multinuclear mass. This variety of epithelioma is sometimes called *giant-cell epithelioma*.² Two types of giant cells may be formed (Figs. 263 and 264). In one the nucleus divides without corresponding response from the cell cytoplasm, so that a large syncytial mass is formed. In the other a true Langhans'

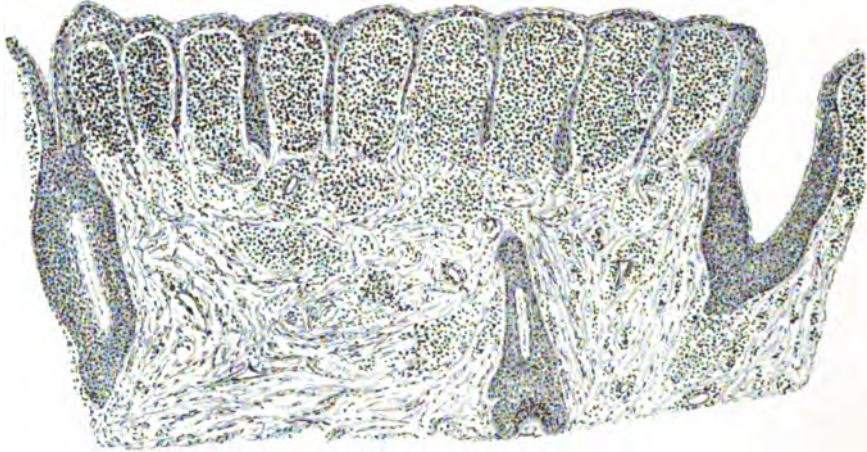


FIG. 259.—A PORTION OF A CONGENITAL NÆVUS OF THE SKIN.

Such small nœvi are sometimes mistaken for epitheliomata and occasionally afford a starting-point for the latter.

giant cell is produced, probably by fusion of a number of smaller cells, making a large cell with peripherally arranged nuclei. Both of these phenomena are apt to occur chiefly in epitheliomata growing freely through soft tissue, such as a granulating cervix uteri or an ulcerating epithelioma of the tongue.

Epitheliomata are apt to recur if not thoroughly removed, and may form metastases, but in general they are the least malignant of the carcinomata. Some of the smaller forms, especially those of the basal-celled type, may exist for years with no evident tendency to growth (Figs. 261 and 262).

Certain tumors of the retina, often classed with glioma and apparently arising from the external layers of the retina, are of ectodermal origin and are called *neuro-epitheliomata*, though they show none of the morphological characteristics of squamous epithelium.

Cylindrical-celled Carcinoma.—These tumors, closely allied to some forms of adenoma (see Fig. 246), occur in the stomach, intestines, and

¹ For further consideration of these tumors see *Krompecher*, *Ziegler's Beitr.*, Bd. xxxvii., p. 28, 1905; also his monograph "Der Basalzellen Krebs," 1903; also ref. to *Wood*, p. 651.

² For a study of giant cells in carcinoma see *Delamare* and *Lecène*, *Arch. d. méd. exp.*, t. xviii., p. 102, 1906.

uterus. The cells may be only in part cylindrical, the remainder having various shapes, and all being loosely or closely packed in larger or smaller alveoli. They may have much or little stroma. They merge imperceptibly into the next class, though rarely the two forms may exist simultaneously in the same organ and form separate metastases in the neighboring lymph-nodes.

Carcinoma Simplex.—These, which are by far the most frequent of the carcinomata of internal parts, are characterized by irregular anastomosing masses of epithelial cells, sometimes solid, sometimes with

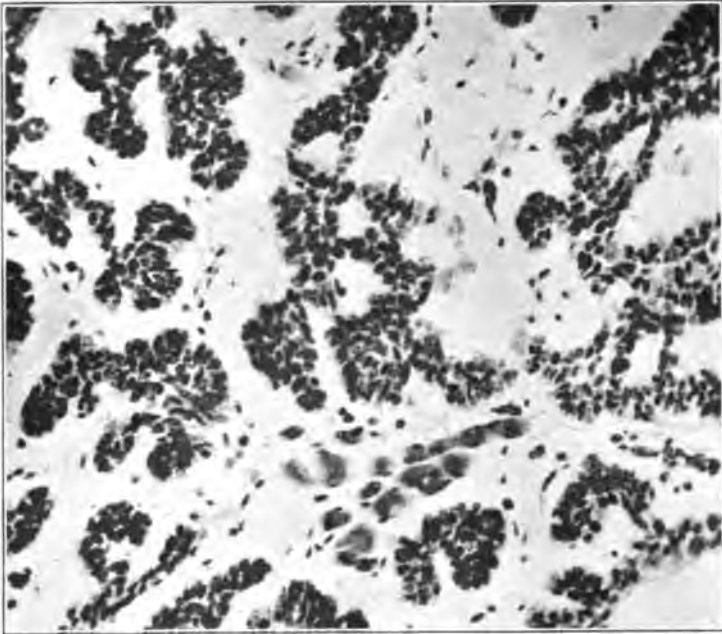


FIG. 260.—BASAL CELLED EPITHELIOMA. METASTASIS IN THE MUSCLE OF ABDOMINAL WALL.
The stroma is extremely oedematous and contains very few cells.

interior spaces recalling the lumina of glands; all enclosed by a more or less abundant fibrillar stroma. The epithelial cells have no uniform shape but may be cuboidal, polyhedral, spheroidal, or fusiform, and are often so merged that they resemble a nucleated mass of cytoplasm rather than an aggregate of cells (Fig. 265). They not infrequently undergo degeneration and softening, which, if on the surface, may lead to extensive ulcers. The cells may or may not resemble the epithelium of the gland in which they originate.

They are usually nodular tumors, and may be hard or soft. If the new-formed stroma is abundant and dense, and preponderates over the cellular elements, the tumor is usually hard and is called *scirrhus* or *fibro-carcinoma* (Fig. 266).

If, on the other hand, the cellular elements largely preponderate, the tumor is usually soft, and, if it do not contain too many blood-vessels, may have a general resemblance to brain tissue, and is then called *encephaloid* or *medullary cancer*; or, better, *carcinoma molle* (Fig. 241). These are among the most malignant of the carcinomata.

The intercellular tissue in carcinomata may become so abundant as nearly to obliterate the cellular elements, but it is doubtful if they

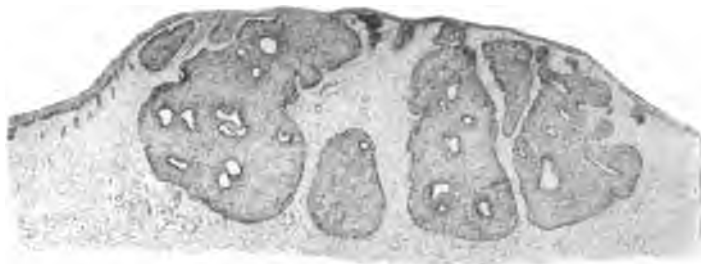

FIG. 261.—SMALL EPITHELIOMA OF THE SKIN OF THE FACE.

ever undergo spontaneous cure in this way. They may be hard in one portion and soft in another. They may contain many blood-vessels, *C. telangiectoides*. They occur as primary tumors especially in the mamma, gastro-intestinal tract, liver, kidney, pancreas, thyroid, and prostate glands, occasionally in the testicle and ovary, and very rarely in the salivary glands.

Gelatinous Carcinoma.—The cells of certain carcinomata, especially of the gastro-intestinal canal and surface of the peritoneum, may develop

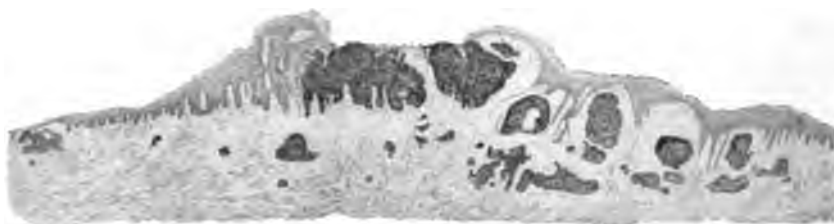

FIG. 262.—SMALL SUPERFICIAL EPITHELIOMA OF THE FACE.

a translucent gelatinous material whose nature is not well understood, which accumulates within the cells.¹ In some cases this accumulation is moderate when the protoplasm of the cells may be more or less encroached upon by the translucent droplets of the gelatinous material; but in other cases, over large areas the cells are partially or entirely destroyed, and replaced by the new material, so that the alveoli of the

¹ These tumors are often called "colloid cancers," but the material which characterizes them is not true colloid.

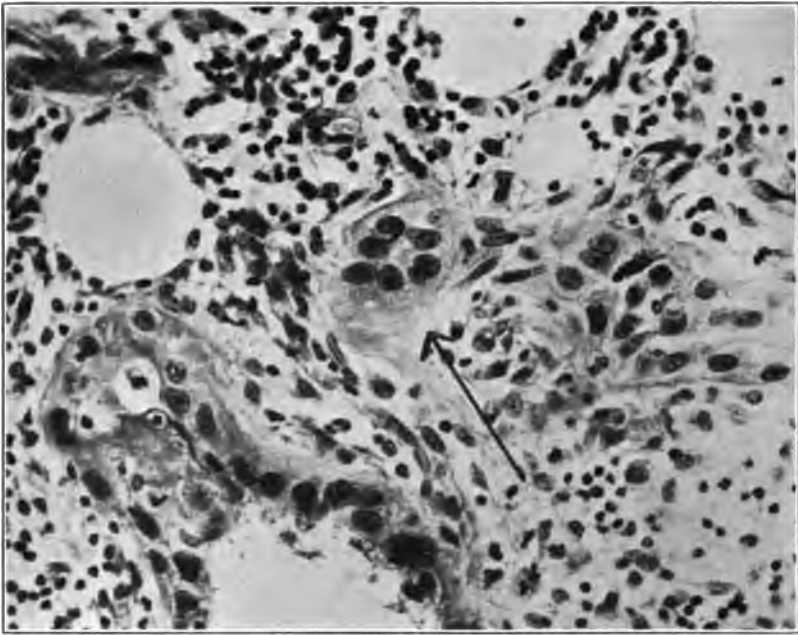


FIG. 263.—GIANT CELLS IN EPITHELIOMA.

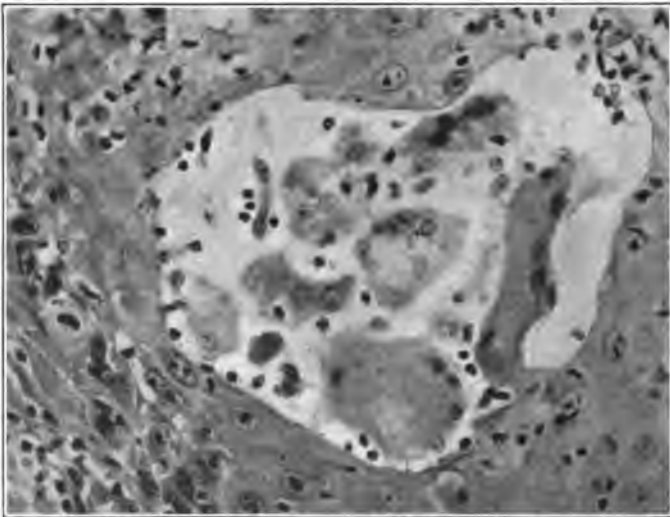


FIG. 264.—GIANT-CELLED EPITHELIOMA OF THE CERVIX UTERI.

tumor are distended by it, and their walls appear very distinct in the midst of the gelatinous substance (Fig. 267). In such cases the alveolar structure of the tumor is sometimes very evident to the naked eye, and

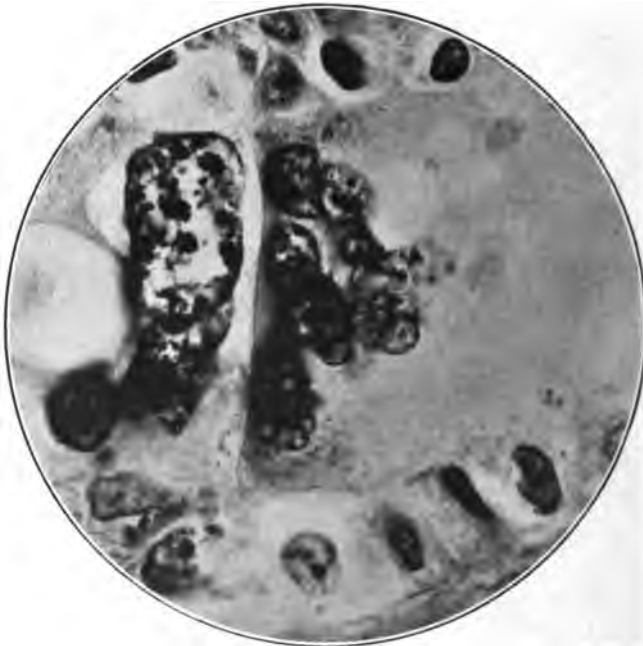

FIG. 265.—CARCINOMA OF THE BREAST. SHOWING LARGE CELLS WITH MULTIPLE NUCLEI.

these tumors are therefore often called *alveolar carcinoma*. Sometimes only a part of the tumor is affected in this way.

Carcinoma Myxomatodes.—The cellular elements of carcinomata may suffer mucous softening, and thus larger and smaller cysts containing a

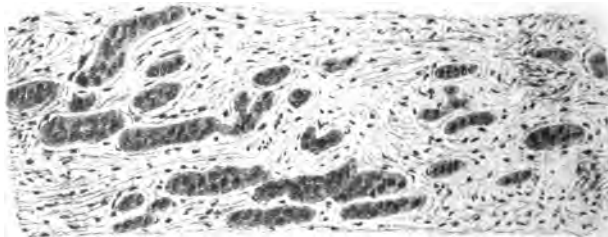


FIG. 266.—FIBRO-CARCINOMA OR CARCINOMA DURUM (SCIRRHOUS CARCINOMA).

mucous fluid are sometimes formed. To this type of metamorphosed tumor the above name is sometimes applied, but it more properly belongs to carcinomata in which the stroma is composed of mucous tissue (Fig.

268). Such tumors are most frequently found in the gastro-intestinal canal and mamma.

Melano-carcinoma.—Tumors of this class are rare, and are characterized by the presence of a variable quantity of black or brown pigment particles either in the stroma or in the cells. They are usually soft and malignant, and most frequently occur in the skin.

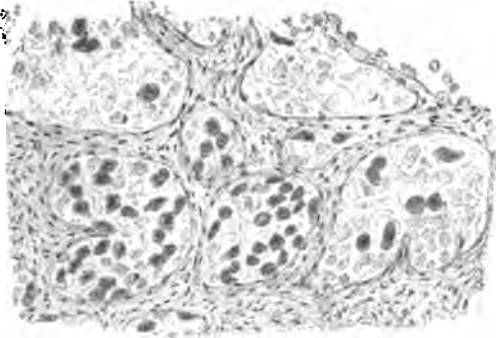


FIG. 267.—CARCINOMA GELATINOSUM—"COLLOID CANCER."
From a tumor of the stomach.

MOLLUSCUM CONTAGIOSUM is the designation of small soft multiple growths of the skin, most frequent on the face, arms, and chest, and on the external genital organs. They are lobulated and contain cells similar to those of the rete Malpighii. Within the cells and crowding the nucleus to one side, or free among the cells, are rounded or ovoid bodies which are believed by many to be protozoan parasites.

ADAMANTINOMA (*Cystadenoma adamantinum*; *Epithelioma adamantinum*).—This group of tumors is of occasional occurrence in the jaws either on the surface beneath the mucous membrane, or in the depth of the bone. They appear to be

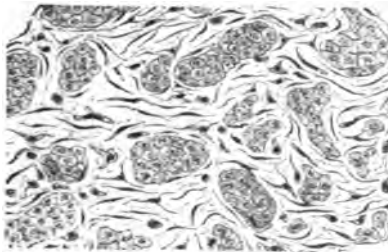


FIG. 268.—CARCINOMA MYXOMATODES.
From a tumor of the mamma.

derived from the enamel organs of developing teeth. They are frequently cystic from the softening and absorption of their tissues, and, while in general benign, may infiltrate the jaw, inducing its atrophy. They are most apt to form during the period of development of the teeth. They consist in general of a fibrillar connective-tissue stroma in which ramify irregular and complex masses of epithelial cells (see Fig. 269). These epithelial-cell masses are made up of rows of cylindrical cells or of superimposed layers of cylindrical, polyhedral, and flattened cells. Frequently these lamellæ of epithelial cells enclose a central mass of branching cells. The situation of these

tumors, their period of formation, and the resemblance of the structure to that in various phases of the evolution of the enamel organ, indicate their origin in some abnormality in the development of the teeth. There is frequently a recurrence after the removal of these tumors, and the growth may become sarcomatous.¹

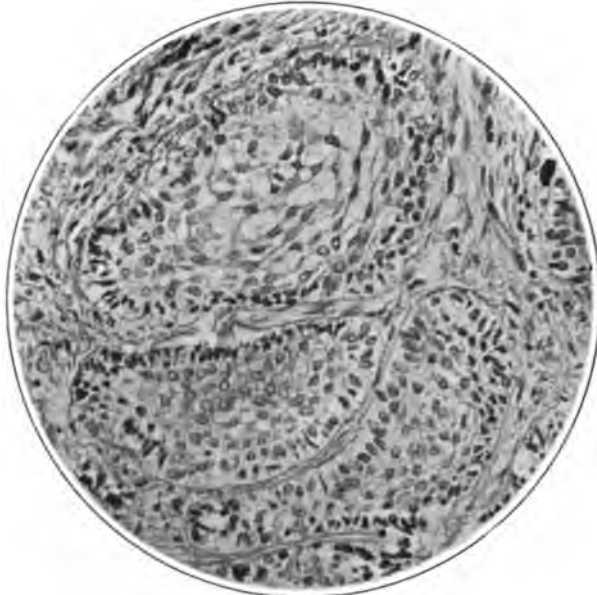

FIG. 269.—ADAMANTINOMA.

Bibliography of Tumors.

An extensive and important work on tumors, containing a vast store of information, is that of *Rudolph Virchow*, "Die krankhaften Geschwülste." It is not completed and is old, but is still invaluable as a work of reference. A valuable bibliography and digest of recent observations on tumors will be found in *Ziegler's* "Lehrbuch der path. Anat.," Bd. i., last edition. An important *résumé* on the malignant tumors in childhood, by *Stern*, may be found in the *Deutsche med. Wochenschrift*, June 2d, 1892, p. 494. "An Introduction to General Pathology," by *Sutton*, contains many suggestive facts about tumors, drawn from comparative pathology. Current additions to the subject may be found in the files of *Lubarsch* and *Ostertag's* "Ergebnisse," see particularly *Lubarsch*, Jahrg. 1, p. 289, for a comprehensive summary; also for newer bibliography to 1899, *Aschoff*, Jahrg. 5, for 1898, p. 73. *Borst's* "Lehre v. d. Geschwülsten," 1902, is a valuable work with many excellent illustrations and bibliography; as is also *Ribbert's* "Geschwulstlehre," 1904.

¹ See for a *résumé* and bibl. of these tumors *Chibret*, *Arch. de méd. exp.*, t. vi., 1894, p. 278; also *Borst*, "Geschwülste," p. 605.

CHAPTER XII.

THE LESIONS INDUCED BY POISONS.

Forms of Poisons.

A POISON has been commonly considered to be a substance which when introduced into the body from without is capable of inducing, by means other than mechanical, pathological alterations of function or structure, or both. But this conception of poisons as extraneous preformed substances has recently been greatly modified. For it has been learned that poisons may be formed within the body, either through the action of micro-organisms upon its organic constituents or through the metabolism of the body-cells themselves.

It is thus convenient in considering the lesions induced in the body by poisons—toxic lesions—to place in one group those due to preformed extraneous poisons—*exogenous poisons*—and in another group those due to substances formed within the body—*endogenous poisons*.

It has furthermore been found convenient to make three classes of the endogenous poisons: First, those which are formed under the influence of micro-organisms in the course of the acute infectious diseases and whose effects are most appropriately studied in that connection; these may be called *endogenous poisons of infectious origin*; second, those which are formed under the influence of micro-organisms in the gastrointestinal canal or elsewhere and absorbed into the body fluids; third, those which are formed by the metabolism of the body-cells themselves.

To endogenous poisoning induced by either of the latter two classes of agents the term *auto-intoxication* has been most commonly and most appropriately applied.

As we have already studied the toxic lesions of the infectious diseases, we have only to consider here:

First, the lesions induced by preformed or extraneous poison—*exogenous poisons*; and second, those due to the *endogenous poisons* which are concerned in the so-called *auto-intoxication*.¹

The Lesions Induced by Exogenous Poisons.²

Sulphuric Acid.

The effects of this poison vary with the amount taken and with its strength. Death usually occurs in from two to twenty-four hours after the ingestion of the con-

¹ The limitation of the term auto-intoxication as it is here used is adopted from *Martius*, who has written most clearly and suggestively upon the subject. See *Martius*, "Pathogenese innerer Krankheiten," Hefte i. and ii., 1899-1900.

² For special precautions to be taken in the post-mortem examination in cases of suspected poisoning see p. 1022.

concentrated acid. A case of death within an hour is recorded. When the poison is less concentrated or its effects are less intense, the patient may survive for months.

The skin of the face about the mouth may be blackened and charred by the acid.

The mouth and pharynx are of a grayish or blackish color, or are covered with a whitish layer, while the deeper tissues are reddened. Sometimes these regions escape the action of the poison.

The *larynx*, *trachea*, and *lungs* are sometimes softened and blackened by the accidental passage of the acid into them. This may take place even when the acid does not pass into the *œsophagus*.

The *œsophagus* seldom escapes. It is colored grayish or blackish, softened, and the mucous membrane comes off in shreds. If life is prolonged, cicatrices and strictures are formed. The *stomach* may contain a blackish, pulpy fluid, due to the action of the acid on mucus, blood, etc. It is coated on its internal surface with a black, sticky layer, beneath which the mucous membrane is reddened. The mucous membrane may be blackened in patches or stripes. The organ may be contracted and the mucous membrane corrugated. Sometimes perforation takes place and the acid blackens and softens the adjoining viscera. In protracted cases cicatrices are formed and the organ is contracted. If the poison is dilute there may be only the lesions of chronic gastritis.

The *blood* is sometimes thickened, syrupy, acid, and may form thrombi in the vessels.

Fatty degeneration of the renal epithelium is mentioned by some authors.

The body may be partially preserved from decomposition, owing to the action of the acid upon the tissues.

The solution of indigo in sulphuric acid, commonly known as sulphate of indigo, produces the same lesions as sulphuric acid, and also stains the tissues with which it comes in contact a dark-blue color. It is stated that an indigo-blue tint is often found in the mucous membranes after poisoning by pure sulphuric acid.

Nitric Acid.

Death may occur very soon after the taking of the poison, but is not usual until the lapse of several hours, and may not ensue for several days or weeks.

The surface of the mucous membrane of the *mouth*, *pharynx*, and *œsophagus* is covered with yellow eschars wherever the acid has touched it. Beneath and around the eschars the tissues are congested and red. The poison may reach the *œsophagus* without acting on the mouth. The *stomach* contains a viscous, sanguinolent, yellow or greenish fluid. The mucous membrane is congested, red, swollen, softened, and ecchymotic. It is rarely perforated. The *duodenum* may be inflamed, and the inflammation extend to its peritoneal coat. The rest of the intestines usually escapes the action of the acid.

The *larynx* is very frequently acted on by the acid. There are yellow eschars, congestion and swelling of the mucous membrane, sometimes œdema of the glottis. The *trachea* may be inflamed and the *lungs* congested.

If the patient survive the first effects of the poison, chronic inflammation, cicatrization, and contraction may occur.

The acid nitrate of mercury, if taken in a concentrated form into the stomach, may induce the same lesions as nitric acid.

Hydrochloric Acid.

In fatal cases death occurs on the average in about twenty-four hours. The lesions are in general similar to those produced by sulphuric and nitric acids, except that the eschars are usually of a whitish color at first, becoming, after a time, discolored and disintegrated. It is also more common to find false membranes on the inflamed surfaces.

Oxalic Acid.

In fatal cases death may occur within ten minutes (in one case it occurred in three minutes) or it may be delayed for two or three weeks. The period of death does not depend, as do in general the symptoms, upon the amount and concentration of the poison.

The mucous membrane of the *mouth*, *pharynx*, and *oesophagus* is usually white and shrivelled, and easily peeled off, and may be covered with brownish vomit from the stomach. The *oesophagus* may be much contracted. The *stomach* is usually contracted and contains a dark-brown, acid, mucous fluid. The mucous membrane of the stomach may be pale, soft, and easily detached, sometimes looking as if it had been boiled in water. Sometimes it is red and congested; sometimes blackened and gangrenous; sometimes peeled off in patches. Perforation is of rare occurrence. If life be prolonged the whitened condition of the mucous membrane is succeeded by congestion and inflammation. The *small intestines* may be inflamed. Inflammation of the *pleura* and *peritoneum*, and congestion of the *lungs* are of occasional occurrence. In some cases of death from oxalic acid there are no well-marked lesions.

Potassium oxalate produces the same lesions as oxalic acid.

Tartaric Acid.

This acid is seldom used as a poison, but in large doses may prove fatal. The lesions in the cases observed were redness and inflammation of the mucous membrane of the gastro-intestinal canal.

Potash, Soda, and their Carbonates.

These substances are not commonly used as poisons with suicidal or homicidal intent, but may be taken by mistake. They may cause death in a few hours, or life may be prolonged for several weeks.

The mucous membrane of the *mouth*, *pharynx*, *oesophagus*, and *stomach* is softened, swollen, congested, and inflamed, or may be peeled off. It may be blackened from local changes in the blood. The mucous membrane of the *larynx* and *trachea* may also be swollen and inflamed.

If life is prolonged for some time, cicatrices and strictures of the *oesophagus* and *stomach* are apt to be produced as a result of the reparative inflammation.

Ammonia.

The vapor of strong ammonia may cause death from inflammation of the larynx and air passages. The strong solution of ammonia produces lesions similar to those of potash and soda. The *larynx*, *trachea*, and *bronchi* are frequently inflamed, and may be covered with false membranes. Fatal inflammation of the rectum and colon has been produced by an enema of strong solution of ammonia.

Potassium Nitrate.

Accidental poisoning sometimes occurs from large doses of this salt. In the observed cases there were intense congestion and inflammation of the *stomach* and *intestines*, and in one case a small perforation of the stomach existed.

For the effects of several infrequently employed salts of the alkalies and alkaline earths, which for the most part produce simple inflammation of the gastro-intestinal canal, we refer to special works on toxicology.

Phosphorus.

Poisoning by phosphorus is much more common in France and Germany than in this country. Some of the forms of rat poison, of which this is a frequent ingredient,

and the ends of matches, are common media for its administration. It is more often used with suicidal than with homicidal intent.

The post-mortem appearances vary according to the length of time which elapses before death, which may be from a few hours to several months.

If death takes place in a few hours the only lesions may be those produced by the direct local action of the poison. The mouth, pharynx, and œsophagus usually escape. The stomach may be only slightly reddened, or there may be patches of inflammation and erosion. The contents of the stomach are often mixed with blood and may have the peculiar smell of phosphorus. There may be little bits of wood present when the poison has been taken from the heads of lucifer matches. It is said that the mucous membrane of the stomach may emit a phosphorescent light in the dark.

If death does not ensue until after several days the lesions are more marked. The body is usually jaundiced. There may be ecchymoses beneath the pericardium, pleura, and peritoneum, in the lungs, the kidneys, the bladder, the uterus, the muscles, and the subcutaneous connective tissue, and bloody fluid in the visceral cavities.

Chromatolysis of the ganglion cells may occur.

The *heart and voluntary muscles*, the walls of the *blood-vessels*, and the epithelium of the pulmonary air vesicles may be in the condition of fatty degeneration. The blood is usually dark and fluid.

The *stomach* sometimes presents no very striking changes. There may be small circumscribed spots of inflammation, erosion, or gangrene, and occasionally perforation. The most constant change is albuminous and fatty degeneration of the cells which line the gastric follicles. In consequence of this the mucous membranes appear thickened, opaque, of white, gray, or yellow color. The *small intestine* appears normal or is congested.

The *liver* is found in different degrees of albuminous and fatty degeneration, and is often stained yellow from the jaundice. It is usually increased in size and of a grayish-yellow or light-yellow color, unless stained by the bile. Less frequently the centres of the acini are congested, or the entire liver is congested, or there are small hæmorrhages in the liver tissue. The liver may be soft, flabby, and smaller than normal. In the interstitial tissue of the liver and along the branches of the portal vein there may be marked infiltration with small spheroidal cells.

The *kidneys* often present albuminous and fatty degeneration of the epithelium. The *mesenteric lymph-nodes* may be soft and swollen from hyperplasia.

Arsenic.

This poison is very frequently employed with suicidal intent. Death may occur in a longer or shorter time from the direct irritative effects of the poison upon the gastro-intestinal canal, with the symptoms which usually accompany the ingestion of irritant poisons; or it may occur with symptoms of collapse, or coma, or shock; or the symptoms may resemble those of cholera. The average time of death in acute fatal cases is about twenty hours, but death has occurred in twenty minutes and has been postponed for two or three weeks.

The *mouth*, *pharynx*, and *œsophagus* may be inflamed, but are more frequently unaltered. The *stomach* may be empty or contain mucus mixed with blood. The arsenic, in substance, may be found adherent to the mucous membrane or mixed with the contents of the organ. It has, in rare cases, been found encysted in the stomach in considerable quantity. When invisible to the naked eye a microscopical examination of the stomach contents will not infrequently reveal characteristic crystals of arsenious acid or some of its compounds. The stomach may be contracted and its mucous membrane corrugated. The entire inner surface may be red and inflamed, or there may be patches or streaks of inflammation or deep congestion. The inflamed and congested patches may be thickened and covered with false membrane mixed with larger and smaller particles of masses of the poison. Ulceration, perforation, and gangrene are rare. Blood may be extravasated into the mucosa and submucosa, and with the congestion give the mucous membrane a very dark-red or brown appearance.

Frequently the mucous membrane is studded with small petechiæ. Sometimes the arsenic is converted in the stomach into the yellow sulphid. There may be acute gastritis, even when the poison is absorbed by the skin or otherwise and not introduced into the stomach. The epithelium of the gastric glands may undergo granular and fatty degeneration.

The entire length of the *intestine* may be congested and inflamed, but the action of the poison does not usually extend beyond the duodenum. In some cases the *solitary lymph-nodules*, *Peyer's patches*, and the *mesenteric nodes* are swollen. Inflammation of the *bladder* and *peritoneum*, and congestion and œdema of the *brain*, have been observed, but are neither frequent nor in any way characteristic. Fatty degeneration of the *muscles*, *liver*, *kidneys*, *blood-vessels*, and *vesicular epithelium* of the *lungs* and chromatolysis of the *ganglion cells* may follow arsenical poisoning.

Alterations in the spinal cord indicative of acute myelitis have been described by Popon¹ as occurring in dogs poisoned with arsenious acid.

The walls of the stomach and intestines and other parts of the body may be preserved from decomposition for a long time after death by arsenical poisoning.

It should always be borne in mind, in examining cases of suspected arsenical poisoning, that death may be produced by arsenic and its compounds without any appreciable lesions. While in general it may be said that in the cases in which no lesions are discovered death has probably occurred soon after the ingestion of the poison, it should be remembered that death without lesions may exceptionally take place long after the usual time at which inflammatory changes commence.

Compounds of arsenic, such as the chlorid and sulphid, and the arsenite (Scheele's green, Paris green), are sometimes used for suicidal purposes, and produce lesions similar to those of arsenious acid. Paris green is a favorite article in New York, particularly among Germans, for suicidal purposes. It is usually taken in considerable quantities, and is often found in the stomach after death.²

Corrosive Sublimate.

The mucous membrane of the *mouth* and *throat* may be swollen, inflamed, or have a grayish white appearance. The *œsophagus* may be swollen and white, or congested, or unaltered. The mucous membrane of the *stomach* is usually congested or inflamed, or there may be patches of softening, ulceration, or gangrene. Perforation is of rare occurrence. Small ecchymoses in the mucosa are not uncommon. Sometimes there is little or no change in the stomach. Sometimes the mucous membrane of the stomach is slate-colored from the deposition of metallic mercury from the decomposed salt. The *intestines* may appear normal, or there may be patches of congestion and ecchymosis. The *larynx* and *trachea* may be congested.

The *kidneys* are congested, there is albuminous and fatty degeneration and necrosis of the epithelium, especially of Henle's loops and the convoluted tubules. The epithelium may desquamate and block the tubules. The glomeruli are not obviously involved. Calcification may follow the degeneration and necrosis of epithelium³ (Fig. 30).

Lead.

The different preparations of lead may prove fatal either from the immediate effect of large doses or from the gradual effects of repeated small doses. Although

¹ Popon, "Ueber die Veränderungen im Rückenmarke nach Vergiftung mit Arsen," etc., Virch. Arch., Bd. xciii., p. 351.

² It is advisable, in cases of suspected arsenic poisoning, particularly if the body has lain for some time, as in exhumations, to preserve not only all of the internal organs entire for the chemist, but also portions of the muscles (back, thigh, arm, and abdomen), and also one of the long bones, preferably the femur, since arsenious acid and its compounds are quite diffusible, and may be present in proportionately larger quantity in other parts than in the gastro-intestinal canal. It is desirable to save the whole of the internal organs, and to weigh the muscle and bones as well as the whole body at the autopsy, in order that the calculations of the chemist, in case arsenic be found, may rest upon a definite basis, and be as little as possible dependent upon estimates, whose value may be questioned by lawyers should the case come into the courts.

An interesting article on arsenic as a poison, with various collateral data by Pellew, will be found in Hamilton's "System of Legal Medicine," vol. i., p. 349.

³ For studies on the action of sublimate on the kidneys see ref. footnote, to Neuberger and to Elbe, p. 753. See also Mouisset and Mouriquand, Jour. de phys. et path. gén., t. viii., p. 292, 1906.

there may be marked symptoms during life, the post-mortem lesions are few and variable.

There may be chromatolysis of the ganglion cells.

Large doses may produce acute gastritis, and sometimes a whitening of the mucous membrane. The intestines are generally contracted, and there may be fatty degeneration of the renal epithelium; very frequently there are no appreciable lesions.

In chronic lead poisoning the intestines may be contracted, the voluntary muscles flabby and light-colored, or partially replaced by connective tissue, and there may be chronic meningitis.

Copper.

Acute poisoning by salts of copper is not very common, but it is of occasional accidental occurrence, and the salts are infrequently used with suicidal intent. The sulphate and acetate are the most important salts in this respect. Soluble salts of copper may be formed in the use of copper cooking utensils, and accidents most frequently occur in this way.

The post-mortem appearances are somewhat variable. The *pharynx* and *æso-phagus* may be somewhat inflamed or unchanged. The mucous membrane of the *stomach* and *intestines* may be inflamed, ulcerated, or gangrenous, and perforation and peritonitis may occur. The mucous membrane may have a diffuse greenish color, or particles of the salt may be found adhering to it.

Tartar Emetic.

This preparation of antimony may prove fatal when administered in a single large dose or in repeated small doses. The post-mortem lesions are not constant. In cases of chronic poisoning there are usually no appreciable lesions.

In cases of acute poisoning there may be evidence of acute inflammation of the *æso-phagus*, *stomach*, *intestines*, and *peritoneum*. Sometimes the stomach exhibits no lesions, while the intestine is involved. The *larynx* and *lungs* may be deeply congested.

Vegetable Irritants.

Aloes, *colocynth*, *gamboge*, *jalap*, *scammony*, *savin*, *croton oil*, *colchicum*, *veratria*, *hellebore*, *elaterium*, and *turpentine*.

All these drugs may produce poisonous effects. The post-mortem lesions are congestion, inflammation, and sometimes ulceration of the gastro-intestinal mucous membrane; but these lesions are sometimes present and sometimes absent.

Cantharides.

This substance may be given in powder or tincture. The entire length or only a portion of the *alimentary canal* may be congested or inflamed. There may be patches of gangrene of the mucous membrane of the *stomach*. When the poison has been taken in substance a microscopical examination of the contents of the alimentary canal or of the mucous membrane may reveal the glistening green and gold particles of the fly.

The *kidneys*, *ureters*, and *bladder* may be congested and inflamed. There is sometimes congestion of the *brain* and its membranes.

Opium and Morphin.

The post-mortem appearances in persons who have died from opium or morphin poisoning are inconstant and not characteristic. Congestion of the *brain* and its membranes, with serous effusion in the membranes and ventricles, and congestion of the *lungs*, are changes occasionally seen, but they are frequently entirely absent, and when present are not characteristic of death from this poison.

Poisonous Fungi.

The action of these substances varies greatly, and the post-mortem appearances are inconstant and not characteristic. In general, when any lesions are present they are those of gastro-intestinal irritation or of venous congestion, or both.

Microscopical examination may reveal characteristic fragments of fungi in the contents of the alimentary canal.

Hydrocyanic Acid.

This poison in fatal doses may destroy life in a very short time. The post-mortem appearances are inconstant and not characteristic. The skin may be livid and the muscles contracted. The *stomach* may be congested or normal. The most frequent internal appearances are those of general venous congestion. Under favorable conditions the odor of prussic acid may be detected in the stomach or blood or brain, or other parts of the body. It may be absent in the stomach and present in other parts of the body. If the patient have lived for some time the odor may be absent altogether.

Cyanide of potassium may produce the same lesions as hydrocyanic acid, and there is the same inconstancy in their occurrence.

Nitrobenzol.—This substance produces general venous congestion, and the odor of the oil of bitter almonds may be more or less well marked in the body after death.

Carbolic Acid.

When this poison in concentrated form is taken into the stomach the mucous membrane of the *mouth*, *oesophagus*, and *stomach* may be white, corrugated, and partially developed in patches, and the edges of the affected parts may be hyperæmic or there may be patches of extravasation. Brownish, shrunken patches may be present about the mouth. The *brain* and *meninges* may be congested. There may be congestion and œdema of the *lungs*, and congestion of the *liver* and *spleen*. The blood is usually dark and fluid. The *urine* is commonly of a dark or greenish color. The odor of the poison may be evident in the body and in the urine.

In cases which are not at once fatal the affected mucous membrane may slough, and healing follow with contraction of the stomach. Death from innutrition may follow temporary recovery after a considerable interval. If diluted carbolic acid be taken the white appearance of the mucous membrane may be absent but death may ensue with marks of necrosis, hyperæmia, and inflammation of the *oesophagus* and *stomach*.

Alcohol.

The different preparations of alcohol, when taken in concentrated form or in large quantities, sometimes produce sudden coma and death in from half an hour to several hours. In acute poisoning, if death have followed soon after the ingestion of the poison, the body may resist decomposition for an unusual length of time. The stomach and tissues may even have a more or less well-marked alcoholic odor. The *stomach*, and even the *oesophagus* and *duodenum*, may be of a deep-red color. There may be punctiform ecchymoses in the gastric mucous membrane. In many cases the stomach is apparently quite normal. There is apt to be venous congestion in some of the internal organs, but this is not constant. There are frequently congestion, and sometimes extravasation of blood in the *brain* and its *membranes*, and œdema of the membranes or of the brain substance, or both. There may be a serous effusion in the ventricles of the brain, also chromatolysis of the ganglion cells.

In chronic alcohol poisoning death may ensue from some other disease, or after a debauch. In the latter case there may be *delirium tremens*, or the patient dies exhausted and comatose. Chronic alcoholism is not infrequently mistaken clinically for meningitis. The post-mortem lesions are sometimes marked, sometimes absent. There may be chronic pachymeningitis, resulting in thickening of the *dura mater* and

its close adherence to the skull. The *pia mater* may be thickened and œdematous. The *brain* may be normal or œdematous or atrophied and show chromatolysis of the ganglion cells. The *lungs* are frequently congested. The heart may be thickly covered with fat, and its walls may be flabby and fatty. The *stomach* frequently presents the lesions of chronic gastritis. The *liver* may be cirrhotic, with or without fatty infiltration. The *kidneys* may present the lesions of albuminous or fatty degeneration or of chronic diffuse nephritis.

It should always be remembered, however, that all or a part of the above lesions may be absent in the bodies of drunkards, and, furthermore, that the same lesions may be due to other causes.

Chloroform.

Chloroform may cause death when it is taken in fluid form into the stomach or when inhaled. Death from swallowing liquid chloroform is rare, and its immediate cause is usually uncertain. The post-mortem changes are variable; sometimes there are no lesions. In some cases there is simple reddening of the gastric mucous membrane; occasionally there is acute gastritis or ulceration of the mucous membrane. The odor of chloroform may or may not be evident. Discoloration and softening of the mucous membrane of the pharynx, œsophagus, and duodenum have been observed. There may be general venous congestion; the heart may be flabby. Bubbles of gas have been frequently seen in the blood, but this is not characteristic. Degeneration and necrosis of the liver cells may follow chloroform administration (see page 716).

Death from inhalation of chloroform is a not infrequent accident in surgical practice. After death from inhalation the results of the examination are usually quite negative, and in no case are there lesions which in themselves enable the examiner to declare death to have been due to chloroform poisoning.

Ether.

The inhalation of ether occasionally causes death. The post-mortem examination is negative. The ingestion of fluid ether may induce inflammation of the stomach. The odor of ether may be perceptible if the autopsy is made soon after death.

Chloral Hydrate.

There are no characteristic post-mortem appearances after death by chloral. Hyperæmia of the brain, and the odor of the drug, have been noticed.

Strychnin—Nux Vomica.

The post-mortem appearances after poisoning by these drugs are not characteristic and are inconstant. The body is usually relaxed at the time of death, but the rigor mortis, as a rule, comes on early and remains long. There may be congestion of the *brain* and *spinal cord*, and sometimes of the *lungs* and *stomach*. Chromatolysis of the ganglion cells is recorded.

Animal Venom, Etc.

The poisons which may be introduced into the body through the bites of venomous snakes and reptiles and the bites of insects cannot be considered in detail here.¹

The action of the venom of snakes, scorpions, etc., upon the animal body, is in many respects similar to that of certain bacterial toxins and cytolytic substances. By gradual adaptation of the lower animals to these venoms, antivenoms, i. e. *antivenins*, may be secured.

Our knowledge of snake venom and especially of cobra venom is the most extensive. Snake venom contains toxins of several kinds, hæmolytic, neurolytic, nephrolytic.

¹ Consult Langmann, "Poisonous Snakes and Snake Poison," Medical Record, vol. lviii., p. 401, 1900; also Brown, "Twentieth Century Practice," vol. xx., bibl.

etc.¹ Some of these toxins seem to require the presence of complement to secure their hæmolytic action upon the red blood cells. Furthermore this complement may, as it would appear, be furthered by the red blood cells themselves—endocomplement. It is conjectured that in this case the lecithin of the red cells may act as complement.²

Abrin and ricin are examples of poisonous substances which induce in the body lesions similar to those in certain infectious diseases (see p. 203).

Carbonic Oxide.

This is one of the gases generated in the burning of charcoal, and forms one of the ingredients of illuminating gas. A most characteristic post-mortem appearance is the cherry-red color of the *blood*, and of the tissues and viscera which contain blood. The presence of carbonic acid in the gas may obscure the bright red of the carbonic oxide by the dark color which it induces in the blood, so that spectroscopic or other tests are sometimes necessary for its detection.

There may be œdema and hyperæmia with hæmorrhage in the brain and meninges. There may be hæmorrhages, often symmetrical, in the basal ganglia and in the internal capsule. Or there may be areas of softening in the brain and cord. In some cases there appear to be hyaline thrombi formed of red blood cells in the vessels of the central nervous system as well as in the other viscera, to which, in part at least, the hæmorrhages and softening may be attributed.³ Some of them may, however, be due to direct action of the poison.

Recovery from carbonic-oxide poisoning in cases not immediately fatal is often slow, and various serious disturbances of the nervous system may accompany it. Any apparent speedy recovery may be followed by the development of nerve lesions which in a longer or a shorter time may prove fatal. In cases in which death follows several weeks after the poisoning the areas of softening, often especially marked in or near the internal capsule,⁴ may show secondary changes due to absorption of degenerated material, growth of connective tissue, etc.

The lesions are essentially those of asphyxia, but the brain is said to be more frequently congested than in asphyxia by simple obstruction of respiration.

Conium, Aconite, Lobelia Inflata, Digitalis, Stramonium.

These vegetable poisons are administered in their natural form of leaves, berries, and roots, or in tinctures, infusions, and extracts, or in the form of their active alkaloid principles.

If the leaves, berries, or seeds are given they may be detected in the contents of the alimentary canal by microscopical examination. Otherwise the results of autopsies are not characteristic.

The *brain* and its membranes, and the lungs, may be congested. The *stomach* may present patches of congestion, inflammation, and extravasation, or its entire mucous coat may be inflamed, or it may appear normal.

Ptomains and Other Putrefactive Products.

Poisonous substances of various kinds are often developed in the putrefaction of organic substances, and certain alkaloidal substances called ptomains form in the decomposition of proteids without putrefaction. Thus in sausages, some kinds of cheese, ice-cream, decayed fish and mussels, such substances have caused serious and even fatal poisoning. There are no characteristic post-mortem changes in poisoning by these substances. But the lesions of gastro-intestinal inflammation or toxæmia may be present.

¹ *Flemer and Noguchi*, Jour. Exp. Med., vi., 278, 1901-1905.

² *Keyes*, Berl. klin. Wochenschr., xxxix, 886, 1902.

³ See *Schmidtman*, "Gerichtl. Med.," 9th ed., *Casper-Liman*., Bd. i., p. 872, 1905.

⁴ For a consideration of the reasons for the localization of secondary lesions of CO poisoning in the basal ganglia see *Hoffmann's* "Gerichtl. Med.," 9th ed., p. 739, 1903.

For a study of the blood supply of the basal ganglia see *Kolisko*, Wiener klin. Wochenschr., 1893, No. 11

These alkaloidal substances may be of extreme importance in certain cases of death from obscure causes on account of the medico-legal questions which may arise.¹

Bibliography of Poisons.

For a more detailed consideration of poisons, their effects, modes of detection, etc. consult the great work of *Kobert*, "Lehrbuch der Intoxikationen," or the following: *Taylor* on Poisons; *Maschka's* "Handbuch der gerichtlichen Medicin," Bd. ii.; *Woodman* and *Tidy*, "Forensic Medicine"; *Hoffmann's* "Lehrbuch d. gerichtlichen Medicin." *Wormley's* "Micro-chemistry of Poisons" contains a series of good plates of the microscopical appearance of various forms of crystals of poisonous substances. *Peterson* and *Haines's* "Textbook of Legal Medicine and Toxicology," 1904, may also be consulted.

Lesser's "Atlas der gerichtlichen Medicin" contains a series of colored plates showing the appearance of the stomach after the action of various poisons. The work of *Guy* and *Ferrier* on "Forensic Medicine," 7th ed., revised by *Smith*, contains in very compact and reliable form much information on the general subjects treated in the foregoing section. *Lewin's* "Lehrbuch der Toxicologie" contains many valuable and suggestive general considerations on the action of poisons. *Schmidtman's* "Handbuch d. gerichtlichen Medicin," 1905, is the last and 9th edition of the standard work of Casper-Liman and contains much valuable lore.

Lesions Induced by Endogenous Poisons—Auto-Intoxications.

As we turn now from poisons formed outside of the body to those formed within it—the *endogenous poisons*—we encounter two classes:
I. Those poisons which arise from the metabolism of micro-organisms.
II. Those which arise from the normal or aberrant metabolism of the body-cells themselves.

I. ENDOGENOUS POISONS FORMED LARGELY UNDER THE INFLUENCE OF MICRO-ORGANISMS.²

1. Those which are formed in infectious diseases (see Chapter IX., Part I., on Infectious Diseases).

2. Those formed in the body without infection.

The most common and important metabolic poisons of this class are those which are formed in the gastro-intestinal canal through the action of micro-organisms, mostly bacteria, upon the organic constituents of the intestinal contents and secretions. The new chemical substances thus formed become deleterious when absorbed into the body fluids, and this may occur either when they are produced in unusual quantity or when their elimination with the excreta is interfered with. When absorbed, some of these poisons may be demonstrable in the urine, and they may give rise to a variety of symptoms which cannot be considered here, but which are appropriately designated as marks of *enterogenic auto-intoxication*.³ Such are dizziness, headache, some forms of tetany, gastro-enteritis, etc.

¹ For chemical aspects of this subject consult *Vaughn* in Hamilton's "System of Legal Medicine," vol. i., p. 475, and *Vaughn* and *Novy*, "Cellular Toxins"; also *Vaughn* in "Twentieth Century Practice," vol. xiii.

² Consult in connection with this and the following section *Herter*, "Chemical Pathology," also *Wells*, "Chemical Pathology," and *Taylor* on "Auto-intoxication," in Osler's Modern Medicine, vol. i.

³ It is the opinion of some pathologists that the term *auto-intoxication* should be strictly limited to the effects of those substances which are actually derived from the cells of the body; that these alone are truly endogenous: that intoxication by bacterial products is not auto-intoxication. This is no doubt a just opinion. But the term has been used so long and so generally in its wider sense that the writer does not deem it practicable now to attempt a reform.

Endogenous poisons analogous in origin with these may be formed in the bladder, in putrid abscesses, or in necrotic tissues in various parts of the body. Structural lesions, if such there be, occurring under these conditions, are as yet but little known.

II. ENDOGENOUS POISONS FORMED BY THE BODY-CELLS—HISTOGENIC POISONS.

It is only within the past few years that the studies on cell metabolism have led to the belief that the body-cells may not only under occasional abnormal conditions form poisonous chemical compounds, but that even in the normal processes some of the intermediary metabolic products may be inimical to the welfare of the body, if they be not constantly rendered inert. This may be affected either by excretion or, as now seems probable, in part at least through the influence of what have been called the "internal secretions" of such glands as the thyroid, pancreas, adrenals, hypophysis, etc., or possibly in ways as yet wholly unknown.

Thus there is a group of auto-intoxications due to the accumulation in the body of the products of normal metabolism through defects in the excretory apparatus; for example, uræmia in renal insufficiency or retention of urine; cholæmia in retention of bile; carbonic-acid poisoning in various forms and grades of asphyxia. Possibly some of the serious symptoms following extensive burns of the skin and occurring in sun-stroke and eclampsia are of similar origin. This may be called *auto-intoxication through retention*.

On the other hand, there is a group of auto-intoxications which it is assumed may in part at least be due to a failure of the organs concerned with the internal secretions to furnish the necessary link in the chain of intermediary metabolic products. In this group may be placed cachexia strumipriva and myxœdema, pancreatic diabetes, Addison's disease, and possibly some forms of acute yellow atrophy of the liver.

While the nature and action of the recently discovered internal secretions are still obscure, they do exist and are of extreme importance in the subtle adjustments of individual cell metabolism to the welfare of the organism as a whole, and there is abundant reason to believe that, when this adjustment is disturbed, forms of histogenic auto-intoxication may arise.

At any rate the hypotheses which have been formed in the new light have contributed largely to our understanding of a series of important general diseases. These diseases, whether involving or not internal secretions in accordance with our present conceptions, may be considered as *dyscrasic auto-intoxications*.¹

Whether gout, oxaluria, and some forms of simple diabetes should be considered as auto-intoxications may be questioned. Probably Basedow's disease and some forms of puerperal eclampsia (see p. 717) should be regarded as involving the formation and retention of histogenic poisons.

¹ For a discussion of internal secretions, with bibliography, consult Transactions of the Congress of American Physicians and Surgeons, vol. iv., 1897; see also *Starling*, Chemical Correlation of Functions of the Body," Lancet, 1905, ii., and Harvey Lectures, 1907-8.

Of course this grouping of diverse forms of disease should be considered as only tentative and suggestive. And it may well be doubted whether analogy may not be often overstrained in regarding as the effect of poisons what may, after all, be metabolic aberrancies of far more subtle character than the word *auto-intoxication* would imply.

It should be borne in mind that in but a very small proportion of the abnormal processes which are considered auto-intoxications have the assumed poisons been actually demonstrated. The assumption rests largely upon symptoms which are regarded as analogous with those incited by known exogenous poisons. It is wise to remember also that even in poisoning by well-defined agents whose general effects have long been known we are almost totally ignorant, except in the case of the so-called destructive or corrosive poisons, of the exact ways in which they act. A few induce changes in the blood; many appear to act upon the nerve cells; but the nature of this action is still unknown.¹

Without insisting upon the advantages of such a grouping as has been outlined above, and with the full recognition of its incompleteness, the more important of the so-called "general diseases," some of which may be regarded as auto-intoxications, will be considered in the next chapter.

¹ For convenience of reference, the grouping of poisons briefly set forth above may be tabulated as follows:

I. Exogenous poisons	Inorganic and organic.			
II. Endogenous poisons—concerned in autochthonous or endogenic poisoning—auto-intoxication.	<table> <tr> <td rowspan="2"> { Endogeneous poisons formed largely by micro-organisms. </td> <td rowspan="2"> { A. In infectious diseases. B. Without infection, largely enterogenic. </td> </tr> <tr> <td> { Endogenous poisons formed under the influence of or by the body-cells—<i>histogenic poisons</i>—inducing <i>auto-intoxication</i> in the more limited sense. </td> </tr> </table>	{ Endogeneous poisons formed largely by micro-organisms.	{ A. In infectious diseases. B. Without infection, largely enterogenic.	{ Endogenous poisons formed under the influence of or by the body-cells— <i>histogenic poisons</i> —inducing <i>auto-intoxication</i> in the more limited sense.
{ Endogeneous poisons formed largely by micro-organisms.	{ A. In infectious diseases. B. Without infection, largely enterogenic.			
		{ Endogenous poisons formed under the influence of or by the body-cells— <i>histogenic poisons</i> —inducing <i>auto-intoxication</i> in the more limited sense.		

CHAPTER XIII.

GENERAL DISEASES.

In the so-called general diseases, various parts of the body are structurally or functionally involved, but there is usually a primary lesion in some special organ. The grouping of certain diseases under this heading is rather for convenience than because these diseases are fundamentally different in their relations to the body as a whole from many others, such as infections, intoxications, etc. Fever, which is so often one of the manifestations of toxæmia, has been grouped with the general diseases, because in some respects it presents important analogies with them.

CACHEXIA STRUMIPRIVA—MYXEDEMA.

The thyroid is one of the so-called ductless glands which furnishes internal secretions essential to normal metabolism in the body.

Removal or destructive lesions of this gland, both in man and the lower animals,¹ may be followed by serious and fatal disease characterized as *cachexia strumipriva*. In man the more common manifestation of this disease is called *Myxedema*. It occurs most frequently in middle-aged women.

The skin of the face is apt to be swollen and waxy, giving a peculiar and rather characteristic appearance to the features, (Fig. 270). The skin of the body is apt to be dry and rough, and the hair may fall out. Perspiration is, as a rule, diminished. The mental condition is dull, and loss of memory and insanity may occur. Bodily movement and speech are apt to be impaired. The fat tissues may be atrophic, and the subcutaneous tissue has been shown in some, though not all, of the cases to contain an unusual amount of mucin. In some cases the fibres of the upper layers of the corium are crowded apart by fluid.

The most marked and constant lesion in this disease is an atrophic condition of the thyroid gland. The parenchyma of the gland is more or less completely replaced by fibrillar connective tissue, and by new-formed reticular tissue resembling the lymphatic tissue of the lymph-nodes. The general appearance of the atrophied thyroid gland is shown in Fig. 272.

In addition to the lesion of the thyroid there are apt to be chronic endarteritis and chronic diffuse nephritis. In some cases there is an accumulation of small spheroidal cells about the smaller blood-vessels in various parts of the body, and also petechial hæmorrhages.

If the thyroid be completely removed in young animals there is deficient development of the osseous system, while in man the frequent

¹ For an extensive critical and experimental study of this subject see *Cunningham*. "Experimental Thyroidism," *Jour. Exp. Med.*, vol. iii., p. 147, 1898, bibliography. For a study of the transplantation of the thyroid see *Papp*, *Arch. f. klin. Chirurgie*, Bd. lxxx., 1906.

association of cretinism with goitre or other thyroid lesions indicates in another way the close relationship between the thyroid and cell metabolism.¹

Cretinism is a congenital condition in which development is retarded and faulty. An adult in years is often infantile or childish in stature and mental capacity, ill formed and uncouth (see Fig. 271).



FIG. 270.—MYXŒDEMA.
Showing "puffy" skin of face and falling of the hair—case of Dr. Henry Hun.

The nature of the substances composing the internal secretions of the thyroid is little understood, but the wonderful therapeutic effects of the administration of the extract of the gland in cases of myxœdema and in cretins, in which they are deficient, make clear their great importance. Whether directly toxic substances are formed in the thyroid or not, it seems proper to consider the cachexia strumipriva as due directly or indirectly to auto-intoxication.

¹ Consult *Oster*, "Sporadic Cretinism in America," *Trans. of the Congress of American Physicians and Surgeons*, vol. iv., p. 169, 1897.

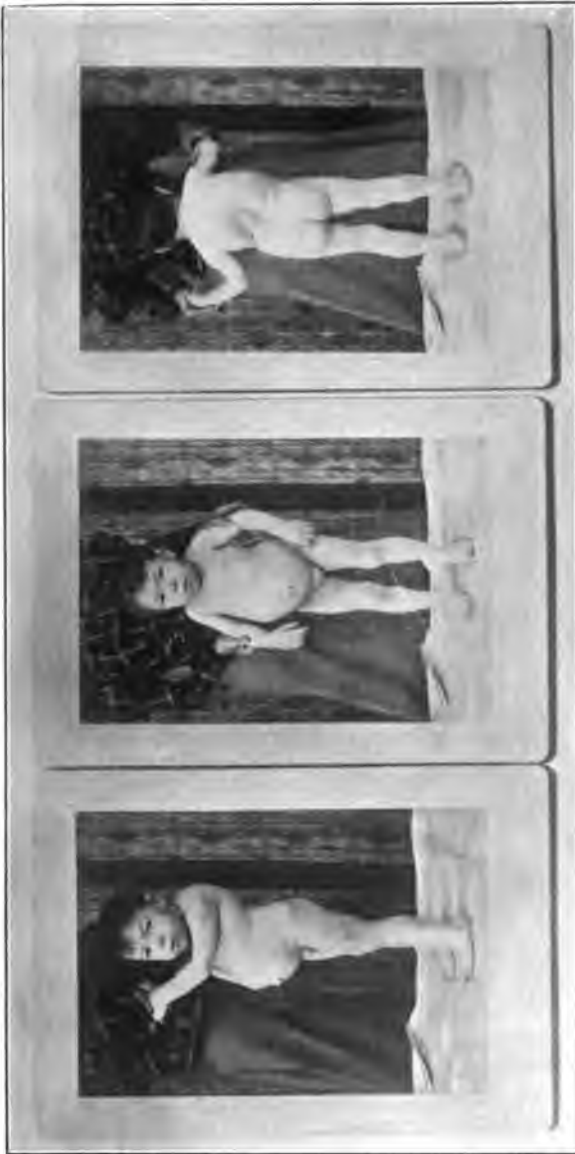

FIG. 271.—A. CARTIN.
About twenty years of age.

EXOPHTHALMIC GOITRE. (Basedow's Disease, Graves' Disease.)

The characteristic general lesions of this disease are unilateral or bilateral enlargement, largely hyperæmic, of the thyroid gland and protrusion of the eyeballs—exophthalmos. These lesions are apt to be associated with functional disturbance of the heart—tachycardia and muscular tremor. There is reason to believe that this condition is due to hypersecretion of the thyroid gland, and that its functional characteristics may be properly regarded as indications of an auto-intoxication.

Ewing¹ has described the following lesions of the thyroid occurring in early and late stages of Graves' disease: Hyperæmia with increased secretion of colloid showing diminished staining reaction with eosin;

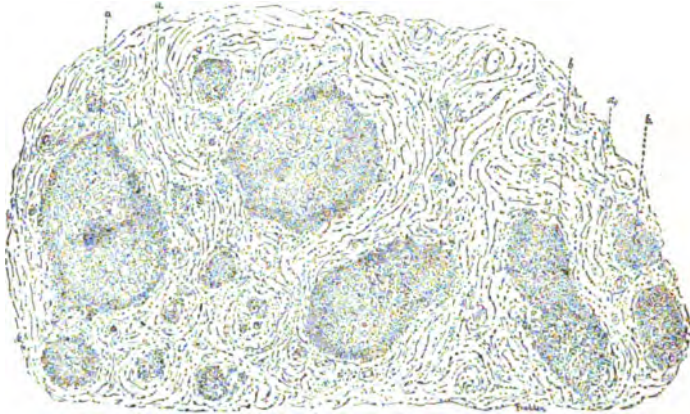


FIG. 272.—SECTION OF THE ATROPHIED THYROID GLAND IN MYXŒDEMA.

a, Interstitial tissue; b, atrophied lobules with small spheroidal-celled or lymphatic tissue in their peripheries.

increased vascularity, abundance of abnormal colloid, and cellular hyperplasia; varicosities of large vessels and diminished capillary circulation; comparative or complete absence of colloid, extensive cellular hyperplasia, occasionally fibrosis; atrophy and fibrosis, with hyaline changes in the stroma, sclerosis of vessels, hæmorrhages, and cyst formation.

Ewing regards as specific to Graves' disease, and not occurring in simple goitre, the extensive cellular hyperplasia, with large areas of imperfectly formed alveoli lined by multiple rows of large cells interspersed with giant cells, and resulting in nearly complete loss of colloid, which occurs in connection with the nervous symptoms.

The alterations in the alveoli of the thyroid are marked chiefly by variations in size and form. The epithelium grows into folded diverticulum-like structures which may become contracted, in places forming new alveoli.² The epithelium may show mitoses and may assume cylindrical forms. In general the lesion resembles that obtained in experimental compensatory hypertrophy of the thyroid.

¹ Ewing, *Trans. Assn. Amer. Phys.*, vol. xxi., p. 567, 1906.

² See MacCallum, *Bull. Johns Hopkins Hosp.*, vol. xvi., p. 287, 1905.

The effects of overdoses of thyroid extract upon the normal organism, in inducing some of the general symptoms of exophthalmic goitre; the beneficent effects of thyroidectomy in the disease; and the cellular hyperplasia above noted are the chief reasons for the belief that this disease is largely due to excessive secretion of the thyroid gland.

ADDISON'S DISEASE.

This name is applied to a disease especially characterized morphologically by a peculiar pigmentation of the skin and by certain changes, morphological or functional, in the adrenals. The patients suffer from cerebral symptoms, great prostration, syncope, and derangements of the functions of the stomach and intestines.

The pigmentation of the skin is the symptom which has especially attracted attention. The change in color usually begins and becomes most marked in those parts of the skin which are not covered by the clothing or are naturally of darker color. The rest of the skin afterward changes color, but not uniformly, white patches being left. The color is at first a light yellow or brown; this becomes darker until it is of a dark greenish, grayish, or blackish brown. The mucous membrane of the tongue, lips, and gums may be similarly pigmented.

Under the name of Addison's disease different observers have described cases in which the symptoms and bronzed skin existed without disease of the adrenals; cases in which the bronzed skin was the only lesion; and cases in which the adrenals were diseased without symptoms or bronzed skin.

The Skin.—The discoloration of the skin is due to a deposit of yellowish brown pigment in the deeper layers of the epidermis, especially in the layer covering the papillæ, and less constantly in the connective tissue of the cutis.

The Brain.—Pigmentation of the gray matter, acute meningitis, chronic meningitis, and distention of the ventricles with serum have been observed.

The sympathetic nerves, especially those which are in contact with the adrenals, may show a variety of changes apparently due to chronic inflammation. Various changes in the nerve cells of the semilunar ganglia have been described.

There may be fatty degeneration of the heart muscles and hyperplasia of the intestinal lymph-nodules and spleen.

The Adrenals.—The most common lesion of these bodies is a tuberculous inflammation, and this or some other lesion has been found in nearly one-half of the cases. On the other hand, it should be remembered that similar lesions of the adrenals often occur without other indications of Addison's disease. Tuberculous adrenals may be large, hard, and nodular; less frequently of normal size or smaller than normal. On section they may contain cheesy masses surrounded by zones of gray, semitranslucent tissue. Later the cheesy masses may become calcified or they may

soften and break down. The grayish zones are composed of tubercle tissue or denser connective tissue.¹

Other cases have been described in which the adrenals were the seat of carcinoma or of fatty or waxy degeneration. But these lesions, especially carcinoma of the adrenals, may occur without the manifestations of Addison's disease. The adrenals may be atrophied. They may, however, be normal, and in some such cases lesions of the semilunar and other sympathetic ganglia have been found.

On the whole, the clinical, morphological, and experimental data now available seem to point to lesions of both the sympathetic system and the adrenals as of probable significance in determining this disease.

The hypothesis which is most in favor at present assumes that the adrenals furnish an internal secretion without which normal metabolism cannot be effected, and that lesions of the adrenals or of the sympathetic ganglia and vessels about them, by altering or diminishing this secretion, may lead to the functional and structural changes characterizing the disease. The propriety of considering Addison's disease as an example of auto-intoxication can hardly be questioned in the light of the facts now at our command. It is clear that the adrenals contain very powerful chemical substances which have a marked effect upon certain tissues of the body,² especially upon the muscles. The action of extracts of the adrenals upon the muscle fibres of arteries leads to an increase in blood pressure. The relationship between the medulla of the adrenals and the sympathetic is apparently intimate but is as yet obscure. Complete removal of the adrenals is fatal. Injections of the extracts after removal of the organs fails to maintain life.

DIABETES MELLITUS.

This disease involves such defects in nutrition as lead to an abnormal accumulation of sugar in the blood and its discharge by the urine (glycosuria), which is increased in amount.³

A great variety of lesions have been found in the body after death from diabetes, but few of them, aside from those of the pancreas appear to be of well-defined significance in this special relationship. The general condition of malnutrition and debility, so often marked in this disease, renders diabetics especially vulnerable to slight injuries or infections, furunculosis, carbuncle, eczema, etc.; gangrene is liable to occur either with or without marked injury in cases of diabetes.⁴

The *brain* may appear to be entirely normal; it may be congested; there may be an increase of serum; the convolutions may be shrunken; there may be meningitis; there may be dilatations of the blood-vessels, small extravasations of blood around the vessels, enlargement of the

¹ For a study of experimental tuberculosis of the adrenals and its relations to Addison's disease see *de Vecchi*, *Cent. f. allg. Path.*, Bd. xii., p. 577, 1901.

² For a summary of observations on the effects of removal of suprarenal body and the nature of its "active principle," consult *Abel*, "Vaughan Anniversary Contributions to Medical Research," 1903, p. 139, bibl.

³ For a *résumé* of metabolism in diabetes, see *Lusk*, *Harvey Lectures*, 1908-9, bibl.

⁴ For bibliography of diabetic gangrene consult *Davis*, *Jour. Amer. Med. Assn.*, July 16th, 1898.

perivascular spaces, and alterations in the perivascular sheaths and nerve tissue bounding the cavities; there may be tumors at the base of the brain.

The *spinal cord* may present dilatation of the blood-vessels; dilatation of the central canal; changes in the gray matter of the anterior cornua. Marks of multiple neuritis and lesions of the sympathetic ganglia may be present. The *Lungs*.—There may be the lesions of pleurisy, bronchitis, broncho-pneumonia, lobar pneumonia, gangrene, tuberculosis. The *heart* may be small or hypertrophied; there may be chronic endocarditis. The *Stomach and Intestines*.—The stomach may be dilated, its walls may be thickened, there may be hæmorrhagic erosions of the mucous membrane. In the intestines there may be tuberculous ulcers or enteritis. The *liver* may be cirrhotic or fatty, or glyco-genic infiltration may occur. The *kidneys* may be enlarged; they may be the seat of albuminous degeneration or diffuse nephritis; there may be glyco-genic infiltration of the epithelium of Henle's loops. The *Blood*.—In a few cases fat has been found in the blood, and fat emboli in the vessels of the lungs.

The *Pancreas*.—In a considerable proportion of cases the examination of the pancreas reveals some lesion, usually atrophy of the parenchyma, often with increase of the interstitial tissue. Hyaline degeneration and interstitial inflammation involving the islands of Langerhans have been assumed to be of much significance,¹ but this is not yet clearly established. Fatty degeneration, tumors, and cysts have been found. Extirpation of the pancreas in man or dogs may lead to diabetes. While diabetes may occur without demonstrable lesions of the pancreas, it is fair to assume that functional lesions of grave importance may nevertheless be present.

Diabetes mellitus may be associated with hæmachromatosis and cirrhosis of the liver—so-called "bronzed diabetes."²

Under the influence of the doctrine of internal secretions it is now commonly assumed that the pancreas, in addition to its intestinal secretion, furnishes some other substance to the body which is essential in the metabolic changes to which the carbohydrates and proteids must be subjected in securing normal nutrition.³ Interference with this internal secretion of the pancreas is thus assumed to be accountable for the faulty metabolism.⁴

GOUT.

The characteristic lesion of gout is the presence of an abnormal amount of uric acid in the blood and the deposit of urate of sodium in

¹ For the relationship of diabetes to lesions of the pancreas, and particularly to lesions of the islands of Langerhans, see *Opie*, "Disease of the Pancreas," 1903; also *Cecil*, *Med. and Sur. Rept. Presbt. Hosp.*, viii., 1908.

² See *Opie*, *loc. cit.*, p. 54.

³ Internal secretions which, formed in one organ, are necessary or useful in correlating the functions of the organ of origin with those of other organs of the body are called *hormones*, see *Starling*, *Harvey Lecture*, 1907-8.

⁴ Other forms of glycosuria are known which are to be otherwise accounted for. They may be associated with lesions of the nervous system or induced by the action of certain poisons, phloridzin-diabetes for example, or may occur under other conditions.

the articular cartilages, the ligaments of the joints, the ears, and the eyelids. Inflammatory changes may be associated with the deposits in the joints. There appears to be an hereditary predisposition to the disease.

The most frequent situation of the gouty deposit is the metatarsophalangeal joint of the great toe. The cartilage may be infiltrated or encrusted with the deposit. These masses of urates, often called "chalk-stones" or "tophi," may appear upon the surface by the ulceration of the skin (Fig. 273).

A very important feature of gout is that patients with the gouty diathesis are especially liable to derangements of digestion and to certain



FIG. 273.—LESIONS OF GOUT IN THE HANDS.

• Some of the smaller tophi at the finger tips are ulcerating.

chronic inflammations, such as chronic inflammation of the arteries, the bronchi, and the kidneys. Cardiac hypertrophy may be associated with the arterio-sclerosis. The interstitial tissue, especially in the pyramids of the kidney, may be infiltrated with the urates.

The nature of the disturbances of nitrogenous metabolism underlying the manifestations of gout is not yet clear, nor are we able to estimate the influences upon accumulations of uric acid in the body of faulty elimination or local tissue alterations. Nor is the relationship plain of local inflammatory processes to the gouty deposits.

SUNSTROKE. (Insolation; Heat Exhaustion.)

Persons exposed, while at work or when exhausted, to the sun or to high temperatures are liable, especially if of intemperate habits, to sud-

den prostration, often associated with cardiac failure, asphyxia, convulsions, and coma. Death in many cases soon ensues.

After death, decomposition sets in early and progresses rapidly. The blood usually remains fluid.

The brain and its membranes are in some cases congested, in others not. There may be an increased amount of serum beneath the pia mater, or small and thin extravasations of blood beneath the pia mater and between the pia and dura mater. Chromatolysis of the ganglion cells has been described by Van Gieson¹ and others. The thoracic and abdominal viscera may be congested; albuminous degeneration may be evident in the liver and kidneys.

In the cases in which cerebral symptoms are protracted for a number of days the lesions of meningitis have been found after death.

According to Cramer,² persons surviving for some time the first severe effects of the heat may suffer important alterations in certain nerve fibres of the brain.

SCORBUTUS. (Scurvy.)

This disease appears to result from imperfect nutrition under conditions which cannot be considered in detail here, but which is usually attributed to insufficient or inappropriate diet. The lesions are variable, the most common being anæmia; extravasation of blood in the skin, subcutaneous tissue, and muscles; swelling and ulceration and bleeding of the gums. Small and sometimes extensive hæmorrhages are apt to occur in the mucous membranes and on serous surfaces. Small ulcers may form in the mucous membranes. Fatty degeneration of the heart, liver, and kidneys is not uncommon. The spleen may be large and soft. No constant characteristic changes have been discovered, either in the blood-vessels or the blood, which would satisfactorily account for the extravasations and other lesions.

The body is apt to decompose early. The skin may be mottled with small and large purple, blue, brown, or blackish spots produced by degenerative changes in the extravasated blood in the cutis. Sometimes ulcers are produced by the perforation of effused blood on to the surface. The joints may be inflamed, may contain serum or blood. Rarely the hæmorrhages are followed by destruction of the cartilages and ends of the bones. Very rarely there is hæmorrhage between the periosteum and bone, and in the bone itself, producing softening and destruction of the bone, and separation of the epiphyses. The sternal ends of the ribs are the most frequent seat of this change. Albuminous degeneration of the heart, liver, or kidneys, and enlargement of the spleen, are common.

Infantile Scorbutus.—Infants (under two years) may develop similar anæmia and tendency to hæmorrhages. The most common location of the hæmorrhages is beneath the periosteum of the bones of the lower extremities, especially of the femora, with separation of the lower epiphy-

¹ *Van Gieson*, "Toxic Basis of Neural Diseases," N. Y. State Hospital Bulletin, vol. i., p. 407, 1896; also *Lambert*, Medical News, July 24th, 1897.

² *Cramer*, Centralblatt für allg. Path., etc., Bd. i., p. 185, 1890.

ses. There may be hæmorrhages in the skin and subcutaneous tissues, the eyelids, and orbit, and in the internal organs. Hæmorrhagic inflammation and ulceration of the gums are usually limited to infants having teeth and to portions of the jaw in which teeth are apparent or just about to come into view.¹

That some forms or phases of scorbutus are of infectious nature is not improbable, but definite data in this direction are wanting.

ACROMEGALIA.

This rare disease is especially marked by an overgrowth of the terminal portions of the extremities, and of the bones of the face.² But there may be a general involvement of the skeleton—gigantism. This excessive growth is in the diameter rather than in the length of the bones, and is accompanied by local exostoses. Equally important and common is a general hyperplasia of the connective tissue of the body. Various lesions of the thyroid have been described, but they are not constant. The thymus may be persistent; there may be fibrous-tissue formation in the walls of the vessels and in the sympathetic ganglia. The skin is often pigmented.

Many visceral lesions have been described. The most constant lesion which appears to bear upon the etiology of acromegalia is that of the *hypophysis*. This in many cases has been found to be the seat of lesions, most frequently a hyperplasia or adenomatous growth in the prehypophysis. While endothelioma and sarcoma of the hypophysis have been described in acromegaly, it seems not unlikely that hyperplasia has, in most cases at least, been mistaken for these tumors. The complete removal of the hypophysis or of its anterior portion is invariably fatal. It is believed that the hyperplastic hypophysis is in some way concerned in inducing the nutritional abnormalities leading to the general overgrowth of connective tissue and bone,³ probably through interference with its internal secretion.

PURPURA. (Purpura Hæmorrhagica.)

This name is applied to a variety of conditions in which extravasations of blood are present in the skin or the mucous and serous membranes.

Hæmorrhages, particularly from the mucous membranes, may be severe and even fatal. This condition is often called purpura hæmorrhagica.

¹For a study of scorbutus in infants, "Barlow's Disease," which was first recognized in the United States by Northrup, consult *Northrup and Crandall*, N. Y. Med. Jour., May 26th, 1894.

See also The American Pediatric Society's "Collective Investigation on Infantile Scurvy in North America," *Trans. Amer. Ped. Soc.*, vol. x., 1898, p. 5.

For a study of histological changes consult *Jacobsthal*, *Ziegler's Beitr. z. path. Anat.*, Bd. xxvii., p. 173, 1900.

²Several cases have been described in which there was enlargement of the hands and feet and lower ends of the long bones, without involvement of the bones of the face. While this condition may follow syphilitic infection, its frequent association with pulmonary lesions has led to the designation *hypertrophic pulmonary arthropathy*. See study and bibl. by *Th. Janeway*, *Am. Jour. Med. Sci.*, vol. cxxvi., 1903, p. 563.

³For an excellent *résumé* of acromegalia, with cases and bibl., see *Brooks*, *Archives of Neurology and Psychopathology*, vol. i., p. 485, 1898; see also *Lewis*, *Bull. Johns Hop. Hosp.*, vol. xvi., 157, 1905.

The ecchymoses characteristic of purpura may occur as a result of poisoning with certain drugs, and with snake venom; in various cachectic conditions; in diseases of the nervous system; in rheumatism; in gastrointestinal disorders, especially of children. The local ecchymoses in pyæmia are sometimes classed as a form of purpura; and in these, bacteria, especially the pyogenic forms, may be demonstrable.¹

Either from the direct action of poisons; or through degeneration of the endothelium of the smaller vessels; or as the result of capillary embolisms, extravasation of blood may take place.

LYMPHATIC CONSTITUTION. (Constitutio Lymphatica: Status Lymphaticus.)

Attention has been recently called to a series of cases, especially in the young and in connection with sudden death, in which there was general hyperplasia of the lymph-nodes, spleen, and thymus, with hypoplasia of the heart and aorta. This condition often accompanies rickets.




FIG. 274.—HYPERPLASIA OF LYMPHOID TISSUE OF THE INTESTINE IN THE STATUS LYMPHATICUS.

Many instances of sudden death during anæsthesia or slight operations, or following slight traumatic injuries, have been found to accompany the status lymphaticus.

Hypoplasia of the heart and aorta is apparently a congenital defect, and while not limited to well-defined cases of lymphatic constitution, appears in this connection, and when occurring alone, to mark a noteworthy lack of resistance on the part of the organism to various forms of injury, infection, etc.

¹ For a more detailed consideration, in the light of recent studies, of cases often grouped under the name "Hæmorrhagic Infections," consult *Honl*, Lubarsch and Ostertag's "Ergebnisse der allg. Aetiologie," Jahrg. i., Ab. I, p. 793, bibl.

Lymph-Nodes and -Nodules.—The pharyngeal, thoracic, and abdominal lymph-nodes are most frequently involved in hyperplasia, the new cells often infiltrating the surrounding tissue. There may be hyperplasia of the tonsils, of the cervical, mediastinal, axillary, and abdominal lymph-nodes, as well as of the lymphatic tissue of the gastro-intestinal canal (Fig. 274).

The *thymus* may be congested and large and soft from hyperplasia. It sometimes evidently exerts such pressure on the adjacent bronchi and large vessels as to lead to death.

The *spleen* may be moderately enlarged from hyperplasia, especially of the lymphoid tissue of the Malpighian bodies, and it may be congested.¹

FEVER. (Pyrexia.)

The heat of the body is derived from tissue metabolism. The heart, the muscles, the liver, and other abdominal organs are the great sources of heat production. The temperature of the body under normal conditions is maintained within narrow limits by the heat-regulating mechanism which preserves the balance between heat production and heat loss effected largely through the skin and respiratory surfaces.

Fever may be defined as a general disturbance of metabolism usually due to infection or various forms of intoxication which leads to a rise of the temperature within the body.

The rise of temperature in fever depends primarily upon an increase in the metabolic combustion. Oxygen is used in larger amount than is usual, while the combustion products, carbonic acid, and the nitrogenous substances, urea, uric acid, etc., are excreted in greater abundance. This increased combustion is usually associated with disturbances of digestion and assimilation of food, so that the abnormal heat production is effected largely at the expense of the body proteids of the various tissues and organs concerned in metabolism.

But with the increased heat production there usually occur, in the earlier periods of fever, such disturbances in the vasomotor control of the cutaneous blood-vessels as lead to their contraction. Thus, heat elimination is retarded. In later periods the vessels of the skin may dilate so that, in spite of its persistent dryness and lack of the cooling effect of sweat evaporation, there is an excessive loss of heat from this source. This is not sufficient, however, to balance the excessive heat production. We need not consider here the various subjective and objective phenomena characteristic of the febrile condition. The height of temperature varies in fever, seldom exceeding 42° C. (107.6° F.), and is usually much less than this.

In the great majority of cases fever is due to the presence in the body of deleterious substances, either introduced from without, or, more commonly, produced within the body. These are most often formed in infections, and arise either from the growth in the tissues of pathogenic

¹ For a study of the lymphatic constitution and its relationship to sudden death see *Ewing*, N. Y. Med. Jour., July 10th., 1897, bibl.; see also for a study of the lymph-nodes, etc., in this condition *Bartel* and *Stein*, Arch. f. Anat. u. Physiol., anat. Abth., Jahrg., 1906, p. 231, bibl.

micro-organisms or from the disintegration of their bodies; that is, they are *toxins* or *endotoxins*. But there is abundant evidence that fever is not infrequently due to perverted metabolism of the tissue cells, leading to the formation of toxic substances. Such self-engendered substances are called autotoxins. The pyrexia of sunstroke is believed to be an example of this phase of auto-intoxication.

Similarly it is known that certain drugs—cocain, phosphorus, various bacterial toxins, and organic substances—proteids, ferments, etc.—introduced from without may induce fever.

Exactly how these various substances act in the incitement of fever is unknown. But one assumes that the cell metabolism is disturbed by the poison, while the heat-regulating mechanism is so modified that the normal balance is overthrown. That the nervous system may play an important rôle in these disturbances is indicated by the fact that more or less persistent elevations of temperature may follow puncture or hæmorrhage in the corpus striatum or lesions of the bulb or certain other affections of the nervous system.¹

¹For a study of fever and allied conditions see *Chantemesse* and *Podwyssotsky*, "Les Processes Généraux," 1901; see also *Krehl*, "Clinical Pathology," Tran. by Hewlett.
For metabolism in fever see *MacCallum*, Harvey Lectures, 1908-9.

CHAPTER XIV.

THE LESIONS IN CERTAIN FORMS OF DEATH FROM VIOLENCE: SUDDEN DEATH.

The Lesions in Certain Forms of Death from Violence.

SUFFOCATION—ASPHYXIA.

By suffocation is meant that condition in which, without direct pressure on the larynx or trachea, air is prevented from penetrating into the lungs. The interruption of the function of respiration which is thus brought about induces the condition known as *asphyxia*. In this way many deaths from drowning and strangulation take place.

The ways in which the supply of air may be cut off from the lungs are various. The mouth and nose may be closed by the hand, by plasters and cloths, by wrapping up the head in cloths, by covering the face with earth, hay, grain, etc. Foreign bodies may be introduced into the mouth, pharynx, and larynx. Blood may pass into the trachea from an aneurism or from a wound. The glottis may be closed by inflammatory swelling. Vomited material may lodge in the larynx.

On the other hand, injury or disease of the medulla oblongata, or paralysis or spasm of the muscles of respiration from drugs, tumors pressing upon the air passages, or diseases of the lungs themselves, or irrespirable gases which exclude oxygen from the lungs, may induce asphyxia.

EXTERNAL INSPECTION.—The body should be examined for marks of violence, the cavities of the mouth and nose for foreign substances.

The face may be livid and swollen or present a natural appearance. The conjunctiva may be congested and ecchymotic. There may be small ecchymoses on the face, neck, and chest. The mouth often contains frothy blood and mucus. The tongue may be protruded.

INTERNAL EXAMINATION.—*The brain* and its membranes may be congested, or anæmic and œdematous, or unchanged. *The blood* throughout the body is usually dark-colored and fluid.

The larynx may contain foreign bodies which have induced the suffocation. The mucous membrane of the larynx, trachea, and bronchi may be congested and sometimes ecchymotic: these passages contain frothy blood and mucus. *The lungs* are usually congested and œdematous, but sometimes do not differ from their ordinary appearance. There may be small patches of emphysema near the surface of the lungs. Sometimes, especially in infants, small ecchymoses are found in the costal and pulmonary pleura.

The heart usually presents its right cavities full of blood, its left cavities empty; but to this there are frequent exceptions.

The abdominal viscera are usually congested.

DEATH FROM STRANGULATION—HANGING.

Strangulation is effected by the weight of the body in hanging, by pressure on the neck with the hands or by some other object, or by constriction of the neck with a cord or ligature of some kind. Death usually occurs by asphyxia, or by asphyxia combined with the effect of the cutting-off of the blood supply to the brain by pressure on the large vessels of the neck. In some cases of hanging, death ensues as a result of fracture or dislocation of the cervical vertebræ.

EXTERNAL INSPECTION.—The face may be livid and swollen, the eyes prominent, the lips swollen, and the tongue protruded. These appearances are, however, often absent. Erection of the penis, ejaculation of semen, and evacuation of feces and urine are frequently observed.

In many cases marks are left upon the neck by the objects which have directly produced the strangulation. In cases of hanging, the mark about the neck varies considerably in position, direction, and general characters, depending upon the kind of ligature employed, the time of suspension, period after death at which the observation is made, etc. The most common mark left by a cord about the neck is a dry, dense, brownish furrow, whose breadth corresponds but in a very general way with the diameter of the cord. In some cases, according to Tidy and others, there may be no mark at all if the hanging be quickly accomplished with a soft ligature and the body cut down immediately after death. There may be abrasions and ecchymoses of the skin at the seat of ligature.

In cases of strangulation by the fingers the mark on the neck may correspond in a general way to the shape of the fingers.

The application of the same forces immediately after death may produce the same marks as when death is induced by them.

INTERNAL EXAMINATION.—*The brain* and its membranes may be congested, or there may be extravasation of blood, or there may be no abnormal appearances.

The Neck.—In some cases there is effusion of blood beneath the ligature, rupture of the cervical muscles, fracture of the os hyoides and cartilages of the larynx, fracture and dislocation of the cervical vertebræ, rupture of the internal vertebral ligaments and of the inner and middle coats of the carotid arteries. Similar changes may be produced in the dead body by the use of great violence.

If death occur from asphyxia, the internal lesions are similar to those described above. In some cases—for example, where death has occurred from fright or shock—the results of post-mortem examination are entirely negative.

DEATH FROM DROWNING.

In examining the bodies of persons who are supposed to have been drowned, it is necessary to bear in mind a number of questions which may arise: Whether the person came into the water alive or dead? How long a time has elapsed since death? Whether the person has committed suicide, or was drowned by accident, or was murdered? These questions are to be solved sometimes certainly, sometimes with probability, sometimes not at all, by the post-mortem examination. Persons dying in the water, to which condition the term drowning is commonly applied, may die from asphyxia, from exhaustion, from fright or syncope, from disease of the heart, apoplexy, injuries, etc. While in the majority of cases asphyxia is a predominant or important factor in death by drowning, the conditions under which death occurs are so apt to be complex that in the minority of cases only are the lesions of

pure asphyxia found after death, while in most cases the bodies present the more or less well-marked lesions of asphyxia together with those indicative of complicating conditions. There are no post-mortem conditions which alone are absolutely characteristic of drowning, and it is only by considering all the facts elicited by the autopsy together that any just conclusion can be arrived at. It should always be borne in mind, moreover, that even the most characteristic of the evidences of drowning are apt to be modified or to disappear as decomposition goes on.

EXTERNAL INSPECTION.—Post-mortem rigidity usually sets in early, sometimes immediately after death. Decomposition progresses, especially in summer, with unusual rapidity in bodies which have been removed from the water. Frequently, but by no means constantly, the peculiar roughening of the skin, known as goose-skin (*cutis anserina*), is found, but this may occur after death from other causes. A light, lathery froth, either white or blood-stained, is frequently seen about the mouth and nostrils within twelve to twenty-four hours after removal of the body from the water, but it may be absent, and may be seen after death from other causes. After the body has lain for several hours in the water (twelve to twenty-four) the thick skin of the palms of the hands and soles of the feet may become macerated and thrown into coarse wrinkles, just as it may after prolonged soaking during life, or in a dead body thrown into the water. The penis and nipples may be retracted, and the scrotum shrunken, but this is not constant nor characteristic.

If the person has struggled in the water and clutched at objects within his reach, there may be evidences of this in excoriation of the fingers or in the presence of sand, weeds, etc., under the nails or grasped in the hands.

External marks of injury, bruises, etc., should be sought for, since persons in dying, or on being thrown into the water with homicidal intent, may have died from the violence, and not, strictly speaking, from drowning. It should also be borne in mind in such complex cases that injuries, not in themselves fatal, may, when the body is in the water, prove so on account of the inability of the person to rescue himself or gain time for recovery from the injury, and that then the struggle for breath may be but slight, and the more prominent signs of drowning but little marked.

INTERNAL EXAMINATION.—*The Brain.*—Congestion of the brain and its membranes is found only in a small proportion of cases.

The blood, when death occurs from asphyxia, is usually fluid throughout the body and of a dark color, as in asphyxia from other causes.

The Air Passages.—In persons who die from asphyxia the mucous membrane of the larynx, trachea, and bronchi is usually congested, and the air passages contain a variable quantity of bloody or mucous froth. In persons dying in the water from other causes than asphyxia, these appearances are absent. Foreign substances from the water, such as sand, weeds, etc., or materials regurgitated from the stomach, may find their way into the air passages during the act of drowning or as a post-mortem occurrence. Thus, in bodies washed about the bottom, sand or mud may get into the air passages for a certain distance, from the mechanical action of the water.

The lungs in typical cases are distended so that they fill the thorax and cover the heart. The increased size is due partly to congestion, partly to the presence of the fluid in which the person was drowned, which is often inspired during the act of drowning, and partly to the distention of the air vesicles with air. In cases of drowning in which there is a struggle and water is breathed in, the lungs may contain considerable fluid; but, as a result of decomposition, this may find its way in greater or less quantity into the pleural cavities by transudation, leaving the lungs comparatively empty. It should be remembered, however, that a considerable quantity of reddish fluid may collect in the pleural cavities under other conditions than drowning, through a post-mortem change, by transudation from the blood-vessels and other adjacent tissue.

The Heart.—In those who die from asphyxia the right cavities are usually filled

with fluid blood, while the left cavities are empty. But when death is due to complex causes this may not be the case.

The abdominal viscera may be congested in persons who die from asphyxia.

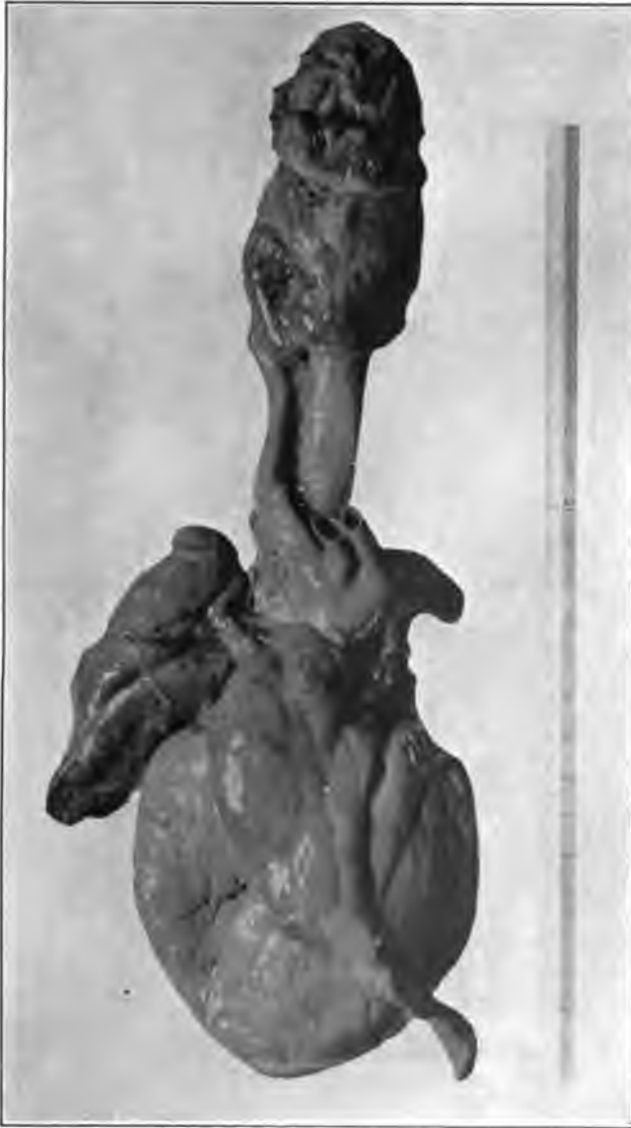

FIG. 275.—ENLARGED THYMUS.
Case of sudden death in child of twelve years.

The Stomach.—The fluid in which the person was drowned, sometimes mixed with sand, weeds, etc., may be swallowed during the act of drowning. Sand may wash for a short distance into the œsophagus after death, in bodies washing about the bottom.

In persons dying in the water from syncope, shock, etc., we may find no lesions. When the death is partly due to asphyxia and partly to other causes, the lesions may vary in numerous ways, which need not be described here.

In important cases of doubtful drowning it is desirable carefully to collect and save some of the fluid from the lungs and stomach for micro-chemical examination, since the identification of these fluids with those in which the person was presumably drowned will often give certainty to an otherwise doubtful case.

For the detailed consideration of the anatomical diagnosis of drowning, the changes which bodies dead from drowning undergo from decomposition, and the factors bearing on the question of suicide, homicide, etc., we refer to works on medical jurisprudence.

Sudden Death.

Some forms of sudden death from violence have been already considered. Aside from these, by sudden death, in the ordinary sense, is usu-

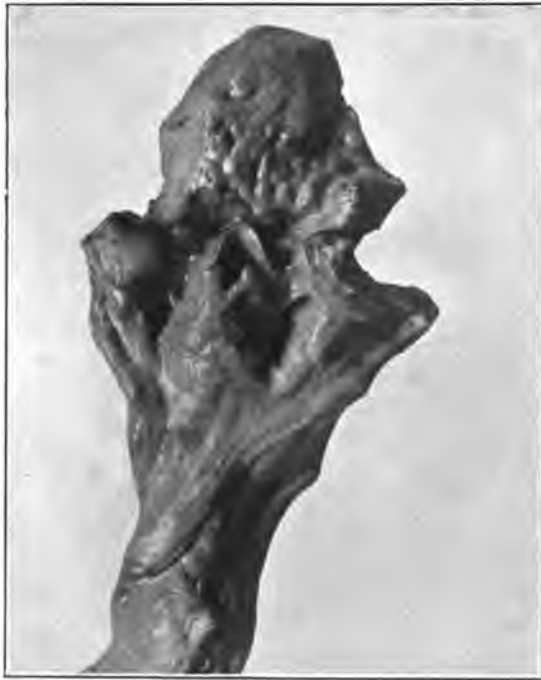

FIG. 276.—ENLARGED THYMUS—SUDDEN DEATH. CHILD TWELVE YEARS OF AGE. Showing enlarged lymph nodules at the base of the tongue and in the walls of the pharynx.

ally meant "the rapid and unforeseen termination of a latent acute or chronic disease." We shall not consider here sudden death either from violence or poisoning or in well-defined and evident acute or chronic diseases: it will be practicable only to enumerate some of the more common conditions under which sudden death may occur—and first in the *adult*.

Circulatory System.—Heart—fatty degeneration, chronic myocarditis abscess of the myocardium, rupture, lesions of the coronary arteries, endocarditis, and pericarditis. Blood-vessels—arterio-sclerosis, aneurisms—especially intracranial, intrapericardial, abdominal, and pulmonary; rupture of the aorta, congenital narrowness of the aorta, thrombosis and embolism of the pulmonary or cerebral arteries.

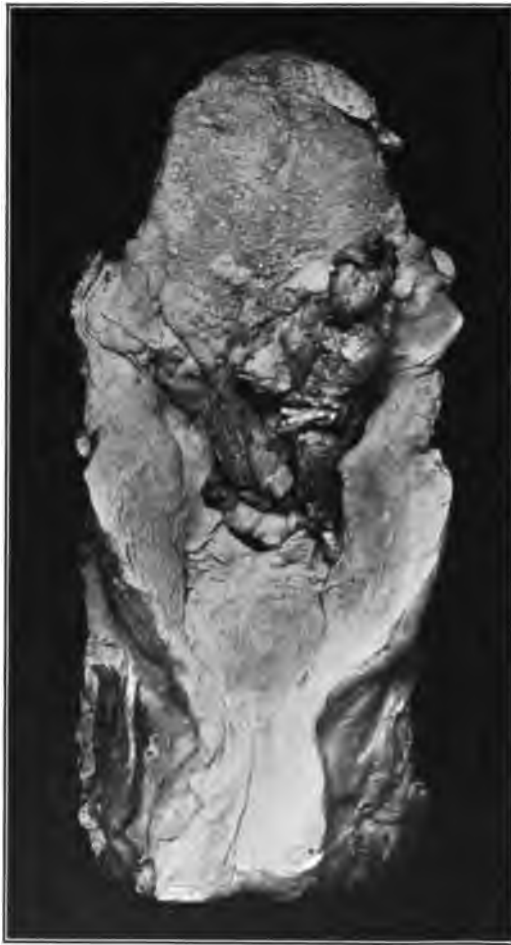

FIG. 277.—SUFFOCATION FROM THE LODGMENT OF A LARGE PIECE OF MEAT IN THE LARYNX. This individual died within a few seconds after bolting this mass of meat.

Brain—hæmorrhage, meningitis, abscesses, and tumors. Very slight injuries of various parts of the body have been followed by sudden death, probably through inhibition. Syncope or shock may terminate in death.

Respiratory System.—Foreign bodies lodging at the entrance to the

larynx are not infrequently followed by immediate death without evidence of asphyxia (Fig. 277). Edema of the glottis, œdema of the lungs, hypertrophy of the thyroid, mediastinal tumors, pleurisy, and pneumothorax may lead to sudden death.

Abdominal Viscera.—Rupture of visceral abscesses; perforation of ulcers of the gastro-intestinal canal; rupture of the spleen, especially if the latter be enlarged as in malaria; extra-uterine gestation, retro-uterine hæmatocele, and rupture of the uterus, are among the lesions not infrequently leading to sudden death.

Sudden death is frequent in diabetes, in various forms of kidney lesion and in alcoholism, and in association with the so-called lymphatic constitution.¹

Sudden death in *young children* is most often associated with disorders of the respiratory system, thus differing from adults, in whom lesions of the circulatory system are of the greatest significance. Brouardel attributes sudden death in children usually to one of five principal causes—syncope, convulsions, asphyxia, pulmonary congestion, and intestinal disorders. A large thymus (Figs. 275 and 276) with the lymphatic constitution is frequent in cases of sudden death in young children.²

¹ See *Ewing*, *New York Med. Jour.*, vol. lxvi., p. 37, 1897, bibl.

² For further details on sudden death consult *Brouardel*, "Death and Sudden Death," English translation, 1897; also *Ewing*, in Peterson and Haines' "Text-book of Legal Medicine," 1903.

PART II.

SPECIAL PATHOLOGY.



SPECIAL PATHOLOGY.

General Considerations.

WE have now completed the study of those fundamental processes and structural alterations which are embraced in general pathology. These have been considered without reference to special regions or organs of the body. We now enter upon the study of these pathological processes and their associated lesions as they are modified by the special conditions and characteristic structures of one and another of the tissues or organs or regions of the body. It is clear that both the disease processes and the structural alterations with which these are associated may be modified by the functional and structural peculiarities of the affected organ. Thus while degeneration, regeneration, inflammation, etc., may be fundamentally similar, for example, in liver, kidney, and nerve, they may present sufficient variation in one or another of these parts to require a separate consideration and even a special nomenclature. We shall have occasion to call attention now and then to those functional and structural characteristics of the organs which often throw much light upon their mode of response to the various excitants of disease.

It is well, on the other hand, to remember that there are in all the organs and in most parts of the body certain elementary structures, such as connective tissue, blood- and lymph-vessels, and nerves, whose lesions are quite similar wherever they may be. So that many forms of lesion involving these structures, while of varying significance to the organism, differ in the various parts of the body chiefly in distribution or topography.

CHAPTER I.

THE BLOOD AND THE BLOOD-FORMING ORGANS.

Changes in the Composition and Structure of the Blood.¹

The Coagulability of the Blood and the characters of the resulting clot vary widely, depending partly upon the composition of the blood and partly upon the conditions under which the coagulation occurs. There may be very little coagulation of the blood in death from suffocation, or from conditions which interfere with the aëration of the blood and permit the accumulation of carbonic acid within it. Thus, in death from strangulation, high-voltage electric currents, drowning, many chronic diseases, or scurvy, and under many conditions which we do not understand, the blood may remain fluid, or nearly so, after death. On the other hand, in a variety of infectious diseases, such as rheumatism, pneumonia, etc., very voluminous clots may be formed, although this is by no means constantly the case. The fact that large clots form after death is not conclusive evidence that an undue amount of fibrin-forming elements was present in the blood, nor does the absence of marked coagulation prove a diminution in the blood of fibrin-forming elements.

The composition of the clot varies with the rapidity of its formation and with the specific gravity of the plasma. Clots very rapidly formed in plasma of high specific gravity, or in still slowly circulating blood, are apt to be dark red, from admixture of red cells and fibrin. After complete failure of circulation, especially in plasma of low specific gravity, the red cells tend to settle to dependent vessels. Yellowish white succulent clots then form in the clear supernatant plasma, while soft black clots result from the excess of red cells collected in the dependent vessels.

The current theory of coagulation of the blood is that four factors are necessary for the production of fibrin: fibrinogen, prothrombin, thrombokinase, and calcium salts. By the interaction of the latter three, thrombin is produced; and this substance acting on fibrinogen causes the formation of fibrin, or clotting. The fibrinogen is in solution in the plasma. By the action of thrombin upon it, it is split into a soluble serum globulin and fibrin. Prothrombin is present in the circulating blood and of itself has no action on fibrinogen, but in the presence of thrombokinase and a calcium salt, a new body, thrombin, is formed, which acts upon fibrinogen. Thrombokinase is not found in the plasma of the circulating blood, but is present in the tissues and in the leuco-

¹ A full discussion of the subjects in this chapter can be found in *Ewing*, "Clinical Pathology of the Blood," 1903; *DaCosta*, *Clinical Hematology*, 1905; and *Naegeli*, *Blutkrankheiten und Blutdiagnostik*, Leipzig, 1908.

cytes and blood platelets of the blood. Thrombin is formed by its action, and the greater the quantity added to the blood from the tissues or formed elements, the more rapid is the change of prothrombin into fibrin.

The time of coagulation of the blood in healthy persons is fairly constant when determined by satisfactory methods. In disease, considerable variations have been noted in the coagulation time. In cases of hereditary hæmophilia the blood may require 60 to 70 minutes to coagulate instead of the normal 7 to 10 minutes. In jaundice the coagulability of the blood may be impaired. Some of the severe anæmias and purpuras may also show moderate slowing of coagulation. Repeated hæmorrhages shorten the time of coagulation. It has been stated that the injection of gelatine into the vessels and the ingestion of calcium chloride or lactate also shorten the coagulation time. The facts concerning calcium chloride are fairly well established, but the influence of gelatine is still open to question. The difficulty lies largely in our inability to obtain a satisfactory quantitative method by which the amount of thrombokinase can be accurately determined, and the influence of accidental mechanical factors can be eliminated.

Reaction of the Blood.—Owing to the general use of litmus as an indicator the reaction of the blood has long been considered to be alkaline. This substance, however, does not afford reliable determinations of the actual reaction, and it has lately been shown by physico-chemical methods that the blood may be considered as approximately a neutral fluid; that is, that the proportion between the hydrogen and the hydroxyl ions is nearly the same as in distilled water. The reason for the apparent alkalinity to litmus and the real neutrality of the blood is that there are present in this fluid substances which when dissociated act both as acids and as alkalis. The acids are represented by the carbon dioxide dissolved in the plasma and phosphoric acid present as a monosodium salt. The alkalis are represented by sodium bicarbonate and disodium phosphate which are alkaline in reaction. The proteids of the blood also act both as bases and as acids. Litmus not being sensitive to carbon dioxide is turned blue by the excess of basic ion present. If, however, a more sensitive indicator is used, such as phenolphthalein, no alteration in the color is produced; in other words, the blood is actually acid to that substance. For clinical purposes the best indicator is rosolic acid,¹ which is capable of demonstrating slight variations on either the acid or the alkaline side.

All the older observations based upon litmus as an indicator must be revised, and there are at present but few reliable determinations available. These show that even in diabetes with a high content of beta-oxybutyric and aceto-acetic acids in the blood there is but very slight alteration in the reaction towards the acid side. The maximum change observed in such cases does not render the blood over three times as acid as distilled water, and so great is the binding power of the proteids and so large an amount of free alkali is available for neutralization that the

¹ *Adler*, Amer. Jour. Physiol., 1907, xix., 1.

conclusion must be drawn that there is no real acid intoxication as indicated by marked changes in the blood reaction.

Anhydræmia—the condition in which the blood contains an excessive proportion of albumin, cells, and other solid elements—occurs in diseases associated with excessive serous discharges from the intestines. It is extreme in some cases of cholera, and has been noted in a lesser degree in other infectious diseases, as pneumonia and diphtheria.

After removal of large quantities of fluid from the peritoneal or pleural cavities a passing concentration of the blood even to the doubling of the number of red corpuscles present may be observed. This is due to the rapid transudation of serum from the blood to take the place of that withdrawn from the serous cavity. When the balance is again established the anhydræmia quickly gives place to the opposite condition, hydræmia.

Hydræmia is that condition in which the blood contains a large amount of water in proportion to the solid ingredients. It occurs in a variety of diseases of the heart, lungs, liver, and kidneys, and characterizes all forms of anæmia.

Hæmoglobinæmia.—Owing to the destruction of red blood cells in some forms of poisoning, burning, etc., the blood plasma may contain free hæmoglobin, by which it is discolored (*hæmoglobinæmia*), or it may be stained from the absorption of bile pigment.

A similar destruction of the red cells with solution of the hæmoglobin is occasionally observed following direct transfusion in persons suffering from severe anæmia, especially of the pernicious type.

Anæmia.—In general, anæmia means a diminished quantity of blood or of red blood cells in the vessels of the whole or any part of the body. With one exception—mild chlorosis—it is invariably characterized by a reduction in number and change in form of the red cells (*oligocythæmia*), and by diminished alkalinity and coagulability. It is always associated with a reduction in specific gravity, in hæmoglobin, and in solid elements. Hydræmia and an increased tendency toward osmosis are equally constant features of this condition. The albumens remaining in the serum after coagulation are very slightly diminished in anæmia.

Generally speaking, anæmia is produced by excessive hæmatolysis, or by defective hæmatogenesis, or by actual loss of blood, in bulk (*hæmorrhage*), or in its fluid ingredients (*transudation*).

Anæmia may be secondary to hæmorrhage, to exudative processes, to prolonged malnutrition, to chronic organic diseases of many kinds, to the action of poisons, to congenital hypoplasia of heart and arteries, to functional disturbances of an unknown nature in the blood-forming organs, and to wholly unknown causes. Simple atrophic changes in many tissues, hypertrophy of the red marrow, lymph-nodes, spleen, liver, and thymus, fatty degeneration of the liver, kidneys, heart, and blood-vessels, with capillary hæmorrhages and transudations, are frequent accompaniments of severe anæmia.

Polycythæmia.—By polycythæmia in its proper usage is meant an increase in the number of corpuscles in the blood without necessarily an

increase in the total volume. This condition is frequently noticed in chronic dyspnoea from either congenital or acquired heart disease, in certain chronic diseases of the lungs accompanied by cyanosis, and after poisoning by illuminating gas. What may be termed a physiological polycythæmia has been observed in persons living at high altitudes. This has been attributed to the stimulating effect of the diminished oxygen partial pressure on the blood-forming organs, which causes them to produce an excessive number of red cells, and to the rapid evaporation from the skin which takes place, thus concentrating the blood by the transfer of plasma from the blood to the tissues. The question can not, however, be regarded as finally settled.¹

The other type of polycythæmia, seen in diseases in which the circulation is interfered with, is probably entirely a local phenomenon, the increase in the number of corpuscles being due in all probability to the concentration of the blood-vessels in the peripheral capillaries. This is induced by the increased viscosity of the blood incident upon the increased carbon dioxide content following the imperfect aëration in the lungs. The polycythæmia disappears in such cases very promptly on inhalation of oxygen, and at the same time the viscosity falls. As soon, however, as the oxygen treatment is terminated the peripheral stasis reappears. In cases of chronic cardiac disease with broken compensation the disappearance of the polycythæmia is noted as soon as the heart lesion improves. While the polycythæmia is usually a general phenomenon, that is, the blood concentration exists in all the peripheral vessels, it may occasionally be local. The most striking example of such local concentration of the formed elements of the blood is seen in cases of intrathoracic tumor with a compression of the superior vena cava and azygos veins. Under these circumstances intense congestion of the upper extremity may be induced, and blood taken from the finger may show a million more red cells to the cubic millimeter than that taken from the toe.

Plethora.—The existence of a true plethora, that is, an increase in the volume of the blood accompanied by a co-ordinate increase in corpuscles, has long been debated; but recently cases have been reported, occurring chiefly in persons suffering from a disease of unknown etiology, generally accompanied by hyperplasia of the spleen or bone marrow, high blood pressure, and cyanosis, and designated clinically as polycythæmia or erythræmia. The number of red and white cells and the amount of hæmoglobin are greatly increased. The condition of plethora may be suggested at autopsy by the very great distention of all the vessels and the overfilling of the organs with blood.² The only accurate method, however, is to determine the total amount of blood in the body during life by the relatively simple procedure of Haldane,³ by which the patient inspires a measured quantity of carbon monoxide. A sample of the

¹ For a very full discussion of the work of previous observers and many important personal observations, see Zuntz, Lowy, Müller, u. Caspari, *Hohenklime u. Bergwanderungen*, Berlin, 1906.

² Westenhoefer, *Ein Beitrag zur pathologischen Anatomie der plethora vera*, *Deutsch. med. Wehnschr.*, 1907, xxxiii., 1446.

³ Haldane and Smith, *Jour. of Physiol.*, 1897, xxii., 231; 1900, xxv., 331.

blood is then taken and analyzed to determine what percentage of hæmoglobin has been altered into carbon monoxide hæmoglobin.¹

THE RED BLOOD CELLS.

These may be diminished in number and may undergo various changes in shape and size and structure.

ALTERATION IN NUMBER OF THE RED BLOOD CELLS.

Oligocythæmia is that condition of the blood in which the number of the red cells is reduced. This reduction in number may be temporary, as after hæmorrhage, or it may be persistent, as in some forms of anæmia. The number of red blood cells may in extreme cases of anæmia be reduced to one-tenth of the normal, or even less; that is, from the normal number, which is between four and five millions, there may be a reduction to half a million or less.

A persistent diminution in the number of red cells may be effected either by increased destruction (*hæmatolysis*) or by defective formation (*hæmatogenesis*) of these elements, but the relation of the two factors in the production of the chronic anæmias is as yet imperfectly determined.

EXCESSIVE HÆMATOLYSIS occurs after burns, is the result of poisoning by arsenic, phosphorus, and chlorates, phenylhydrazin, nitrobenzol, acetanilid, etc., and may occur in infectious diseases through the action of bacterial toxins. All stages of a peculiar destruction of red blood cells may readily be followed in the blood in malaria. In chronic infectious diseases, prolonged suppuration, and in the cachexia attending malignant new growths, destruction of red cells is probably effected, in part, by toxic agents circulating in the blood. In pernicious anæmia the condition of the blood may, with considerable certainty, be referred largely to a destruction of red cells by some unidentified toxic material in the blood.

In the destruction of the red cells, especially if rapid, hæmoglobin may separate from the cells, dissolve in the plasma (*hæmoglobinæmia*), and may then be excreted unchanged in the urine (*hæmoglobinuria*). Such destruction occasionally follows chilling of the extremities after exposure to cold in persons suffering from a disease known as paroxysmal hæmoglobinuria.²

The gradual and more common form of destruction of red cells is attended with an alteration of the hæmoglobin, effected chiefly in the liver, and with its deposit in the endothelial and glandular cells of various organs, especially in the liver, spleen, kidneys, bone marrow, and secondarily in any of the tissues.

A part of the altered hæmoglobin is to be found in the form of pigment granules, or as a diffuse deposit, in the cells of the above-named organs, where its content of iron may or may not be demonstrable by

¹ For a full review of the subject of polycythæmia, erythræmia, and plethora, see paper by F. P. Weber, *Quart. Jour. Med.*, 1908, ii., 85.

² For an interesting study of the conditions underlying the hæmolysis which occurs in paroxysmal hæmoglobinuria see Donath and Landsteiner, *Zeit. f. klin. Med.*, Bd. lviii., 1906, p. 173.

microchemical tests (*hæmosiderin*). Another product of the hæmoglobin, not containing iron, may be found in the same situations, in the forms of granules or crystals (*hæmatoidin*). Finally, the derivatives of hæmoglobin are excreted largely in the form of normal or pathological urinary pigment. The remaining fragments and stroma of the red cells are soon removed from the circulation largely by leucocytes, and partly by endothelial cells and giant cells, in the liver, spleen, and marrow.

DEFECTIVE HÆMATOGENESIS must be regarded as an important factor in the production of such anæmias as are associated with pathological changes in the bone marrow (pernicious anæmia), and in the lymph-nodes spleen, and liver (leukæmia). This, too, is probably the chief cause of the persistence of an anæmia following prolonged malnutrition (secondary anæmia). The pathological changes in the blood-producing organs may sometimes arise as primary diseases of these organs, or similar changes may be secondary to excessive demands for the regeneration of the blood. In mild grades of anæmia the regeneration of the blood is attended with an hyperplasia of the red marrow, which replaces the yellow marrow of the long bones. The chief defect in the production of red cells may then be a deficiency in hæmoglobin (chlorosis). In severe and prolonged anæmia, under the influence of toxic agents in the blood, the reproduction of cells may be insufficient, and these new cells may be more susceptible to the action of the toxic agent, which is itself the cause of their structural defects. In such cases the normoblasts of the marrow may be produced in very large numbers and form red cells of normal or slightly diminished size, or they may be replaced by very large nucleated red cells (*megaloblasts*); from these are developed very large red cells which are comparatively incapable of the functions of the normal cell. The megaloblastic form of regeneration is confined to the anæmia of a pernicious type, with the exception of the form due to the *Bothriocephalus latus* or that following the prolonged action of certain organic poisons such as nitrobenzol.

ALTERATIONS IN MORPHOLOGY OF THE RED BLOOD CELLS.

In *mild forms of anæmia* the red cells are deficient in hæmoglobin, the blood may be pale or watery in appearance, and the cells appear in the fresh condition as very pale discs or as slightly refractive rings enclosing a nearly colorless central mass. In dry preparations stained with eosin, such cells may show only a narrow red ring surrounding a central portion which is entirely devoid of hæmoglobin. In this grade of anæmia there may be noted moderate differences in size and irregularities in shape of the red cells. In severe anæmia and under a variety of conditions, as after certain forms of poisoning, extensive burns, etc., varying numbers of very small red cells are seen, called *microcytes*. They are spheroidal or irregular in shape, may be excessively minute, and their hæmoglobin is either increased, or normal, or diminished. Under similar conditions, a variety of bizarre forms of red cells are found, called *poikilocytes*. In certain forms of anæmia very large red cells occur in consider-

able numbers. These cells, called *megalocytes*, are derived from the large nucleated red cells of the marrow, and their appearance in the blood indicates the early onset or actual establishment of some form of progressive pernicious anæmia (see Plate II., Fig. 4).

Amœboid movement of megalocytes has been observed in specimens from the blood of pernicious anæmia examined on a warm stage. The tendency of the red cells to form rouleaux is much diminished or absent in very grave anæmia.

Not infrequently a loss of hæmoglobin is associated with a change in the stroma of the cell, so that the mass stains slightly with methylene blue. To this change the name of anæmic or polychromatophilic degeneration has been given, and it is thought to show a more or less complete coagulation necrosis by which change the protoplasm of the red cell becomes more basophilic¹ in its staining reaction, though recent investigations have shown that similar cells are present in normal bone marrow and in the blood of the fœtus. It is therefore probable that our staining methods do not differentiate between a degenerative change in the body of the cell and a condition expressive of physiological youth. Normally, perhaps, such cells are retained in the marrow until fully developed and only appear in the blood when excessive demands are made upon the blood-forming organs.

Instead of a uniform absorption of the dye some parts of the cell may be condensed in the form of small granules or rings occupying the cell body and staining more deeply with methylene blue than do normal cells (granular degeneration).

It should be remembered that during the manipulations required in making dried specimens the red cells may suffer a variety of artificial changes, many of which are very confusing.

Nucleated red blood cells are found in the blood in all forms of anæmia, and their appearance indicates regenerative activity on the part of the blood-producing organs. Their presence in the blood in large numbers, though at all periods of extra-uterine life abnormal, has been regarded as of favorable import in disease. Within a few hours after severe hæmorrhage nucleated red cells may be noted in considerable numbers.² During the regeneration of the blood in anæmia, the occurrence of nucleated red cells is nearly constant, but subject to rather sudden periodical variations sometimes called "blood crises." In favorable cases of anæmia nucleated red cells of normal size only (*normoblasts*) (Plate II., Figs. 2 and 3) are seen, whose compact, darkly staining nuclei may be found either in the centre of the cell or slightly protruding from the periphery; or, nuclei apparently quite extruded from the cell may be found free in the plasma.

In severe anæmia attended with an abnormal type of blood formation,

¹ It is convenient to classify the dyes used in staining into the acid, the neutral, and the basic, and to designate cells, in accordance with the relative persistency with which they hold these dyes, as acidophile, neutrophile, or basophile.

² The appearance of nucleated red cells and abnormal forms has been frequently noted in those who have recently arrived in mountainous regions, the probable explanation being that the lowered oxygen tension of the rarefied air demands a larger amount of hæmoglobin to supply the wants of the tissues, with the result that for a short time immature red cells are set free from the bone-marrow.

very large nucleated red cells (*megaloblasts*) (Plate II., Fig. 4) appear in varying numbers. The protoplasm of these cells often shows an excess of hæmoglobin, but frequently the purple stain produced by a combination of the eosin and methylene blue indicates an altered form of hæmoglobin, or very fine basophile granules may be demonstrated by treatment with methylene blue. The nuclei of the megaloblasts may be single and compact, or a single large nucleus may show stages of direct division, or in extremely large cells (*gigantoblasts*) the nuclei may present phases of mitosis.

THE WHITE BLOOD CELLS.

THE LEUCOCYTES OF NORMAL BLOOD.

The leucocytes of normal blood may be classified according to their place of origin, or by the character of their nuclei, or by the reaction of the granules in their protoplasm to certain dyes. The most serviceable classification is that based both upon the character of the nucleus and upon the reaction of the protoplasm to dyes, according to which we may distinguish in normal blood the following forms (see Plate II., Fig. 1):

1. **Lymphocytes**, small leucocytes of about the size of red cells or larger, with a single, compact, deeply staining nucleus, surrounded by a thin rim of homogeneous protoplasm. The cell body usually possesses a stronger basophilic reaction than the nucleus, so that in staining with methylene blue the nucleus shows as a pale spot in the centre of the dark ring of the cell body. This ring is often ragged in its outline and may show distinct projections which are sometimes cast off into the circulating blood. Large and small lymphocytes may be distinguished (Plate II., Fig. 5).

When deeply stained with a methylene azure-eosin mixture, the bodies of a certain number of the lymphocytes show moderate numbers of so-called azure granules. These granules are usually not found in the lymphocytes from normal blood. They have been variously interpreted (a) as granules of the same specific quality as those in other leucocytes, (b) as secretory products of the cell protoplasm occurring during degenerative changes, and, finally, (c) as very small nuclear fragments set free in the protoplasm of the cell. The last view is strongly suggested by morphological appearances in the cells.

2. **Large mononuclear leucocytes**, with a single, compact or vesicular, rather faintly staining nucleus, and a relatively large amount of protoplasm which stains much less strongly than the nucleus. According to Ehrlich, these cells represent a type different from the lymphocytes; but it is often difficult to make such a distinction on a morphological basis. At the present time they are usually classed as belonging to the group of large lymphocytes, though some observers consider them as precursors of the myelocytes. They may contain azure granules.

3. **Transitional leucocytes**, of the same size as many of the large mononuclear leucocytes, with a compact or vesicular, irregular or

DESCRIPTION OF PLATE II.

All the Specimens are Stained with Eosin and Methylene-azure.

FIG. 1. NORMAL BLOOD.—The red cells are nearly uniform in size and shape. The hæmoglobin is fairly evenly distributed, but is slightly more dense near the periphery than at the centre, especially in those cells which have dried slowly. In rapidly dried red cells the stain is even throughout. To the left is a lymphocyte with reddish, deeply stained nucleus and a pale bluish cell body, which is narrow in proportion to the size of the nucleus. To the right is a small lymphocyte, smaller than the red cells which surround it, with a deeply stained nucleus and a narrow cell body from which projects a small mass of protoplasm. At the upper portion of the figure is a large oval cell which corresponds to the large mononuclear cell of Ehrlich, but considered by many equivalent to a large lymphocyte. In the centre of the drawing is a cell with a lobed nucleus and purplish granules by which this basophile cell is distinguished from the neutrophile just below it and from the eosinophile in the right lower quadrant. Two neutrophile cells are shown, one with abundant fine granules, the other showing a smaller number; both types being abundantly present in normal blood. To the right is a small cluster of blood-plates, some of which show darker staining masses near the centre which are presumed by some observers to be nuclear remains, by others to be fragments of hæmoglobin. The eosinophile cell in the lower right-hand quadrant is distinguished from the neutrophile by the coarseness of its granules, which are shot-like and quite regular in form, though not all the granules are of the same size. They often take a much more brilliant red color than the neutrophiles.

FIG. 2. CHLOROSIS.—The blood was obtained from a young woman of twenty-two years, who had 3,000,000 red cells and 30 per cent. of hæmoglobin. The red cells are about of the same size as those in normal blood, but show a greatly diminished amount of hæmoglobin to the individual cell, as evidenced by the much fainter staining of a number of cells in the plate which appear merely as remnants. Some of the cells have assumed irregular shapes and are known as poikilocytes. In the left upper quadrant are three forms which may be considered as pathological in circulating blood. Below, to the left, is a purplish red cell rather deeply stained, showing polychromatophilia. To the right of this cell and separated from it by a nucleated red cell of normoblastic type is a cell showing granular degeneration.

FIG. 3. SECONDARY ANÆMIA.—The blood was obtained from a case of carcinoma of the stomach in which the red cells were reduced to 1,500,000; the hæmoglobin was 25 per cent.; the leucocytes, 30,000. The changes in the red cells are much the same as those noted in the chlorotic plate. There is marked diminution of the hæmoglobin of the red cells with poikilocytosis and also granular degeneration and polychromatophilia. Two nucleated red cells are present, one in the upper right, the other in the lower left-hand quadrant. Both show degenerative changes in the nuclei, which should not be mistaken for mitotic figures. In secondary anæmia of this type the polynuclear neutrophiles are notably increased.

FIG. 4. PERNICIOUS ANÆMIA.—The blood was obtained from a case showing 400,000 red cells, 10 per cent. of hæmoglobin, and 3,000 leucocytes. The striking features of the blood in this disease are the marked alterations in size, shape, and staining properties of the red cells. The leucocytes are usually diminished in number and show no characteristic changes, with the exception of a relative increase in the lymphocytes. The various types of deformation of the red cells are very well noted in the various poikilocytes in the sketch, some of which contain large quantities of hæmoglobin, others a diminished amount. In the red cells approaching more nearly to the normal form it will be immediately noted that the amount of hæmoglobin present as evidenced by the depth of stain is relatively large. The cell in the centre of the field, for example, stains a great deal more deeply than any normal cell. These deeply staining cells are also very large and often of peculiar oval and irregular form. The so-called megaloblasts are abundantly present in the blood of pernicious anæmia, in contrast to the microcytic type of cell usually found in the secondary anæmias and in chlorosis. It is this macrocytosis with the consequent increase in the hæmoglobin content of each cell that gives rise to the high relative hæmoglobin index of the blood of pernicious anæmia. A normal-sized cell showing marked polychromatophilia is seen above; a macrocyte with granular degeneration is seen below it, and a normal-sized red cell with nucleus, or normoblast. In the lower left quadrant is a large erythrocyte with a large nucleus with fine chromatin network. The cell body takes on a combination of the blue and pink of the stain; in other words is polychromatophilic. Below it is a normal lymphocyte. In the lower right quadrant are two other megaloblasts showing a slightly different morphology and with an orthochromatic protoplasm; that is, the cell body takes the eosin alone. The upper cell shows a dense nucleus with thick strands of chromatin forming a network. In the lower the chromatin shows no structure.

FIG. 5. CHRONIC LYMPHATIC LEUKÆMIA.—The blood of this case showed 3,500,000 red cells, 160,000 leucocytes, and 50 per cent. of hæmoglobin. Of the leucocytes 95 per cent. were lymphocytes. It will be noted from the drawing that the red cells are practically normal in size and shape. The abundance and variety of the lymphocytes will be noted immediately. In the upper right quadrant is a single normoblast; in the lower right quadrant of the upper part is a washed-out cell with irregular outline which is a degenerated lymphocyte. In the acute forms of lymphatic leukæmia these cells become exceedingly abundant.

FIG. 6. MYELOGENOUS LEUKÆMIA.—The blood of this case showed 1,000,000 red cells, 20 per cent. hæmoglobin, and 1,200,000 leucocytes, the exact proportions of which could not be determined on account of the large number of irregular and degenerated forms, but myelocytes and basophiles were very abundant. In the upper left quadrant can be seen an eosinophile myelocyte with a single oval nucleus and large shot-like granules. Below it are a normoblast with granular degeneration of the protoplasm and a polymorphonuclear neutrophile with fine granules. In the lower left quadrant can be seen a large degenerated neutrophile myelocyte in which the granules have become scattered over the slide in the process of spreading the blood. To the right and below the centre are a normoblast with clover-leaf nucleus, a polymorphonuclear neutrophile and a lymphocyte, and above an eosinophile myelocyte. In the upper right quadrant, beginning at the left, can be seen a small basophile cell with faintly staining nucleus, to the right two myelocytes, one with deeply staining nucleus, the other somewhat fainter, both containing neutrophile granules. To the right a normoblast with pyknotic nucleus, and still farther to the right a so-called basket-cell or degenerated leucocyte.




Fig. 1. Normal Blood.



Fig. 2. Chlorosis.




Fig. 3. Secondary Anaemia.




Fig. 4. Pernicious Anaemia.




Fig. 5. Chronic lymphatic Leukaemia.




Fig. 6. Myelogenous Leukaemia.

Changes in the Morphology of the Blood.

incurved nucleus, and a considerable mass of protoplasm, in which fine neutrophile granules can occasionally be demonstrated.

4. **Polynuclear neutrophile leucocytes**, of the same size as the transitional leucocytes, with a partially or completely divided nucleus, of which the separate portions are either compact or vesicular, deeply or faintly staining, and with considerable protoplasm in which distinct granules may be demonstrated by the neutral dyes.

5. **Eosinophile cells**, of the same characters as the ordinary polynuclear leucocytes, but containing in their bodies large refractive granules, which stain deeply with so-called acid dyes such as eosin.

6. **Basophile cells**, of about the same size as the polynuclear cells, but containing coarse granulations stained only by basic dyes such as methylene blue. The nucleus is small, stains feebly, and is usually lobular. It is often covered very largely by the granulations.

These various forms of leucocytes occur in normal blood in the following proportions, which represent averages only and are subject to considerable variations:

Polynuclear neutrophile leucocytes	60 to 72 per cent.
Large mononuclear and transition forms	2 to 4 per cent.
Lymphocytes	22 to 35 per cent.
Eosinophiles	2 to 4 per cent.
Basophile cells less than	0.5 per cent.

In the normal blood of young children the relative proportion of mononuclear cells is considerably greater than in that of adults.

The numbers and proportions of the polynuclear leucocytes are in disease subject to very wide variations, and abnormal forms of the white cells frequently make their appearance in the blood.

THE LEUCOCYTES OF ABNORMAL BLOOD.

1. **Myelocytes**.—In many diseases, especially the leukæmias, large mononuclear cells make their appearance in the blood. They measure from 15 to 20 μ in diameter. (Plate II., Fig. 6.) Three types may be differentiated by the tinctorial relations of their granules: neutrophilic, eosinophilic, and basophilic. The nucleus is usually pale, and oval or round, and lies to one side of the cell. The protoplasm is generally fairly abundant. The neutrophile myelocytes contain large numbers of fine neutrophile granules which, however, often show a basophilic habit when compared with the neutrophile granules of normal blood.

Eosinophile myelocytes are of much the same type, but are easily differentiated by the large size of the granules. The cells are very easily destroyed in the process of making smears, and the granules may be scattered to a considerable distance from the nucleus.

Basophile myelocytes are quite rare, are usually smaller than the other two types, and contain large numbers of irregularly shaped basophile granules. In these cells also a considerable variation in the staining qualities of the granules may be observed, some taking with the Jenner stain a reddish color, others a pale violet.

All these types of cells arise normally from the bone marrow and can be found in smears from this organ. In advanced leukæmias it is probable that the liver and spleen assume to a certain extent their embryonic function and act as centres for the production of these cells.

Myelocytes are found in the blood chiefly in leukæmias, but the neutrophile form occasionally appears in severe infectious diseases and in primary or secondary tumors of the bone marrow. Eosinophile myelocytes have been very rarely seen in high eosinophilia due to the presence of parasites in the body.

2. **Large Lymphocytes.**—While cells of a lymphocytic type appear in normal blood in moderate numbers, a very large cell giving the same staining reactions also occurs in acute lymphatic leukæmia. Until recently these cells were considered as unquestionably large types of lymphocytes; but the demonstration of proteolytic and lipolytic ferments by Longcope¹ and of oxidases by Schultze² suggests that the cells belong to the bone-marrow group, and not to the true lymphocytes which do not give these reactions. A further discussion of this question will be found under acute lymphatic leukæmia (p. 465).

3. **Plasma Cells.**—In severe anæmias and leukæmias and in certain of the infectious diseases, large cells measuring 6 to 15 μ , with a single pale nucleus and a cell body staining very deeply with methylene blue, appear in the circulation. The cell body shows a definite spongy structure. These were named by Türk³ "irritation forms." It has been shown that these cells have many tinctorial relations with the cells seen in large numbers in chronic inflammations occurring in connective tissue, and though there are slight morphological differences between the two forms yet these blood cells are usually considered as of the plasma-cell group.

4. **Myeloblasts.**—In myelogenous leukæmia and also in typhoid fever, large cells resembling myelocytes appear in the circulation, but they contain no characteristic granules stainable either with the Jenner or with one of the azure stains. They can be differentiated from the large mononuclears by the fact that the nucleus is very rich in chromatin and shows large nucleoli. The protoplasm also is more basophilic than that of the large lymphocytes. These cells have been named myeloblasts by Naegeli.

LEUCOCYTOSIS.

Leucocytosis is that condition of the blood in which the leucocytes are temporarily or persistently increased in number. When several forms of leucocytes are increased in number and the usual proportions are but partially disturbed, we speak of *mixed leucocytosis*. Such a condition is seen in some forms of anæmia. When the polynuclear neutrophile leucocytes alone are increased, the condition is termed *polynuclear leucocytosis*, or simply *leucocytosis*. If the mononuclear cells are chiefly

¹ Longcope and Donhauser, Jour. Exper. Med., 1908, x., 618.

² Schultze, München. med. Wchnschr., 1909, lvi., 167.

³ Türk, Vorlesungen über klinische Hämatologie., Wien, 1904.

affected, the condition may be denoted as *lymphocytosis*. The eosinophile cells alone may be increased.

Polynuclear leucocytosis may be either physiological or pathological.

Physiological polynuclear leucocytosis is seen during normal digestion, in the later months of pregnancy, and in the first days of infancy, and is usually of moderate grade.

Pathological polynuclear leucocytosis occurs in many inflammatory and infectious diseases, and accompanies the various cachexias. Of the infectious diseases attended with leucocytosis may be mentioned pneumonia, diphtheria, scarlet fever, erysipelas, rheumatism, suppurative cerebro-spinal meningitis, and any disease associated with a pronounced exudative or suppurative lesion. On the other hand, leucocytosis is absent in uncomplicated typhoid fever, typhus, malaria, measles, and tuberculosis.

The origin and significance of the leucocytosis of infectious diseases are imperfectly understood, but may be partially explained by the principles of chemotaxis and phagocytosis. From experimental evidence and clinical observation it is known that during the onset of some infectious diseases the entrance of bacteria or their products into the blood is followed by a disappearance from the circulation of many polynuclear leucocytes, which are removed from the larger vessels and lodged in the capillaries, principally in the lungs and liver. This condition of the blood, called *hypoleucocytosis*, may be attended with a transient reduction in temperature and weakening of the heart's action, and is usually succeeded shortly by the reappearance of polynuclear leucocytes in large numbers, and by a rise of temperature. These leucocytes are apt to gather in regions in which micro-organisms are abundant, and are believed to take up and destroy micro-organisms (phagocytosis), and to prevent their further entrance, and possibly the entrance of their products also, into the circulation. Of the place and method of origin of these new leucocytes very little is definitely known.

In many very severe cases of infectious disease, such as pneumonia, diphtheria, and peritonitis, the initial hypoleucocytosis persists, in which event the disease usually runs an asthenic and fatal course, with a tendency to low temperature and feeble pulse.

When leucocytosis is established, the grade varies frequently with the extent of the local lesion and the height of the fever associated with the infectious process, and disappears with, or soon after, the decline of the disease. In general, according to our present knowledge, the leucocytosis of infectious diseases may be regarded as the effort of the blood-producing organs to protect the blood and tissues by means of leucocytes against the invasion of micro-organisms and against the action of toxins present in the circulation.

The blood in typhoid fever presents a peculiar variation from that in most infectious diseases. In the first weeks of the disease there is usually a reduction in the number of leucocytes, especially of the polynuclear forms. In the later weeks the lymphocytes may form 80 per cent. of the leucocytes present in the blood. Each relapse is attended

with an increase of the lymphocytosis, while an increase of polynuclear leucocytes usually occurs with complications only.

In the various forms of tuberculosis there is no leucocytosis unless the lesion is markedly exudative in character, as in tuberculous meningitis, or is complicated by suppuration or chronic anæmia. In pulmonary tuberculosis with secondary infection by pyogenic cocci, leucocytosis is apt to develop.

Cachectic leucocytosis is a feature of altered conditions of the blood, such as are associated with the growth of malignant tumors, and with many diseases producing secondary anæmia. This increase of polynuclear leucocytes may serve to distinguish many forms of secondary from primary anæmia. The inflammation and toxæmia accompanying many new growths afford a sufficient reason for the appearance of cachectic leucocytosis, but under many other circumstances its direct cause is less apparent.¹

Hypoleucocytosis occurs not only in infectious diseases, when the polynuclear cells alone are reduced in numbers, but also from shock, reduction of body temperature, and exhaustion, when all forms of leucocytes may be diminished. It is a fairly constant feature of primary pernicious anæmia.²

Polynuclear Eosinophile Leucocytosis is found in a number of unrelated conditions. In bronchial asthma the eosinophile cells are considerably increased, often forming 10 to 20 per cent. of the total white cells. A considerable increase is seen in scarlatina. In acute and chronic diseases of the skin, such as pemphigus, prurigo, and psoriasis, the eosinophiles are often increased to a marked degree, but the condition is not constant. In trichinosis and helminthiasis the increase is so constant that it becomes of diagnostic value in these conditions. A post-febrile eosinophilia is frequently observed.

Lymphocytosis, frequently seen in the anæmias, in pertussis, and the acute intestinal disorders of childhood, has also been noted in some forms of secondary anæmia (syphilis), and in an extreme degree as the chief characteristic of the blood of lymphatic leukæmia. It is also quite frequent in exophthalmic goitre.

Degenerative Changes in the Leucocytes are usually indicated by variations in the percentage of normal and abnormal varieties, rather than by alterations in the individual cells, for degenerating leucocytes are usually quickly removed from the circulation. Occasionally, however, there may be seen in normal blood a cell in which the nuclear chromatin has entirely lost its power to take the stain; and these degenerating or basket cells are sometimes very abundant in the leukæmias. Staining reactions of the various granules, by which degenerative changes may be recognized, have not yet been devised. In leukæmia, pernicious anæmia, and diphtheria, a diminished reaction to nuclear dyes has been observed. In leukæmia, and in the severe infectious diseases, the

¹ For further data concerning leucocytosis consult *Rieder*, "Beiträge zur Kenntniss d. Leukocytose," Leipzig, 1892; *Türk*, "Klin. Untersuchungen u. d. Verhalten d. Blutes," etc., Wien, 1898.

² For hypoleucocytosis consult *Löwit*, "Studien über Physiol. und Pathol. d. Blutes u. d. Lymphe," Jena, 1892; *Ewing*, "Toxic Hypoleucocytosis," New York Medical Journal, vol. lxi., p. 257, 1895.

leucocytes may be extremely cohesive, and it is believed that a large quantity of bacteria or toxins in the circulation may even effect a complete solution and destruction of leucocytes (leucocytolysis). Fatty and glycogenic degeneration of leucocytes has been demonstrated.

Blood Plates.—These are small spherical or oval transparent bodies which appear in the blood plasma in large numbers. They measure from 2 to 3.5 μ in diameter, though occasionally in pneumonia and suppurative conditions very large plates may be found measuring up to 5 or 6 μ . Structurally they are composed of a peripheral hyaline transparent layer with a granular central mass which is not sharply outlined. This granular mass takes a faint color with the ordinary chromatin stains; the periphery is clear. In stained specimens it is occasionally possible

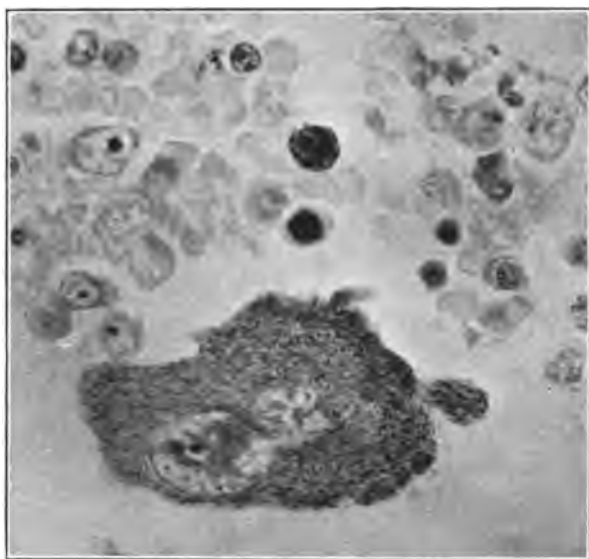


FIG. 278.—MEGAKARYOCYTES FROM BONE MARROW. SHOWING FORMATION OF BLOOD PLATELETS. From preparation of Dr. J. H. Wright.

to find long curved protoplasmic processes, simulating cilia, given off from the periphery of the blood plate. Under suitable conditions the blood plates show ameboid motion.

Their number in the blood varies, the average number is considered as approximately 200,000 to 250,000. The number of blood plates is increased in many anemias, both primary and secondary, and especially in carcinoma. In pneumonia, septic processes, and leukemia there is also an increased number of blood plates. A diminution of the plates is noted chiefly in cases of purpura and pernicious anemia.

The blood plates are closely connected with the formation of thrombi, and some of the small, so-called white thrombi are entirely composed of

these bodies. They are also thought to carry the blood-coagulating ferment, thrombokinase.

There are a number of theories concerning the origin of blood plates. Hayem considered them predecessors of the red blood cells. Others regard them as individual cells, and not as fragments of leucocytes or red cells as has also been frequently suggested. The theory that they are formed by the extrusion of the nuclear substance of the red cells has had many adherents. Wright¹ has recently offered very strong evidence that blood plates are formed from the megakaryocytes of the bone marrow. These cells frequently show budding masses of the same structure as the blood plates (see Figs. 278 and 279). The hyaline peripheral zone

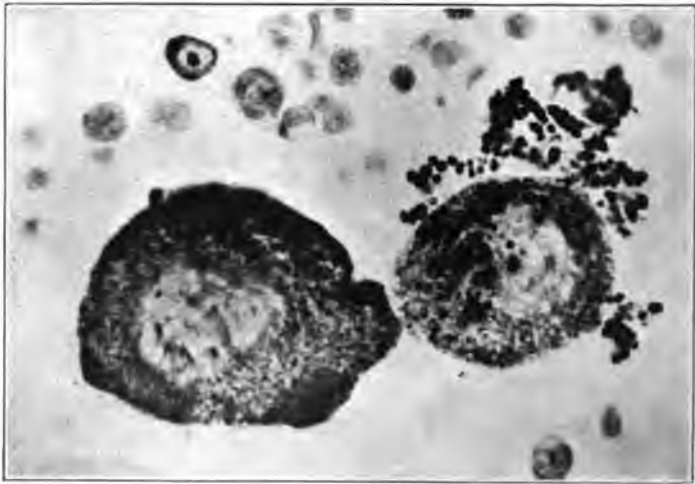


FIG. 279.—MEGAKARYOCYTES FROM BONE MARROW. SHOWING FORMATION OF BLOOD PLATELETS. From preparation of Dr. J. H. Wright.

of the giant cell has the power of amœboid motion and can be observed on the warm stage to give out protoplasmic processes. In addition the blood plates are found only in such mammalia as have megakaryocytes in the bone marrow, and it has also been noted that blood plates appear only in embryonal mammalian blood at the time when the giant cells are present in the blood-forming organs.

METHODS OF EXAMINATION OF THE BLOOD.

The blood may be examined fresh on the warm stage without the addition of any fixative, simply surrounding the cover with oil or vaselin to prevent evaporation. This method is especially useful in the examination of blood for the plasmodia malariae. For most purposes, however, the cells should be treated the instant the blood leaves the vessels in such a way as to retain their normal form. This fixation may be accomplished by the use of chemical agents (wet method) or by quick drying on the cover-glass or slide (dry method).

¹ Wright, *Jour. of Morphology*, 1910, xxi., 2.

WET METHOD.—Among the chemical fixative agents are osmic acid and a solution of corrosive sublimate. *Osmic acid:* Five c.c. of a 1-per-cent. solution of osmic acid are mixed with 10 drops of glacial acetic acid in a Petri dish. Short pieces of glass tubing are placed in the dish to support the slide which is exposed to the vapor of the acids for two minutes. The finger is then punctured and the blood spread in a thin film upon the surface of the slide which has been exposed to the vapor. The slide is then again exposed to the vapor for one minute. It is allowed to dry, passed three times through a film, washed for one minute in a dilute solution of potassium permanganate (extemporized from a concentrated solution by diluting until the fluid is a deep pink), washed in water, dried, and stained by any of the ordinary methods. If it is not desirable to dry the slide it may be transferred into a very dilute alcohol and carried up by stages of 10 per cent. until thoroughly fixed.¹

Sublimate may be used in the form of Hayem's solution, consisting of

Chlorid of sodium	1 gm.
Sulphate of sodium	5 gm.
Corrosive sublimate	0.5 gm.
Water, distilled	200 gm.

The blood is received directly into this solution, in which it is studied. The wet method of fixation is especially to be recommended for studies on the minute structure of blood cells.

Another solution which is highly recommended² is made up as follows:

Müller's fluid	9 parts.
Formaldehyde, 40 per cent.	1 part.
Distilled water	10 parts.

The solution should always be made up fresh and warmed to about 40° C. The fixed blood is washed in distilled water until all the chrome salts are removed, passed through graded alcohols to absolute, transferred to absolute alcohol and carbon bisulphid equal parts, and then to pure carbon bisulphid, carbon bisulphid and paraffin, and finally embedded in paraffin. Thin sections can be cut, which often demonstrate interesting phases of mitosis and other phenomena in the cells.

None of these methods of fixation in bulk, however, is as satisfactory as the Weidenreich or the dry smear methods.

DRY METHOD.—It has been found that if the freshly drawn blood from a finger prick be immediately dried on a glass in a very thin layer, the cell forms are quite well preserved and may be exposed to the action of staining agents.

For this purpose square cover-glasses of medium size should be cleaned in strong nitric acid, rinsed in alcohol and ether, carefully dried, and kept free from dust. A drop of blood may be expressed by very light pressure only from the finger tip, previously cleansed with alcohol and ether, and for the best results the drop must be spheroidal and about one-sixteenth of an inch in diameter. One cover-glass should be held in the forceps, or between the fingers if thoroughly dry, and its central point touched to the drop of blood. After contact with the blood this cover-glass should be instantly laid upon a second glass so as to cover all but an eighth of an inch along one side; and as soon as the blood has spread to the edges, the cover-glasses should be quickly separated by sliding without pressure and dried in the air. If, instead of drying in the air, the specimens are rapidly dried high over an alcohol flame, the fixation will be more successful, and many artificial changes in the red cells will be avoided.

Another method, more successful in many hands, consists in touching the drop with the smooth edge of a glass slide, applying this edge with its adherent blood obliquely to a slide, and, when the blood has spread along the edge of the slide, drawing it rapidly across the surface of the second slide.

For the permanent fixation of the cells and to prevent their solution by strong dyes, one of two methods may be recommended:

¹ *Weidenreich, Folia hæmatologica, 1906, iii., 1.*

² *Schridde u. Naegeli, Hamatologische Technik, Jena, 1910.*

1. *Heat Fixation*.—The specimens are heated in a hot-air bath or on a copper plate, for from five minutes to two hours at a temperature of 110° C. to 120° C.

2. *Chemical Fixation*.—The specimens are placed for from one to thirty minutes in strong methyl alcohol.

Various staining agents are to be employed according to the object in view. The triacid mixture of Ehrlich¹ gives an excellent stain for the neutrophile and eosinophile granules, but fails to show basophile granules or parasites, for which reason it is being supplanted for general work by combinations of methylene blue and eosin. The composition of the Ehrlich stain is as follows:

Saturated aqueous solutions of

Orange G	13 to 14 c.c.
Acid fuchsin	6 to 7 c.c.
Methyl green	12.5 c.c.

To the mixture of these add

Water	15 c.c.
Absolute alcohol	25 c.c.
Glycerin	10 c.c.

The specimen should be stained in this fluid for three to five minutes, washed in distilled water, dried, and mounted in dammar dissolved in xylol.

The red cells are then found stained orange-yellow, the nuclei dark green or blue, the neutrophile and eosinophile granules dark red. The mast-cell granules are not stained.

For general purposes a stain which has been devised by Jenner bids fair to supplant the older methods on account of its simplicity, rapidity, and ease of application. It consists of a half-per-cent. solution in methyl alcohol of a compound made by mixing a 1.2-per-cent. aqueous eosin and a 1-per-cent. aqueous methylene-blue solution. The precipitate which forms is filtered off, washed with distilled water, dried, and dissolved in the methyl alcohol. The blood smears are fixed and stained by this solution in from one to three minutes. The red cells are of a terra-cotta color, the nuclei blue, the neutrophile and eosinophile granules red, the mast-cell granules purple; bacteria, malarial organisms, and blood plaques blue.

An extremely satisfactory stain which not only demonstrates the important morphological details of the red and white cells, but also gives a characteristic chromatin stain to the malarial parasite is the following:²

Five gm. of sodium bicarbonate, 10 gm. of methylene blue (B. X. or "medicinally pure") and 1,000 c.c. of water are heated in a steam sterilizer at 100° C. for a full hour. The mixture should be contained in a flask of such size as to allow it to form a layer not over 6 cm. deep. After cooling it is filtered to remove the precipitate. When cold it should be of a deep purple-red-color when viewed in a thin layer by transmitted yellowish light.

To each 100 c.c. of the filtered mixture, 500 c.c. of a 0.1-per-cent aqueous solution of Grüber's "yellowish, water-soluble" eosin are added and mixed thoroughly. The precipitate which appears immediately is collected on a filter and when dry dissolved in methylic alcohol (Merck's reagent) in the proportion of 0.1 gm. to 60 c.c. of alcohol, rubbing them together in a porcelain dish or mortar to facilitate solution. This forms the staining fluid. It should be kept in a well-stoppered bottle, and if it becomes too concentrated by evaporation, may be thinned by the addition of the proper amount of methylic alcohol. The method of staining is as follows:

1. Cover the film with a *noted* quantity of the stain with a medicine dropper.

2. After one minute add to the staining fluid on the film an equal quantity of distilled water by means of the dropper, and allow the mixture to remain for two or three minutes according to the intensity of the stain desired. Too long staining may

¹ Great care must be used in selecting these dyes. Those made by Grüber, of Leipsic, are reliable. It is far better to purchase the solution already mixed as sold by Grüber under the name of "triacid mixture for neutrophile granules."

² Wright, Jour. Am. Med. Assn., 1910, lv., 1979.

produce a precipitate. Eosinophilic granules are best brought out by a short staining period.

3. Wash the preparation in water for thirty seconds, or until the thinner portions of the film become yellow or pink.

4. Dry and mount in xylol-dammar.

Films more than a few hours old do not stain as well as fresh ones.¹

For the demonstration of *fat* in blood from a finger prick, cover-glass preparations dried in the air should be fixed in formalin vapor and stained with Sudan III (see p. 44). To avoid numerous sources of error, a control preparation should be previously placed in chloroform for twenty-four hours to dissolve the fat, and two specimens, carried together through the stain. In the one, red fat droplets will be seen, which should be entirely absent in the other.

FOREIGN BODIES IN THE BLOOD.

Various bodies which do not belong there, aside from those above mentioned, may find access to the vessels and mingle with the blood. Pus cells may get into the blood from the opening of an abscess into a vessel or from some inflammatory change in its walls. Desquamated endothelial cells from the vessel walls, either in a condition of fatty degeneration or in various stages of proliferation, may be mingled with the normal blood elements; also tumor cells of various kinds, fragments of disintegrated thrombi, portions of heart valves, etc. Crystals of bilirubin have been found in the blood in icterus, and Charcot-Leyden crystals have been seen post mortem in the blood and bone marrow of cases of leukæmia.

Fat, in a moderate amount, is a normal ingredient of the blood, during digestion and in lactation it is increased. Under pathological conditions it may occur in larger and smaller droplets. This *lipæmia* occurs in diabetes, in drunkards, in acute phosphorous poisoning, and in some cases of dyspnoea from various causes. The droplets are small and liable to escape observation, but if the blood is kept a white layer of fat collects on the surface of the serum as it separates.

In many cases of injury, particularly in crushing fractures of the bone, the fat of the marrow finds its way into the blood, and it may collect in large drops in the vessels of the lungs, forming the so-called *fat emboli* (Fig. 9, p. 30); or it may pass the lungs and form emboli in other parts, as the brain, kidneys, etc. Fat embolism in eclampsia is of occasional occurrence.

The fat may be absorbed from the vessels, having produced little or no disturbance; or in some cases it may produce serious results by the stoppage of a large series of vessels in the lungs, brain, or other parts of the body.²

Tissues and organs whose blood-vessels are suspected to contain fat droplets should be fixed in Müller-formol or 4 per cent. formaldehyde and thoroughly washed in water. Frozen sections are then treated with a mixture of equal volumes of Müller's fluid and 2 per cent. osmic acid, or stained with Sudan III (see p. 44). The sections should then be stained with hæmatoxylin and mounted in glycerin.

¹ For other blood stains see under Malaria, page 316.

² For résumé of this subject, with bibliography, consult Welch in article on Embolism in Allbutt's "System of Medicine," vol. vi., p. 258.

Air, as a result of an opening in the veins, is of occasional occurrence. If the amount of air be small, it appears to be readily absorbed, and does little or no harm. If, on the other hand, a large quantity is admitted to the veins at once, it collects on the right side of the heart, from which the contractions of the organ are unable to force it in any considerable quantity, and, the supply of blood being thus cut off from the lungs, death very quickly ensues. The blocking of the smaller pulmonary vessels and of the vessels of the heart with air bubbles may also hasten death. It is especially from wounds of the veins of the neck and thorax that the accident is most apt to occur. But it may be due to the introduction of air into the uterine veins in intra-uterine injection, or in the removal of tumors.¹ One should remember in this connection that infection with *Bacillus aërogenes* gives rise to gas bubbles in the blood-vessels, as well as in other tissues (see p. 289) and that gas may form in the blood in caisson disease (see p. 11).

Parasites and other Foreign Bodies in the Blood.—The occurrence of animal and vegetable parasites is considered more in detail in parts of this book devoted to these organisms. It will suffice to mention here that the more important of the parasites found in the blood are: The *Plasmodium malariae*, *Trypanosomata*, *Filaria sanguinis hominis*, the embryo of *Trichina spiralis*, the *Spirillum Obermeieri*, and the *Spirochæta pallida*.

The various forms of bacteria which may be found in the blood will be considered in parts of this book in which these organisms are treated in detail.² Parenchyma-cell emboli are considered on page 29.

Melanæmia.—In this condition the blood contains larger and smaller irregular-shaped particles or masses of brown or black pigment. This condition is most frequently the result of intermittent and remittent fever, particularly the severer forms. It may be accompanied by anæmia and leucocytosis. It does not occur in all cases of the above-named affections. It may be transient in character. The pigment may be free, or, more usually, enclosed in leucocytes. Under the same conditions pigment may be deposited in the liver, spleen, lymph-nodes, bone-marrow, and blood-vessels. Owing to the deposit of pigment in the organs they may assume a gray or slate color. The pigment developed in malaria originates in the decomposition of the hæmoglobin under the influence of the plasmodium. Pigment which has been taken into the lungs from the air, such as coal dust, etc., may find its way into the blood either before or after deposition in the bronchial or other lymph-nodes, and may be afterward deposited in the spleen and liver.³

¹ *Welch, ibid.*, Allbutt's "System of Medicine," vol. vi, p. 254.

² For methods and results of bacterial studies of the blood, with bibliography, consult *Kühnau*, *Zeit. f. Hyg.*, Bd. xxv., p. 492, 1897; *Rosenberger*, *Am. Jour. Med. Sci.*, vol. cxxvi., 1903, p. 234; *Canon*, "Die Bakteriologie des Blutes," Jena, 1905; *Lenhartz*, "Die Septischen Erkrankungen," Wien, 1903. For method of demonstrating animal parasites see *Stäubli*, *Münch. med. Woch.*, 1908, No. 50.

³ For further details concerning changes in the blood consult *Simon*, "Clinical Diagnosis," 4th ed.; *Ewing*, "Clinical Pathology of the Blood," 1903; *Cabot*, "Clinical Examination of the Blood," 1904; or *Wood*, "Chemical and Microscopical Diagnosis," 3d ed., 1911.

General Diseases Involving the Blood and Blood-Forming Organs.¹

There is a group of diseases in which the most striking lesion seems to be an alteration in the composition of the blood, although in some members of the group other lesions are also present. This group embraces chlorosis, secondary and pernicious anæmia, leukæmia, and certain closely related, but still obscure conditions.

CHLOROSIS.

Chlorosis is a disease of the blood seen in women only and attended with a diminution in the hæmoglobin, and usually in the number of the red blood cells.

Of the essential element in the incitement of this disease and of the exact method of its origin we are ignorant. The condition has been attributed to congenital hypoplasia of the heart and blood-vessels, to prolonged malnutrition, to intestinal intoxication, and to functional disturbance of an unknown nature in the blood-producing organs.

In the mildest grade of chlorosis the only change to be observed is a slight diminution of hæmoglobin. In severer forms may be added a diminution in number and moderate variations in size and shape of the red cells. In very severe and relapsing cases the hæmoglobin may be excessively decreased, the color index falling even as low as 0.4; the red cells may number less than two millions per cubic millimetre, and the average size of the cells be less than normal. The leucocytes are not increased in number. There may be a slight relative increase of the lymphocytes; megalocytes, microcytes, and poikilocytes may appear (see Plate II., Fig. 2). Polychromatophilia is frequent.

The specific gravity of the blood is diminished in proportion to the fall in hæmoglobin; the total quantity is greatly increased. The time of coagulation is often very short, a change undoubtedly correlated with the not infrequent thrombosis seen in chlorosis. Even in cases of considerable severity the degenerative changes in the viscera characterizing other forms of anæmia have been found wanting, although degenerative changes in the red cells may occur in accordance with the severity of the disease. The liver does not contain an excess of iron, and the urine is free from pathological urinary pigments.

The regeneration of the blood in chlorosis under rest and treatment with iron may usually be rather promptly effected by increased activity of the red marrow, which is probably hyperplastic. This regenerative progress may be indicated in the blood by the periodical appearance of considerable numbers of normoblasts. The appearance of these nucleated red cells may be accompanied by a moderate increase of leucocytes, both mononuclear and polynuclear. Myelocytes also may rarely be seen.

¹ For a full discussion of the subjects treated in this chapter the reader is referred to *von Noorden*, "Bleichsucht," Nothnagel's "Spec. Path. u. Therap.,"; *Ehrlich* and *Lazarus*, "Die Anaemie," Nothnagel's "Spec. Path. u. Therap.,"; *Helly*, *ibid.*, "Die Hämato-poetischen Organe," and *Naegeli*, "Blutkrankheiten und Blutdiagnostik," Leipzig, 1908.

SECONDARY ANÆMIA.

While chlorosis may be considered usually a disease of adolescence, and while its occurrence is confined to the female sex, there is another type of blood change which seems best classified under the heading of secondary anæmia, and which is independent of sex or age. The determining agents are either of a general nature, such as poor food and bad air, or they are actual diseases, or they may be intestinal parasites, or, finally, chronic poisoning. Among those diseases which are likely to induce a well-defined anæmia we may mention prolonged suppuration, mycotic endocarditis, diseases of the stomach and intestines, malaria, syphilis, and malignant tumors. The intestinal parasites are chiefly the *Ankylostoma duodenale* and the *Bothriocephalus latus*. The poisons

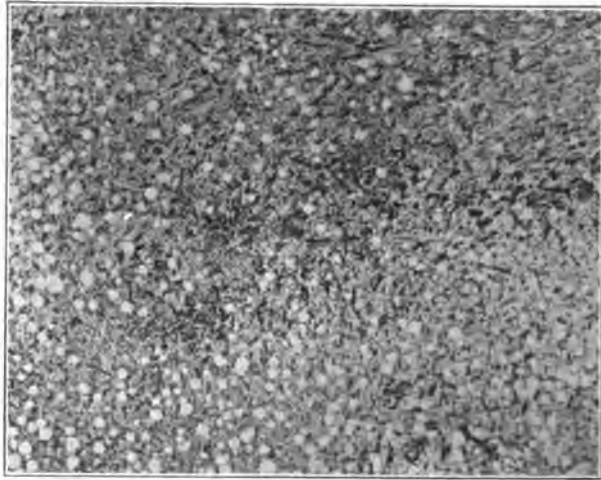


FIG. 280.—BONE MARROW FROM SHAFT OF FEMUR FROM CASE OF SECONDARY ANÆMIA DUE TO RECURRENT CARCINOMA.

The normal fat tissue is to a certain extent replaced by an ordematous reticular connective tissue containing islands of nucleated red cells and myelocytes. The hyperplasia is not so extensive as that seen in leukæmia or pernicious anæmia, in which often all of the fat is replaced by the new growth of cells.

are lead and, more rarely, arsenic. The alterations which are apparent on examining the blood are very variable, depending upon the agent. The hæmoglobin is regularly diminished to a greater per cent. than the red cells; it may fall as low as 15–20 per cent.; the red cells rarely fall below one million. Nucleated red cells of the normoblastic type are frequent in the severe cases; megaloblasts are not found except in advanced cases of *Bothriocephalus* anæmia. As a rule the average diameter of the red cells is slightly below normal, with a moderate poikilocytosis. Granular degeneration is present to a variable extent in the red cells except in malaria and lead poisoning, when it is the rule. In the anæmias produced by the *Bothriocephalus* the blood picture may

be that of pernicious anæmia, with a great increase in the size of the cells and the appearance in the blood of numerous megaloblasts, thus forming an exception to the general rule that the blood of secondary anæmia is normoblastic in type. In the anæmia due to the *Ankylostoma* or the *Uncinaria* the blood shows the picture of a chlorotic anæmia often accompanied by a considerable eosinophilia, which is not usually seen in the *Bothriocephalus* variety. The leucocytes are increased in anæmia due to suppuration and in about 50 per cent. of the tumor cases; in other forms there is usually but little change in the number, though it is impossible to formulate a general rule (Plate II., Fig. 3). When, however, a tumor invades the bone marrow an extensive hyperplasia of this tissue may occur with consequent flooding of the blood current with large numbers of immature leucocytes so that the blood simulates that of myelogenous leukæmia (Fig. 280).

PERNICIOUS ANÆMIA.

Pernicious anæmia is a disease of the blood and blood-forming organs, characterized by excessive destruction associated with defective production of red cells.

The exact relation of the factors concerned in the causation of the disease has not been determined. It may be said, however, that while very rapid cases of pernicious anæmia have been observed unaccompanied by the usual lesions in the bone marrow associated with defective hæmatogenesis, the disease seems not to exist without excessive hæmatolysis.

Pernicious anæmia may probably originate as a primary disease of the blood or bone marrow, but many cases apparently primary have been shown at autopsy to be secondary to such conditions as cancer, nephritis, tuberculosis, atrophy of the gastric mucosa, or the presence of parasites in the blood or intestine. The studies of Hunter indicate that the destruction of the blood may in some cases result principally in the portal circulation and particularly in the spleen from the action of toxic substances absorbed from the intestines, and Herter has shown that the toxic products arising from anaërobic putrefaction of the proteins by certain bacteria may play an important part in the induction of hæmatolysis. Whatever its origin, the distinguishing feature of pernicious anæmia is the fact that the anæmia is entirely disproportionate to any apparent cause, and when once established tends to progress to a fatal issue.

The essential lesion is an extreme and progressive diminution in number and very great variation in size and form of the red blood cells (as shown in Plate II., Fig. 4). Nearly constant is a widely distributed lesion of the bone marrow, in which the normal nucleated red cells are partly replaced by an excessive number of larger nucleated corpuscles or megaloblasts, with atrophy of fat cells. The destruction of hæmoglobin is followed by a considerable deposit of iron in the liver, spleen, marrow, and other organs, and by the appearance of abnormal pigment in the urine. The prolonged anæmia may be accompanied by fatty degenera-

tion in the viscera, especially of the liver, kidneys, and heart muscle. As a combined result of fatty changes in the arterial walls and of the diminution in albuminous ingredients and in the coagulability of the blood, hæmorrhages in various parts of the body, especially the retina, are of frequent occurrence. Disseminated areas of sclerosis in the spinal cord have been described and regarded as the result of minute hæmorrhages in this region.

In the blood the red cells are usually reduced to less than two millions and occasionally to half a million per cubic millimetre. Of the remaining cells a considerable percentage may be abnormally large (megalocytes), or very small (microcytes). Cells of very irregular shape are often present in abundance (poikilocytes) (Plate II., Fig. 4). The quantity of hæmoglobin in the majority of the cells is usually increased, but may be diminished in a certain proportion of cells, which then resemble those found in chlorosis. The "hæmoglobin index"—that is, the relation of the total percentage of hæmoglobin to the total number of cells—may be normal when a deficiency of hæmoglobin in one cell is counterbalanced by a proportionate excess in another, but in general it is greater than unity.

A variety of degenerative changes in the red cells are commonly present, including especially those alterations in the staining reactions of the protoplasm known as *polychromatophilia* and *granular degeneration*. In the first the cell stains a more or less uniform blue with methylene blue; in the second the cells contain granules which give a strong basophilic staining reaction.

Nucleated red cells of normal size (normoblasts) are of frequent occurrence in the blood of well-established pernicious anæmia. Abnormally large nucleated red cells (megaloblasts) are a nearly constant element at some stage of the disease and are of great diagnostic importance, as they indicate the presence of a grave lesion in the bone marrow. They are more abundant than the normoblasts in well-developed cases.

Megalocytes and megaloblasts usually show an excess of hæmoglobin, may exhibit amœboid movement, and have no tendency toward the formation of rouleaux. Extremely large nucleated red cells (gigantoblasts) are frequently found in advanced cases, and in these cells as well as in the megaloblasts the nuclei may be rarely seen in various stages of normal or pathological mitosis. "Blood crises," by which is indicated the appearance of large numbers of normo- or megaloblasts in the circulation, may occur in pernicious anæmia, but it must be remembered that the blood picture in any severe anæmia varies much from day to day without any marked alteration in the general condition of the patient. In the absence of complications producing leucocytosis in pernicious anæmia, the leucocytes are usually diminished in number. There is a relative increase in the number of lymphocytes, and usually a few myelocytes may be found.

Aplastic Anæmia.—A very rare variety of a rapidly fatal form of anæmia has been described in which the number of red cells is diminished without the blood showing the changes characteristic of pernicious

anæmia. The bone marrow in these cases has been found to be fatty instead of hyperplastic as in the typical marrow of pernicious anæmia. It has been suggested that the bone marrow for some unknown reason had not responded to the call made upon it by the rapid hæmatolysis taking place in the disease, and therefore did not undergo the megaloblastic changes so characteristic of the bone-marrow in well-marked cases of pernicious anæmia.¹

LEUKÆMIA (LEUCOCYTHÆMIA).

Leukæmia is a disease in which the characteristic changes are an alteration in the relative proportions of the different leucocytes of the blood, with usually an increase in their number, and the appearance of certain forms not seen in the circulation under normal conditions. The red cells are diminished in number, and abnormal forms appear in the blood. Accompanying these alterations in the circulating blood are changes in the bone marrow, less often in the spleen and in the lymph-nodes. Its inciting factors are still unknown. Leukæmia may be classed in four types, which are fairly well defined clinically and morphologically, but between these there exist many transitional forms, especially from the point of view of the morphology of the blood. These four types are the acute and chronic lymphatic leukæmia and the acute and chronic myelogenous leukæmia (spleno-myelogenous).

Acute Lymphatic Leukæmia is a disease resembling clinically an acute infection, with a rapidly increasing anæmia, enlargement of the lymph-nodes, as a rule, and a moderate increase in the size of the spleen and liver. Cases are on record, however, in which there was no enlargement of the spleen or lymph-nodes.² The blood changes are very characteristic. The red cells diminish rapidly in numbers, normoblasts and occasionally megaloblasts are present, and the leucocytes are increased, though usually below 100,000. The forms present are chiefly lymphocytes, either large or small, the large, as a rule, predominating. While the staining reactions of the large lymphocytes in this disease correspond with those of the cells of normal blood, yet Longcope³ has shown that they contain a proteolytic and lipolytic ferment characteristic of the granular types of cells from the bone marrow. This has been confirmed⁴ by the discovery that in the large lymphocytes it is possible to demonstrate an oxidase, a ferment heretofore considered to be confined to the granular types. These findings indicate that the cells in question should be considered rather as myeloblasts than as large lymphocytes. The bone marrow is altered to a tissue showing large numbers of lymphocytes, the so-called lymphoid hyperplasia, which often extends to the lymphoid tissue in the viscera.

Chronic Lymphatic Leukæmia.—The blood shows a severe anæmia with great increase in the lymphocytes. The small forms of the lympho-

¹ For a study of a series of such cases see *Lavenson*, *Am. Jour. Med. Sci.*, 1907, vol. cxxxiii., p. 100.

² See *Kelly*, *Univ. Penn. Med. Bull.*, 1903, p. 270.

³ *Longcope and Donhauser*, *Jour. Exper. Med.*, 1908, x., 618.

⁴ See *Schultze*, *München. med. Wehnschr.*, 1909, lvi., 167, and *Peters*, *ibid*, 1478.

cytes are most abundant, in contradistinction to the acute type of the disease, in which the large forms are usually in excess. The lymph-nodes and spleen are usually enlarged; the bone marrow is in a condition of lymphoid hyperplasia, and there are lymphoid infiltrations in the various organs (see Figs. 281 and 282 and Plate II., Fig. 5).

Acute Myelogenous Leukæmia.—A few cases of leukæmia of the myelogenous type have been reported in which the clinical course was very acute, with a rapidly increasing anæmia and the occasional appearance of nucleated red cells. In some of the cases the blood was not characteristic and the diagnosis could be made only after death by a

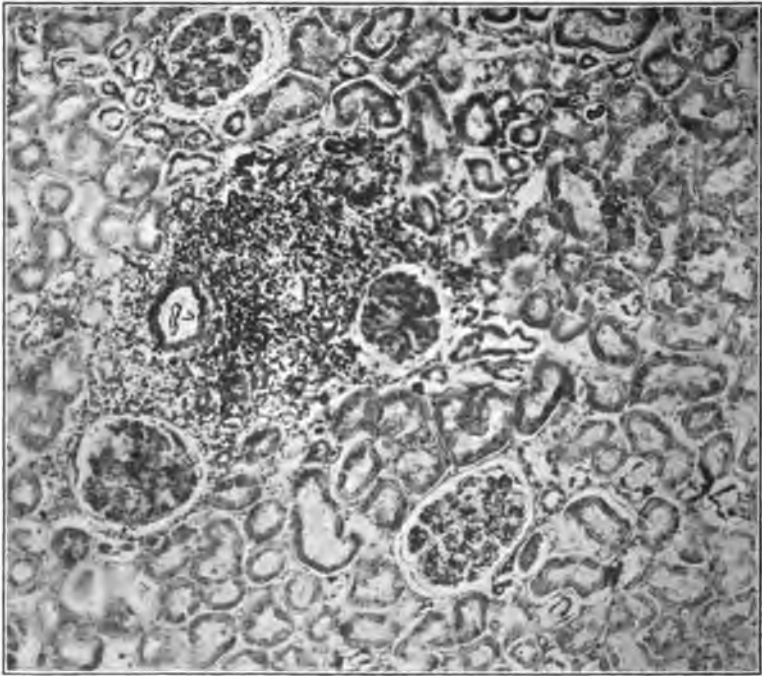


FIG. 281.—LEUKÆMIC INFILTRATION OF KIDNEY IN CASE OF LYMPHATIC LEUKÆMIA.

study of the changes in the bone marrow; in others the blood picture resembled that of a chronic myelogenous leukæmia with the usual large percentage of myelocytes. Some of the cases diagnosed as acute myelogenous leukæmia were undoubtedly of the type of disease known as chloroma, while others were presumably acute infections with a high leukocytosis and the appearance of a few myelocytes in the blood with a marked hyperplasia of the bone marrow due to the prolonged septic condition. The difficulties in the diagnosis of acute myelogenous leukæmia are complicated by the fact that the lymphocytes in acute lymphatic leukæmia may be greatly diminished toward the end of the disease,

and a few myelocytes may appear under these conditions, thus rendering a differentiation impossible.¹

Chronic Myelogenous Leukæmia.—The blood shows a severe anæmia, rarely of a pernicious type, with marked quantitative and qualitative changes in the leucocytes. The increase in number of white cells may be to more than one million per cubic millimetre. Myelocytes, both neutrophilic and eosinophilic, are quite constantly present in considerable numbers. They may form a large proportion of the leucocytes

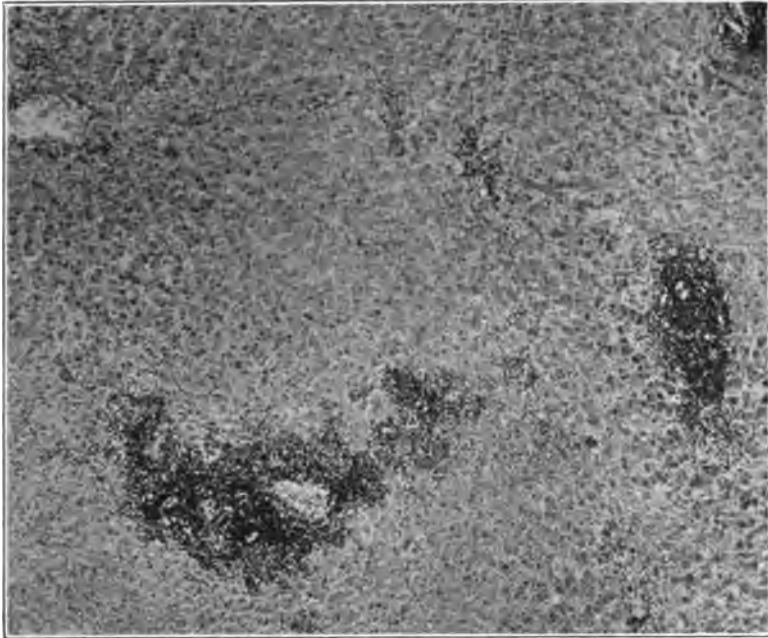


FIG. 282.—LIVER FROM A CASE OF LYMPHATIC LEUKÆMIA.

Showing infiltration of the organ with leucocytes. The large collections are in Glisson's capsules, but small numbers are seen between the liver cells.

present. Basophile cells are very abundant in cases of long duration, especially the type with polymorphic nuclei, myelocytes with basophilic granulations being rare. In rapidly advancing cases mitoses may be rarely seen in the red cells and in the leucocytes (see Plate II., Fig. 5).

The pathological forms of leucocytes in myelogenous and lymphatic leukæmias have little or no amœboid motion. This explains the interesting fact that the pus from an abscess in a leukæmic subject contains only the polynuclear neutrophile cells found in such exudates in persons with a normal blood condition. In acute infections and after treatment with the Röntgen rays, the number of myelocytes present in the circu-

¹ Billings and Capps, "Acute Myelogenic Leukæmia," Amer. Jour. Med. Sci., vol. cxxvi., p. 375, 1903.

lation may be greatly reduced and the blood may even lose the cell forms characteristic of leukæmia, the myelocytes being replaced by lymphocytes or the ordinary polynuclear leucocytes of normal type.

The same condition may be seen in mild cases, which may under treatment reach a point in which it is difficult to make a diagnosis from the blood alone.

In this connection it must be remembered that the blood picture in pernicious anæmia and the leukæmias is a very variable one. As a rule, more than one examination is necessary for a certain diagnosis, and it must not be forgotten that occasionally a case, apparently of pernicious anæmia, may go on to a typical lymphatic or myelogenous leukæmia.

In myelogenous leukæmia there is hyperplasia of the bone marrow, which usually fills the shafts of the long bones with a firm, pink mass composed largely of myelocytes. This hyperplasia may involve the whole bone marrow of all the long bones, or it may be confined to irregular, scattered areas, so that one should be critical in accepting reports of cases of leukæmia without bone-marrow changes. The other organs show hyperplasia of lymphoid tissue, often especially well marked in the gastro-intestinal tract, while scattered through the spleen are often seen numerous small areas containing myelocytes.

There is some reason to think that in the spleen, for instance, some multiplication of the cells goes on in the so-called "marrow cell or myeloid metastases." The same change may rarely be seen in the liver and lymph-nodes. In the blood, spleen, and marrow, after death, elongated octahedral crystals (called Charcot-Leyden crystals) are occasionally found. Hæmorrhages into the serous and mucous membranes and the retina are quite frequent, especially the latter, and fatty degeneration of the viscera is a quite constant expression of the impoverished condition of the blood. For more detail concerning the lesions of the organs see chapters on spleen, lymph-nodes, bones, etc.

CHLOROMA.

Under this name, which means merely "a green tumor," are grouped a number of forms of a disease which shows many points of resemblance to both malignant tumors and the leukæmias. It is now generally considered to belong to the group of primary diseases of the hæmatogenous system, its closest relationships being with the leukæmias. The important lesions are the presence of new growths of a greenish color in the osseous system, accompanied in many cases by alterations in the circulating blood. The tumors are frequently observed in the bones of the skull, but may involve any of the organs of the body. Nothing is known as to the chemical relationships of the coloring matter.

Two chief types of tumors can be distinguished histologically, the lymphoid and the myeloid. In the lymphoid form the tumor and its metastases are composed of cells resembling lymphocytes, generally of the large variety. Diffuse infiltration of the other organs may also occur, resembling that seen in the leukæmias. In the myeloid type

the tumor is characterized by the presence of large cells resembling the myelocytes or myeloblasts of the bone marrow. In this form widespread involvement of the bone marrow and spleen is apt to occur, and extension to other organs generally takes place in the form of small nodules of myeloid tissue.

The blood pictures may be conveniently divided into four types: One with small lymphocytes; one with large lymphocytes, which is the most frequent type; one with atypical large mononuclear cells resembling myeloblasts; and one in which the myelocytes are the cells most abundantly present. The red corpuscles also show the changes due to an anæmia.

Unless definite superficial tumors are present it is often impossible to differentiate the blood picture from that of a leukæmia, and many of the cases have been diagnosed only after death by the finding of greenish tumors scattered throughout the organs.¹

PSEUDO-LEUKÆMIA. ("Hodgkin's Disease," "Adenic.")

For a consideration of pseudo-leukæmia and Hodgkin's disease see page 489.

ANÆMIA INFANTUM PSEUDO-LEUKÆMICA. (Von Jaksch.)

This is a somewhat peculiar form of anæmia occurring in children, and characterized by progressive anæmia, by a considerable increase of leucocytes, by enlargement of the spleen and liver, and often by hyperplasia of the lymph-nodes. A large number of nucleated red cells are present in well-marked cases. Myelocytes are found, but rarely form more than 10 per cent. of the white cells.

By some authorities it is regarded as an early stage of leukæmia or as a type of leukanæmia, by others as a form of secondary anæmia following rachitis, tuberculosis, or syphilis.

The histological changes in the blood-forming organs are, so far as is known, very similar to, but less pronounced than, those of leukæmia.²

SPLENIC ANÆMIA.

A very chronic form of anæmia with enlargement of the spleen was first described by Banti.³ The course of the disease may be divided into three stages; one in which there is marked anæmia with increase in the size of the spleen and irregular attacks of fever, the white cells remaining normal in number and proportion. This period is usually from three to five years, but may be much longer. Then follows an interval of a few months in which there are jaundice and gastro-intestinal disturbances, passing into the final stage with fever, jaundice, ascites, diminished leucocytes, extreme anæmia, and often severe hæmorrhages from the gastro-intestinal tract. The chief lesions are a very much

¹ *Dock*, Amer. Jour. Med. Sci., 1893, cvi., 152; *Dock and Warthin*, Med. News, 1904, lxxxv., 971; *Lehndorff* (Ergeb. d. inn. Med., 1910, vi., 221) gives a very complete discussion of all the published cases, now amounting to about ninety, and a copious bibliography.

² Consult *Monti and Berggrun*, "Die chronische Anaemie d. Kindesalters," Leipsic, 1892.

³ *Banti*, *Ziegler's Beitr.*, 1898, xxiv., 21; *Lossen*, Mitt. a.d. Grenzgeb., 1904, xiii., 753. For a very careful study of the remarkable improvement in the blood following splenectomy see *Bierring and Egdahl*, Jour. Am. Med. Assn., 1906, xlvii., 1149 (bibliography).

enlarged spleen with induration of the splenic pulp, atrophy of the Malpighian bodies, and frequently, though not always, an extreme sclerosis of the portal and splenic vessels. The sinuses are often dilated and may contain large cells filled with phagocytosed red corpuscles. A moderate interlobular cirrhosis of the liver is usually present, but is not of a high grade. In the earlier stages no cirrhosis can be made out. Changes have not been observed in either the lymph-nodes or the bone marrow.

Originally the condition was considered merely an abnormal cirrhosis of the liver with enlargement of the spleen, but study of many cases in recent years, together with the striking improvement noticed after splenectomy, has forced the conclusion that the splenic lesion is the most important and that the cirrhosis is largely a secondary phenomenon.

Umber¹ has described an extremely interesting case in which there was apparently an extensive toxic destruction of the proteid material in the body. After excision of the spleen this destruction was checked and the proteid balance became positive.

In the type of splenomegaly described by Gaucher, there is often extreme anæmia. The blood may contain very large numbers of nucleated red cells, with a high leucocytosis and a small percentage of myelocytes. This is not constant, however, and is apparently due to the presence of metastases in the bone marrow from the splenic tumor. (For a description of the lesions of the spleen, see page 499.)

Splenomegaly accompanied by anæmia is occasionally seen in adults, and in some of the cases there seems to be an actual limitation of the disease to this organ, but there is no reason to consider the condition as worthy of a separate classification. Many of the cases ultimately prove to be obscure forms of lymphatic leukæmia in which the characteristic blood pictures appear only a few days or weeks before death. Other forms are due to a splenic tuberculosis or syphilis. In children, rickets, syphilis, and chronic gastro-intestinal lesions are the chief causes of splenic enlargement with anæmia.

A separate class of splenic anæmias heretofore included in this group has been shown to be due to a parasite of the genus *Leishmania*. This type of splenic anæmia in adults is seen chiefly in India and the Soudan. Minute organisms, the *Leishmania donovani*, are found in the splenic pulp, chiefly inclosed in the mononuclear cells. The disease is also known as kala-azar. The organisms can be grown on artificial culture media and develop into a flagellate form resembling trypanosomes.

The splenic anæmia frequently occurring in children in Southern Italy and Northern Africa has been shown by Nicolle to be due to a similar parasite, the *Leishmania infantum*.

A marked relative lymphocytosis characterizes the blood of both of these conditions. The parasites can be found in the blood in about a half of the adult cases, but in children they are very scanty. In blood obtained by splenic puncture the parasites can, however, be easily found in both forms.

¹ Umber, *Ztschr. f. klin. Med.*, 1904, lv., 289.

CHAPTER II.

THE LYMPH-NODES.

General Characteristics of the Lymph-Nodes.

It is well, in studying the lesions of the lymph-nodes, to remember that they are structures so placed in the course of the lymph-vessels that the lymph, in flowing toward the larger central trunks, passes through them, undergoing a sort of filtration as it percolates through the trabeculæ of the lymph sinuses. If this fact be borne in mind the lesions of the lymph-nodes, which are in the majority of cases secondary, are much more readily understood. Particles of pigment, cells from malignant tumors, fragments of dead or disintegrating cells either free or within phagocytes, red blood cells, bacteria, etc., which in any way get into the lymph-vessels, are carried along until a lymph-node is reached, and here they are, in part at least, deposited among the trabeculæ of the sinuses, or are taken up by phagocytic cells, while the lymph passes on and out of the efferent vessels. Soluble toxic substances also are carried into the lymph-nodes, often inciting marked and significant alterations.¹

The lymph-nodes as blood-forming organs stand in close relationship to many abnormal processes in the body.

What is called *lymphatic tissue* embraces not only the so-called lymph-glands and the less complex but still well-defined structures found in the stomach, intestines, tonsils, and elsewhere, and called lymph follicles, but also the less well-defined, irregular masses of tissue resembling that of lymph follicles, which, as Arnold has shown (Virchow's Archiv, Bd. lxxx., p. 315; Bd. lxxxii., p. 394; Bd. lxxxiii., p. 289; Bd. lxxxvii., p. 114), are widely disseminated in variable amounts in different parts of the body; in the lungs, beneath the pleura, in the interlobular septa, and elsewhere; in the liver, kidneys, etc. Although the exact nature of these more diffuse masses of lymphatic tissue is too little understood, as indeed is that of the lymph follicles and glands themselves, there is reason to believe that they are analogous structures and prone to be affected by similar deleterious agencies. It seems better, in view of the fact that the so-called lymph-glands are not glands at all, in the ordinary sense of the word, to call them *lymph-nodes*, and the smaller masses of lymphatic tissue scattered through various parts of the body *lymph-nodules* instead of "lymph-follicles."²

There is considerable variation in the situation, number, and size of lymph-nodes in special regions of the body, and they vary in size with age. It may be said that the lymph-nodes are most fully developed in the adult, and undergo fatty degeneration and involution in old age.³

Finally the lymph-nodes are built up of cells many of which have not achieved a high degree of differentiation and thus are prone to undergo mitosis and rapid proliferation, when, from infective or destructive processes in regions to which they minister, deleterious agents gather in their recesses.

ATROPHY.

Atrophy is a very regular occurrence in old age. In this condition the nodes are small, hard, and, unless pigmented, light in color. Microscopical examination shows a marked diminution in the number of par-

¹ For a study of bacteria in normal lymph-nodes see Küble, Münch. med. Wochenschr., 1899, p. 622.

² For a study of the structure of lymph-nodes see Weidenreich, Arch. f. mik. Anat., Bd., lxxv., p. 1, 1905.

³ For a study of regeneration of lymph-nodes and vessels see Meyer, Johns Hopkins Hosp. Bull., vol. xvii., p. 185, 1906, bibl.

enchyma cells, while the reticulum and the capsule and trabeculæ may be thickened. There may be an accumulation of fat around the node in senile atrophy.

ŒDEMA.

Œdema of the lymph-nodes may be associated with a blocking of the associated lymph-vessels. Under these conditions the lymph sinuses may be widely distended (Fig. 283).

DEGENERATION.

Amyloid Degeneration of the blood-vessels and reticulum of the lymph-nodes occurs under the conditions which favor this change in general. It may occur in connection with amyloid degeneration of other parts of the body, or by itself. It may occur in nodes otherwise normal.

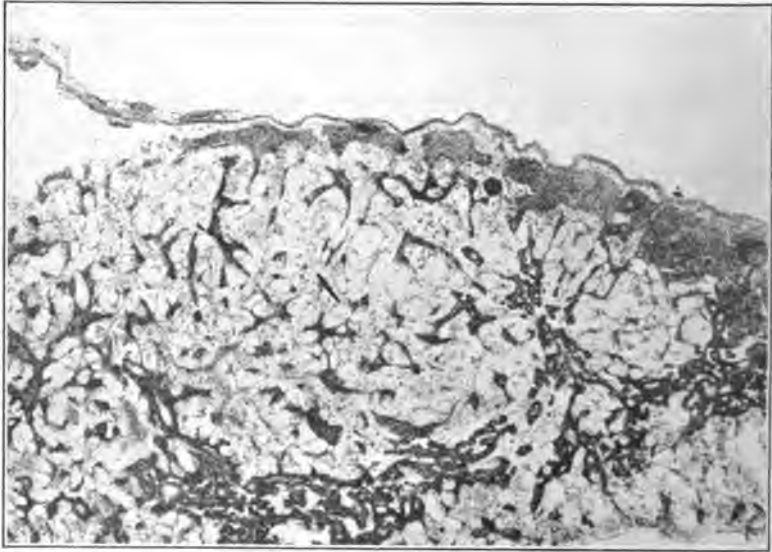

FIG. 283.—ŒDEMA OF A LYMPH-NODE—TYPHOID FEVER.

The perifollicular lymph sinuses are widely distended with clear fluid. The lymph follicles and lymph cords are flattened from pressure of the fluid.

or in those which are the seat of other lesions—thus in simple chronic or tuberculous inflammation. It is frequently found in the mesenteric lymph-nodes, in connection with waxy degeneration of the intestinal mucous membrane.

Hyaline degeneration of the external layers of the smaller arteries and the capillaries and reticulum of the lymph-nodes occurs occasionally in old age or in connection with wasting diseases.

PIGMENTATION.

The pigment which is very frequently found in lymph-nodes may be derived from the hæmoglobin of the blood, either in the nodes themselves or in remote parts, or it may be formed of various materials introduced into the body from without, such as the pigments used in tattooing, respired dust particles of various kinds—coal, stone, iron, etc. (Fig. 284). The pigment particles, which usually lodge first in the lymph sinuses, may collect here in large quantities, either in the reticulum or the cells lying in its meshes; they may penetrate the follicles and cords and find permanent lodgment there. They usually induce a greater or less degree of chronic inflammation, so that in extreme cases, such as are frequently seen in the bronchial lymph-nodes, nothing is finally left of the node, but a more or less deeply pigmented mass of dense connective tissue. The

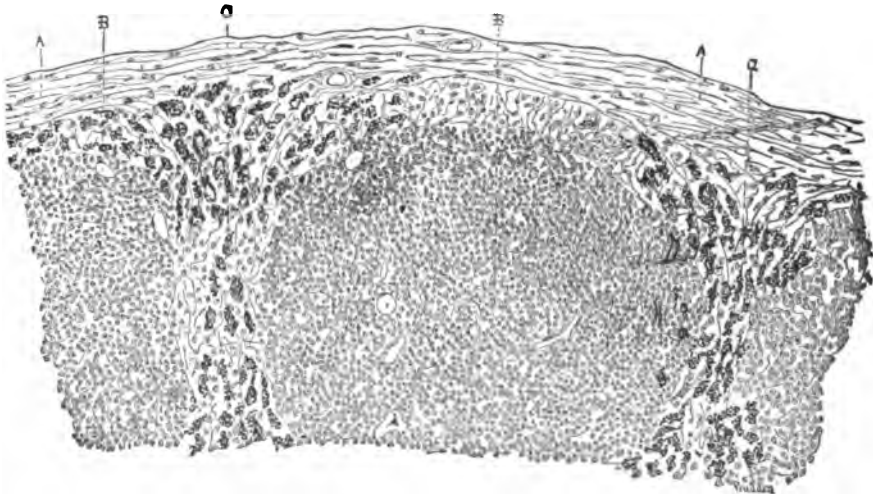


FIG. 284.—PIGMENTATION OF BRONCHIAL LYMPH-NODE.

The pigment is largely in the lymph sinuses and enclosed in cells. A, Capsule of node; B, lymph follicles—nodule; C, perifollicular lymph sinuses.

function of the node may be, of course, in this way partially or entirely destroyed. The pigment in these cases appears to reach the node, in part by being carried along free in the lymph current, in part through transportation by leucocytes in which the particles have become enclosed. Pigmentation of the nodes is most marked in those about the root of the lungs, which are frequently of a mottled gray or a black color, but it may occur in the mesenteric and other nodes. Under similar conditions the diffuse lymphatic structure in the lungs and liver may be pigmented.

INFLAMMATION.

Acute inflammation of the lymph-nodes is commonly due to the presence of pathogenic micro-organisms or of toxic substances, usually bacterial in origin, which may be formed in the node or brought to it in the lymph current from the tributary region of the body. Under these

conditions the nodes are usually swollen, reddened, and softer than normal, and are often the seat of small hæmorrhages. One or all of the nodes of a cluster may be affected.

Two forms of the acute inflammatory process may conveniently be recognized, a **HYPERPLASTIC** and an **EXUDATIVE**.

In the **HYPERPLASTIC** form a microscopical examination shows the lesion to be largely due, in addition to the hyperæmia and hæmorrhage, to a proliferation of the cells of the node, the spheroidal mononuclear cells of the nodules ("follicles") and cords, and especially the endothelial cells of the lymph-spaces (Fig. 285), which may increase in number and exfoliate to such an extent as to fill and largely distend the lymph

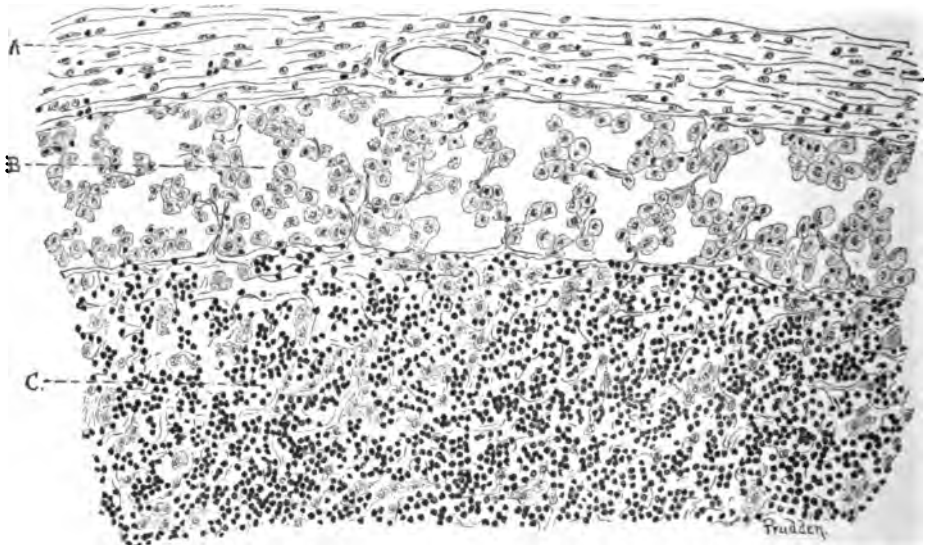


FIG. 285.—ACUTE HYPERPLASTIC INFLAMMATION OF LYMPH-NODE IN TYPHOID FEVER.

Showing a portion of one of the mesenteric nodes. *A*, Capsule; *B*, perfollicular space or lymph sinus, containing in its meshes many large cells; *C*, portion of one of the follicles, with large and small cells in the meshes of its reticulum.

sinuses. These endothelial cells often contain red blood cells, leucocytes, and fragments of other cells (Fig. 286). In diphtheria, scarlatina, and typhoid fever, as well as in many other infectious diseases, necrosis of the hyperplastic tissue is common. The necrosis is usually in circumscribed areas—focal necrosis—and often involves especially the germinal centres of the nodules.

After simple hyperplasia of the lymph-nodes, resolution readily occurs. But if necrosis have taken place, such areas may be replaced by fibrous tissue.

This form of lesion of the lymph-nodes is common. It may occur in the cervical nodes with many forms of angina; in the inguinal nodes in connection with acute infectious processes in the external genital organs; in the axilla with infectious processes in the hand, arm, or breast; in

the mesenteric nodes with infection or intoxication of intestinal or other origin. Similar lesions occur in the solitary lymph-nodules and Peyer's patches of the intestine (Fig. 287).

In **EXUDATIVE** or *suppurative* forms of inflammation of the lymph-nodes, in addition to the simple hyperplastic changes just described, there are emigration and collection of leucocytes, with the formation of more or less fibrin in the lymph sinuses as well as in the interstices of the nodules. The capsule of the nodes may be infiltrated with exudate. With these changes there may be necrosis and softening of the tissue of the nodes and the development of abscesses. Small abscesses may coalesce, and thus a considerable part of the node is converted into a suppurating necrotic mass—*bubo*. Such a

bubo may open externally or into the surrounding tissue and heal by granulation tissue and cicatricial tissue; its contents may be absorbed or become dry and dense and calcified, and surrounded by fibrous tissue. Suppurative inflammation of the lymph-nodes often occurs in connection with suppurative processes elsewhere, in pyæmia, venereal infection, etc.

The lymph-nodes of children are, as a rule, more readily involved in infectious processes of other parts than are those of adults.

Chronic Inflammation.—This is characterized by the increase of the connective-tissue elements of the node, with a gradual and commensurate disappearance of the lymphoid cells. The reticulum of the follicles and sinuses becomes thickened and fibrous, and in the trabeculæ

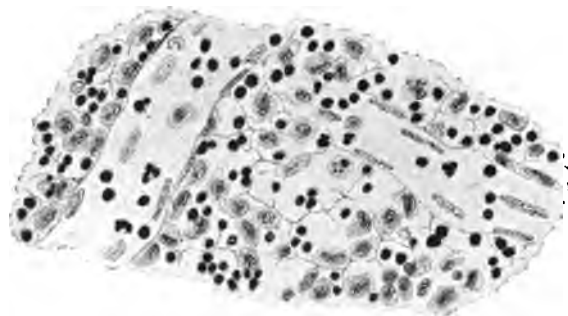

FIG. 287.—HYPERPLASIA OF PEYER'S PATCH IN TYPHOID FEVER.

Showing new-formed endothelial cells in the meshes of the reticular tissue between the blood-vessels.

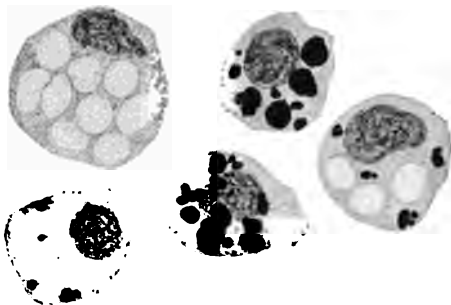


FIG. 286.—ENDOTHELIAL CELLS IN HYPERPLASIA OF THE LYMPH-NODES.

The exfoliated cells contain red blood cells, fat droplets, and masses of blood pigment.

and capsule new connective tissue is formed, until, in advanced cases, the entire node may be more or less extensively converted into a mass of fibrous tissue. This condition is very frequently seen in the lower tracheal and in the bronchial nodes, apparently as a result of the lodgment in them of respired pigment particles; but it may occur in any nodes, either as a result of repeated moderate degrees of inflammation or from causes

which we do not know. In some cases the nodes are greatly enlarged and the new tissue contains many large cells, while in other cases the connective tissue is dense and contains but few cells (Fig. 288).¹

Tuberculous inflammation may be local, confined to the nodes, or it may occur in connection with general acute miliary tuberculosis, or with tuberculous inflammation of single organs. It may occur in single nodes, or in several nodes of the same group, or in groups situated in different parts of the body. In its simple and acute form there may be no evident change to the naked eye in the appearance of the nodes, or they may

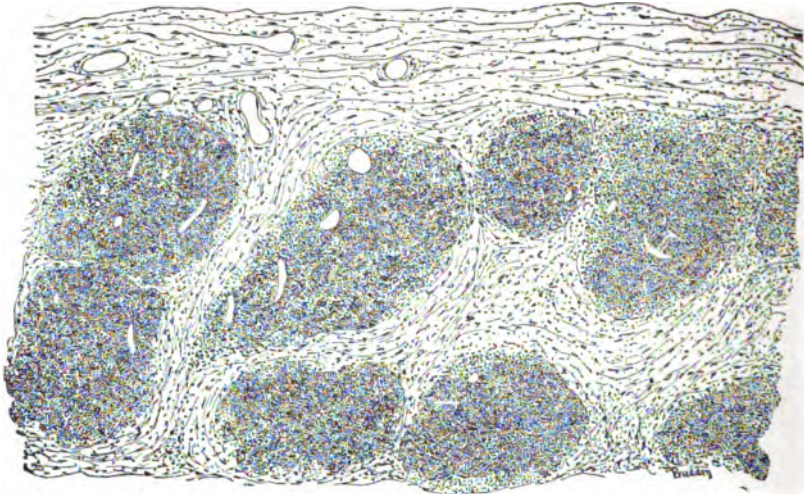


FIG. 288.—CHRONIC INFLAMMATION OF BRONCHIAL LYMPH-NODE.
Showing obliteration of the lymph sinuses and atrophy of the lymph-nodules by the new-formed connective tissue.

be besprinkled with small, grayish white, translucent spots. Under these conditions the nodes may be reddened and soft, or swollen and denser than normal. In more advanced forms of the lesion the tubercles coalesce and undergo a greater or less degree of cheesy degeneration. Under these conditions the cheesy areas are evident to the naked eye as more or less sharply circumscribed, opaque, whitish or yellowish areas, frequently surrounded by an irregular, more translucent, grayish zone of tubercle tissue which merges insensibly into the adjacent tissue. The entire node may become involved, and more or less completely converted into a cheesy mass, in the periphery of which a zone of tubercle tissue may or may not be evident.

Microscopically the small nodules or miliary tubercles are seen to consist of more or less circumscribed collections of small spheroidal, or more frequently larger polyhedral cells, with or without well-defined giant cells. They usually commence to form in the follicles and lymph cords of the nodes, and from these may spread and involve the entire

¹ Consult *Ribbert*, "Ueber Regeneration und Entzündung der Lymphdrüsen," *Ziegler's Beiträge zur path. Anat.*, Bd. vi., p. 187, 1889.

surrounding tissue. The cheesy degeneration, which here as elsewhere is apt first to involve the central portions of the tubercles, presents the usual appearances. Tubercle bacilli may be found in the edges of the cheesy areas or in the tubercle tissue about them.

Simple inflammatory changes regularly occur in the periphery of the tubercles. There is an increase of cells in the lymph sinuses and follicles, and a more or less marked swelling, and apparently a proliferation of the cells of the reticular tissue of the node. In cases in which the process is chronic there is often marked increase of the connective tissue of the nodes, the reticular tissue becomes dense and fibrous, and the trabeculae and capsule are thickened. The tubercles themselves, instead of undergoing cheesy degeneration, may become fibrous or be converted into a hyaline material.

The cheesy material may dry and shrink, and become enclosed by a capsule of dense connective tissue and become calcified; or it may soften, and thus cavities be formed in the nodes, filled with grumous material; or inflammatory changes may be induced in the vicinity of the nodes, leading to abscesses. On the other hand, hyperplastic inflammation in the periphery of the affected nodes may result in their becoming bound together into a dense nodular mass.

The formation of bone in lymph-nodes has been described in connection with tuberculous inflammation, carcinoma, and other lesions.¹

SCROFULA.—Tuberculous inflammation of the lymph-nodes, especially in those of the cervical,² bronchial (Plates III. and IX.), and mesenteric groups, often occurs in children, particularly in those who are ill-nourished. Northrup and Bovaird found in an analysis of 200 cases of tuberculosis in children that the lungs and bronchial lymph-nodes were involved in 148.³ Such persons, in addition to the lesion of the lymph-nodes, are very liable to suffer from chronic tuberculous and other inflammations of the mucous membranes, skin, periosteum, joints, and the subcutaneous and other connective tissues. This general condition is known as *scrofula*, and the lesion of the nodes is sometimes called *scrofulous inflammation*.

While in many cases the portal of entry of the tubercle bacilli is not evident, and the lesions often present the appearance of hyperplasia of the lymphoid tissue with cheesy degeneration and the formation of more or less dense fibrous tissue rather than the typical characters of tuberculous tissue, nevertheless, miliary and other forms of tuberculous inflammation are often present in so-called scrofula, and tubercle bacilli, while sometimes absent, are often present and virulent.⁴

The necrotic portions of such cheesy lymph-nodes in scrofula may

¹ See *Merkel*, Munch. med. Woch., 1905, p. 1238.

² For bibliography of cervical tuberculous lymph-nodes see *Dowd*, *Annals of Surgery*, May, 1899.

³ For a study of tuberculous bronchial lymph-nodes in children consult *Northrup*, N. Y. Med. Jour., vol. liii., p. 203, 1891; also *Bovaird*, *ibid.*, vol. lxx., p. 1, 1899. See further, reference to *Marfan*, p. 543. For later study of tuberculosis of lymph-nodes, especially in childhood, see *Harbitz*, Jour. Inf. Dis., vol. ii., p. 143, 1905.

⁴ In the examination of lymph-nodes for tubercles and tubercle bacilli it should be remembered that not infrequently, though one fails to find either morphological tubercles or stained bacilli, the inoculation of portions of the fresh tissue into guinea-pigs will show that living and virulent bacilli were present.

soften and break down, and by the establishment of purulent and necrotic inflammation about them abscesses may form which may open externally. These abscesses may heal; but usually the healing is difficult and slow, and long-continued suppurations, frequently with the development of fistulæ, are very common. Instead of softening, the cheesy material in the nodes may become dry and hard and undergo calcification.

GENERALIZED TUBERCULOUS LYMPHADENITIS.—Several cases have been recorded of extensive tuberculous hyperplasia of the lymph-nodes in various parts of the body, the lesion resembling in its gross characters that of pseudo-leukæmia. While in some of these cases the morphology of the lesions is characteristic of tuberculosis, in others the new tissue is diffuse and consists largely of new-formed, small, spheroidal and polyhedral cells with large multinuclear cells, and of fibrous tissue. The new-formed cells may undergo necrosis. Thus the tuberculous nature of the lesion is not always plain, even on microscopic examination. Animal inoculations are often necessary for the establishment of the nature of such cases.¹

Syphilitic Inflammation.—The lesions of the lymph-nodes which occur in connection with syphilis vary greatly, depending upon the stage of the disease. In the primary stage the nodes in the region of the seat of infection are apt to present the lesions of an ordinary acute inflammation, frequently with suppuration.

In the secondary stage of the disease the nodes of other regions, neck, elbow, axilla, etc., are often swollen and hard. On microscopic examination, there may be an increase of connective tissue in the capsule and trabeculæ, but the chief change is in the accumulation in the follicles and lymph sinuses of larger and smaller spheroidal and polyhedral cells. The reticular tissue may be thickened and the walls of the blood-vessels infiltrated with cells. In this condition the nodes may remain for a long time, not tending to form abscess; or they may undergo resolution through degeneration and absorption of the cells.

In the tertiary stage of the disease the nodes may be the seat of chronic inflammation characterized by the formation of gummata. Under these conditions they may form large, firm nodular masses from the growing together by new connective tissue of several altered nodes. The gross and microscopical characters of gummata of the lymph-nodes are, in the main, similar to those in other parts of the body.

HYPERPLASIA OF THE LYMPH-NODES. (Lymphoma.)

In addition to the considerable enlargements of the lymph-nodes in inflammation which have been described above, they become enlarged under a variety of conditions which we do not understand. This lack of knowledge of the etiology, together with our ignorance of certain functions of the lymph-nodes, and the morphological similarity, or even identity, which these enlarged nodes present under various conditions,

¹ For a study of this form of tuberculosis consult *Crowder*, N. Y. Med. Jour., vol. lxxii., pp. 443 and 490, 1900, bibl.

render it very difficult to decide upon the exact nature of the change, and in many cases to distinguish one form of enlargement from another.

In the first place, there is a class of cases in which, sometimes slowly, sometimes with great rapidity, the lymph-nodes of certain regions, especially the abdominal, axillary, cervical, and inguinal, enlarge, not infrequently to an enormous extent. They may be either hard or soft, even almost fluctuating; the individual nodes may be distinct or merged into one another. Sometimes the nodes in nearly all parts of the body are affected. Microscopic examination shows, in the soft varieties, a large increase of small spheroidal and polyhedral cells and a growth of the reticular tissue. It is a new formation of lymphatic tissue, but the normal relations of follicles, cords, and lymph sinuses are not preserved. In the harder varieties there is a thickening of the reticular tissue in addition to an increase of cells. In rare cases portions of the nodes become necrotic. Sometimes larger and smaller hæmorrhages occur in the nodes, especially in the softer forms. In addition to these changes in the lymph-nodes there is, in a considerable proportion of cases, a new formation of lymphatic tissue in greater or less quantity, in other parts of the body, in the spleen, in the gastro-intestinal canal, in the marrow of bones, in the liver, kidneys, etc., and the number of lymphocytes in the blood and in other parts of the body is increased. This general condition is known as *leukæmia* and has been considered above, under "Diseases of the Blood and Blood-forming Organs." The enlarged lymph-nodes in this disease may be called, for convenience, *leukæmic lymphomata*.

There is occasionally a moderate enlargement of the lymph-nodes in the myeloid form of leukemia, though the increase in size is rarely so great as that seen in the lymphatic type. The nodes remain discrete, though the capsule is frequently infiltrated with cells resembling lymphocytes or myelocytes. Microscopically there is a growth of mononuclear cells of the granular types ordinarily found in the bone marrow. As these areas of myelocytes increase in size the lymph follicles gradually disappear and finally the whole lymphoid tissue of the node may be replaced by myeloid structures. Usually such nodes are soft and do not undergo fibrous changes. The blood changes of a myelogenous leukæmia also help to differentiate this type of lesion from the purely lymphatic enlargement.

PSEUDO-LEUKÆMIA.

There are two forms of disease resembling leukæmia in many respects, but usually accompanied with a less marked involvement of the spleen and no increase in the number of leucocytes in the blood. These may be called pseudo-leukæmia and Hodgkin's disease. While the gross appearances of the lymph-nodes in both of these diseases are quite similar, there are differences in the microscopical structure which warrant the separation of the two conditions. In the true pseudo-leukæmia there is a progressive hyperplastic growth of lymph-nodes, and often in addition a diffuse hyperplasia of the lymphoid tissue normally present in such

organs as the liver or kidney. It is not impossible that transitions between this disease and leukæmia may occur, or that many of the cases included under this head may have been forms of chronic lymphatic leukæmia without blood changes sufficiently marked to compel their consideration as true leukæmias.

The changes may involve individual nodes, or, what is more usual, the nodes of a definite region may enlarge simultaneously. When sec-

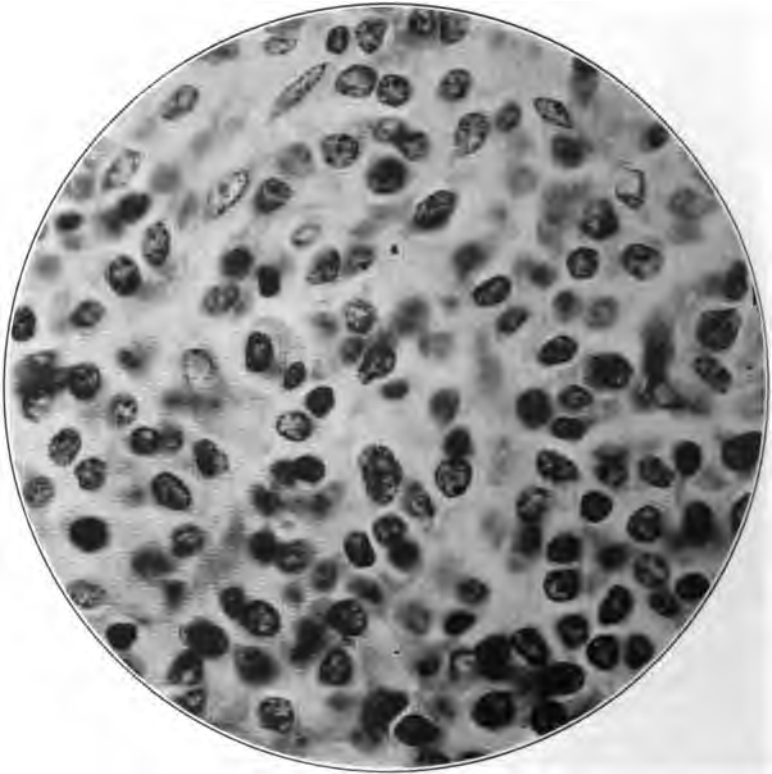


FIG. 289.—LYMPH-NODE FROM CASE OF CHRONIC LYMPHATIC LEUKÆMIA.
Compare with lymph-nodes in Hodgkin's disease.

tioned the tumors are soft and grayish red. They usually do not show necrotic areas.

Microscopically the nodes resemble those seen in lymphatic leukæmia, there being a loss of the typical structure and replacement by a diffuse growth of lymphocytes and fine reticular connective tissue (Fig. 289). Rarely large or even multinucleated cells may be found. The anæmia in these cases is no greater than that due to interference by similarly extensive malignant growths affecting any other tissue.

The second type, or Hodgkin's disease, shows microscopically changes in the lymph-nodes which are entirely different from those just

described. The nodular lesions in some cases which have until recently been classified as Hodgkin's disease resemble tubercle tissue, and the changes are unquestionably due to a diffuse tuberculosis of the lymphoid system,¹ though the bacilli can usually be demonstrated only by animal inoculations.

This group should be sharply differentiated from the other form, which has been designated by Pappenheim "granulomatous pseudo-leukæmia" and is the type to which Hodgkin's name is now generally

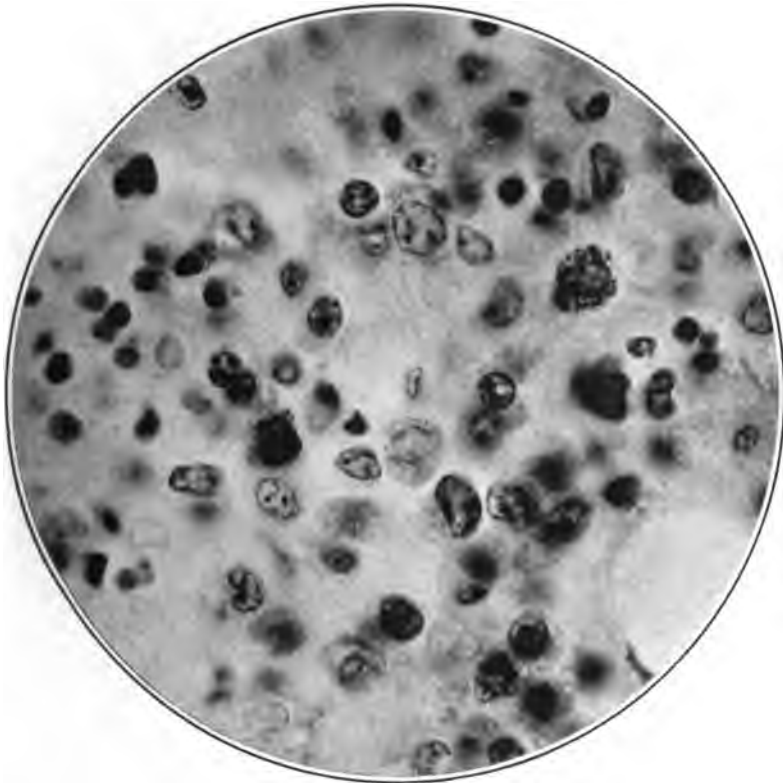


FIG. 290.—BONE MARROW IN HODGKIN'S DISEASE.
Showing eosinophile cells in great abundance.

attached. True tubercles are not present except as an accidental superimposed lesion, but the nodes undergo peculiar changes which are quite characteristic even in an early stage. The alterations characteristic of Hodgkin's disease may involve the superficial nodes of the neck, axilla, inguinal, or cubital regions, or the lesion may be confined entirely to the bronchial or retroperitoneal nodes. In some cases the spleen is very slightly affected; in others extensive necroses with fibrous-tissue replacement may occur. The bone marrow shows a moderate hyperplasia

¹ Sternberg (*Ztschr. f. Heilk.*, 1898, xix., 21) has made a careful study of cases of this type.

(Fig. 290). In advanced cases the liver may show a few of the characteristic nodules (Fig. 291). The gross appearance of the nodes is considerably altered from the normal. They may be lobulated, soft or hard, and white, gray, or red, and often show areas of necrosis. They are usually entirely discrete, and there is no infiltration of the capsule or perinodular fat with lymphocytes as is the case in the forms of enlargement due to leukæmia or lymphosarcoma. At first the only lesion,

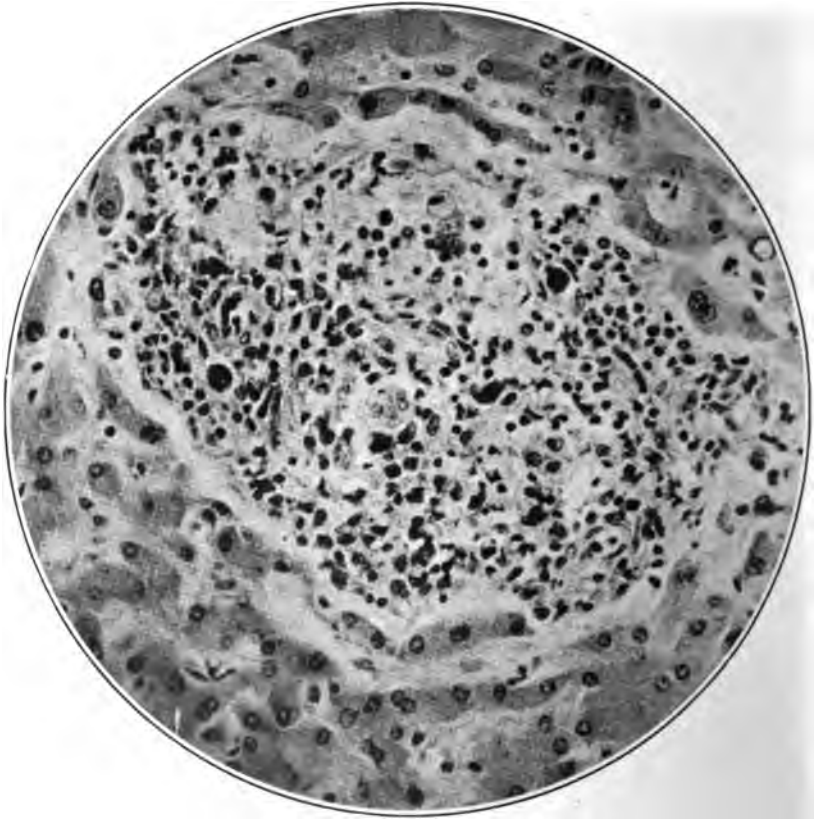


FIG. 291.—HODGKIN'S DISEASE. NODULE IN LIVER.

The abdominal and bronchial lymph nodes alone were involved in this case. The hyperplasia in the liver is of the same type as that in the nodes; with the formation of connective tissue and large irregular multinucleated cells.

besides a moderate hyperplasia, may be the development of areas containing a considerable number of large cells with a faintly staining cell body and a single large nuclei, sometimes showing mitosis (Figs. 292 and 293). In this early stage these cells correspond closely in morphology with the large cells of the germinal centres; they are not the same as the multinucleated cells of the later development of the disease. Not all the enlarged nodes show these changes equally well. Such alterations in the structure can scarcely be considered as specific, since they may be

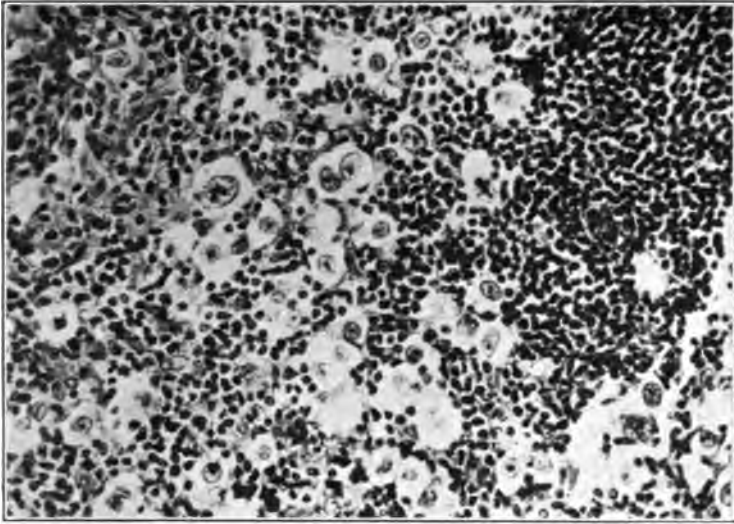


FIG. 292.—HODGKIN'S DISEASE. LYMPH-NODE WITH LYMPHOID TISSUE STILL PREPONDERATING BUT THE LARGE ENDOTHELIAL CELLS SHOW HYPERPLASIA. There is only a moderate connective tissue replacement.

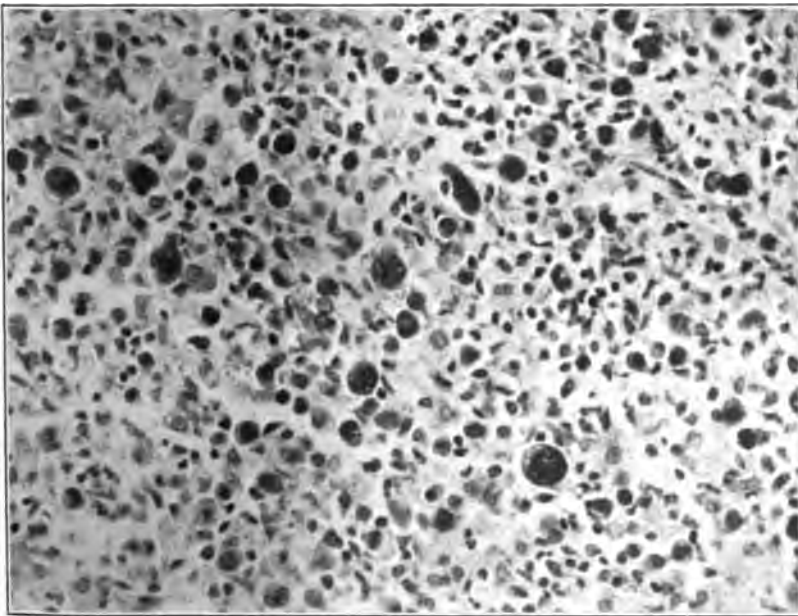


FIG. 293.—HODGKIN'S DISEASE. LYMPH-NODE SHOWING EXTENSIVE HYPERPLASIA OF LARGE CELLS.

found in nodes undergoing chronic hyperplasia in response to the irritation of a neighboring malignant epithelial growth.

In the second stage, however, the diagnosis is usually possible from an individual node, for there are present not only the large cells before mentioned, but necrotic areas surrounded by cells of the epithelioid (Fig. 294) type and more or less numerous large cells with polymorphic nuclei or with two or more small oval nuclei lying in the centre of the cell body. True giant cells of the Langhans' type (see Fig. 264, p. 413) with peripherally arranged nuclei are rare in comparison with the other

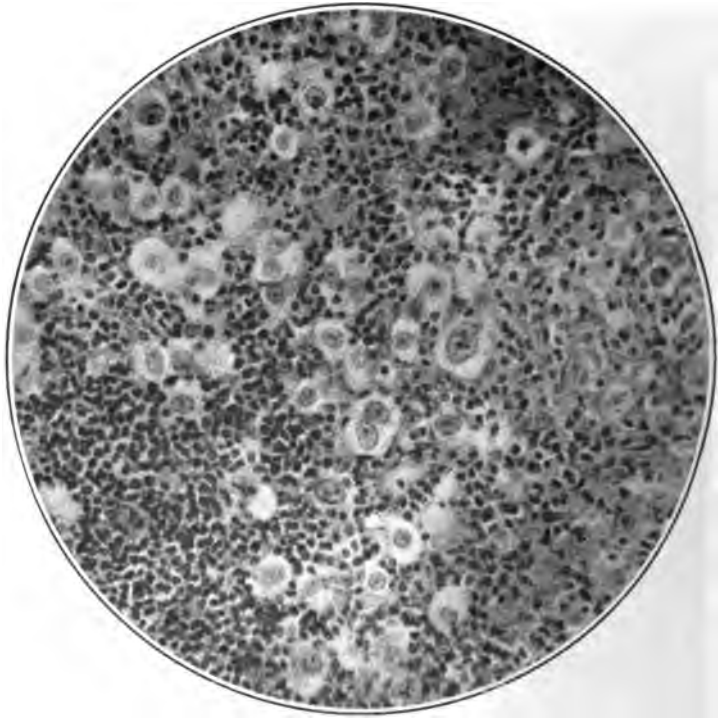


FIG. 294.—HODGKIN'S DISEASE. LYMPH-NODE IN WHICH THE LYMPHOID TISSUE STILL PREDOMINATES, BUT THE LARGE ENDOTHELIAL CELLS SHOW HYPERPLASIA. There is a beginning connective tissue replacement.

form (Fig. 295). This group of cells is probably produced by hyperplasia of the reticular endothelial cells. Necrosis in the nodes and spleen in these cases may be very extensive. There is usually a beginning replacement hyperplasia of the fibrous tissue of the reticulum.

In the third stage the nodes may be smaller than the previous types, and are composed very largely of dense anastomosing bands of fibrous tissue which occasionally undergo hyaline degeneration (Fig. 296). Thrombosis or extensive obliterative endarteritis of the vessels is not uncommon, and the lymphoid tissue may project under the epithelium so as nearly to close the lumen. The lymphoid tissue is occasionally

reduced to a few scattered areas surrounded by dense connective tissue (Fig. 297).

Eosinophile cells may be abundant in the nodular substance, and sometimes an increase in eosinophiles is seen in the circulating blood; but neither condition is constant. Plasma cells also may be found in the tissues in large or small numbers. Lymphoid infiltration in the organs, such as is seen in leukæmia, is not usually found. In fact, an important

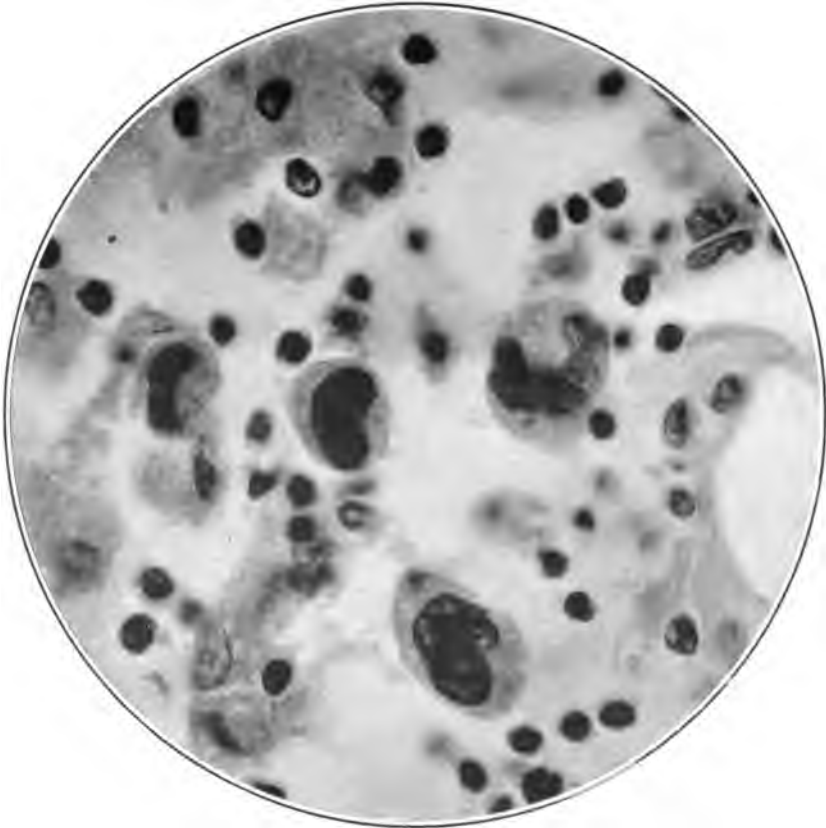


FIG. 295.—HODGKIN'S DISEASE. LYMPH-NODE SHOWING LARGE CELLS.

characteristic of Hodgkin's disease is that the lesions have a tendency to remain in nodular form and not to destroy the organ involved completely, if we except the lymph-nodes. There is always a severe progressive secondary anæmia with occasionally a high leucocyte count, though usually the alterations in number and proportions of the white cells from the normal are slight.¹

Le Count has recently described a benign tumor—lymphoma—in the

¹ Important papers on the histology of Hodgkin's disease, with bibliography, are those by Longcope, Bull. Ayer Clin. Laboratory, 1903, No. 1; Reed, Johns Hopkins Hosp. Rep., 1902, x., 133, and Simmons, Jour. Med. Res., 1903, ix., 378.

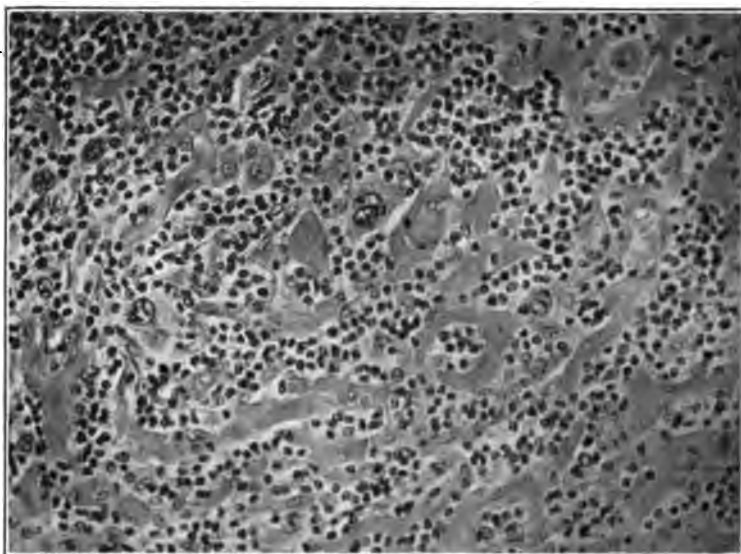


FIG. 296.—LYMPH-NODE IN HODGKIN'S DISEASE.

The trabeculae have undergone hyaline degeneration. A considerable number of lymphoid cells still remain lying between the connective tissue bands, together with some large cells.

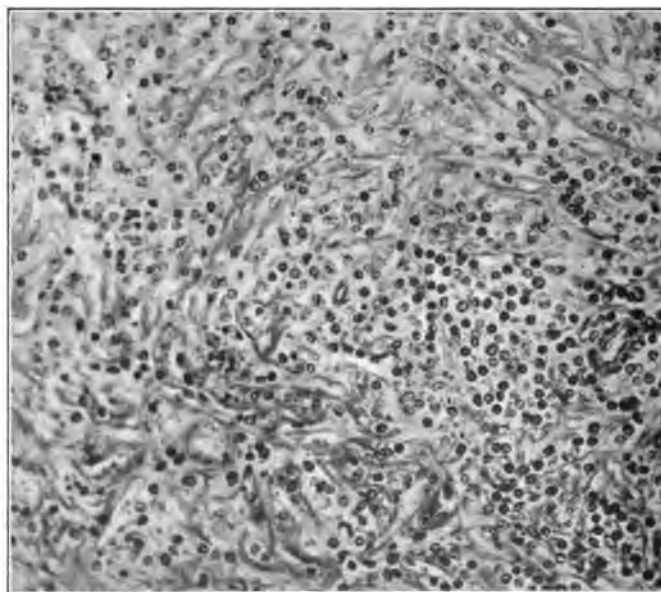


FIG. 297.—LYMPH-NODE IN HODGKIN'S DISEASE, DENSELY FIBROUS.

The lymphoid structures have been almost entirely replaced by connective tissue

groin having the structure of a lymph-node.¹ A form of generalized tuberculous lymphadenitis which may be mistaken for Hodgkin's disease is described above.

TUMORS.

Sarcoma occurs in the lymph-nodes as a primary and secondary tumor, and may be of various forms: spindle-celled, large and small round-celled, and angio-sarcoma. It is not easy in many cases to distinguish morphologically between the small round-celled sarcomata and the above-described lymphomata, but in general the leukæmic and pseudo-leukæmic lymphomata remain circumscribed, while the sarcomata tend to break through the node capsule and invade the surrounding tissues. **Fibroma**, **myxoma**, and **chondroma** occur in the lymph-nodes, but are rare. **Endotheliomata** are described, but are not common. **Secondary carcinomata** of metastatic origin are of frequent occurrence, the form of the cells and the nature of their growth depending upon the seat and character of the primary tumors.

When the cells of malignant tumors are detached in lymph channels and are carried away in the lymph currents, they are usually sooner or later caught in the meshes of the perifollicular lymph sinuses of the nodes. Here they may grow, encroaching upon the lymphoid tissue of the node, which they may finally largely or wholly replace. The node is then markedly enlarged and harder than normal. After a time the proliferating tumor cells may overcome the retarding action of the lymph-node filter, and pass beyond them into the veins, whence they may be widely distributed.

PARASITES.

Aside from the various forms of **bacteria** which are not infrequently found in the lymph-nodes in infectious diseases, among the animal parasites **filaria**, **trichina**, and **pentastomum** have been described.

HÆMOLYMPH-NODES.

Numerous observers have described the occurrence in man and certain of the lower animals, under normal as well as pathological conditions, of structures which resemble lymph-nodes, but are usually smaller and are red or mottled red and white. In man they are found especially in the prevertebral fat, in the deep cervical region, in the retroperitoneal region, near the renal vessels, and about the rim of the pelvis. They are normally present, but they may be more conspicuous under certain pathological conditions—pernicious anæmia, acute infections, intoxications, etc. Their color is due to the presence of blood in the sinuses of the nodes. There are numerous transitional forms between nodes containing lymph sinuses only and those which more nearly resemble the spleen in character. They become more prominent and are increased in number after splenectomy in animals.² These structures do not appear to be lymph-nodes in which blood has accumulated from hyperæmia or hæmorrhage,

¹ *Le Count*, Jour. Exp. Med., vol. iv., p. 559, 1899, bibliography of lymphoma.

² See *Warthin*, Jour. Med. Res., vi., 3, 1901, and "Vaughan Anniversary Contribution to Medical Research," 1903, p. 216.

and the sinuses containing blood may be injected from the blood-vessels. In the most typical forms of hæmolymph-nodes, the cortical and medullary portions are not well defined and the germinal areas in the lymphoid tissue are less marked than in lymph-nodes. Many large cells, probably proliferated endothelium, containing red blood cells and blood pigments, are usually present in the lymph sinuses. In addition to these, phagocytic cells, eosinophiles, and mast cells may be present.

In the opinion of Warthin,¹ who has made especially careful studies of these structures, and of others, they are inconstant or variable organs related to, but distinct from, lymph-nodes, and having special hæmolytic and possibly other functions. The studies of Dayton in general confirm the conclusions of Warthin.²

¹ For a full and excellent summary of this subject, with bibliography, consult *Warthin*, *Trans. Chicago Path. Soc.*, vol. v., p. 151, 1902. For a study of the development of hæmolymph-nodes in adipose tissue see *Proc. Path. Soc. of Phila.*, vol. vi., p. 229, 1903.

² *Dayton*, *Am. Jour. Med. Sci.*, vol. cxxvii., p. 448, 1904.

CHAPTER III.

THE SPLEEN AND THYMUS.

The Spleen.

General Characteristics of the Spleen.

IN studying the lesions of the spleen it is important to bear in mind the peculiar relations in which this organ stands to the blood-vessels and to the circulation. After passing through the various branches of the splenic artery and the limited systems of capillaries which are associated with it, the blood is not received at once into venous trunks, as in other parts of the body, but is poured directly into the pulp tissue. In this it circulates, under conditions which render it liable to stagnation and undue accumulation, before it is taken again into well-defined vessels through the open walls of the cavernous veins. Moreover, these conditions, naturally unfavorable to undisturbed and vigorous circulation, are reinforced by the association of the splenic with the sluggish and often interrupted portal circulation. Bearing these considerations in mind, it is in a measure plain why, as is in fact the case, the spleen should be more liable to alterations in size than any other organ in the body, and why, serving as it does as a sort of blood filter, it should be especially susceptible to the influence of deleterious materials of various kinds which in one way or another gain access to the blood. The relationship between the lymph-vessels and the spleen is also intimate. Finally, the spleen as a blood-cell forming and blood-cell destroying organ bears an important relationship to many abnormal conditions in the body.

Malformations and Displacements.

The spleen may be *absent* in acephalous monsters, and with defective development of other abdominal viscera. Absence of the spleen in otherwise normally developed individuals has been recorded. There may in this condition be a compensatory hyperplasia of the lymphatic tissues of the body.¹ Small *accessory spleens*, from the size of a hazelnut to that of a walnut, are not infrequent. They usually lie close to the spleen, but may be at a considerable distance from it; thus they have been found embedded in the head of the pancreas.² *Two spleens* of about equal size have been observed. The spleen may be made up of several distinct lobes. It may be *displaced* congenitally or as the result of disease. It may be on the right side in transposition of the viscera. As the result of congenital defects in the diaphragm the spleen may be found in the thorax; or in deficient closure of the abdominal wall it may, together with other abdominal viscera, be found outside of the body.

The spleen may be pressed downward by any increase in the contents of the thorax, It may be bound by adhesions to the concave surface of the diaphragm, so that its long axis is nearly horizontal instead of vertical. It may be displaced by changes in the contents of the abdominal cavity. If the organ be increased in size it frequently becomes tilted, so that its lower border reaches the right iliac region. If the ligaments be too long congenitally, or if they are lengthened by traction, and if the organ is at the same time increased in weight, it may become very movable. It may sink downward, with its hilus turned upward; or it may be rotated on its axis, and, owing to torsion of the vessels thus produced, the organ may atrophy; or the pressure of the ligaments and vessels across the duodenum may cause occlusion of the gut.

¹ See *Hodenpfl*, Med. Rec., vol. liv., p. 695, 1898, bibl. For a study of the effect of splenectomy in animals on the hemolymph-nodes see *Warthin*, "Vaughan Anniversary Contributions to Med. Research," 1903, p. 216.

² Hemolymph-nodes may be mistaken for accessory spleens.

WOUNDS, RUPTURE, AND HÆMORRHAGE.

Wounds of the spleen are usually accompanied by extensive hæmorrhage and are commonly fatal. Death usually occurs as the result of this hæmorrhage, but it may be due to secondary inflammatory changes. Healing and recovery may, however, occur.

Rupture of the spleen may be traumatic or spontaneous. In the former case it may be due to direct violence in the region of the organ or to injury to the thorax, falls, etc. In certain diseased conditions the spleen is more liable to rupture than when it is normal. The rupture usually involves not only the capsule, but a more or less considerable portion of the parenchyma, and of course leads to hæmorrhage. Spontaneous rupture is rare, but may occur in excessive enlargement of the organ, as in typhoid fever, malaria, etc.—see below—or as the result of abscess.

Hæmorrhage.—Aside from the extensive hæmorrhages from injury and rupture, the spleen may be the seat of small circumscribed hæmorrhages in various infectious diseases, although, owing to the peculiar distribution of the blood, it is often very difficult to distinguish between a moderate interstitial hæmorrhage and hyperæmia. Sacculated aneurism of the splenic artery has been reported.

ATROPHY.

Atrophy of the spleen may occur in old age; as a result of prolonged cachexiæ, and in connection with profound and persistent anæmia; or, more rarely, from unknown causes. The capsule may be wrinkled and thickened, the color pale, the trabeculæ prominent, the consistence increased. The change is largely in the pulp, whose parenchyma cells are decreased in number.

DEGENERATION.

Amyloid Degeneration.—This may affect the glomeruli or the pulp tissue, or both together. When confined to the glomeruli the spleen may or may not be enlarged, and the cut surface is more or less abundantly sprinkled with round or elongated, translucent bodies resembling considerably in general appearance the grains of boiled sago. These are the waxy glomeruli. Such a spleen is often called "sago spleen" (Fig. 298). Microscopical examination shows that the degeneration is confined to the walls of the arteries, capillaries, and reticulum of the glomeruli, with atrophy and often finally total disappearance of the lymphoid cells.

In other cases, either with or without involvement of the glomeruli, there is waxy degeneration of the blood-vessels and reticulum of the pulp, which may occur in patches or be general and more or less excessive. If the alteration is general and considerable, the spleen is enlarged, its edges are rounded, its consistence is increased. On section it appears translucent, and the distribution of the degenerated areas may be readily seen by holding a thin slice up to the light. The spleen alone may be affected, or there may be similar degenerations in other organs.

PIGMENTATION.

This may occur as the result of the decomposition of hæmoglobin in the organ or elsewhere, under a great variety of conditions: thus after hæmorrhagic infarctions, small multiple hæmorrhages, acute hyperplastic splenitis, and in hæmochromatosis, etc. Or the pigment may be anthracotic and be brought to the organs from the lungs or bronchial nodes; bile pigment may also be deposited in the spleen in jaundice. The pigment may lie in the walls of the smaller arteries, in the cells and reticulum of the pulp, or free in the latter tissue, or in the follicles. It is

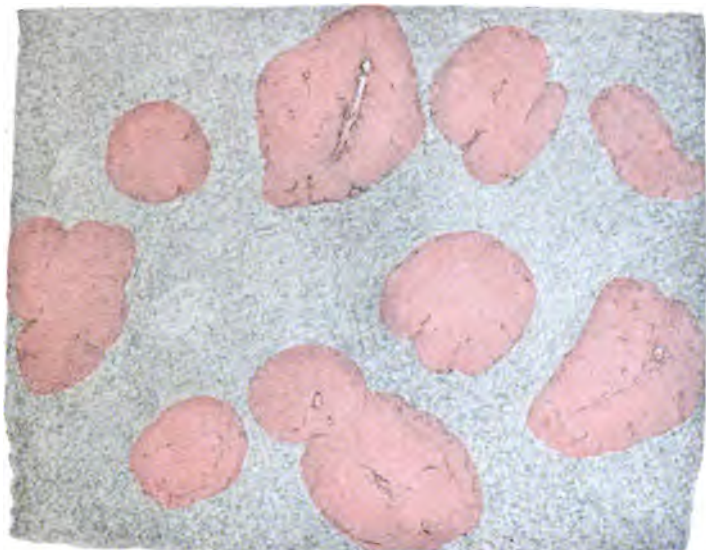

FIG. 298.—AMYLOID DEGENERATION OF THE GLOMERULI OF THE SPLEEN—"SAGO SPLEEN."
The waxy portions are stained.

usually quite unevenly distributed. The pigment may be red, brown, or black. Anthracotic pigment is deposited especially along the adventitial sheaths of the arteries. It may be sometimes seen with the naked eye in the periphery of the glomeruli as dark crescents. This pigment, derived from the lungs, has gained access to the blood-vessels, through which it is brought to the spleen.

DISTURBANCES OF THE CIRCULATION.

Anæmia.—This may be associated with general anæmia, but it is not always present in this condition. When marked and unassociated with other lesions the spleen is apt to be diminished in size, the capsule more or less wrinkled, the cut surface dry and lighter in color than normal, the trabeculæ unduly prominent.

In this, as in other alterations simply of the blood content of the spleen, neither the gross nor microscopical appearances are constant,

because of the redistribution of blood which is apt to occur in the viscera after death.

Hyperæmia.—**PASSIVE HYPERÆMIA** may occur in obstruction to the portal circulation, most frequently in cirrhosis of the liver, but also with certain valvular lesions of the heart, emphysema, etc. The spleen is enlarged, but usually only to a moderate degree. The capsule is apt to be tense, and on section the pulp is dark red and may be soft or firm. The cavernous veins are dilated (Fig. 299). Usually, when the lesion has existed for some time, there is a thickening of the trabeculæ and

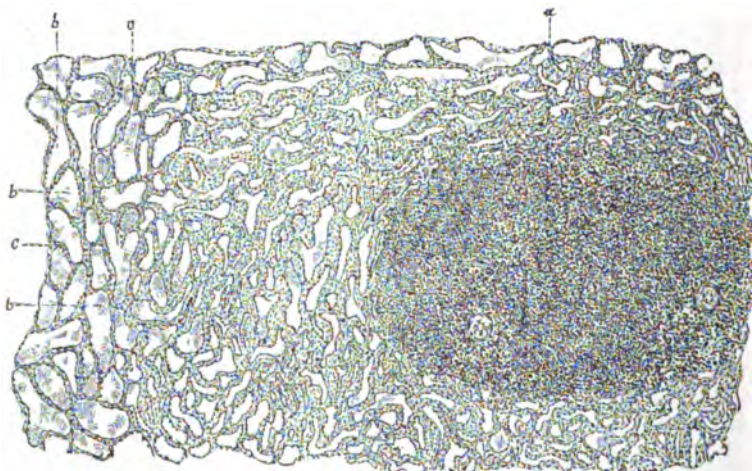


FIG. 299.—HYPERÆMIA—CONGESTION—OF THE SPLEEN.

b, Dilated cavernous veins; c, trabeculæ of pulp tissue compressed between dilated cavernous veins; d, glomerulus.

reticular framework of the spleen, so that these are prominent on section. In other words, there is a chronic interstitial splenitis following the chronic congestion.

ACTIVE HYPERÆMIA of the spleen, which in most cases is scarcely to be differentiated from some forms of acute inflammation, and probably in many cases is associated with it, very frequently occurs in a great variety of acute and infectious diseases, such as typhoid fever, pneumonia, diphtheria, pyæmia, the exanthemata, etc. The spleen is enlarged, the capsule tense; on section the pulp is soft, dark red in color, often swelling out from the cut surface and concealing the glomeruli and trabeculæ. Under these conditions the cavernous veins are distended with blood and the interstices of the pulp infiltrated with a variable, sometimes large quantity of red and white blood cells. Or, in addition to this, there may be hyperplasia (see below).

Embolism and Infarction of the Spleen.—*Embolic infarcts* of the spleen are of frequent occurrence. They may be single or multiple, small or very large, sometimes occupying half of the organ. They usually arise from the detachment of thrombi from the aorta or the heart valves.

They are in general approximately wedge-shaped, corresponding to the area of tissue supplied by the occluded artery (Fig. 10, p. 30). They may be hæmorrhagic, *i.e.*, red, or they may be white. Infarctions, originally red, may become white after a time from changes in the blood pigment (Fig. 300). They may usually be seen as dark red, reddish white, or white, hard, sometimes slightly projecting areas on the surface of the organ. Not infrequently the centre of the infarction is light in color, while the peripheral zone is dark red. A layer of fresh fibrin is sometimes seen over the surface of the infarction. The general as well as the microscopical appearances which they present depend largely upon the age of the infarctions. In the earlier stages the hæmorrhagic infarctions present little more under the microscope than a compact mass of red blood cells, among which may be seen the compressed parenchyma. The white infarction may show at first an outline of the splenic

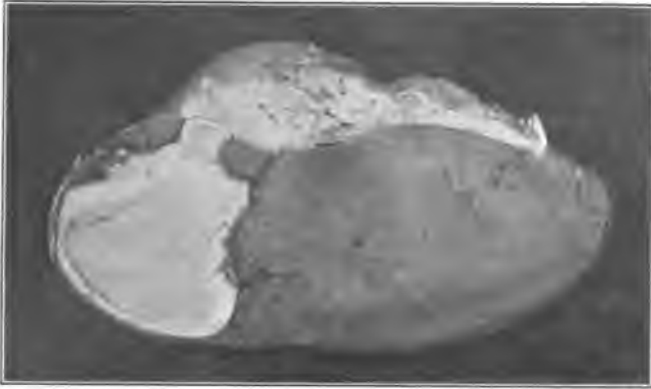

FIG. 300.—INFARCTION OF THE SPLEEN.
Embolus from heart valve in chronic endocarditis.

structure, but the entire tissue is in a condition of coagulation necrosis. The tissue may disintegrate and soften, and be more or less completely absorbed, with or without fatty degeneration. A zone of inflammatory tissue may appear around the infarction and upon the capsule, and this tissue, becoming denser, assume the characters of a cicatrix and contract around the unabsorbed remnant of the infarction, so that finally nothing may be left but a dense mass of fibrous tissue, which frequently draws in the surface, causing more or less distortion of the organ. This cicatrix may be pigmented or white.

If the embolus be infective, in addition to its mechanical effects there may be suppuration, gangrene, and the formation of abscess. There may be perforation of the capsule and fatal peritonitis. Infarctions of the spleen may follow *thrombosis* of the splenic vein.

Thrombosis of the splenic vein is rare as a primary lesion, but it may be of secondary occurrence in connection with portal or mesenteric thrombosis, with other lesions of the spleen, or with acute inflammation

of the pancreas. Thrombosis of the splenic vein has been reported following typhoid fever.

INFLAMMATION.

Inflammatory Hyperplasia (*Acute Hyperplastic Splenitis, Acute Splenic Tumor*).—The conditions under which hyperplasia and acute inflammation of the spleen occur have already been mentioned under "Active Hyperæmia," with which it is usually associated. It is a frequent though not a constant accompaniment of the acute infectious diseases. The spleen is enlarged, sometimes to two or three times its normal size. On section the pulp is soft, often almost diffluent, and projects upon the cut surface. The color is sometimes dark red, sometimes grayish red, or mottled red and gray. The trabeculæ and glomeruli are usually concealed by the swollen and softened pulp, but the glomeruli are sometimes unusually prominent.

Microscopical examination shows the marked increase in size to be due in part to the hyperæmia; in part to a swelling and increase in the number of cells, sometimes of the pulp, sometimes of the glomeruli, or of both. There are multinuclear cells; cells resembling the ovoid and polyhedral cells of the pulp, but larger and with evident division of the nuclei. Cells resembling leucocytes may be present in large numbers, and larger and smaller cells in a condition of fatty degeneration, or containing pigment, are often seen. The elongated cells lining the cavernous veins may be swollen or increased in number. Not infrequently the larger and smaller cells contain red blood cells or their fragments. In some cases, particularly in scarlatina, hyperplasia of the glomeruli is a prominent feature; in other cases, particularly in typhus and recurrent fevers, the cells of the glomeruli undergo marked degenerative changes, so that they may form small softened areas looking like little abscesses. Focal necroses and areas of small-celled accumulation or cell proliferation are common in typhoid fever and other infectious diseases (see p. 203). As the primary disease runs its course the swelling of the spleen subsides, the capsule appears wrinkled, the color becomes lighter, and sometimes the organ remains for a long time, or permanently, small and soft.

The lesions of the spleen are in many cases due to the presence of micro-organisms which are usually present in the spleen in septicæmia or they may be due to soluble toxic substances in the blood.¹

Suppurative Splenitis (*Splenic Abscess*).—Small abscesses may be found in the spleen as the result of minute infectious emboli, and these may coalesce to form larger abscesses. Sometimes the entire parenchyma is converted into a soft, necrotic, purulent mass surrounded by the capsule. It is rare for simple infarctions to result in abscess. Abscess of the spleen may occur from the propagation of a suppurative inflammation to the organ from adjacent parts; from perinephritic

¹ For a study of the rôle of the spleen in infections see *Courmont and Duffau, Arch. de méd. exp., t. x., p. 431, 1898, bibl.*

abscesses, ulcer and carcinoma of the stomach, etc. They may open into the peritoneal cavity, inducing fatal peritonitis, or, owing to an adhesive inflammation, the opening may occur into the post-peritoneal tissue, into the pleural cavity, lung, stomach, intestines, or they may open on the surface. On the other hand, the contents of the abscess may dry, shrink, and become encapsulated and calcified. Abscesses may occur in ulcerative endocarditis, pyæmia, typhoid fever, and, more rarely, in intermittent fever, and under a variety of other conditions.

Chronic Indurative Splenitis (*Chronic Splenic Tumor*).—There may be, as we have already seen, a new formation of connective tissue in the spleen as a result of chronic congestion or infarctions, or about abscesses. But there is a more diffuse formation of connective tissue, usually in the nature of a hyperplasia, which occurs under a variety of conditions, and is now marked and extensive, and again comparatively ill-defined. It is always associated with more or less extensive changes in the parenchyma. In its most marked form it is found in chronic malarial poisoning; and under these conditions it may be found not only in persons who have suffered from repeated attacks of intermittent fever, but also in those who have not thus suffered but have resided in malarial regions. The enlarged spleen is often called "ague cake." Similar conditions, though usually less marked, may occur in congenital and acquired syphilis, from prolonged typhoid fever, and as a result of acute hyperplastic splenitis from various causes, and also in leukæmia and pseudo-leukæmia.

The gross appearance of the spleen in chronic indurative splenitis varies greatly, both in the size of the organ and in the appearance of the section. The spleen may be enormously enlarged or it may be of about normal size. It is usually, however, enlarged. The capsule is commonly more or less thickened, frequently unevenly so. The consistence is as a rule considerably increased, but this is not always the case. The color and appearance of the cut surface present much variation. It may be nearly normal or it may be grayish, or dark brown, or nearly black. The color may be uniform or the surface may be mottled. The glomeruli may be scarcely visible or very prominent; the trabeculæ are in some cases nearly concealed by the pulp; in others they are large, prominent, and abundant, so that the surface is crossed in all directions by an interlacing network of broader and narrower irregular bands, between which the red or brown or blackish pulp lies.

Not less varied are the microscopical appearances of the spleen under these conditions. In one class of cases there is more or less uniform hyperplasia of both pulp and interstitial tissue. The parenchyma cells

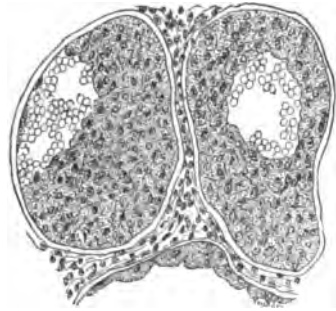


FIG. 301.—CHRONIC INDURATIVE SPLENITIS.

Showing swelling and proliferation of the lining cells of the cavernous veins.

are increased in size and number; there may be swelling and proliferation of the lining cells of the cavernous veins (see Fig. 301). The reticulum of the pulp, as well as that of the glomeruli, and also the trabeculæ, are thickened. In another class of cases the thickening of the reticular

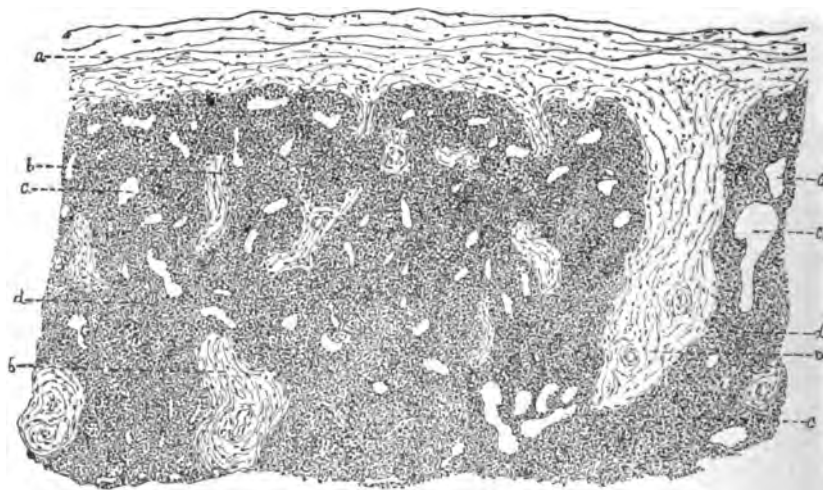


FIG. 302.—CHRONIC INTERSTITIAL SPLENITIS.

a, Thickened capsule; *b*, thickened trabeculae; *c*, dilated cavernous veins; *d*, dense pulp tissue with obliterated cavernous veins.

and trabecular tissue, either uniformly or in patches, is the prominent feature (Fig. 302), while the changes in the pulp are rather secondary and atrophic. In both forms irregular pigmentation is frequent, the pigment particles being deposited either in the cells of the pulp or glomeruli, or in the new-formed interstitial tissue (Fig. 303). Finally, there are all intermediate forms of induration between those described, and the changes are by no means uniform in the same organ. When these spleens are large they are liable to displacement.

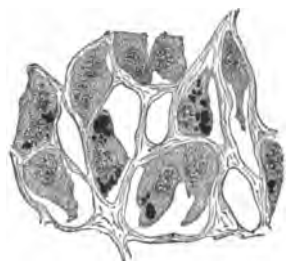


FIG. 303.—MALARIAL SPLEEN.

Showing thickening of the trabecular network of the pulp, with pigmentation of the pulp cells.

Syphilitic Splenitis.—This lesion may present itself as an indurative process due to the formation of new connective tissue, and present no distinct morphological characteristics. In rare cases, however, gummata may be present in connection with the new fibrous tissue; then the nature of the lesion is evident.

Tuberculous Splenitis.—This lesion is usually secondary to tuberculous inflammation in some other part of the body, or is the result of the general infection in acute general miliary tuberculosis. The tubercles may be very numerous and still invisible to the naked eye, or they may be

just visible, or as large as a pin's head, and very thickly strewn through the organ or sparsely scattered. In other cases the tubercles are larger, sometimes as large as a pea (Fig. 304), and they are then ordinarily not numerous. Microscopically they present the usual variety of structure, sometimes as simple tubercle granula, sometimes as conglomerate tubercles; they may consist simply of a collection of small spheroidal cells, or there may be larger polyhedral cells and giant cells with a well-defined reticulum. Cheesy degeneration occurs under the usual conditions. Tubercle bacilli are commonly present, particularly in the more acute forms, sometimes in small, sometimes in enormous numbers. They seem to be especially abundant in acute general miliary tuberculosis of chil-

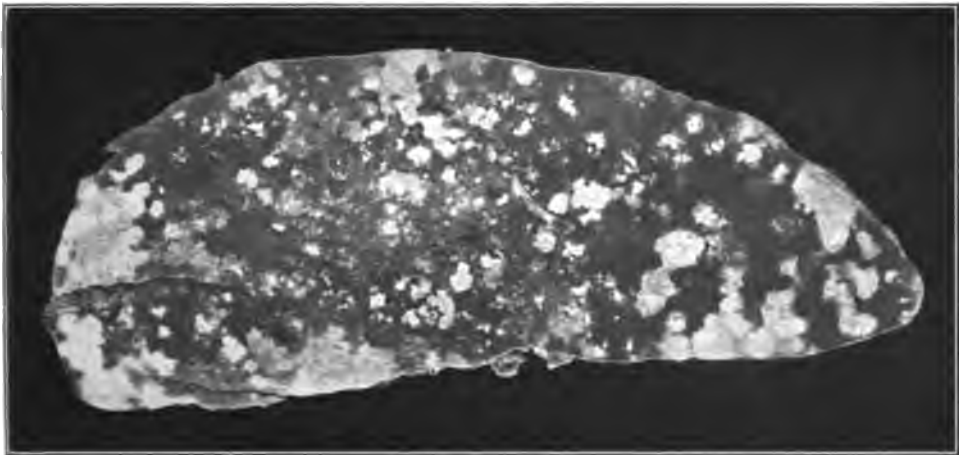


FIG. 304.—TUBERCULOSIS OF THE SPLEEN.

The tubercles are large and irregular in shape and distribution, and are in places confluent.

dren. These tubercles may be formed in the glomeruli, in the walls of the smaller arteries, in the pulp tissue, and in the trabeculæ and capsule. Owing to the peculiar character of the spleen tissue the earlier stages are not readily recognized, since simple collections of small spheroidal cells are not distinctly outlined against the normal tissue. There is frequently a moderate swelling of the spleen, owing to hyperæmia and hyperplasia of the parenchyma.

Perisplenitis.—ACUTE INFLAMMATION of the capsule of the spleen may occur as a part of a general or localized peritonitis, or as a result of lesions of the spleen itself, such as infarctions, abscesses, and acute hyperplastic inflammation. Under these conditions a fibrinous pellicle, with more or less pus, may be formed on the surface of the organ. CHRONIC INFLAMMATION, resulting in the production of new connective tissue, either in patches or as a more or less general thickening of the capsule, is of frequent occurrence. It may follow acute inflammation of the capsule, or be a part of general or localized chronic peritonitis. It

is common in connection with chronic indurative splenitis, and it may occur from unknown causes. Sometimes the capsule is three or four millimetres in thickness over a considerable area; sometimes very small nodular thickenings or papillary projections occur. As a result of this process, adhesions, sometimes very extensive, may form between the spleen and adjacent parts. The thickened capsule is sometimes more or less extensively calcified.

CHRONIC ENDOTHELIAL HYPERPLASIA OF THE SPLEEN. ("Primary Splenomegaly.")

Bovaird has recently described a slowly progressive lesion developing in early life in which the spleen was greatly enlarged and firm in texture, presenting on section numerous irregular white or yellowish areas, extending from the capsule into the substance of the organ. The splenic

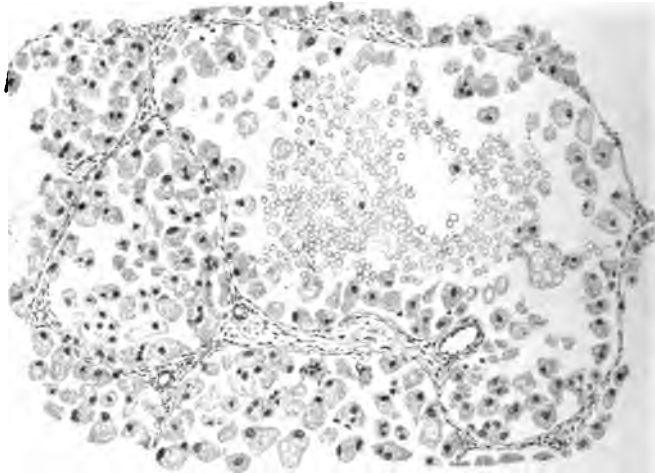


FIG. 305.—CHRONIC ENDOTHELIAL HYPERPLASIA OF THE SPLEEN.
Showing increase in number and exfoliation of the endothelium of the cavernous veins.

and mesenteric lymph-nodes and the liver were enlarged. On microscopic examination the spleen lesion was found to consist largely of an excessive proliferation of the endothelial cells of the pulp (Fig. 305), in part alone, in part associated with fibrous hyperplasia. Similar endothelial hyperplasia occurred in the splenic and mesenteric lymph-nodes and in the connective tissue of the liver. There was marked pigmentation of the involved lymph-nodes and in the liver lesion. This condition has apparently been several times described, but has been usually regarded as tumor rather than endothelial hyperplasia.¹

¹ For details of this lesion see *Bovaird*, *Am. Jour. Med. Sci.*, vol. cxx., p. 377, 1900; also *Brill Mandelbaum*, and *Libman*, *ibid.*, vol. cxxix., p. 491, 1905.

ALTERATIONS OF THE SPLEEN IN LEUKÆMIA AND PSEUDO-LEUKÆMIA.

The lesions of the spleen are essentially similar in both of these conditions. They consist, in general, of a hyperplasia, sometimes most marked in one, sometimes in another, of the structural elements of the organ, but they usually all participate in the alterations. The changes which occur in the earlier stages are but little known (Fig. 306). The gross appearances of the spleen vary. It is, as a rule, enlarged and sometimes is ten or fifteen times the normal size. It is commonly hard, but

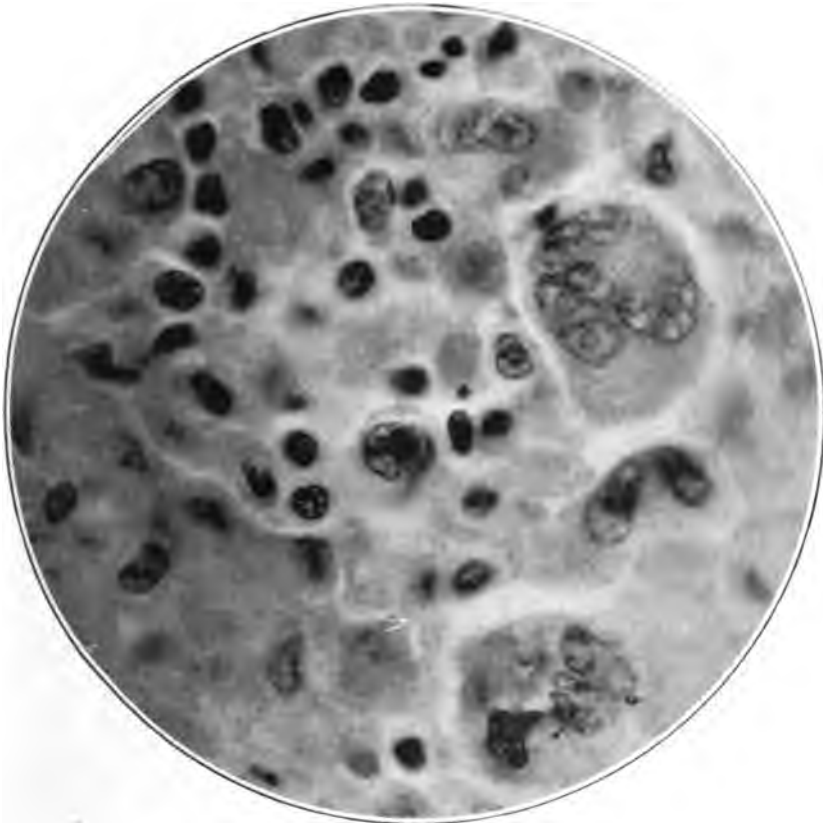

FIG. 306.—HODGKIN'S DISEASE. SHOWING LARGE CELL HYPERPLASIA IN SPLEEN.

is sometimes of the ordinary consistence, or softer, and the capsule is generally thickened and rough (Fig. 307). The section of the spleen may be of a uniform dark red color, but it is more frequently mottled red and gray. Sometimes the glomeruli are inconspicuous, but they are very often enlarged and prominent. They may be two to four millimetres in diameter, and, owing to an infiltration of the arterial sheaths with lymph cells, may appear to the naked eye as grayish, round or elongated bodies, arranged along branching, interrupted, grayish streaks. The trabeculæ

may be greatly thickened, as also the reticulum of the pulp, so as to be evident to the naked eye. Brown or black pigment may be collected around the glomeruli or in the pulp. Hæmorrhagic infarctions or circumscribed extravasations of blood may further complicate the picture.

Microscopically the appearances are essentially the same as those above described in acute hyperplasia and in chronic interstitial splenitis, depending upon the stage and variety of the disease. Owing to the great

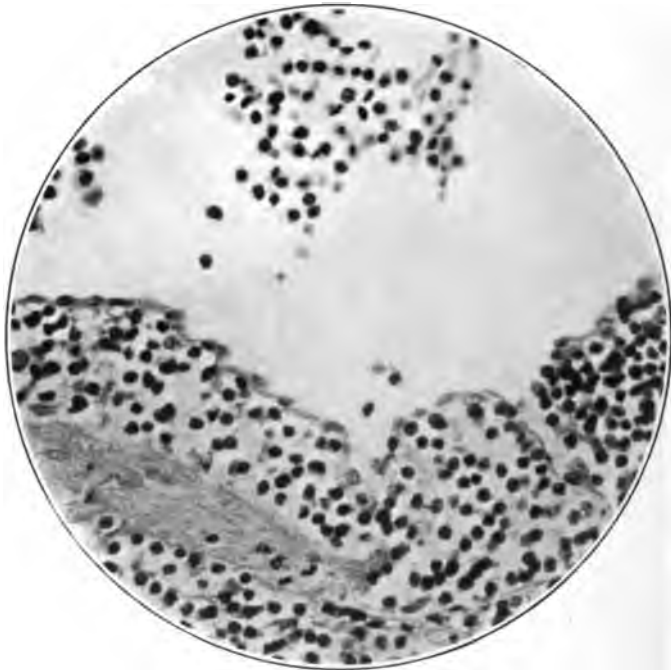


FIG. 307.—SUBENDOTHELIAL INFILTRATION OF SPLENIC SINUSES BY LYMPHOID CELLS IN A CASE OF LYMPHATIC LEUKÆMIA.
A similar lesion occurs in Hodgkin's disease.

size which some such spleens attain they are liable to displacement, and they may interfere by pressure with the functions of neighboring organs.

TUMORS.

Primary tumors of the spleen are rare. Small **fibromata**, **sarcomata**, and **cavernous angiomata** sometimes occur. **Sarcoma** and **carcinoma** may occur in the spleen secondarily either as metastatic tumors or by extension from some adjacent part, as the stomach. **Dermoid cysts** are described, but are rare. Other larger and smaller cysts, whose mode of origin is in most cases obscure, not infrequently occur; some of these may be **lymphangiomata**.¹

¹ For cysts of spleen see *Otto*, *Arbeiten path. anat. Inst. Tübingen*. Bd. v., p. 13, 1904.

PARASITES.

Pentastomum denticulatum is not infrequently found in the spleen, usually encapsulated and calcified. **Cysticercus** is rare. **Echinococcus** is occasionally found, and, if the cysts are large or numerous, may cause more or less extensive atrophy of the organ.

Various forms of bacteria have been found in the spleen. The **pyogenic cocci** have been found in pyæmia, small pox, ulcerative endocarditis, diphtheria, and under other conditions. The **Bacillus anthracis** occurs here in anthrax; the **Bacillus tuberculosis** in tuberculous inflammation; and **typhoid bacilli** in typhoid fever. **Spirochæte Obermeieri** may be present in relapsing fever.

The Thymus.

MALFORMATION AND HYPERTROPHY.

Small accessory thymus glands are occasionally found near the thyroid.

It is usual for the development of the thymus to reach its height in the early years of life. It then undergoes involution or atrophy, losing its epithelial characters and becoming largely composed of lymphoid cells. It is finally represented in old age by a small mass of fat tissue. Occasionally, however, the thymus persists until youth or middle age¹ (Fig. 275). Furthermore, it may become enlarged—so-called *hypertrophy* of the thymus. The enlargement is, however, due to a hyperplasia rather than hypertrophy: the new-formed tissue may present a more or less marked lobulated or glandular appearance. This new-formed tissue, according to the studies of Sultan and Lochte, may be largely composed of lymphoid cells, or of larger polyhedral cells, so-called "epithelioid" cells.² Focal necroses have been recorded in diphtheria.

HÆMORRHAGE.

Small, and sometimes large, hæmorrhages are occasionally seen in the thymus of young children as the result of venous congestion in asphyxia, poisoning, etc. They may also occur in the hæmorrhagic diathesis.³

INFLAMMATION.

Suppurative inflammation of the thymus is of occasional occurrence, and is usually secondary to a similar inflammatory process in some other part of the body. **Tuberculous** and **syphilitic** lesions of the thymus are described, but are rare.

TUMORS.

Sarcoma of the spheroidal-cell form is the most common tumor; **Angioma**, **Endothelioma**, and **Dermoid Tumors** are recorded.

¹ See *Lochte*, *Centbl. f. allg. Path. u. path. Anat.*, Bd. x., p. 1, 1899, bibl.

² For the significance of a persistent thymus in certain cases of sudden death see *Norton*, *Phila. Med. Jour.*, vol. i., p. 249, 1898, bibl.; also ref. to *Ewing*, p. 1. On the relationship of hyperplasia in a persistent thymus to Hodgkin's disease consult *Brigidi* and *Piccoli*, *Ziegler's Beitr. z. path. Anat.*, etc., Bd. xvi., p. 388, 1894. For a study of the weight of the thymus in infancy see *Bovaird* and *Nicoll*, *Arch. of Pediatrics*, Sept., 1906. For a thorough and admirable study of the normal and pathological histology of the thymus see *Pappenheimer*, *Jour. Med. Res.*, xxii., 1, 1910.

³ For a study of "Apoplexy" of the thymus see *Mendelsohn*, *Arch. f. Kinderheilkunde*, Bd. xlv., p. 1, 1906.

CHAPTER IV.

THE THYROID AND ADRENALS.

The Thyroid.

Malformations.

THE thyroid gland is sometimes very small, either as the result of atrophy or as a congenital deficiency. For the relationship of this condition to cretinism and myxœdema see page 429.

The thyroid may be irregularly lobulated. There may be small accessory glands situated at some distance from the normal position, as in the mediastinum or pleura.¹

DEGENERATION.

Colloid degeneration of the epithelial cells of the gland, and the filling of the alveoli with colloid material, are of common occurrence, and when in moderate degree may be regarded as normal, since a certain amount of this change is found in many otherwise apparently normal glands. It may occur, however, to such an extent as to constitute an important lesion (see below).

Amyloid degeneration, particularly of the blood-vessels, is of infrequent occurrence.

Hyaline degeneration of the stroma of the thyroid may occur.

DISTURBANCES OF CIRCULATION.

Hyperæmia of the thyroid gland, often accompanied by considerable enlargement of the organ, may be the result of valvular disease of the heart; it occurs in Basedow's disease; it may be temporary or permanent, and in the latter case may be associated with the formation of new connective tissue. Hæmorrhages may occur, leading to cysts and to pigmentation of the organ.

INFLAMMATION. (Strumitis.)

Inflammation of the thyroid gland is not very common and may occur under a variety of conditions, especially in infectious diseases, septicæmia, typhoid fever, diphtheria, etc. It may result in the formation of larger and smaller abscesses or in the production of new connective tissue which may be associated with atrophy of the parenchyma. **Tuberculous inflammation**, with the formation of miliary tubercles, is of infrequent occurrence.² **Syphilitic inflammation**, with the formation of gummata, has been described, but is rare.³

For references to studies on removal and transplantation of the thyroid see foot-note, p. 78.

² See *Roger and Garnier*, *Arch. gén. de méd.*, t. iii., p. 385, 1900, bibl.

³ For a study of the normal and pathologic histology of the thyroid, with bibliography, consult *Muller, Ziegler's Beitr. z. path. Anat.*, etc., Bd. xix., p. 127, 1896; also *Erdheim, Ziegler's Beitr.*, Bd. xxxiii., 1903, p. 159. For myxœdema and Basedow's disease see pp. 429 and 432. For relations of thyroid to pregnancy see *Ward, Surgery, Gynecology, and Obstetrics*, ix., 617, 1909.

STRUMA. (Hyperplasia of the Thyroid; Goitre.)

Among the most important of the lesions of the thyroid is the enlargement of the organ commonly known as the *goitre* or *struma*. The enlargement of the gland may occur in several ways. Thus, a simple hyperæmia may, as above stated, lead to considerable enlargement of the organ, and this is sometimes called *struma hyperæmica*. The true goitre, however, consists in the enlargement of the old and the formation of new gland alveoli, while with these changes there is very frequently

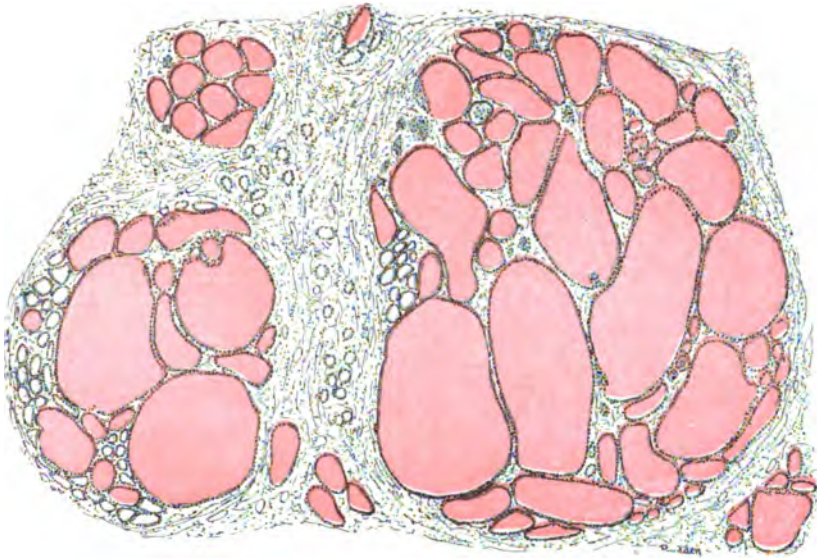


FIG. 308.—COLLOID STRUMA—GOITRE.
The colloid material filling the alveoli is stained red.

associated a greater or less amount of colloid degeneration. When there is new formation of gland tissue the growth has the character of an *adenoma*. The hyperplasia may occur diffusely, so that the whole gland is more or less enlarged; or it may occur in the form of circumscribed nodules. When the colloid degeneration is prominent, so that the tumor has a gelatinous appearance, it is called *colloid struma* (Fig. 308).¹ Accumulations of fluid, blood, colloid, etc., in the old or new-formed alveoli, may lead to dilatation and atrophy of the walls of the alveoli, so that cysts, sometimes of large size, are formed. Thus occurs the *cystic struma*. Again, the blood-vessels may undergo marked dilatation, so that we may have a *telangiectatic struma*; or *cavernous angiomata* may form within goitres. Very frequently all these varieties of lesions are present in the same goitre. The appearances may be rendered still more complex by the occurrence of hæmorrhages and pigmentation, calcification, purulent

¹ For a consideration of the nature of colloid and its formation in struma see Reinbach, Ziegler's Beitr. z. path. Anat., etc. Bd. xvi., p. 596, 1894, bibl.

or indurative inflammation (strumitis), and by the not very infrequent association with carcinoma and sarcoma. The excitants of goitre are not well understood. The growth is, as a rule, slow, but occasionally a very rapid enlargement occurs as the result of a sudden increase of the colloid degeneration. In many cases even very large goitres give rise to but moderate inconvenience, but they may assume great significance by encroaching upon neighboring parts. Thus death may be caused by pressure on the trachea, œsophagus, or on the large vessels. For lesions believed to be characteristic of exophthalmic goitre see page 432.

TUMORS.

Some of the forms of goitre above described may be regarded as tumors or may be associated with tumors. **Sarcoma** and **endothelioma** are the most common tumors of the thyroid.

Sarcoma, either spheroidal or spindle-celled, may occur as primary tumors in the thyroid, either in otherwise normal glands or in connection with struma.¹ **Melano-sarcoma** has been observed. Secondary sarcomata are rare.

Primary **carcinoma**, both glandular and scirrhous, occurs in the thyroid, and, particularly in the softer forms, may spread to adjacent parts and occasionally form distant metastases. Dermoid cysts are of occasional occurrence.² Blood cysts are frequently found.³

PARASITES.

Echinococcus cysts have been found in the thyroid.

PARATHYROID GLANDS.

Closely connected with the thyroid, occasionally within, sometimes without its capsule, are four small gland-like bodies, usually two on each side. These are the parathyroids ("epithelial bodies") and are apparently in some way associated with the thyroid in function.⁴ There may be accessory parathyroids.

The parathyroids appear to be of great importance in the metabolism of the body, since their complete removal apparently usually leads to fatal tetany. It has been shown by MacCallum and Voegtlin⁵ that the calcium salts of the body are rapidly excreted on the removal of the parathyroids in dogs, and that the symptoms of tetany following the removal cease on the administration of calcium salts. It is inferred from these observations that the parathyroids control the calcium metabolism of the body. Berkeley and Beebe⁶ conclude from their experiments that the symptoms following removal of the thyroid are due to deranged metabolism giving rise to some active poison and not to the abnormal excretion of calcium.

¹ Consult for summary of observations on sarcoma of the thyroid, *Morf*, Jour. Am. Med. Ass'n, vol. xxxii., p. 911, 1899, bibl.

² For a résumé of mixed tumors of the thyroid see *Leo Loeb*, Am. Jour. Med. Sci., vol. cxxv., p. 243, 1903.

³ For a study of hæmorrhagic cysts of the thyroid see *Bradley*, Jour. Exp. Med., vol. i., p. 401, 1896.

⁴ For a study of the parathyroids, with bibl., see *Thompson*, Jour. Med. Res., vol. xv., p. 399, 1906.

⁵ *MacCallum and Voegtlin*, Johns Hopkins Hosp. Bull., xix., 91, 1908, and Jour. Exp. Med., xi., 118, 1909.

⁶ *Berkeley and Beebe*, Jour. Med. Res., xx., 149, 1909.

The parathyroids may be the seat of tumors.¹ Other lesions have been described, but the nature and pathology of these organs are too little understood to permit of further consideration of them here.²

The Adrenals. (Suprarenal Bodies, Suprarenal Capsules.)

Malformations.

In acephalic and other monsters the adrenals may be atrophied or entirely absent. Sometimes in well-formed adults these organs cannot be discovered. There may be little rounded nodules loosely attached to the surface of the adrenals and having the same structure. Accessory and misplaced adrenals are not uncommon. A few cases have been reported of accessory adrenals in the broad ligament.³ They may be present in the liver.⁴

If one kidney be absent or in an abnormal position its adrenal usually retains its proper position.⁵

ATROPHY AND DEGENERATION.

Atrophy of the adrenals may be extreme.

Fat Infiltration.—An accumulation of fat or of myelin droplets⁶ in the cortical portion is the rule in the adult. It sometimes occurs in

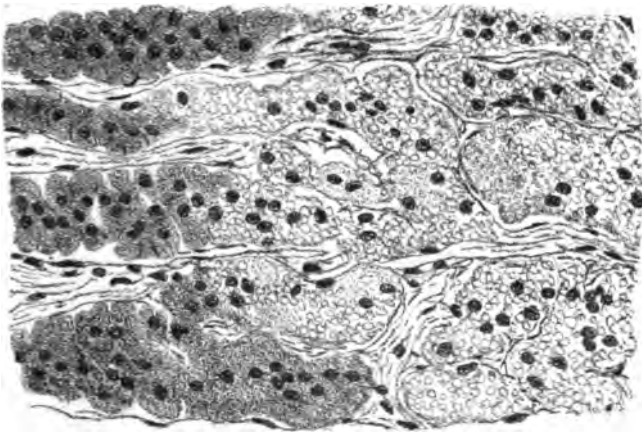


FIG. 309.—FATTY DEGENERATION OF THE ADRENAL.

nodular areas (Fig. 309). In children under five years of age it is pathological.

Amyloid degeneration may involve both the cortical and medullary portions. In the cortex it usually involves only the walls of the blood-vessels; in the medulla both the blood-vessels and the cells of the paren-

¹ See *MacCallum*, Johns Hopkins Hosp. Bull., vol. xvi., p. 87, 1905; also *Weichselbaum*, Verh Deut. Path. Ges., Bd. x., p. 83, 1907.

² For transplantation of parathyroids see *Thompson and Leighton*, Jour. Med. Res., xxi., 135, 1909.

³ See *Warthin*, American Journal of Obstetrics, vol. xlii., 1900, bibl.

⁴ See *Noyes*, Trans. New York Path. Soc., 1899-1900, p. 4; also *Beer*, Zeits. f. Heilkunde—Abth. path. Anat., Bd. xxv., p. 381, 1904.

⁵ For consideration of relationship of the adrenals to the nervous system see *Alexander*, Ziegler's Beitr. z. path. Anat., Bd. xi., p. 145, 1892, bibl.

⁶ For a study of myelin substances in the adrenal see *Herrmann*, Arbeiten a. d. path. Inst., Tübingen, Bd. v., p. 417, 1906.

chyma may undergo this degeneration. The organs are usually firm and have a grayish, semitranslucent appearance.

Pigmentation of the inner cortical zone is frequent in old persons. Focal necroses may occur in infections.

THROMBOSIS AND HÆMORRHAGE.

Venous and capillary thrombosis may occur.

In children, soon after birth, it is not very infrequent to find large hæmorrhages in one of the adrenals, converting it into a cyst filled with blood (Fig. 310). This lesion has been observed in a few cases in adults.¹

INFLAMMATION.

Suppurative inflammation, with the formation of abscesses, has been seen in a few cases.

The most frequent lesion of the adrenals is **tuberculous inflammation**. They are usually increased in size; their surfaces are smooth or nodular.

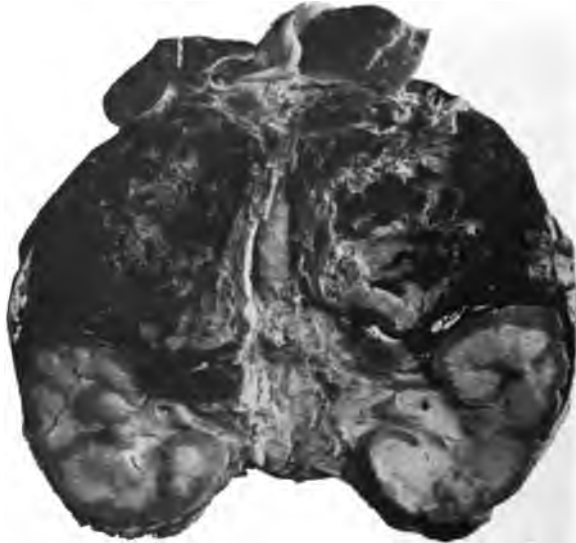

FIG. 310.—HÆMORRHAGE INTO AND ABOUT THE ADRENAL. (Infant.)

The normal structure of the gland is more or less replaced by tubercle tissue, which usually undergoes cheesy degeneration and may soften. Fibrous tissue may form in considerable amount. For a consideration of the relationship of lesions of the adrenals to Addison's disease see page 433.²

Syphilitic inflammation, with and without the development of gummata, is of occasional occurrence.

¹ For bibl. see *Arnaud*, *Arch. gén. de méd.*, t. iv., p. 5, 1900.

² For reference to nature of adrenal secretion, etc., see *Abel*, foot-note, p. 434. For a study of pathology of adrenals see *Karakaschew*, *Ziegler's Beitr.*, Bd. xxxix., p. 373, 1906, bibl.; see also for recent *résumé*, *Davis*, *N. Y. Med. Jour.*, vol. lxxxiv., p. 263, 1906, bibl.

TUMORS.

Sarcoma, glioma,¹ and endothelioma occur in the adrenals.

Neuroma.—Ganglionic neuromata have been described by Weichselbaum and Freeman.

Adenoma of the adrenals, resembling in type the structure of the cortex, may form as small encapsulated nodules or as large vascular tumors, often necrotic and hæmorrhagic, which may invade the neighboring vessels and form metastases. This condition has been called *stroma suprarenalis lipomatosa*. The so-called fat droplets here, as in the normal suprarenal, are probably myelin. Some of the so-called adenomata of the kidney are adenomata of displaced accessory adrenals (see p. 777).

Carcinoma is not common, but may be primary or secondary.²

The Pituitary Body. (Hypophysis Cerebri.)

This organ, formed like the adrenals, of epithelial and nerve structures, presents three sections: 1, anteriorly, a series of epithelial cells with abundant blood vessels; 2, an intermediary portion, containing epithelial cells and neuroglia fibrils; and 3, a posterior portion formed of neuroglia cells and fibres. While the function of this gland is not known, it has been found that extracts of the intermediary and posterior portions have an influence on blood pressure and on urinary excretion. Complete removal of the gland is fatal.

Hyperplasia and tumors involving the gland are often associated with acromegaly (see p. 438).

The Carotid Gland.

This is a small ductless, encapsulated structure, five to seven millimetres long, lying at the bifurcation of the carotid artery. It is composed of a connective-tissue framework and masses of polyhedral cells grouped with tufts of blood capillaries. It contains many nerves. It is believed to be analogous to the adrenals, hypophysis cerebri, and coccygeal gland. The carotid gland is occasionally the point of origin of lobulated tumors. These have been called angio-sarcoma, endothelioma, perithelioma.³

¹ For a study of glioma of sympathetic and adrenal, see *Schilder*, *Frankfurter Zeitschr. f. Path.*, iii., 317, 1909.

² For bibliography of primary malignant tumors of the adrenals see *Ramsay*, *Johns Hopkins Hospital Bulletin*, vol. x., p. 20, 1899.

³ For a study of carotid tumors see *Keen and Funke*, *Jour. Amer. Med. Assn.*, vol. xlvii., pp. 469 and 566, 1906, bibl.

CHAPTER V.

THE CIRCULATORY SYSTEM.

The Pericardium.

INJURIES.

THE pericardium may be injured by penetrating weapons, by gunshot wounds, and by fragments of bone. It may be ruptured by severe contusions of the thorax, and by rapid extravasation of blood into the pericardial sac. Perforations may occur with empyema, mediastinal abscesses, abscesses of the chest wall and of the liver, or in connection with aneurisms of the aorta and suppurative inflammation of the pericardium.

HÆMORRHAGE. (Hæmopericardium.)

Extravasations of blood into the cavity of the pericardium may follow wounds and rupture of the heart, rupture of the aorta and of aneurisms, and may occur with pericarditis from the rupture of new-formed blood-vessels. Small extravasations in the substance of the pericardium are found with scurvy, purpura, and in infectious diseases.

HYDROPERICARDIUM. (Dropsy.)

At autopsies a few hours after death a few cubic centimetres of clear, light-yellow serum are usually present in the pericardial sac. If decomposition have commenced, this may be reddish, or it may be slightly turbid from the falling-off of the pericardial endothelium.

Large accumulations of clear yellowish serum are often found as part of general dropsy from heart disease, kidney disease, etc. The amount is sometimes so great as to interfere with the movement and nutrition of the heart.

PNEUMOPERICARDIUM.

Air or gas in the pericardium may be the result of post-mortem decomposition and there may then be drying of portions of the pericardium. Wounds or paracentesis of the pericardium; the perforation of ulcers of the stomach, cavities of the lungs, and ulcers of the œsophagus, or subdiaphragmatic abscess, may admit air into the pericardial cavity.¹ In purulent pericarditis with foul, decomposing exudate, gases may be evolved.

INFLAMMATION. (Pericarditis.)

Pericarditis is rarely primary, but is usually secondary to infectious diseases, such as pneumonia, pleurisy, tuberculosis, typhoid fever, endo-

¹ See *James, Am. Med.*, vol. viii., p. 23, 1904.

carditis, and pyæmia. It may follow injuries and is frequently associated with rheumatism or inflammation of the kidneys. It may be *exudative* or *productive* in character.

Exudative Pericarditis.—It is convenient to distinguish in exudative pericarditis a *fibrinous*, a *sero-fibrinous*, and a *purulent* form.

FIBRINOUS AND SERO-FIBRINOUS PERICARDITIS.—In the earlier stages or lighter forms of fibrinous pericarditis, the whole surface or portions of the pericardium may be dull or slightly roughened from a delicate fibrinous pellicle, more or less hyperæmic, and often studded with minute petechiæ. Later, if the exudate accumulate, the entire surface



FIG. 311. FIBRINOUS PERICARDITIS.

The pericardial sac is laid open and the part is seen covered with an irregular villous layer of fibrin.

of the pericardium may be covered with a net-like layer of thick masses of fibrin. This may cover both the visceral and parietal surfaces and is often beset with irregular villousities (Fig. 311). Fibrinous adhesions may form between the two layers. There is usually some serous fluid as well as leucocytes mingled with the fibrin.

Serum may accumulate in considerable quantity—*sero-fibrinous pericarditis*. The pericardial sac may be greatly distended with this form of exudate so as to displace the heart and compress the larger air passages, the œsophagus, or the aorta.

PURULENT PERICARDITIS.—In this form of exudative pericarditis there are usually more or less serum and fibrin mingled with pus cells and often red blood cells. The process may start as a sero-fibrinous inflammation. It is apt to occur as an extension of an infectious process in the neighborhood or as a part of a general pyæmic process. *Streptococcus pyogenes*, *Diplococcus pneumoniae*, *Staphylococcus pyogenes aureus*, and the tubercle bacillus are the bacteria most commonly found in exudative pericarditis.

Chronic Pericarditis.—In exudative pericarditis the mesothelium¹ (endothelium) in the early stages, and later this with the underlying connective-tissue cells contributes to the cellular elements in the exudate. In recovery the exudates degenerate and are gradually absorbed, while

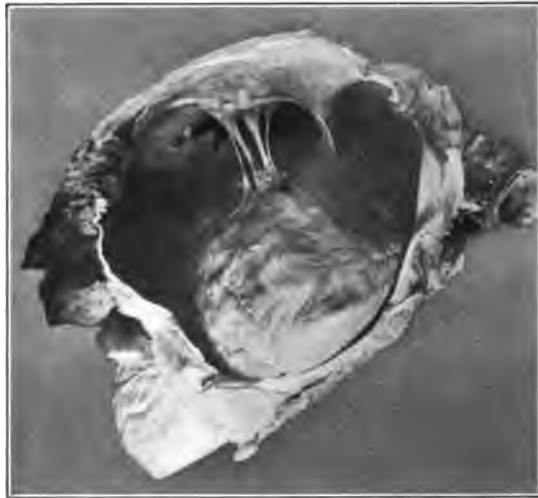

FIG. 312.—ADHESIONS OF THE PERICARDIUM.

The pericardial sac is opened so that the heart is viewed from the direction of the apex. There are two clusters of delicate fibrous bands joining the parietal and the visceral pericardium.

from the blood-vessels and the connective-tissue cells of the pericardium more or less new fibrous tissue is formed, at first very cellular and vascular, later dense in character. There may finally be local or general thickenings of the pericardium. If a moderate amount of new fibrous tissue is formed this may appear as thin, white patches on the pericardium surface, the so-called *maculae tendineæ*. The new fibrous tissue may extend between the subpericardial muscle fibres of the heart. Calcification of this new-formed fibrous tissue may occur. But more or less permanent adhesions may form between the visceral and parietal pericardium. These may be in the form of delicate fibrous strings (Fig. 312) or of larger areas of firm adhesion.

OBLITERATION OF THE PERICARDIAL SAC.—As the result of the for-

¹ See reference to *Minot*, p. 377.

mation of vascular new connective tissue between the pericardial walls, the sac may be partially or wholly obliterated (Fig. 313).

This may be the conclusion of an acute inflammatory process or it may result from the organization of a blood-clot following hæmorrhage into the sac. It may occur as the result of the latter process early in life.

SUPRA-ARTERIAL EPICARDIAL FIBROID NODULES.—Small fibrous nodules are occasionally formed along the branches of the coronary arteries, especially on the surface of the ventricles. According to the studies of Knox¹ they are frequently associated with lesions of the arteries, leading to the weakening of their walls at these situations.

Tuberculous Pericarditis.—This lesion may occur by itself, but is apt to be associated with other tuberculous inflammation in the vicinity of

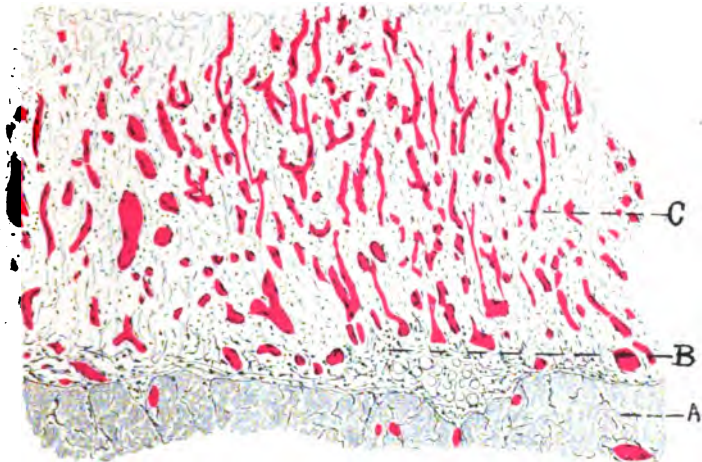


FIG. 313.—OBLITERATION OF THE PERICARDIAL SAC IN A CHILD, FOLLOWING PERICARDITIS.

Showing blood-vessels growing from the visceral pericardium into the blood-clot filling the sac. Transverse section. A, Heart; B, pericardium; C, new-formed vascular tissue extending above to the unorganized clot. A similar layer of new vascular tissue was present over the parietal pericardium, and in places the two layers had coalesced, obliterating the sac.

the heart. There may be miliary tubercles scattered diffusely, or limited to certain regions in the pericardium, which is otherwise little changed. Not infrequently, however, there is a considerable thickening of the pericardium, either visceral or parietal, or both.

In such cases the new-formed tissue consists of fibrous tissue and of tubercle tissue which has undergone extensive cheesy degeneration (Fig. 314). The thickened visceral and parietal layers of the pericardium are often more or less grown together, so that the pericardial sac may be partially or almost completely obliterated. An inflammatory exudate often accompanies the tuberculous process.²

¹ Knox, *Jour. of Exp. Med.*, vol. iv., p. 245, 1899.

² For bibliography of tuberculous pericarditis see Norris, *Bull. Univ. Penn.*, vol. xvii., p. 155, 1904.

TUMORS.

Fibromata are sometimes developed in the pericardium. They are often of polypoid form, and from atrophy of the pedicle may become free in the pericardial sac. **Lipoma** of the pericardium has been described. **Endotheliomata** are of occasional occurrence as primary tumors.

Sarcomata and **carcinomata** occur as secondary growths either from continuous infiltration or as metastatic tumors. Primary sarcoma of the pericardium has been described.¹

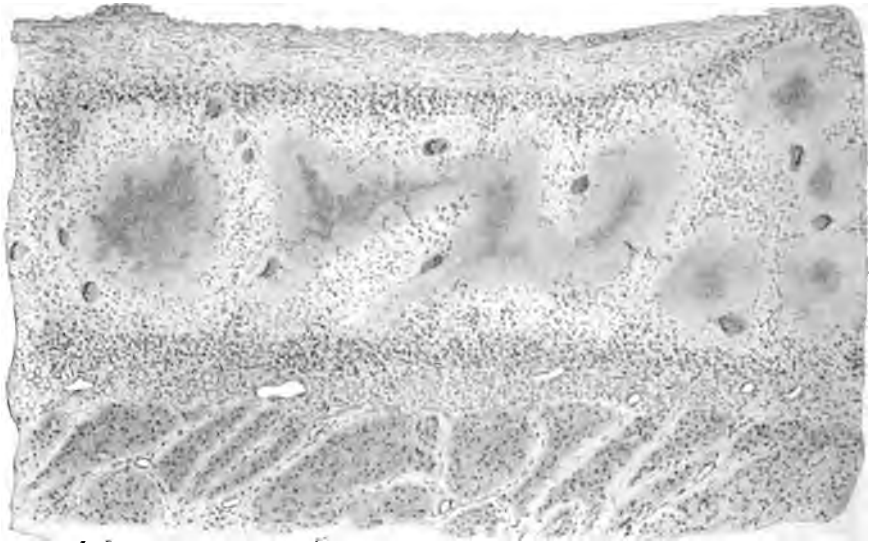


FIG. 314.—TUBERCULOUS PERICARDITIS.

The greatly thickened pericardium shows diffuse tissue with giant cells and irregular areas of cheesy degeneration. The free—upper—surface is covered with a layer of fresh fibrin.

Cysts of the visceral pericardium have been described. The writer has seen a pedunculated cyst, containing about 6 c.c. of clear fluid, hanging into the pericardial sac from its attachment near the pulmonary artery. The origin of such cysts is obscure.

The Heart.

Malformations and Malpositions.

MALFORMATIONS OF THE HEART.—The malformations of the heart are usually closely associated with malformations of the aorta and pulmonary artery. They depend on arrest of, or abnormal, development; on endocarditis, myocarditis, thrombosis, or mechanical causes.

I. The common arterial trunk is only partially, or not at all, separated into aorta and pulmonary artery. The divisions between the heart cavities are at the same time

¹ *Williams*, N. Y. Med. Jour., vol. lxxi., p. 537, 1900, bibl.

defective, so that there may be one ventricle and no auricles; one ventricle and one auricle—reptilian heart (Fig. 315); or one ventricle and two auricles.

II. The trunk of the pulmonary artery or of the aorta is stenosed or obliterated, and from the obstruction to the current of blood there is interference with the development of the septa between the heart cavities.

1. The aorta, at its origin, or in the ascending portion of the arch, is stenosed or closed. The pulmonary artery gives off the descending aorta, and supplies the carotids and subclavians. The foramen ovale remains open, or there is no septum between the auricles. The ventricular septum is also usually defective. The right ventricle is hypertrophied.

2. The pulmonary artery is stenosed or closed (Fig. 316). Its branches are supplied by the aorta, through the ductus arteriosus. The ventricular septum is defective, the foramen ovale is open, or the auricular septum defective.

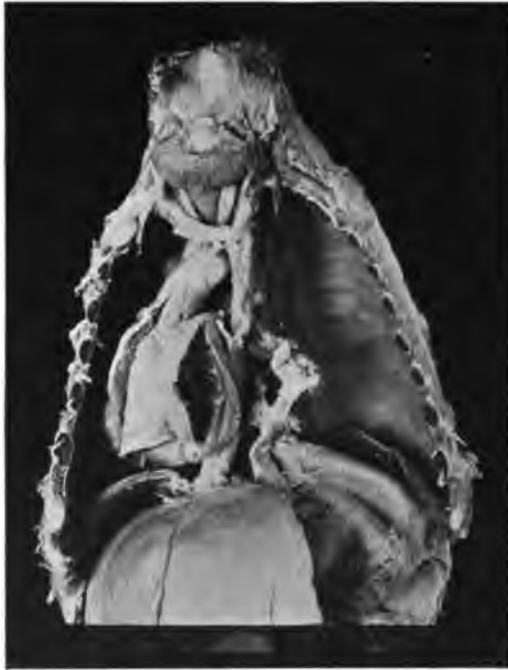

FIG. 315.—REPTILIAN HEART.
Shows one auricle and one ventricle.¹

III. The malformation affects the aorta and pulmonary artery after they are more fully developed.

1. There is stenosis of the aorta between the left subclavian and ductus arteriosus, or just at the opening of the ductus arteriosus. The descending aorta is then a continuation of the pulmonary artery.

2. The aorta gives off all its branches from the arch, but the descending aorta is a continuation of the pulmonary artery; or the carotids may spring from the aorta, the subclavians from the pulmonary artery.

3. The vessels are transposed; the pulmonary artery arises from the left, the aorta from the right ventricle; the pulmonary veins empty into the left, the venæ cavæ into the right auricle; or the veins also may be transposed. The septa are defective.

¹ For a description of this case see *Northrup*, Trans. N. Y. Path. Soc., 1888, p. 41.

IV. The aorta and pulmonary artery are normal, but the cardiac septa are defective.

1. The foramen ovale remains partly open. This condition may continue through life without ill effects. It has been found by some observers in about one-fifth of their autopsies.

2. The ductus arteriosus may remain open for many years; this also may cause no disturbance.

3. There is a small or large opening in the ventricular septum, usually in its upper part (Fig. 317). This may give rise to no symptoms, unless disease of the heart or lungs be superadded.

V. Either of the auriculo-ventricular orifices may be entirely closed. The foramen ovale remains open, and the ventricular septum is defective.¹



FIG. 316.—STENOSIS OF THE PULMONARY ARTERY.
The ductus arteriosus is open.

VI. The valves of the different orifices of the heart may be absent or defective. The arteries or the ventricles are usually defective at the same time.

The aortic and pulmonary valves may consist of two large or four small leaves, instead of the usual three.

The edges of the semilunar valves may be fenestrated. This alteration is usually of no significance. It is frequent in the aortic and pulmonary valves. The valves may be thinner than normal, and near their free edges are small slits or openings (see Fig. 318).

Generally speaking, the existence of openings between the two auricles or the two

¹Consult for a study of rare forms of cardiac anomalies, *Hektoen*, *Am. Jour. Med. Sci.*, vol. cxxi., p. 163, 1901, bibl.

ventricles, admitting some admixture of venous and arterial blood, produces no marked change in the circulation. If, however, the passage of the current of venous blood into the right heart is in any way interfered with, the consequences are very serious. Cyanosis is produced, the skin is of a bluish color, the small veins and capillaries are dilated, exudation of serum and hypertrophy of connective tissue take place, especially in the fingers and toes.

There may be absence of the heart; abnormal septa and chordæ tendinæ¹ (Fig. 319) in the heart cavities; abnormal shapes of the heart. Very rarely two more or less perfect hearts are found in the same thorax.

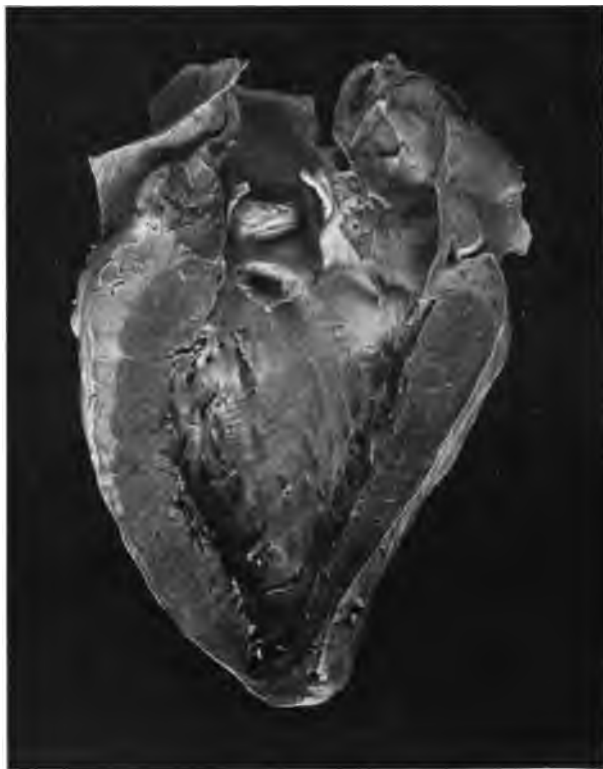

FIG. 317.—OPENING IN THE VENTRICULAR SEPTUM OF THE HEART—INTERVENTRICULAR FORAMEN. The opening is about 5 mm. in diameter, and its edges are formed by fibrous tissue.

MALPOSITIONS OF THE HEART.—1. There is a smaller or larger defect in the walls of the thorax, so that the heart projects on the outside of the chest; the pericardium is usually absent.

2. The diaphragm is absent, and the heart is in the abdominal cavity.

3. The heart is in some part of the neck or head; this occurs only in fetuses very much malformed.

4. The heart is transposed, being on the right side.

ABNORMAL SIZE OF THE HEART.—1. The heart may be abnormally large in connection with obstructive anomalies of the great vessels.

¹ For a study of the origin of abnormal chordæ tendinæ in the heart see *Tawara, Ziegler's Beitr.*, Bd. xxxix., p. 563, 1906.

2. The heart may be abnormally small (hypoplasia). This abnormality is apt to be associated with the so-called status lymphaticus (see p. 439).

DISPLACEMENTS OF THE HEART.—Changes in the position of the heart are congenital or acquired. The congenital malpositions have already been mentioned.

The acquired malpositions may be associated with:

1. Hypertrophy of the heart; its long axis approaching the horizontal position.
2. Changes in the thoracic viscera. Emphysema of both lungs may push the heart downward. Emphysema, pleurisy with effusion, or pneumothorax of one side pushes

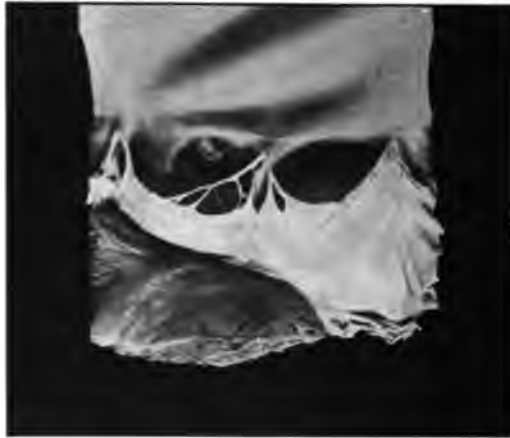

FIG. 318.—FENESTRATION OF THE SEMILUNAR VALVES.

the heart to the other side. Pleurisy or chronic pneumonia, producing retraction of one side of the thorax, draws the heart to that side. New growths, aneurisms, and curvatures of the spine displace the heart in various directions.

3. Changes in the abdomen. Accumulations of fluid and new growths in the abdomen, and tympanites, may push the heart upward.

WOUNDS AND RUPTURES.

Wounds of the heart are most frequently made by penetrating instruments, by bullets, and by fragments of bone. The right ventricle is the more frequently wounded (Fig. 320); next the left; rarely the auricles. The wound may penetrate into the cavities of the heart or pass only partly through its wall, or a bullet or the broken end of a weapon may be embedded in the wall. If the wound penetrate a cavity and be gaping, death may follow instantly and the pericardium be found filled with blood. If the wound be small and oblique, the blood may escape gradually and death may not ensue for several days. In rare cases adhesions are formed with the pericardium and the wound cicatrizes. Wounds which do not penetrate may cause death by the inflammation which they excite, or they may cicatrize.

Bullets and foreign bodies may become encapsulated in the heart wall and remain so for years.

Rupture of the heart wall occurs in various ways:

1. Severe contusions of the thorax may produce rupture, usually of one of the auricles.¹

2. Spontaneous rupture occurs usually in advanced life. Rupture is most frequent in the left ventricle, and, in a considerable proportion of cases, near the apex. There is usually one rupture, but sometimes there are more. The rupture is usually oblique and larger internally than externally. The heart wall, near the seat of rupture, may be infiltrated

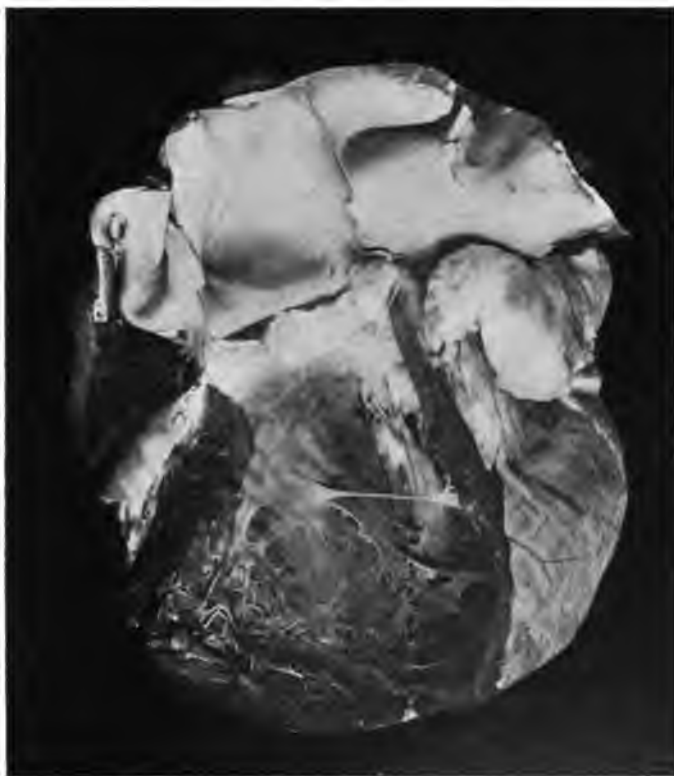

FIG. 319.—ABNORMAL CHORDÆ TENDINEÆ.

These unite to form a slender band stretching across the cavity of the ventricle.

with blood, or blood may infiltrate the subpericardial fat. The heart wall may be of normal thickness, or thin; it is usually soft and in a condition of fatty infiltration or degeneration. The rupture very frequently takes place when the patient is quiet. Death may be almost instantaneous or may not ensue for several hours.

Fatty degeneration leading to rupture of the heart may be general, or it is frequently circumscribed and due to obliterating endarteritis, ather-

¹For bibliography see *Newton*, *Med. Record*, vol. iv., p. 864, 1899. Also *Hamilton*, *Phila. Med. Jour.*, January 24th, 1903.

oma, thrombosis, or embolus of one of the coronary arteries, whereby a portion of the heart wall is deprived of nourishment and degenerates. Or rupture of a branch of one of the coronary arteries may induce rupture of the heart wall. Acute and chronic myocarditis, with or without the

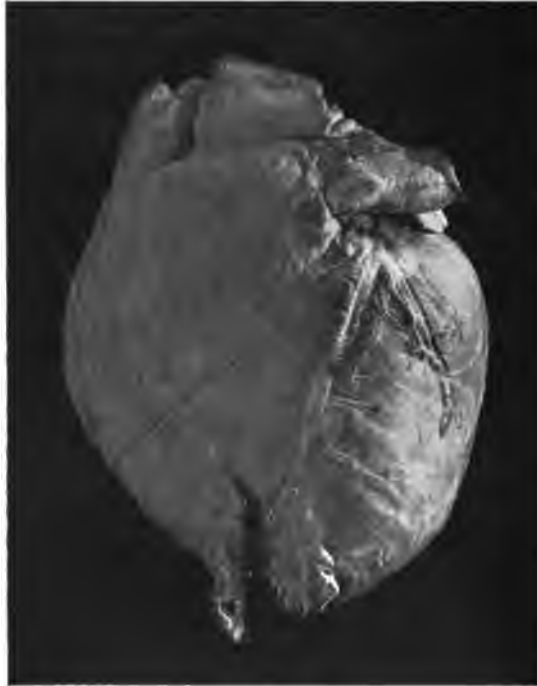

FIG. 320.—RUPTURE OF THE HEART.
From contusion.

formation of abscess or cardiac aneurism, or the presence of tumors in the heart wall, or hydatids, may lead to rupture.¹

3. In rare cases rupture is associated with stenosis of the aorta and dilatation of the heart cavities.

4. Rupture of the papillary muscles and tendons may be due to fatty degeneration or inflammatory or ulcerative processes.

ATROPHY.

Atrophy of the walls of the heart may be accompanied with no change in the size of its cavities; or with dilatation ("passive dilatation"); or, more frequently, with diminution in the size of the cavities.

The atrophy involves most frequently all the cavities of the heart, but may be confined to one or more of them.

¹ Consult *Councilman*, "On Sudden Deaths due to the Heart," *Boston Med. and Surg. Jour.*, Nov. 9th, 1893.

The muscular tissue appears normal, or may be brown from the presence of little granules of pigment in the muscle fibres, which are sometimes present in large numbers—*brown atrophy*; or the muscle fibres may undergo fatty degeneration; or there may be an abnormal accumulation of fat beneath the pericardium; or there may be a peculiar gelatinous material beneath the pericardium—this consists of fat which has undergone mucous degeneration. The heart may be so much atrophied as to weigh only four ounces.

Atrophy of the heart may be congenital; it may be associated with repeated hæmorrhages or wasting diseases, or senility, with chronic pericarditis, with effusion, with obstructive lesions of the coronary arteries, with chronic myocarditis, or with mitral stenosis.

Atrophy of the pericardial fat tissue not infrequently occurs in persons emaciated by chronic disease, and then the usual situa-

tions of the fat are occupied by a tissue resembling mucous tissue in its gross characters. Microscopical examination shows that in this atrophic fat the fat cells have largely lost their contents, and the whole tissue has undergone a partial reversion to its embryonic form (see Fig. 321).

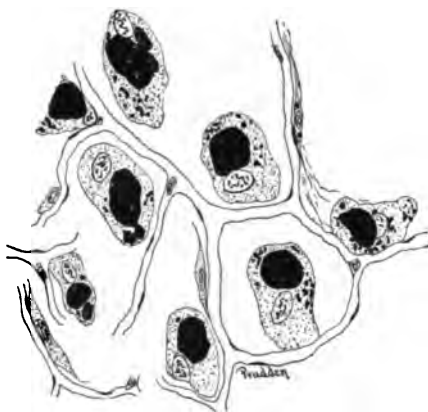


FIG. 321.—ATROPHIC PERICARDIAL FAT TISSUE.

From a young person dead of carcinoma of the stomach and peritoneum. Stained with osmic acid and teased.

ANEURISM OF THE HEART AND VALVES.

Aneurism of the Heart.—Sacs filled with blood, situated in the walls of the heart and communicating with its cavities, are formed in several different ways:

1. In interstitial myocarditis a small or large portion of the wall may be replaced by fibrous tissue, and this, yielding to the pressure of the blood from within, may be pressed outward. Such a pouch may be a circumscribed sac communicating with the heart cavity by a small opening, or may be a simple dilatation of part of the ventricle. The wall of such an aneurism becomes thinner as the sac increases in size. It is composed of the endocardium, new fibrous tissue, visceral pericardium, and sometimes the adherent parietal pericardium. The walls may calcify, or rarely they become so thin as to rupture externally or into the right ventricle. The sacs may contain fluid blood or be filled with fibrin.

Such aneurisms are usually situated in the wall of the left ventricle; rarely in that of the left auricle. If they are in the septum they may project into the right ventricle or auricle (Fig. 322). They are usually single, but sometimes two or three are found in the same heart.

2. Fatty degeneration of the heart wall may reach such a degree that the wall yields and is pouched out into an aneurismal sac.

3. Endocarditis and myocarditis, or fatty degeneration, may so soften a portion of the heart wall that the endocardium and part of the muscular tissue are ruptured and a ragged cavity is formed. This form of aneu-

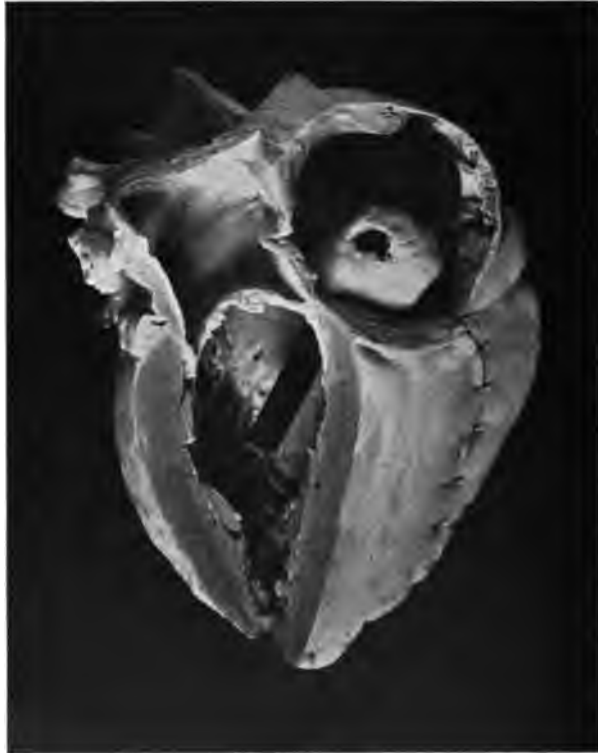

FIG. 322.—ANEURISM OF THE HEART OPENING FROM THE LEFT VENTRICLE INTO THE RIGHT AURICLE.
Seen from behind.

rism usually does not attain a large size, but soon ruptures externally and causes the death of the patient.

Small aneurisms of the sinus of Valsalva are of occasional occurrence.

Aneurisms of the Valves.—These are formed in two ways:

1. They are the result of endocarditis. One of the lamellæ of the leaf of a valve is destroyed, and the other lamella is converted into a sac filled with blood. These aneurisms are found in the aortic valve, projecting into the ventricle, and in the mitral valve, projecting into the auricle. Not infrequently the wall of the aneurism gives way, so that there is a rupture entirely through the valve.

2. The entire thickness of a leaf of a valve is pouched, forming a sac filled with blood. This occurs in the aortic, mitral, and tricuspid valves.

THROMBOSIS OF THE HEART.

It is common to find after death, in the heart cavities, yellow, succulent, semitranslucent masses. They are most common and of firmest texture in persons who die of acute inflammatory diseases. They may adhere quite firmly to the walls of the heart and may extend in long, branching cords into the vessels. They are formed in the last hours of life and just after death. They are not of clinical or pathological importance. It is, however, often difficult to determine to what extent such clots have been formed during life, for these so-called "agonal" clots may be continuous with those formed some time before death as well as with those formed after life has become extinct.

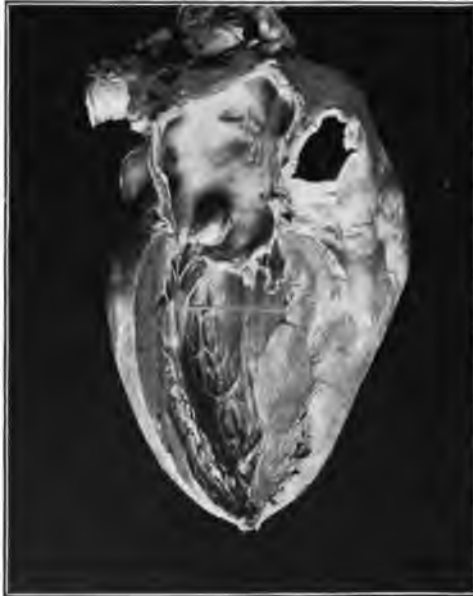

FIG. 323.—POLYPOID THROMBUS IN THE LEFT AURICLE OF THE HEART.
The thrombus was dark red in color, with smooth surface.

Coagula of the fibrin of the blood in the heart form during life, and may exist for years. If the fibrin adheres to the valves in small masses these are called vegetations; if it coagulates in the heart cavities in larger bodies they are called thrombi or heart polypi.

Such thrombi are found in all the heart cavities. They form flattened masses firmly adherent to the endocardium; or rounded bodies in the spaces between the trabeculæ; or have a polypoid shape and are attached by a narrow pedicle (Figs. 323 and 324); or very rarely are globular and free in the cavity of the auricle (Fig. 325). Cardiac thrombi are most frequent in the auricular appendages and between the columnæ carneæ near the apices of the ventricles. (See Fig. 326.)

They are usually found in connection with some valvular lesion (Fig. 327), which involves a roughening of the surface, or prevents the free circulation of blood through the heart.¹

Old cardiac thrombi are firm, dry, and of a whitish color; they may soften and break down at their centres, so as to look like cysts filled with pus, or they may calcify. They are usually entirely unorganized, consisting simply of fibrin, but may become organized.

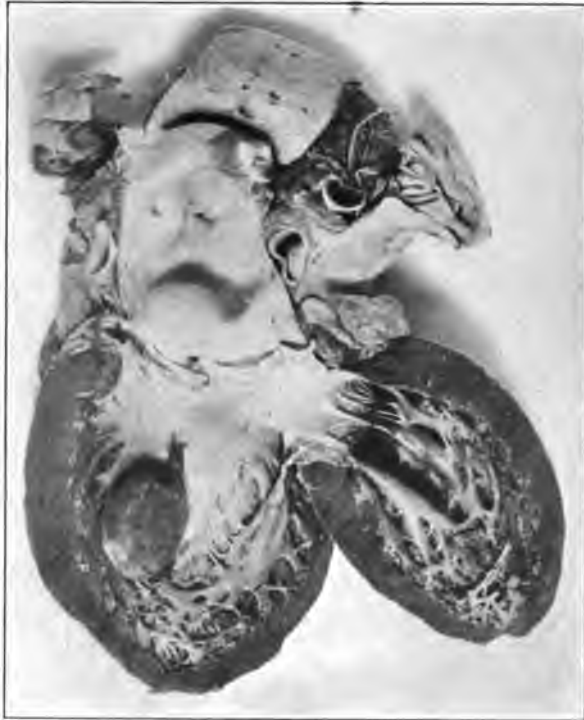

FIG. 324.—GLOBULAR THROMBUS IN THE LEFT VENTRICLE.

This thrombus was softened at its centre.

Cases are reported of organized thrombi in the auricles, the seat of tuberculous inflammation.²

Sometimes sarcomatous and carcinomatous tumors in different parts of the body are accompanied by the formation of thrombi in the heart cavities, which are composed partly of coagulated blood, partly of tissue like that of the primary tumor.

¹ For a study of cardiac thrombosis see *Martin and Rennie*, *Lancet*, 1899, ii., p. 782. See also *Welch* in *Allbutt's "System of Medicine,"* vol. vi., p. 182.

² *Kotlar*, *Ref. Cbl. f. Bak.*, Bd. xv., p. 498, 1894; also *Moser*, *l. c.*, 542.

DEGENERATION.

Albuminous Degeneration. (Parenchymatous Degeneration.)—This lesion frequently occurs in diphtheria,¹ typhoid and typhus fever, pyæmia, erysipelas, and other infectious diseases, as a result of burns, and under a variety of other conditions. It is characterized by the presence in the muscle fibres of the heart of greater or less numbers of albuminous granules of various sizes, most of them very small. They are not as refractile

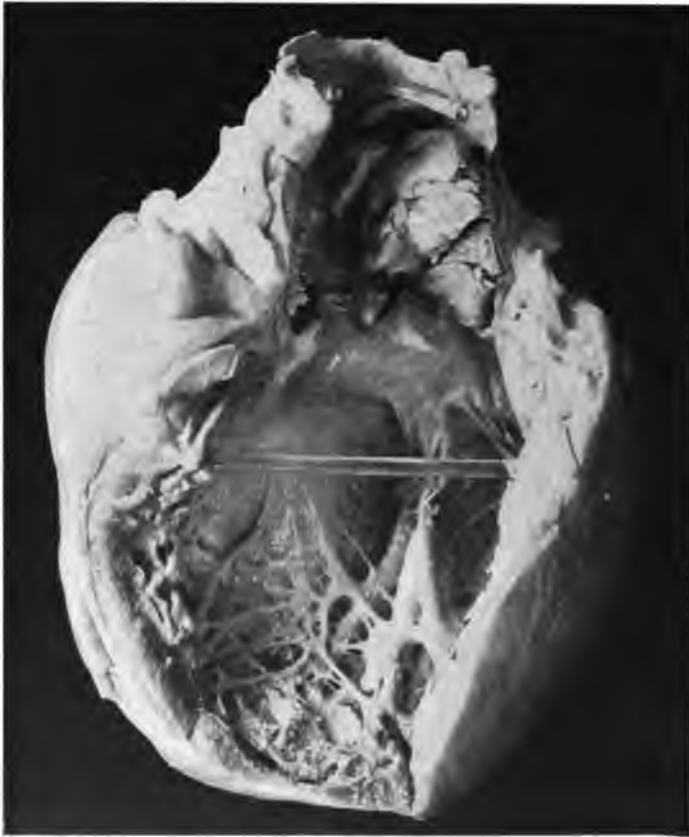


FIG. 325.—LARGE GLOBULAR THROMBUS IN THE RIGHT AURICLE OF THE HEART.

as fat droplets, and are insoluble in ether, while swelling up and becoming almost invisible under the influence of acetic acid. Sometimes they are so abundant as to conceal the striations of the fibres. The degeneration is usually quite uniformly diffused through the heart, whose walls are softer than normal and of a grayish color. This lesion may be associated with or followed by fatty degeneration.

¹ See reference, p. 282.

Fatty Degeneration of the Heart Muscle.—This consists in the transformation of portions of the muscle fibres of the heart into fat or closely allied substances,¹ which collect in the fibres in larger and smaller droplets, sometimes few in number, sometimes so abundant as almost entirely to replace or conceal the normal striations (Fig. 328). These droplets are soluble in ether, and remain unchanged on treatment with acetic acid. This degeneration is sometimes quite universal, but is more apt to occur in patches, giving the heart muscle a mottled appearance.

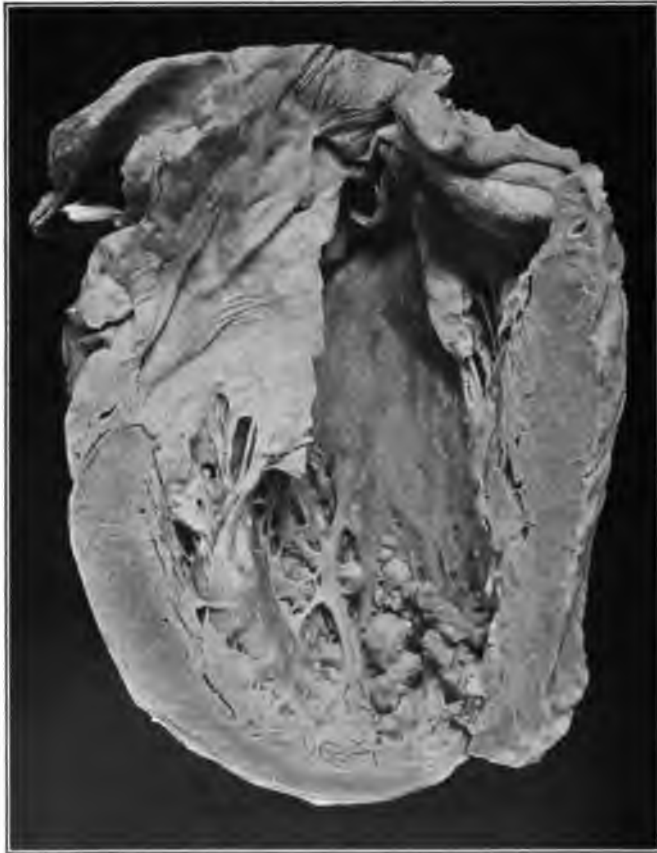


FIG. 326.—THROMBI AMONG THE TRABECULAE OF THE HEART.

This mottling may usually be best seen on the papillary muscles. The degenerated areas have a pale yellowish color, and the muscle tissue is soft and flabby; but when moderate or slight in degree the gross appearance may be little changed, and the microscopical examination be necessary for its determination. This degeneration may lead to thinning of

¹ See, in this connection, p. 40.

the walls, or to rupture of the heart, or to inability to fulfil its functions. It is not infrequently the cause of sudden death.

Fatty degeneration may be secondary to hypertrophy of the heart, to inflammation of the heart muscle, or to pericarditis; to disturbances of the circulation of the coronary arteries by inflammation, atheroma, etc. It may be due to deteriorated conditions of the blood in wasting diseases, excessive hæmorrhages, exhausting fevers, leukæmia, etc., to poisoning with phosphorus and arsenic, and to the toxins of microbial origin developed in infectious diseases, such as diphtheria, scarlatina, typhoid fever, etc.¹ It may occur in otherwise apparently healthy persons.

Fatty Degeneration of the Endocardium.—It is not uncommon to find, especially in elderly persons, fatty degeneration occurring in patches, especially on the valves, but also on the general endocardium. It may also occur in ill-nourished and anæmic individuals. Small, or even considerable, areas of fatty degeneration appear, as a rule, to be of little or no clinical significance. They are at least not inconsistent with perfect health. In these areas of fatty degeneration the connective-tissue cells are more or less completely filled with larger and smaller fat droplets.

Amyloid degeneration of the endocardium or the walls of the blood-vessels and intermuscular connective-tissue septa is a not very infrequent, but usually not very important, lesion.

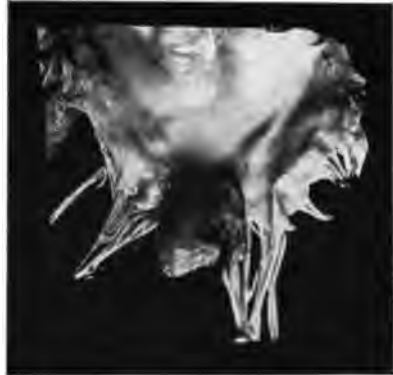

FIG. 327.—THROMBUS FORMED OVER THE ROUGHENED EDGE OF THE MITRAL VALVE.



FIG. 328.—FATTY DEGENERATION OF HEART MUSCLE.

Hyaline degeneration sometimes occurs in the blood-vessels and in the muscle fibres.

There may be **calcification** of the products of inflammation in pericarditis, or of connective-tissue membranes in chronic pericarditis; in the latter case the heart may be more or less enclosed by a calcareous shell.

The muscle fibres of the heart wall may, though rarely, become densely infiltrated with salts of lime.

Fatty Infiltration.—This lesion, which should be clearly distinguished from fatty degeneration, consists of an unusual accumulation of fat about the heart and between its muscle fibres.

¹ Consult *Fleener*, Johns Hopkins Hosp. Bull., vol. v., p. 26, 1894.

The subpericardial fat, which may be present in considerable quantity under normal conditions, may be so greatly increased in amount as to form a thick envelope enclosing nearly the entire organ. Sometimes the accumulation of fat extends into the walls of the heart, between the muscles, causing atrophy of the latter, frequently to a very great extent

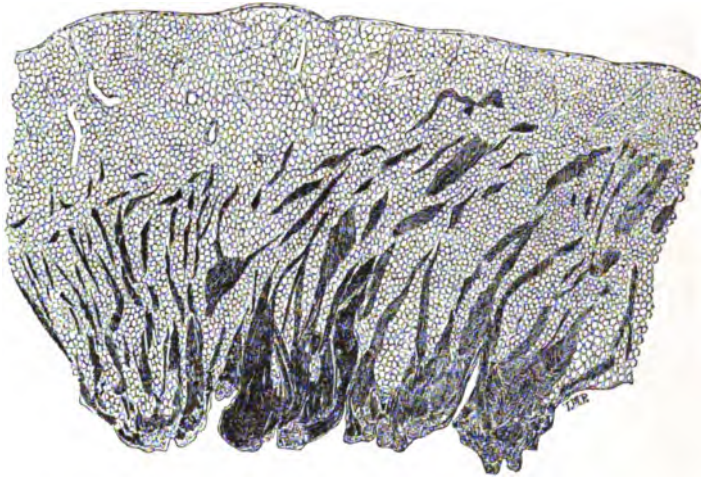


FIG. 329.—FATTY INFILTRATION OF THE HEART—LIPOMATOSIS.

The lesion is excessive, the heart muscle being to a large extent atrophied. (The fat cells are represented in the drawing, for the sake of clearness, of relatively too large size.)

(Fig. 329), so that the function of the heart is seriously interfered with. This occurs sometimes in general obesity, or as a result of chronic pericarditis, or in drunkards, or in debilitated or old persons.

SEGMENTATION AND FRAGMENTATION OF THE MYOCARDIUM.

Attention has been called by a number of observers to a condition of the heart muscle sometimes observed, it is said, in acute infectious diseases, in acute and chronic diseases of the central nervous system, and in sudden death from a variety of causes. The muscle tissue is soft, friable, opaque, and often yellowish. Examination shows a loosening of the muscle cells from one another, as if by some change in the cement substance—*segmentation*—or the fibres may be broken across—*fragmentation*. The significance of this alteration is not yet fully established, for though in some cases it is associated with degeneration and other changes in the heart muscle, in others these are not present and the alteration may be agonal, or it may in some instances be due to post-mortem changes.¹

¹ Consult *Hektoen*, *Am. Jour. Med. Sci.*, vol. cxiv., p. 555, 1897, bibl.; *MacCallum*, *Jour. Exp. Med.*, vol. iv., p. 409, 1899, bibl.

LESIONS OF THE CORONARY ARTERIES.

Lesions of the Coronary Arteries in Acute Infections.—It has recently been shown that in acute infectious diseases, typhoid fever, diphtheria, influenza, scarlatina, pyæmia, and others, the media and the intima of the coronary arteries may be involved in necrotic and hyperplastic processes which are apparently of great significance in leading to certain forms of sclerosis of these vessels.

The coronary arteries may show, on gross examination, in both larger and smaller trunks, circumscribed, yellowish white, elevated spots, from 2 to 6 mm. in diameter, or small dull white depressions of the intima. These lesions seem to begin as a localized serous infiltration in the media which undergoes necrosis. At a later period, after recovery from the acute disease, fibrous tissue may form in the media and intima, sometimes associated with calcification. Thus a patchy form of arterio-sclerosis may be developed.¹

SCLEROSIS AND THROMBOSIS.

Obliterating Endarteritis—Sclerosis—of the coronaries, which occurs frequently, is of great significance, since diminished nutrition of the heart wall may lead to local anæmia, degeneration of the muscle, fibrous hyperplasia or aneurism, etc.; but the formation of thrombi increases the gravity of the lesion. **Thrombosis** most commonly occurs in connection with degenerative or inflammatory processes in the coronary arteries. It may, however, be associated with occlusion of the coronary arteries at their orifices either through inflammation of the aorta in this region or by vegetations or clots on the aortic valves.

The blocking of one main trunk of the coronary arteries by a thrombus may cause death, but this is not always the case.

When through obliterating endarteritis, thrombosis, or embolus of a branch of the coronary arteries,² the blood supply is cut off from a circumscribed portion of the heart wall, the tissue in the affected area may undergo fatty degeneration, leading to rupture.³ Or, instead of extensive fatty degeneration, the cutting off of the blood supply from a limited region may result in necrosis—*white infarction*. These areas, grayish in color, often slightly projecting from the surface, are frequently surrounded by a red zone of hyperæmia. The nuclei of muscle

¹ For a study of this lesion of the coronary arteries see *Wiesel*, *Wiener klin. Wochenschr.*, 1906, p. 723; and *Zeits. f. Heilkunde, Abt. f. path. Anat.*, Bd. xxvii., p. 262, 1906; also *Wiesner*, *Wien. klin. Woch.*, 1906, p. 725.

² According to *Sternberg*, the right coronary artery supplies the following regions of the heart: most of the right auricle; the posterior part and most of the anterior part of the right ventricle; most of the interauricular and interventricular septa; the posterior part of the left ventricle and the posterior papillary muscles. The remainder of the heart is supplied by the left coronary artery.

While there are superficial anastomoses between the larger trunks of the coronary arteries, their branches do not communicate after they enter the heart muscle. For a study of coronary arteries see the monograph of *Jamin and Merkel*, "Die Koronararterien des menschl. Herzens," 1907.

³ Through the Thebesian vessels sufficient nutriment may reach the myocardium to maintain the muscle for a time, even with considerable lesion of the coronary arteries. See *Pratt*, *American Journal of Physiology*, vol. i., p. 86, 1898. Also *Baumgarten*, *ibid.*, vol. ii., p. 243, 1899. For a study of the results of occlusion of one or more of the coronary arteries see *Porter*, *Jour. of Physiol.*, vol. xv., p. 121, 1898; also *Jour. Exp. Med.*, vol. i., p. 46, 1896.

and fibrous tissue fail to stain, the muscle cells become necrotic, lose their striation and degenerate, and may be absorbed or gradually replaced by fibrous tissue. When larger areas are involved, the muscle fibres may break down into a granular detritus and the connective tissue about them suffer degeneration or necrosis, so that the whole affected area may be soft and yellowish white or grayish in color. If, as not infrequently occurs, there is considerable extravasation of blood, the degenerated area may be of a dark red color.¹ Under these conditions the heart wall may rupture, or acute inflammatory processes may occur, or the degenerated muscle tissue may be gradually absorbed and replaced by granulation tissue formed from the surrounding fibrous tissue and blood-vessels. This gradually grows dense, shrinks, and assumes the characters of cicatricial tissue.

This may occur in any part of the heart wall or in the papillary muscles, but is most common in the region supplied by the left coronary artery; that is, in the interventricular septum and the anterior wall of the left ventricle near the apex. Thrombosis of the coronary arteries is more frequent than embolism and more commonly leads to infarction. When the heart wall is involved the new-formed connective tissue may yield to the blood pressure from within and aneurism of the heart be formed.

Impaired nutrition of a portion of the heart wall as the result of narrowing or obliteration of the coronary arteries or their branches, whether it lead to such extreme lesions as those just described, or to fatty degeneration, or to atrophy of the muscle cells with a production of new connective tissue, is of great significance, and it may be the dominant factor in many cases of sudden death.

Embolism of the coronary arteries is much less common than thrombosis and may be followed by similar lesions of the myocardium. Infective emboli are frequent excitants of suppurative lesions of the myocardium.

INFLAMMATION.

MYOCARDITIS.—The inflammatory changes in the walls of the heart involve primarily the interstitial tissue and blood-vessels, the muscle fibres being secondarily affected by atrophic and degenerative changes.

Interstitial myocarditis may be acute and suppurative, or chronic with the formation of new connective tissue.

Acute suppurative myocarditis may be diffuse, infiltrating the wall of the heart with pus. This may occur as a complication of infectious diseases, such as scarlatina, diphtheria, typhoid fever, gonorrhœa,² or may be associated with ulcerative endocarditis.³

More frequently the suppurative inflammation is circumscribed, resulting in abscesses. These occur with pyæmia, mycotic ulcerative

¹ This condition of the heart is often called "myomalacia."

² For a consideration of gonorrhœal myocarditis consult *Councilman*, *Am. Jour. Med. Sci.*, vol. cvi., p. 277, 1893.

³ For a special study of this mode of origin see *Josserand* and *Bonnet*, *Arch. de méd. exp. et d. Path. anat.*, t. xi., p. 570, 1899.

endocarditis, and other infectious diseases. They are of different sizes and either single or multiple. They are produced by the lodgment of infectious emboli in small vessels. There is at first necrosis of the muscle fibres near the bacterial mass (Fig. 330), followed by local suppuration and the formation of abscess. The contents of the abscesses consist of pus, broken-down muscle tissue, and bacteria. These abscesses may open into the pericardial sac and set up a purulent pericarditis; or into a heart cavity, giving rise to thrombi in the heart and infective emboli in different parts of the body; or the wall of the heart is weakened by the abscess so that it ruptures, or an aneurismal sac is formed; or an abscess in the interventricular septum may establish an opening between the ventricles; or the suppurative process may extend upward and form an

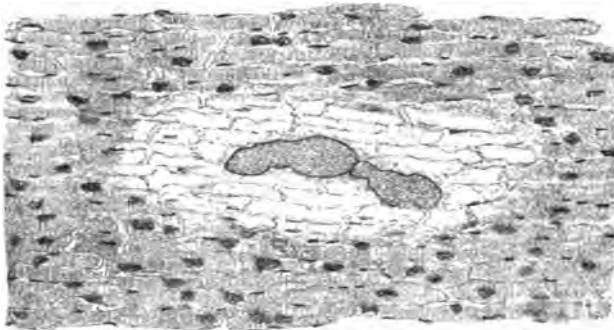


FIG. 330.—BACTERIAL EMBOLUS IN HEART MUSCLE.

The bacteria have multiplied since lodgment in the small vessel, so that the latter is widely distended. The surrounding muscle is necrotic.

abscess in the connective tissue at the base of the heart. *Streptococcus* and *Staphylococcus pyogenes* are the most common excitants.

In rare cases the patients recover, the contents of the abscesses become dry and hard and enclosed by a wall of fibrous tissue, or the contents may be absorbed and the whole replaced by fibrous tissue.¹

Chronic interstitial myocarditis may be associated with chronic pericarditis or endocarditis; it may be secondary to damage to the muscle by bacterial or other toxins, but in a large proportion of cases it occurs in connection with lesions of the coronary arteries.

Lesions of the coronary arteries which interfere with the blood supply of the heart muscle, such as obliterating endarteritis with or without thrombosis or embolism, may lead to degeneration or necrosis of the muscle and to a new formation of fibrous tissue which is in reality a replacement hyperplasia. Thus either in small foci or over more diffuse areas, patches of fibrous tissue may be formed as the muscle disappears (Figs. 330 and 331).

If the occlusion of the coronaries has led to infarctions of the heart,

¹ For study of experimental myocarditis, *Fleischer and Loeb*, *Arch. Int. Med.* iii., 78, 1909.

then also, as we have seen above, new fibrous tissue may form, replacing the muscle.

Local degenerative processes and necrosis in the muscle tissue of the

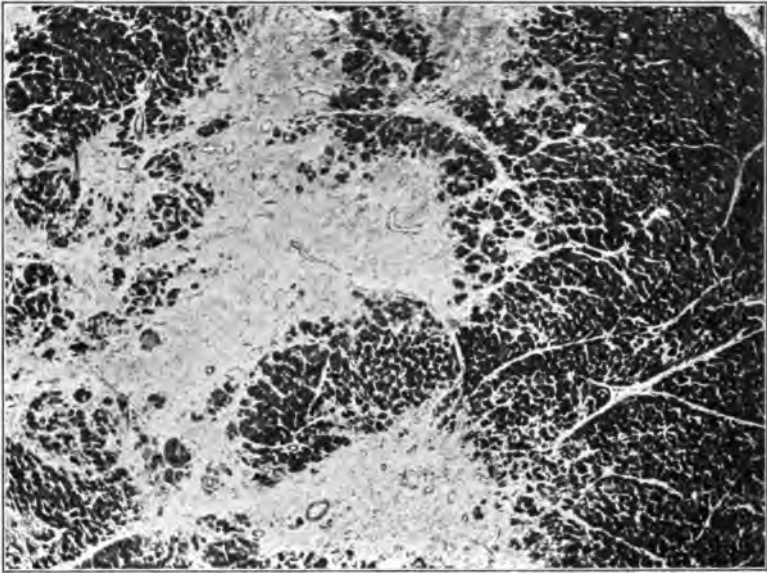


FIG. 331.—CHRONIC INTERSTITIAL MYOCARDITIS (Fibrous Replacement Hyperplasia).

heart may be associated with acute infectious diseases, especially with diphtheria, typhoid fever, and scarlatina. In such areas of damaged muscle new connective tissue may form. This is at first cellular, later

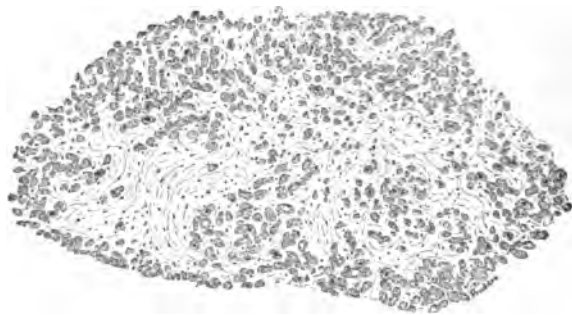


FIG. 332.—CHRONIC INTERSTITIAL MYOCARDITIS.

Showing transverse section of a portion of a papillary muscle. The fibrous tissue is dense and the muscle fibres are atrophied.

dense and cicatricial in character. As the result of this replacement hyperplasia, patches of fibrous tissue may be scattered through the myocardium. Similar lesions may be induced experimentally in animals

by the injection of bacterial toxins.¹ Calcification of the muscle fibres has been observed in connection with the degenerative processes due to the action of toxins.²

Chronic interstitial myocarditis, whether diffuse or focal, leads to a weakening of the heart wall. This may be slight or excessive. Hypertrophy of the muscle may follow or be associated with it; degeneration of the remaining muscle may occur; or the heart wall may yield to the internal pressure and pouch, forming aneurism of the heart. Thrombi

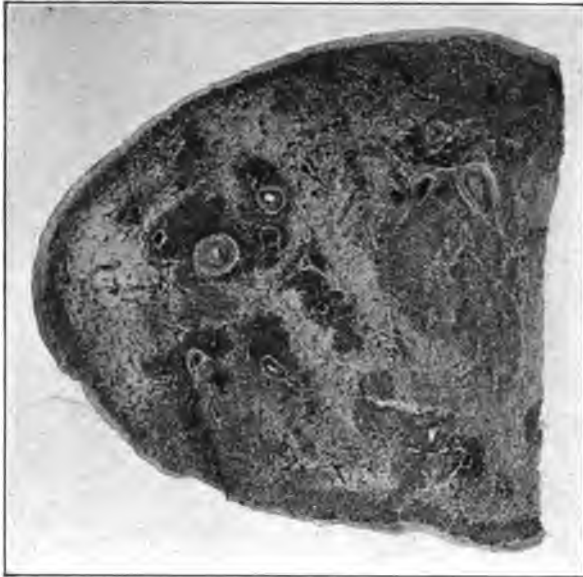


FIG. 333.—CHRONIC INTERSTITIAL MYOCARDITIS.

Showing cross section of a papillary muscle. The muscle tissue is least involved about the vessel and near the surface.

may under these conditions form in the dilated cavities. Lack of rhythm in the heart-beats or cardiac pain—angina pectoris—may result from myocarditis.

It is believed by most modern observers that the new connective tissue which develops in the heart in connection with atrophy of the muscle fibres, as a result of impaired nutrition due to a narrowing of the lumen of the coronary arteries or due to other causes, is not in the stricter sense inflammatory in its nature, but is rather a *fibrous hyperplasia*, the new-formed connective tissue forming secondarily, to replace the muscle fibres which have atrophied. Nevertheless we still for con-

¹ *Fleener*, Johns Hopkins Hosp. Rep., vol. vi., p. 259, 1897.

Degeneration of muscle fibres and the formation of new connective tissue has been induced by *Pearce* in the hearts of rabbits by the injection of adrenalin into the ear vein. See *Pearce*, Jour. Exp. Med., vol. viii., p. 400, 1906.

² *Cullen*, Johns Hopkins Hosp. Bull., vol. xvii., p. 267, 1906.

venience call the lesion myocarditis, thus implying inflammation. It is interesting in this connection to note that under these conditions the muscle fibres immediately beneath the endocardium and close around the blood-vessels where the nutritive supply is most abundant are often not atrophied, nor is the growth of connective tissue marked (Fig. 333).

Tuberculous myocarditis is of occasional occurrence and may be associated with tuberculosis of the pericardium or endocardium.¹



FIG. 334.—ULCERATIVE ENDOCARDITIS.

The valve and adjacent portion of the heart wall are ulcerated, and a ragged clot has formed upon the roughened surfaces.

Syphilitic Myocarditis is accompanied by the growth of connective tissue or granulation tissue in the wall of the heart between the muscle fibres or in the walls of the blood-vessels. The pericardium and endocardium may also be thickened, and pericardial adhesions may be formed. Gummata of the heart are of rare occurrence.²

ENDOCARDITIS.—The endocardium is a connective-tissue membrane, containing but few blood-vessels, which lines the cavities of the heart and forms its valves. Its inner surface is covered with a layer of endothelial cells. The connective-tissue cells and basement substance are principally concerned in the inflammatory processes. The new tissue thus produced is prone to degeneration and calcification. The roughening of

¹ Consult Moser, "Tuberculosis of the Heart," Rep. of the Bost. City Hosp., 11th series, p. 194, 1900. Also Anders, Jour. Am. Med. Assn., vol. xxxix., p. 1081, 1902. Also Raviart, Arch. de méd. exp., t. xviii., p. 141, 1906, bibl.

² See Loomis, Am. Jour. Med. Sciences, vol. cx., p. 389, 1895, bibl. Also Adler, Trans. Assn Am. Phys., vol. xiii., p. 73, 1898, bibl.

the endocardium due to the inflammation often leads to the formation of fibrin on the affected surface.

The endocardium which forms the valves is that which is most frequently involved, but the other portions of it are by no means exempt. In adult life it is the endocardium of the left ventricle, and especially the aortic and mitral valves, which are most commonly affected.

In foetal life it is the endocardium of the right heart which is usually affected.

1. Simple Acute Endocarditis.—This is frequent with rheumatism, but may occur under other conditions. It may occur in a heart previously healthy, or in one already the seat of chronic endocarditis.

In some cases the only lesion is a simple swelling of the valves. These

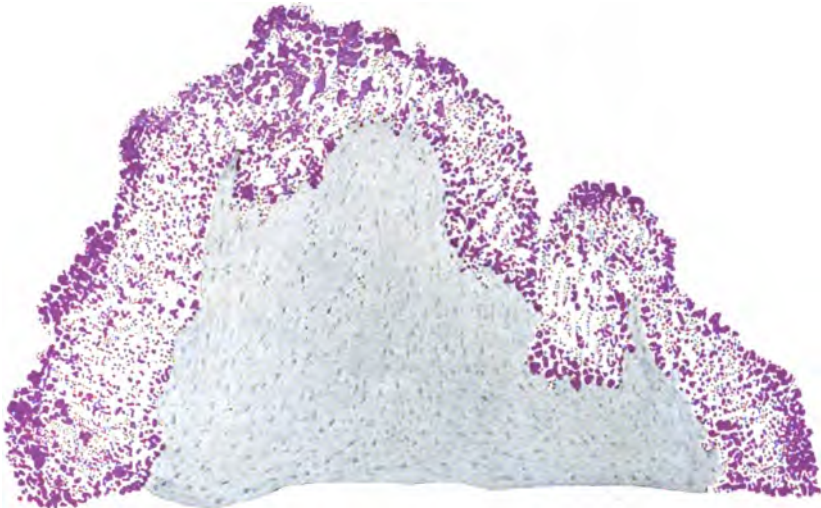


FIG. 335.—MASSES OF BACTERIA IN VEGETATION ON THE HEART VALVE IN INFECTIVE (MALIGNANT) ENDocarditis.

are thick and succulent, but their surfaces remain smooth. The basement substance is swollen, and there is a moderate production of new connective-tissue cells. In other cases the growth of connective-tissue cells is more marked, the basement substance is split up, and little cellular fungous masses of connective tissue, called "vegetations," project from the free surface of the endocardium. This is sometimes called *verrucous endocarditis*. On these roughened surfaces the fibrin of the blood may be deposited, and thus vegetations of considerable size may be formed (see Fig. 334). In still other cases the cell growth, while in some places forming vegetations, in other places degenerates, and thus portions of the valves are destroyed. This is *simple acute ulcerative endocarditis*. In some cases of this disease the patients recover and the valves seem to return to a normal condition; in other cases the valves are left permanently damaged; and in still others chronic endocarditis follows the acute form.

2. **Mycotic or Malignant Endocarditis (Malignant Ulcerative Endocarditis).**—The direct excitants of simple acute endocarditis of the forms described above are unknown, but in a considerable number of cases of acute endocarditis bacteria have been found in and about the vegetations, and proved, by careful experiments, to stand in a causative relation to the lesion.

Those cases of acute endocarditis in which the lesions are induced by the direct action of bacteria are called *mycotic* or *malignant endocarditis*; or, since the new-formed as well as the old tissue about the bacteria is



FIG. 336.—CHRONIC ENDOCARDITIS.
Section showing thickening of the cusp of the aortic valve.

apt to become necrotic and thus lead to larger or smaller losses of substance, the lesion is often called *malignant ulcerative endocarditis*. Cases of multiple aneurism in connection with mycotic endocarditis have been reported. Various species of bacteria may be excitants of malignant endocarditis (Fig. 335).

It is most commonly induced by *Staphylococcus pyogenes aureus* and *Streptococcus pyogenes*. *Diplococcus pneumoniae*,¹ *B. typhosus*, *B.*

¹ For a résumé of pneumococcus endocarditis see Preble, *Am. Jour. Med. Sci.*, vol. cxxviii., p. 782, 1904.

tuberculosis, *B. anthracis*, *Micrococcus gonorrhœæ*,¹ and others have been occasionally found.²

It has, furthermore, been found that a lesion or injury of the endocardium, either on the heart valves or elsewhere, predisposes to the lodg-

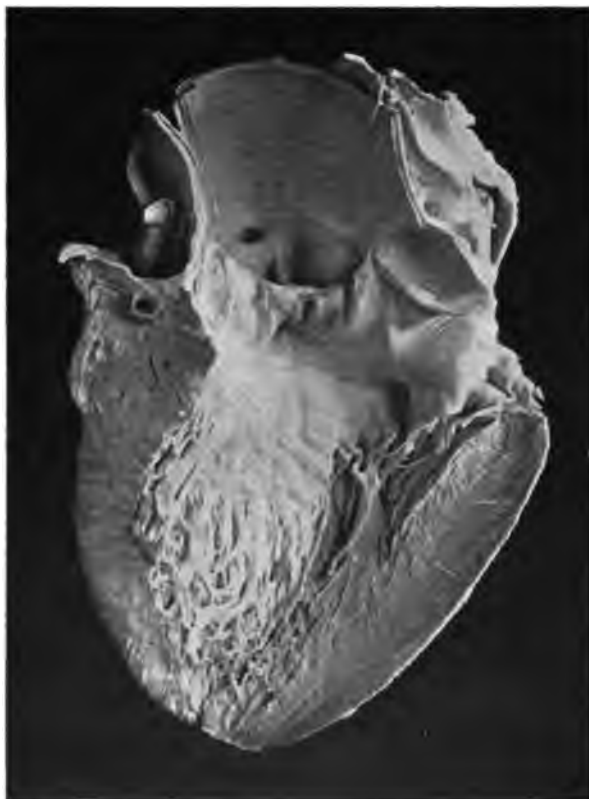

FIG. 337.—CHRONIC ENDOCARDITIS.
Showing thickening and coalescence of two of the aortic cusps.

ment and growth upon it of pathogenic bacteria when once they have gained access to the circulating blood.

Mycotic endocarditis is frequently a secondary complicating lesion, but may occur as a primary disease. It is most apt to be associated with the acute infectious diseases, and may be one of the local manifestations of pyæmia.³

In some cases there is a formation of new tissue in the form of organ-

¹ For ref. and bibl. of gonorrhœal endocarditis see *Lartigau*, *Am. Jour. Med. Sci.*, vol. cxxi., p. 52, 1901. For later summary *Külbs*, *Wiener klin. Woch.*, Jan. 3, 1907, p. 11.

² For a general consideration of the pathology of infective endocarditis see *Washbourn and others*, *Brit. Med. Jour.*, Nov. 4th, p. 1269, 1899. For a study of the meningococcus in acute ulcerative endocarditis see *Warfield*, *Bull. Univ. Penna.*, vol. xvi., p. 180, 1903.

³ For a study of local predisposing factors in malignant endocarditis see *Prudden*, *Am. Jour. Med. Sci.*, vol. xciii., p. 55, 1887.

ized vegetations on the valves or general endocardium; in other cases necrosis either of the new-formed or the old tissue is the most marked

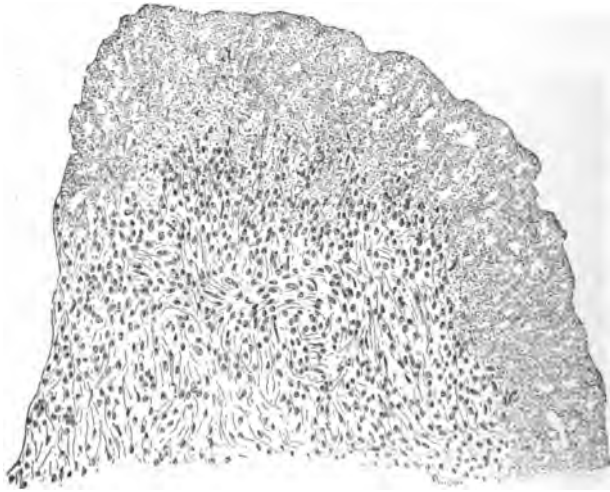


FIG. 338.—VEGETATION ON AORTIC VALVE IN ENDOCARDITIS.
Showing granular thrombus over the surface.



FIG. 339.—CHRONIC ENDOCARDITIS.
Showing fibrous "vegetation" on the mitral valve. With a large blood clot formed upon it.

eature. Thrombi are apt to form on the affected surfaces and often largely make up the so-called vegetations. The mitral and aortic valves are frequently the seat of the lesion, but it may occur elsewhere.

Detachment of bacteria containing fragments of the vegetations or clots may give rise to single or multiple infectious emboli and abscesses in various parts of the body, such as the spleen, kidneys, brain, skin, heart wall, etc. Bacteria similar to those in the heart lesion may be found in these secondary abscesses.

It is probable that abscesses in ulcerative endocarditis do not always arise from cardiac emboli, but may precede the heart lesion.¹

3. Chronic endocarditis may succeed acute endocarditis, or the inflammation may be chronic from the outset. It affects most frequently the aortic and mitral valves, and the endocardium of the left auricle and ventricle, similar changes in the right side of the heart being much less frequent.

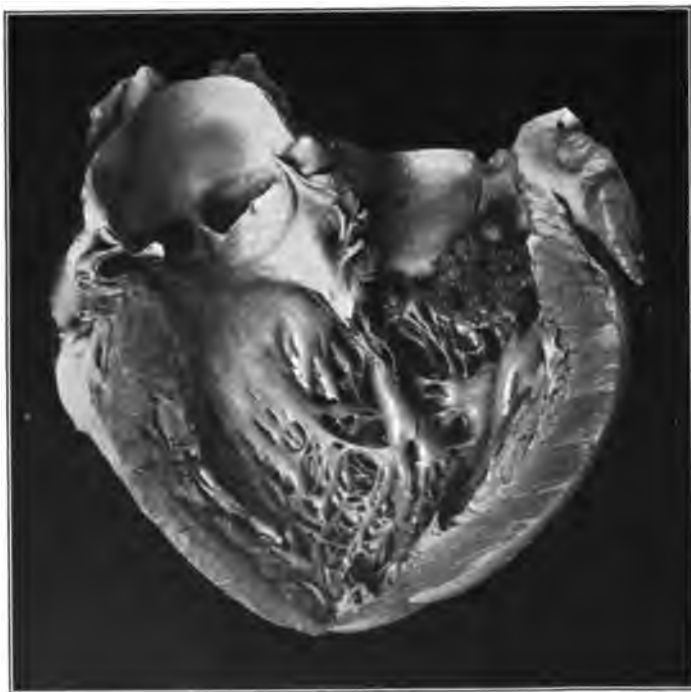

FIG. 340.—CHRONIC ENDOCARDITIS (VERRUCOUS ENDOCARDITIS).

The new papillary growths of connective tissue involve the mitral valve and obstruct the mitral orifice.

There are two main anatomical varieties of chronic endocarditis, which may occur separately or together:

1. The endocardium is thick and dense, its surfaces are smooth or covered with small, hard vegetations or ridges (Figs. 336 and 337); it is often infiltrated with the salts of lime.

2. There is a growth of connective-tissue cells in the endocardium, with a splitting-up of the basement substance. Some of the new cells

¹ For a study of chronic infectious endocarditis, see *Billings*, *Arch. Int. Med.*, iv., 409, 1909; for studies on bacteria in blood in "subacute" endocarditis, *Libman*, *Am. Jour. Med. Sci.*, cxl., 516, 1910.

continue to live, others degenerate. By the combination of such a cell growth and destruction the endocardium is in some places destroyed, in others changed into projecting vegetations (see Fig. 338). Fibrin is deposited on the roughened surfaces (Figs. 339 and 340). After a time the condition may be further complicated by the shrinkage and deposition of the salts of lime in the new tissue and in the endocardium (Fig. 338). All these changes may extend to the wall of the heart beneath the endocardium. As the result of the new formation of connective tissue the cusps of the valves may be shortened or grown together or adherent to the heart wall. The chordæ tendineæ may be shortened and the papillary muscle fibres shortened and distorted.

The most important result of chronic endocarditis is its effect on the heart valves, producing insufficiency and stenosis (Figs. 341 and 342).

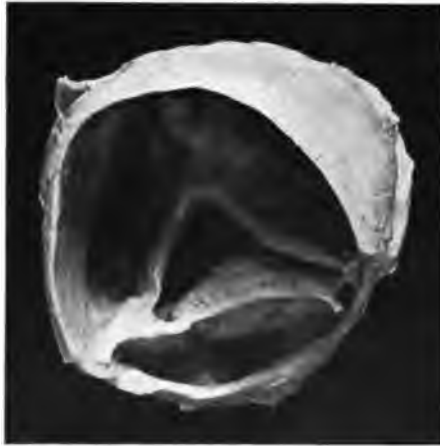

FIG. 341.—STENOSIS OF THE AORTIC VALVES.
In chronic endocarditis.

The changes in the valves are followed by changes in the walls and cavities of the heart, and disturbances of the circulation throughout the body (see p. 552).

4. Chronic Ulcerative Endocarditis.—Large ulcers or perforations of the valves may be formed in chronic endocarditis, upon which clots may form, so that in gross appearance a great similarity exists between this and malignant ulcerative endocarditis, particularly if the latter have been engrafted upon an already chronically diseased endocardium. The microscopical and biological examinations must usually be resorted to in order to determine the exact significance of the lesion.

5. Tuberculous Endocarditis may occur in connection with tuberculous pericarditis or general miliary tuberculosis. The tubercles may be small and single, or grouped in masses, and show the usual degenerative changes.¹

¹ See reference, *Moser*, p. 542; also *Etienne*, *Arch. de méd. exp.*, vol. x., p. 146, 1898.

STOKES-ADAMS' DISEASE.¹

In this disease there is a slow pulse, sometimes accompanied by pulsation in the veins of the neck, which is more frequent than the beat of the ventricles. This is associated with attacks of syncope with a very slow pulse rate. This lack of rhythm in the beat of the auricles and ventricles is sometimes considerable, the former sometimes contracting three or four times as often as the latter. This condition, called "heart-block," is attributable to interference with the muscular connection which has been shown to exist between the auricles and ventricles.

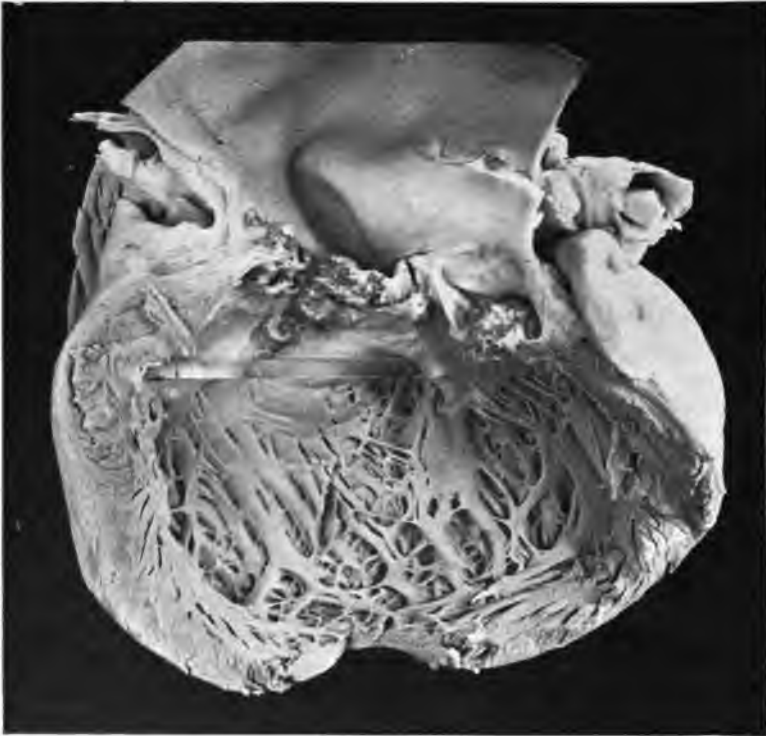


FIG. 342.—CHRONIC ENDOCARDITIS WITH CALCIFICATION OF THE THICKENED VALVES.

It was formerly believed that the impulse which causes the walls of the chambers of the heart to contract arises in the automatic heart ganglia, and is conveyed to the muscle cells by nerves. The more modern view is that the impulse arises in the musculature of the great veins and is propagated to the walls of the heart chambers through their musculature.²

¹ For a study of this condition see *Erlanger*, *Jour. Exp. Med.*, vol. vii., p. 676, 1905; also *ibid.*, vol. viii., p. 8, 1906.

² For a summary with bibliography of the cause of the beat see *Howell*, "Harvey Lectures," 1905-1906.

His has shown that in mammals there is a narrow band of muscle joining the septa of the auricles and ventricles. This is called the "auriculo-ventricular bundle of His,"¹ and it is important in regulating the heart beats.

In many cases of Stokes-Adams' disease, autopsy has failed to reveal lesions directly involving the region of the His bundle, but in others lesions have been found. In one case a small mural tumor was discovered; in another a gumma;² in another³ there was a patch of sclerosis and atheroma involving the bundle; in still other cases lesions have been found.⁴ The experiments on animals in which heart-block has been induced by injuries of the wall near or involving the His bundle, together with the observed local lesion, show the importance of careful examination of this region in such cases.

Other forms of irregular heart action, palpitation, arrhythmia, tachycardia (rapid heart), bradycardia (slow heart) are so frequently unassociated with obvious lesions that we refer for their consideration to treatises on clinical pathology.⁵

HYPERTROPHY AND DILATATION OF THE HEART.

We have seen in an earlier chapter that the circulation of the blood may be impaired by deficient cardiac power, such as may result from innutrition of the muscle from general causes, or from obstruction of the coronary arteries, from degenerative changes in the muscle, faulty innervation, the action of poisons, etc.

But with unimpaired vigor of the heart muscle the circulation may be interfered with by many abnormal conditions. If the orifices of the heart are narrowed the blood is forced through them with difficulty; if the valves are defective the blood regurgitates. If there be obstruction in the vascular system the flow of blood is retarded.

Under these and many other conditions an unusual amount of work is thrown upon the heart muscle, which may adapt itself to its unusual tasks by a hypertrophy which more or less fully compensates for the difficulties of the circulation.⁶ This is compensatory hypertrophy of the heart. The portion of the heart muscle especially involved in hyper-

¹ See *Erlanger*, ref. above, for more detailed description of the His bundle and ref. to *His* and *Retzer*.

The following summary descriptive of the bundle is given by *Erlanger* after *Retzer*: "The auriculo-ventricular bundle runs posteriorly in the septum of the ventricles about 10 mm. below the posterior leaflet of the aortic semilunar valves; with a gentle curve it passes posteriorly just over the upper edge of the muscular septum and sends its fibres into the musculature of the right auricle and of the auricular valves. . . . In the heart of the adult the bundle is 18 mm. long, 2.5 mm. wide, and 1.5 mm. thick."

See also for description of the bundle, with illustrations, *Keith and Flack*, *Lancet*, 1906, vol. ii., p. 359.

² See *Ashton, Norris, and Lavenson*, *Am. Jour. Med. Sci.*, vol. cxxxiii., p. 28, 1907.

³ See *Stengel*, *Amer. Jour. Med. Sciences*, vol. cxxx., p. 1083, 1905.

⁴ See *Schmoll*, *Deutsch. Arch. f. klin. Med.*, Bd. lxxxvii., p. 554, 1906.

⁵ For an illuminating review of cardiac arrhythmia see *Meltzer*, *N. Y. Med. Record*, May 22, 1909; also see discussion in *Verh. Deutsch. Path. Ges.*, Tagung. xiv., 3, 1910.

⁶ For a suggestive study of cardiac hypertrophy as an adaptive process see *Welch*, "Adaptation in Pathological Processes," *Trans. Congr. of American Phys. and Surg.*, vol. iv., 1897.

For a comprehensive résumé of the normal and pathological physiology of the heart and its morphological and functional lesions see *Heinz*, "Handbuch d. exp. Path. und Pharmakol.," 1905, Bd. i.

trophy is determined by the location of the obstruction to the circulation. The hypertrophy is usually associated with dilatation of one or more of the heart cavities.

Hypertrophy may involve the walls of one or more or all the cavities of the heart. While the wall of a ventricle is thickened, its cavity may retain its normal size—*simple hypertrophy*; or be dilated—*excentric hypertrophy*; or it may be contracted—*concentric hypertrophy*. Simple hypertrophy is not common, but may occur in connection with the atrophied kidneys of chronic diffuse nephritis.

Care should always be exercised in judging of cardiac hypertrophy, for a firmly contracted heart seems to have a small cavity and thick walls

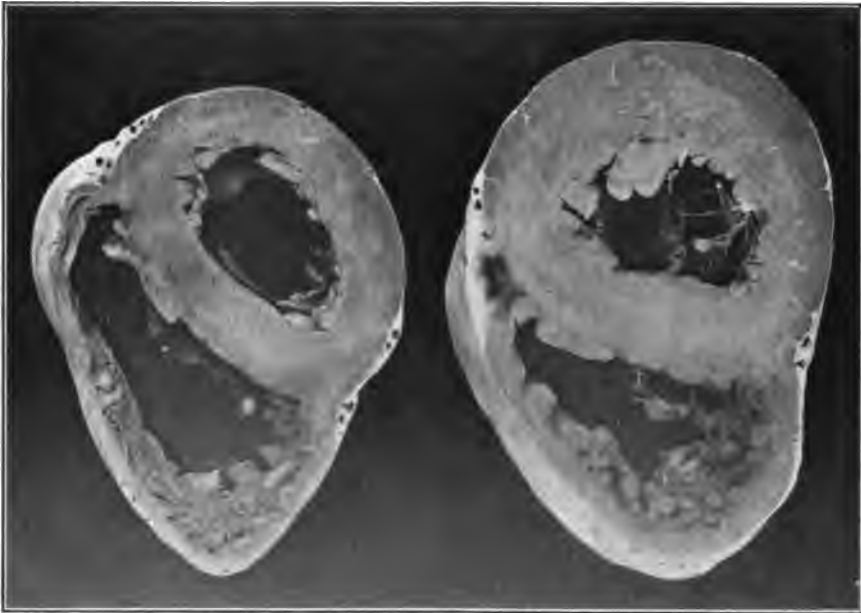

FIG. 343.—CROSS-SECTIONS OF HEARTS SHOWING HYPERTROPHY.

The heart at the left is normal. The heart at the right shows hypertrophy (concentric) with contraction of the left ventricle.

(Fig. 343). It should also be borne in mind that an increase in the amount of fat in and about the heart may make the organ appear larger, when there may be actually a considerable decrease in the amount of muscle tissue. The existence of such a condition as concentric hypertrophy is denied by some authors. Excentric hypertrophy is the most common form. The muscle tissue in hypertrophied hearts is firmer and denser than normal, and is apt to have a darker color. Fatty degeneration may, however, be associated with it, giving the walls a lighter appearance. It is probable that the increase of tissue in the hypertrophied heart wall is the result of increase both in size and number of the muscle fibres.

Hypertrophy of both ventricles increases both the length and breadth of the heart. Hypertrophy of the left ventricle (alone) increases its length. The apex is then lower and farther to the left than usual. Hypertrophy of the right ventricle (alone) increases the breadth of the heart toward the right side; but sometimes the right edge of the heart retains its normal situation and the apex is displaced to the left. With large hypertrophy of both ventricles, the base of the heart may sink, so that its long axis approaches a horizontal direction.

Hypertrophied hearts may weigh from forty to fifty ounces, or even more.

Hypertrophy of the heart may depend upon a variety of conditions which increase its work.

LESIONS OF THE HEART VALVES IN RELATION TO HYPERTROPHY AND DILATATION.

As the result of acute infective processes in the endocardium the heart valves may undergo numerous changes. These are most frequent in connection with acute articular rheumatism, various forms of septicæmia, typhoid fever, scarlatina, gonorrhœa, etc. We have already seen in detail the alterations induced in infections of the endocardium. As the result of these and other processes the heart valves suffer ulceration, thrombosis, adhesions, distortions; the chordæ tendinæ may be shortened or the papillary muscles deformed; while the orifices may be less exactly controlled than normally as the result of myocardial lesions. Thus it frequently occurs that the orifices of the heart are too narrow or the valves close imperfectly, or both conditions are present together.

The narrowing of the orifices is called *stenosis*; the failure of the valves to close properly is called *insufficiency*.

AORTIC INSUFFICIENCY AND STENOSIS.

In *insufficiency of the aortic valves* the blood which has been sent forward into the aorta by the contraction of the left ventricle in part returns to the ventricle in the following diastole through the incompletely closed aortic orifice. This, unless the ventricle wall adapts itself to the changed conditions, may lead to an interference with the entrance of blood from the left auricle and so to pulmonary congestion. Under these conditions, then, of aortic insufficiency more work is thrown upon the muscle of the left ventricle, which may undergo compensatory hypertrophy. With this there is usually associated a dilatation of the ventricle cavity on account of the larger amount of blood which it is forced to accommodate.

In *stenosis of the aortic valves* there is obstruction to the passage of the blood into the aorta, and the muscle of the left ventricle is forced to do so much extra work that the wall of the ventricle becomes hypertrophied. This hypertrophy may be followed by dilatation of the ventricle through a subsequent weakening of the wall.

MITRAL INSUFFICIENCY AND STENOSIS.

In *mitral insufficiency* a part of the blood during systole of the left ventricle is forced back into the auricle. As the result of this the auricle is forced to do more work; its wall undergoes more or less hypertrophy and dilatation. Under these conditions the blood cannot properly flow from the pulmonary veins, which become congested. This in turn brings more work upon the right ventricle, which undergoes hypertrophy. But when the diastole of the left ventricle occurs, blood flows into it from the auricle and the pulmonary system under increased pressure, while it is forced to do more work in systole to compensate for the backward current through the faulty mitral valve. Thus the wall of the left ventricle becomes hypertrophied and at the same time becomes dilated from the increased amount of blood which it is forced to accommodate.

In *mitral stenosis* the flow of blood from the left auricle into the left ventricle is obstructed so that more work must be done by the muscle of the wall of the auricle. This undergoes a certain amount of hypertrophy and also of dilatation on account of the increased pressure in the pulmonary veins. For the pulmonary vessels become overfilled owing to the resistance which the blood encounters in the obstructed mitral orifice. The heightened pressure of the pulmonary vessels is felt in the right ventricle, which must do more work, and undergoes hypertrophy.

As to the left ventricle, the wall may remain unaffected in uncomplicated mitral stenosis or may suffer degenerative changes or atrophy if the right heart fails to compensate properly for the obstructive lesion.

INSUFFICIENCY AND STENOSIS IN THE RIGHT HEART.

We need not trace these lesions of the right side of the heart in detail, for the changes are quite similar in principle to those which we have just considered. But they are by no means as frequent or as pronounced, nor is the compensatory mechanism as perfect as in the left heart. Lesions of the valves of the right heart are less frequent than those of the left. Tricuspid lesions infrequently develop in adult life. Lesions of the pulmonary valves developing in the adult are rare. During foetal life, however, lesions of both of these valves are not infrequent. Congenital heart lesions, such as stenosis of the pulmonary artery, may lead to hypertrophy of the right ventricle.

While we have thus briefly touched upon some of the more common and obvious of the conditions associated with the lesions of one or the other of the heart valves, there are many intricacies and variations for the details of which we must refer to special works on the subject.¹ But we should remember that there are frequent combinations of valvular lesions on both sides of the heart. Thus simple mitral insufficiency is common, while uncomplicated mitral stenosis or aortic insufficiency or stenosis is less frequent than are combinations of insufficiency with stenosis in either the mitral or aortic valves.

¹ See *Krehl*, "Clinical Pathology," Hewlett's Eng. Trans., 1905.

SUMMARY OF CONDITIONS LEADING TO HYPERTROPHY OF THE VENTRICLES.**Hypertrophy of the Right Ventricle.**

This occurs especially under conditions which lead to increased resistance to the flow of blood in the pulmonary vessels, for example, in interstitial pneumonia, pulmonary tuberculosis, emphysema with chronic bronchitis and pleuritis, rarely with sclerosis of the pulmonary artery or incompetence or stenosis of the pulmonary or tricuspid valves. But lesions of the mitral valve or lesions of the wall of the left ventricle interfering with the pulmonary circulation may indirectly lead to hypertrophy of the right ventricle.

Hypertrophy of the Left Ventricle.

Aside from the valvular lesions already considered, hypertrophy of the left ventricle may arise from stenosis of the aorta, from an increased resistance of the flow of blood through the peripheral arteries as in various forms of obliterating endarteritis or arterio-sclerosis, and from certain forms of diffuse nephritis.¹

Arteries whose walls are stiffened from new-formed tissue or from degeneration or calcareous infiltration, or whose lumina are obstructed through obliterating endarteritis, do not so readily dilate as in normal conditions, nor do they promptly and readily recover when the heart pressure is reduced in diastole. Thus it is that, since the elasticity of the arteries is an important factor in the maintenance of the circulation, more work in the conditions above indicated is thrown upon the heart, which may lead to its hypertrophy.

The relationship of arterio-sclerosis to hypertrophy of the heart is most complex and the results of recorded observations conflicting. One of the chief reasons for this uncertainty is doubtless the crude methods of determination of both the degree and seat of the hypertrophy and the character and grade of the arterial lesion. The common method of determining hypertrophy of the heart by simple inspection or by measurement of the thickness of the heart wall is essentially faulty because no account is taken of the degree of contraction of the muscle wall of the heart which makes the greatest difference in its thickness. Only by the method of W. Müller, in which, after the removal of the fat about the heart, the muscle wall of each cavity is separated and weighed and the weight of each part compared with the weight of the whole heart, and its proportional weight to that of the whole body, or by some similar method, can exact data be obtained.²

Furthermore, the full significance of arterio-sclerosis can be determined only by the more exact methods suggested by Thoma.³

¹ For an experimental study of hypertrophy of the left ventricle with diminished kidney structure see *Pässler* and *Heineke*, ref. foot-note, p. 768.

² See *Müller*, "Die Massenverhältnisse des menschl. Herzens," 1883; also summary by *Hasenfeld*, *Deutsch. Arch. f. klin. Med.*, Bd. lix., p. 205, 1897; and *Hirsch*, *Deutsch. Arch. f. klin. Med.*, Bd. lxxviii., pp. 55 and 321, 1900.

³ *Thoma*, *Virchow's Arch.*, Bd. civ., and following volumes.

The arterial lesions which appear to be of most significance in relation to hypertrophy of the heart are those of the upper aorta and those of the splanchnic system.¹ To what extent the association of kidney lesions and hypertrophy of the heart are dependent upon arterial lesions can be determined only by the accumulation of data by the more exact methods above indicated.

Hypertrophy of Both Ventricles from General Conditions.

Hypertrophy of the heart may accompany any condition which leads to a prolonged increase in the rapidity of its contractions. It may accompany exophthalmic goitre. It may be associated with severe or persistent muscular exertion, or excesses in beer-drinking or other indulgences. It may be associated with chronic pericarditis with adhesions. With the hypertrophy arising under these general conditions there may be also varying degrees of dilatation.²

The Limitations of Compensatory Hypertrophy.

While the hypertrophy of the heart may for a longer or shorter time measurably compensate for the various disturbances of the circulation which have been considered, it is by no means always a perfect or permanent adaptive measure.

Excessive functional demands upon the heart, interstitial myocarditis, which may have preceded the hypertrophy or followed it, degeneration of the muscle, dilatation of the cavities, obliterating inflammation and degeneration of the coronary arteries, singly or in various combinations, may in hypertrophied as in other hearts lead to irreparable damage to the organ.

DILATATION OF THE HEART.

In certain valvular lesions of the heart, as we have seen above (p. 552), there occurs a dilatation of the heart cavities associated with hypertrophy of the muscle. This provides for the larger amount of blood which the cavities are obliged to receive and propel, and is thus compensatory and conservative. This is called *active dilatation*. On the other hand there may be no increase of muscle tissue, but a thinning of the walls proportionate to the dilatation of the cavity—*passive dilatation*.

Either one or all of the heart cavities may be dilated, the auricles most frequently; next the right ventricle; least often the left ventricle. Active dilatation has been already considered with hypertrophy.

Passive dilatation may be associated with:

1. Changes in the valves. Mitral or aortic stenosis or insufficiency may lead to dilatation of the auricles and right ventricle. Pulmonary stenosis or insufficiency may lead to dilatation of the right auricle and

¹ See *Hasenfeld*, ref. above.

² *Howard's* table of 105 cases of cardiac hypertrophy shows its association with arterio-sclerosis in 59 per cent.; with nephritis in 13.4 per cent.; with valvular lesion in 12.4 per cent. *Johns Hopkins Hospital Reports*, vol. iii., p. 265, 1894. For possible errors in such statistics see p. 554.

right ventricle. Aortic insufficiency, with or without stenosis or mitral insufficiency, may lead to dilatation of the left ventricle. Dilatations under these conditions are often succeeded and compensated for by hypertrophy of the heart walls.

2. Changes in the muscle tissue of the heart walls. Serous infiltration from pericarditis, myocarditis, fatty degeneration and infiltration, atrophy of the muscle fibres, may all lead to dilatation.

3. A heart which is already hypertrophied may, as we have seen, from degeneration of the muscle, become dilated.

4. Acute exudative inflammation of the lungs and acute pleuritic exudations, by rendering a large number of vessels suddenly impermeable to the blood current, may produce sudden stasis in the pulmonary artery and dilatation of the right heart.

5. There are curious and often serious cases of acute and chronic dilatation of the ventricles for which no mechanical explanation is found.

TUMORS.

Primary tumors in the heart are rare, but **sarcomata**, **myxomata**,¹ **fibromata**, and **lipomata** may occur. **Rhabdomyomata**, probably congenital, may occur in the heart wall as circumscribed nodular masses.² A **cavernous** tumor of this kind has been described. Secondary tumors, as a result of metastasis or of continuous growth from the pleura or œsophagus or other adjacent parts, are not very infrequent. These are usually **carcinomata** or **sarcomata**. Secondary **chondromata** have been observed.³ A few tumors of the heart valves have been described.⁴

PARASITES.

Echinococcus sometimes occurs in the heart wall and may perforate into the cavities. **Cysticercus cellulosæ** has been observed.

The Blood-Vessels.

HYPOPLASIA, ATROPHY, AND HYPERTROPHY.

Hypoplasia.—The aorta and larger vessels are sometimes disproportionately small as a congenital condition—hypoplasia—in which the heart may also share.⁵ This condition may be associated with the so-called “status lymphaticus” (p. 439), and may accompany chlorosis.

Atrophy of the blood-vessels may involve the entire trunk or some of its elements. It may occur as a part of general malnutrition of the body,

¹ See for study of myxoma of heart *Leonhardt*, *Virch. Arch.*, Bd. clxxxii., p. 347, 1905, *bibl.*; also *Bacmeister*, *Cbl. f. allg. Path.*, Bd. xvii., p. 257, 1906.

² *Seiffert*, *Ziegler's Beitr.*, Bd. xxvii., p. 145, 1900, *bibliography*; also *Knox and Schorer*, *Arch. of Pediat.*, Aug., 1906; also *Wolbach*, *Jour. Med. Res.*, xvi., 495, 1907.

³ For bibliography of heart tumors consult *Berthenson*, *Arch. de méd. exp.*, vol. v., p. 386, 1893.

⁴ See *Djewitzky*, *Virch. Arch.*, Bd. clxxxv., p. 195, 1906.

⁵ For a study of hypoplasia of the arterial system see *von Ritoók*, *Zeits. f. klin. Med.*, Bd. lxi., p. 32, 1907.

or in connection with atrophy of particular organs, or as an accompaniment of various diseases of the vessels themselves.

Hypertrophy, which is especially seen in the arteries, may occur in the establishment of a collateral circulation upon the closure of arterial trunks; or it may occur as the result of increased blood pressure, as in some forms of hypertrophy of the heart, or from overwork. While all the coats of the vessel may be involved in hypertrophy the media is apt to be especially affected. This is seen in chronic diffuse nephritis. The hypertrophied media is liable to degeneration and weakening leading to arterio-sclerosis (see p. 564).

The Arteries.

RUPTURE AND WOUNDS.

The arteries are predisposed to rupture by fatty degeneration, arterio-sclerosis with atheroma, and in various forms of acute inflammation.¹ Stenosis of the aorta may be followed by rupture between the occlusion and the heart. The rupture may be complete or a dissecting aneurism may form (see p. 568). Rupture of the aorta may lead to sudden death (Fig. 344). There may be partial or complete rupture of an artery from contusions, wrenchings, falls, etc. The injury to an artery from a penetrating wound may be fatal if the vessel be large. The wound of a small artery may close or a false aneurism may develop at its seat.

In the healing of a wounded artery the vessel retracts and contracts, and a thrombus is formed within it. The contraction alone may be sufficient to close the vessel; its coats thicken, and the inner surfaces finally are fused together; or the blood coagulates and forms a thrombus in the vessel near the wound. This thrombus later becomes organized and the vessel is converted into a fibrous cord.

DEGENERATION.

Fatty Degeneration.—This may occur in the walls of otherwise unaltered vessels, or in those which have undergone a variety of inflammatory or degenerative changes. It may occur either in the intima or media, or both, and may be so extensive as to form a very prominent gross lesion, or so little developed as to require the microscope for its recognition. When marked, especially if occurring in the intima of large vessels, smaller and larger spots or stripes or patches may be seen, of a yellowish white color, usually sharply circumscribed, and sometimes smooth, sometimes roughened on the surface. It is most apt to occur in the aorta, but may be found in any of the vessels. In moderate degrees of the lesion we find on section that the cells of the intima contain fat droplets in greater or less number. When further advanced, not only are the cells crowded with fat droplets, but the intercellular tissue also may be more or less densely infiltrated with them. Sometimes the infiltration is so dense that the tissue breaks down, and there may be an

¹ For a study of perforations of aorta in pyæmia see *Witte, Ziegler's Beitr.*, Bd. xxxvii., p. 151, 1905.

erosion of the surface, forming a so-called fatty ulcer. When the media is involved the muscle cells contain fat droplets. It may lead to the formation of aneurism or to rupture of the vessels.

Amyloid degeneration, which may affect all the coats of the arteries, but especially the intima and media, has already been described in general (p. 48). It will be further considered under the lesions of the organs in which it most commonly occurs.

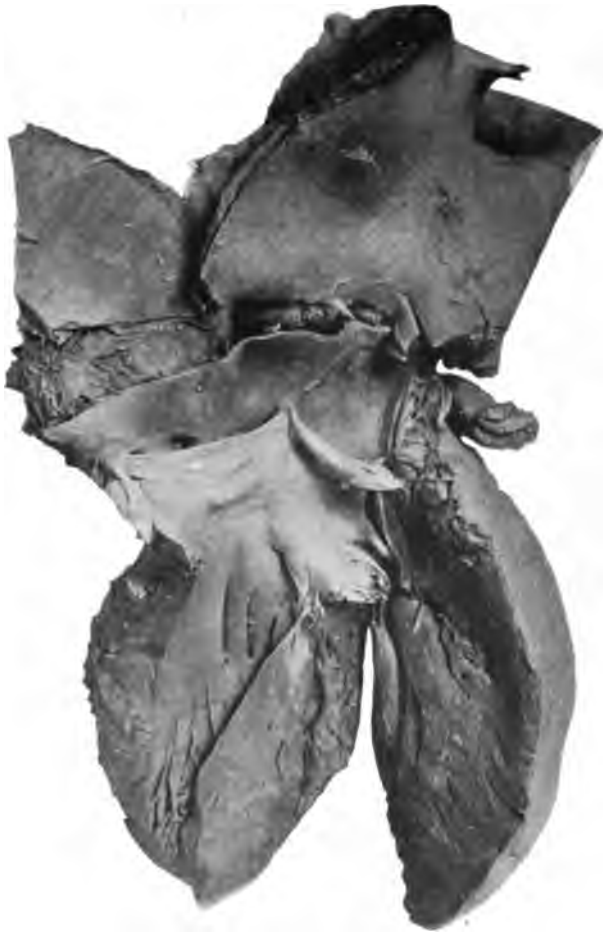

FIG. 344.—TRANSVERSE RUPTURE OF THE AORTA. (Traumatic.)

Hyaline degeneration may cause thickening of the intima of the blood-vessels by its conversion into or infiltration with a homogeneous matter somewhat similar to amyloid (see p. 48). Or it may involve the entire wall of smaller vessels, converting them into irregular lumpy cords. The lumen of vessels thus changed may be obliterated or occluded by thrombi.

Calcification usually occurs in vessels otherwise diseased, and may involve either the intima or media. It consists in the deposition of salts of lime either in the cells or intercellular substance. The lime may be in the form of larger or smaller granules or in dense translucent plates.

INFLAMMATION.

Acute Arteritis.—Acute inflammation of the walls of the arteries is, in the majority of cases, the result of injury, or of an inflammation in the vicinity of the vessel, or of the lodgment within it of some foreign body of an irritating or infectious nature. The inflammatory process may be largely confined to the inner coat of the vessels—*endarteritis*; or it may commence in the outer coats—*periarteritis*; or it may involve the entire wall.

The blood-vessels in the outer coats may be congested, the tissue œdematous and infiltrated with pus cells, and the entire wall may become necrotic. The intima, if this layer be involved, loses its natural gloss and looks dull yellowish and is swollen and may then ulcerate. Under these conditions thrombi usually form, and in these may occur the various changes which have been already described on page 24. But the process may originate in an infective thrombus or embolus most commonly associated with *Streptococcus* or *Staphylococcus pyogenes*,—*thromboarteritis*—*embolic arteritis*.

In cerebro-spinal meningitis, whether this be incited by the meningococcus, streptococcus, pneumococcus, or by the tubercle bacillus, there may be an acute endarteritis characterized by the accumulation of leucocytes and polyhedral cells beneath the endothelium, often raising this layer from the underlying tissue (Figs. 128 and 129). This lesion may occur with or without the involvement of the outer layers of the vessel.¹

Rupture of the artery with more or less extensive hæmorrhage may follow acute suppurative and necrotic inflammation of these vessels. Thus false aneurisms (see p. 568) may be formed. Or true aneurisms may be developed at the weakened point. In healing, fibrous tissue may form, leading to various phases of arterio-sclerosis. Finally, as the result of organization of thrombi (see p. 27), which may be present, new tissue may form within the lumen of the involved vessel—*thromboarteritis proliferans*.

Arterio-sclerosis (Chronic Arteritis).—Since the publication of the studies of Gull and Sutton on arterio-capillary fibrosis, attention has been every year more and more directed to chronic pathological changes in the arteries as of great frequency and importance. These changes are productive and degenerative in character and have an important bearing upon the circulation and upon the integrity of the vessel walls. They are in part primary, in part secondary, and may involve single vessels or vascular territories or may affect the entire vascular system.

The lesions differ somewhat in the small and large vessels. In very

¹ For a study of this lesion of the subendothelial layers of the arteries in tuberculosis, see *Hektoen, Jour. Exp. Med.*, vol. i., p. 112, 1896, bibl. See also *Flechner*, p. 225.

small arteries there is a more or less general though not uniform thickening of the intima (Figs. 345 and 346). This is due in part to a prolifer-




FIG. 345.—CHRONIC ARTERITIS—ARTERIO-SCLEROSIS—OBLITERATING ENDARTERITIS.

Showing a thickening of the intima in a small artery of the brain.



FIG. 346.—CHRONIC ARTERITIS—ARTERIO-SCLEROSIS—OBLITERATING ENDARTERITIS.

The new-formed tissue is most abundant at one side of the vessel, where the external coats are pouched. There is degeneration of the new-formed tissue.

ation of the endothelium, in part to increase in the connective tissue of the intermediary layer: In this way a considerable amount of moderately cellular fibrous tissue (Fig. 348) may form within the membrana elastica,




FIG. 347.—OBLITERATING ENDARTERITIS.

Complete occlusion of the lumen followed by gangrene of the toe. There is also fibrous thickening of the muscular coat.

and the lumen may be largely or wholly obliterated—*obliterating endarteritis*. The middle coat as well as the inner may be thickened (Fig. 347).

In larger arteries the new tissue may form beneath the endothelium

diffusely or in circumscribed masses, or may encircle the vessel. The endothelium over the involved areas may remain intact or it may proliferate or become fatty or necrotic. The new-formed fibrous tissue of the intima, which may contain also new elastic fibres,¹ is usually dense, having few cells, and is prone to undergo fatty degeneration, to become necrotic, and to disintegrate, and thus larger and smaller cavities, filled with disintegrated tissue, fat, and cholesterin crystals, may develop in the new-formed tissue (Figs. 346 and 349). These are called *atheromatous cysts*.² They may extend toward the lumen of the vessels, into which they may open, giving rise to emboli and forming rough-edged ulcers, often with undermined edges. Upon these thrombi may form. In the new-formed tissue of the intima, as well as in the necrotic foci and in the detritus of the cysts, calcification may occur.

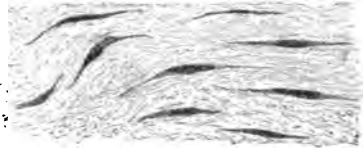


FIG. 348.—CONNECTIVE TISSUE FORMED IN THE INTIMA IN ARTERIO-SCLEROSIS.




FIG. 349.—CHRONIC ARTERITIS—ARTERIO-SCLEROSIS—CEREBRAL ARTERY.

Inner coat thickened; degeneration and softening (atheroma) of a part of the thickened area.

ularis and adventitia of the involved vessels. There may be degeneration and atrophy of the elastic laminae.

Similar processes may occur in the aorta, the new tissue growth and the degeneration being less definitely limited to the inner layer of the wall. The elastic laminae may be degenerated, partially atrophied or

¹ See Jores, Ziegler's Beitr., Bd. xxiv., p. 458, 1898, bibl.

² The word atheroma is sometimes applied to the whole process of arterio-sclerosis, but it would be well to limit it to the degenerative phases which result in softening of the tissues.

absent, in patches in the wall of the vessel (Fig. 350). The aorta may thus be beset with larger and smaller, irregular, white, hard, elevated




FIG. 350.—ATROPHY OF ELASTIC TISSUE IN WALL OF THE AORTA IN ATHEROMA.
The elastic tissue is replaced by dense fibrous tissue.

thickenings (Fig. 351), often yellowish from fatty degeneration. Beneath these there may be atheromatous softening, or these sclerotic areas may



FIG. 351.—ATHEROMA OF THE AORTA.
There are fatty degeneration, thickening of the intima, calcification, and erosion. Thrombi have formed over the roughened surface of the erosions.

be calcified and project as hard, often brownish plates with smooth or rough edges. The surface of the aorta may be rough from erosion over

the degenerated areas, and upon these or elsewhere parietal thrombi may form (Fig. 352). Such sclerotic areas are often well marked at the junction of smaller vessels with the aorta.

We have seen that in the smaller vessels arterio-sclerosis may lead to extreme narrowing or occlusion of the lumen. When this does not occur,

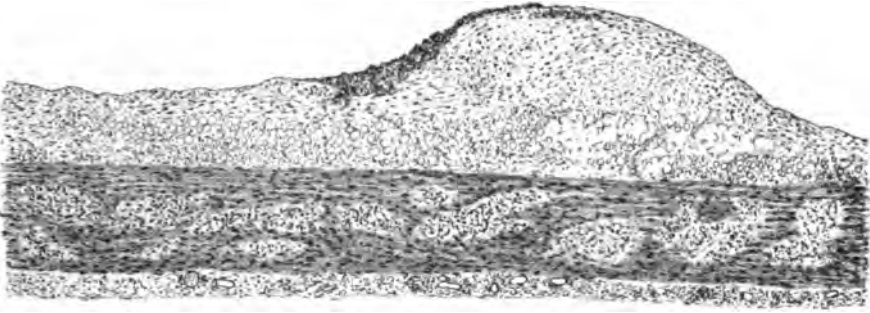


FIG. 352.—CHRONIC INFLAMMATION OF THE AORTA—ATHEROMA OF THE AORTA.

Section showing involvement of all the layers. The thickening of the intima is irregular, and areas of degeneration are seen in its deeper portion. Patches of fibrous tissue are present in the muscularis. A small thrombus has formed upon the surface.

and especially in the medium-sized arteries, since the new tissue is less elastic than normal and liable to yield to the pressure of the blood, the lumen may in places be dilated (Fig. 353) or the wall may rupture. In this way aneurisms may form. This is especially apt to occur when atheromatous degeneration has taken place and the muscularis is either




FIG. 353.—CHRONIC ARTERITIS—ARTERIO-SCLEROSIS.

Showing pouching of the wall of the artery at the side on which is the largest formation of new fibrous tissue.

atrophied or degenerated. In the aorta also dilatation and rupture may occur.

Arterio-sclerosis may be largely limited to the aorta or to other single vessels, or it may occur in special vascular tracts, such as those of the brain or heart.

As the result of arterio-sclerosis a great variety of circulatory disturbances may arise, both local and general. The effect upon the heart of the narrowing of the lumen of the arteries, as well as the loss of their elasticity, we have seen above (p. 554).¹

THE CONDITIONS LEADING TO ARTERIO-SCLEROSIS.—The lesions of arterio-sclerosis often occur with gout, syphilis, chronic lead and alcohol poisoning, overwork, and overfeeding. They are usual in senility,² and predisposition to them may be inherited. They may be associated with cardiac hypertrophy from valvular lesions or with chronic diffuse nephritis or other conditions involving increased arterial tension. They may occur locally in connection with tumors. In various acute infections—diphtheria, scarlatina, typhoid fever, influenza, pneumonia, and pyæmia—localized lesions of the medium-sized arteries may occur, leading to sclerosis. There is degeneration of the smooth muscle cells and the elastic tissue of the media occurring in patches and followed by necrosis. These local lesions may heal by connective-tissue formation, or they may involve the intima, leading to sclerosis and more or less obstruction of the lumen. The aorta, the arteries of the brain, and the coronaries are frequently involved.³

While the mechanical conditions under which arterio-sclerosis develops are not very fully understood, the studies of Thoma have pointed the way along which fruitful research may be confidently expected.

In accordance with the results of Thoma's experiments one may regard the primary lesions of arterio-sclerosis as a compensatory hyperplasia of the intima. If for any reason—congenital defects, for example—the wall of the artery in a given region, as is the case in the circumscribed or nodular forms of arterio-sclerosis, be weakened and yields to the blood pressure, it is at this point that the new tissue forms in the intima and restores the lumen to its natural calibre (see Figs. 346 and 353) with restitution of the rate of blood flow. That this compensation is often incomplete or temporary, or that it brings with it other and often serious complications, does not militate against this view of the significance of these blood-vessel lesions, and is only one of many examples of imperfect adaptation in pathological processes.⁴

Many conditions other than congenital defects in the vessel walls may result in arterio-sclerosis. In fact any long continued disturbance of the normal balance between the blood pressure and the resistance of the vessel wall apparently may lead in a variety of ways to arterio-sclerosis. Thus syphilitic inflammation of the arterial wall with necrosis may result in the formation of scar tissue, replacing the muscular and elastic supports of the walls by less resistant structures. The effects of alien substances or of natural substances in undue amount in the blood, which induce a continuing contraction of the muscularis of the arteries, or of overwork may lead through a primary hypertrophy followed by

¹ For a comprehensive *résumé* of the normal and pathological physiology of the blood-vessels see *Heinz*, *Handbuch d. exp. Path. und Pharmakol.*, 1905, Bd. ii.

² For changes in elastic tissue in aorta in advancing age, *Foster*, *Jour. Med. Res.*, xxi., 297, 1909.

³ See *Wiesel*, *Zeits. f. Heilkunde*, Abt. d. path. Anat., Bd. xxvii., p. 262, 1906.

⁴ See reference to *Welch*, p. 110.

degeneration of the muscle cells to a general weakness of the walls with coincident general or local thickening of the intima. Senile or other general degeneration of the media with widespread calcareous deposits may determine sclerotic changes in the intima. In all these cases the intimal thickening is not, according to the widely entertained view, inflammatory, but has the nature of a replacement hyperplasia in walls damaged and weakened in various ways.

But this view, largely inspired by the work of Thoma,¹ that the intimal lesions in arterio-sclerosis are compensatory, has not found universal acceptance. Indeed there are many conditions under which it seems clear that the sclerotic lesions of the intima, while often associated with damaging or destructive changes in the other layers, especially the media, are not secondary to them but are due to common agents acting on both. Furthermore, there appear to be intimal inflammatory thickenings induced by infective or toxic agents acting primarily on the intima.²

Finally, there may be lesions of the intima secondary to those of the media, without the former being in any sense compensatory.

CLASSIFICATION OF THE FORMS OF ARTERIO-SCLEROSIS.—Various classifications of the lesions of arterio-sclerosis have been made. These must all be considered somewhat arbitrary and superficial until our knowledge of the mechanics of the circulation and the evolution of the lesions are more clearly defined. Much of the uncertainty in the interpretation of arterial lesions is due to the fact that observations in the past have been made largely on vessels in the contracted condition in which the cessation of blood pressure at death left them. So that the exact condition of the lumen during life in various sclerotic lesions is not really known. Thoma places in one class the primary and more limited nodular forms of fibrous-tissue growth, especially in the larger vessels, which he regards as compensatory in the way just indicated; in another the diffuse or secondary form, which is attributable to an increased resistance to the flow of blood in peripheral vessels, such as those of the kidney, a weakening of the muscularis through degeneration, the consequent dilatation, and then the compensating fibrous-tissue growth in the vessels at large.

Councilman³ has grouped the lesions into three forms: 1st, the *nodular*, corresponding with the primary form of Thoma; 2d, a *senile* form, in which there are often great distortion of the vessels, calcification, and frequent thinning of the walls; atrophic changes in the viscera are apt to be associated with this form of senile arteritis; 3d, a *diffuse* form of marked obliterating endarteritis with fibrous involvement of the muscular layer. This is apt to be associated with hypertrophy and often with

¹ Thoma, see Virch. Arch., Bd. xciii., p. 443; *ibid.*, Bd. cxvi., p. 1; also Thoma's "Text-book of General Pathology," vol. i., Eng. trans.; also reference to Thoma's works, Arch. f. Entwickl. Mech., Bd. xii., p. 352.

² For summaries of more recent conceptions of arterio-sclerosis see Adami, Am. Jour. Med. Sci., cxxxviii., 485, 1909; and Klotz, Jour. Exp. Med., xii., 707, 1910.

³ For a *résumé* of views based upon Thoma's studies see Councilman, Trans. Assn. Am. Phys., vol. vi., p. 179, 1891. For a general study of pathogenesis of arterio-sclerosis see Pic and Bonnamour, Jour. de phys. et. path., gén., t. viii., p. 495, 1906, bibl.

dilatation of the heart, and with chronic diffuse nephritis often with atrophy. The arterial changes may be marked in the liver as well as in the kidneys.

The experimental study of arterio-sclerosis has thrown much light on the subject within the last few years. But into this we cannot enter here.¹

Periarteritis Nodosa.

A few cases have been described in which many of the small arteries in the muscles and in the viscera were beset with small white knobs projecting from the side or surrounding the vessels. These circumscribed thickenings of the vessel walls are apt to involve all the layers of the vessel, and may encroach upon the lumen. The thickened portions are infiltrated with small spheroidal cells. Multiple aneurisms may develop at the seat of the local thickening.²

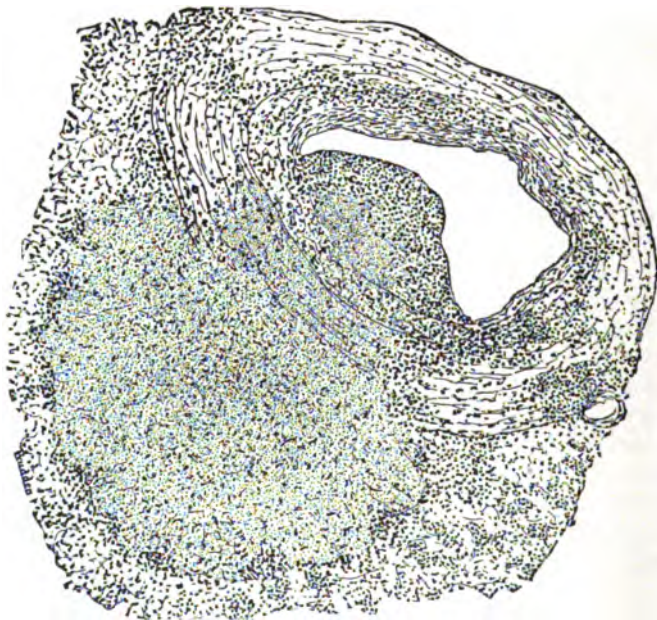


FIG. 354.—TUBERCULOUS ARTERITIS IN THE LUNG.

Showing the encroachment of an area of tuberculous inflammation upon the wall of the artery, and the formation of a mass partly occluding the lumen of the vessel. This section shows how the generalization of the tuberculous inflammation through the body may occur by the sweeping away of the tubercle bacilli by the blood and the establishment of new foci in various parts of the body.

Tuberculous Arteritis.—Tuberculosis of the arteries is usually secondary, the process extending to their walls from an already established focus (Fig. 354).³ Tubercle tissue with necrosis may involve the external layers, while an obliterating inflammation often closes the lumen. Thus it is that in tuberculous cavities of the lungs large arterial trunks may

¹ For a more comprehensive consideration of arterio-sclerosis with references to experimental studies see *Adami and Nicholls*, "Principles of Pathology," vol. ii., 171, 1909.

² Consult *v. Kahlden*, *Ziegler's Beitr. z. path. Anat.*, etc., Bd. xv., p. 581, 1894; also *Graf*, *ibid.*, Bd. xix., p. 181, 1896.

³ For a study of tuberculosis of arteries see *Geissler*, *Virch. Arch.*, Bd. clxxxvi., p. 135, 1906, *bibl.*

be laid bare (see Plate X.) without a distribution of the bacilli through the body and without hæmorrhage. Tuberculosis of the aorta is of occasional occurrence.¹

Syphilitic Arteritis.—In the more characteristic forms of this lesion there may be gummata formed in the walls. Or there may be a diffuse formation of new cells and new fibrous tissue, especially in the adventitia of the vessels. This may extend to the middle and internal layer and lead to narrowing of the lumen. There may be degeneration and ulceration. Such lesions may be circumscribed or extensive and may result in aneurism or rupture or closure of the lumen.²

Save for the occasional formation of gummata and the frequent development of considerable new polyhedral-celled tissue there appear to be no distinctive morphological characteristics of syphilitic arteritis.

ANEURISM.

An aneurism is a dilatation of an artery, either cylindrical, fusiform, or sacculated, the walls consisting of all or part of the coats of the artery variously altered.

The conditions which commonly lead to aneurisms are arterio-sclerosis, either with or without associated degeneration; or such local weakening of the walls of the vessels, from various causes, as often leads to compensatory arterio-sclerosis, but in which protective compensation does not take place; or the blocking of a vessel by embolus or trauma. Aneurism may develop at the point of partial rupture of the walls of an artery. Aneurisms may follow the local necrotic and ulcerative process in the walls of the vessels or on the heart valves incited by infectious agents, which as emboli or otherwise have reached these parts. Such mycotic aneurisms are frequently multiple.³

In **cylindrical or fusiform aneurism** there is apt to be at first a distention of all the walls of the vessel; but this is often irregular, so that the sac may bulge more in one place than in another (Fig. 355). The walls may become thin or through new-formed tissue they may become thickened; they may undergo degeneration or calcification. Such aneurisms are most frequent in the aorta, but may occur in other vessels.

In the **sacculated aneurism** there is either a dilatation of the entire circumference of an artery over a short portion of its length, or there may be a dilatation of only a small portion of one side of the wall, so that the aneurism looks like a swelling attached to one side of the artery. The aneurism may commence as a dilatation of all the coats of the vessel; but the middle coat soon atrophies, so that the wall is composed of the inner and outer coats; or the inner coat is destroyed by endarteritis, so that the outer coat alone forms the wall of the aneurism; or the dilata-

¹*Stroebe*, *Centralbl. f. Path.*, Bd. viii., p. 998, 1897, bibl. Consult *Blumer*, *Am. Jour. Med. Sci.*, vol. cxvii., p. 19, 1899, bibl. For bibl. of tuberculous arteritis see ref. *Hektoen*, foot-note, p. 559.

²For a careful study of alterations of the blood-vessels in syphilis see *Abramow*, *Ziegler's Beitr. z. path. Anat.*, Bd. xxvi., p. 202, 1899, bibl. For a review of syphilitic aortitis see *Fahr*, *Virch. Arch.*, Bd. clxxvii., p. 508, 1904; also *Chiari*, *Verh. Deut. path. Gesellsch.*, Bd. vi., p. 137, 1904.

³For a study of mycotic aneurisms, with bibl., see *McCrae*, *Jour. of Path. and Bact.*, vol. x., p. 373, 1905.

tion may commence at the seat of rupture of one or more coats of the vessels. As the aneurism increases in size it may press upon and lead to partial destruction of neighboring tissues and viscera, so that portions of these tissues and viscera may take the place of the wall of the aneurism. The cavity of the aneurism is filled with fluid or clotted blood, or with layers of fibrin (Fig. 356) which adhere closely to its wall. The communication between the aneurism and the artery may be small or large.

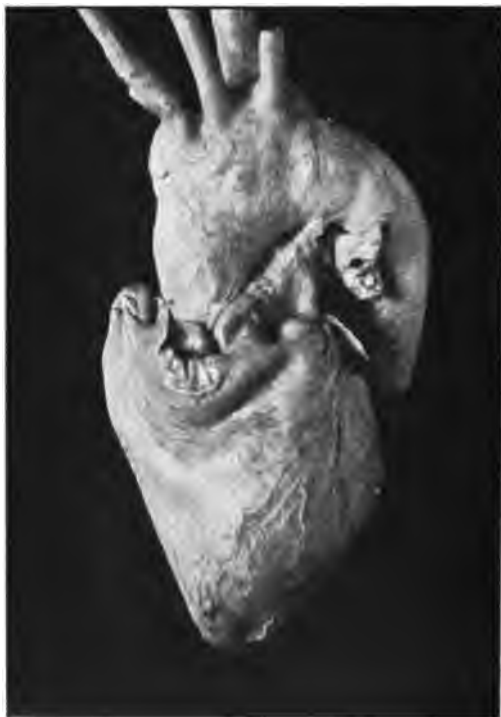

FIG. 355.—FUSIFORM ANEURISM OF THE ARCH OF THE AORTA.

If arterial branches are given off from the aneurism they may remain open or become plugged with fibrin; or their walls are thickened and their cavities narrowed by endarteritis. Death may occur by the pressure and interference of the aneurism with the adjoining viscera, or by rupture.

Dissecting aneurisms are those in which, owing to a solution of continuity of the inner layers of the artery, the blood gets between the media and adventitia, and forces its way for a greater or less distance between them. Or it may separate the media into two layers.¹

Spurious or false aneurisms are most frequently connected with vessels of the extremities. When an artery is wounded the blood escapes

¹ For a study of dissecting aneurism see *Adami*, Montreal Med. Jour., June and July, 1896.

into the surrounding soft parts, and a cavity is formed filled with blood and broken-down tissue.

The wound in the artery may heal and the effused blood be absorbed; or it may become the seat of secondary inflammatory processes.

Finally a wall of fibrous tissue may be formed, while the wound of the artery remains open, so that there is an aneurismal sac through which the blood is constantly pouring. This is called a *false aneurism*.

Aneurismal Varix: Varicose Aneurism.—If an artery be wounded, and at the same time the vein which accompanies it, we have as the result the conditions called aneurismal varix and varicose aneurism. In aneu-

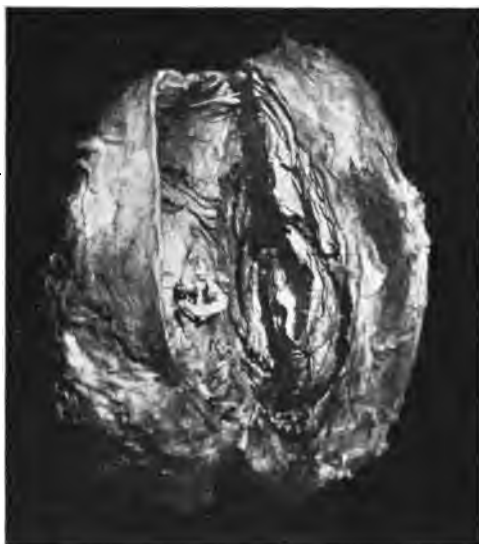

FIG. 356.—ANEURISM OF THE POPLITEAL ARTERY.
Showing lamellated clot.

rismal varix the artery and vein become adherent at the seat of injury, so that the arterial blood passes directly into the vein. There is a smooth, rounded opening between the two vessels, the vein is dilated into a sac, and the veins emptying into it are dilated and tortuous. In varicose aneurism the artery and vein do not communicate directly, but a false aneurismal sac is formed between the vessels, into which the blood is poured before passing into the vein. Varicose aneurism may also be formed by the spontaneous rupture of an aneurism into a vein. The aneurism presses against the vein, becomes adherent, and finally ruptures into it. This condition has been observed between the aorta and pulmonary artery; the aorta and inferior and superior vena cava; the popliteal artery and vein; the femoral artery and vein; the splenic artery and vena azygos; the internal carotid and sinus cavernosus.

Cirsoid aneurism is one formed by the dilatation and lengthening of large or small arteries or arterial tracts. The walls of the arteries are

thinned, the vessels are tortuous and in places sacculated. These changes are most frequent in small arteries, especially the temporal and occipital. They involve the trunk of the vessel and its branches, or may extend to the capillaries and small veins. They form larger or smaller tumors beneath the skin.

ANEURISMS OF THE DIFFERENT ARTERIES.

The aorta may be dilated over its entire length, or there may be diffuse or circumscribed dilatations at any portion of its course; or there may be several aneurisms, situated at different points. The ascending portion of the arch of the aorta may be uniformly dilated in a fusiform shape (Fig. 355), or there may be circumscribed dilatations on its anterior wall, or, more rarely, on its posterior wall. The sacculated aneurisms vary in size and may rupture within the pericardium; or they may form a cavity in the upper part of the ventricular septum and communicate by openings into the pulmonary artery and left ventricle; or they may dilate downward between the visceral and parietal pericardium, in front of the heart, pushing that organ backward. They may perforate into the right or left auricle or right ventricle, the superior vena cava, or the pulmonary artery; or they may reach a large size, press on and erode the right side of the sternum and adjoining ribs, project under the skin, and even rupture externally.¹

The transverse portion of the arch may be dilated in a fusiform shape, or there may be sacculated aneurisms at any point in its wall. The sacculated aneurisms usually reach a considerable size. They press on the sternum and ribs in front, or on the œsophagus, trachea, and bronchi behind. The large arteries given off from the arch may be occluded. They cause death by pressure on the air passages, the œsophagus, and the vena cava; or may rupture externally or into the œsophagus, trachea, bronchi, pulmonary artery, or pleural cavities.

On the abdominal aorta aneurisms are usually sacculated. If they are situated high up they may project into the pleural cavities; if lower down, into the abdomen. They may compress and displace the viscera, vessels, and nerves, and erode the vertebræ. They may rupture behind the peritoneum, into the peritoneal cavity, the pleural cavities, the inferior vena cava, the bronchi, the lungs, the duodenum, the colon, the pelvis of the kidney, or the posterior mediastinum. Rupture of the aorta with the development of a long dissecting aneurism parallel to the vessel may give rise to a condition simulating a double aorta.²

The coronary arteries may be dilated throughout, or may be the seat of small sacculated aneurisms.³ These may rupture into the pericardium, or may lead to rupture of the heart wall.

The pulmonary arteries are rarely the seat of aneurisms. Diffuse and circumscribed dilatations, however, sometimes occur on the main trunk

¹ For extension of aortic aneurism into the heart, and dissecting aneurisms of the heart, see *Hektoen* Trans. Assn. Am. Phys., vol. xvi., p. 127, 1901.

² See case reported by *G. P. Biggs*, Proc. New York Path. Soc., 1897-98, p. 109.

³ Consult *Capps*, Am. Jour. Med. Sci., vol. cxviii., p. 312, 1899, bibl.; also *Griffith*, Brit. Med. Jour. February 2d, 1901, p. 266, bibl.

and on the two principal branches of the artery. They do not usually reach a large size, but may cause death by rupture. General dilatation of all the branches of the pulmonary artery is more common. It is found in connection with stenosis of the mitral valves and with compression or induration of the lung tissue. Small multiple aneurisms—*miliary aneurisms*—may occur in the cerebral arteries; less frequently in the pulmonary and mesenteric. These are probably due to some congenital weakness of the walls at the point of formation of the aneurism.

Of the other arteries of the body there is hardly any one which may not become the seat of an aneurism.¹

STENOSIS AND OBLITERATION OF THE AORTA.

This lesion near the entrance of the ductus arteriosus has been observed in a considerable number of cases. The degree of stenosis varies. The aorta may be entirely closed and converted into a solid cord for a half-inch; or there may be a constriction through which there is a larger or smaller opening. The walls of the aorta at this point may be thickened and sclerosed. The ductus arteriosus may be closed or open. Above the constriction the aorta is usually dilated; below it, it is normal, dilated, or stenosed.

Stenosis of the aorta is followed by hypertrophy of the left ventricle, and, later, of the right ventricle, with venous congestion throughout the body; or there may be a collateral circulation developed between the arteries given off above and below the constriction; or there may be rupture of the aorta, the right ventricle or auricle.

This condition is found at all ages, but is induced during foetal life or in the first year of extra-uterine life. It is probable that it may be caused after birth by an abnormal closure of the ductus arteriosus. This vessel normally becomes closed without the formation of a thrombus. If a thrombus be formed it may extend into the aorta and obstruct it; or the ductus arteriosus is filled with a thrombus, but increases for a time in size; afterward, as the thrombus is absorbed, the vessel contracts and draws the walls of the aorta together.

TUMORS OF THE ARTERIES.

Secondary tumors, chiefly **carcinomata** and **sarcomata**, may occur in the walls of the arteries by continuous growth from without, involving first the external layers. To these layers they are usually confined, for the density of the inner layers affords such marked resistance to the infiltration of the tumor cells that arteries are apt to pass intact through the tumor, which grows around them. More frequently the arteries become secondarily involved in the growth of malignant tumors by the occurrence within them of emboli formed by larger and smaller masses of tumor cells.

These emboli are usually of small size, and are apt to get into the

¹ For details concerning form, distribution, and frequency of aneurisms see the larger works on the practice of medicine or surgery.

circulation by growing through the walls of the veins into their lumina. Large emboli from tumors are most apt to lodge in the branches of the pulmonary artery. The emboli, formed as they are for the most part by cells capable of growth and proliferation, are apt soon to form connection with the walls of the vessels, and, by the growth into them of blood-vessels from the *vasa vasorum*, to find the conditions necessary for their development, and they may thus soon involve the entire wall of the vessel and grow out into adjacent parts.

The Veins.

DILATATION. (Phlebectasia.)

Dilatation of the veins, or phlebectasia, presents itself under a variety of forms:

1. **SIMPLE DILATATION.**—The vein is uniformly dilated in a cylindrical or fusiform shape; its length is not increased; its walls may be thicker than normal or thinned; the valves may be thickened, or are insufficient, or atrophic, or are torn.

2. **CIRSOID DILATATION.**—The vein is cylindrically dilated, but is also increased in length, so that it assumes a very tortuous course. The walls may be thickened or thinned.

3. **VARICOSE DILATATION.**—Portions of the wall of the vein undergo saccular dilatation. The wall of the sac is formed of the coats of the vein, but these may be thickened or thinned; the middle coat may disappear entirely. There may be only one such dilatation, or there may be a number on the same vein, or a number of veins may be affected at the same time. The vein may be otherwise normal, or, more frequently, is more or less uniformly dilated.

4. **ANASTOMOSING DILATATION.**—A number of contiguous and anastomosing veins are dilated, both in the cirroid and varicose forms. The vein then looks like a series of cavities separated by thin partitions. The dilatations of the same vein become adherent to each other and to those of the adjoining veins; portions of the walls of the dilated parts may atrophy so that there may be a number of cavities containing venous blood and separated from each other by thin partitions.

DISTRIBUTION, CAUSES, AND EFFECTS OF PHLEBECTASIA.—There is hardly one of all the veins of the body which may not be dilated. The hæmorrhoidal veins forming "hæmorrhoids"; the veins of the leg and thigh; those of the pelvis and pelvic viscera; those of the spermatic cord, scrotum, and labia; those of the abdominal wall; those of the neck and arms—are most frequently involved. The immediate cause of dilatation is usually some obstruction to the passage of the blood through the veins toward the heart; but alterations in the walls of the vessels from degeneration, inflammation, or injury are often important predisposing factors. Spontaneous restitution of dilatations of the veins is not common, and usually occurs only in the lesser degrees of the lesion. The tendency of the dilatation is to increase. Thrombi frequently form in the dilated

veins, and either partially or completely fill them. These thrombi may become organized, or they may dry and become calcified, forming *phleboliths*, and by the formation of new connective tissue in the walls they may become enclosed in a fibrous capsule, with the obliteration of the vessel. The wall of the dilated sac may become so thin that it finally ruptures. Inflammation of the dilated vein may occur, followed by fibrous thickening. When occurring in mucous membrane, dilated veins are usually associated with persistent catarrh.

WOUNDS—RUPTURE.

Wounds of the veins usually heal by a simple contraction and an adhesive inflammation of their walls; sometimes by the formation of a thrombus. **Rupture** of the veins may be produced by severe contusions and crushings of the body and by violent falls. **Perforation** of a vein may be produced by suppuration of the soft parts and the invasion of the walls of the vessel; by the pressure of an aneurism or of a new growth; by the thinning of the wall of the vein in phlebectasia.

THROMBOSIS.

Thrombosis of the *inferior vena cava* has been many times recorded. It is usually due to pressure on the vessel or may occur as an extension of thrombi from the contributory veins.¹

Thrombosis of the *superior vena cava* usually follows pressure from without by tumors, aneurisms, or enlarged lymph-nodes.

Thrombosis of other *large venous trunks* may occur under various local and general conditions (see below, Thrombosis and Phlebitis, and p. 24).²

DEGENERATION.

Fatty degeneration and **calcification** may occur in the walls of the veins under conditions similar to those in which these changes take place in the arteries.

INFLAMMATION. (Phlebitis.)

Inflammation of the veins, *phlebitis*, may involve chiefly the external layers—*periphlebitis*; or the internal—*endophlebitis*; or, as is very frequently the case, the entire wall may be affected. Phlebitis may be due to an infectious thrombus, to injuries, or to an infectious inflammation of the surrounding tissues. Thrombosis of the vein, either primary or secondary, is a very constant accompaniment of phlebitis. Thrombosis and phlebitis are not infrequent in association with or following infectious diseases, in cachectic conditions, and with rheumatism and gout.

Acute infective phlebitis may follow a suppurative periphlebitis. The outer layers of the vein wall are congested, swollen, infiltrated with serum

¹ For a case of complete fibrous obstruction of superior and inferior venæ cavæ see *Meyer*, Mt. Sinai Hosp. Rep., vol. iii., 1903, p. 35.

² For a consideration of peripheral venous thrombosis in heart disease consult *Welch*, Trans. Assn. Am. Phys., vol. xv., p. 441, 1900, bibl.

and pus. The inner coats may become infiltrated with pus; they may become necrotic and disintegrate. A thrombus is constantly formed under these conditions, which may for a time stop the circulation and keep the products of inflammation and degeneration and infectious material from mixing with the blood; but the thrombus itself is prone to disintegration, and thus the exudates and fragments of disintegrated thrombi or tissue or bacteria may enter the circulation.

On the other hand, owing to the presence of irritating or infectious material within the vein, and the formation of a thrombus, the inflammatory process may be at the commencement an endophlebitis, but usually, if the inflammation be at all severe, the entire wall of the vessel is eventually involved.

Acute phlebitis may terminate in the absorption of the thrombus and the return of the vein to its normal condition, or in the obliteration of the vein. The pyogenic cocci, the typhoid bacillus, the pneumococcus, and several other micro-organisms have been found in phlebitis. In the

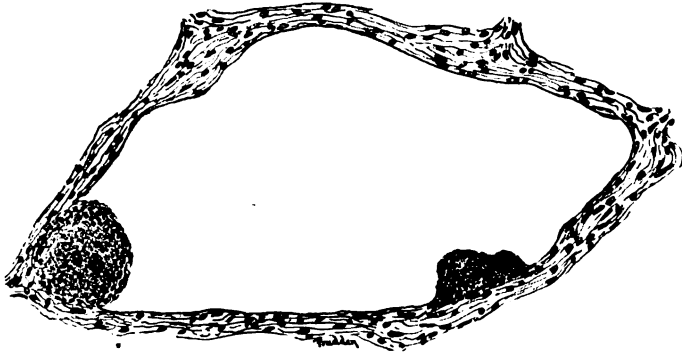


FIG. 357.—TUBERCULOUS PHLEBITIS.

The section is from one of the pulmonary veins in a child dead of acute general miliary tuberculosis.

phlebitis with thrombosis, which frequently complicates infectious diseases such as typhoid fever, pneumonia, etc., the bacteria present are frequently not those which are the excitants of the primary disease.

The most important results of phlebitis are usually those which depend upon the introduction into the blood of infectious or other emboli (see p. 28). The relationship between non-infectious thrombi and phlebitis is in many cases not clear.¹

Chronic periphlebitis results in thickening, principally of the outer coats of the veins, but the inner coats may also be involved. The surrounding tissue may also be thickened and coalesce with the walls of the vein. There may or may not be thrombosis.

Chronic endophlebitis is a not very common lesion, of the same general character as chronic endarteritis, with which it is often associated. More or less circumscribed patches of new connective tissue are formed in the inner coats, which may undergo fatty or calcareous degeneration.

¹ Consult in this connection *Welch* on "Thrombosis," Allbutt's "System of Medicine," vol. vi., p. 170.

Tuberculous inflammation of the walls of the veins may occur as an extension of the process from without or from a lodgment of the tubercle bacilli in the blood current on the intima (Fig. 357). This is not infrequent in the pulmonary veins, and Weigert has called attention to the fact that in acute miliary tuberculosis the growth of tubercle tissue into the lumina of these veins from tuberculous lymph-nodes is of frequent occurrence and readily explains the topography and mode of occurrence of the general disease. The tubercle bacilli which are present in the tuberculous tissue growing into the lumen of the veins find thus an easy distribution.¹

Syphilitic inflammation may involve the walls of the veins either as gummy tumors or as more diffuse thickenings.

TUMORS.

Primary tumors of the veins are rare. Small **leiomyomata** have been described in the saphenous and ulnar veins. A **myo-sarcoma** as large as a man's fist has been described, situated in the dilated vena cava inferior. The veins are not infrequently secondarily involved by **sarcomata** and **carcinomata**, and sometimes by **chondromata**. The thin walls of the veins offer comparatively little resistance to the encroachment of malignant tumors, which thus gain access to the circulation and may form metastases in various parts of the body.

PARASITES.

Echinococcus is sometimes found in the veins, having either developed there or perforated from without.

Two species of **distoma** (*liver fluke*) occur in man. *D. hepaticum* occurs rarely and, while usually found in the bile-ducts, may occur in the vena cava. *D. hæmatobium* is very common in man in Egypt and in other parts of Africa, and usually occurs in the portal vein or its branches, and frequently in other veins.

The Capillaries.

The walls of the capillaries are so thin and so intimately connected with the surrounding tissues that their lesions are studied most appropriately among the diseases of the several organs. Dilatation of the new-formed capillaries in tumors, granulation tissue, etc., fatty amyloid and hyaline degeneration of their walls, and capillary aneurisms, may be mentioned here as readily observed lesions occurring under a variety of conditions. Angiomas and telangiectases, usually congenital, are occasionally seen.

The changes which we assume to occur in the walls of the smaller veins and capillaries in exudative inflammation, by reason of which fluids and blood cells pass through them, are not yet sufficiently understood to be described with definiteness.

¹ See references under "Miliary Tuberculosis," p. 252.

The Lymph-Vessels.

General Characters of the Lymph-Vessels.

The smaller lymph-vessels can hardly be treated as independent structures, since their walls are so closely joined with the tissues through which they pass. It is perhaps wiser to follow the suggestion of Adler and Meltzer¹ and call the spaces of the connective and other tissues into which transudations from the smaller blood-vessels takes place, not lymph radicles or "lymph capillaries" as is commonly done, but to consider them tissue spaces from which the transudates of varying composition are gathered into the lymph-vessels. But the larger lymph-vessels we find the seat of various more or less independent lesions.

LYMPHANGIECTASIS.

Dilatation of the lymph-vessels occurs under a variety of conditions. It may be congenital, or it may be due to some hindrance to the flow of lymph onward—*es* by pressure from any cause, or from the occlusion of the vessels by inflammation. If the dilated vessels form a circumscribed mass, this is often called a **lymphangioma** (Fig. 240). In certain forms of *elephantiasis* and in *macroglossia* the dilatation of the lymph-vessels is an important factor. Its occurrence is not infrequent in the labia, prepuce, and scrotum. Dilatation of the chyle vessels may occur in the mucous membrane of the intestine and in the mesentery. Filial lymphatic varix is of occasional occurrence.²

Obstruction of the thoracic duct may be due to tumors,³ or enlarged lymph-nodes, or inflammatory processes in the mediastinum; to aneurism, to thrombosis of the left innominate vein, to insufficiency of the tricuspid valve; or to inflammatory processes in the wall of the duct. It may occur under various other conditions. It may be compensated by collateral lymphatic anastomoses, or it may lead to various lymph-angiectasæ and to transudation of lymph. Thus chylous ascites may occur.

Congenital doubling or division and other abnormalities of the thoracic duct are recorded.⁴

LYMPHORRHAGIA.

If through injury, necrosis, or other pathological process, the walls of the lymph channels suffer solution of continuity the lymph may escape into surrounding tissues or spaces. Thus upon the surface of the skin or into loose connective-tissue spaces or into the great body cavities, lymph may be poured out. A chylous hydrothorax or chylous ascites may occur from a rupture of the thoracic duct or its radicles.

THROMBOSIS.

Thrombi may form in the lymph-vessels by the coagulation of the lymph or by the deposition of fibrin on the walls of the vessels at the seat

¹ Adler and Meltzer, Jour. Exp. Med., vol. i., p. 482, 1896.

² See Opie, "Filarial Lymphatic Varix," Trans. Assn. Am. Phys., vol. xvi., p. 331, 1901.

³ For bibliography of carcinoma involving the thoracic duct see A. H. Smith, Med. Record, vol. lvi., p. 813, 1899.

⁴ Butler, Jour. Med. Res., vol. x., p. 153, 1903, bibl.

of degeneration or inflammation. These lymph thrombi are formed largely of fibrin and leucocytes. Such thrombi may cause disturbances of the lymph circulation or portions of them may become detached, forming emboli.

INFLAMMATION. (Lymphangitis.)

Acute Infective Lymphangitis.—Inflammation of the larger lymph-vessels is usually secondary and often connected with an infected wound or injury. Owing to the entrance into the lymph trunk of bacteria or other infectious agents, poison of venomous reptiles, insects, etc., the vessels, sometimes for a considerable distance away from the wound, become red, tender, and painful. Under these conditions the appearances which the vessels present vary. In some cases the redness disappears after death and we find no appreciable alteration. In other cases, the walls of the lymph-vessels are more or less densely infiltrated with pus cells, there is proliferation of the endothelium, and the lumen may contain variable quantities of pus and fibrin and desquamated degenerated endothelium. The vessel may be occluded by a thrombus. The tissue about the vessels may also be infiltrated with serum and pus. These lesions may undergo resolution and the vessel be restored to its normal condition; or the vessel wall and surrounding tissue may die or become involved in abscess; or new connective tissue may form in and about the vessel, sometimes with obliteration of its lumen. The associated lymph-nodes may participate in the inflammatory process.

Tuberculous Lymphangitis.—Tuberculous inflammation occurs both in large and small lymph-vessels. Miliary tubercles and diffuse tubercle tissue may form in the walls and project into the lumen of the larger trunks; or in the smaller vessels the new growth may entirely fill the lumen, and grow within it, with more or less involvement of the walls. This may occur independently, but it is most frequently seen in connection with tuberculous inflammation of adjacent tissues. Thus from tuberculous lymph-nodes in the vicinity of the thoracic duct there may be a direct extension of the tuberculous inflammation, an involvement of the walls of the duct, and a growth of tubercle tissue into its lumen. Such growths in the thoracic duct have been shown by Weigert to occur in acute general miliary tuberculosis (see p. 252). In the vicinity of tuberculous ulcers in the intestines, furthermore, we often see the subserous lymph-vessels, which pass from the vicinity of the ulcers, distended with the products of tuberculous inflammation and looking like dense white knobbed cords (Fig. 435).

Syphilitic lymphangitis not infrequently occurs in the vicinity of syphilitic ulcers in the primary stage. In later stages there may be thickening of the walls of the vessels and the development of gummy tumors in and about them.

TUMORS.

The relation of the endothelium of the lymph-vessels and spaces to **endotheliomata** has been already mentioned in the section on Tumors.

The dissemination of malignant tumors through the lymph channels is of frequent occurrence, and is particularly marked in the case of carcinoma. In the vicinity of carcinomata the lymph-vessels are not infrequently crowded with the tumor cells, forming white, irregular cords; or small masses of the tumor cells may be found in the lymph-vessels, either near to or remote from the tumor. White, irregular networks are often formed in this way beneath the pleura in carcinoma of the lung, or beneath the capsule of the liver. Transverse sections of lymph-vessels thus distended show sometimes swelling and detachment of the endothelium and a crowding of the lumen with tumor cells.

CHAPTER VI.

THE RESPIRATORY SYSTEM.¹

The Nose and its Associated Cavities.

THE mucous membrane lining the nose under normal conditions cleanses from dust the air which impinges upon and sweeps across it in respiration. It is in this way exposed to various deleterious agencies. It is subject also to such sudden changes of temperature as may involve great and abrupt alterations in the condition of its blood-vessels.

MALFORMATIONS.

Absence or deformity of the nose or some of its parts, deviations of the septum, clefts, usually associated with cleft palate and harelip (Figs. 175 and 176), are among the more frequent of the congenital anomalies of the nose.

HÆMORRHAGE. (Epistaxis.)

This may result from injury; it may be an expression of local or general hyperæmia from cardiac or vascular lesions, obstruction of vessels, etc. It not infrequently occurs in an early stage of acute infections, such as typhoid fever. It may accompany general conditions such as hæmophilia, pernicious anæmia, etc. Epistaxis may result from lesions of the nasal mucous membranes, ulcers, telangiectasis, etc.

INFLAMMATION. (Rhinitis.)

Acute catarrhal inflammation is common and often associated with a similar process in the pharynx and larynx. There is at first a hyperæmic swelling followed by an increased production of mucus and transudation of serum from the blood-vessels; emigration of leucocytes and desquamation of epithelium may follow. This and other inflammatory processes may extend to the frontal sinuses and the antrum, where the

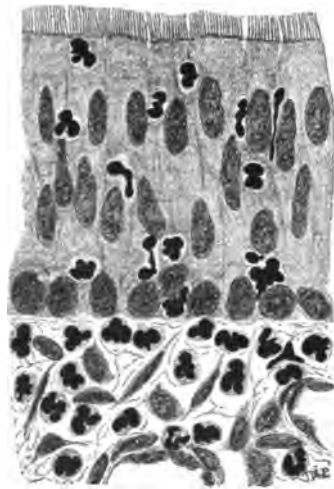


FIG. 358.—CATARRHAL INFLAMMATION OF THE MUCOUS MEMBRANE OF THE ANTRUM.

Showing migration of leucocytes through the epithelium.

¹For general considerations relating to the lungs see p. 593.

exudates may collect (Fig. 358). As the process resolves, the exudation ceases, the epithelium regenerates, and the mucosa is restored to its normal condition.¹

Pseudo-membranous inflammation, either simple or diphtheritic, may involve the nasal cavities. Phlegmonous inflammation involving adjacent parts is of occasional occurrence. Bacteria apparently play an important part as excitants of acute catarrhal and pseudo-membranous inflammation.²

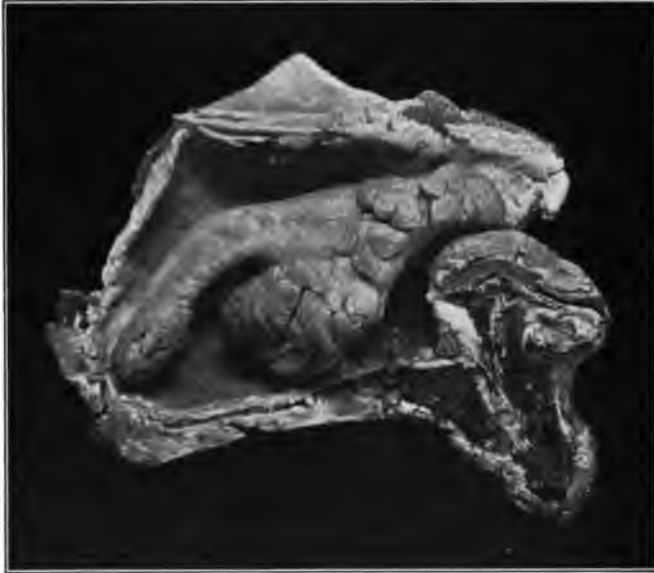

FIG. 359.—MUCOUS POLYP OF THE NOSE.

Chronic catarrhal inflammation may follow the acute form, and is marked by hyperplasia of the fibrous tissue in the submucosa, often followed by atrophy of the mucosa. Ulceration of the mucosa may occur; the exudate may assume a fetid character. A hyperplasia of the mucosa may lead to the formation of the so-called mucous polyps³ (Figs. 359 and 360). These often contain hyperplastic mucous glands and they are often œdematous.

Tuberculous and syphilitic inflammation with the usual morphological characters of these processes are common in the nasal cavities.

¹ For a study of the pollen of plants as excitants of hay fever see *Liefmann, Zeits. f. Hyg., etc. Bd. xlvii., p. 153, 1904*, and for *résumé* with Dunbar serum treatment see *Glegg, Jour. of Hyg., vol. v., p. 369, 1904*.

² For a study of the bacteriology of nasal inflammation see *Howard and Ingersoll, Am. Jour. Med. Sci., vol. cxv., p. 520, 1898*. See also for bacteria of the nose, *Neumann, Zeits. f. Hyg., etc., Bd. xl., p. 33*, also *Hasslauer, Cbl. f. Bak., I. Abt. Ref., Bd. xxxvii., p. 1, bibl., 1906*. For a study of the lymph-vessels of the nose and pharynx see *Most, Arch. f. Anat. u. Phys., 1901, p. 75*.

³ For a summary of facts concerning the nature of the ordinary nasal polyps see *Wright, Med. Record, vol. lix., p. 132, 1901, bibl.*

TUMORS.

Aside from the **nasal polyps** which may be adenomatous in character, the most common tumors are **epithelioma** and **sarcoma**.

Dermoid cysts have been described.

Adenoids.—In children, especially when ill-nourished, there is often a hyperplasia of the lymphoid tissue of the posterior pharyngeal region. This is often associated with nasal or pharyngeal catarrh. These new

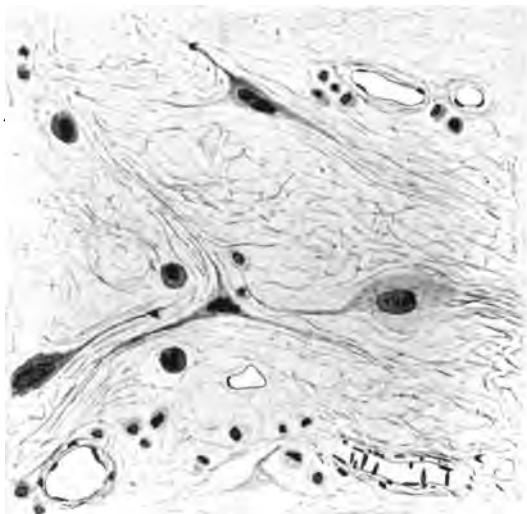

FIG. 360.—MUCOUS POLYP OF THE NOSE.
Showing branching cells with loose delicate stroma containing much fluid.

growths form irregular projections or lobular masses (Figs. 359 and 360), often blocking the naso-pharyngeal passage. These hyperplasiæ are covered with squamous or columnar epithelium. They are called “adenoids.” Some of these growths are tuberculous; others, without obvious morphological tubercles, contain tubercle bacilli.¹

The Pharynx.

The lesions of the pharynx similar to those just described as involving the nasal cavities are reviewed on p. 647.

The Larynx and Trachea.**Malformations.**

The larynx and trachea may be absent. The larynx may be abnormally large or small; the epiglottis also may be too large or too small, or may be cleft. There may be communications between the trachea and the œsophagus, and then the pharynx generally ends in a cul-de-sac, and the œsophagus opens into the trachea. There may

¹ *Lartigau and Nicoll, Amer. Jour. Med. Sci., vol. cxxiii., p. 1031, 1902.*

be imperfect closure of the original branchial arches, so that there are fissures in the skin leading into fistulæ which open into the pharynx or trachea. The fissure in the skin is small and is situated about an inch above the sterno-clavicular articulation, usually on one or both sides, more rarely in the middle line. Individual cartilages, as the epiglottis, or one or more rings of the trachea, may be absent, or there may be supernumerary rings. The trachea may divide into three main bronchi instead of two, and in that case two bronchi are given off to the right lung and one to the left. The trachea may be on the left side of the œsophagus or behind it.

HÆMORRHAGE.

In trauma and acute inflammatory processes, in syphilis and tuberculosis, and when tumors are present, especially carcinoma and some forms of vascular papilloma, there may be hæmorrhage from the larynx. It may occur also under the general favoring conditions, such as hæmophilia, scurvy and various abnormal conditions of the circulation leading to local or general hyperæmia.¹

ŒDEMA OF THE GLOTTIS.

This is a condition in which there is an accumulation of serous fluid in the submucosa of the upper part of the larynx. This may be due to simple circulatory disturbances, local or general, or it may be inflammatory in character. The greatest accumulation of fluid is in places in which the submucous tissue is abundant and loose in texture, as in the posterior wall of the epiglottis, in the ary-epiglottidean folds, and in the false vocal cords. The swelling of these parts may be so great as to occlude the air passage. After death the œdematous swelling may largely disappear, but the mucous membrane may be left unusually wrinkled and flabby.

Œdema of the glottis is comparatively infrequent in association with such heart, kidney, and lung lesions as lead to general œdema. It is, on the contrary, frequent in connection with various forms of laryngeal inflammation. It may occur in drunkards or others who are poisoned and fall asleep in a sitting posture so that the head drops sharply forward with constriction of the neck. Under these conditions the individual may die from asphyxia with no obvious lesion accounting for it other than the œdema of the glottis.

INFLAMMATION. (Laryngitis.)

Acute Catarrhal Laryngitis.—This occurs as an independent process in common "colds." It may be a complication of the infectious diseases, or may be induced by the inhalation of irritating vapors and of hot steam and smoke. The inflammation varies in its intensity in different cases. The mucous membrane is at first congested, swollen, and dry; then the mucous glands become more active and an increased quantity of mucus is formed. There is desquamation of the superficial

¹ For a study of hæmorrhage of the larynx see *Rhodes*, Jour. Amer. Med. Assn., vol. xliii., p. 1284, 1904.

epithelial cells, while through emigration leucocytes may infiltrate the submucosa, and together with mucus and desquamated epithelium form the exudate. There may be œdema of the glottis. All of these lesions may disappear with complete restoration of the mucous membrane.

After death the congestion of the mucous membrane marking an acute form of the disease frequently disappears altogether.

Chronic Catarrhal Laryngitis.—This may follow repeated attacks of acute inflammation or be the result of the persistent inhalation of harmful substances. It may accompany chronic hyperæmia from cardiac or vascular lesions. It may be associated with syphilis and tuberculosis.

The surface of the mucous membrane is dry or coated with mucus. The epithelium is thickened in some places, thinned in others, or in places entirely destroyed. The submucosa may be infiltrated with cells,

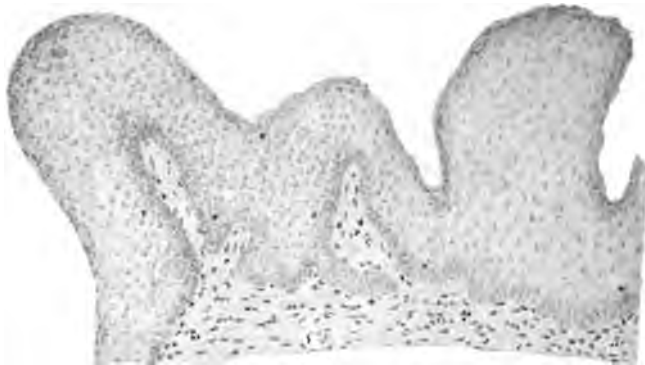

FIG. 361.—LOCALIZED HYPERPLASIA OF THE EPITHELIUM AND SUBMUCOUS CONNECTIVE TISSUE OF THE FALSE VOCAL CORDS.

The section shows a portion of a small, rough wart-like or papillary growth.

diffusely thickened, or form little papillary outgrowths; it may be thinned, or necrotic and ulcerated.

The mucous glands may be swollen and prominent. The inflammation may extend to the perichondrium of the cartilages, which may become necrotic. In chronic laryngitis there may be a more or less diffuse thickening of the epithelium, often associated with a hyperplasia of the submucous tissue. This is called *pachydermia diffusa*. A similar process, if localized, may lead to larger and smaller wart-like excrescences—*pachydermia verrucosa* (Fig. 361).

Pseudo-membranous Laryngitis (Croupous Laryngitis).—This occurs most frequently as the characteristic local lesion in diphtheria, of which the *Bacillus diphtheriæ* is the excitant (see p. 282). It may, however, be incited by the *Streptococcus pyogenes* and other bacteria, and not infrequently accompanies other infectious diseases, scarlatina, typhoid fever, and the exanthemata (see p. 303). The false membrane may be continuous with a similar structure in the pharynx, and it may extend down into the bronchi (Fig. 362).

Phlegmonous Laryngitis.—Suppurative inflammation involving the mucosa and submucosa is usually secondary to catarrhal, croupous, tuberculous, or syphilitic laryngitis; or it may be associated with pyæmia, erysipelas, smallpox, or typhoid fever. It may follow mechanical injury from a foreign body. It is not uncommon on the posterior surface of the epiglottis or in the ary-epiglottidean folds, and may be associated with œdema of the glottis. Abscesses may form which rupture into the larynx, or they may extend into the neck or the pharynx or œsophagus.

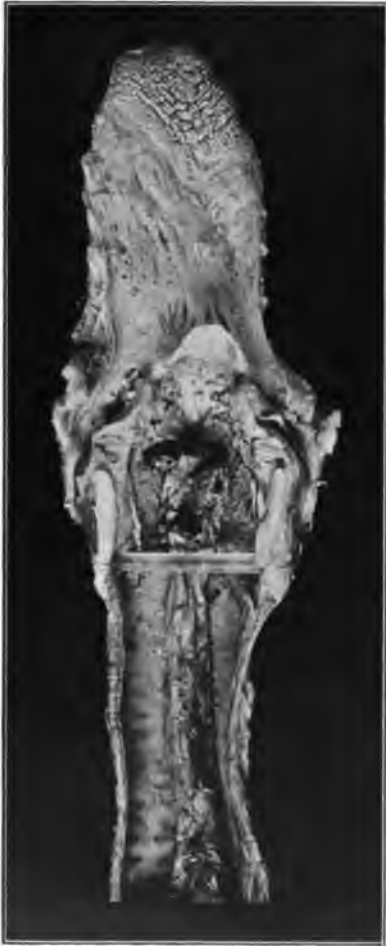

FIG. 362.—DIPHThERIA OF THE LARYNX AND TRACHEA.

The membrane extends from the epiglottis down to the bifurcation of the trachea.

Tuberculous Laryngitis.—This lesion is most frequently associated with pulmonary tuberculosis. Early in the process there is a formation in the submucosa of miliary tubercles together with more or less new small-celled tissue; with this is a catarrhal inflammation with an exudate of mucus, pus cells, and desquamated epithelium.

As coagulation necrosis of the subepithelial tubercles occurs, ulcers are formed, often with an increase of the catarrhal exudate. The process may extend so as to involve the walls of the larynx, and necrosis of the cartilages may follow. Adjacent ulcers may become confluent so that considerable areas of the mucous membrane may be destroyed (Fig. 363).

Syphilitic Laryngitis.—This form of inflammation may have the ordinary characters of an acute or chronic catarrhal inflammation, or it is productive in character with the formation of new tissue in the stroma of the mucous membrane. This new tissue is principally composed of small cells, which often degenerate

and become necrotic. In this way the mucous membrane of the larynx and the tissues beneath are thickened in some places and destroyed in others, giving rise to erosions and ulcers. These changes are especially marked in the upper portion of the larynx. If the perichondrium be involved there may be necrosis of the laryngeal cartilages. Owing to

the cicatricial contractions of healed syphilitic ulcers there may be great deformity of the larynx.

Lesions of the **trachea** are often associated with those of the larynx and are in general similar in character.

TUMORS OF THE LARYNX AND TRACHEA.

Retention cysts of the mucous glands of the *larynx* may form sacs projecting into its cavity.

Papilloma, single or multiple, is the most common form of benign tumor of the larynx (Fig. 364). It is most frequent upon the vocal cords and is usually associated with chronic inflammation. **Adenoma**, **fibroma**, **lipoma**, **myxoma**, and **angioma** occasionally occur. **Chondromata**

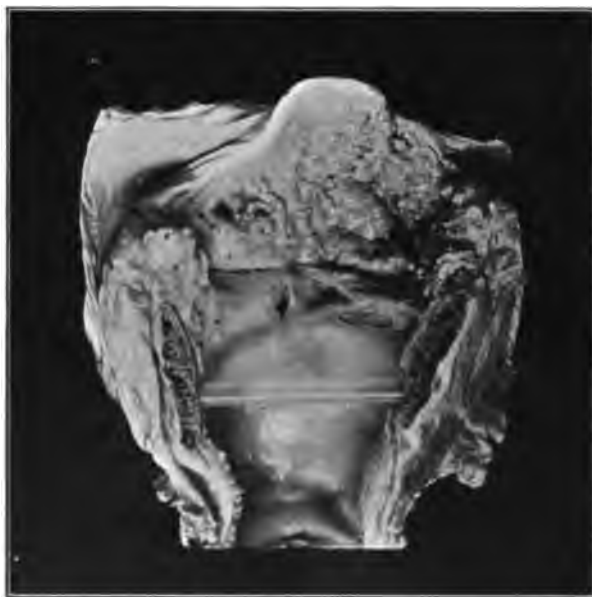

FIG. 363.—TUBERCULOUS LARYNGITIS.

The posterior surface of the epiglottis and the adjacent tissue are involved in tuberculous ulcers.

grow from the normal cartilages and are usually multiple and sessile. They may project into the cavity of the larynx.

Fusiform or spheroidal-celled **sarcomata** of the larynx have been seen in a considerable number of cases, both in children and in adults.

Carcinomata, usually the epitheliomatous type, may originate in the larynx, most commonly upon the false vocal cords. But from adjacent structures, usually from the œsophagus, cancer may invade the larynx.

In the *trachea* tumors are of rare occurrence, but occasional examples of growths similar to those in the larynx have been found. Tuberculous

and otherwise altered bronchial lymph-nodes may by ulcerative processes enter and obstruct the trachea.

Single or multiple **amyloid masses**, often associated with cartilage, have been described in the larynx and trachea.¹

The Bronchi and Lungs.

The Bronchi.

HÆMORRHAGE.

In hæmorrhage from the bronchi the source of the blood is often to be sought in the parenchyma of the lung (see p. 595) or in a ruptured aneurism. But hæmorrhage from the bronchial walls may occur in tuberculous or other forms of ulceration, chronic bronchitis, malignant tumors, etc.

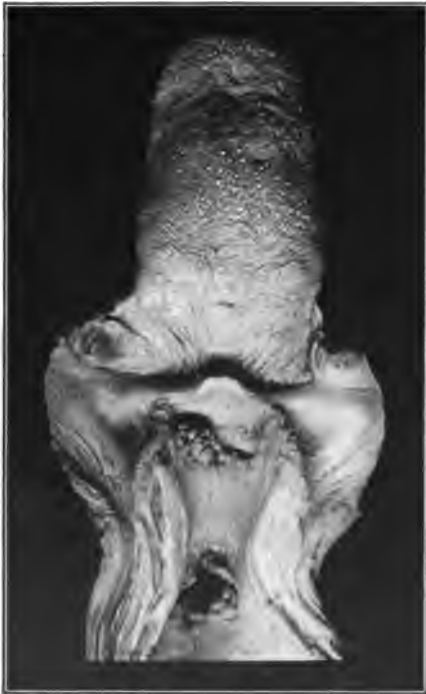

FIG. 364.—PAPILLOMA OF THE LARYNX.

The left vocal cord is involved in the lobulated growth. A tracheotomy opening is seen below the tumor.

INFLAMMATION. (Bronchitis.)

Acute Catarrhal Bronchitis.—

This is frequently associated with a similar process in the trachea. It is characterized by hyperæmia and swelling of the mucous membrane, with the formation of exudate, which usually consists largely of mucus formed by the hypersecretion of the mucous glands or degeneration of the epithelial cells. Mingled with this are exfoliated and more or less degenerated epithelium from the mucous membrane, leucocytes from the dilated vessels of the submucosa, varying numbers of red blood cells, and bacteria.

The microscopic appearances differ in different parts of the bronchial tubes in accordance with the differences in structure. Mucous glands, when these are present, may reveal great functional activity, and their

ducts may be distended with mucus which, often mingled with exfoliated and degenerated cells, streams out upon the surface. Swelling and proliferation of the connective-tissue cells and endothelium of the vessels of the submucosa, œdema, and emigration from the dilated vessels are

¹ See *Manasse*, *Virch. Arch.* Bd. clix., p. 117, 1900.

often marked. The leucocytes may be seen making their way through the epithelium into the other exudates upon the surface. The epithelium may be loosened, single or clustered cells falling off here and there, or shreds of cells may exfoliate together (see Fig. 365).¹ The deeper spheroidal epithelia, the so-called mother cells from which the new ciliated cells on the surface are formed in both physiological and pathological regeneration, usually remain in place upon the basal membrane. In the small bronchi whose walls are thin, little else may be seen than an irregular exfoliation of the epithelium. On the other hand, the smaller bronchi may be much involved and their lumina filled with exudate; when this, which has been called "*capillary bronchitis*," occurs, the inflammatory process usually involves the adjacent and associated territories of lung tissue, constituting one of the important forms of broncho-

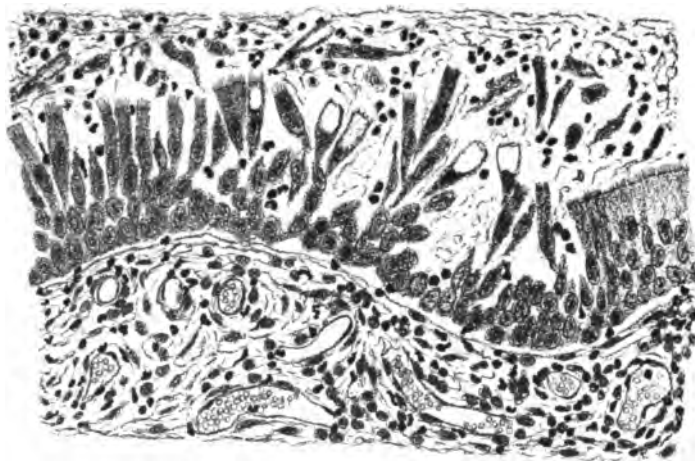


FIG. 365.—ACUTE CATARRHAL BRONCHITIS.

This section of a small portion of the bronchial wall shows considerable exfoliation of the epithelium, but many of the deeper so-called "mother cells" remain in place. There are swelling of the connective-tissue cells and congestion of blood-vessels in the submucosa, with oedema and emigration of leucocytes. Some of the leucocytes are passing through the epithelium to mingle with the mucous exudate and exfoliated cells in the lumen of the bronchus. Some of the ciliated cells show the "beaker" shape with a homogeneous interior indicating the production of mucus within them.

pneumonia. In some forms of bronchitis the exudate may consist largely of pus—"*purulent bronchitis*."

Atelectasis of corresponding tracts of the lung may follow the occlusion of the bronchi with exudate. As recovery advances, the submucosa assumes its normal thickness and character and the epithelium is regenerated from the cells of the deeper layers.

Various forms of *bacteria* may be associated with acute bronchitis, and are presumably the excitants under favorable conditions of the lesions; the etiological relationship has, however, not yet been experimentally established. The most common forms of bacteria are *Streptococcus*

¹ For a study of physiology and pathology of ciliated epithelium of the respiratory organs see *Lommel*, *Deutsch. Arch. Klin. Med.*, xciv., 365, 1908.

pyogenes, the pneumococcus, Staphylococcus aureus, and the influenza bacillus.¹

Chronic Catarrhal Bronchitis.—This form of bronchitis may be the sequel of one or more attacks of acute bronchitis. More frequently it is associated with emphysema, heart disease, interstitial pneumonia, phthisis, pleuritic adhesions, or the inhalation of irritating substances. There is in most cases a constant production of mucus, pus, and serum in considerable quantities, and these inflammatory products may have a very foul odor. Less frequently these products are very scanty—*dry catarrh*. The epithelium is deformed and desquamating, with a production of new cells in the deeper layers. There may be epithelial

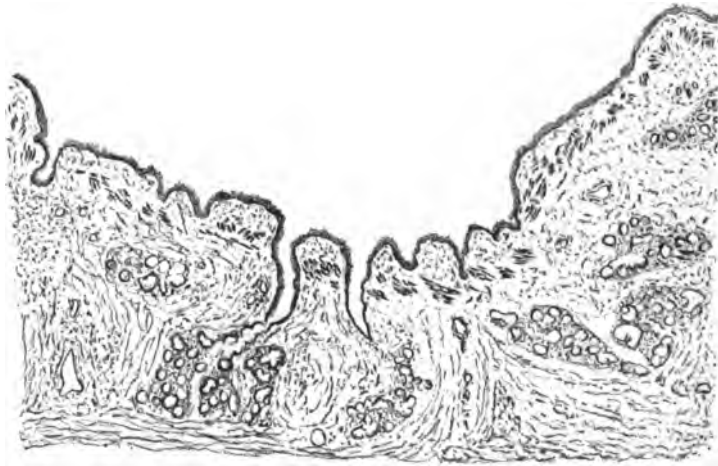


FIG. 366.—CHRONIC BRONCHITIS WITH MODERATE BRONCHIECTASIA.

This transverse section of a portion of the wall of a dilated bronchus shows atrophy of the epithelium; fibrous hyperplasia of the submucosa with the formation of longitudinal ridges on the interior of the tube (cut across in this section); thickening of the wall of the bronchus and atrophy of the mucous glands.

hyperplasia or atrophy; the mucous glands are large or atrophied; there may be hyperplasia or atrophy of the submucosa; the muscularis may show hypertrophy or atrophy. These changes in the fibrous and muscular elements of the walls lead to the so-called "trabeculation" of their inner surfaces (Fig. 366). Obliterating arteritis of the associated vessels may occur. These changes in the walls of the bronchi may lead to bronchiectasia.

Acute Pseudo-membranous Bronchitis—Croupous Bronchitis—may occur with croupous laryngitis, as a lesion of diphtheria, with lobular pneumonia, and sometimes without these associations. The bronchi are lined or filled with a mass of fibrin, pus, and desquamated epithelium. Fibrin and pus may also be found beneath the epithelium and infiltrated in the stroma.

¹ For a study of the bacteria found in bronchitis see *Ritchie*, Jour. Path. and Bact., vol. vii., p. 1, 1901; also *Karcher*, Deut. Arch. f. klin. Med., Bd. lxxxiii., p. 244, 1905; also reference to bacteria in lungs, p. 614.

Chronic Fibrinous Bronchitis is attended with the formation in one or more bronchi of masses of fibrin which are expectorated by the patient in the form of branching casts of the bronchi (Fig. 367). After death the bronchi are said to be but little altered from the normal.¹

Curschmann has described under the name "*bronchiolitis exudativa*" a form of bronchitis in which small threads and bands of gray or yellow, partly transparent, coagulated material are formed in the small bronchi—"Curschmann's spirals." These sometimes occur in pneumonia. In different forms of bronchitis, especially in those associated with asthma,

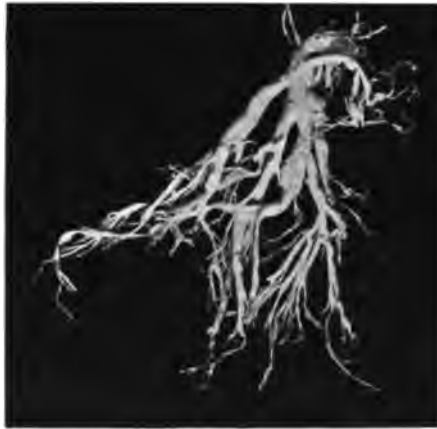

FIG. 367.—CHRONIC FIBRINOUS BRONCHITIS.

Fibrinous casts of the bronchi, similar to those shown in the photograph, were coughed up at irregular intervals for several years.

the exudation may contain numerous octahedral bodies—Charcot-Leyden crystals—and also a very large number of eosinophile cells.

Tuberculous Inflammation of the bronchi frequently occurs in connection with pulmonary tuberculosis. The lesion may be miliary or larger involvement of the walls may lead to ulceration.

Syphilitic Inflammation may lead to ulcers and to distortions and stenosis through cicatrization.

BRONCHIECTASIA.

Dilatations of the bronchi may be cylindrical, fusiform, or sacculated. The sacculated dilatations are usually the largest. These communicate with one side of the bronchus. The peripheral portion of the bronchus may be obliterated; the bronchus leading to the cavity may be of normal size, or dilated, or stenosed, or even completely obliterated. Such sacculated dilatations may reach a very large size and may communicate with each other. Dilatations are apt to occur under conditions which interfere with the integrity of the bronchial wall.

¹ For a résumé and bibliography see *Bettmann*, *Am. Jour. Med. Sci.*, vol. cxiii., 1902, p. 304.

In acute general bronchitis and broncho-pneumonia in children, cylindrical dilatation of a number of the medium-sized bronchi often occurs.

In the persistent broncho-pneumonia of children such dilatations may reach a still greater development.¹ Chronic bronchitis may lead to cylindrical or sacculated dilatations, sometimes of great size.

Occlusion of some of the bronchi, consolidation of portions of the lung, and extensive pleuritic adhesions may also lead to bronchiectasia (Fig. 368).

The walls of bronchiectatic cavities may be lined with mucous membrane, which, however, is apt to undergo various changes as the process

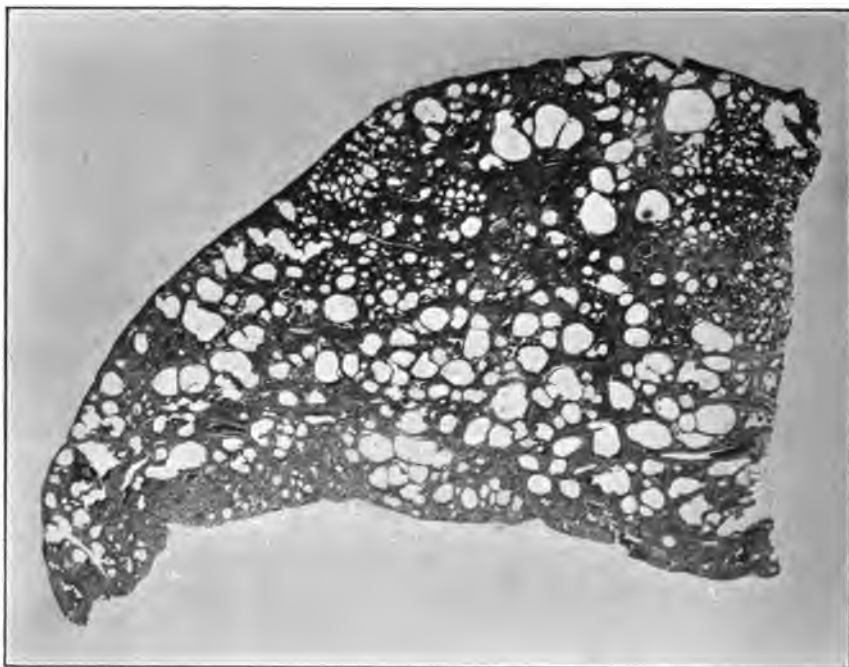


FIG. 368.—MULTIPLE BRONCHIECTASIAE WITH INTERSTITIAL PNEUMONIA.

Portion of anterior free border of lungs. From an adult after unresolved lobar pneumonia

advances. Thus the subepithelial layer may be vascular and cellular and thrown into folds, or it may be thin and dense. The epithelium is often irregular, sometimes irregularly thickened, sometimes thin, or it may be largely absent. The glands, muscle, and cartilages of the walls of the bronchi may disappear through atrophy. The presence of certain forms of bacteria in the exudate in bronchiectasia may lead to offensive putrefactive process and even to gangrene. Moulds may be present.

In acute and chronic phthisis the tuberculous inflammation of the

¹ For a study of bronchiectasia in children see *Lapin*, Arch. f. Kinderheilkunde, Bd. xxxvii., 1903, p. 406.

walls of the bronchi often gives rise to sacculated dilatations, which expand with time and become still larger by the destruction of the adjacent lung tissue—tuberculous bronchiectasia.

TUMORS.

Primary tumors of the bronchi are rare. **Lipoma**, **chondroma**, and **fibroma** have been observed. **Sarcoma** is rare, but may occur, especially

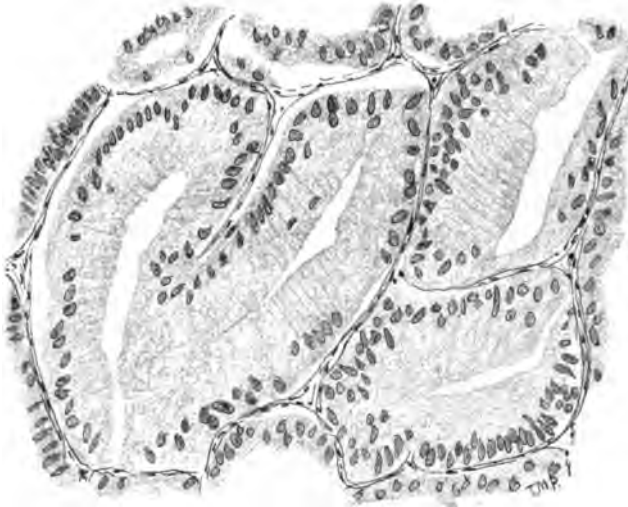


FIG. 369.—PRIMARY ADENOMA OF THE BRONCHI.

in spheroidal-cell forms, or as an extension of similar growths in the mediastinum. **Adenoma** (Fig. 369) and **primary carcinoma** are rare.

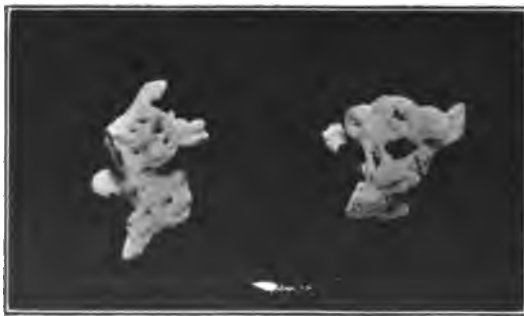

FIG. 370.—LUNG STONES. (*From a case of Tuberculous Bronchitis.*)
These calcified masses were found in the dilated bronchi.

Secondary carcinoma is not uncommon and may also involve the trachea or the lungs.

Occlusion of bronchi, partial or complete, may occur from tumors,

polypi, metazoan parasites, foreign bodies, exudates, etc., or through obstructive lesions in the walls.

Calcified masses called "lung stones" (Fig. 370) may be found in the bronchi.

LESIONS OF THE TRACHEAL AND BRONCHIAL LYMPH-NODES.

The tracheal and bronchial lymph-nodes may be the seat of a variety of lesions which, owing to their situation, as well as for other reasons,

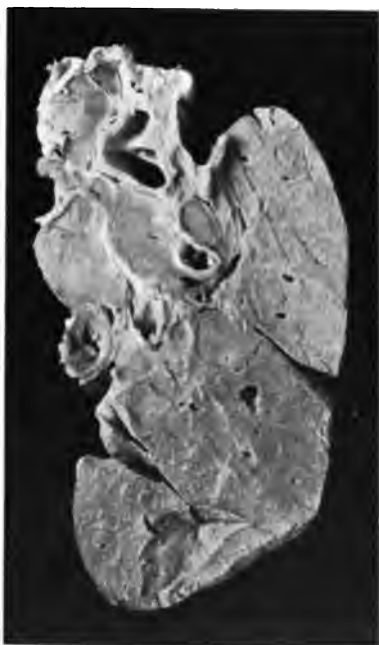

FIG. 371.—TUBERCULOUS AND CASEOUS BRONCHIAL LYMPH-NODES.

The nodes are much enlarged and press upon the larger bronchi.

are of considerable practical importance. They may be enlarged from hyperplasia in acute infectious diseases; by the development in them of tumors; in leukaemia and with especial frequency in tuberculosis (Plate III.). They may become pigmented from inhaled coal or other dust and may atrophy or become fibrous or calcified.¹ In cheesy degeneration following tuberculosis (Fig. 371), or in suppurative inflammation, perforation may take place into the air passages, the oesophagus, the pulmonary blood-vessels, or aorta, or into the pericardial or pleural cavities;² in this way hæmorrhage or secondary inflammatory processes or gangrene may occur. Death may occur from pressure upon the trachea by tumors of the adjacent lymph-nodes. Sudden death from asphyxia may result from perforation into the trachea. Pressure upon the pulmonary veins may lead to pulmonary oedema. The bronchial lymph-nodes are very important as distributing centres of infectious micro-organisms, and particularly as points of lodgment of tubercle bacilli, which have been

gathered from the pulmonary air spaces from the pharynx or elsewhere.³

¹ For the association of pigmentation and tuberculosis of the bronchial lymph-nodes and the pleura see p. 640. For a study of alleged intestinal origin of lung pigment, see *Montgomery, Jour. Med. Res.* xxiii, 111, 1910.

² See *Sternberg, Wiener klin. Wochenschrift*, 1905, p. 1214.

³ Consult for summary of lesions of bronchial lymph-nodes *Hall, Phila. Med. Jour.*, Dec. 1st, 1900, bibl. See also concerning tuberculosis reference *Northrup and Bovaird*, p. 487, and *Harbitz, Jour. Inf. Dis.*, vol. ii., p. 143, 1905. See also statistics of *Hand, Phila. Path. Soc.*, vol. vi., p. 132, 1903. For an excellent *résumé* concerning normal and pathological tracheal and bronchial lymph-nodes see *Marfan* in *Boucharl and Brissaud's "Traité de Médecine,"* t. vii., p. 525; also *Zuber* in *Grancher, Comby, and Marfan's "Traité des Maladies de l'Enfance,"* t. iv., p. 235. For a study of the relation of the bronchial lymph-nodes to the lymph-vessels of the thorax see *Woleminsky, Berl. klin. Woch.*, 1905, p. 743. For a study of the relationship of the cervical and bronchial lymph-nodes see *Beitzke, Virch. Arch.*, Bd. clxxxiv., p. 1, 1906.

The Lungs.

Malformations.

One or both lungs may be wanting or only partially developed. One lung is sometimes converted into a number of sacs formed of dilated bronchi, while the lung parenchyma is undeveloped. Supernumerary bronchi are recorded.

The lobes may be subdivided by deep fissures, accessory lobes may be present, or an accessory lung may be present. An accessory lung in the abdominal cavity has been described.¹ There may be, with absence of part of the wall of the thorax, hernia of the lung. There may be transposition of the lungs, with similar changes in the position of the heart and the abdominal viscera.

INJURIES—PERFORATIONS.

Severe contusions of the thorax may produce rupture of the lungs, with extravasations of blood into the pleural cavities.

The lungs may be wounded by a fractured rib and by penetrating weapons and projectiles. Such injuries often lead to bleeding into the lung tissue, followed by inflammatory changes. The lungs, however, exhibit a considerable degree of tolerance for such injuries.

Collections of pus in the pleural cavities, the mediastinum, the liver, the spleen, the kidneys, and the peritoneal cavity may perforate the lungs. See also Hydro-pneumothorax.

DISTURBANCES OF CIRCULATION.

It is very useful to anticipate a study of the diseases of the lungs by an examination of the circulation in the lung of a curarized frog on the Thoma frog-plate (see p. 111). In no other way can one gain so vivid a conception of the complexity and abundance of the circulatory mechanism.

Anæmia.—The lungs may be anæmic in connection with a general anæmia of the body; or from compression of a part or a whole organ, as by pleural exudates, tumors, or new-formed fibrous tissue; from occlusions of blood-vessels or in atrophy of these in emphysema.

HYPEREMIA AND ŒDEMA.

Hyperæmia may occur as the result of the inspiration of irritating gases; from the presence of toxic substances in the blood; in early phases of inflammation, or as the result of such an occlusion of vessels in one part as causes its accumulation in another.

On the other hand, hyperæmia of the lung is often due either to some hindrance to the exit of blood through the pulmonary vein, such as mitral stenosis or insufficiency, or to enfeeblement of the ventricular contractions, as in fatty degeneration of the heart muscle or interstitial myocarditis. In the last hours of life the feeble action of the heart disposes to pulmonary congestion. The position of the body upon the back in bed favors an accumulation of blood in the posterior portions of the

¹Consult *Vogel, Virch. Arch.*, Bd. clv., p. 235, 1899, bibl.; also *Hammar, Ziegler's Beitr.*, Bd. xxxvi., p. 518, 1904.

lungs—*hypostatic congestion*. Hyperæmic lungs are in varying degrees darker and heavier than normal; an unusual amount of blood flows from the cut surface. Edematous fluid is often also present. Red blood cells often pass through the capillary walls in hyperæmia, and these with more or less exfoliated epithelium may be found in the air vesicles.

Chronic Congestion.—In prolonged hyperæmia of the lungs, notably in connection with lesions of the mitral and aortic valve, or degeneration or dilatation of the left ventricle, the veins and capillaries, especially the capillaries, become permanently distended, pouched, and elongated, so that they often stretch in loops into the air spaces (Fig. 372). Red blood cells find their way from the contorted vessels by diapedesis or small hæmorrhages into the air vesicles or interstitial tissue of the lung. Here

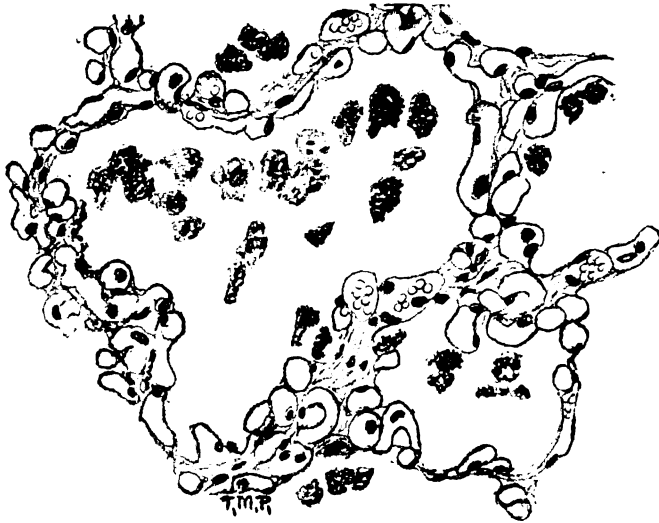
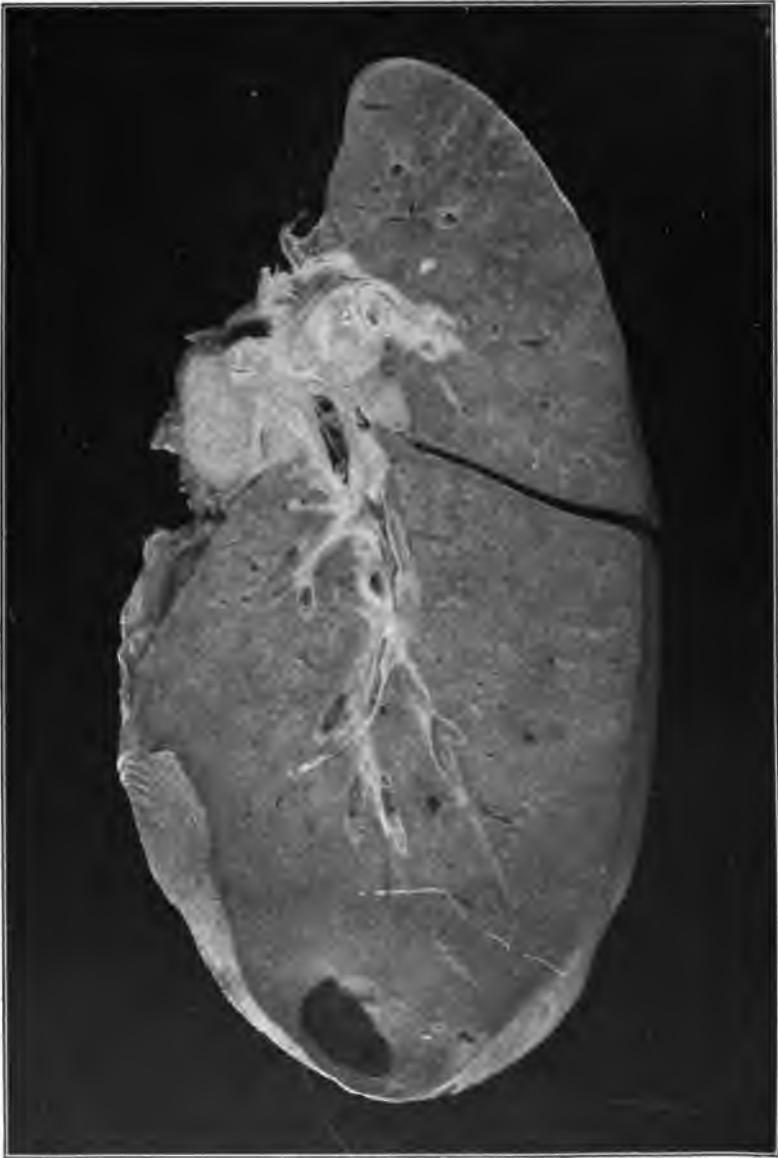
FIG. 372.—CHRONIC CONGESTION OF THE LUNG. (BROWN INDURATION.)


Showing dilated capillaries of the walls of the air vesicles and hæmatogenous pigment in the exfoliated epithelial cells of the air vesicles.

decomposition of the hæmoglobin leaves brownish pigment particles which may remain free or be taken into cells. In the air vesicles the epithelial cells usually desquamate in considerable numbers, and take up the pigment in varying amount. This pigment gives to the lungs a peculiar brownish pink or salmon color. The appearance of these lungs may be modified by hæmorrhagic infarctions, by pre-existing emphysema or œdema, or by exudative inflammation. Associated with these changes there is usually a new formation of fibrous tissue, so that the lung becomes indurated, leathery, and dry, and collapses less readily than normal. This condition is often called *brown induration* of the lung. This formation of fibrous tissue is analogous with that which occurs in other organs, such as the kidney and liver in chronic congestion. Emigration of leucocytes is not infrequently associated with diapedesis from the



Tuberculous Bronchial Lymph-Nodes.

The nodes are enlarged and caseous, with areas of commencing softening. An isolated tubercle in the lung tissue above the enlarged nodes indicates a local dispersion of the tubercle bacilli. The lung was hardened in alcohol.



dilated capillaries, and these, with the desquamated epithelium, may accumulate in the air vesicles.

ŒDEMA OF THE LUNGS.

This condition is rarely independent, but is usually associated with other lesions of the circulatory or respiratory systems. It may be circumscribed or involve one or both lungs. The lungs in pronounced œdema do not collapse, as is usual on opening the thorax. They may appear translucent. Fluid runs or is readily squeezed from the cut surfaces.

In œdema of the lungs the vesicles contain a clear, sometimes foamy albuminous fluid, occasionally tinged with blood, usually mixed with exfoliated vesical epithelium. Leucocytes and red blood cells may also be present. The œdematous fluid may be present in the bronchi and in the interstitial tissue of the lungs. Œdema is often associated with hyperæmia, and like this may vary in different parts of the lung. On the other hand, there may be extensive œdema without overfilled blood-vessels; these in excessive œdema may indeed be nearly empty and compressed. Œdema of the lungs may occur in general infections and intoxications, or in association with local inflammatory processes.

It may be associated with cardiac and renal lesions. It may be a part of general dropsy or exist independently of this. It frequently occurs in the last hours of life—agonal œdema. Œdema of the lung may occur suddenly without the obvious inciting accompaniments above noted, and may be fatal. Fatal œdema of the lungs may be associated with fat embolism.¹

The studies of Welch² show that with diminished force exerted by the left side of the heart, the vigor of the right remaining unimpaired, œdema of the lungs may follow.³

HÆMORRHAGE AND INFARCTIONS.

HÆMORRHAGE.

Hæmorrhages into the lung tissue and air spaces of the lungs may occur from trauma, from rupture of aneurism, in acute infectious diseases and intoxications, in scurvy and hæmatophilia, in asphyxia from brain lesions or other conditions, from tuberculous ulcerations involving the blood-vessels. Multiple ecchymoses may occur in fat embolism.

Hæmorrhage is of frequent occurrence in excessive hyperæmia of the lungs, notably in connection with mitral stenosis and insufficiency. Under these conditions the extravasation of blood may take place by diapedesis or by rhexis. The accumulations of blood may be single or

¹ See ref. fat embolism, foot-note, p. 34.

² Welch, Virchow's Archiv, Bd. lxxii., p. 375; *résumé* by Meltzer, Amer. Med., vol. viii., p. 391, 1904.

³ For a study of œdema of the lungs based on numerous cases, see Coplin, Proc. Path. Soc. of Phila., vol. ix., p. 77, 1906; also Riesman, Am. Jour. Med. Sci., vol. cxxxiii., p. 88, 1906. For a study of the disturbances of circulation in the lungs under various abnormal conditions see Esser, Centralbl. f. ges. Med., Jan. 26th, 1901, bibl.

multiple, localized or diffuse, dense and firm, or, when œdema is present, soft and fluid in character. During the last hours of life, owing to enfeeblement of the heart, extravasation of blood may occur which sinks to the posterior dependent portions of the lungs.

THROMBOSIS, EMBOLISM, INFARCTS.

As a result of thrombosis or embolism of the pulmonary artery, *hæmorrhagic infarcts* may be formed.

They are not very common in the lungs because the supply of blood is through both the pulmonary and bronchial arteries, so that even with stoppage of the pulmonary artery by a thrombus or embolus, hæmorrhagic infarcts are not necessarily formed. When, however, the pulmonary circulation is faulty as in various cardiac lesions, hæmorrhagic infarcts are more apt to form as the result of embolism or thrombosis of the pulmonary artery.

These infarcts are often multiple, usually circumscribed, and rounded or wedge-shaped, from the size of a walnut to that of an orange. They are of dark red color, hard and unaërated, with the air spaces distended with blood, and are often surrounded by a zone of inflammatory exudate. They may be situated in any part of the lungs, but are most common in the lower lobes. At the apices of the infarcts, the occluding thrombus or embolus may be discovered. When, as is usually the case, they are near the surface of the lungs, a circumscribed inflammation of the pleura often occurs. The air spaces within the infarcts are filled with blood and the capillaries distended.

Such infarcts may be followed by death; they may become gangrenous, or if the emboli or thrombi be not infectious, the blood may become absorbed, and, especially in the smaller forms which are more often due to embolism, they may be gradually changed into a smaller mass of pigmented fibrous tissue.

A large part of the lungs may be involved in hæmorrhage due to thrombosis of large trunks of the pulmonary artery. Hæmorrhagic infarctions from thrombosis or embolism are most frequent in lungs which are the seat of chronic congestion. The most common source of the emboli of the pulmonary artery is the right heart or peripheral thrombi.¹

ATELECTASIS.

In atelectasis the walls of the air spaces lie together, either because they are collapsed or compressed, or because, as in congenital atelectasis, the lungs, or portions of them, have not been expanded in respiration.

In fetal or *congenital* atelectasis defects in the respiratory mechanism, or blocking of the air passages, may be responsible for the unaërated condition which may affect only parts of a lung or a whole organ. The

¹For a fuller consideration of embolism and thrombosis of the pulmonary artery consult *Welch*, in Allbutt's "System of Medicine," vol. vi., p. 261.

atelectatic portions of the lungs are dark red in color and of fleshy consistence.¹

Atelectasis may, on the other hand, be *acquired*, either in childhood or in adult life. In young children collapse of portions of the lung is of frequent occurrence, through occlusion of bronchi by inflammatory exudate. The region thus cut off is gradually deprived of air, so that, as the blood continues to circulate, it is dark red and firm in texture. *Compression atelectasis* may be due to exudates, tumors, etc., in the pleural cavities. Under these conditions the portion of lung involved may be paler than normal from the pressing out of the blood. In adults,

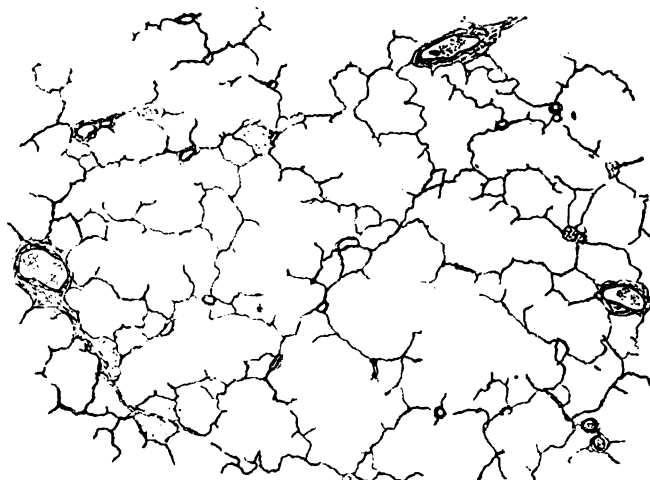


FIG. 373.—VESICULAR EMPHYSEMA.
Showing enlargement of the air spaces and thinning of their walls.

large or small portions of lung tissue may collapse from occlusion of a bronchus by exudate or stenosis, by paralysis of the vagus, or in long-continued feebleness of respiration. Edema may be associated with collapse.

Atelectasis may resolve by an early admission of air to the collapsed region. On the other hand, if prolonged, fibrous tissue may form and the involved portion may be finally converted into a cicatricial mass, sometimes containing bronchiectatic cavities.

EMPHYSEMA.

Vesicular Emphysema.—In forcible inspiration or expiration through obstruction of the air passages, in coughing, or in the use of wind instruments, or with consolidation or compression of portions of the lungs, the walls of the air spaces of the lungs may be more or less distended, either in circumscribed regions or over large areas of the lungs. This may

¹ Collapsed lungs, from their red color and fleshy consistence, are often spoken of as "carnified."

develop in a short time, and then the condition is designated acute emphysema.

If the conditions which induce emphysema be persistent, as in chronic bronchitis with difficult respiration and coughing, atrophy of the walls of the air vesicles and alveolar passages may take place—chronic emphysema. The walls become thinner and are often perforated; adjacent air spaces coalesce, so that larger and smaller irregular, thin-walled cavities are formed (Fig. 373). Destruction of the capillary network of the atrophied walls occurs, and the lung may thus become pale and anæmic. As a rule, the distention of the air spaces is most marked along the anterior margins of the lungs, but it may be more general. Through the atrophy of the elastic tissue of the lungs, when the lesion is general and advanced, these organs do not collapse when the chest is opened. They appear pale, are dry and soft, and pit on pressure by the finger.

The microscopic picture is that of varying degrees of atrophy; desquamation and fatty degeneration of the vesical epithelium are common.

As already indicated, emphysema of the lungs is often associated with chronic bronchitis. With this may be more or less hyperplasia of the interstitial tissue. Dilatation or hypertrophy of the wall of the right ventricle is common. Chronic endarteritis of the pulmonary vessels may be associated with

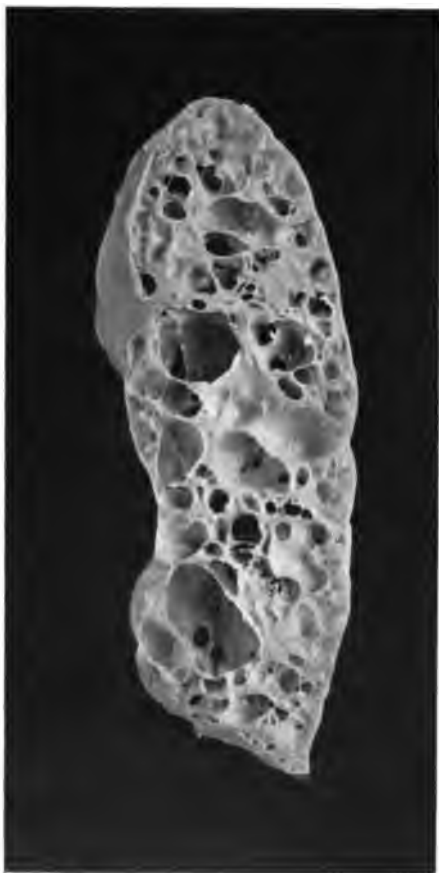

FIG. 374.—INTERLOBULAR EMPHYSEMA OF LUNG.
Child two months old. After whooping-cough.¹

emphysema. There may be chronic venous congestion of the abdominal viscera and dropsy. Delafield holds that the more essential lesion in some forms of emphysema is the development of new connective tissue with which dilatation of the air vesicles and atrophy of their walls are in varying degrees associated.

In old age, atrophic processes in the lungs may be associated with

¹ For a fuller description of this unusual case see *Northrup, Am. Jour. Med. Sci.*, vol. lxxxvi., 1883, p. 147.

dilatation and mergence of the air spaces. This is called senile emphysema. Excessive emphysema, apparently congenital, may be present in young children (see Fig. 374).

Interstitial Emphysema.—Rupture of the walls of the air spaces may permit the escape of air into the interstitial tissue of the lungs

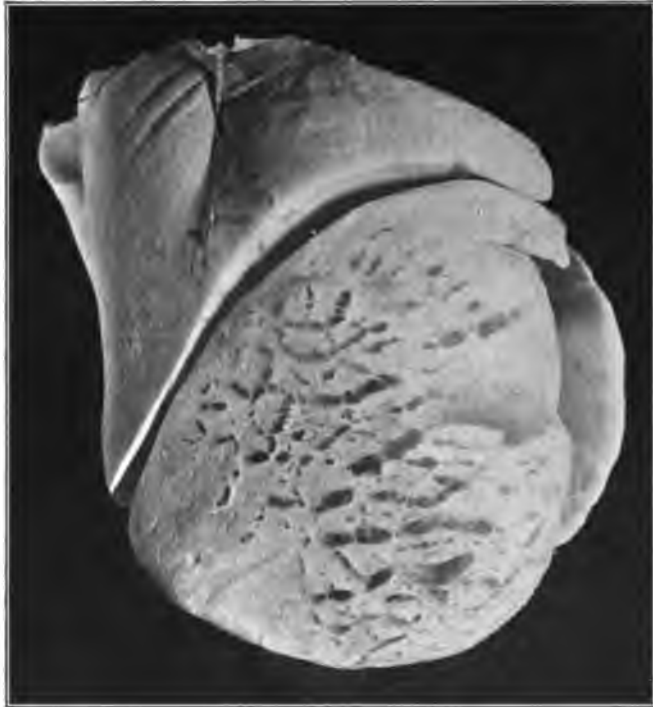

FIG. 375.—INTERSTITIAL EMPHYSEMA OF THE LUNG OF A CHILD.
The irregular darker areas in the lower lobe indicate the air largely in the interlobular septa.

(Fig. 375). Rupture of the pulmonary pleura may admit air into the mediastinum and thence into the tissues of the neck. Gas may form after death in the interstitial tissue of the lungs, from the presence of the *Bacillus aërogenes capsulatus* or other putrefactive bacteria.

GANGRENE.

Circumscribed gangrene occurs in the form of one or more rounded or irregular masses of variable size. The gangrenous portion of lung is at first brown and dry. The surrounding lung tissue is congested or œdematous, or infiltrated with blood, or inflamed. If the gangrenous focus is near the pleura, the latter will be coated with fibrin. Gradually the gangrenous portion of lung assumes a dirty green color and a putrid odor. It becomes soft, disintegrated, and separated from the surround-

ing lung. The blood-vessels may be obliterated by thrombi, or eroded, so that there are profuse hæmorrhages.

Such a gangrenous process may extend to the adjacent lung tissue, or a zone of gray or red hepatization or of connective tissue may be formed. The fluid from the gangrenous lung may pass into the bronchi and be expectorated; or it may run from one bronchus into another and incite new gangrenous foci or diffuse gangrene. The pulmonary pleura may be perforated and a gangrenous pleurisy produced. Gangrene may follow lobar or broncho-pneumonia, especially such phases of the latter as result from the inspiration of foreign material containing micro-organisms from the mouth; it may arise from infectious emboli in the lungs, or by an extension of a gangrenous process from an adjacent part. It may be associated with œsophageal diverticula.¹

Diffuse gangrene may follow the circumscribed form; it may complicate lobar pneumonia or occur as an independent condition. A large part of a lobe or of an entire lung becomes greenish, putrid, and soft, and the pulmonary pleura is inflamed. There may be hæmorrhages from eroded vessels. There may be general septicæmia.

Various forms of bacteria may be present in gangrenous areas of the lungs. Among the more common are *Streptococcus pyogenes*, *Staphylococcus pyogenes*, pneumococcus, and various saprophytic micro-organisms.²

INFLAMMATION. (Pneumonia, Pneumonitis.)

General Considerations.

Before commencing the study of inflammation of the lungs it is well to recall some of those features of structure and function which influence the local manifestations of disease in these organs and largely determine the special character of its lesions. In the first place, the lungs, like the gastro-intestinal canal, while in a topographic sense within the body, are still in open communication with the exterior, and are thus more directly exposed to various deleterious agencies than are those structures and organs wholly enclosed by living tissues. Notwithstanding this vulnerability of location, the recesses of the lungs are guarded by protective mechanisms of great efficiency.

Since many of the lesions of the lungs, as we shall presently see, are induced by the entrance of foreign material into them in the form of dust, it will be useful here to glance at some of the ways in which the body is protected against the entrance of dust and the means by which it is disposed of when it does pass, as is frequently the case, even the most effective barriers.

In normal breathing through the nose, the air impinging upon the moist surface of the tortuous passages loses a considerable part of its dust and bacteria. In the throat, larynx, and trachea, a similar clearing occurs, so that at the end of inspiration the air has been so far freed from its floating particles that it emerges in the expiration practically dust- and germ-free.

If the nasal passages are not normal, or breathing through the mouth is practised, the air contaminations may pass more deeply into the recesses of the lungs, or may still remain to a certain extent suspended in the expired air.

Many of the dust particles which may lodge upon the walls of the deeper air passages are swept upward by the ceaseless ciliary movement and cast out, as are the secretions and dust accumulations from the nose and throat. The growth of many

¹ See reference to *Starck*, p. 652.

² See for "acid-proof" bacilli in gangrene, *Ophuls*, *Jour. Med. Res.*, vol. viii., p. 242, 1902.

micro-organisms is inhibited by the mucus of the air-passages. Many inert dust particles which are taken into the tissues at the tonsils or in the deeper recesses of the air tubes are carried in the lymphatics to places of temporary or permanent deposit. Many micro-organisms within the tissues are destroyed by phagocytes or by the body fluids.

Thus it is that although large numbers of dust particles may enter the respiratory passages at every breath, the larger proportion are usually safely disposed of, most of them through the secretions of the throat and nose.

It has long been known that a certain number of inert dust particles from the inspired air, in spite of the tortuous and narrow passages which they must pass in the deeper recesses of the lungs, do reach the air vesicles, from which they may be largely removed to the adjacent tissues or to the bronchial lymph-nodes by way of the pleural and other lymph-vessels.

Whether living bacteria can reach the air vesicles under the ordinary conditions of respiration is a much discussed question, which has given rise to many painstaking researches. One group of workers has concluded that the lungs, except for the larger air passages, are usually germ-free. On the other hand, many have concluded from equally careful studies that the lungs of both men and animals often, if not always, contain a moderate number of living micro-organisms. The technical difficulties in this research are so great, and the conditions under which they have been undertaken are so various, that this difference of opinion is not surprising.

Without attempting to marshal the evidence adduced on both sides of the question it appears that in most of the earlier studies on the artificial introduction of living micro-organisms into the lungs, the time which was allowed to elapse between the introduction of the germs and the examination of the lungs was too long, so that the possibility that the lungs might rapidly dispose of germs lodged in their deeper recesses by lysis or phagocytosis, was overlooked.

In fact, it has been found that in experiments in which animals are exposed to an atmosphere laden with bacteria-containing dust or spray, if the animals be killed at once after the exposure, living micro-organisms may be found even in the deepest portions, while if even a short time be allowed to elapse they will have entirely disappeared.

While, however, in the air passages and lungs we have a most efficient protective mechanism against the entrance and permanent lodgment under ordinary conditions of both inert dust particles and living micro-organisms in such situations as would involve serious damage to these delicate organs, it should be remembered that the efficiency of these safeguards may be greatly diminished if they are overworked and abused.

The lungs of practically all persons who live indoors contain a considerable amount of soot, which blackens them (see p. 616). The irritation incited by this foreign stuff leads in most adults to some part of the lungs becoming dense and useless. The overworking of the delicate mechanism for filtering the foreign matter out of the lymph flowing from the lungs to the interior blood channels leads to serious damage of this mechanism and to an increased vulnerability to infection which the healthy body should and could resist.

The responses of the lung tissue to the excitants of inflammation are not fundamentally as distinct nor as variable as the common classifications of pneumonia would seem to indicate. Exudation from the smaller blood-vessels is one of the most common features of the acute phases of pulmonary inflammation.

The formation of exudates is favored by the extensive capillary network which is almost directly exposed to such deleterious agents as may gain access to the air spaces; while a great accumulation of exudates is possible owing to the spongy structure of the organs. The transitional character of the epithelium lining the air vesicles predisposes to cell proliferation and exfoliation, and thus to the formation of exudate. On the other hand, the abundant blood and lymph channels¹ favor the speedy removal from the air spaces in the lungs of large quantities of exudate.

There are two sets of lymph-vessels in the lung; first, those which accompany the

¹ See *Miller*, Arch. f. Anat. und Physiologie, Anat. Abth., 1900, p. 197, bibl.

pulmonary artery and pour their lymph into the bronchial nodes at the hilum of the lung; second, those which ramify in the interacinous and interlobular tissue of the lung (Fig. 376) and join the branches of the pleural plexus between the lobules. It is evident from this arrangement of the pulmonary lymphatics that a close relationship is maintained between even the deeper recesses of the lung and the pleura.¹

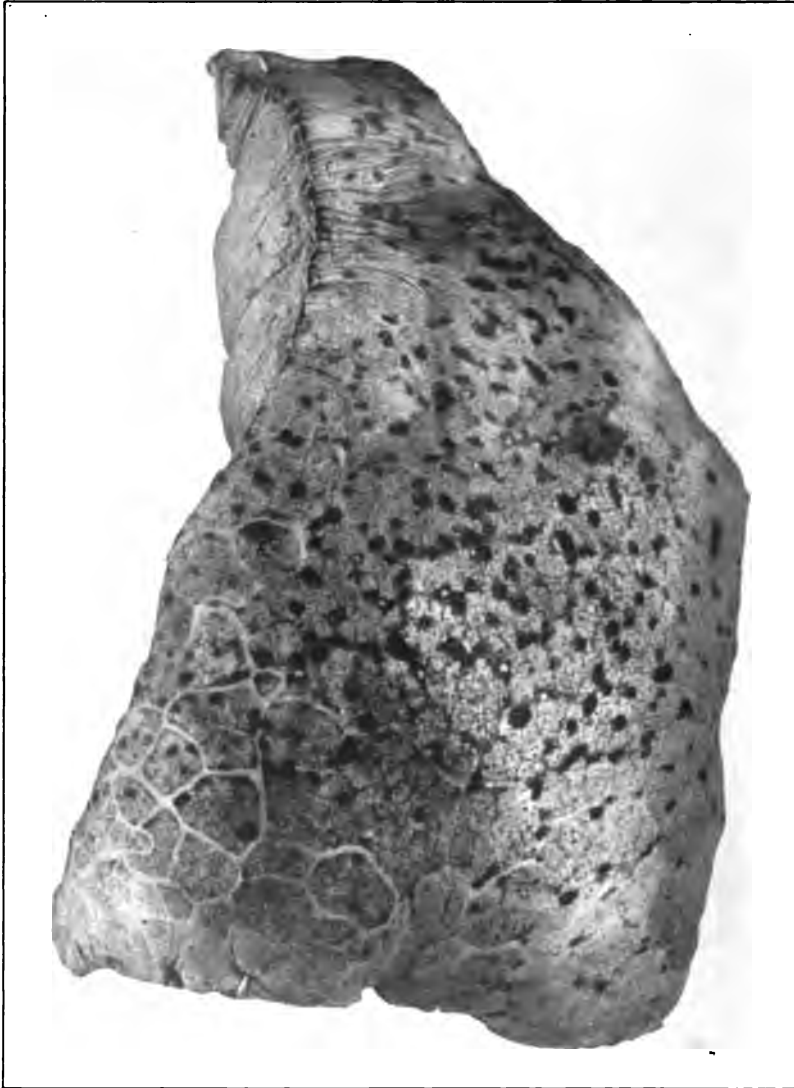

FIG. 376.—LUNG SHOWING TUBERCLES WITH PIGMENTATION IN THE PLEURA.

At the lower left-hand portion the lobules of the lung are outlined by the thickening of the walls of the lymph channels and of the interlobular septa.

¹ Note by Councilman, "The Lobule of the Lung and Its Relation to the Lymphatics," *Boston Jour. Med. Sci.*, vol. iv., p. 165, 1900. For a study of the comparative histology of the lungs of domestic animals see Müller, *Arch. f. Mik. Anat.*, Bd. lxxix., p. 1, 1906.

Along the subpleural lymph-vessels are numerous islets of lymphoid tissue and often a few small lymph-nodes.¹

While the abundant lymphatics of the lungs aid in the rapid disposal of exudates, they, on the other hand, favor the absorption of toxic substances into the body at large when bacteria, for example, are the excitants of the local inflammation. So that although exudative pneumonia is commonly considered a local disease, it is often rather a local expression of a general infection or is doubly significant on account of the associated toxæmia. In addition to the development and accumulation of exudates, necroses and the formation of fibrous tissue are the most noteworthy general pathological processes in the lungs.

While the conspicuous differences in the various forms of pneumonia are largely due to differences in the nature, virulence, and distribution of their excitants, predisposing factors dependent upon age, constitutional condition, and the protective mechanism of the lungs are of great significance.

The common classifications are based partly upon etiology, partly upon morphology, and the names used suggest now the topography of the lesions or the character of the tissue which is especially affected, and again the species of the bacterial excitant. Thus the term lobar pneumonia is topographical; tuberculous pneumonia emphasizes the excitant; while interstitial pneumonia suggests the form of tissue involved.²

ACUTE LOBAR PNEUMONIA. (*Fibrinous Pneumonia*—

Croupous Pneumonia.)

This is an infectious disease incited by the *Diplococcus pneumoniae* (pneumococcus of Fraenkel).³ It is especially characterized by an exudative inflammation in which red and white blood cells, serum, and fibrin accumulate in the air spaces of the lungs, usually involving, especially in adults, the whole of one lobe or lung or portions of both lungs.⁴ Toxæmia from the absorption of poisons formed locally in the lungs is an important and often most significant factor in the disease. The pneumococcus is usually widely disseminated in the blood.

During the first hours of the inflammation the capillaries of the air spaces are congested, the lung is œdematous, firmer than normal, but not markedly consolidated. The air spaces contain varying numbers of leucocytes, red blood cells, serum, and fibrin (Fig. 377). The epithelial cells lining the air vesicles may be swollen, they sometimes proliferate, and are usually detached in considerable numbers. Catarrhal bronchitis and pleuritis may at this time develop. This is called the stage of "congestion" or "engorgement" and may last for a few hours or for several days.

As the process continues, red blood cells, but especially polymorphonuclear leucocytes, and fibrin accumulate in the air spaces and smaller

¹ See for a study of pleural lymph-nodes and lymphoid tissue *Heller*, *Deut. Arch. f. klin. Med.* Bd. lv., p. 141, 1895.

² For a comprehensive *résumé* of the normal and pathological physiology of the lungs see *Heinz*, "*Handbuch d. exp. Path. und Pharmak.*," 1905, Bd. 2.

³ We shall use here as synonymous the names *Diplococcus pneumoniae* and pneumococcus; when pneumococcus is used the pneumococcus of Fraenkel is referred to. For a description of this organism see p. 218.

⁴ The clinical course and the morphological characters of the inflammation of the lungs associated with the *Diplococcus pneumoniae* are so typical that we seem justified in limiting the term lobar or fibrinous pneumonia to this condition, even though inflammations of the lungs due to other excitants are occasionally lobar in extent and may have a fibrinous exudate, and though exceptionally the pneumococcus inflammation itself fails to reach lobar proportions.

bronchi, so that the portion of lung involved becomes solid and friable, somewhat resembling the liver in color and consistence; hence the term

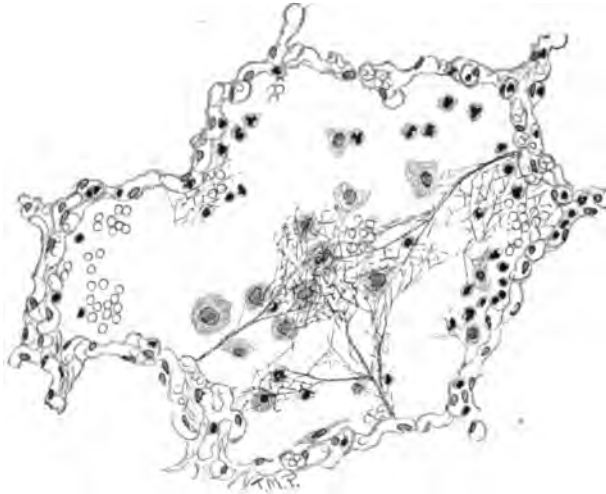


FIG. 377.—ACUTE LOBAR PNEUMONIA—EARLY STAGE.

This single air vesicle shows congestion of the capillaries in the walls, and a small amount of exudates, fibrin, leucocytes, red blood cells, and exfoliated epithelium.

“*red hepatization*” which has been used to indicate this condition. The cut surface of the consolidated portion is dry and coarsely granular, the granules being plugs or casts of exudate in the air spaces. A light

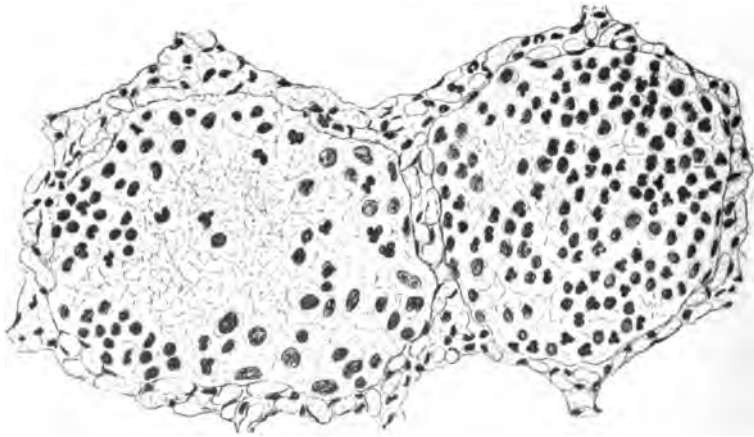


FIG. 378.—ACUTE LOBAR PNEUMONIA—STAGE OF “RED AND GRAY HEPATIZATION.”

The air vesicles are filled with exudate consisting largely of leucocytes, fibrin, and serum with a few epithelial cells.

scraping of the cut surface of the lung with the knife readily removes these granules or plugs of exudate, which consist largely of fibrin and leucocytes with red blood cells and exfoliated epithelium (Fig. 378). The

relative amount of leucocytes, red blood cells, and fibrin in the air spaces varies greatly, sometimes one, sometimes the other, preponderating (Fig. 349). The fibrin fibrils often coalesce or swell, forming homogeneous, irregular masses. On staining, large numbers of pneumococci may be found mingled with the other elements or within the cells of the exudate. While the general appearance of the lung in this stage is red, it is often mottled with gray and frequently is not uniformly solid. Although the capillary blood-vessels are compressed, they for the most part remain pervious; but thrombosis is not infrequent. Fibrinous pleuritis is commonly present, and the interstitial tissue of the lung,

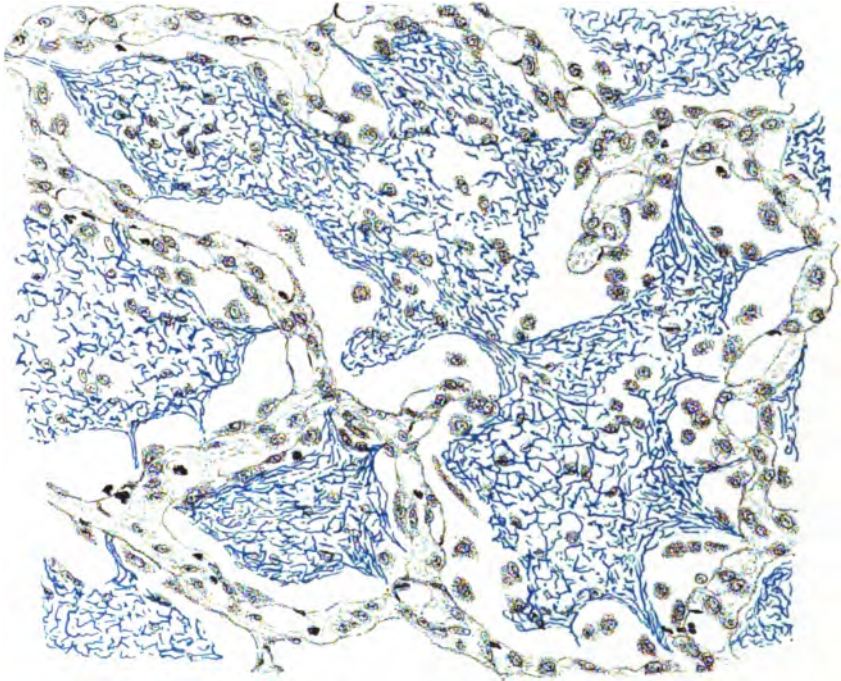


FIG. 379.—ACUTE LOBAR PNEUMONIA.
Showing fibrinous exudate stained by Weigert's method.

while usually free from exudate, may be œdematous and contain a few leucocytes and some fibrin.

The quantity of exudate in the lung is often very large. Hodenpyl has found it sometimes to be from three to four or even six pounds in weight.

In the usual course of events the red blood cells now lose their hæmoglobin, the exudate begins to soften, and the lung assumes a grayish color—*gray hepatization* or *commencing resolution*. The leucocytes and exfoliated epithelium undergo granular and fatty degeneration¹ or necro-

¹ See on fatty degeneration of pneumonic exudates *Christian, Jour. Med. Res., vol. x., p. 109, 1903, bibl.*

sis, and these with the fibrin soften and disintegrate (Fig. 380). The cut surface of the lung is now moister, less granular, and is often covered with a grumous fluid. In view of the new studies on cytolysis it seems probable that here, as in the removal of alien and dead organic material

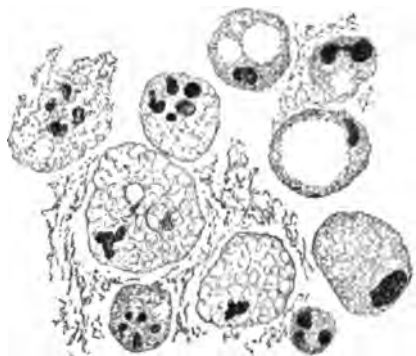


FIG. 380.—EXUDATE FROM THE LUNG IN RESOLVING LOBAR PNEUMONIA.

The cells show various phases of granular and fatty degeneration with fragmentation of the nuclei and disintegration of the cell bodies.

elsewhere in the body, the exudate is softened and rendered capable of solution by an exaggeration of the normal autolytic processes (see p. 106).¹ The softened exudate is gradually absorbed or may be in part expectorated. The involved portion of lung again contains air; the epithelium of the air spaces is regenerated.

While it is customary and convenient to describe definite stages of lobar inflammation of the lung—red and gray hepatization and resolution—these in fact not only merge gradually into each other, but often coexist in different parts of the lung. The process of reparation also

usually occurs irregularly, so that a lung in resolution may show side by side in neighboring air spaces well-formed cellular and fibrinous exudate, degenerated exudate, and various phases of epithelial cell repair.²

The nature of the characteristic crisis in pneumonia marked by a sudden fall in the temperature and improvement of the general symptoms is not clear. It is not accompanied by obvious changes in the pulmonary exudate. Many studies have been made on this subject, upon which we cannot enter here.³

For the evidence of communicability of the infectious agent in lobar pneumonia see page 219.⁴

Associated Lesions in Other Organs.⁵—Fibrinous or sero-fibrinous pleuritis, usually with slight but often with voluminous exudate, commonly accompanies lobar pneumonia. Catarrhal and fibrinous bronchitis is also usually associated with the pneumonic process. Pericarditis and endocarditis are not infrequent complications; meningitis occasionally occurs. The excitant of these complications is usually the pneumococcus.⁶

Chromatolysis of the ganglion cells, albuminous degeneration in the

¹ For a study of the chemistry of resolution of the exudate see *Simon*, *Deut. Arch. f. kl. Med.*, Bd. lxx., 1901, p. 604. See also references to studies on autolysis, p. 107.

² For a study of the histology of acute lobar pneumonia with bibl. see *Pratt*, *Contr. to Welch Anniv. Vol.* 1900, p. 265, and *Johns Hopkins Hosp. Rep.*, vol. ix.

³ See for a study of the crisis *Tchistovitch*, *Ann. Inst. Pasteur*, t. xviii., p. 304, 1904, bibl.; also discussion of opinion p. 219.

⁴ See for a general study of communicability *Edsall* and *Ghriskey*, *Trans. Col. of Phys., Phila.*, vol. xxvi., p. 6, 1904.

⁵ See for résumé of statistics of complications *Kerr*, *Trans. Chicago Path. Soc.*, vol. v., 1903, p. 274. Also, for an analysis of four hundred and eighty-six cases, *McCrae*, *Fyshe*, and *Ainley*, *Am. Med.*, vol. vii., p. 135, 1904.

⁶ For a study of blood cultures in pneumonia see *Rosenow*, *Jour. of Infec. Dis.*, vol. i., 1904, p. 280, bibl.

kidney, liver, and heart, hyperplasia of the bronchial lymph-nodes' together with leucocytosis, fever, and frequent serious enfeeblement of the heart action, are marks of toxæmia. The bronchial lymph-nodes may contain, especially in the perifollicular sinuses, and often within phagocytes, red blood cells, cell detritus, and pneumococci brought from the lungs; fibrin is frequently also present.

In lobar pneumonia in young children, in those enfeebled by acute and chronic disease, and in the aged, the lungs are often less uniformly consolidated and less dense and hard than in vigorous adults. When lobar pneumonia occurs in lungs already the seat of chronic lesions, such as chronic congestion, emphysema, interstitial pneumonia, or tuberculosis, the gross appearances of the organs may differ in various ways from those of uncomplicated pneumonia.

While *Diplococcus pneumoniae* is the regular excitant of lobar pneumonia, other bacteria—see below—are not infrequently associated with it, sometimes, though by no means always, leading to clinical complications and to modifications of the appearance of the lesion. Predisposition of the individual is an uncommonly conspicuous and important factor in the etiology of this as other forms of pneumonia, so that, as is well known, exposure, fatigue, etc., may induce the favoring bodily conditions under which the pneumococcus becomes harmful. The experiments upon animals are most conclusive in demonstrating that intrapulmonary injections of pneumococcus cultures, which may be entirely without obvious effects in a healthy animal, may induce exudative inflammation or become quickly fatal after such exposure to cold or fatigue or injury, or to the action of drugs, as interferes with the integrity of the blood or locally damages the pulmonary tissues.¹

Delayed Resolution after Lobar Pneumonia ("Organizing Pneumonia").—Instead of undergoing resolution, the fibrinous and cellular exudate in the air spaces in lobar pneumonia may persist, and by a process similar to that which is called organization of a thrombus (p. 27) may be gradually replaced by new vascular fibrous tissue. New connective-tissue cells grow out from the walls of the air spaces into the exudate; these cells become elongated. Intercellular fibrils develop, and long masses or bands of this new tissue, often containing blood-vessels, may extend for considerable distances through the air channels of the lung (Fig. 381). These may gradually coalesce with the walls, and together with an interstitial connective-tissue growth may lead to a fibrous consolidation of the lung.

Delafield describes such an intra-alveolar formation of connective tissue leading to fibrous induration of lobes of the lung and occurring as an independent lesion apart from the exudative form of lobar pneumonia.

CONCURRENT INFECTION AND SUPPURATIVE INFLAMMATION OF THE LUNG FOLLOWING LOBAR PNEUMONIA.

Although, as stated above, *Diplococcus pneumoniae* usually occurs alone in typical lobar pneumonia, it may be accompanied by the *Strepto-*

¹ For reference to experimental excitation of pneumonia see p. 614.

coccus and *Staphylococcus pyogenes* and occasionally by other micro-organisms. The exact significance of these mixed or concurrent infections in lobar pneumonia is not always clear. But instead of the usual resolution there may be gangrene; or suppuration of the interstitial lung tissue with the formation of abscess may occur. In such cases *Streptococcus pyogenes* and *Staphylococcus pyogenes aureus* or putrefactive bacteria may be present with the pneumococcus in the exudate.

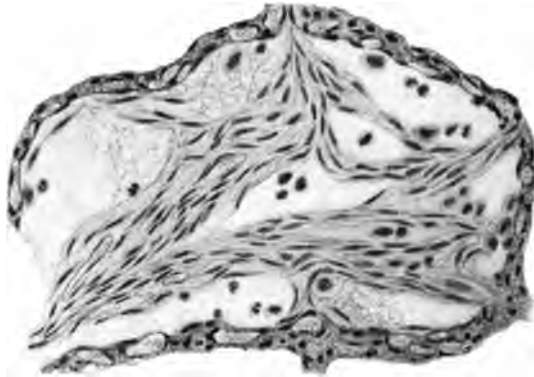


FIG. 381.—“ORGANIZING” PNEUMONIA—DELAYED RESOLUTION AFTER LOBAR PNEUMONIA. Anastomosing fascicles of fusiform connective-tissue cells lie within the air vesicle and are continuous with similar new formations in adjacent air spaces.

Suppurative inflammation of the interstitial tissue of the lungs may involve not only the larger fibrous-tissue bands, but the walls of the air vesicles and other air spaces. It is often called “purulent infiltration.” From the cut surface of the lungs in resolving lobar pneumonia a grumous fluid resembling pus often exudes, and this is sometimes mistaken for a mark of interstitial suppuration of the lung.

Suppurative inflammation of the interstitial tissue of the lung may occur without association with lobar pneumonia.

LOBULAR PNEUMONIA AND BRONCHO-PNEUMONIA.

In distinction from that common form of pulmonary inflammation induced by the *Diplococcus pneumoniae*, which as we have seen is usually lobar in character, there are exudative inflammations of the lungs, due to many different excitants, which are “patchy” or “lobular” in extent, the consolidated areas varying in size from such as are scarcely visible to those several centimetres in diameter.¹ These patches of lobular consolidation often join and merge, so that solidification of whole lobes or lungs is not uncommon. But the mottled, uneven surface and color of the lungs on section, and the usual absence of the peculiar granu-

¹ The term lobular does not refer exclusively to the anatomical “lobule” of the lung, since the masses or patches of consolidation often embrace several lobules or parts of these.

lation ordinarily suffice for the distinction, even to the naked eye, of the lobar from the coalescent lobular forms of exudative pneumonia.

It is convenient to recognize several types of lobular exudative pneumonia, although the character of the exudate is not distinctive.

Broncho-pneumonia.—Lobular Pneumonia with Inflammation of the Smaller Bronchi.

This most important type of lobular pneumonia frequently develops in connection with, and as an extension of that form of inflammation of the smaller bronchi commonly called "capillary bronchitis." At first dark red in color, the lobular areas of consolidation in broncho-pneumonia become more gray at the centre through degeneration of the exudate, while the advance of the process in the periphery is marked by a less solid, redder zone. On section of the fresh lung these areas (Fig. 382)

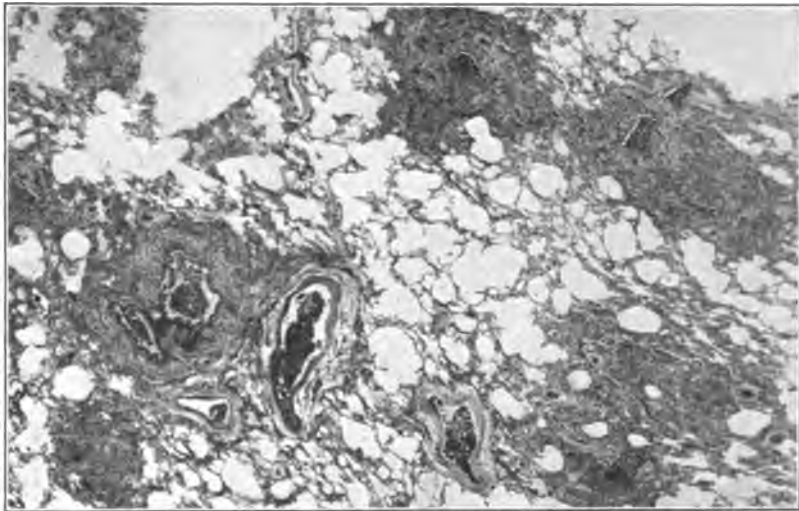


FIG. 382.—BRONCHO-PNEUMONIA IN AN ADULT.

Showing several areas of consolidation with the central bronchus filled with exudate—stained dark in the section from which the photograph was made.

usually project somewhat above the general surface, and at their centres the involved bronchi may appear as lighter spots, from which pus may exude or be easily pressed out. Such areas may coalesce, forming larger consolidations. The exudate, which more or less completely fills the air spaces (Fig. 383), consists of serum, old and new-formed epithelial cells from the walls of the air spaces, red blood cells, and often fibrin and polymorphonuclear leucocytes (Fig. 384) with various forms of micro-organisms. As a rule, however, fibrin and leucocytes are not as abundant as in the exudate of lobar pneumonia. Mucus and bronchial epithelium may be aspirated into the air spaces and mingled with the exudates.

Broncho-pneumonia involves a direct extension of the inflammatory process from the bronchi to the contiguous lung tissue, so that there is both an interstitial and exudative pneumonia about the bronchial tubes, the whole forming the lobular areas of consolidation (Fig. 385). This

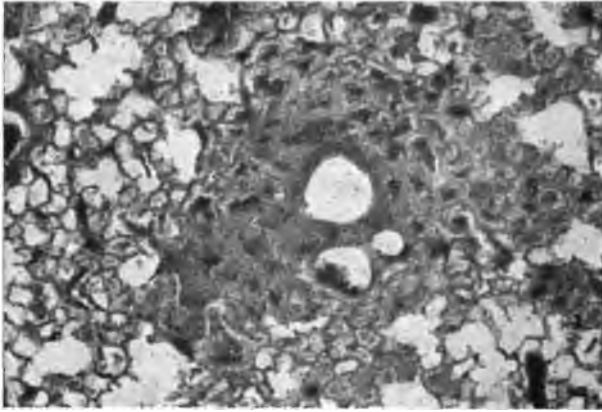


FIG. 383.—BRONCHO-PNEUMONIA IN A CHILD.

The section shows a single lobular area of consolidation with its bronchus whose thickened wall merges with the surrounding zone of exudative pneumonia.

involvement of the bronchial wall in inflammation with a direct extension of the process to the surrounding lung tissue has been urged especially by Delafield as the process to which the term *broncho-pneumonia* should be *par excellence* applied.

Between the consolidated areas there may be atelectasis of lung tissue from the occlusion of the smaller bronchi with exudate. When the consolidated areas are situated at the surface of the lungs, fibrinous pleuritis may be present over the affected regions.




FIG. 384.—BRONCHO-PNEUMONIA—EXUDATE IN A SINGLE AIR VESICLE.

This form of broncho-pneumonia is frequent in children, sometimes as an independent process, but often associated with or following diphtheria, scarlatina, measles, etc. It occurs also in adults, either as a complication of infectious diseases such as typhoid fever, smallpox, influenza, etc., or as a primary process. It may occur in the aged or in those enfeebled by chronic wasting diseases.

Resolution may take place in the areas of broncho-pneumonia by processes of cell degeneration and absorption identical with those through which restoration is secured in lobar pneumonia. If, however, resolution in broncho-pneumonia do not presently take place, and the lesion persist, dense connective tissue is

apt to form about the bronchi and in the interstitial tissue of the lungs, which may lead to induration and distortion of the organs, atelectasis, chronic bronchitis with dilatation of the bronchi, etc. A photograph of a section of such a chronic or "persistent" broncho-pneumonia is reproduced in Fig. 386.

Other Forms of Lobular and Broncho-Pneumonia.—There are forms or types of lobular pneumonia in which serum and epithelial cells with more or less fibrin and leucocytes collect in the air spaces of a limited

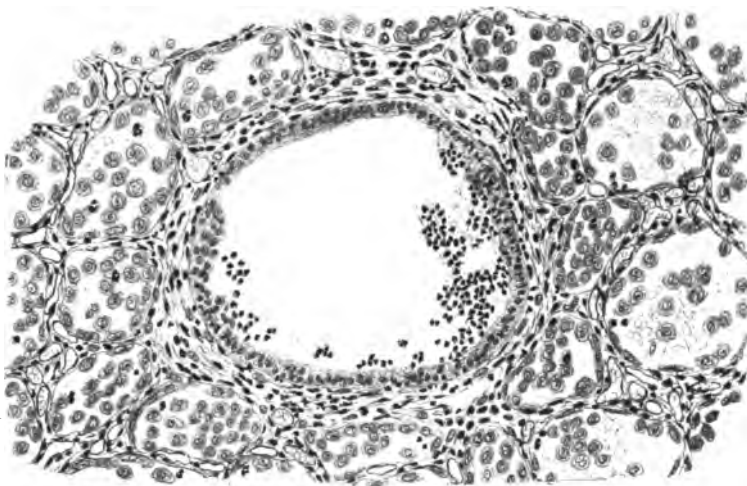


FIG. 385.—BRONCHO-PNEUMONIA—CHILD.

Showing slight change in the epithelium of the bronchus; a purulent exudate in the lumen; thickening of the wall of the small bronchus, and exudate in the adjacent air vesicles.

region without primary bronchitis and without involvement of the walls of the bronchi and air spaces.

In one type of lobular pneumonia and broncho-pneumonia the exudate may consist largely of pus cells which infiltrate the walls of the air spaces and bronchi as well as fill the air spaces themselves. This type of inflammation may be induced by the aspiration in feeble persons of irritating substances or bacteria-containing material of various kinds, particles of food, saliva, etc. This is called *aspiration pneumonia* and may result in necrotic or gangrenous processes in the involved regions of the bronchi and lungs. Again there may be circumscribed areas of exudative pneumonia, often suppurative in type and involving the walls of the air spaces, which originate through the transportation by the blood-vessels of various forms of bacteria, especially the *Streptococcus* and *Staphylococcus pyogenes*, as in *pyæmia*; this is called lobular pneumonia of *hæmatogenous origin*, or *pyæmic* or *septic pneumonia*. Thus, *abscesses* of the lungs may be formed.

In the lobular pneumonia of bubonic plague the exudate is said to

contain few leucocytes and epithelial cells, and to consist largely of blood and plague bacilli.¹

In the aged or those long in bed in an enfeebled condition, hyperæmia and œdema with more or less exudate, usually epithelial in character, may develop in the dependent posterior portions of the lungs—*hypostatic congestion* and *hypostatic pneumonia*.

There is a peculiar and rare form of broncho-pneumonia associated with necrosis in which forms of streptothrix have been isolated which are undoubtedly the excitants of the disease.² Actinomyces is also an occasional excitant of broncho-pneumonia.

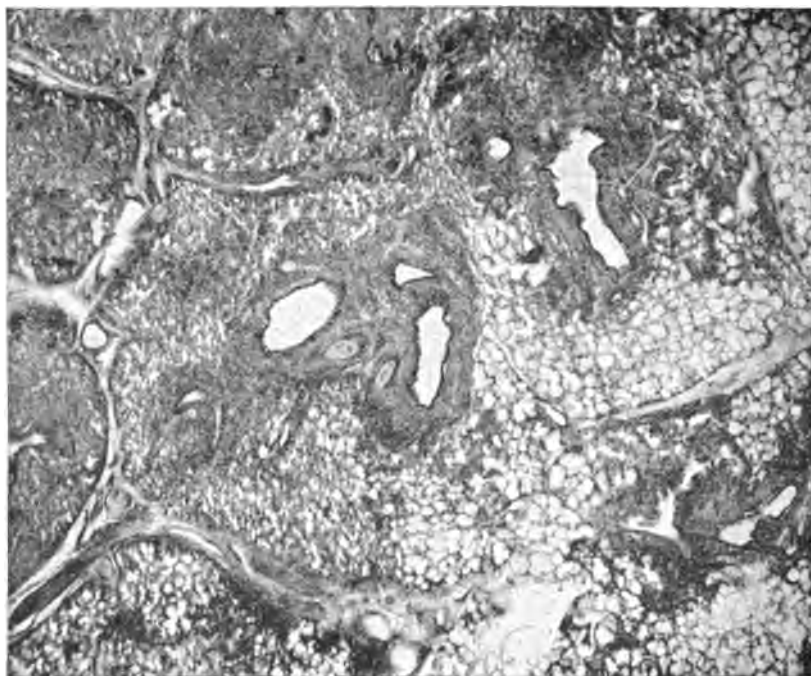

FIG. 386.—PERSISTENT—CHRONIC—BRONCHO-PNEUMONIA.

In all these forms of lobular pneumonia œdema and atelectasis of uninvolved portions of the lung may occur.

It is evident that in lobular pneumonia the infectious agent may reach the lungs either through the air passages or through the blood- or lymph-vessels, and that differences in the portals of entry as well as in the nature and virulence of the excitant and the susceptibility of the individual have an important bearing both upon the course of the disease and the morphology of the lesion.

¹ Consult *Flechner*, *Trans. Assn. Am. Phys.*, vol. xvi., p. 481, 1901.

² Consult *Norris and Larkin*, *Jour. of Exp. Med.*, vol. v., p. 155, 1900, bibl. Also further reference on p. 232.

THE EXCITANTS OF LOBULAR AND BRONCHO-PNEUMONIA.—The excitants of broncho-pneumonia and other types of lobular pneumonia are most frequently *Streptococcus pyogenes* (Fig. 387), the pneumococcus, *Staphylococcus pyogenes*, the typhoid, diphtheria, influenza, and plague bacilli, and the pneumobacillus of Friedlander; the streptothrix, above mentioned, and other bacteria have been occasionally found.¹ Pathogenic moulds may be excitants of acute forms of lobular pulmonary inflammation.

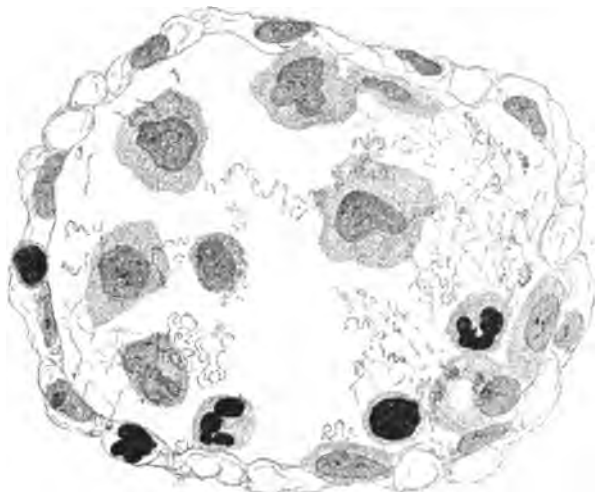


FIG. 387.—AIR VESICLE IN BRONCHO-PNEUMONIA WITH STREPTOCOCCI.

This specimen is from a case of broncho-pneumonia complicating a pseudo-membranous inflammation of the larynx in scarlatina. Exfoliated epithelium, leucocytes, and a little fibrin with the streptococci form the scanty exudate.

It will thus be seen that while it is convenient to group the exudative forms of pulmonary inflammation on the basis of distinctions which are in part morphological, in part etiological, the types in fact frequently merge or concur. This should not lead to confusion if we remember that these are infectious diseases whose most conspicuous lesion is located in the lungs, and that they are not species in the natural-history sense, for which fixed and definite characters must be established, but that the groups only indicate various forms and phases of response of a living organ in various conditions of susceptibility to the damage inflicted by one or another, and not infrequently by two or more combined forms of micro-organisms. These pneumonias are not considered among the infectious diseases where they logically belong, partly because there are practical advantages in grouping pulmonary lesions together and partly because our knowledge of the relative frequency and significance of the bacterial excitants of the various types is still in many cases too incom-

¹ For a study of the bacteriology of lobular pneumonia, especially in adults, see *Blumer*, Albany Med. Annals, vol. xxii., Aug. 1901.

plete to permit the establishment of a distinctive and clearly defined form of infection.¹

INTERSTITIAL PNEUMONIA.

This name is given to a chronic productive inflammation, which involves the connective-tissue framework of the lung and the walls of the

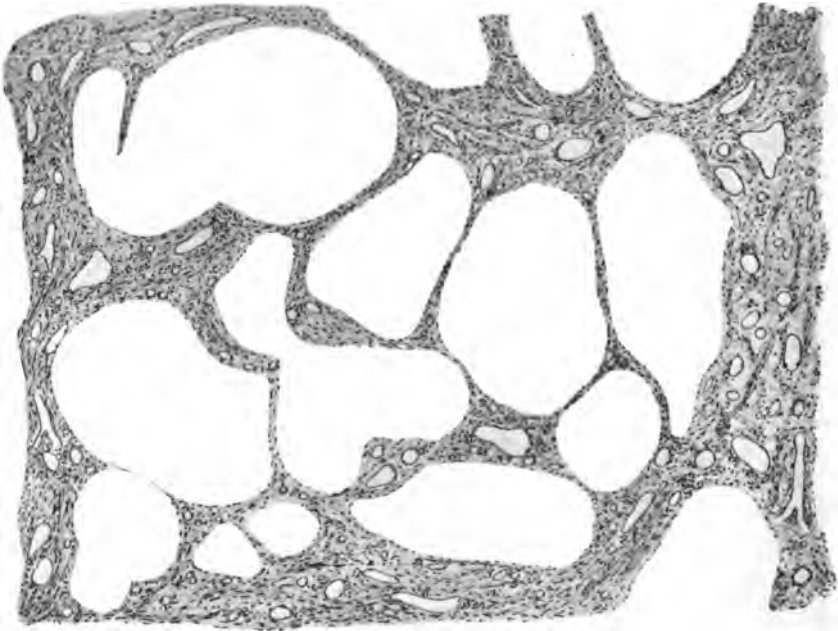


FIG. 388.—INTERSTITIAL PNEUMONIA.

With emphysema. The walls of the enlarged air vesicles and spaces are converted into dense fibrous tissue.

air spaces, and results in the formation of new connective tissue and the obliteration of the air spaces (Fig. 388).

Such an interstitial pneumonia may follow acute lobar pneumonia

¹ For a *résumé* of earlier attempts to induce experimental pneumonia in animals, consult *Aufrecht* in *Nothnagel's "Specielle Pathologie u. Therapie,"* Bd. xiv., Th. 2, p. 36, bibl., p. 221.

For a study of bacteria in the lungs and their relationship to pneumonia consult *Klipstein*, *Zeits. f. klin. Med.*, Bd. xxxiv., p. 191, 1898; also, with special reference to children, see *Dürck*, *Deut. Arch. f. klin. Med.*, Bd. lviii., p. 368, 1897.

For a study of bacteria in the lungs of man and lower animals see *Beco*, *Arch. de méd. expérimentale*, etc., t. xi., p. 318, 1899, and t. xiii., p. 851, 1901.

For a study of experimental cooling of the body which may induce changes in the blood, predisposing to infection with the pneumococcus, see *Reineboth* and *Kohlhardt*, *Deut. Arch. f. klin. Med.*, Bd. lxv., p. 192, 1900.

For a study of the effects of cooling in general as a predisponent to infection, see *Lode*, *Arch. f. Hygiene*, Bd. xxviii., p. 344, 1897; also *Kisskall*, *ibid.*, Bd. xxxix., p. 142, 1901, bibl.

For a study of the portals of entry in lung infection, with special reference to the pleura, see *Grober*, *Deutsch. Arch. f. klin. Med.*, Bd. lxviii., p. 296, 1900, bibl.

For a recent comprehensive *résumé* of bacteria in the lung, of the predisposing factors in pneumonia, and a summary with new studies of experimental pneumonia, see *Wadsworth*, *Am. Jour. Med. Sci.*, vol. cxxvii., p. 851, 1904.

Concerning circulatory changes in the lungs under various pathological conditions see reference to *Esser*, p. 595.

with the production of new intra-alveolar connective tissue, broncho-pneumonia, chronic pleurisy, chronic bronchitis, and atelectasis, or may be induced by the inhalation of the dust of coal, stone, or other inorganic substances. Diffuse interstitial pneumonia may occur in syphilis.

The topography of the lesion varies considerably in the different conditions under which the new tissue growth occurs. If it follow acute lobar pneumonia, one lobe or the whole of one lung may be involved and covered with pleuritic adhesions. The lobe or the lung is small, smooth on section, and firm in texture. The air spaces and small bronchi may be largely obliterated by the new connective tissue. If it follow broncho-pneumonia, one or more lobes are studded with fibrous nodules, which correspond to the affected bronchi and the associated lung territory; or a large part of a lobe is converted into dense fibrous tissue; the pleura may be thickened; there may be chronic bronchitis and bronchiectasia.

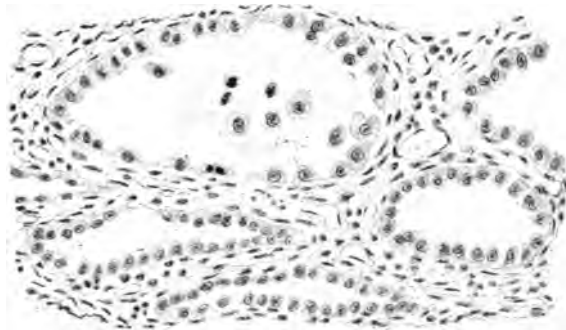


FIG. 389.—CHRONIC INTERSTITIAL PNEUMONIA. REVERSION OF EPITHELIUM IN ISOLATED AIR VESICLES.

If interstitial pneumonia be associated with thickening of the pleura, bands of connective tissue extend from the pleura into the lung, the bronchi are inflamed and often dilated. When associated with chronic bronchitis there are fibrous nodules around the bronchi, with more or less diffuse connective tissue.

The changes in interstitial pneumonia may occur by a slow hyperplasia of the fibrous tissue or by the formation of granulation tissue, which gradually becomes denser with contraction. Although this process is primary in the interstitial tissue, exudates are often present in the air spaces; atelectasis may occur, while emphysema and bronchiectasia are common.

Sometimes a noteworthy change occurs in the epithelium lining air vesicles which have been cut off from their neighbors by the new fibrous tissue. The epithelial cells increase in number, become thicker, and finally the small or distorted cavities may be lined with a complete investment of cuboidal cells (Fig. 389). This reversion of the epithelium of the air vesicles to a less differentiated type occurs in many chronic processes in the lungs.

Pigmentation of the Lung.—The inhalation of dust and smoke is so continuous among those who live much indoors that the lungs of nearly all persons from the earliest years are more or less pigmented. The foreign particles which get into the deeper recesses of the lungs are in part taken up by the epithelium of the air spaces, in part are carried by phagocytes or otherwise to the interstitial tissue of the lungs (Fig. 390). Here, either within cells or without, they are deposited along and within the lymph channels or in the lymph-nodules of the pleura and interstitial

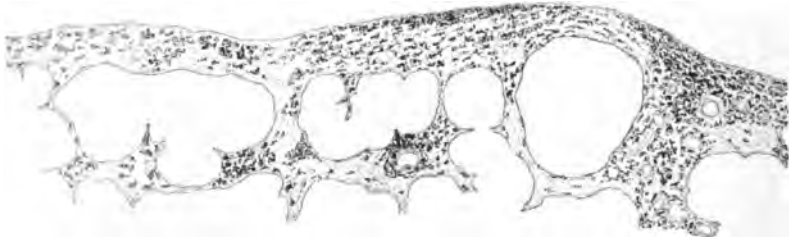


FIG. 390.—ANTHRACOTIC PIGMENTATION OF THE LUNG.

Showing pigment beneath the thickened pleura and in the thickened septa of the emphysematous lung.

tissue (Fig. 391), or they may be carried to the lymph-nodes at the root of the lungs. Rarely, this inhaled dust passes the tracheal and bronchial lymph-nodes and may be deposited in the viscera, especially in the liver and spleen.

Under ordinary conditions a moderate deposit of inhaled pigment particles in the lungs does not seem to be of great significance, but it does lead, if present in amounts as large as are frequently found in the air of many private houses, stores, factories, theatres, and other places of public assembly, to obliteration of lymph-channels and conversion of lymph-nodes into masses of pigmented fibrous tissue and in this way there is little doubt that it may predispose to more serious lesions. On the other hand, miners and others working or confined in smoky air, stone or metal workers, and the like, are liable to excessive pigmentation and to develop interstitial pneumonia, especially marked at first along the interlobular septa and frequently associated with chronic bronchitis, emphysema, atelectasis, or bronchiectasia. This condition of the lung when due to the inhalation of coal dust is called *anthracosis*; when due to dust of various minerals, *chalicosis*; when due to iron dust, *siderosis*.¹ The general process has been called *pneumokoniosis*. The color varies in these lungs with the character and amount of the deposited material, which is frequently quite unevenly distributed. The amount of foreign material in such lungs is sometimes large.²

¹ For a study of the condition of iron pigment in cells and tissues see *Arnold*, *Virch. Arch.*, Bd. cxi., p. 284, 1900.

² For an analysis of the lungs of a case of extreme anthracosis see *Hodenpyl*, *Proc. New York Path. Soc.*, 1899-1900. For a summary of the protective mechanism of the respiratory passages see p. 600. For a summary of dusty trades and consumption, see *Hoffman*, Bureau of Labor, Dept. of Commerce and Labor, U. S. A., Bull. 79, 1908, and Bull. 82, 1909, bibl.

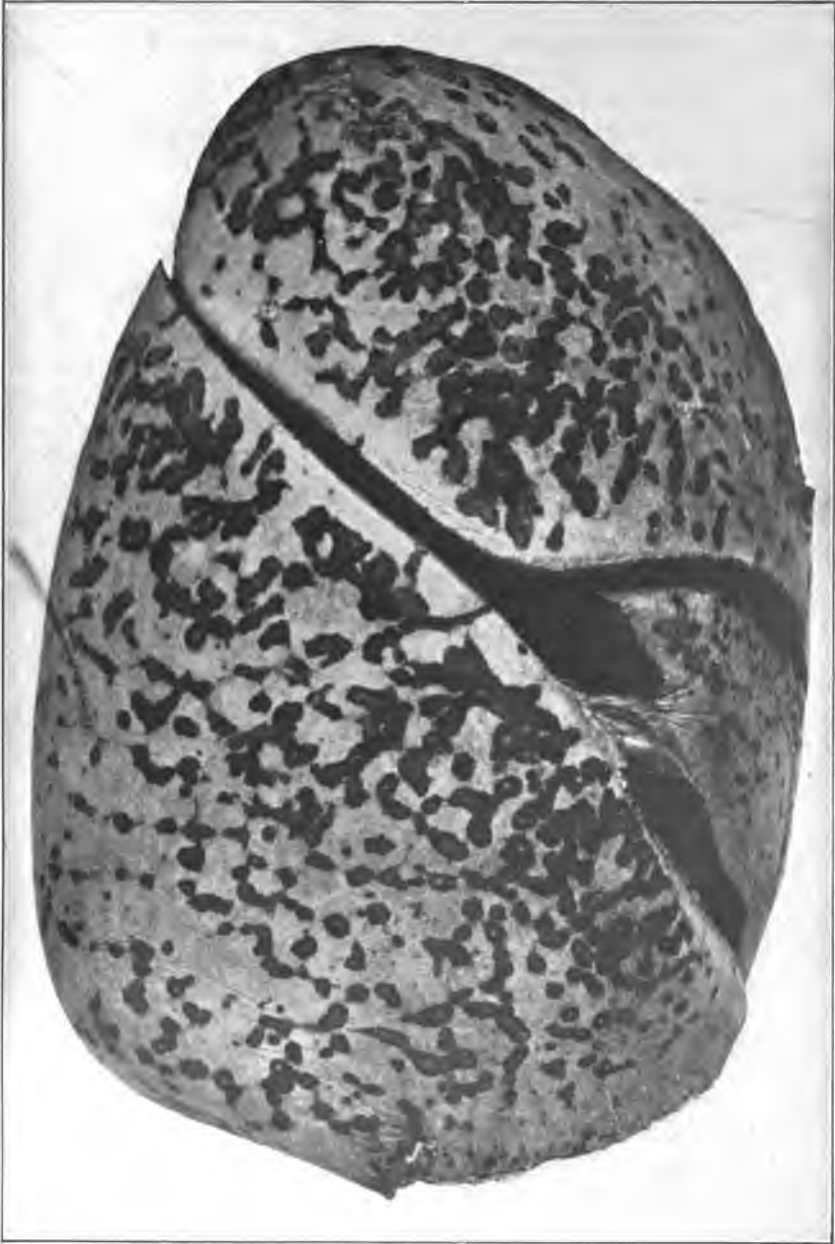


FIG. 391.—ANTHRACOSIS OF THE LUNG.

A few tubercles are seen at the centres of the pigmented areas. There are slight pleuritic adhesions between the lobes. This is from a photograph of the lung of an actor who had been for many years upon the stage in the nearly always dusty air of theatres.

TUBERCULOUS PNEUMONIA.

General Considerations.—Tuberculous inflammation of the lungs is similar in nature to tuberculous inflammation in other parts of the body. But since the morphological features of the response of a tissue to injury are largely dependent upon the form and capacities of its cells, it is not surprising that in such complex organs as the lungs, the lesions of tuberculosis should present many variations from the usual type elsewhere. The bronchial passages and the connecting air spaces, the numerous blood- and lymph-channels, especially favor the distribution of the tubercle bacillus within these organs; the open texture of the lungs permits, as in other forms of pneumonia, of great accumulation of exudate, while the delicacy and thinness of the air chambers favor extensive disintegration of the old or new-formed tissues or exudates when these have become necrotic under the influence of the poisons of the tubercle bacilli.

Thus the variety of cells and tissues involved and their peculiar relationships to one another and to the invading organisms render the lesions of pulmonary tuberculosis more complex in morphology than are tuberculous lesions in any other part of the body.

The classification of these lesions is largely based upon topographic considerations and is not to be regarded as indicating fundamental differences in the reaction of the tissues.

Portals of Entry.—Tubercle bacilli may enter the lungs either through the blood- and lymph-vessels, being brought from a focus of tuberculous inflammation in another part of the body, or, as is frequently the case, they are introduced through the air passages by the inhalation of floating dust particles, among which are living tubercle bacilli. There is evidence that tubercle bacilli may enter the body through the nasal and buccal mucosa or the tonsils or through gastro-intestinal mucous membrane without the development of tuberculous lesions at the point of entry.¹

Reaction of Tissue.—The introduction of tubercle bacilli into the lungs may induce an exudative inflammation with the accumulation of fibrin, leucocytes, and exfoliated epithelium in the air spaces; a productive inflammation with the growth of epithelial cells, or of round-celled tissue, or of a tissue composed of basement substance, large and small cells, and giant cells called tubercle tissue (see p. 252); or there may be added necrosis of the new tissue and of portions of the lung. All of these phases of tuberculous lesions may and usually do occur together.

The character of the inflammation in each case seems to be governed by the type of cells especially involved, by the number, virulence, and proliferative capacity of bacilli which are introduced into the lungs, and the way in which these enter, as well as by the susceptibility of the individual. If a large number of virulent tubercle bacilli be inhaled or aspirated through the bronchi, or if the bacilli grow with great rapidity,

¹ For a discussion of the sources and portals of entry of the tubercle bacillus see p. 264.

For a study of tubercle bacillus in the blood in pulmonary tuberculosis see *Lüdke*, *Wiener klin. Woch.*, p. 949, 1906. See also ref. *Anderson*, p. 264.

both productive and exudative inflammations may be set up in a considerable portion of the lungs. If, on the other hand, but few bacilli enter and their proliferation or virulence be not extreme, or if these find their way in small numbers into the lungs through the blood-vessels or lymphatics, then there may be small foci of productive inflammation with but little exudation. The tuberculous alterations in the lungs are usually accompanied or followed by a series of secondary processes which often complicate the condition of the patient as well as the morphological appearances of the organs. The obliteration or destruction of the smaller blood-vessels of the lungs in the tuberculous areas contributes to the gray or whitish appearance of the lesions, due largely to new-formed tissue or accumulated exudate. The formation of fibrous tissue in the attempts at repair of the damage wrought by the tubercle bacillus often dominates the structural picture.

Classifications.—The traditional distinctions between acute and chronic forms of pulmonary tuberculosis are often morphologically not at all well defined and are of value chiefly for clinical purposes.

It has been customary to set apart those forms of acute tuberculosis of the lungs in which the lesions are in the form of small discrete so-called "miliary" foci, calling the condition *Acute Miliary Tuberculosis*. The other tuberculous lesions involving in varying degree the lungs and the bronchi with associated and often extensive exudative necrotic and reparative processes have been commonly jumbled together as *Acute* and *Chronic Phthisis*, many phases of which have been elaborately described as if they were the expression of independent processes.

With our present knowledge of the nature and etiology of tuberculosis it seems better to let the word phthisis fall into disuse as speedily as possible, and to consider under more exact and significant designations such phases of pulmonary tuberculosis as the morphological characters of the lesions justify. We shall review the lesions of pulmonary tuberculosis then under the following primary headings:

1. Focal or miliary tuberculosis.
2. Tuberculous broncho-pneumonia.
3. Complex forms of nodular and diffuse tuberculous lesions.
4. The formation of cavities.
5. Secondary lesions in pulmonary tuberculosis.
6. Concurrent infection.

FOCAL TUBERCULOSIS. (*Miliary Tuberculosis*).

Acute Miliary Tuberculosis.—The rapid and widespread development of miliary tubercles in the lungs is often a part of general tuberculosis, although the lesion may be most extensive in the lungs. Both lungs are apt to be involved, but the distribution, number, size, and character of the miliary tubercles differ in different cases. The tubercles are found in the parenchyma of the lung, in the connective tissue forming the septa, along and in the walls of the bronchi and blood-vessels, and in the pulmonary pleura. They may be scattered singly through the lungs

(Plate IV.), or aggregated in groups (Plate VI. and VII.). They may be separated by considerable interspaces, or so close together that the lung is rendered nearly solid. Some are so small and transparent that they can hardly be seen with the naked eye; others are larger and more opaque and may have a lighter centre marking the area of necrosis.

In many cases it is evident that the lungs are infected through the blood-vessels or the lymphatics, for the general tuberculous infection is secondary to a localized tuberculosis either in the lungs or in some other part of the body. In a considerable proportion of cases of miliary




FIG. 392.—MILIARY TUBERCLE OF LUNG.

This tubercle has replaced several air vesicles whose walls are obliterated. In the centre is an area of conglutination necrosis; outside of this is a zone of organized tubercle tissue; the surrounding air vesicles contain a cellular exudate.

tuberculosis of the lungs, tuberculous lesions of the bronchial lymph-nodes or of the lung tissue at the apex of much longer standing indicate the probable immediate source of origin of the widely distributed tubercle bacilli. Very often in miliary tuberculosis of the lungs the tubercles in one part of the lungs are larger and appear to be older than those in other parts. Thus it is not infrequent to find the tubercles in the upper portion of the lungs more abundant, larger, and more fibrous than in the lower lobes (see Plate VII.). It is in fact probable that in many cases of acute miliary tuberculosis of the lung, either associated or not with older local tuberculous lesions from which the distribution of bacilli may have taken place, the generalization has not occurred at once, but by successive fresh infections.¹

¹ For references to the origin of miliary tuberculosis see *Benda*, *Lubarsch* and *Ostertag's* "Ergebnisse," Jahrg. v., p. 447, 1898; see also ref. to *Ribbert*, foot-note p. 252.



Miliary Tuberculosis (Acute) of the Lung.

The miliary tubercles, small and irregular in shape, are distributed throughout the lung—more abundantly in the upper and middle thirds.

The blood-vessels are injected with blue gelatin, so that in this photographic reproduction of the specimen the uninvolved portions of the lung are dark, while the tubercles—in which the blood-vessels are compressed or obliterated—are light.

Miliary tubercles in the lungs are in structure essentially similar to those formed elsewhere in the body, except that the filling of the air spaces with exudate makes the lesion somewhat more complex.

The tubercles may be composed of small spheroidal cells or of larger polyhedral cells with more or less fibrous stroma, or of small and large cells and stroma. Giant cells may be present, coagulation necrosis is

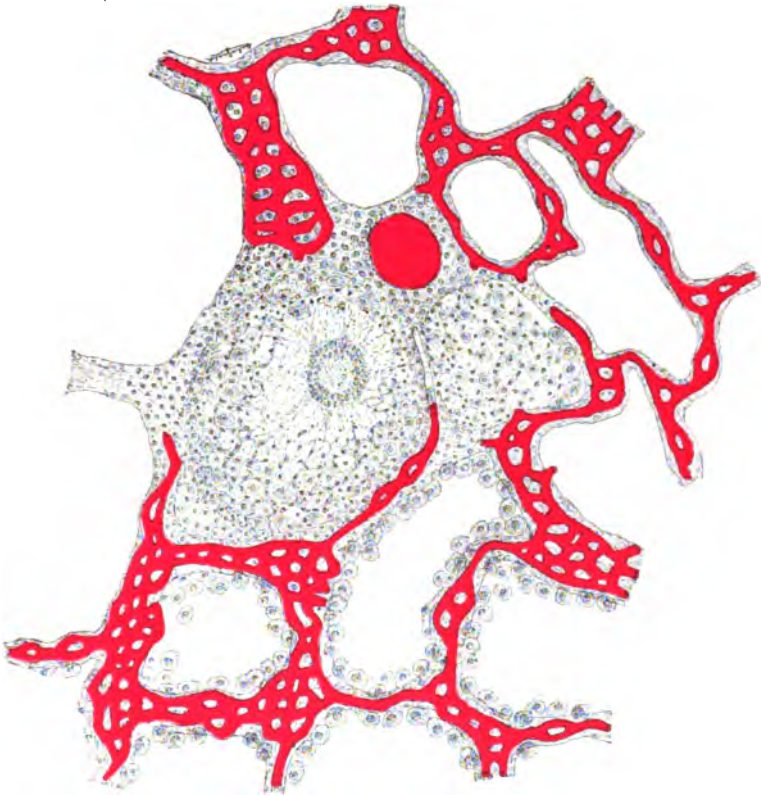


FIG. 393.—A MILIARY TUBERCLE OF THE LUNG.

Involving only two air vesicles, of which the walls are infiltrated and the cavities filled with tubercle tissue. The blood-vessels of the air vesicles are injected, except where these are obliterated by the tuberculous involvement of their walls.

usual (Fig. 148, p. 254). Such forms of miliary tubercles may be and commonly are associated with the presence of an exudate in the adjacent or involved air vesicles (Fig. 392). This exudate may be largely made up of exfoliated epithelial cells which have proliferated; or with these there may be serum, leucocytes, and fibrin. The blood-vessels within the tubercles which replace the lung tissue are partially or wholly obliterated (Fig. 393).

But the miliary foci of tuberculous inflammation in the lungs may consist wholly of inflammatory exudate which early becomes necrotic,

often with necrosis of the walls of the involved air spaces. Such tubercles of the exudative type are apt to occur in children and usually contain large numbers of tubercle bacilli. They may occur in connection with various other phases of acute and chronic pulmonary tuberculosis.

When miliary tubercles are situated in the parenchyma of the lung the walls of the air spaces may be visible in the new growth or they may be largely or wholly obliterated (Fig. 394).

In the obliteration of the walls of the air vesicles, their former situation may be indicated by structureless bands or streaks of necrotic material, or they may disappear altogether.




FIG. 394.—A MILIARY TUBERCLE OF THE LUNG.

This tubercle is largely caseous, the walls of the involved air vesicles being merely indicated in the dead mass by slightly stained streaks or bands. There is cellular exudate in the surrounding air vesicles.

Chronic and "Healed" Miliary Tubercles.—The small foci of tuberculous inflammation which are called miliary tubercles may, as we shall see later, extend and coalesce so that with more or less exudative pneumonia large areas of the lung may become consolidated, thus developing one of the forms of pulmonary tuberculosis called phthisis.

On the other hand, small tuberculous foci in the lungs may with or without extensive necrosis become surrounded by or converted into masses of dense fibrous tissue. These fibrous-tissue masses, which are often called "healed tubercles" (Figs. 395 and 396), may contain necrotic material, are often mottled black from anthracotic pigment, or they may be calcified at the centre. Tubercle bacilli may be absent from them, or the bacilli may remain alive within them for a long time quiescent but, as Lartigau and others have shown, still virulent. When such circumscribed masses of more or less fibrous tubercle tissue are scattered through the lungs, although the individual masses may be of considerable size, the process is sometimes called "*chronic miliary tuberculosis*."

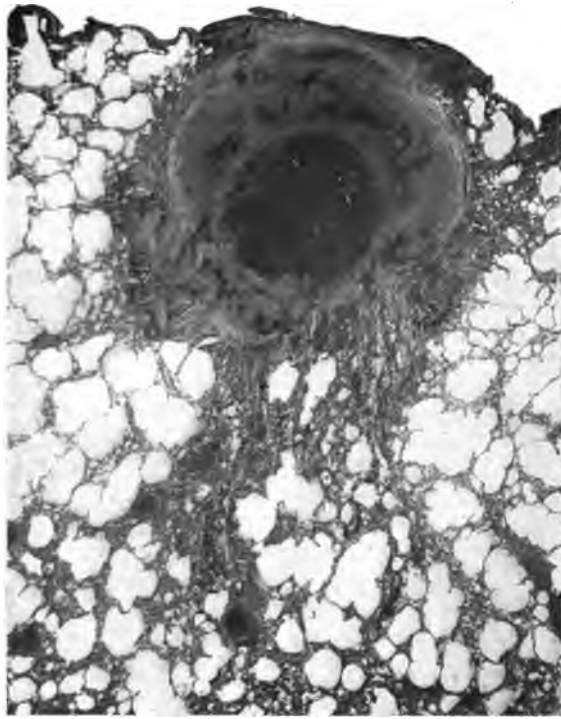


FIG. 395.—AN OLD FIBROUS TUBERCLE OF THE LUNG—"HEALED TUBERCLE."

The central portion is necrotic and irregularly pigmented. The periphery is composed of dense pigmented fibrous tissue. There are emphysema and distortion from cicatricial contraction of the fibrous tissue.

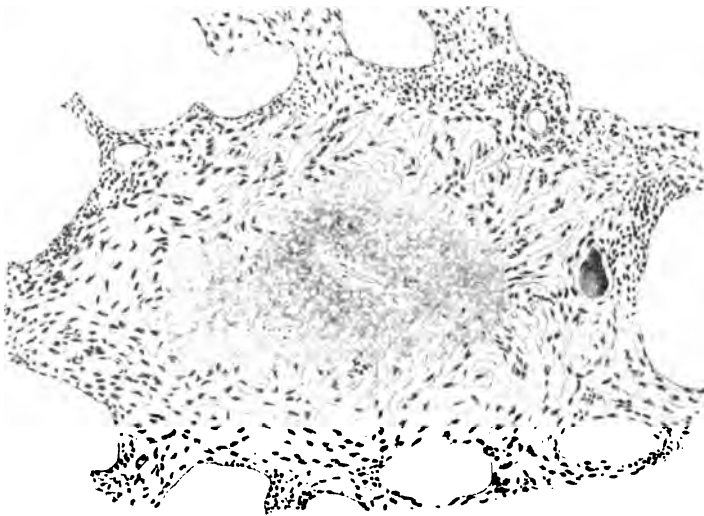


FIG. 396.—A FIBROUS TUBERCLE—"HEALED TUBERCLE" OF THE LUNG.

The centre is caseous, the fibrous tissue surrounding this is dense, the walls of the surrounding air spaces are thickened. A giant cell at the right is calcified.

It should be remembered that the new fibrous tissue which forms in and about miliary tubercles, as well as other tuberculous lesions, is the result of a distinctly reparative process in which the already formed tubercle tissue or its products apparently act somewhat as foreign bodies may in inducing fibrous-tissue growth.

TUBERCULOUS BRONCHO-PNEUMONIA.

In another most important phase of tuberculous inflammation of the lung there is an involvement of the walls of the smaller bronchi and the associated groups of air spaces. This may occur through inhalation of bacilli or by their aspiration from an established tuberculous focus; for

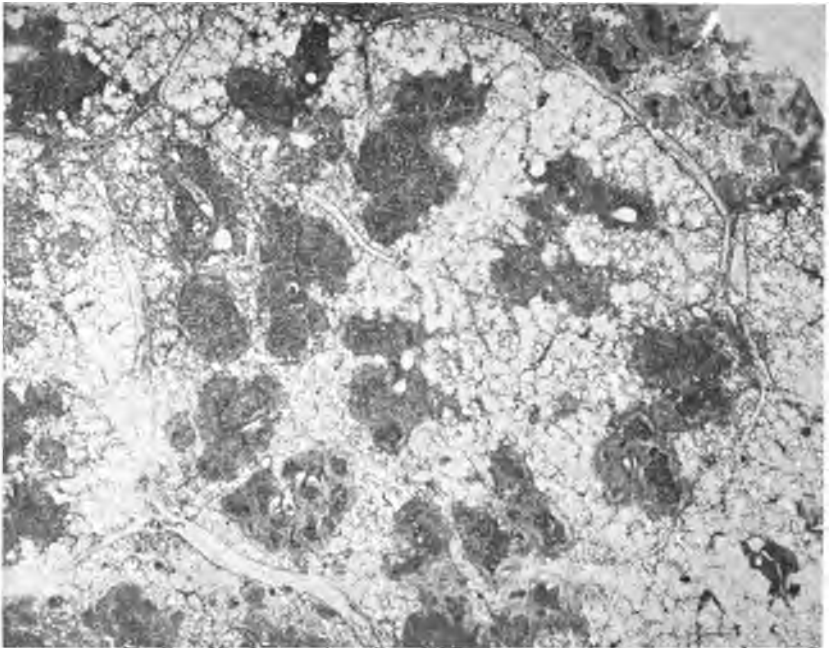


FIG. 397.—TUBERCULOUS INFLAMMATION OF THE LUNG WITH CHEESY DEGENERATION ABOUT THE BRONCHI IN A SINGLE LOBULE OF THE LUNG—TUBERCULOUS BRONCHO-PNEUMONIA.

example, from a lesion at the apex, or, as is often the case in children, from tuberculous bronchial lymph-nodes; or infection may take place through the blood- or lymph-vessels. In the early stages of tuberculous broncho-pneumonia the cut surface of the fresh lung may present small gray or yellowish white areas of consolidation with necrosis clustered about the small or terminal bronchi (Plate V.). The process is at first largely exudative, involving a catarrhal and necrotic inflammation of the mucous membrane of the bronchus with more or less exudate—which also may soon become necrotic—in the associated groups of air spaces (Fig. 397). Sometimes organized tubercle tissue may form in the walls of



Tuberculous Broncho-Pneumonia.

The walls of the smaller bronchi are involved, being thickened and caseous, while the ulceration of many of them has led to the formation of numerous small cavities.

The blood-vessels are injected with blue gelatin, so that the less affected and the intact parts of the lungs are the darker.



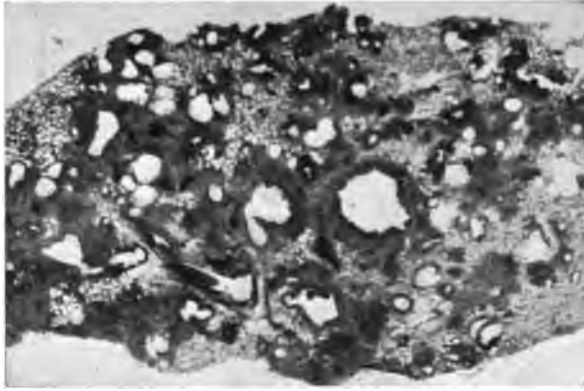


FIG. 398.—TUBERCULOUS BRONCHO-PNEUMONIA.

The walls of the bronchi are thickened and caseous and are surrounded by zones of exudative and caseous pneumonia. This cut shows a small region, more highly magnified, of a lesion similar to that shown in Plate V.

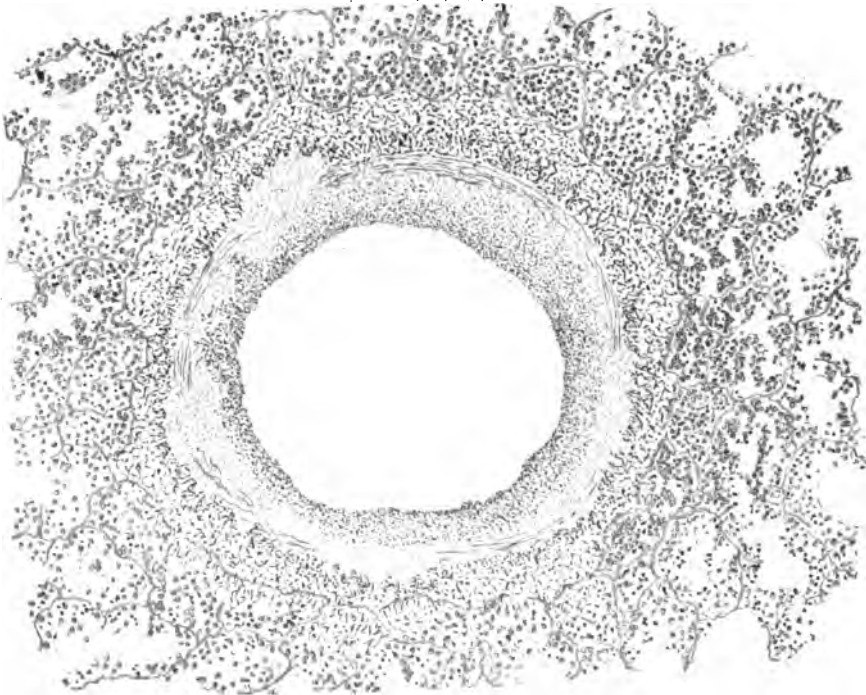


FIG. 399.—TUBERCULOUS BRONCHO-PNEUMONIA.

The wall of this medium-sized bronchus is caseous, tubercle tissue is formed about it and is extending into the surrounding lung tissue. A cellular exudate is seen in the contiguous air vesicles.

the bronchi, with thickening of the walls and obliteration of the blood-vessels of the adjacent air spaces.

By the extension of the process from one and another affected bronchus, and the coalescence of these, large areas of the lungs may become involved. In this more advanced stage of broncho-pneumonia the larger and smaller consolidated areas may be dark red with firmer gray or yellowish gray central portions, in which the blood-vessels are obliterated, or the whole area may be solid and in the fresh lung grayish white. This new-formed tissue may undergo necrosis and ulceration so that with an advancing consolidation of the lung tissue about the bronchi numerous

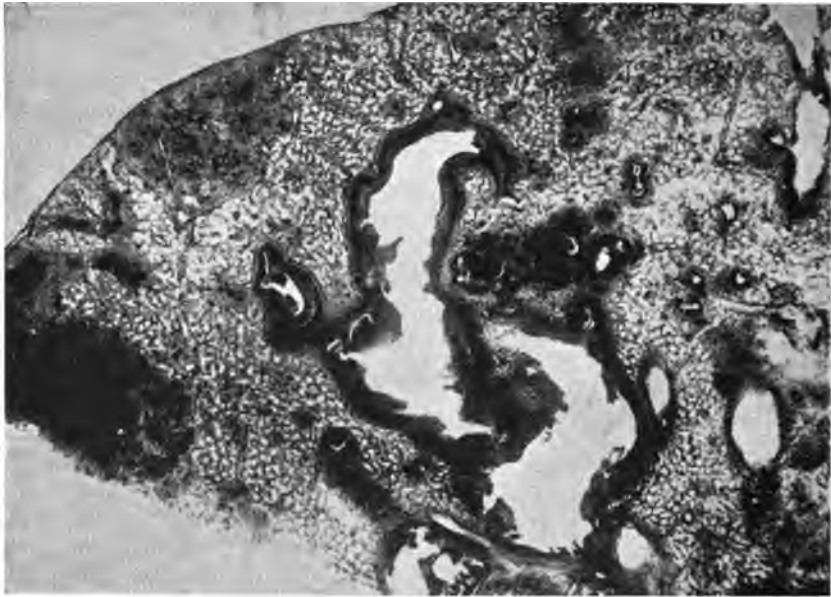
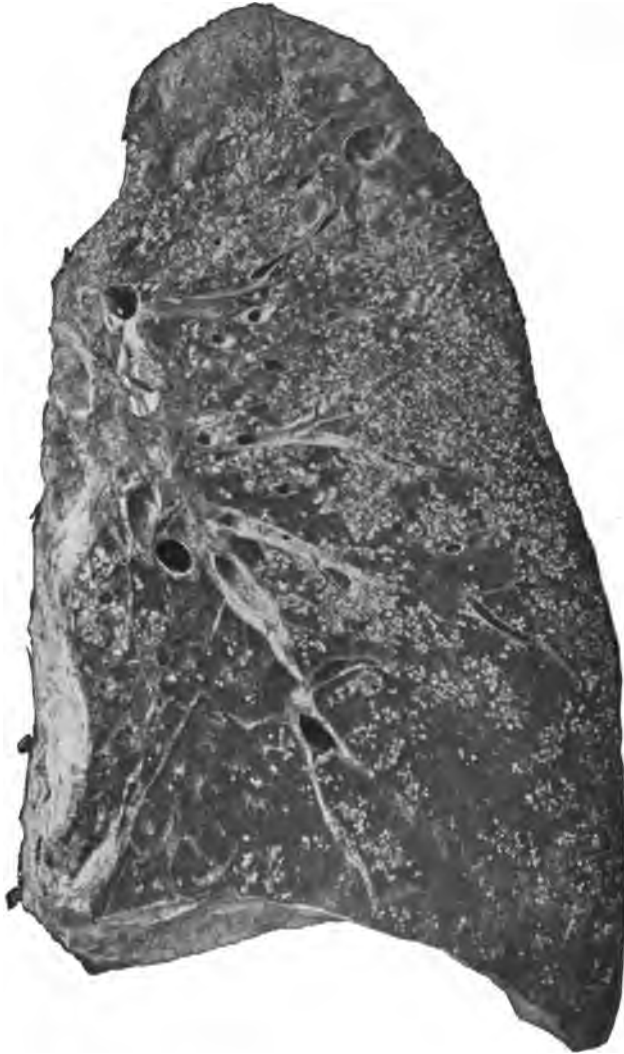


FIG. 400.—TUBERCULOUS BRONCHO-PNEUMONIA.

Showing the formation of cavities in the lung in acute phthisis. To the right are small, in the centre large, tuberculous bronchiectatic cavities. At the left are areas of tuberculous consolidation with caseation in their central portions.

larger and smaller, rough, irregular cavities may be formed (Fig. 398). The walls of the larger bronchi also may become the seat of a tuberculous inflammation with more or less necrosis (Fig. 399). Ulceration of these necrotic bronchial walls may lead to the formation of ragged cavities (Plate IX. and Fig. 400).

The secondary development of dense fibrous tissue in connection with tuberculous broncho-pneumonia is a marked feature of the persistent or chronic forms. Tuberculous broncho-pneumonia is one of the most important of that complex of pulmonary lesions called phthisis, and is commonly associated with other forms of tuberculous involvement of the organ—miliary tubercles, larger areas of consolidation, etc.



Miliary Tubercles and Tuberculous Broncho-Pneumonia with Diffuse (Chronic) Tuberculous Lesions in the Apex.

There is in the apex tuberculous consolidation with coagulation necrosis (caseation), new fibrous tissue, and a small cavity. The middle third of the lung contains many small single and clustered miliary tubercles and foci of tuberculous broncho-pneumonia. The lower third contains a few similar small tuberculous foci, also scattered and in clusters.

The appearance of the lung leads to the conjecture that tubercle bacilli may have been gradually disseminated from the earlier lesion in the apex. The blood-vessels are injected with blue.



COMPLEX FORMS OF NODULAR AND DIFFUSE TUBERCULOUS LESIONS.

(Phthisis.)

With or without the various well-defined forms of tuberculous broncho-pneumonia and miliary tubercles above described, there may be more or less circumscribed small or large areas of productive and exudative tuberculous inflammation of the lung with necrosis, both of the lung tissue, the new-formed tissue, and the exudate (Plate XII.). These may develop as the result of fresh infections of the lung through the lymphatics or otherwise. These areas or nodules may coalesce so that whole lobes or parts of lobes of the lungs may become consolidated (Plates VII. and VIII.). Microscopically, these consolidated areas may be composed of tubercle tissue more or less necrotic, with partial or total obliteration of the walls of the air spaces. On the other hand, when the process has been exudative as well as productive in character, one may see in the solid areas the outlines of the air vesicles and larger spaces; but these, together with the enclosed exudate, may be necrotic and granular with few stained nuclei and fragments of chromatin. Much of the exudate which fills the air vesicles either within or about these more densely consolidated areas may not be caseous or necrotic, but may consist of well-preserved or fatty epithelial cells, or of these with varying quantities of leucocytes and fibrin.

Aside from these complex forms of nodular and diffuse tuberculous lesions one may recognize a **Diffuse Exudative Tuberculous Inflammation of the Lungs of Acute and of Chronic Type.—Cheesy Pneumonia; Pneumonic Phthisis.**

1. **ACUTE TYPE.**—Sometimes large areas or whole lobes or the whole lung may be the seat of an exudative process by which the affected region becomes solidified, the exudate consisting of epithelium with more or less fibrin and pus. This exudate, together with the lung tissue, soon undergoes necrosis, so that the solidified lung becomes dense, mottled, and gray in color. Extensive disintegration (Fig. 401) of the consolidated and necrotic portions of the lung may take place, with the formation of large ragged cavities (see Plate X.). In many cases enormous numbers of tubercle bacilli are present in the exudate of the involved region in this type of exudative and necrotic pulmonary tuberculosis.

2. **CHRONIC TYPE.**—There may be a more gradual development of the exudate, involving larger or smaller areas, often with tuberculous thickening and necrosis of the walls of the air spaces. With this as with other forms of pulmonary tuberculosis there may be associated a growth of simple fibrous tissue with the formation of cavities.

Not infrequently the exudate in such forms of diffuse tuberculous inflammation of the lung is less cellular and more serous or sero-fibrinous in character, when the appearance of the consolidated region is translucent and gelatinous.

Obliteration of the larger blood-vessels by thrombosis or inflammation of the wall often plays an important part in most forms of tuberculous lesions of the lungs. When large trunks are involved, large lung

areas, supplied by the occluded vessels, particularly those in which exudate is present, may become necrotic *en masse*, then often appearing on section smooth, shining, grayish-white in color, and bloodless.

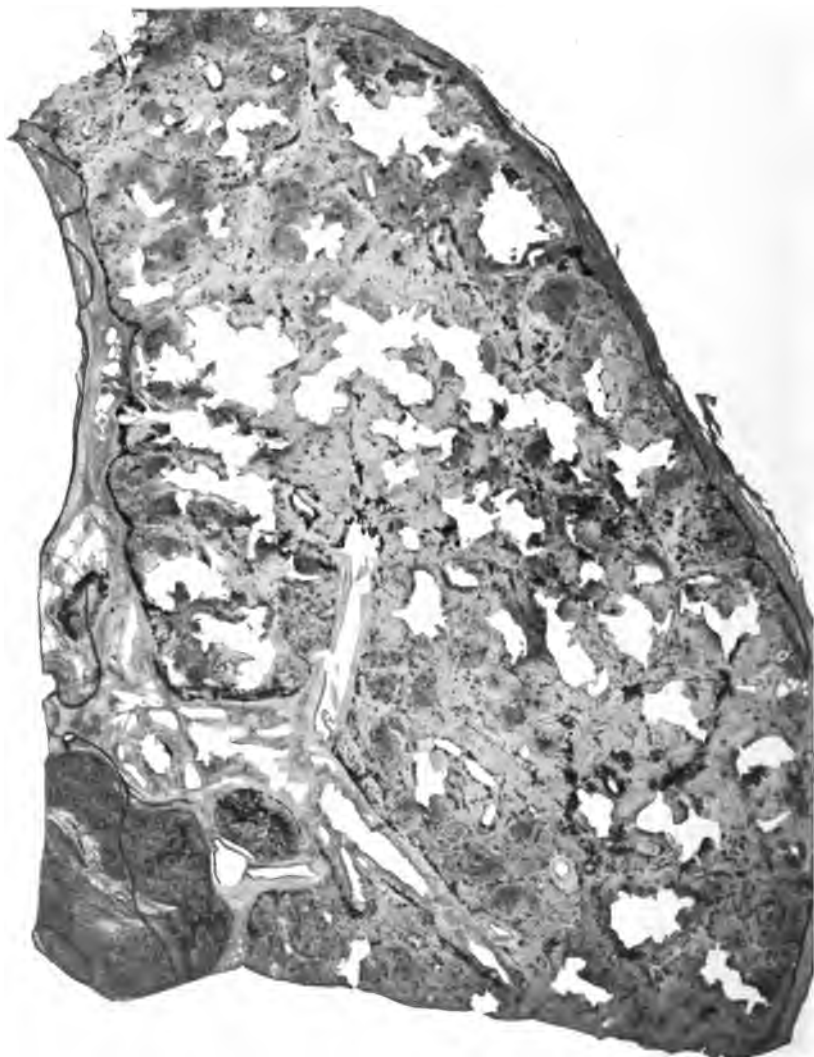
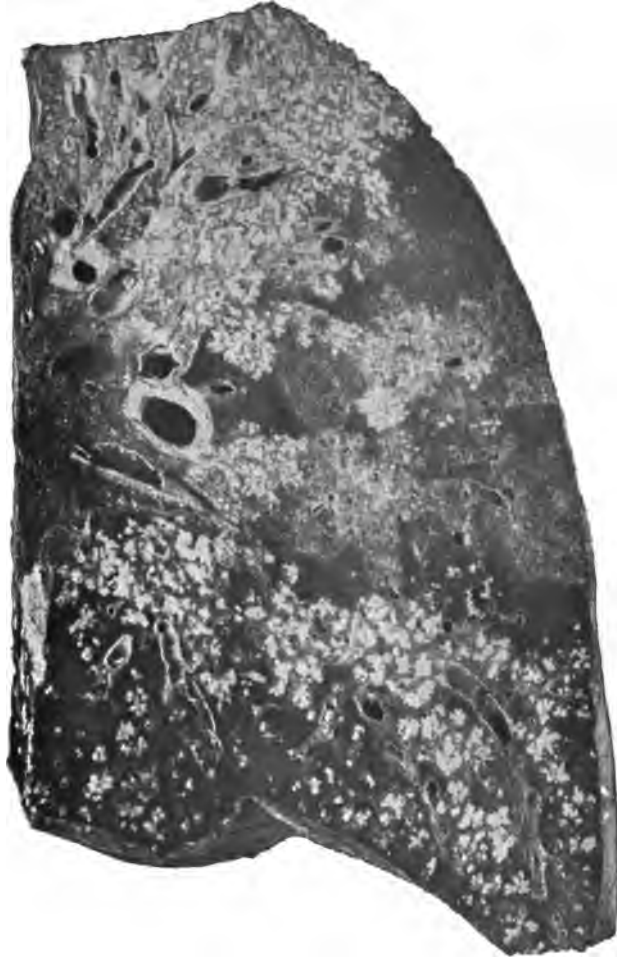

FIG. 401.—ACUTE PULMONARY TUBERCULOSIS—EXUDATIVE TYPE (ACUTE PHTHISIS—CHEESY PNEUMONIA); WITH EXTENSIVE DISINTEGRATION AND FORMATION OF CAVITIES.

The pleura is much thickened.

THE FORMATION OF CAVITIES IN PULMONARY TUBERCULOSIS.

We have seen that in tuberculous broncho-pneumonia ragged cavities may form by a progressive necrosis and disintegration of the thickened walls of the affected bronchi and the adjacent lung tissue (Plate IX.




Diffuse and Focal (Chronic) Pulmonary Tuberculosis—
“Chronic Phthisis.”

In the upper third of the lung there is tuberculous broncho-pneumonia with commencing ulceration of small bronchi: nearly complete consolidation from the extension and coalescence of small tuberculous foci and diffuse formation of fibrous tissue.

In the lower third of the lung are irregular, dense, sharply outlined tuberculous foci (chronic miliary tubercles).

In the middle third there is tuberculous pneumonia of the exudative type, the incompletely consolidated areas having become, in part, caseous.

The less involved portions of the lung in this, as in the other injected specimens, are the darker.



and Fig. 400). Similar destructive alterations may occur in the areas of tuberculous and necrotic tissue which involve larger and smaller portions of whole lobes (Plate XI.). This is most often rapid and extensive in solidified and necrotic areas of the exudative type (Plate X. and Fig. 401). These ragged cavities may communicate with one another as well as with the bronchi.

While at first without distinct limiting walls, if the necrotic process be not too active and extensive, new fibrous tissue may gradually form about tuberculous cavities (Plate XII. and Fig. 402); and these may become lined with granulation tissue or a layer of new-formed tubercle tissue. Here an enormous proliferation of tubercle bacilli may occur for long periods. These may be cast out in the sputum or aspirated into other parts of the lungs. The old blood-vessels of the involved portion of the lung may lie upon the walls or stretch across these cavities, sometimes with obliterated lumina, sometimes still permeable; and from these hæmorrhages may occur. There may be continuous and prolonged suppuration of the walls of the cavities and putrefactive processes may be incited by the advent through the air passages of various forms of bacteria. The walls of cavities may become fibrous with an arrest of the tuberculous process, and they may become shut off from bronchial communication.

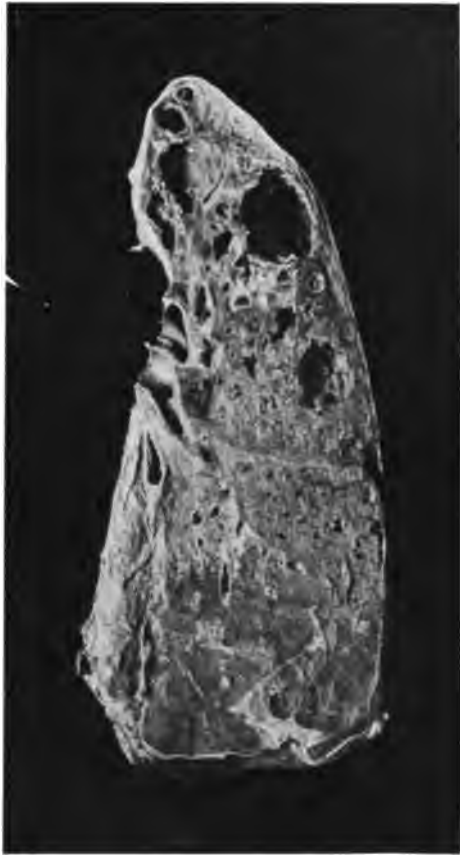


FIG. 402.—CHRONIC PULMONARY TUBERCULOSIS (CHRONIC PHTHISIS), WITH CAVITIES.

There is much dense fibrous tissue in the upper lobe surrounding and between the cavities, as well as in the upper portion of the lower lobe.

SECONDARY LESIONS IN PULMONARY TUBERCULOSIS.

A variety of secondary processes may be associated with the various phases of pulmonary tuberculosis which we have briefly reviewed. The *blood-vessels* in affected regions may be intact, or, as we have seen, their walls may be involved in the productive and necrotic processes, with thrombosis or obliteration of the lumen; or more or less extensive hæmor-

rhages may occur. If the consolidation be not complete, lung tissue, often in a condition of *atelectasis* or *emphysema* and with more or less cellular or granular exudate, may remain between the tuberculous areas. Miliary tubercles may be scattered among the larger consolidated masses or in parts of the lung otherwise free.

In chronic forms of pulmonary tuberculosis the anthracotic *pigment* is often conspicuous, particularly in the cheesy and fibrous areas, standing out in masses and streaks in contrast to the new or dead tissue. Furthermore, there may be associated with the lung lesions acute exudative or chronic fibrous *pleuritis* with adhesions; or tuberculous *pleuritis* of varying extent; *empyema* and *pneumothorax*. There is nearly always more or less chronic *catarrhal bronchitis* or *broncho-pneumonia* and frequently *bronchiectasia*.

Tuberculous inflammation in the bronchial lymph-nodes frequently accompanies and often precedes the development of pulmonary tuberculosis. In children the tuberculous lymph-nodes often extend far into the lung and may on softening give rise to cavities at a considerable distance from the hilus of the lung.

Tuberculosis in other parts of the body is common in connection with pulmonary tuberculosis.

In all these various processes new-formed *fibrous tissue*, not tuberculous in character, may develop, variously distorting the lungs and sometimes enclosing the tuberculous areas. There is much reason for the belief that the characteristic so-called tubercle-tissue formation in all phases of tuberculosis is a response of the living cells to injury, which as in other phases of inflammation is fundamentally conservative (see p. 107). But whether this be so or not, it is certain that it is through the development of fibrous tissue, which is so important a feature in persistent phases of pulmonary tuberculosis, that the delimitation or replacement of tuberculous foci, the encapsulation of tuberculous cavities, etc., occur. While, therefore, fibrous-tissue formation in the lung is frequently associated with the necrotic and other destructive tuberculous lesions, and is often a very conspicuous factor, it should be remembered that the healing which takes place in the majority of cases in man after moderate infection is achieved through its agency.

It is especially upon the presence or absence of fibrous tissue in the lesions that the distinction between acute and chronic phthisis is based.

It will be seen from this brief outline of various prominent phases of pulmonary tuberculosis that the gross appearances of the lungs are most diverse, although the processes by which these changes are induced are few and comparatively simple. While no two lungs are quite similar in the complex phases of the lesion, systematic gross and microscopical examinations soon enable the student to recognize the type of lesion under great complexity of detail.

THE DISTRIBUTION OF THE LESIONS IN PULMONARY TUBERCULOSIS.

Aside from general miliary tuberculosis in which the tubercles are widely distributed throughout one or both lungs, the most common seat



Diffuse (Chronic) Pulmonary Tuberculosis—"Chronic Phthisis."

In the upper half of the lung there are scattered miliary tubercles and irregular areas of consolidation, with a diffuse formation of fibrous tissue; the pleura is thickened. A large portion of the lower lobe is densely consolidated from tubercle tissue and exudate with coagulation necrosis of the involved regions. These regions are light in color, dense, hard, and bloodless. Such dead caseous areas may persist for some time, or may soften and disintegrate, giving rise to cavities.





Tuberculous Bronchiectatic Cavities in Pulmonary Tuberculosis.

The advancing tuberculous involvement of the walls of the larger bronchi in the upper lobe is associated with ulceration, so that the bronchiectatic cavities gradually become larger. In the upper portion of the upper lobe there is diffuse consolidation with caseation; the lower portion of the lobe shows miliary tubercles and partial consolidation of the lung about them by exudate.

The lower lobe is free save for a few scattered tubercles. The blood-vessels are injected with blue so that the uninvolved portions of the lung are dark.

and starting-point of tuberculous lesions in adults is the apical region or the depth of the lung, particularly the right, somewhat below the apex.¹ In children, the tuberculous process more frequently commences in the bronchial lymph-nodes (Plates III. and XI.).

From the apex the tuberculous process may extend downward, and with various forms of lesions involve more or less of the lungs. It is common to find at autopsies older fibrous lesions about the apices while marks of more active processes are to be seen below (Plate XII.). In a considerable percentage of bodies examined at autopsies, small and often healed tuberculous foci are found at the apex or in the bronchial lymph-nodes without evidence of extension of the process.

CONCURRENT INFECTION IN PULMONARY TUBERCULOSIS.

While it has been definitely established that tubercle bacilli are the excitants of both the productive and exudative forms of tuberculous inflammation, these bacilli are not infrequently associated in pulmonary tuberculosis with other organisms, especially with the *Streptococcus* and *Staphylococcus pyogenes*, with *Diplococcus pneumoniae*, and the influenza bacillus.

There is reason to believe that in many cases at least the concurrent infection of tuberculous lungs with the *Streptococcus pyogenes* may be an important factor in the formation of cavities in areas of consolidation already established.² The pyogenic cocci apparently play an important part in the bronchitis which so often accompanies acute and chronic phthisis.

Bacteriæmia has been shown to exist in a certain proportion of cases of active progressive pulmonary tuberculosis, but in many such cases the blood is sterile.³

Artificial Pulmonary Tuberculosis in Animals.

Much light may be gained upon the successive steps in the development of the lesions of pulmonary tuberculosis as well as upon the rapidity with which in a susceptible animal the lesion may develop, by the study of the tuberculosis artificially induced in rabbits with pure cultures.

By the injection of tubercle bacilli alone and associated with streptococci into the lungs of rabbits through the trachea, it has been possible to reproduce very closely the lesions of pulmonary tuberculosis in man.⁴

If a small quantity of a pure culture of the tubercle bacillus in very minute flocculi be mixed with a considerable quantity of salt solution and introduced into the lungs of rabbits through the trachea, a number of small areas of consolidation are produced which have the gross appearance of miliary tubercles (Fig. 403). These small areas of consolidation are composed of epithelial cells and leucocytes. After the development of these cell masses, which may occur within a few hours, they may remain with little apparent change, or become more or less infiltrated with leucocytes, or become cheesy,

¹ For a suggestive consideration of apical vulnerability see *Hutchinson*, "Studies in Human and Comparative Pathology," 1901, p. 81.

² For bibliography of concurrent infection in tuberculosis see *Lartigau's* article on the bacteriology, pathology, and etiology of tuberculosis, "Twentieth-Century Practice of Medicine," vol. xx.; also for special bibliography of concurrent infection in pulmonary tuberculosis see *Marfan*, *Boucharde* and *Brissaud's* "Traité de Médecine," t. vii., p. 234, 1901.

³ For a study of bacteriæmia in pulmonary tuberculosis see *Jochmann*, *Deut. Arch. f. klin. Med.*, Bd. lxxxiii., p. 558, 1905.

⁴ *Prudden*, *New York Med. Jour.*, July 7th, 1894.

or be surrounded by a dense zone of small spheroidal cells; or small foci of new tissue with more or less exudate, and necrosis, may form.

When larger quantities of the tubercle bacillus are introduced into the lungs through the trachea, large areas of consolidation are formed (Fig. 404), which may involve whole lobes or whole lungs.

Microscopically, these consolidated areas are practically identical with those which are found in man in various forms of tuberculous broncho-pneumonia. A later fibrous-tissue development may occur, and blood-vessels may be obliterated.



FIG. 403.

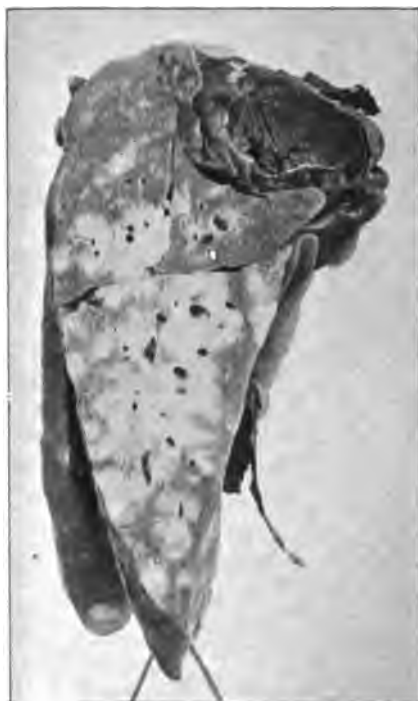

FIG. 404.

FIG. 403.—EXPERIMENTAL TUBERCULOUS INFLAMMATION (MILIARY) IN THE LUNG OF A RABBIT.
The rabbit's lung shows miliary foci of tuberculous inflammation twenty-two days after the injection through the trachea of a small quantity of broth culture of the tubercle bacillus.

FIG. 404.—EXPERIMENTAL TUBERCULOUS INFLAMMATION IN THE LUNG OF A RABBIT.
Large areas of solidification in the lung twenty-eight days after the injection through the trachea of a considerable quantity of a pure culture of the tubercle bacillus. The lesions resemble those of acute phthisis in man.

In the presence of the tubercle bacillus alone the consolidated and caseous areas rarely soften and break down so as to form cavities. If, however, after the tuberculous lesion of the lung has been induced and allowed to continue for a number of days, a culture of *Streptococcus pyogenes* be introduced into the trachea of the rabbit, within twenty-four hours the caseous areas often begin to soften. The softening may begin at the centre, or may surround a central portion of the necrotic mass. The softening is soon followed by absorption, and so cavities are formed of varying sizes and shapes (Fig. 405).

It will thus be seen that in the rabbit a concurrent infection with the tubercle




Pulmonary Tuberculosis—Exudative Type—with Large Cavities.

The entire lung is solid from new-formed tubercle tissue and exudate which are both largely in a condition of coagulation necrosis.

The thickened trunks of the larger pulmonary vessels are exposed in the depths of the ragged communicating cavities.

This lung was hardened in alcohol without injection of the blood-vessels.



bacillus and the streptococcus has an important bearing upon the breaking down of lung tissue which leads to the formation of cavities. While it would not be wise to assume from these experiments on the rabbit that a similar condition is always present when cavities form in man, we have seen that in fact a similar concurrent infection in man in acute phthisis actually does often exist.

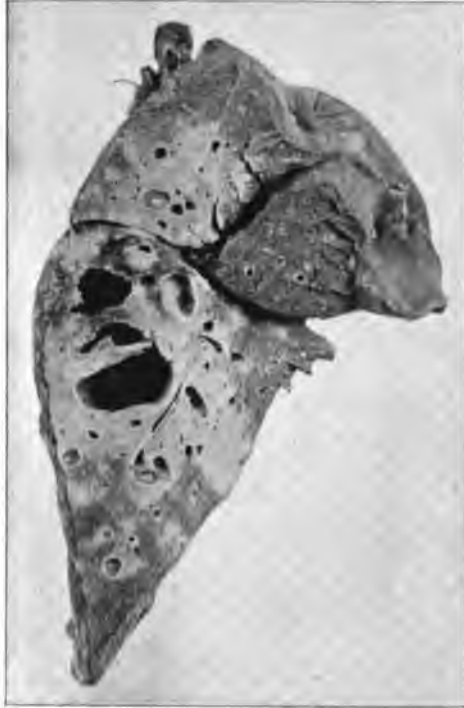

FIG. 405.—EXPERIMENTAL TUBERCULOUS INFLAMMATION IN THE LUNG OF A RABBIT, WITH THE FORMATION OF CAVITIES.

The lung was injected with a considerable quantity of tubercle-bacillus culture through the trachea, followed after twenty-eight days by the injection of the broth culture of the *Streptococcus pyogenes*. Animal killed seven days after the streptococcus injection. The specimen shows large areas of consolidation with cavities. The lesions resemble those of acute phthisis with cavities in man.

SYPHILITIC PNEUMONIA.

Persons suffering from inherited or acquired syphilis sometimes develop inflammations of the lungs which seem to be due to the syphilitic infection. The lungs may then be affected in several different ways.

There may be well-defined large or small gummata with or without interstitial and more or less exudative pneumonia. There may be a formation of new fibrous tissue in the walls and lung tissue about the bronchi, often with ulceration of the mucous membrane and distortion of these structures. There may be, particularly in the new-born, lobular or lobar hepatization, the affected region appearing reddish or gray or white. This is due to a growth of new cellular tissue in the walls of the air

spaces and to an exudate largely of epithelial cells in the air spaces. Infarctions of the lung from obliterating endarteritis may be present. It is often difficult to determine in many cases of interstitial inflammation of the lungs whether the lesion be syphilitic or not.¹

TUMORS.

Fibroma and **osteoma** are rare. **Enchondroma** may occur as a primary tumor originating in the cartilages of the bronchi. **Sarcoma** is not

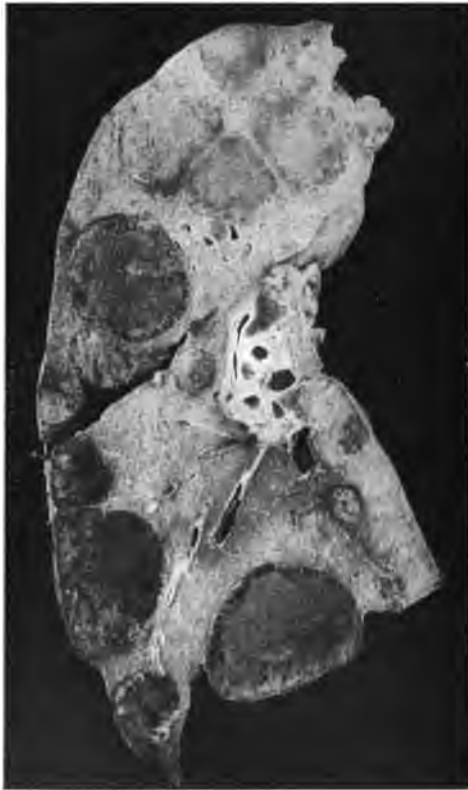

FIG. 406.—SECONDARY CARCINOMA OF THE LUNG. The primary tumor involved the gall-ducts, liver, and pancreas. The metastatic tumors in the lung were in part white, in part dark red from interstitial hæmorrhage.

common and is usually secondary.² "**Lymphoma**" may develop in the lungs in leukæmia and pseudo-leukæmia. **Endothelioma** is of occasional occurrence in the lung, and, following the subpleural lymph-vessels, may

¹ For a bibliography of pulmonary syphilis consult *Flockemana*, *Centralbl. f. Path.*, Bd. x., p. 449, 1899.

² For a study of primary sarcoma of the lung see *Eckersdorff*, *Centralbl. f. Path.*, Bd. xvii., p. 355, 1906; also *Pater and Rivet*, *Arch. de méd. exp.*, t. xviii., p. 85, 1906.

form a reticular raised white network on the surface of the lung (Figs. 407 and 408). **Adenoma** as a primary tumor is rare. **Primary carcinoma** of the lung, originating in the bronchi, is of occasional occurrence.¹

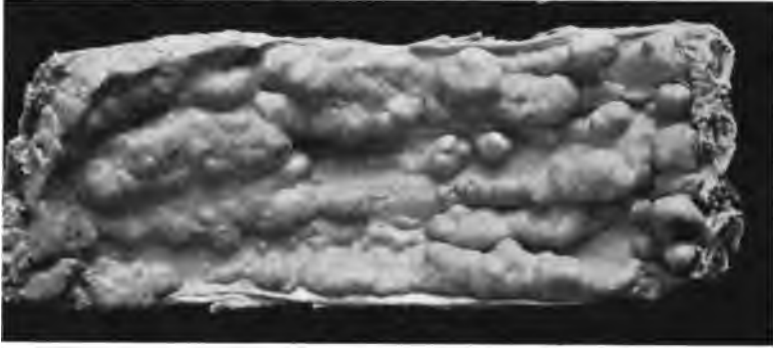


FIG. 407.—ENDOTHELIOMA OF THE PLEURA.

The inner surface of a segment of the costal pleura, containing three of the ribs, is shown in the cut.

It may be associated with exudative pneumonia and involve large portions of the lungs as well as the pleura. **Secondary carcinoma** of the lung is not infrequent. The malignant growths in the lung may occur

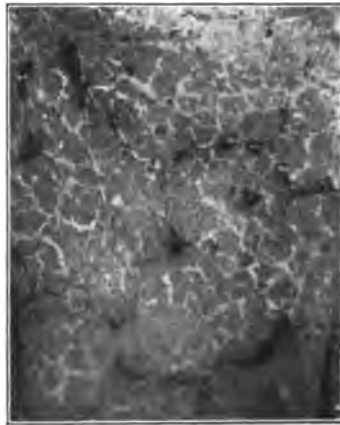


FIG. 408.—ENDOTHELIOMA OF THE PLEURA.

Showing the growth of the tumor along the superficial lymph-vessels.

as circumscribed nodular masses, displacing the lung tissue (Fig. 406), or they may infiltrate the lung, often following the bronchi and larger blood-vessels. The cells of such tumors often grow into and fill up the air

¹ See *Passler*, *Virch. Arch.*, Bd. cxlv., p. 191, 1896, bibl.

spaces of the lung, over large areas, without immediate involvement of their walls.¹

Dermoid cysts have been found in the lung.

THE MEDIASTINUM.

INFLAMMATION.—Suppurative inflammation may occur either in the anterior or posterior mediastinum. It may be caused by fractures, caries or necrosis of the sternum and vertebræ, by perforation of the œsophagus, by suppuration of the lymph-nodes, or by pleurisy, or may occur without discoverable cause.

The pus may infiltrate the connective tissue, or may form abscesses which may attain a large size. The inflammation may extend to the pleura or the pericardium, the abscesses may displace the heart, the lungs, or the sternum; or they may perforate through the skin, into a pleural cavity, the œsophagus, the trachea, or a bronchus.²

A few cases of chronic inflammation of the tissues of the mediastinum have been reported—chronic mediastinitis.³ Lesions of the tracheal and bronchial lymph-nodes are considered on page 592.

TUMORS.—The most common form of new growth in the mediastinum is that known by the names of *lymphoma*, *lympho-sarcoma*, and *lymph-adenomâ*.

These tumors are confined to the mediastinum, or they are associated with similar growths in other parts of the body in the disease called "pseudo-leukæmia." Persons between the ages of twenty and thirty years seem to be the most liable to the growth, but it is also not uncommon in children. It begins in the lymph-nodes in the mediastinum, and at the root of the lung. It increases at first slowly, then more rapidly, and gradually infiltrates the adjoining tissues. In this way the walls of the trachea, bronchi, aorta, the pericardium, the pleura, and the lung, become infiltrated with compression of the surrounding organs.

The growth is composed of a fibrous stroma associated with small round cells, the relative quantity of cells and stroma varying in the different cases.

Besides this form of tumor there may also occur in the mediastinum tumors similar to those which grow in the pleura and behind the peritoneum—tumors which resemble both the sarcomata and carcinomata, and which it is difficult to classify. Aberrant thyroid-gland tissue may be found in the mediastinum.

Complex tumors belonging among the fetal inclusions or teratomata are of occasional occurrence in the anterior mediastinum.⁴ They may contain bone, cartilage, connective tissue, muscle, hairs, skin, etc. Cysts sometimes lined with ciliated epithelium may form in such tumors.⁵

The Pleura.

HYDROTHORAX.

Non-inflammatory accumulations of clear serum in the pleural cavities are of frequent occurrence. They occur under conditions similar to those which lead to dropsy in other parts of the body—lesions of the heart, liver, and kidneys, and changes in the circulation and in the composition of the blood.

If the amount of serum be large it may compress the lower lobes of the lungs.

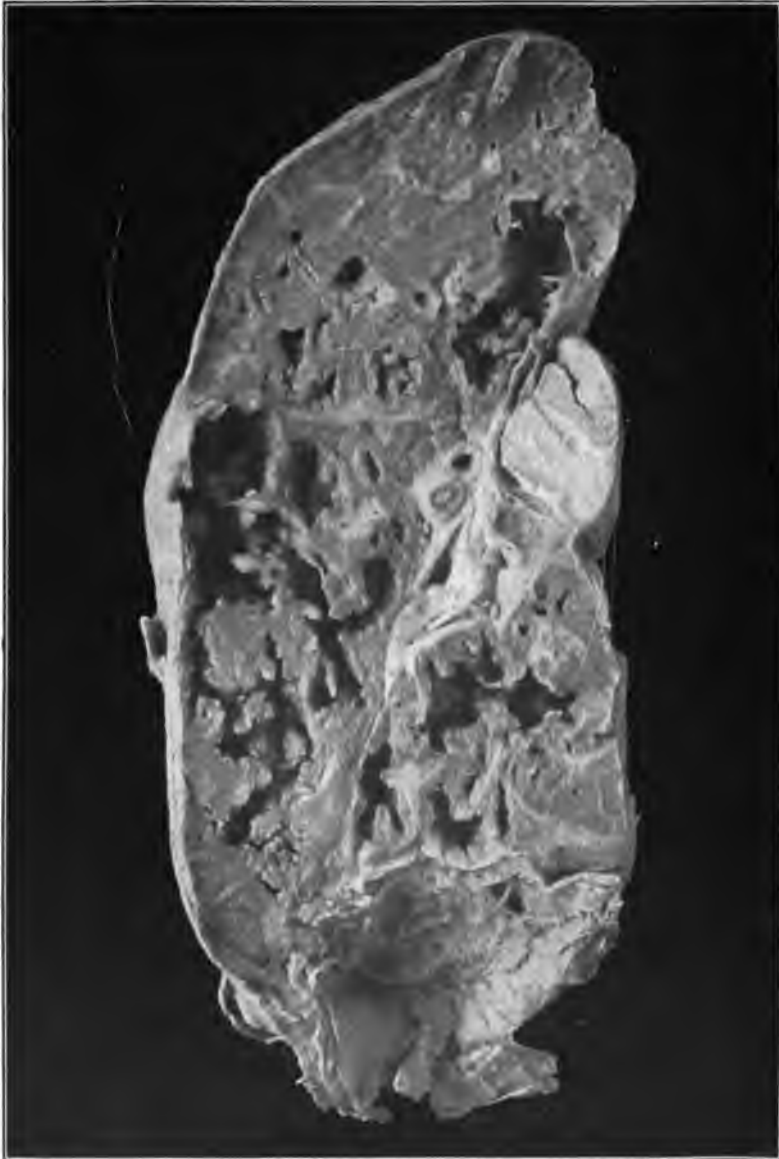¹ For a consideration of the diagnosis of malignant tumors of the lung consult *Adler*, *New York Med. Jour.*, Feb. 8th and 15th, 1896, bibl.

² For tuberculous lesions of the tracheo-bronchial lymph-nodes see reference, p. 592.

³ *Whipham*, *Lancet*, 1899, vol. i., pp. 882, 947, bibl.


⁴ See *Mandlebaum*, *Am. Jour. Med. Sciences*, vol. cxx., p. 64, 1900.

⁵ Consult *Hare*, "Tumors of the Mediastinum," *Phila.*, 1889; also *Zahn*, *Virchow's Archiv*, Bd. cxliii., pp. 170 and 416, 1896; also *Lohrisch*, *Lubarsch and Ostertag's "Ergebnisse,"* Jahrg. vii., 1900-1901, p. 912, bibl.; also, for a study of dermoid cysts of the mediastinum, see *Morris*, *Med. News*, vol. lxxxvii., pp. 404, 438, 494, 538, 1905.



Pulmonary Tuberculosis (Chronic), with Large Cavities.

The ragged communicating cavities involve a large part of the lung and are bronchiectatic in origin. The bronchial lymph-nodes are enlarged, tuberculous, and caseous. The pleura and interlobar septum are thickened by the formation of dense fibrous tissue.





Chronic Pulmonary Tuberculosis with a Fibrous-Walled
Cavity at the Apex.

The fibrous wall of the cavity is dense and is continuous with the greatly thickened pleura and with the diffuse new-formed connective tissue throughout the upper lobe. The upper lobe is greatly reduced in size by the cicatricial contraction of the fibrous tissue. The lower lobe shows two areas of tuberculous consolidation; both are caseous in the central portions; the upper shows commencing tuberculous bronchiectasia. The upper part of the fibrous wall of the cavity, firmly adherent to the thoracic wall, has been cut away.

HYDRO-PNEUMOTHORAX—PYO-PNEUMOTHORAX.

The presence of air in the pleural cavities is usually associated with a serous or purulent exudate. It may occur as the result of perforation of the lung, from rupture, from ulceration of tuberculous lesions at the pleural surfaces, from injuries to the chest wall, perforation of the diaphragm by suppurative or cancerous lesions of the œsophagus, stomach, or intestine, as well as in a variety of other conditions. Gas may form in the pleural cavities in infection by the *Bacillus aërogenes capsulatus*.¹

HÆMORRHAGE.

Subpleural ecchymoses may occur in asphyxia or during infectious diseases or intoxications. More extensive extravasations of blood—hæmothorax—may be the result of injuries to the wall of the thorax or the rupture of aneurism.

Hæmorrhagic Exudates are usually associated with tuberculous inflammation of the pleura or with infarctions of the lungs, carcinoma, or injuries, infectious diseases, or cirrhosis of the liver.

INFLAMMATION. (Pleuritis, Pleurisy.)

Inflammation of the pleura may occur as an independent lesion, but it is commonly associated with pathological processes in the lungs, pericardium, abdomen, or chest wall. It may be exudative in character, usually associated with more or less proliferation of the mesothelial ("endothelial") and connective-tissue cells, or it may be productive with the formation of new connective tissue. These phases of inflammation may be associated. Through the production of new connective tissue, repair of the acute inflammatory lesion is commonly effected. In the exudative forms of pleurisy the exudate may consist of fibrin, or of serum and fibrin, or of serum with fibrin and pus.

Simple Fibrinous Pleurisy (Dry Pleurisy; Pleuritis Sicca).—This may involve circumscribed areas of the costal, mediastinal, diaphragmatic, or pulmonary pleura, less frequently the entire pleura of one side of the chest. The affected portions of pleura are dull and lustreless and coated with fibrin, opposing surfaces often being joined by bands of fibrin. There are swelling, degeneration, proliferation, and exfoliation of the mesothelium, with swelling and proliferation of the connective-tissue cells beneath. Exceptionally, there is involvement of the entire pleura of one side, with the production of such a large amount of fibrin as seriously to compress the lung.²

Sero-fibrinous Pleurisy (Pleurisy with Effusion).—This is the most common form of pleurisy. As a rule, it involves the greater part of the

¹ For a study of pneumothorax see *Emerson*, Johns Hopkins Hosp. Rep., vol. xi., p. 1, 1903.

² For a study of the origin of fibrin and adhesions of the serous membranes consult *Heinz*, Virch Arch., Bd. clx., p. 365, 1900; also *Gaylord*, Jour. Exp. Med., vol. iii., p. 1, 1898, bibl.

pleura of one side of the chest. Sometimes, however, the pleura of both sides of the chest is involved, and then the pericardium also is often inflamed.

While the inflammation is in progress the surface of the affected pleura is coated with fibrin, and bands of fibrin stretch between the parietal and pulmonary pleuræ. In the pleural cavity is serum in variable quantity. This serum is clear, or turbid from the presence of exfoliated mesothelium, leucocytes, and flocculi of fibrin or red blood cells. The lung is compressed in different degrees and positions, according to the quantity of the serum and the character of the adhesions. The heart may also be displaced by the accumulated exudate.

The natural termination of such a pleurisy is the recovery of the patient, with thickenings of the pleura and adhesions. The irregular terminations are: The death of the patient, the protracted existence of the fibrin and serum, and the change of the character of the inflammation so that pus is produced.

If the patient recover, the serum is absorbed, the fibrin disappears, and repair is effected, as in simple fibrinous pleurisy, by the formation of granulation tissue, which gradually becomes dense and cicatricial in character and may remain as local or general thickenings or firm adhesions of the opposed pleural surfaces. The lung may be distorted by contraction of the new-formed connective tissue. The exudates in the sero-fibrinous form of pleurisy do not usually infiltrate the pleura, but gather upon its surface and in the cavity.

THE EXCITANTS OF SERO-FIBRINOUS PLEURISY.—Cultivations from the exudate give in the larger proportion of cases negative results; but the pneumococcus, *Streptococcus pyogenes*, *Staphylococcus aureus* and *albus*, and the typhoid bacillus have been isolated. When the inflammation of the pleura is consecutive to acute lobar pneumonia, the pneumococcus may still not be found in the exudate. The presence of the streptococcus is frequently followed by the formation of pus. The organisms named above may be present alone or in various associations. Many cases with simple sero-fibrinous exudate prove on inoculation to be tuberculous.¹

Suppurative Pleurisy (Empyema).—Suppurative pleurisy may occur either with or without the formation of a considerable sero-fibrinous exudate. The exudate may be purulent from the beginning, or a sero-fibrinous exudate may assume this character.

The pleural cavity in empyema is partly or completely filled with purulent fluid, and the lung is either compressed against the vertebral column or partly adherent to the chest wall. Sometimes, however, the purulent fluid is shut in by adhesions, either between parts of the lung and the thoracic wall, or between the lung and the diaphragm, or between the lung and the pericardium, or between the lobes of the lung.

The fluid in the pleural cavity is usually a thin, purulent serum,

¹ For a study of the bacteria in exudative pleuritis, with the earlier bibliography, consult *Prudden*, *New York Med. Jour.*, June 24th, 1893. For fuller data see *Netter*, *Bouchard* and *Brissaud's* "Traité de Médecine," t. vii., p. 399, 1901.

composed of serum, pus cells, mesothelial cells, and flocculi of fibrin; but sometimes this fluid is thick and viscid.

While in children the more or less active suppurative process in the pleura may continue for a long time without deep involvement of the pleura, in adults granulation tissue may form upon the pleura, which thus becomes gradually thickened and may so remain for months with its inner vascular surface covered with pus and fibrin. In such cases, as well as in less chronic forms, the fibrin fibrils are often swollen and coalesce to form irregular homogeneous or finely granular masses. Resolution may occur in one region of the pleura while the exudate in another may become encapsulated by new-formed connective tissue.

In old cases the thickening of the pleura may be great and it may become calcified.¹ The perichondrium of the cartilages and the periosteum of the ribs may become inflamed, with necrosis of the cartilages and ribs or a production of new bone. Necrosis and gangrene of the involved pleura may occur and putrefactive process be set up in the exudate. The suppurative process may extend from the pleura involving adjacent parts, such as the fasciæ, the muscles, the skin, the diaphragm, or the lungs. Thus the pus may find an exit, through the wall of the thorax, into the peritoneal cavity or into the lungs.

In inflammation of the pleura the process may extend to the lymphatics in the interlobular septa, around the bronchi, and around the blood-vessels. This interlobular lymphangitis occurs more frequently in children than in adults. The lymphatics in the interlobular septa and those around the bronchi and blood-vessels are distended with pus cells, the septa are much thickened, and the lobules separated from each other.

Sero-fibrinous pleurisy and empyema may occur as complications of infectious diseases, such as scarlatina, typhoid fever, and various forms of septicæmia, or by an extension of an inflammatory process from such adjacent parts as the pericardium, lungs, mediastinum, etc.² The various forms of pneumonia are frequently associated with local or general inflammation of the pleura.

THE EXCITANTS OF EMPYEMA.—*Streptococcus pyogenes* is the most frequent excitant of suppurative inflammation of the pleura. According to the statistics of Netter this organism has been found in a little over forty per cent. of the cases examined of all ages. The pneumococcus has been found in over twenty-five per cent. of cases examined. The streptococcus and the pneumococcus are associated in a small proportion of cases. Of less frequent occurrence are *Staphylococcus pyogenes*, *Bacillus typhosus*,³ *Bacillus coli communis*, the gonococcus, the pneumobacillus of Friedländer, and the influenza bacillus. In empyema with fetid exudate, various forms of bacteria may be present. While in the adult the streptococcus is most often found in the empyemic exudate,

¹ For a résumé of our knowledge of various calcifications in the lungs, and allied conditions often called "lung stones," consult *Polailon*, "Les Pierres du Poumon," etc., Paris, 1891; or *Legry*, *Arch. gén. de méd.*, vol. i., pp. 337 and 466, 1892.

² For a study of relation of œsophageal diverticula to empyema see *Starck*, *Arch. f. Verdauungskr.*, Bd. vii., 1901, p. 1.

³ Consult for cases and bibl. *Gordinier and Lartigau*, *Am. Jour. Med. Sci.*, vol. cxxi., p. 43, 1901

in young children the pneumococcus is, according to Netter,¹ most common.

Chronic Pleurisy with Adhesions.—This form of pleurisy may follow one of the varieties of pleurisy just described, it may be associated with emphysema and chronic phthisis, or it may occur by itself.

After death the pulmonary and costal pleura are found thickened and joined together by numerous adhesions. These changes may involve only a part or the whole of the pleura on one or both sides of the chest.

The thickened pleura is covered with mesothelium; the new connective tissue may be very dense and may contain few or many cells. Blood-vessels may be numerous and irregular in distribution or few in number. New lymph-vessels are formed with the growth of the new tissue.² These, as well as the old lymph-vessels, may be dilated, forming small cysts.

Tuberculous Pleuritis.—Acute general tuberculosis of the pleura is usually secondary to tuberculous inflammation elsewhere in the body, either in the lungs, which is most common, or the bronchial lymph-nodes, peritoneum, bones, etc., or it may be a part of a general miliary tuberculosis. There may be localized or widely disseminated miliary tubercles upon or beneath the pleural surfaces, either in direct association with lesions beneath the pulmonary pleura or apart from these or upon the costal pleura. The tuberculous foci may be larger and more diffuse. The minute characters of the inflammation are not essentially different from those found in tuberculosis in connective tissue elsewhere, but the mesothelial cells covering the pleura may share largely in the early phases of the new growth.

If the process be prolonged, much dense fibrous tissue may be formed in which are miliary tubercles in various stages of coagulation necrosis, or larger patches of necrotic tissue surrounded by miliary tubercles or diffuse tuberculous tissue.

With acute types of tuberculous inflammation of the pleura more or less exudate may form. This may be sero-fibrinous, often with very little fibrin, or, as is frequently the case, it may be tinged or deeply colored with blood. The exudate may be purulent. The tubercle bacillus may be associated with other bacteria, most often with the *Staphylococcus pyogenes* in the purulent exudate.

Many cases of pleuritis with a sero-fibrinous exudate giving no growth of bacteria on the ordinary culture media are found to be tuberculous, by the inoculation of guinea-pigs with the fluid.

Chronic Miliary Tubercles.—Miliary tubercles of the pleura, chronic in form, mostly composed of fibrous tissue, with cheesy degeneration or calcification, are very common, and are frequently associated with tuberculous bronchial lymph-nodes without tuberculosis in other parts of the body. These tubercles are usually widely scattered over the pleura and are almost always associated with anthracotic pigmentation.

¹ Netter, Bouchard and Brissaud's "Traité de Médecine," t. vii., p. 445, 1901. For a study of the ways of infection of the pleura see Grober, Deut. Arch. f. klin. Med., Bd. lxxviii., p. 296, 1900, bibl.

² For a study of the formation of new lymph-vessels in pleurisy see Guyot, Ziegler's Beiträge, Bd. xxxviii., p. 207, 1905.

The dense fibrous tubercle or the cheesy or calcified portion may be seen as a lighter spot in the pigmented area (Fig. 376). Such tubercles are sometimes accompanied by minute cystic dilatations of the lymph-vessels on which they are formed.

These pleural tubercles develop along the subpleural lymphatic vessels, or in the areas of lymphoid tissue or in the minute subpleural lymph-nodes.¹

The presence of these healed tubercles, which rarely harbor stainable tubercle bacilli, together with the simultaneous involvement and pigmentation of the bronchial lymph-nodes, affords strong evidence of the frequency of the direct infection of the lungs through the respiratory passages. They are formed along the lines of lymph drainage of the lungs which ultimately enter the bronchial nodes. Since in this drainage inhaled pigment particles and tubercle bacilli are deposited together, the frequent association of pigmentation and tuberculosis is comprehensible.

Hodenpyl² has shown the great frequency of those chronic pleural pigmented tubercles, and Ribbert³ believes that the tuberculous process precedes the local pigmentation and furnishes suitable conditions for it.

TUMORS.

Fibroma, sarcoma, and endothelioma may occur as primary tumors of the pleura. Small, white, slightly projecting, often pigmented elevations of the pleura, either single or multiple, are common. These were formerly regarded as mostly miliary fibromata. But Hodenpyl and

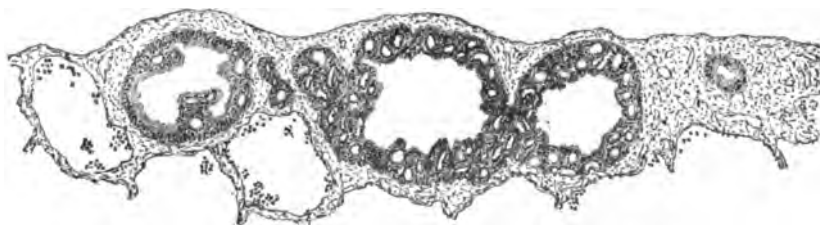

FIG. 409.—ENDOTHELIOMA OF THE LUNG.

The growth is in the subpleural lymph-vessels, which seen from the pleural surface in the fresh lung formed a white raised network over a considerable portion of one lung. The lymph-vessels in the cut are seen in transverse section.

others have shown that while some may be fibromata or lymphangioma or air cysts, they are mostly fibrous masses which replace or enclose miliary tubercles.⁴ Fibroma and lipoma formed in the subpleural tissues may encroach upon the pleural cavity. *Endothelioma* usually occurs in the form of larger and smaller, flat or projecting, irregular nodular masses

¹ See p. 603.

² *Hodenpyl*, *Med. Record*, vol. lv., p. 903, 1899.

³ *Ribbert*, *Deut. med. Woch.*, p. 1615, 1906.

⁴ See ref. *Hodenpyl*, above.

(Fig. 407), frequently most marked and extensive upon the costal pleura (Figs. 408 and 409).¹ This as well as other tumors of the pleura may be associated with an exudative pleuritis.

Carcinoma, primary in the thyroid, mamma, œsophagus, and stomach, may invade the pleura. Echinococcus and other **cysts** of the pleura have been recorded.²

¹ For bibliography of endothelioma of the pleura consult *Glockner, Zeits. f. Heilkunde*, Bd. xxviii., p. 209, 1897.

² For a description of ciliated cysts of the pleura see *Zahn, Virchow's Arch.*, Bd. cxliii., p. 170, 1896.

CHAPTER VII.

THE DIGESTIVE SYSTEM.

The Mouth.

Malformations.

MALFORMATIONS of the lips and cheeks are usually associated with defective formation of the bones of the mouth. The entire process is generally due to an arrest of development or a failure of the branchial arches to fuse normally (see Figs. 175 and 177).

1. The lower jaw is absent; the upper jaw and hard palate are small and imperfectly formed; the temporal bones nearly touch in the median line. The lower part of the face is, therefore, wanting; the mouth is absent, or small and closed posteriorly; the tongue is absent. Such a malformation is rare; the foetus is not viable.

2. The face remains in its early foetal condition of a large cleft; the mouth and nose form one cavity; the orbits may be united in the same cavity. The foetus is not viable.

3. There is a cleft in the upper lip, upper jaw, and hard palate. The cleft corresponds to the point of junction of the processes of the superior maxilla with the intermaxillary bone. There may be one cleft or two, one on either side of the intermaxillary bone. The cleft involves the lip alone,—harelip (Fig. 176)—or the lip and superior maxilla, or the lip, maxilla, and palate. There may be a single, or a double cleft in the palate, and the cleft may involve either the hard or soft palate, or both. If there are two clefts of the lip and maxilla the portion of lip and bone between them may be small, or entirely absent so as to leave a large open space. The soft palate may be entirely absent. This is a common malformation and does not endanger life.

4. Rarely there is a cleft involving the middle of the lower lip, and sometimes extending into the inferior maxilla.

5. Either the inferior, or the superior, or both maxillary bones may be abnormally small.

6. The edges of the lips may be partly or completely joined together. The opening of the mouth may be only a round hole.

7. The lips may be absent or imperfectly developed.

8. The corners of the mouth may be prolonged by clefts in the cheeks nearly to the ears.

INFLAMMATION.—(Stomatitis.)

Catarrhal stomatitis is most frequent in children and occurs with a great variety of local and general disturbances.

During life the congestion and swelling of the mucous membrane may be well marked and there are often white patches, produced by the death of the superficial epithelial cells. There may be an increased production of mucus, or, instead of this, the entire mucous membrane is unnaturally dry. In addition to hyperæmia and local œdema there may be proliferation, exfoliation, and degeneration of the epithelium.

Extravasated leucocytes may infiltrate to a moderate degree the stroma of the mucous membrane and appear upon its surface. Small, clear vesicles may form beneath the epithelium from the collection of serous exudate.

Croupous stomatitis is incited by local irritants, by local infection, or by the extension of the same form of inflammation from the pharynx; it frequently occurs with diphtheria and other infectious diseases.

Portions of the mucous membrane are swollen and congested, and covered with a false membrane. This false membrane is composed of a thickened layer of epithelium in the condition of coagulation necrosis, and of fibrin and pus in variable relative quantity. The stroma of the mucous membrane may be infiltrated with pus and fibrin, and portions of it may become necrotic.

Aphthous Stomatitis.—In this condition small whitish projecting patches surrounded by a zone of hyperæmia may form upon the mucous membrane. These consist of a more or less fibrinous exudate beneath the epithelium which may exfoliate, leaving small ulcers.

Ulcerative Stomatitis.—This form of stomatitis is apt to occur in ill nourished children or in young adults, in scurvy, or in mercurial poisoning. It usually begins at the margin of the gums of the lower jaw and extends to the cheeks and tongue. The affected parts are swollen and coated with a grayish, soft pellicle composed of bacteria and necrotic tissue. The gums may be destroyed around the teeth, and these may fall out. The surrounding soft parts are swollen, and there may be necrosis of the jaws.

In **noma** or **gangrenous stomatitis** similar changes may be associated with extensive gangrenous destruction of the cheeks. This most often occurs in young children in connection with measles, scarlatina, or typhoid fever. It has been claimed that a special micro-organism is the excitant of this disease, but this has not yet been proven.

Thrush. (**Soor; Parasitic Stomatitis.**)—In ill-nourished children or in adults suffering from chronic disease a fungus related to the yeasts—*oïdium albicans*—may grow among the epithelial cells of the mouth, forming white membranous patches. These may involve large areas of the mouth and pharynx and extend to the œsophagus or upper respiratory passages.

Phlegmonous Stomatitis.—Exudative inflammation of the mouth may result from infected wounds, in connection with erysipelas or suppurative or other infectious process near the mouth. Various pyogenic bacteria may be its excitants.

Chronic Stomatitis.—This may follow acute catarrhal or other inflammatory processes, and may be due to persistent irritation—for example, from the use of tobacco. Owing to hyperplasia of the epithelium and submucous tissue, white patches of varying extent may form on the tongue or elsewhere—*leucoplakia buccalis*. These through excessive increase in the epithelium may project in wart-like form from the surface—*ichthyosis*.

Tuberculous stomatitis commences with the formation of miliary tubercles or of larger tuberculous masses in the stroma of the mucous membrane. These masses soon degenerate, soften, and form ragged ulcers.

Syphilitic Stomatitis.—As a result of syphilis there may be produced

either the so-called mucous patches or gummy tumors. In the mucous patches the epithelial layer is at first thickened and the papillæ of the stroma are swollen and infiltrated with cells (see Fig. 157, p. 271 and Fig. 158, p. 272). This may be followed by desquamation of the epithelium and ulceration.

TUMORS.

Fibroma, lipoma, and enchondroma have been seen in a few cases in the lips. When in the mouth they usually grow from the bones. **Epulis** is a tumor of the jaw, fibrous, sarcomatous, or epitheliomatous.

Papillomata occur most frequently at the edges of the lips, but are also found on the gums, the floor of the mouth, and the cheeks. They are formed of hypertrophied papillæ, covered with thickened epidermis. They often ulcerate. **Angioma**, either congenital or developed after birth, occurs in the lips. **Adenoma** may be formed in the mucous membrane covering the mouth, lips, and soft palate. The tumors are rounded, usually small, sometimes as large as a hen's egg. They may be situated in the thickness of the mucous membrane, or project in a polypoid form.

Carcinoma is of frequent occurrence and is usually of the epitheliomatous form. Such tumors may form at any part of the mucous membrane of the mouth, but often begin in the edge of the lower lip as a result of persistent irritation, as in pipe smokers.

They may originate in an ulcerating papilloma, or as a flat, superficial growth from the deeper layers of the epithelium, or as deep nodules starting in the mucous glands. They are composed of large masses of epithelial cells, closely packed together, often forming nests, and arranged in anastomosing tubular masses. The stroma surrounding these masses is infiltrated with cells. In a few cases the infiltration of the stroma with small round cells may be very marked, so marked that the epithelial growth may be obscured. The new growth may increase in size, ulcerate, infiltrate the adjacent tissues, and may give rise to metastatic tumors.

Cysts.—Dermoid cysts and cysts of the embryonal branchial clefts may involve the mouth. Simple cysts may form in the jaws from aberrancies in the development of the teeth. For a description of the so-called adamantinoma, see p. 415. Complex congenital tumors of the gums are of rare occurrence, apparently arising in some congenital anomaly.¹

The Tongue.

Malformations.

Absence of the tongue may be associated with the extreme defects of development of the face already mentioned.

The anterior portion of the tongue may be absent while its base remains. The lower jaw is then small. The tongue may be cleft or lobulated.

It may be partly or completely adherent to the floor of the mouth. The frenulum

¹ For a study of such complex tumors of the mouth see *Schorr, Ziegler's Beitr.*, Bd. xxxix., p. 82, 1906.

may be abnormally short, or may extend to the tip of the tongue. In rare cases the sides of the tongue are adherent, or its upper surface may be adherent to the roof of the mouth.

HYPERTROPHY AND INFLAMMATION.

Macroglossia, or *hypertrophy* of the tongue, is almost always a congenital lesion, and is especially common in cretins. The tongue may be so large that it protrudes through the lips. The lips may also be similarly enlarged. There is hyperplasia of the fibrous and other tissues of the tongue, and in addition to this there may be a dilatation of the lymphatic vessels.

Inflammations of the tongue—*glossitis*—may be associated with similar changes in the mouth, or may occur by themselves. In catarrhal inflammation the accumulation of epithelium may give rise to the “furred tongue.” Most of the inflammatory processes above indicated as occurring in the mouth may affect the tongue also.

TUMORS.

Cysts.—The most common forms of cysts are the sacs beneath or partly in the substance of the tongue—*ranula*. They are formed by dilatation of the ducts of the mucous glands, or of the submaxillary and sublingual glands. **Amyloid tumors** of the tongue have been reported.¹

Lipoma and **fibroma** are rare. They form nodules in the substance of the tongue or project in a polypoid form. Composite tumors, composed largely of fat, are found on the tongue as a congenital condition.

Angioma.—Cavernous vascular tumors are found in the substance of the tongue and projecting from its surface.

Sarcoma is not common in this situation, but may occur both in children and in adults. **Carcinoma**, usually of the epitheliomatous type, may originate in the tongue or may extend to it from the adjacent tissues.

MICRO-ORGANISMS OF THE MOUTH.

Micro-organisms of various forms—bacteria, moulds, and yeasts—are always present in the mouth, often in enormous numbers. They are for the most part not of significance save for the putrefactive processes which they initiate and maintain in mouths not properly cleansed. On the other hand, *Staphylococcus* and *Streptococcus pyogenes* and the pneumococcus are of frequent occurrence in the mouths especially of those who live in towns and crowded dwellings, and, while usually harmless, they may under favorable conditions become excitants of serious disease.

The tubercle bacillus may be present in the mouth as well as in the nose of those who care for uncleanly consumptives.

The fungus of aphthæ (soor), and leptothrix, which under usual conditions are not harmful, may incite serious local disease.

¹ See *Schmidt*, *Virch. Arch.*, Bd. cxliii., p. 369, 1896, bibliography of amyloid tumors in general.

The so-called Mycosis pharyngis is apparently due to the growth in susceptible persons of a form of leptothrix not yet thoroughly studied, on account of the technical difficulties in the way of its artificial cultivation.¹

The Pharynx.

Malformations.

BRANCHIAL FISTULÆ AND CYSTS.—When, as not infrequently occurs, the embryonal gill clefts do not properly close, *fistulæ* may remain.² These may in rare cases be complete, so that an opening exists from the pharynx, larynx, or trachea to the side of the neck (see Fig. 175, p. 322). More frequently, however, these fistulæ are incomplete and shallow, and open either inward into one of the above-named organs or

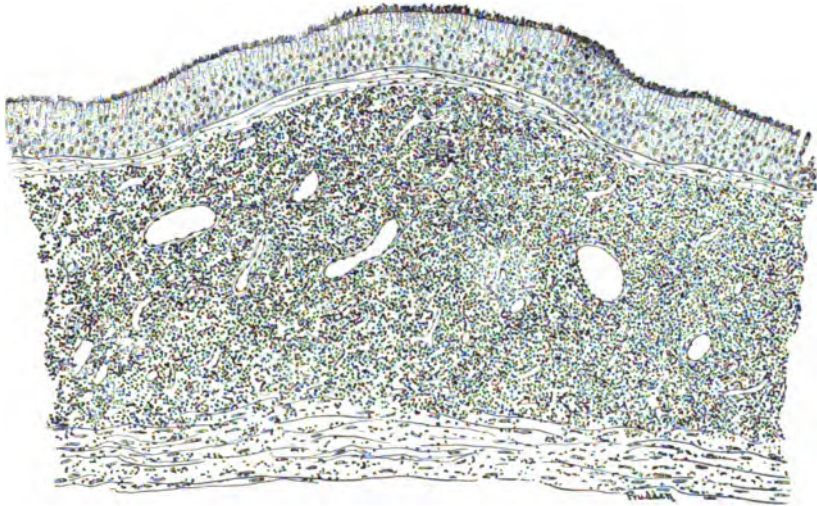

FIG. 410.—SECTION OF THE WALL OF A BRANCHIAL CYST OF THE NECK. Formed from the imperfect closure of an embryonal gill cleft. The cyst is lined with ciliated epithelium, and the wall is largely formed of diffuse lymphoid tissue.

outward on to the neck. Small portions of the gill clefts may persist without external openings, and from these subcutaneous *cysts* of the neck are often developed. Or a portion of the cleft may be cut off, forming a cyst, while the fistula persists with its external opening.

The walls of these fistulæ and cysts may be covered with mucous membrane having cylindrical or flattened or ciliated surface cells. Or, when formed from the outer clefts, they may be lined with skin.

Not infrequently the walls of these cysts and fistulæ are embedded in lymphatic tissue, which may be diffuse or gathered in nodular form (see Figs. 410 and 411).³

DIVERTICULA of the pharynx have been observed.

¹ For a *résumé* with bibliography of the bacteria found in the mouth as well as in other parts of the body under normal and pathological conditions see Macé, "Bacteriologie," 1901, p. 1140. See also Madzsar, *Cent. f. Bakt.*, I. Abt. Ref. p. 489, 1902. For bacteria in the mouths of nurslings see Lewkowicz, *Arch. de méd. exp.*, t. xiii., 1901, p. 633. See also for bacteria most frequent in the mouths of healthy children Oshima, *Arch. f. Kinderheilkunde*, Bd. xlv., p. 21, 1906.

² For details of the formation of fissures in the cervical region from incomplete closure of the branchial clefts see Thoma, "Text-book of General Pathology," Eng. transl., 1896, p. 201.

³ For bibliography of branchial cysts and fistulæ see Coptin, *Proc. Path. Soc. of Phila.*, N.S., vol. iv., p. 109, 1901.

INFLAMMATION. (Pharyngitis, Angina.)

Catarrhal pharyngitis is usually associated with the same forms of inflammation in the mouth and has similar characters.

In catarrhal inflammation involving the tonsils and those portions of the pharynx richly supplied with the so-called submucous adenoid—lymphoid—tissue, leucocytes may in considerable numbers pass through the thin epithelial layer and mingle with the exudate upon the exposed surface.

In chronic inflammation of the pharynx there may be a large and permanent hyperplasia of the lymphoid tissue, with more or less dense




FIG. 411.—SECTION OF THE WALL OF A BRANCHIAL CYST OF THE NECK.

This cyst, like that shown in Fig. 410, has much lymphoid tissue in the wall, but nodular in character; while the epithelial lining is squamous in type.

fibrous tissue, leading to diffuse or circumscribed nodular or pedunculated masses of vascular new tissue in the vault or elsewhere in the pharynx, called “adenoids.”¹

Phlegmonous pharyngitis may occur with inflammations of the mucous membrane, with caries of the cervical vertebræ, with inflammation of the cervical and parotid glands, with periostitis of the cranial bones, or it may occur independently. It may result in swelling and œdema, in induration, or in suppuration. It is most important when it affects the posterior wall of the pharynx and forms retro-pharyngeal abscesses. Such abscesses may cause death by suffocation.

Diphtheritic pharyngitis is that form of pseudo-membranous or croupous inflammation of which the *Bacillus diphtheriæ* is the excitant. The general characters of the diphtheritic infection have been considered in an earlier part of this book. The local process, often

¹ See p. 650. For a study of the uvula in various abnormal conditions see *Hoën*, *Jour. Exp. Med.*, vol. iii., p. 549, 1898.

affecting the fauces, pharynx, and tonsils, may involve the mouth as well as the larynx and trachea. (For details of the local lesion see p. 282.)

Tonsillitis.—The tonsils may share in the inflammatory processes of the pharynx or be independently affected. The structural characters of the tonsils render them liable to infection and involve certain peculiarities in the lesions.¹

In FOLLICULAR TONSILLITIS the swollen organ shows upon section an increase in the number of the lymphoid cells of the nodules and a hyperplasia of the endothelium of the reticulum. These new-formed and often exfoliated endothelial cells are similar to those found in the lymph-nodes in general in the presence of bacterial or other toxic substances. There may be an increase in the cells of the stroma of the tonsil. The epithelial cells of the surface and the crypts may increase in number and exfoliate. Epithelial cells and leucocytes and other forms of exudate may gather in the crypts or over the surface of the tonsil, forming white plugs or a whitish pellicle.²

IN EXUDATIVE TONSILLITIS (suppurative or phlegmonous tonsillitis, quinsy) there are, in addition to hyperplasia and catarrhal inflammation, œdematous swelling and suppuration often leading to abscess.

Acute inflammation of the pharynx and tonsils is usually infectious in character, and may be due to various forms of pyogenic and other organisms. Thus in tonsillitis and other forms of acute angina, the most common micro-organisms concerned are Streptococcus and Staphylococcus pyogenes, the pneumococcus, and the Micrococcus tetragenus. Many other forms have been isolated.³

IN CHRONIC TONSILLITIS (the so-called hypertrophy of the tonsils) there is hyperplasia of the lymph-nodules with increase in the fibrous stroma. The mouths of the crypts may be occluded and distended with exfoliated cells and cell detritus; these may become calcified.⁴

Tuberculous Pharyngitis.—Tuberculous inflammation of the pharynx may be primary or secondary to tuberculous lesions elsewhere; ulcers may form and the tonsils may be involved.

The hyperplasiæ of the pharyngeal mucosa in children, commonly called "adenoids," have been found in a considerable number of cases to be tuberculous. Whether in these instances the lesion is tuberculous in origin or whether the hyperplastic tissue affords a portal of entry and local vulnerability to infection by the tubercle bacillus is not yet clear.⁵

¹ Consult Dobrowolski, "Lymph Nodules of the Larynx, Œsophagus, etc.," Ziegler's Beiträge z. path. Anat., Bd. xvi., p. 43, 1894.

² See Hodenpyl, "Anatomy and Physiology of the Fauical Tonsils," Am. Jour. Med. Sciences, vol. ci., p. 257, 1891; also Packard, Phila. Med. Jour., vol. v., 1900, pp. 914, 957. For a study of the lymph drainage of the faucial tonsils see Wood, Am. Jour. Med. Sci., vol. cxxx., p. 216, 1905. For a study of absorption in the tonsil see Wright, N. Y. Med. Jour., vol. lxxxiii., p. 17, 1906.

³ Consult for bacteriology of angina Lartigau, Phila. Med. Jour., vol. iii., p. 899, 1899, bibliography; for a study of acute tonsillitis see Goodale, Jour. Boston Soc. Med. Sciences, vol. iii., p. 63, 1899. For a study of actinomyces-like structures in the tonsillar crypts see Gappisch, Verh. Deutsch. path. Ges., Bd. ix., 1905, p. 130; also Wright, Am. Jour. Med. Sci., vol. cxviii., p. 74, 1904.

⁴ For résumé of tonsillar calculi with bibliography see Robertson, British Med. Jour., 1899, vol. i., p. 14. For a study of bone in tonsils see Lubarsch, Virch. Arch., Bd. clxxvii, p. 371, 1904; also Ruckert, *ibid.*, p. 387.

⁵ For a study of hyperplasia of the pharyngeal lymphoid tissue (adenoids) with reference to

The possibility should be borne in mind that from tuberculous "adenoids" tubercle bacilli may pass through the lymph-channels to the bronchial lymph-nodes, and that the pharynx may thus be a more important portal of entry in tuberculosis than has been hitherto recognized.

TUMORS.

Fibromata grow from the periosteum of the bones at the base of the skull, and project into the cavity of the pharynx and posterior nares in the form of large polypoid tumors. Soft polypoid tumors, consisting



FIG. 412.—"ADENOID" POLYP OF PHARYNX.

largely of loose succulent connective tissue and lymphatic tissue, and often called "**adenoid polyps**" (see Fig. 412), are of frequent occurrence. They are usually to be regarded rather as hyperplasiæ than true tumors. Hairy polyps of the pharynx have been described by Arnold¹ and others.

primary tuberculosis of the pharyngeal tonsil see *Lartigau and Nicoll*, *Am. Jour. Med. Sc.*, vol. cxxiii., 1902, p. 1031, bibliography.

Also for a study of the tonsils as portals of entry of tubercle bacilli see r. *Scheibner*, *Ziegler's Beitr.*, Bd. xxvi., p. 511, 1899; also *Friedmann*, *ibid.*, Bd. xxviii., p. 66, 1900. Also bibliography in *Wood*, *Bull. Univ. Penna.*, vol. xvi., 1903, p. 368. See also reference to *Grober*, p. 640. For relation of cervical and bronchial lymph-nodes in tuberculous infection see *Beitzke*, *Virch. Arch.*, Bd. clxxxiv., p. 1, 1906.

For general bibliography on the tonsils see *Ullman*, *Medical News*, January 26th, 1901, p. 137.

¹ *Arnold*, *Virchow's Arch.*, Bd. cxl., p. 176, 1888, bibl.

Sarcoma, carcinoma,¹ and various tumors of mixed type are of frequent occurrence in the pharynx.²

The Œsophagus.

Malformations.

Malformations of the œsophagus are rare. The œsophagus may be entirely absent or its lower portion may be present and joined to the pharynx by a solid cord; or the pharynx, or the lower part of the œsophagus, may be continuous with the trachea; or the entire œsophagus may be represented by a solid cord. Dilatations of the œsophagus and division of the middle portion of the œsophagus into two branches have been observed.³ The mucosa may be folded across the lumen partially occluding it.

PERFORATION AND RUPTURE.

Foreign bodies in the œsophagus may, as already mentioned, perforate its wall. Perforation of the œsophagus from without may be produced by inflamed bronchial glands, by the extension of cavities and gangrene of the lungs, by abscesses in the mediastinum, by abscesses accompanying caries of the vertebræ, and by aneurisms of the aorta. Rupture of the wall of the œsophagus by violent coughing and vomiting has been described, but it seems improbable that this should occur without some previous local lesion.⁴ A few cases of perforating ulcer of the œsophagus have been recorded.

HÆMORRHAGE.

Aside from injuries, ulceration, etc., hæmorrhage may take place from the lower veins of the œsophagus, which, in obstructed circulation, especially in atrophic cirrhosis, may be much dilated—*œsophageal varices*.⁵

DILATATION.

Simple Cylindrical Dilatations of the œsophagus are usually the result of long-continued stenosis of the œsophagus or of the cardiac end of the stomach, although not nearly all the stenoses are followed by dilatation. These dilatations are formed at first immediately above the stenosis and then extend upward. Dilatation may occur below the stricture. Only in rare cases does the dilatation involve the whole length of the tube. The entire wall of the dilated portion of the œsophagus is thickened, and there may be polypoid growths from the mucous membrane.

In rare cases there is cylindrical dilatation of part or of the whole of

¹ For a study of carcinoma originating in the branchial cleft see *Powers*, *Annals of Surgery*, February, 1898.

² For literature of malignant disease of the tonsils consult *Newman*, *Am. Jour. Med. Sciences*, vol. ciii., p. 487, 1892; also *Honsell*, *Beitr. zur klin. Chirurgie*, Bd. xiv., 1895.

³ For a study of aberrant islets of gastric mucosa in the upper end of the œsophagus see *Schaffer*, *Virch. Arch.*, Bd. clxxvii., p. 181, 1904.

⁴ For a study of rupture of œsophagus see *McWeency*, *Lancet*, 1900, vol. ii., p. 158, bibl.

⁵ See *Preble*, *Am. Jour. Med. Sci.*, vol. cxix., p. 263, 1900.

the œsophagus without a stenosis or any discoverable cause. In these cases the dilatation is usually greatest near the middle of the œsophagus and diminishes upward and downward, so that the œsophagus has a fusiform shape. The dilatation may reach a very considerable degree, the walls of the œsophagus are thickened, its mucous membrane may be covered with papillary outgrowths or ulcerated.

The Sacculated Dilatations of the œsophagus are of two kinds: those due to pressure, and those due to traction.

The dilatations due to pressure are situated in the posterior wall of the pharynx, just at its junction with the œsophagus. The smaller sacs are from the size of a pea to that of a hazelnut; the larger sacs may reach a large size and hang down between the œsophagus and the vertebral column, the opening into the œsophagus remaining comparatively small. It is supposed that a limited area of the wall of the œsophagus loses its power of resistance against the pressure exercised upon it in each act of swallowing; it then is forced outward by the pressure, and so there is formed first a protrusion and then a sac. When a sac is formed the food enters it, accumulates there, and the sac becomes larger and larger.

The dilatations due to traction are situated on the anterior wall of the œsophagus, at a point nearly corresponding to the bifurcation of the trachea. They are of funnel shape, with the small end outward. Their length varies from two to twelve millimetres; the width of the opening into the œsophagus is from six to eight millimetres.

These dilatations are due to inflammation of the parts adjoining the œsophagus, especially of the bronchial nodes, followed by adhesions to some part of the anterior wall of the œsophagus. These adhesions then contract and draw the wall of the œsophagus outward, and in this way the dilatations are formed.

At a later time these sacs may perforate into the bronchi, the lungs, the pleural cavity, the pericardium, the aorta, or pulmonary artery.¹

STENOSIS.

Congenital Stenosis.—Besides the defects of development of the œsophagus which are incompatible with life, there may be a congenital stenosis of some part of it which causes difficulty in swallowing, but yet does not destroy life.

Compression Stenosis is not uncommon. Tumors of the neck and mediastinum, and aneurisms of the aorta are the usual causes. Stenosis from vertebral echondroses has been reported.²

Obstruction Stenosis.—Foreign bodies may be lodged in the œsophagus. Tumors may hang down from the pharynx into the œsophagus, or may be situated in the wall of the œsophagus. Inflammation of the

¹ For bibliography of œsophageal diverticula see *Brosch*, *Deutsch. Arch. f. klin. Med.*, Bd. lxxvii., p. 44, 1900; also *Starrk*, *Arch. f. Verdkr.*, Bd. vii., 1901, p. 1. For later cases see *Paff*, *Trans. Assn. Am. Phys.*, vol. xvi., 1901, p. 656.

² See *Zahn*, *Munch. med. Wochenschr.*, May 8th, 1906.

œsophagus, due to the ingestion of irritating poisons, may induce cicatricial stenosis. A few cases of stenosis due to syphilitic inflammation have been reported.

INFLAMMATION. (Œsophagitis.)

Catarrhal Œsophagitis may be either acute or chronic. The chronic form may lead to ulceration, or relaxation and dilatation of the walls, or to hypertrophy of the muscular coat. Leukoplakia is not uncommon.

Pseudo-membranous Œsophagitis may occur with a similar process in the pharynx, with the exanthemata and other severe diseases, or under other conditions. It may be diphtheritic in character or due to other excitants than the diphtheria bacillus.

Other Forms of Inflammation of the Œsophagus.—Foreign bodies which are swallowed and become fixed in the œsophagus may incite inflammation of the mucous membrane and of the adjoining soft parts. Abscesses may form around the œsophagus, or destroy the wall of the canal, and the foreign body may find its way into the trachea, aorta, or pericardium.

Inflammation of the submucous tissue of the œsophagus, apart from the cases just mentioned, is not common. It may result in abscess or the formation of fibrous tissue, causing stenosis.

Irritating and caustic acids and alkalies may destroy larger or smaller portions of the mucous membrane. The necrosed portions are of a black or whitish color, surrounded by a zone of intense congestion. If the patient recover, the patches of membrane which have been destroyed slough and fall off, leaving a surface covered by granulation tissue. As this assumes cicatricial characters and contracts, serious stenosis of the œsophagus may be produced.

Tuberculous Œsophagitis may occur in generalized miliary tuberculosis or by local infection from tuberculous sputa, either with or without obvious predisposing local lesion, or through an extension of a tuberculous process from adjacent structures. Ulceration is apt to occur.¹

Syphilitic Œsophagitis.—There may be gummata which encroach upon the lumen, or ulceration followed by cicatrices may lead to stenosis.

TUMORS.

Small Papillomata may occur singly or in considerable numbers throughout the entire length of the œsophagus. Large papillary tumors are more rare. Small submucous **fibromata** and **lipomata**, **angiomata**, and **leiomyomata** of considerable size may occur in the œsophagus. **Sarcomata** are rare.² **Adenomata** and **myxomata** have been observed.

Carcinoma may originate at any part of the wall of the pharynx and œsophagus. The tumor may encircle the tube; it may remain as a flat

¹ For bibliography of tuberculous œsophagitis see *Flechner*, Johns Hopkins Hosp. Bull., vol. iv., p. 4, 1893; and also *Cone*, *ibid.*, vol. viii., p. 229, 1897.

² *Livingood*, Johns Hopkins Hosp. Bull., vol. ix., p. 159, 1898, bibl.

infiltration (Fig. 413), or project inward in large, fungous masses. In either case it is prone to ulceration. The growth may extend up and down the œsophagus, and even involve the pharynx or stomach. The ulcerative process may extend outward so as to lead to perforation into the air passages, the lungs, pleuræ, pericardium, and large blood-vessels. The new growth may extend outward and infiltrate the surrounding soft parts, so that the œsophagus is surrounded by large, solid, cancerous masses. Metastatic tumors are also sometimes formed.¹

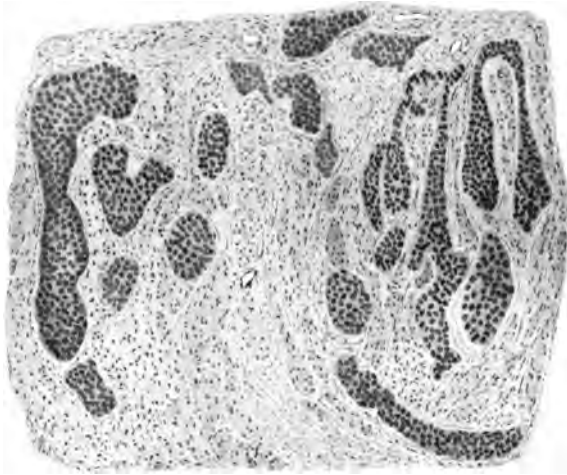


FIG. 413.—INFILTRATING CARCINOMA OF THE ŒSOPHAGUS.

¹ **Cysts.**—Small retention cysts of the follicles of the mucous membrane are sometimes found. Larger cysts of the œsophagus lined with ciliated epithelium have been described.²

The Stomach.

Malformations.

Malformations of the stomach are not common. The organ may be entirely wanting in acephalous fœtuses. It may be of various degrees of smallness, sometimes no larger than the duodenum. It may be divided into two halves by a deep constriction in the middle. It may be vertically placed. Diverticula are noted. The stomach may be outside of the abdominal cavity from a hernial protrusion through the diaphragm or at some point in the abdominal wall. It is found on the right side, instead of the left, when the other viscera are transposed, and the position of the cardiac and pyloric orifices is correspondingly inverted.

Congenital stenosis of the pylorus in infants is of occasional occurrence. It is com-

¹ For a résumé of tumors of the œsophagus see *Coplin*, *Am. Med.*, vol. vii., 1904, p. 773.

² For recent bibliography of lesions of œsophagus see *Thorel*, *Lubarsch* and *Ostertag's* "Ergebnisse, Jahrg. v. for 1898, p. 128.

monly due to fibrous hyperplasia of the submucosa, sometimes involving the internal muscular layers.¹

Cadaveric Changes.

The mucous membrane of the stomach is liable to undergo considerable alterations soon after death, owing to changes in the distribution and composition of the blood and to the action of the digestive fluids. The blood is apt to collect in the small veins, especially at the fundus, while, by diffusion of the coloring matter, red or brown or black streaks and patches form in the mucous membrane.

Those portions of the mucosa on which the food and digestive fluids collect, usually at the fundus and on the posterior aspect of the stomach, frequently appear gray and turbid, and are soft and easily rubbed off. The epithelium in these regions is unusually granular or disintegrated, and is often detached. Sometimes this post-mortem softening involves the entire thickness of the stomach wall, which is converted into a gray or yellow or brown gelatinous pulp. Thus large or small post-mortem perforations may occur.

INJURIES.

Perforating wounds of the stomach usually give rise to a fatal peritonitis. It is possible, however, for the wound to heal, or a gastric fistula may be formed.

Rupture of the stomach may be produced by severe blows or falls.

HÆMORRHAGE. (Hæmatemesis.)

Small extravasations of blood in the wall of the stomach are frequently found in persons who have died from one of the infectious diseases.

Hæmorrhage into the cavity of the stomach may occur in a variety of ways. It may take place from injuries or poisons; from ulcers or carcinoma; from rupture of small aneurisms of the stomach, or from the rupture into the stomach of aneurisms elsewhere. It may occur in infectious diseases, especially in yellow fever, or in diseases of the blood. It may be associated with passive congestion of the stomach in hepatic cirrhosis of the liver, obstruction of the portal vein, chronic disease of the heart and lung; with an enlarged spleen, and in chronic gastritis. In the new-born and young infants hæmorrhage into the stomach not infrequently occurs without apparent lesions which would account for it; or there may be ulcers of the mucous membranes, or cardiac disturbances, or infection. While the source of hæmorrhage into the stomach is often evident, in many cases none can be discovered. Considerable bleeding can evidently take place by diapedesis in congested vessels.

Some cases of chronic gastritis are characterized by general bleeding from the mucous membranes of the stomach.²

¹ See *Meltzer*, N. Y. Med. Record, vol. liv., p. 253, 1898, bibl.; also *Rolleston and Crofton Atkins*, Brit. Med. Jour., 1900, vol. ii., p. 1768; also *Wachenheim*, Am. Jour. Med. Sci., vol. cxxix., p. 636, 1905.

² For a study of occult hæmorrhage in the gastro-intestinal canal see *Jaworski and Korolewicz* Wiener klin. Wochenschr., p. 1129, 1906.

ATROPHY AND DEGENERATION.

Atrophy of the stomach occurs in a variety of cachectic conditions, in chronic inflammation, and in stenosis of the cardiac orifice.

Albuminous degeneration of the epithelium may occur in infectious diseases and in inflammation of the stomach.

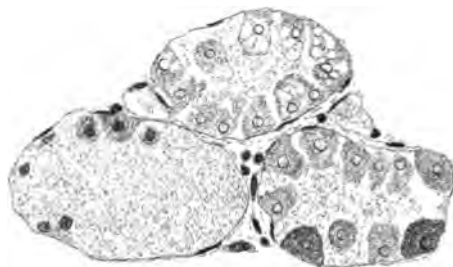


FIG. 414.—FATTY DEGENERATION OF THE EPITHELIUM OF THE GASTRIC TUBULES IN PHOSPHORUS POISONING.

Fatty degeneration is often associated with arsenic and phosphorus poisoning (Fig. 414).

Amyloid degeneration of the small vessels is associated with a similar process in other parts of the body.

INFLAMMATION. (Gastritis.)

Acute Catarrhal Gastritis is usually due to the ingestion of irritating decomposing or infectious substances and may accompany general infectious diseases.

After death the mucous membrane may be congested and swollen, or the congestion may have disappeared. The mucous membrane is coated with an increased amount of mucus, especially at the pyloric end of the stomach.

The structural changes in the mucous membrane consist chiefly in swelling and albuminous degeneration, and sometimes exfoliation of the epithelium with an increase in the production of mucus by the cylindrical cells (Fig. 415), while the intertubular tissue and the submucosa may be œdematous and contain a few emigrated leucocytes. The solitary lymph-nodes may be enlarged from hyperplasia, and hæmorrhagic erosions may be present.

Chronic Gastritis.—This, with the continuance of the exciting conditions, may follow the acute form. It is often associated with the persistent use of alcohol, with ulcers and carcinoma, with venous congestion from heart lesions, cirrhosis of the liver, obstruction of the portal vein or ascending vena cava, or chronic diffuse nephritis. These are doubtless predisposing conditions rather than actual excitants of the disease.

The stomach may be normal in size or small or dilated. Its inner

surface is usually covered with tenacious mucus. The mucous membrane may be congested with minute hæmorrhages or erosions, or it may

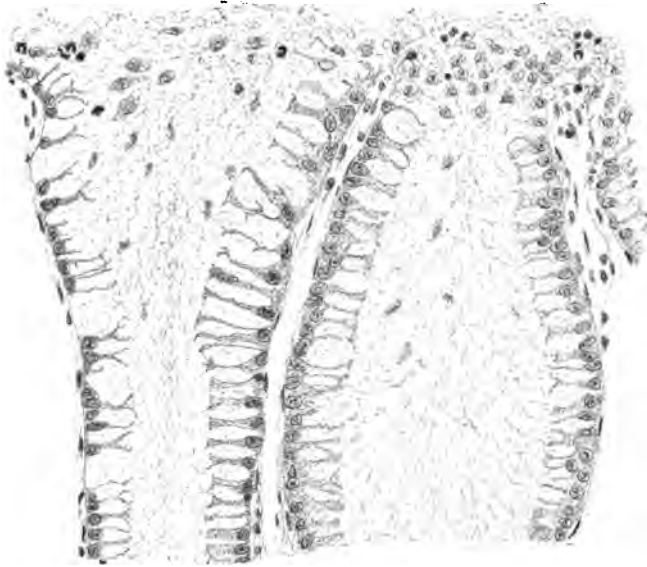


FIG. 415.—ACUTE CATARRHAL GASTRITIS.

Showing the open ends of two gastric tubules. There is a considerable formation of mucus by the epithelial cells, many of which have the so-called "beaker" form. There is exfoliation of epithelium which, with mucus and a few leucocytes and red blood cells, covers the surface of the mucous membrane.

be pale and gray or pigmented from former hæmorrhages. It may be thickened or thinner than normal. Often, owing to irregular thickening, it projects in places in the form of minute granules, or it is irregularly

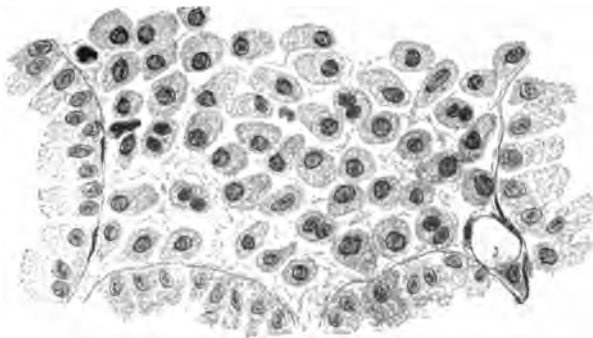


FIG. 416.—CHRONIC GASTRITIS.

Showing a small portion of the new-formed tissue between the gastric tubules. There are many large polyhedral cells in the new tissue.

roughened—*état mamelonné*—or there may be distinct polypoid out-growths. These alterations are usually most marked in the pyloric

region. Microscopical examination shows alterations varying in different parts of the organ and in different stages of the disease. The surface epithelium may be degenerated and exfoliated. The detached epithelium with leucocytes may be mingled with the mucus covering the surface. The gastric glands may be variously altered. They may be dilated, or elongated and tortuous, or hyperplastic¹ or atrophied; their epithelium may be flattened, degenerated, or detached. The interstitial tissue and the submucosa may be infiltrated with small spheroidal cells or new-formed larger polyhedral cells (Fig. 416), and new fibrous tissue may form (Fig. 417), thus often greatly thickening the mucous membrane and causing atrophy of the glands. The lymph-nodules at the base of the glands may be enlarged from hyperplasia. On the other hand, the

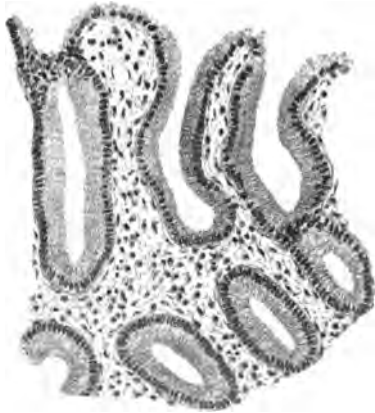


FIG. 417.—CHRONIC GASTRITIS.

Showing the new-formed fibrous tissue between the gastric tubules.

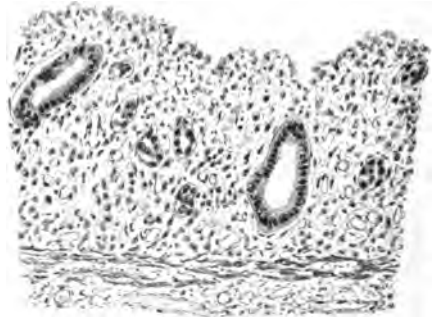


FIG. 418.—CHRONIC GASTRITIS.

Showing atrophy of the mucous membrane with much new-formed fibrous tissue.

mucous membrane, as contraction takes place in the new-formed interstitial tissue, may undergo great atrophy (Fig. 418), so that it is pale, thin, often gray in color, with more or less pigmentation.

The formation of new fibrous tissue may later involve the muscularis also, leading to various distortions of the stomach.

Croupous Gastritis (Membranous or Diphtheritic Gastritis).—This form of gastric inflammation, most common in children, may be associated with diphtheria or with other infectious diseases, but may occur independently. In adults it is usually secondary to typhus fever, pneumonia, pyæmia, typhoid fever, the exanthemata, and other infections, and may follow the ingestion of irritant poisons. The excitants are thus of the most varied kinds, as is the case in pseudo-membranous inflammation elsewhere in the body. The false membrane may be in small patches or line a considerable portion of the stomach.

Exudative Gastritis (Suppurative or Phlegmonous Gastritis).—This

¹ See Cone, "Welch Anniversary Contributions to the Science of Medicine, p. 877, 1900, bibl.

process is characterized by the formation of purulent and other exudate in the connective tissue of the mucosa and submucosa. The exudate may be diffuse or localized in the form of abscess. As an independent affection it is rare. It is more frequent in connection with puerperal fever and other infectious diseases; it has been ascribed to injury.

The accumulation of exudate may be slight, the interglandular and submucous tissue being œdematous with few pus cells. The mucous membrane may under these conditions remain intact or show slight catarrhal lesions. When this relatively slight accumulation of exudate occurs in the pyloric region it may apparently occasion temporary stenosis. On the other hand, a considerable or large amount of exudate may form, and the process may involve diffusely a large part of the wall of the stomach; or the process may be circumscribed and abscesses may form. The suppurative process may extend to the mucous membrane, or to the serosa, and thus perforations may occur and the excitement of peritonitis. Little is known of the direct excitants of phlegmonous gastritis.¹ *Streptococcus pyogenes* has been found in the exudate.²

Toxic Gastritis.—The mineral acids, the caustic alkalies, arsenic, corrosive sublimate, and the metallic salts, phosphorus, camphor, and other irritating materials, induce different lesions of the stomach, according to their quantity, their strength, and the length of time which has elapsed before death.

In large quantities they destroy and convert into a soft, blackened mass both the mucous membrane and the other coats, so that perforation may take place. In smaller quantities they produce black or white sloughs of the mucous membrane, surrounded by a zone of intense congestion. If death does not soon ensue, the ulcerative and cicatricial processes which follow such sloughs may contract and deform the stomach in various ways.

If the poisons are of less strength they may induce a diffuse congestion of the mucous membrane, with catarrhal or croupous exudation on its surface and serous infiltration of the submucous coat (see chapter on Poisons).

Tuberculous Gastritis of the stomach is rare and is usually secondary to tuberculous lesions elsewhere. There may be miliary tubercles or small or large, single or multiple ulcers involving especially the mucosa and submucosa.³

Syphilitic Inflammation of the stomach with ulceration has been occasionally observed.⁴

¹ Reference to the bibliography of micro-organisms of the normal stomach may be found in an article by *Weiss* on "Bacteria in the Stomach of the Cat," *Jour. of Applied Microscopy*, vol. iii., p. 827, 1900; also *Coyon*, "Flore microbienne de l'estomac," Thèse de Paris, 1900, bibliography. For bibl. of phlegmonous gastritis see *Leith*, *Edinburgh Hospital Reports*, vol. iv., p. 51, 1896. For a later study see *Schnarrwyler*, *Arch. f. Verdkr.*, Bd. xii., p. 116, 1906, bibl.

² See *Kinnicutt*, *Trans. Assn. Am. Phys.*, vol. xv., p. 127, 1900, bibl. For a study of lesions of the stomach as portals of entry of bacteria see *James*, *Trans. Assn. Am. Phys.*, vol. xvi., p. 72, 1901.

³ Consult for bibliography of tuberculosis of stomach, *Blumer*, *Albany Medical Annals*, March, 1898.

⁴ Consult for bibliography *Flexner*, *American Journal of Medical Sciences*, vol. cxvi., p. 424, 1898.

ULCERS OF THE STOMACH.

Chronic Perforating Ulcer.—This form of ulcer is often seen; according to Brinton, in five per cent. of persons dying from all causes. It occurs in females nearly twice as frequently as in males. As regards the age, Brinton concludes that the liability of an individual to become the subject of gastric ulcer gradually rises, from what is nearly a zero at the age of ten, to a high rate, which it maintains through the period of middle life; at the end of which period it again ascends, to reach its maximum at the extreme age of ninety.

The analysis of 793 hospital cases by Welch¹ shows that the ulcers were on the lesser curvature in 288, in the posterior wall in 235, at the pylorus in 95, on the anterior wall in 69, at the cardia in 50, at the fundus in 29, on the greater curvature in 27.

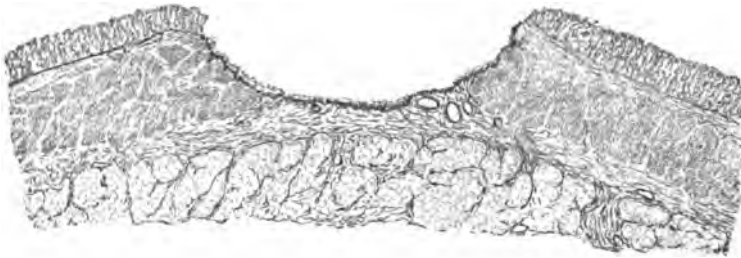


FIG. 419.—CHRONIC ULCER OF THE STOMACH.
Showing a section through the stomach wall at the central part of the round ulcer

As regards the number of ulcers, two or more are present in about twenty-one per cent.; there may be two, three, four, or even five ulcers. In cases of multiple ulcers these are often developed successively.

In size the ulcers vary from one-quarter of an inch to five or six inches. They are usually of circular shape, sometimes oval; sometimes two or more are fused together.

The ulceration is largest in the mucous membrane (Fig. 419). It may remain confined to this, or extend outward and involve the connective tissue, muscular and peritoneal coats, its diameter becoming smaller as it advances. The ulcer looks like a clean hole punched out of the wall of the stomach (Fig. 420). Its floor may show no active inflammatory changes. Its edges may be in the same condition, or they may be thickened by the growth of connective tissue and cell. The rest of the mucous membrane of the stomach is apt to be in a condition of chronic catarrhal inflammation.

The ulcer may perforate directly through the wall of the stomach, and the contents of the latter are discharged into the peritoneal cavity; or

¹ Welch, Pepper's "System of Practical Medicine," vol. ii., p. 504, 1885. Many important data are to be found in this excellent article.

adhesions are formed between the wall of the stomach and the neighboring viscera, so that the bottom of the ulcer is closed; or if the liver, the intestines, or the abdominal wall become adherent, these may be invaded by the ulcerative process, and cavities or fistulæ are formed communicating with the stomach; or, if the adhesions are incomplete, a local peritonitis and collections of pus may be developed. Perforation may take place into the colon or duodenum, or into the pericardium or pleura.

During the progress of the ulcer there may be repeated small hæmorrhages from the erosion of small blood-vessels, or large hæmorrhages from the erosion of larger arteries.



FIG. 420.—CHRONIC PERFORATING ULCER OF THE STOMACH.

In many cases these ulcers cicatrize, and such a cicatrization may produce various deformities of the stomach.

The origin of such ulcers is often obscure. It seems probable that the nutrition of a circumscribed part of the wall of the stomach is interfered with, and that this portion is then destroyed by the action of the gastric juice. But we are in most cases still ignorant of the way in which the obliteration of the arteries is effected. It has, indeed, been demonstrated in animals that an artificial embolism of the branches of the gastric arteries may lead to ulcers of the stomach; and in the human stomach we occasionally find cases of embolism of the branches of the gastric artery and ulcers. But the clinical history of most cases of ulcer of the stomach does not correspond with such a mode of origin. A chronic obliterating endocarditis would seem to be a more probable cause. The possibility of a bacterial origin in some cases should not be overlooked.

Follicular Ulcers, similar to those in the small intestine, are of occasional occurrence in the stomach. They are formed by the degenerative changes and necrosis in the solitary lymph-nodules of the stomach.

For **Tuberculous Ulcers**, see above.

Hæmorrhagic Erosions occur as rounded spots or narrow streaks, formed by a loss of substance of the mucous membrane. The mucous membrane at these points may be congested, soft, and covered by small blood-clots. The destruction of the mucous membrane is usually superficial, but may involve its entire thickness. The internal surface of the stomach may be studded with these erosions. They give rise to repeated hæmorrhages, and are accompanied by catarrhal inflammation of the rest of the mucous membrane.

They occur at all periods of life, even in infants. Their usual seat is the pyloric portion of the stomach. They may occur independently of other obvious lesions, but are most frequent in connection with chronic congestion of the mucosa, chronic gastritis, in infectious diseases, and intoxications.

DILATATION AND DISPLACEMENT.

Very considerable degrees of dilatation of the stomach are found at autopsies, without stenosis of the pylorus or other mechanical cause to account for them. It is usually difficult to determine how long these dilatations have existed and their influence in the illness or death.

Acute dilatation of the stomach, with vomiting of very large quantities of thin fluid, has been observed in a few cases, the dilatation being developed suddenly and without discoverable cause.

Of the mechanical factors which lead to dilatation of the stomach a stenosis of the pylorus is the most common. Such a stenosis may be effected by a tumor, by chronic inflammation and thickening, and by the cicatrization of ulcers. Less frequently obstructions of the small and large intestines act in the same way. Some forms of chronic gastritis are attended with dilatation of the stomach without stenosis. In rare cases circumscribed, sacculated dilatations are produced by the presence of foreign bodies—portions of wood, metal, etc.

The stomach may be variously displaced by pressure from without.

TUMORS.

Papillomata.—It has already been mentioned that in some cases of chronic gastritis there are small, polypoid hypertrophies of the mucous membrane. Besides these we find polypoid tumors which may reach a considerable size. They are composed of a connective-tissue stroma arranged in tufts covered with cylindrical epithelium. In some cases there are also tubules lined with cylindrical epithelium, so that the tumor has partly the structure of an adenoma (Fig. 421). **Fibromata** of small size are sometimes found in the connective-tissue coat. **Lipomata** are formed in the submucous connective tissue in the shape of rounded or polypoid tumors. They usually project inward, but sometimes outward beneath the peritoneum. They may also appear in the form of numerous yellow nodules beneath the mucous membrane.

Myomata occur in the form of rounded tumors which originate in the

muscular coat, but may gradually separate themselves from it and project inward or outward. The submucous myomata are at first small tumors lying loosely attached in the submucous tissue. As they grow larger they push the mucous membrane inward and take the shape of polypoid tumors. Small multiple **angiomata** may be found in the stomach in connection with similar tumors in the submucosa throughout the gastro-intestinal canal.¹ **Lymphomata** in the wall of the stomach are seen in some cases of leukæmia.

Sarcomata of the stomach are rare. In some of the tumors of the wall of the stomach, which are ordinarily called cancerous, the structure is not well defined, and it is possible that some of them are sarcomata. Sarcomata of the stomach may be round-celled or spindle-celled, and mixed forms occur—myxo-sarcoma, angio-sarcoma, etc.²




FIG. 421.—SMALL PAPILLARY ADENOMA OF THE STOMACH.

This is confined to the mucous membrane, forming a small polypoid growth into the cavity. Enlarged about five diameters.

Adenoma.—It has been already mentioned that in some of the papillary tumors of the mucous membrane there is a considerable growth of tubules lined with cylindrical epithelium (Fig. 421). Besides these we find in the submucous coat circumscribed tumors composed of tubules irregular in form and lined with one or more layers of cylindrical epithelium, like those of the gastric mucous membrane. (See Adeno-carcinoma below.)

Carcinoma of the stomach is usually primary, but is occasionally secondary to cancer elsewhere. It is of relatively common occurrence, the

¹ See references to *Bennecke* and *MacCallum*, foot-note, p. 688.

² See *Dock*, *Trans. Assn. Amer. Phys.*, vol. xv., p. 165, 1900, bibl.; also *Fenwick*, *Lancet*, vol. i., p. 463, 1901, bibl.; also *Corner* and *Fairbanks*, *Practitioner*, lxxii., 810, 1904.

stomach in Welch's analysis of over 30,000 cases being, next to the uterus, the organ most frequently affected.

The situation in Welch's summary of 1,300 cases¹ was: in the pyloric region, 791; lesser curvature, 148; cardia, 104; posterior wall, 68; involving a greater part of the stomach, 61; greater curvature, 34; anterior wall, 30; fundus, 19; multiple tumors in 45 cases. Carcinoma of the stomach is rare in childhood.²

Carcinomata of the stomach occur in various forms. There may be larger or smaller, flat or rounded or lobulated growths projecting from

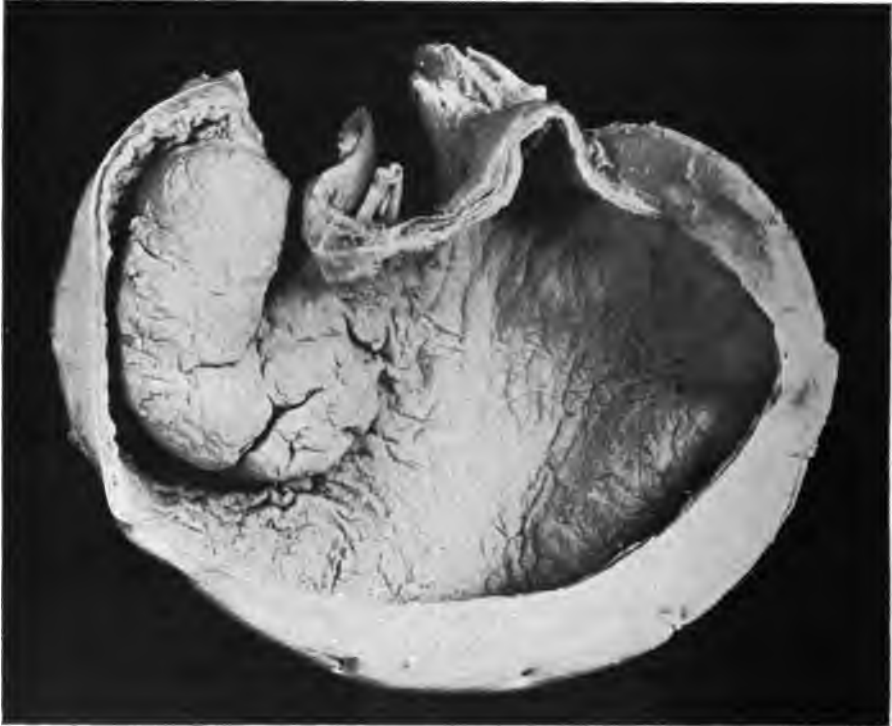

FIG. 422.—CARCINOMA OF THE STOMACH. (Pyloric Region.)
A large globular tumor mass projects into the cavity.

the inner surface of the stomach (Fig. 422). The mucous membrane over them may be intact or with a portion of the tumor may ulcerate. The destructive process may advance so that some of the ragged or smooth-edged ulcers may reach a large size. The wall of the stomach may be involved; peritoneal adhesions may form, or perforation may occur. On the other hand, the carcinoma may grow in the form of a

¹ Welch, Pepper's "System of Practical Medicine," vol. ii., p. 561, 1885.

² See Oster and McCrae on "Carcinoma of the Stomach in the Young," N. Y. Med. Jour., vol. lxxi., p. 581, 1900.

diffuse infiltration of the wall of the stomach (Fig. 423). Such tumors are less liable to ulcerate. They may be overlooked or mistaken for a chronic inflammatory lesion.

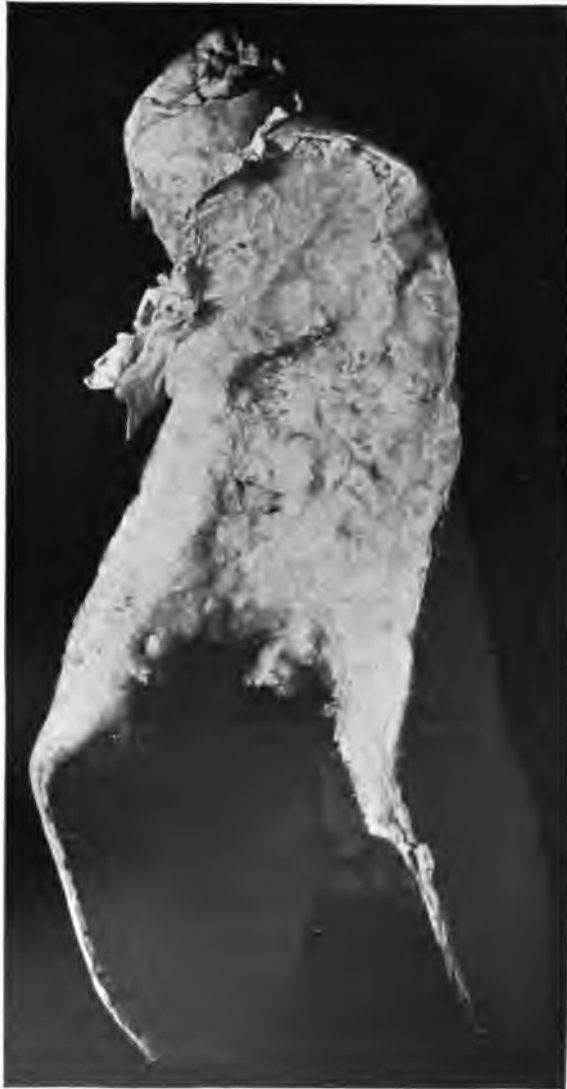

FIG. 423.—GELATINOUS CARCINOMA OF THE STOMACH.
Showing the infiltrating form of tumor occupying the pyloric end of the stomach and advancing along the wall.

Metastatic tumors in the liver, the lymph-nodes, and the peritoneum are common, but such metastases may occur in any part of the body.

The most common type of carcinoma of the stomach is the medullary' or so-called *adeno-carcinoma*, in which often to a considerable extent the glandular type is maintained in many parts of the growth (Fig. 246, p. 400). The cylindrical or polyhedral epithelial cells line variously shaped alveoli, which frequently maintain well-marked lumina. Cystic distention of these may occur.

Fibrous carcinoma, scirrhous, is the next most frequent type, and such are often the infiltrating forms (Fig. 266, p. 414).

The third type, *gelatinous carcinoma* (Fig. 267, p. 415), often forms extensive growths and is apt to invade adjacent structures and to establish metastases.¹



FIG. 424.—HAIR BALLS FROM HUMAN STOMACH.

This specimen consists largely of hairs, cotton and woolen threads, straws, etc.

Stenosis of the pylorus and chronic gastritis, adhesions, fistulæ, distortion of the stomach, perforations, etc., hæmorrhage, suppurative inflammation, are among the frequent secondary complications of gastric cancer.

Among the relatively infrequent secondary cancers of the stomach, those originating in the breast are proportionately large.²

Cysts of the stomach wall have been recorded.³

For general bibliography of lesions of the stomach see Thorel, Lubarsch and Ostertag's "Ergebnisse," Jahrg. V. for 1898, p. 142.⁴

¹ For a case of squamous epithelioma of the stomach see *Borst*, "Geschwulste," 1902, p. 665; also *Futterer*, Jour. Am. Med. Assn., vol. xliii., p. 1129, 1904.

² For statistics see *Welch*, reference above.

³ *Schultze* has seen a large cyst of undetermined origin, Proc. N. Y. Path. Soc., 1899-1900.

⁴ For a study of retrograde metastases of carcinoma through the lymph-channels from the stomach to the liver see *Jacob*, Arbeiten Path. Anat. Tubingen, Bd. v., p. 121, 1904. See also monograph on the growth and mode of extension of carcinoma by *Borrmann*, Mittheil. a. d. Grenzgebiet. d. Med. u. Chir., First Suppl. Heft, 1901.

FOREIGN BODIES.

Among the various foreign bodies which by accident or design may be present in the stomach may be mentioned hairs, thread, string, etc., which have been swallowed from time to time, usually by hysterical women. These may be closely packed together into a large mass nearly filling the cavity of the stomach, to which in shape it may correspond (Fig. 424).¹

The Intestines.

Malformations.

ATRESIA ANI.—Absence of the anal opening is frequent. This may be associated with partial or complete atresia of the rectum or of the colon which may be represented by solid cords. Blind terminations of the small intestine may occur, or there may be complete closure of the gut. There may be absence of continuity between the large and small intestine.

The *appendix* may be absent, but this is a very rare anomaly.²

TRANSPOSITION.—The position of the intestines may be the opposite to that which is usually found. The transposition may affect all the abdominal viscera, or only a single viscus is transposed.

ANOMALOUS POSITIONS.—The intestines with the other abdominal viscera may be partly without the abdominal cavity in failure of the abdominal walls to close in development (see Fig. 178, p. 324). Displacements of the colon are not infrequent.³

DIVERTICULA.—*Congenital Diverticula.*—These are most frequent in the lower part of the ileum. They usually spring from the convex surface of the intestine, more rarely from its attached border. In the latter case they are joined to the mesentery by a fold of peritoneum. The diverticulum forms a pouch from one to six inches long, of about the same diameter as the intestine, smallest at its free extremity (Fig. 395).

Such diverticula do not interfere with the functions of the intestines. They occasionally form part of a hernia. Sometimes the remains of these intestinal diverticula—called Meckel's diverticula—form soft, projecting tumors at the umbilicus⁴ in children.

Microscopical examination of such tumors often shows the structure of the intestinal *mucosa* and *muscularis*. If they remain attached by a fibrous cord to the navel, this cord may be the cause of incarceration of a portion of the intestines.⁵

Acquired Diverticula.—Not infrequently one finds at autopsies either in the small or large intestine diverticula or herniæ, which project from the exterior of the gut, usually near its mesenteric attachment. These consist of the mucous membrane

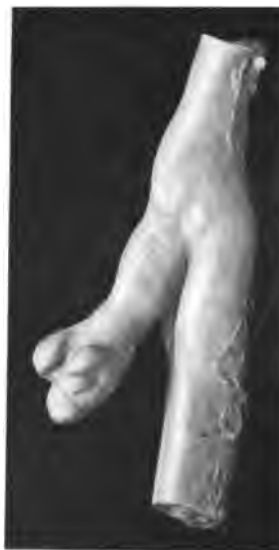

FIG. 425.—DIVERTICULUM OF THE SMALL INTESTINE.

¹ Such a specimen, mentioned by *Oster*, is in the museum of McGill University; another, reported by *Findler* (see Fig. 394), is in the museum of the College of Physicians and Surgeons, N. Y. See *Jacobson*, *Med. News*, Feb. 16th, 1901; also *Fenwick*, *Brit. Med. Jour.*, vol. ii., p. 1696, 1902, *bibl.*

² For congenital absence of the appendix see *Schridde*, *Virch. Arch.*, Bd. clxxvii., p. 150, 1904.

³ For bibliography of reported cases see *Shober*, *Am. Jour. Med. Sci.*, vol. cxvi., p. 405, 1898.

⁴ For bibliography of umbilical tumors see *Giannettasio*, *Arch. gén. de Méd.*, t. iii., p. 65, 1900.

⁵ For bibliography see *Riesman*, *Proc. Path. Soc. of Philadelphia*, N. S., vol. i., p. 193, 1898. For case of volvulus of Meckel's diverticulum see *Taylor*, *Johns Hopkins Hosp. Bull.*, vol. xii., p. 326, 1901.

which has been crowded through the muscularis and is covered by serosa. They may form in connection with the appendix. These so-called "false diverticula" may be large, but are generally not larger than a pea; they may be single or numerous (Fig. 396.). They as a rule cause no functional disturbance, but may, through the accumulation of fecal material within them, be the seat of perforation, inducing abscesses or peritonitis. Or they may lead to local adhesion to adjacent parts.¹



FIG. 426.—MULTIPLE FALSE DIVERTICULA OF THE INTESTINE.

CLOACÆ.—The rectum may open into the bladder, urethra, or vagina. Thus cloacæ are formed which are often associated with other malformations of the abdominal wall, intestines, and generative organs.

Incarceration, Volvulus.

1. The most common form is that in which a portion of intestine is strangulated by a fibrous band. Such fibrous bands are the result of peritonitis or may be of foetal origin. They pass from the intestines to the abdominal wall, or from one part of the intestines to another. The intestine becomes in some way caught under one of these bands and is compressed by it. The stricture thus produced may lead to a gradual accumulation of feces in the intestine above it, and may last for a long time before death ensues. In other cases the stricture interferes at once with the circulation of the blood; the intestine is intensely congested, becomes gangrenous, and death takes place with the symptoms of general peritonitis.

2. A portion of intestine becomes caught in some abnormal opening in the mesentery or omentum, or in the foramen of Winslow, or between the two layers of the mesentery. We have seen a case in which twelve feet of intestine had passed through a small opening in the mesentery.

3. A coil of intestine makes a half turn at its base, so that the two sides of the loops cross at its base. In this way the lumen of the intestine is completely closed and the vessels are compressed, so that congestion, peritonitis, and gangrene result. This form of lesion is most frequent in the ascending colon. In the small intestine it may occur when the gut is fixed by old adhesions. This twisting of the gut is called *volvulus*.

4. A portion of the intestine, with its mesentery, makes one or more complete turns on itself, closing the canal and compressing the vessels.

5. A portion of the intestine makes a half or entire turn about its longer axis. This is very rare, and occurs only in the colon.

6. The mesentery of a part of the intestine is long and loose, in consequence of a dragging down of the intestine by a hernia or by habitual constipation. The portion

¹ Consult *Fischer*, "False Diverticula of the Intestine," *Jour. Exp. Med.*, vol. v., p. 333, 1901, *bibl.*; also *Beer*, *Am. Jour. Med. Sci.* vol. cxxviii., p. 135, 1904. For diverticula of appendix see *Corn-ing*, *Albany Med. Annals*, Dec. 1905.

of intestine thus permitted to hang down is habitually filled with fæces, and by its pressure on some other part of the intestine produces an incomplete stricture.

Intussusception.

This change of position consists in the invagination of one portion of intestine in another portion (Fig. 427). Usually this takes place in the direction of the peristaltic movements, from above downward; more rarely in the opposite direction.



FIG. 427.—INTUSSUSCEPTION.

A portion of the gut is completely invaginated in the segment below and strangulated.

The parts are found in the following condition: There are three portions of intestine, one within the other. The inner portion is continuous with the intestine above the intussusception; its peritoneal coat faces outward. The outer portion is continuous with the intestine below; its peritoneal coat also faces outward. The inner portion

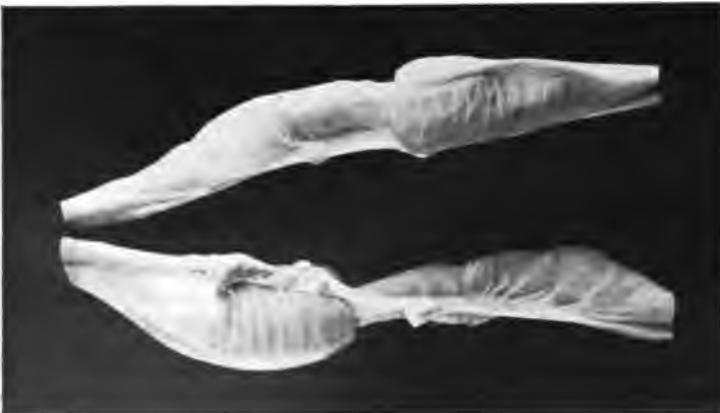

FIG. 428.—INTUSSUSCEPTION—AGONAL OR POST-MORTEM IN INTESTINE OF INFANT.

is turned inside out, its mucous membrane is in contact with the mucous membrane of the outer portion. In rare cases the intussusception is complicated by the invagination of a second portion of intestine in the inner tube, and even by a third intussusception

into the second one. These changes occur both in the large and small intestine; most frequently the lower part of the ileum is invaginated in the colon. The invaginated portion may be from a few inches to several feet in length. The lesion is most frequently found in early childhood.

The intussusception, by the dragging and folding of the mesentery which it involves, may lead to intense congestion of the parts, and even to large hæmorrhages between the coats of the intestine. The congestion may induce fatal peritonitis, or

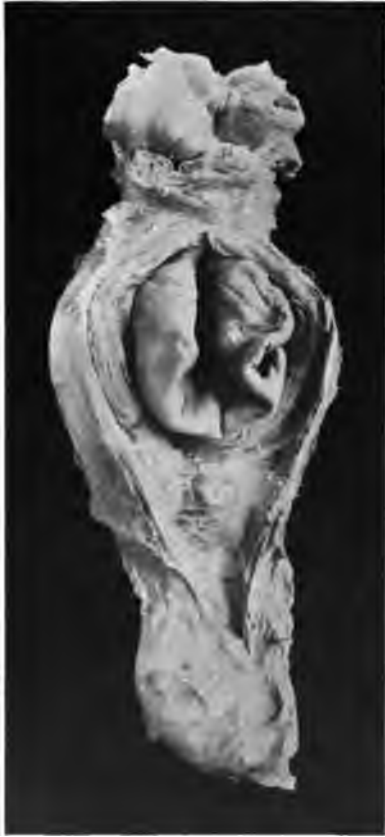

FIG. 429.—INGUINAL HERNIA—INTESTINAL.

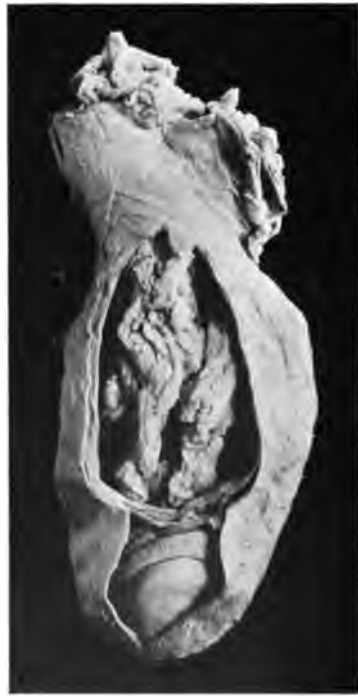

FIG. 430.—INGUINAL HERNIA—OMENTAL.

gangrene of the intestine, or chronic inflammation and adhesions, and the patient may live for a considerable time with symptoms of stricture. In other cases the invaginated portion of the intestine sloughs, the outer and inner portions become adherent, and the patient recovers, with or without stricture.

Besides this grave form of intussusception we often find, especially in children, one or more small invaginations not attended with congestion or inflammation. These are agonal or are formed immediately after death (Fig. 428).

Hernia.

The dislocation and protrusion of the whole or a part of an internal organ from its normal position is called hernia. This may occur in various parts of the body, but most frequently involves the abdominal viscera, especially the intestine or omentum.

In the most common form of the so-called inguinal hernia, which is of frequent occurrence in men, there is a descent into the inguinal canal of either a loop of intestine (Fig. 429) or a portion of the omentum (Fig. 430). For a description of the various forms of hernia we refer to works on surgery.

Dilatation of the Colon.

This may be congenital or acquired and is sometimes excessive.¹

WOUNDS—RUPTURES.

Penetrating wounds of the intestine usually prove rapidly fatal, either from shock or from peritonitis. Sometimes, however, the wound becomes closed by the formation of adhesions with the neighboring parts. Sometimes the wound in the intestines becomes adherent at the position of the wound in the abdominal wall, and an intestinal fistula is formed.

Rupture of the small intestine is not infrequently produced by severe blows on the anterior abdominal wall. It is noticeable that such blows may not produce marks or ecchymoses of the skin. Such ruptures usually prove fatal very soon, but sometimes the patient lives several days and the edges of the rupture undergo inflammatory changes.

Strictures of the intestine are sometimes followed by rupture of the dilated intestine at some point above the stricture.²

DISTURBANCES OF THE CIRCULATION—HÆMORRHAGE.

Hyperæmia of the intestine may be inflammatory in character or it may be associated with disturbance of the portal circulation. Under both of these conditions ecchymoses may occur. Pigmentation may follow large or small interstitial hæmorrhages.

As a result of **embolism** or **thrombosis** of the mesenteric vessels **hæmorrhagic infarctions** may occur, sometimes involving a considerable portion of the gut.³ Hæmorrhage into the lumen may follow, or gangrene, or inflammation. The latter processes are readily induced in the injured regions by the bacteria constantly present in the intestinal contents. Septic emboli may induce suppurative inflammation in the mesentery and in the wall of the intestine.

Intestinal **hæmorrhage** may occur in venous congestion, as in certain forms of cirrhosis of the liver. It may follow ulceration, in typhoid fever, in chronic colitis, in malignant tumors, etc.; it may accompany infarction.⁴

DEGENERATION.

Amyloid degeneration may be associated with a similar process elsewhere in the body. The iodine test may reveal the existence of this alteration in the villi of the small intestine.

¹ See *Fitz*, *Am. Jour. Med. Sci.*, vol. cxviii., p. 125, 1899, bibl.; also *Griffith*, *Trans. Assn. Am. Phys.*, vol. xiv., p. 1, 1899.

² See summary of cases by *Gallaverdin*, *Gaz. des Hôpitaux*, Aug. 24th and 31st, 1901, bibl.

³ For a further consideration of thrombosis of the mesenteric veins consult *Welch*, Allbutt's "System of Medicine," vol. vi., p. 218. See also study by *Jackson, Porter, and Quinby*, *Jour. Am. Med. Assn.*, vol. xlii., p. 1469, 1904.

⁴ For reference to occult hæmorrhage in gastro-intestinal canal see *Jaworski and Korolewicz*, footnote, p. 655.

INFLAMMATION.

INFLAMMATION OF THE SMALL INTESTINE. (*Enteritis.*)

Acute Catarrhal Enteritis.—This may occur under conditions similar to those inciting catarrhal inflammation in the stomach. It may be local or general and may be associated with similar processes in the stomach and colon. In ptomain poisoning the lesions are often severe. Comparatively mild forms of the lesion may predispose the intestine to the incursions of intestinal bacteria and the development of more severe forms of destructive lesions. The mucosa may be reddened or ecchymosed, and covered with mucus mingled with degenerated epithelium and leucocytes. The epithelium may be degenerated and peeled off (Fig. 431), and the cylindrical cells may be distended with mucus formed within them—"beaker cells."

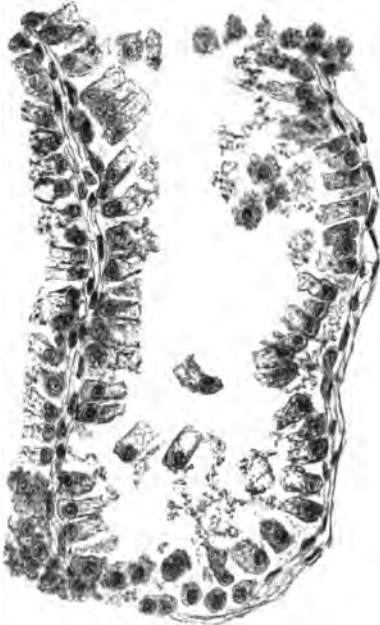

FIG. 431.—ACUTE CATARRHAL ENTERITIS.
Showing the open end of one of the tubular glands with exfoliating and disintegrating epithelium.

and pigmentation are frequent. There is hyperplasia of the interglandular tissue of the mucosa and the submucosa. In this way there may be atrophy of the glands, and the mucous membrane may be thin and fibrous. The muscularis may also be involved and atrophied. The submucosa and the muscular layer may, on the other hand, be thickened from the new-formed fibrous tissue.

Pseudo-membranous Enteritis may occur in connection with a similar condition in the colon, in infectious diseases, in chronic diseases of the liver and kidney; in cachectic conditions, or as the result of the ingestion of irritant poisons. The mucous membrane may be the seat of superficial

The solitary and agminated lymph-nodules may be swollen from hyperplasia. When this hyperplasia is marked (Fig. 432), the lesion is often called *follicular* or *nodular enteritis*, and erosions and ulceration may occur (Figs. 440 and 441).¹ This lesion is especially common in children suffering from various types of acute infection. For hyperplasia of the lymphoid tissue of the intestine in typhoid fever see p. 235.

Chronic Catarrhal Enteritis.—This may follow the acute form or occur independently. It often accompanies many forms of chronic disease of the heart, kidneys, lungs, etc. The mucous membrane may be covered with mucus; ecchymoses, erosions, and pigmentation are frequent.

Chronic Catarrhal Enteritis.—This may follow the acute form or occur independently. It often accompanies many forms of chronic disease of the heart, kidneys, lungs, etc. The mucous membrane may be covered with mucus; ecchymoses, erosions, and pigmentation are frequent.

¹ It is better to abandon the name nodular enteritis for this lesion and call it *nodular hyperplasia*.

necroses, sometimes in patches, and the pellicle may consist largely of mucus with necrotic epithelium. Fibrin may be present, and fibrin and extravasated leucocytes and serous fluid may infiltrate the submucosa.

Exudative or Suppurative Enteritis is rare. Purulent foci, usually




FIG. 432.—NODULAR ENTERITIS.
From the intestine of a child.

metastatic in origin, may form in the wall of the intestine. A more diffuse suppuration may follow infection after obstruction or strangulation.¹

Tuberculous Enteritis.—The lymph-nodules and Peyer's patches are often involved in intestinal tuberculosis and often ulcerate (Fig. 433). Miliary tubercles may be present with cheesy degeneration (Fig. 434) and




FIG. 433.—TUBERCULOUS ULCERS OF THE SMALL INTESTINE.

In the larger ulcers the mucous membrane is almost entirely gone, leaving the muscularis exposed at the bottom.

the subperitoneal lymphatic vessels are often involved and may appear as white, nodular, branching, slightly elevated cords, running around the gut (Fig. 435). Tuberculous ulcers are apt to extend most rapidly in a direction transverse to the axis of the gut (Fig. 436), differing in this

¹ See for a study of phlegmonous enteritis *MacCallum*, *Johns Hopkins Hosp. Bull.*, vol. xvii., p. 254, 1906, bibl.

respect from typhoid ulcers (see p. 237). But to this there are frequent exceptions. Tuberculous ulcers rarely perforate. (See for other forms of tuberculosis of the intestine page 682.)¹

The mesenteric lymph-nodes are frequently involved in either active

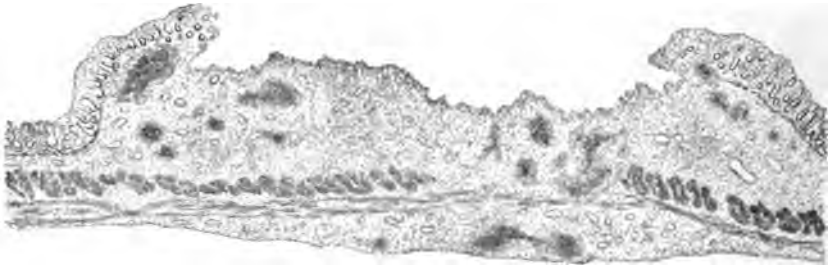

FIG. 434.—SECTION OF A TUBERCULOUS ULCER OF THE SMALL INTESTINE. Showing tubercle tissue with miliary tubercles and caseation at the bottom of the ulcer. There are miliary tubercles beneath the serosa. (See Fig. 435.)

or inactive tuberculosis in any part of the body. They may not show gross lesions, but the microscope may show characteristic lesions or tubercle bacilli. Frequently, when neither lesions nor bacilli are demonstrable, inoculation of guinea-pigs shows that the nodes are infected.




FIG. 435.—SUBSEROUS TUBERCLES FOLLOWING THE LYMPH-VESSELS AT THE BOTTOM OF A TUBERCULOUS ULCER OF THE SMALL INTESTINE.

The mesenteric nodes are frequently infected without other tuberculous lesions in the body.²

Syphilitic Ulcers, originating in the lymphatic structures, are sometimes found in infantile syphilis.

¹ For statistics of intestinal tuberculosis see *Zahn*, *Munch. med. Woch.*, p. 49, 1902; also *Nebelthau*, *ibid.*, pp. 1246 and 1300, 1903; also *Wagner*, *ibid.*, pp. 2036 and 2095, 1903; also *Ipsen*, *Berl. klin. Wochenschr.*, p. 791, 1906. For presence of tubercle bacilli in mesenteric lymph-nodes see *MacFadyen* and *MacConkey*, *Brit. Med. Jour.*, vol. ii., p. 129, 1903.

² See *Rosenberger*, *Am. Jour. Med. Sci.*, vol. cxxx., p. 95, 1905. For reference to intestines as portals of entry of tubercle bacilli, see p. 694.

Duodenal Ulcers may be tuberculous or may follow extensive burns. In the latter case their mode of origin is obscure. They may occur under a variety of other conditions.¹

Other Forms of Ulcers.—The solitary and agminated lymph-nodules frequently undergo hyperplasia, in infectious diseases, after extensive




FIG. 436.—TUBERCULOUS ULCERS OF THE SMALL INTESTINE.
Showing the extension of the ulcers in a direction transverse to the axis of the gut.

burns, in various forms of inflammation of the intestine. Hyperplasia of the lymphatic tissue—see p. 672—with ulceration is especially frequent in children.

INFLAMMATION OF THE LARGE INTESTINE. (*Colitis*.)

The mucous membrane of the large intestine is frequently the seat of acute and chronic inflammatory and necrotic processes known clinically as *dysentery*.² The rectum is most often involved, but sometimes the upper part of the colon and sometimes the whole colon is affected.

Acute Catarrhal Colitis.—This process is frequently limited to the lower end of the colon and presents several types. There may be an increased production of mucus, which coats the surface of the mucous membrane and is mixed with exfoliated and fatty or disintegrated epithelium and red blood cells. The surface epithelium may be degenerated and exfoliate, many “beaker cells” being present, indicating the source of over-production of mucus (Fig. 437). The mucous membrane may be congested and infiltrated with serum and leucocytes. Again, with conditions similar to those just described, there may be a purulent exudate in the mucous membrane. There is a form of catarrhal colitis in which there is a more or less extensive formation of new connective tissue between the glands and in the submucosa. Finally, there may be small or extensive ulceration in the involved areas of the mucosa.

Acute Infectious Colitis (Tropical Dysentery) is of especially frequent occurrence in warm countries and is often epidemic. In one group of

¹ For a study of duodenal ulcers see *Weir*, *Medical Record*, vol. lvii., p. 749, 1900, bibl.

² The classification of these lesions is with our present knowledge unsatisfactory, and is largely based upon morphology. In some phases of so-called dysentery—infectious colitis—however, the nature of the excitant is taken into the account. Consult for a special study of forms of colitis seen in New York, *Delafield*, *Am. Jour. Med. Sci.*, vol. cxiv., p. 401, 1897.

cases (a) the disease is probably incited by protozoa—*Entamoeba histolytica*; while in the other (b), bacteria, some apparently related to the typhoid-colon bacillus group, and possibly others, are believed to be the excitants.

(a) AMŒBIC COLITIS.—This form of colitis is apparently incited by the presence of the wall in the intestine of the *Entamoeba histolytica*.

The amœbæ are found in the gelatinous masses which are common in the stools. They are of rounded shape, and, when alive, change their




FIG. 437.—ACUTE CATARRHAL COLITIS.

The epithelium of the tubular glands, especially near their mouths, is forming an excessive amount of mucus with destruction and exfoliation of the cells. The tubules are dilated with mucus which covers the surface. The mucosa at the right is necrotic and forms the edge of an ulcerated area.

position and shoot out and retract little projections (pseudopodia). Their outer portion is composed of a pale hyaline or homogeneous substance; the inner contains vacuoles and is more refractive (see Fig. 73).

In the colon the amœbæ are found in the connective-tissue coat (Fig. 438) and in the floors of the ulcers.

Amœba excites at first a moderate exudative and productive inflammation followed by necrosis. Thus ulcers are formed. The ulcers may be superficial or deep, sometimes extending to the peritoneum; they enlarge by infiltration and necrosis at their edges, so that extensive destruction of the mucous membrane may occur. The amœbæ may be present in the connective tissue at the base or sides of the ulcers. Not infrequently, owing to bacterial infection from the intestinal contents, varying degrees of suppurative inflammation may complicate the lesion.

Necrotic and suppurative processes may be set up in the liver (see p. 722) and in the right lung, and in these lesions the amœba may be found.

(b) ACUTE INFECTIOUS COLITIS WITH BACTERIAL EXCITANTS.—The lesions in those forms of infectious colitis which are not associated with amœba are varied, and it is not yet possible to give a very precise morphological characterization of them. In general it may be said that the lesion when pronounced is pseudo-membranous, exudative, and necrotic, with or more less ulceration of the mucosa and submucosa.

The earlier bacterial studies of the various types of infectious colitis—dysentery—tropical, epidemic, sporadic, or pseudo-membranous, gave little definite data. Many bacteria were found, most of them of species not infrequently present in the normal intestine. In 1897, however, Shiga made a careful study of a series of cases in a serious dysentery epidemic occurring at that time in Japan. Shiga found constantly in these cases a bacillus—*Bacillus dysenteriae*—not normally present and pathogenic for animals, which gave agglutinative reactions with the serum of the dysentery patients. This bacillus was formerly regarded as similar to the typhoid bacillus, but can now be readily differentiated from it.¹

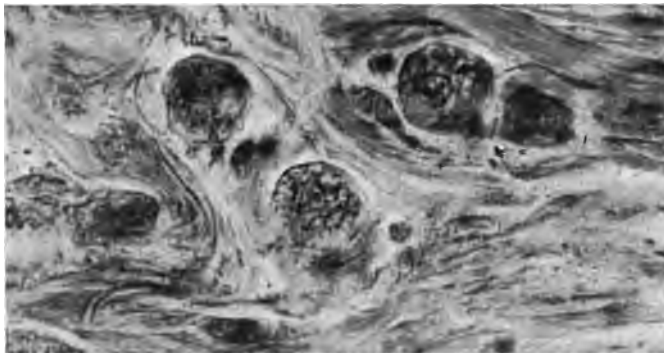


FIG. 438.—AMŒBIC COLITIS.
Showing amœbæ in the submucous fibrous tissue.

Two years later Kruse found a similar bacillus in cases of dysentery occurring in Germany, and Flexner and Strong have found one which they believe to be identical in the Philippines. It has since been found in numerous instances in the United States.²

Considerable doubt has arisen regarding the significance of many of the later determinations owing to the fact that until recently some of the distinctive biological characters were not generally known, and that the agglutination reactions, if not carried out with extreme care, may lead the observer astray.

We cannot enter here upon the details of the various studies of this subject. But it has been shown that there are several groups of the Shiga bacillus which are the excitants of some forms at least of tropical and epidemic or sporadic dysentery. Whether the occurrence which has

¹ See *Hiss and Russell*, *Med. News*, vol. lxxxii., p. 289, 1903.

² See *Park and Williams*, *Pathogenic Bacteria*, p. 276, 1910.

been described of this bacillus or variants of it, in other forms of intestinal disorder, such as some types of infantile diarrhoea, is of significance or not, it is yet too early to say.¹

While the value of protective serum prepared by animal inoculations

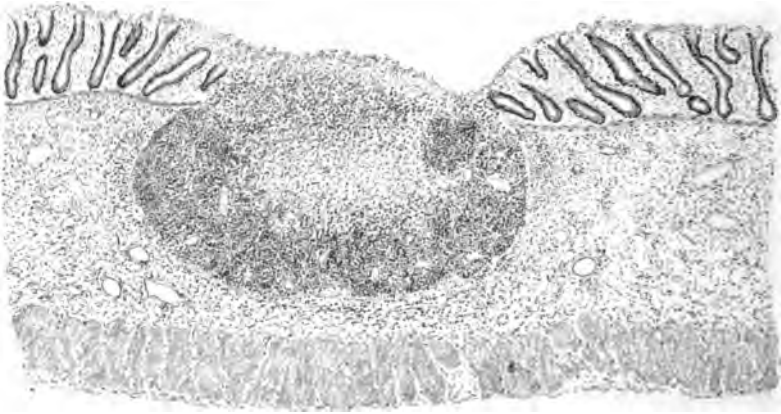


FIG. 439.—NODULAR COLITIS—FOLLICULAR COLITIS.
Showing commencing necrosis of the mucosa over the hyperplastic lymph-nodule.

of Shiga's bacillus has been claimed, the evidence is yet too meagre to permit of final judgment.²

Bacillus pyocyaneus has been repeatedly found in the discharges in cases of dysentery as well as in other intestinal disorders under conditions



FIG. 440.—NODULAR COLITIS WITH ULCERATION.
Showing necrosis and ulceration of the lymph-nodule with opening into the lumen of the gut.

which justify the conjecture that it is sometimes at least an excitant of intestinal inflammation and necrosis. *Streptococcus pyogenes* has been repeatedly found in association with enteritis and colitis. Intestinal infection with streptococcus is more frequent and significant in children than in adults.³

¹ For a study of experimental colitis see *Fleznar and Sweet*, *Jour. Exp. Med.*, vol. viii., p. 514, 1906.

² For a general statement of forms and lesions of dysentery and its relationship to micro-organisms see *Fleznar*, *Phila. Med. Jour.*, vol. vi., p. 414, 1900; see also *Lentz*, *Kolle and Wassermann's "Handbuch der Mikroorganismen,"* Bd. i., p. 309.

³ See *v. Lingelsheim*, *Kolle and Wassermann's "Path. Mikroorganismen,"* Bd. iii., p. 336.

Nodular Hyperplasia.—In many cases of catarrhal and croupous inflammation of the colon and of acute infections, especially in children, the solitary follicles (lymph-nodules) become more or less swollen and necrotic. Besides these cases, however, there are others in which the




FIG. 441.—NODULAR COLITIS.

From the intestine of a child, showing numerous ulcers involving solitary nodules. (Compare Fig. 432.)

changes in the nodules form the principal part of the lesion, while the catarrhal or croupous inflammation is but slightly developed. The lesion is similar to that in nodular hyperplasia in the small intestine. The nodules are first swollen—hyperplastic—(Fig. 439), then necrotic,

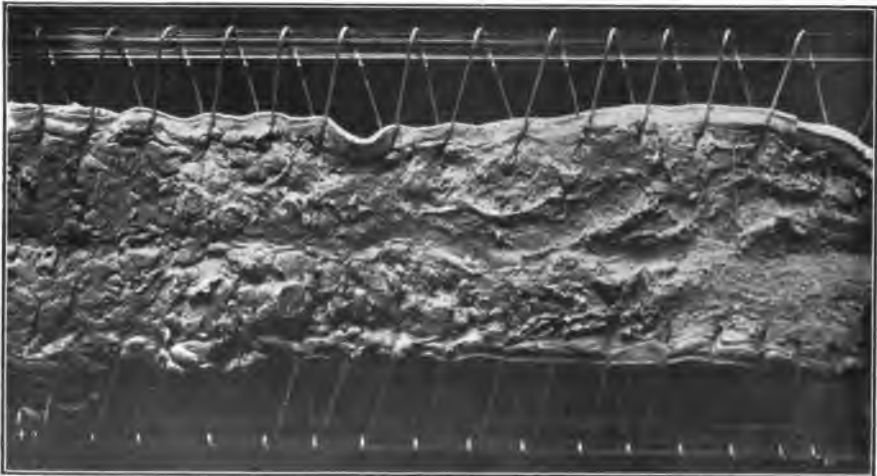


FIG. 442.—PSEUDO-MEMBRANOUS (CROUPOUS) COLITIS.

then slough away and leave little circular ulcers with overhanging edges (Fig. 440). These ulcers are usually numerous (Fig. 441) and may be scattered over a large part of the colon. The ulcers are apt to show but little disposition to heal, and the acute colitis often becomes chronic.

Nodular Colitis.—In rare cases of typhoid fever and occasionally under other conditions there are foci of inflammation with necrosis and ulceration irregularly scattered and involving primarily not the mucous membrane but the underlying tissue. These lesions are not to be identified with hyperplasiæ of the solitary lymph-nodules with ulcerations which occur with especial frequency in children suffering from acute infections.¹

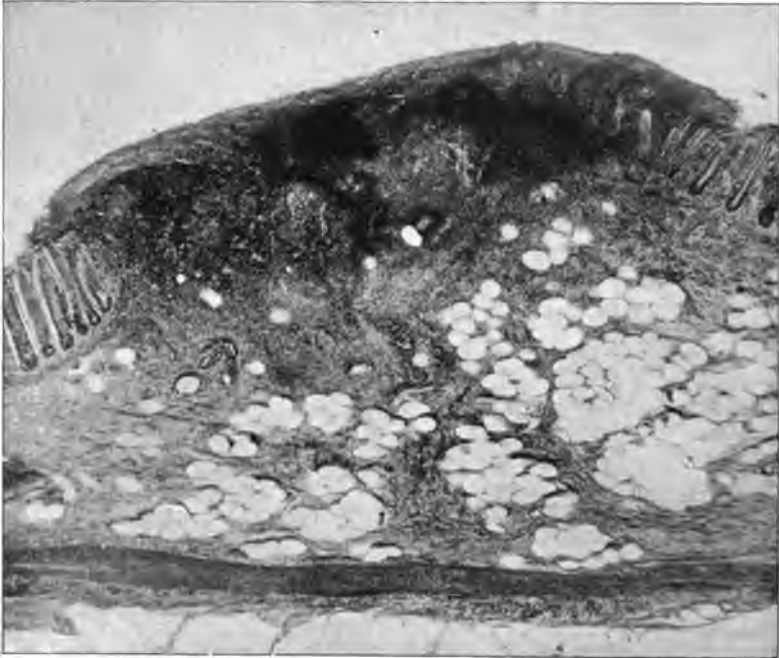

FIG. 443.—NECROTIC COLITIS.

Circumscribed congestion and necrosis of the glandular and connective-tissue coats.

Pseudo-membranous (Croupous) Colitis.—This form of inflammation may involve the rectum alone, or the entire length of the colon, or only its upper portion. The mucous membrane is congested and swollen, and coated with a layer of false membrane; the connective tissue between and beneath the gland tubules is infiltrated with fibrin and pus, and in severe cases the inflammation involves the muscular and peritoneal coats also. The inflammation is usually more intense at some places than at others, so that the surface of the mucous membrane shows the false membrane in isolated patches. (Fig. 442.) Less frequently there is a uniform coating with the false membrane. In mild cases, as the inflammation subsides, the products of inflammation are absorbed and the wall of the intestine returns to its normal condition. In more severe cases the

¹ See Whipple, Johns Hop. Hosp. Bull., vol. xvii., p. 281, 1906.

quantity of the inflammatory products is so great that portions of the wall of the intestine become necrotic. This necrosis may involve only the glandular coat, or it may extend deeper into the wall of the intestine. The necrosed tissue after a time sloughs away, leaving behind ulcers of different sizes and depths. After this the ulcers may cicatrize, or their floors and walls may remain in the condition of granulation tissue for an indefinite length of time. When the latter is the case there is added a chronic inflammation of the wall of the intestine between the ulcers, with changes in the mucous membrane and thickening of the connective-tissue and muscular coats.

Necrotic Colitis.—There is a form of inflammation of the colon in which considerable areas of the connective-tissue coat become necrotic, leaving the glandular coat undermined and separated from the muscular coat. In this way large ulcers with overhanging edges are developed. This form of colitis is very fatal.

There is another very fatal and obscure form of necrotic colitis which appears to be septic in character. After death the inner surface of the colon is found studded with little blackish areas in which the blood-vessels are gorged with blood. The glandular and connective-tissue coats are infiltrated with pus cells and there is a superficial necrosis (Fig. 443).

Various forms of micro-organisms have been found in connection with suppurative and necrotic lesions of the ileum and colon—*Streptococcus pyogenes*, *Staphylococcus pyogenes*, *Bacillus coli communis*, *Bacillus proteus*, *Bacillus pyogenes*, and others. The significance of these organisms is not yet clear.¹



FIG. 444.—CHRONIC ULCERATIVE COLITIS—DYSENTERY.

There are small erosions of the swollen mucous membrane.

¹ See *Kruse and Pasquale*, *Zeits. f. Hygiene und Infkr.*, Bd. xvi., p. 1, 1894; also *Cérenville, Tavel*, and others, *Ann. Suisses des Sc. Méd.*, sér. ii., p. 531, 1895.

See, for consideration of *Streptococcus enteritidis* in infants, *Hirsch*, *Centralbl. f. Bak.*, Abth. I., Bd. xxii., p. 369, 1897, bibl.

For a study of intestinal bacteria see *van Ermenghem*, *Kolle und Wassermann's "Path. Mikroorganismen,"* Bd. ii., p. 937; also *Ford*, "Studies Royal Victoria Hospital," Montreal, vol. i., 1903, *résumé* and bibl.; also *Weiss*, *Cbl. f. Bak.*, Abth. I., Bd. xxxvi., p. 13, 1904. For a study of the permeability of the intestinal wall for bacteria see *Klimenko*, *Zeits. f. Hygiene, etc.*, Bd. xlvi., p. 67, 1904, and *Uffenheimer*, *Deutsch. med. Woch.*, p. 1851, 1906, bibl. See, for a study of absorption in the large intestine, *Bremer*, *Jour. Med. Res.*, vol. xv., p. 89, 1906. For a study of the cause of death of bacteria in the small intestine see *Rolly and Liebermeister*, *Deut. Arch. klin. Med.*, Bd. lxxxiii., p. 413, 1905.

Mucous Colitis (Membranous Colitis).—Under a variety of obscure conditions, probably sometimes inflammatory in character, shreds or sheets or even cylindrical casts of the interior of the gut are passed from the bowels. These consist of dense mucus often mingled with degenerated epithelium.¹

Chronic Colitis.—In prolonged inflammation of the colon, marked structural alterations may take place. The glandular coat may be uniformly thickened or thrown into the form of polypoid tumors, or atrophied, or destroyed by ulcers of various sizes and shapes (Figs. 444 and



FIG. 445.—CHRONIC COLITIS WITH EXTENSIVE ULCERATION OF THE MUCOUS MEMBRANE. In places only a few ragged islets of mucous membrane are left, the muscularis forming the bottom of the ulcers.

445). Small cysts may form from the retention of mucus in the follicles. The connective-tissue and muscular coats may be thickened or thinned. Apparently chronic colitis may follow any of the forms of acute colitis.

Repair may follow even considerable losses of substance in the intestinal mucous membrane. The new-formed connective tissue may undergo slight or marked cicatricial contraction. The denuded surfaces may become covered anew with epithelium derived from the intact cells.²

THE CÆCUM.

Catarrhal Inflammation of the cæcum is not uncommon. It is usually produced by an habitual accumulation of fæces in this part of the intestine. The course of the inflammation is usually chronic, but marked by acute exacerbations. At first the mucous membrane undergoes the ordinary changes of chronic catarrhal inflammation. To this may succeed a slow suppurative inflammation which extends through the wall of the intestine and gives rise to ulcers and perforations.

Through these perforations the fæces may pass into the peritoneal cavity, or the perforations are partly closed by adhesions, and abscesses are formed, or sinuses into the surrounding soft parts.

¹ Numerous observations have been made and a large bibliography has been gathered on what is called *membranous enteritis* or *colitis*, for which the reader may consult *Butler*, N. Y. Med. Jour., Dec. 28th, 1895, or *Akerland*, Arch. f. Verdauungskrankheiten, Bd. i., p. 396, 1896.

² For a study of regeneration of intestinal epithelium see *Quénu* and *Branca*, Arch. d. méd. exp., vol. xiv., 1902, p. 405. For a study of the association of the crypts of Lieberkühn with lymph-nodes in the colon see *Schulze*, Centrbl. f. Path., Bd. xvi., p. 99, 1905.

Chronic Hyperplastic Tuberculosis of the Ileo-cæcal Region and Other Parts of the Intestine.—Attention has recently been called to a peculiar form of tuberculous inflammation of the intestine which is characterized by the extensive formation of small spheroidal-celled and fibrous tissue, especially in the submucosa and often involving the muscular wall and the subserous layer. Miliary tubercles, cheesy degeneration, and ulceration are not usually conspicuous features of the lesion. The ileo-cæcal region is most often involved, the rectum less frequently, while the lesion is rarely limited to the ileum. Both the large and small intestines may be involved together. The new tissue may form a circumscribed annular thickening of the wall of the gut, or it may occur as a distinct tumor or as polypoid projections of the mucous membrane. The intestine in the vicinity of the involved portion may be enclosed in a mass of fibrous fat tissue. Owing to the thickening of the wall of the intestine the lumen may be much narrowed or nearly completely stenosed. On section of the thickened areas, caseous foci may be revealed; ulcerations, in rare cases, may be present; more often they are moderate or extensive.

The microscopical examination shows that while miliary tubercles and cheesy degeneration are commonly to be detected, the new tissue consists in the main of collections of small spheroidal cells with more or less fibrous stroma and occasionally giant cells, and of moderately cellular or dense fibrous tissue. The polyhedral cells common in tuberculous inflammation are not as a rule conspicuous. The new tissue is usually most abundant in the submucosa. The mucosa may be similarly thickened, usually in polypoid form, or unchanged; it may show simple catarrhal alterations or may contain miliary tubercles or be ulcerated. The muscular coat may be also infiltrated and much thickened by the new-formed cellular and fibrous tissue and there may be muscular hypertrophy. The associated lymph-nodes may be involved. Tubercle bacilli are present in the lesions, sometimes in enormous numbers. The process appears to be sometimes primary in the intestine; sometimes it occurs with or follows tuberculous lesions of the lungs. Hyperplastic tuberculous lesions limited to the cæcum have frequently been operated upon under the impression that the process was cancerous.¹

THE RECTUM.

Besides *inflammatory changes* similar to those already described as occurring in the colon, we sometimes find a suppurative inflammation of the connective tissue which surrounds the rectum, either associated with lesions of the mucous membrane or occurring by itself.

In adults the lower end of the rectum is the part of the intestine which is the most frequent seat of syphilitic ulceration. Most of these ulcers seem to be the result of unnatural coitus, or of infection from specific sores of the vulva; but some of them seem to be due to the softening of gummy tumors. The gonococcus is an occasional excitant of inflammation of the rectum.

¹ For a study and bibl. see *Lartigau*, *Jour. Exp. Med.*, vol. vi., 1901, p. 23. See also *Richter*, *Ziegler's Beitr.*, Bd. xxxix., p. 199, 1906, bibl.

Strictures of the rectum may be due to tumors, to cicatrices following trauma or inflammation.¹

Hæmorrhoids (Piles).—Ectasiæ of the hæmorrhoidal veins are of frequent occurrence. They are most frequent in adults and are usually due to venous obstruction in cirrhosis, chronic constipation, pelvic tumors, chronic inflammation of the rectum, etc. The enlarged veins may be within or without the sphincter—internal or external hæmorrhoids. The

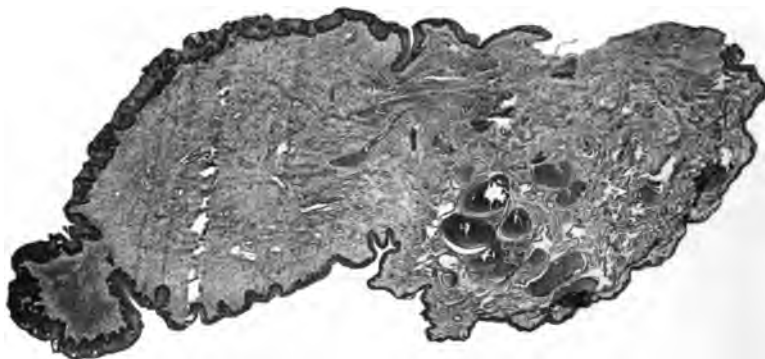

FIG. 446.—HÆMORRHOIDS.

Section of an external hæmorrhoid consisting of fibrous tissue and dilated vessels. Covered with epithelium except at the upper right portion where it was attached.

dilated veins may have thickened walls and may be surrounded by new-formed connective tissue. The projecting mass in external hæmorrhoids may consist in part of dilated vessels, in part of fibrous tissue, and is covered by thickened epithelium (Fig. 446). Considerable hæmorrhage may take place from hæmorrhoids, and they may afford a portal of entry of bacteria leading to local or general infection.

THE APPENDIX VERMIFORMIS.

Inflammation—Appendicitis.—Inflammation of the appendix may present various phases.

1. The mucous membrane may be the seat of *acute catarrhal inflammation*. This is of mild type and short duration, with congestion, swelling, and an increased production of mucus; or it is of severer type, of longer duration, and the cavity of the appendix is distended by mucus and pus.

2. The entire thickness of the wall of the appendix may be the seat of an *acute exudative inflammation*. The appendix is very much increased in size, sometimes to the size of a man's finger. (Fig. 417.) This increase in size is due, not to a dilatation of the cavity of the appendix, but to a thickening of its walls. The walls are congested, swollen, infiltrated with fibrin and pus, the peritoneal coat is covered with fibrin. There is neither necrosis nor perforation. If the appendix is behind the cæcum,

¹For bibliography of non-malignant rectal strictures see *Peterson*, *Jour. Am. Med. Assn.*, vol xxxiv., p. 259, 1900.

or if adhesions are formed early, there is only a localized peritonitis. If the appendix projects freely into the peritoneal cavity and no adhesions are formed, a general peritonitis may be soon established.

3. At one or more points in the wall of the appendix there is an *exudative inflammation with necrosis*. In this way small or large portions of the wall of the appendix are destroyed, large or small perforations are formed, and the contents of the appendix escape into the abdominal cavity. In these cases the appendix usually contains a faecal concretion. Such perforations are usually followed by the collection of pus around

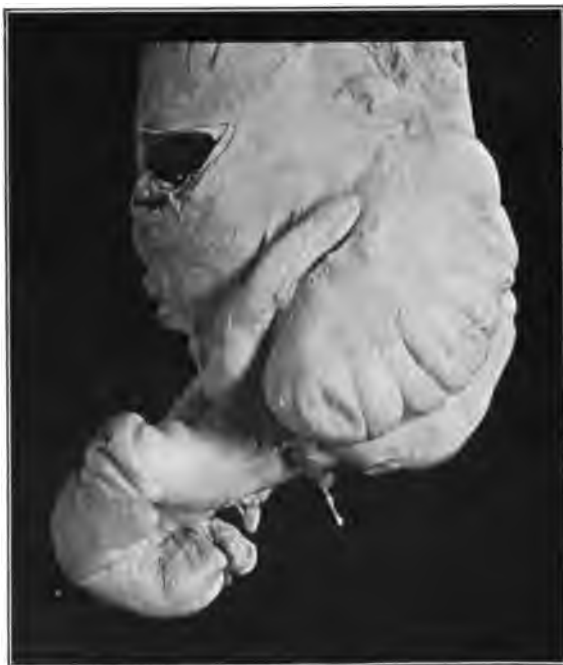

FIG. 447.—ACUTE APPENDICITIS.

A posterior view of the caput coli. The appendix is swollen and a pellicle of exudate covers it and the adjacent intestine.

the appendix (Fig. 448). The pus may extend from this abscess-like collection in any direction and for long distances, so that collections may be found deep in the pelvic cavity, or under the diaphragm, or abscesses may form at other remote points.

4. The entire appendix becomes *gangrenous* within one or two days, with the formation of an abscess, or general peritonitis. This is the most fatal form of appendicitis.

5. Inflammation of the appendix may be *secondary* to *catarrhal* or *croupous colitis*.

6. In *typhoid fever* there may be changes in the wall of the appendix

of a character similar to those in the wall of the small intestine; that is, hyperplasia of the lymphoid tissue with necrosis (p. 235).

7. There may be a *tuberculous inflammation* of the appendix, with the formation of ulcers.

As the result of chronic inflammation in the appendix, atrophy of the glands and lymphoid tissue with increase of the fibrous tissue (Fig. 449) and *strictures* or *obliteration* of its lumen may occur (Fig. 450).

Cystic dilatation of the appendix may be formed by obstruction of

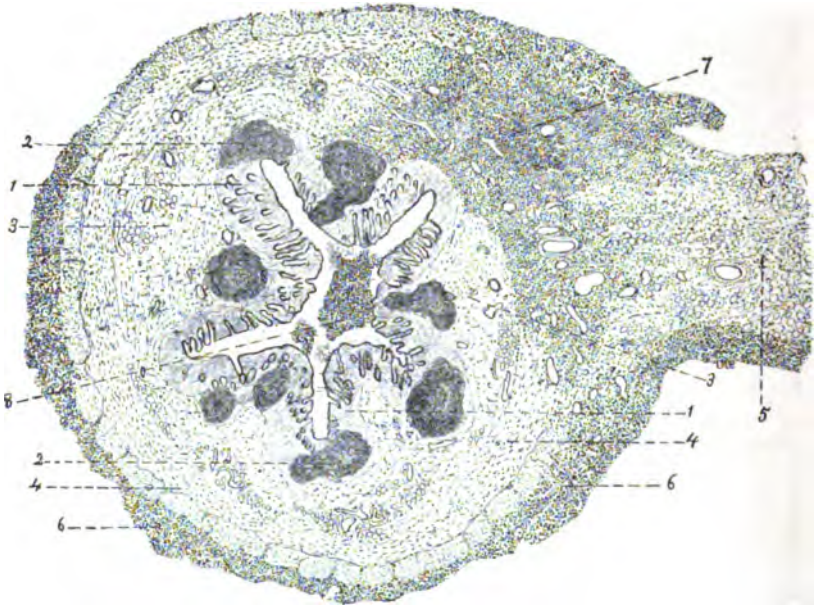


FIG. 448.—ACUTE SUPPURATIVE APPENDICITIS.

Appendix removed by operation twelve hours after first symptoms. Streptococcus was found in the exudate. 1, Mucous membrane of the appendix; 2, lymphatic nodules in the mucous membrane; 3, submucosa; 4, muscularis; 5, mesentery of the appendix; 6, pus and fibrin covering the appendix; 7, dense infiltration of the wall of the appendix with pus.

the lumen. The cysts thus formed may be of considerable size—from one to fifteen centimetres in diameter or larger—and contain mucous, gelatinous, or watery fluid often turbid or colored.¹

The lumen of the appendix frequently contains *concretions* of faecal material which have often been mistaken for foreign bodies. Foreign bodies, such as grape and apple seeds, and various small objects which have been swallowed, sometimes, though rarely, find their way into the appendix.² Both the faecal concretions and the foreign bodies may act as important predisposing agents of inflammation and perforation of the

¹ See for a study of cysts and diverticula of the appendix *Corning*, Albany Med. Annals, Dec., 1905.

² For a study of foreign bodies in appendix see *Mitchell*, Johns Hopkins Hosp. Bull., vol. x., p. 35, 1899.

appendix, through pressure, erosion, etc., of the mucous membrane, affording portals of entry to various forms of pathogenic micro-organisms.

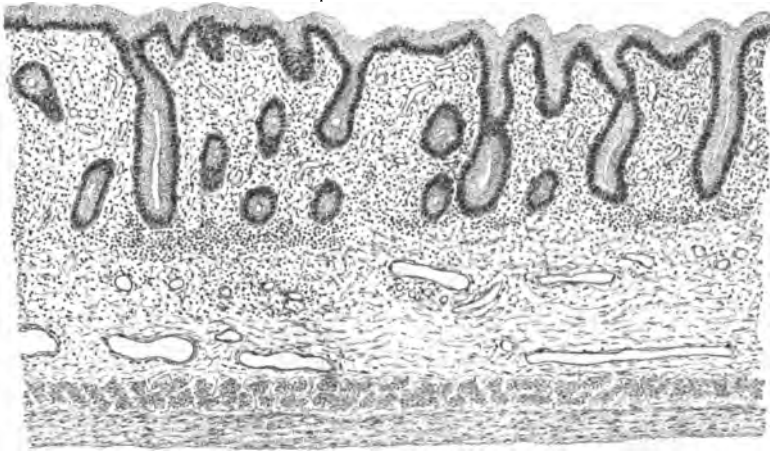


FIG. 449.—CHRONIC APPENDICITIS.

Showing obliteration of the glands and lymphoid tissue with new fibrous tissue in the mucosa and submucosa.

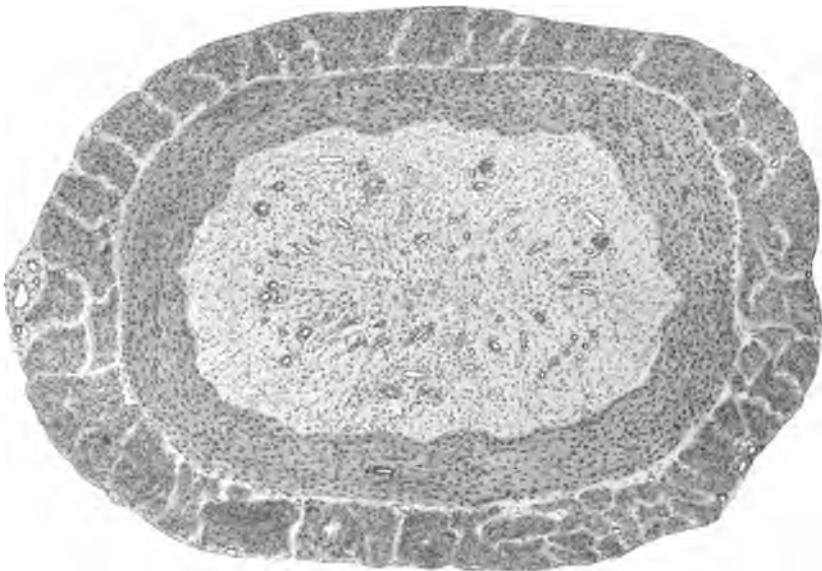


FIG. 450.—APPENDIX WITH OBLITERATION OF THE LUMEN BY FIBROUS TISSUE.

The *bacteria* most commonly found associated with the lesions of acute appendicitis and its accompanying peritonitis are *Streptococcus pyog-*

enes, *Staphylococcus pyogenes*, the *Bacillus coli communis*, *Bacillus proteus*, and *Bacillus pyocyaneus*. Mixed infections are common.¹

A case of complete inversion of the appendix into the cæcum has been reported.²

TUMORS OF THE INTESTINE.³

Fibroma and **lipoma** may be developed from the submucous coat and grow inward, or from the subserous coat and project outward into the peritoneal cavity. Small *multiple cavernous hæmangiomas* are of occasional occurrence in the submucosa of the small intestine. These tumors may be limited to the small intestine or may be found throughout the gastro-intestinal canal.⁴

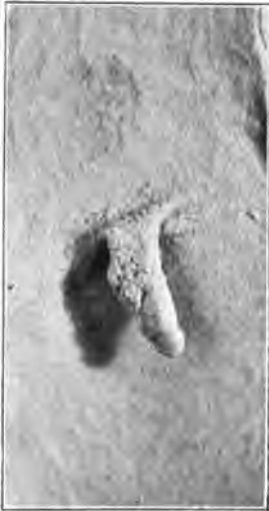

FIG. 451.—SMALL POLYP OF THE MUCOUS MEMBRANE OF THE SMALL INTESTINE.

Myoma may originate in the muscular coat and project inward, obstructing the intestine. In the duodenum such tumors may obstruct the common bile duct. Less frequently these tumors project outward into the peritoneal cavity.

Polypoid growths, projecting into the cavity of the intestine and composed of connective tissue and covered with epithelium are frequently found (Fig. 451). They are associated with catarrhal inflammation or occur by themselves. They are found throughout the intestinal tract and may be single or multiple. They grow from the submucous coat and project inward. Some of them are solid connective-tissue tumors, covered by the mucous membrane which they have pushed inward. Others are of the same character, but of large size. In others the connective tissue is arranged in branching tufts, covered with cylindrical epithelium; and in these last tumors there may also be tubules lined with cylindrical epithelium, giving to the growth the characters of an adenoma.

Lymphoma.—Growths of tissue somewhat resembling that of the lymphatic tissue of the lymph-nodes may originate in the solitary and agminated nodules, and in the intestinal wall in cases of leukæmia and pseudo-leukæmia (Fig. 452).

¹ *Hodenpfl.*, "Etiology of Appendicitis," N. Y. Med. Jour., Dec. 30th, 1893. Consult also *Kelynack*. "Pathology of the Vermiform Appendix," London, 1893; *Berry*, Jour. of Path. and Bact., vol. iii., p. 160, 1895 (bibl.); *Ribbert*, Virch. Arch., Bd. cxxxii, p. 66, 1893. For bacterial reports see *Low*, Rep. Boston City Hosp., Ser. 11, 1900, p. 173; also *Lanz* and *Tavel*, Rev. de Chir., t. ii., 1904; also *Perrone*. Ann. Inst. Pasteur, t. xix., p. 367, 1905. For comprehensive treatise see *Kelly* and *Hurdon* on the vermiform appendix.

² See *Brewer*, Am. Med., vol. ix., p. 67, 1905.

³ For a study of congenital tumors of the intestines consult *Hueter*, Ziegler's Beiträge zur path. Anat., Bd. xix., p. 391, 1896.

⁴ See *Bennecke*, Virch. Arch., Bd. clxxxiv., p. 171, 1906; also *MacCallum*, Johns Hopk. Hosp. Bull., vol. xvii., p. 258, 1906.

Similar growths are found as independent lesions both in the large and small intestines, These are irregular, diffuse growths infiltrating




FIG. 452.—"LYMPHOMATA" OF THE INTESTINE IN PSEUDO-LEUKÆMIA—HODGKIN'S DISEASE. The growths are polypoid, many are pigmented, and they were in this case widely distributed over the intestinal mucosa.

the wall of the intestine, the mesentery, and the neighboring lymph-nodules, and may reach a considerable size. They often ulcerate internally and may lead to dilatation or stenosis of the intestine. The classi-

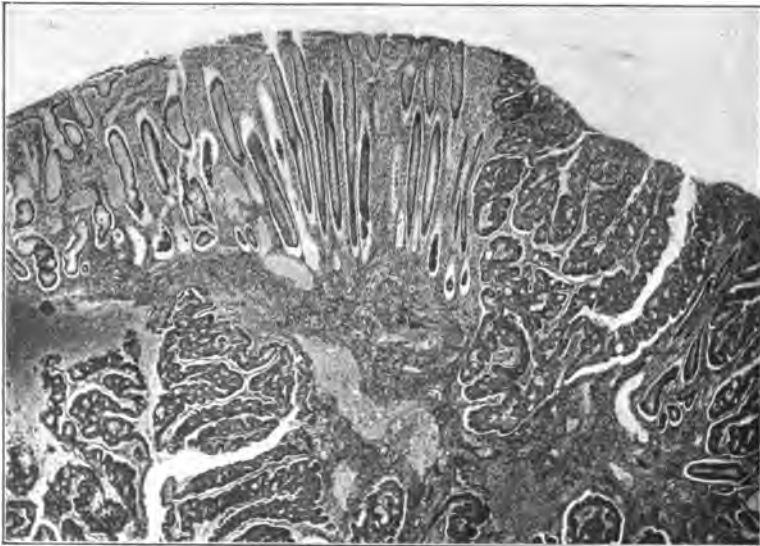


FIG. 453.—ADENOMA OF THE RECTUM.

Shows a portion of normal mucous membrane invaded by adenomatous growth. This type of tumor is frequently called Adeno-carcinoma.

fication of such tumors is difficult and it is often doubtful whether they should be grouped with the sarcoma or the so-called lymphoma.

Sarcomata are of occasional occurrence in the intestine. They appear to be more frequent in the small intestine and in the rectum than in the large intestine. While various structural types are recorded, the so-called lympho-sarcomata are most common.¹

Adenomata are found in the duodenum, colon, and rectum. They form flat infiltrations of the wall of the intestine (Fig. 453) or project inward as polypoid tumors. They are composed of tubular follicles, like those of the intestinal mucous membrane, and of a connective-tissue stroma. In some of these tumors the tubules have a regular shape and arrangement; there is no infiltration of surrounding tissue; the tumor is of benign nature. In other tumors the tubules are irregular in shape and arrangement, and the growth infiltrates the surrounding parts (Fig. 454). There is no sharp dividing line between these tumors and the carcinomata.

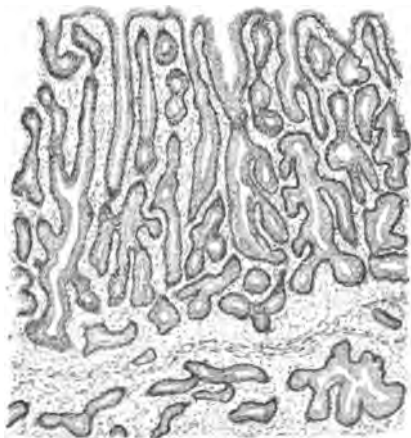


FIG. 454.—ADENOMA OF THE RECTUM. The growth has extended through the muscularis mucosae into the submucosa.

Carcinoma develops most often in the colon and the duodenum.²

The forms which have been described in the stomach occur also here, *i. e.*: 1. The *medullary forms* with relatively little stroma, and epithelial cells either in solid masses within the alveoli, or maintaining in a measure the gland type—*adeno-carcinoma*. 2. *Fibrous form*—*scirrhus*. 3. *Gelatinous forms*, which are more common here than in the stomach. Epithelioma often involves the anus and rectum.

CYSTS OF THE INTESTINE are uncommon.³

TUMORS OF THE APPENDIX are rare—**fibroma**, **lipoma**, **myoma**, **sarcoma**, **endothelioma**, and **carcinoma** are recorded.⁴ Several cases of primary carcinoma of the appendix have been observed.⁵

INTESTINAL CONCRETIONS. (Enteroliths.)

The intestines may contain round, oval, or irregular masses of firm consistence, usually small, but sometimes as large as a man's fist. They consist of faecal matter, mucus, bile, the carbonate and phosphate of

¹ For *résumé* and bibliography of sarcoma of small intestine see *Libman*, *Am. Jour. Med. Sciences*, vol. cxx., p. 309, 1900. For bibliography of sarcoma of large intestine see *Jopson* and *White*, *ibid.*, vol. cxxii., p. 807. For a *résumé* with bibliography of melano-sarcoma of the rectum see *Wiener*, *Ziegler's Beiträge*, Bd. xxv., p. 322, 1899.

² See *Rolleston*, *Lancet*, vol. i., p. 1121, 1901.

³ See *Ayer*, *Am. Jour. Med. Sci.*, vol. cxxxi., p. 89, 1906.

⁴ For bibliography of tumors of the appendix see *Kelly*, *Proc. Path. Soc. of Phila., N. S.*, vol. iii., p. 109, 1900.

⁵ *Whipham*, *Lancet*, 1901, vol. i., p. 319. *Jessup*, *Med. Rec.*, vol. lxii., p. 289, 1902. *Moschcowitz*, *Ann. of Surgery*, June, 1903, bibl. *Norris*, *Bull. Univ. Penna.*, xvi., 1903, p. 334. *Baldauf*, *Albany Med. Annals*, Dec., 1905. *McWilliams*, *Med. and Surg. Rep., Presbyt. Hosp. N. Y.*, viii., 1908.

lime, and triple phosphate. They may induce inflammations, ulceration, and perforation. Small brown concretions—*intestinal sand*—may be found.

PARASITES.

Anthrax Infection of the Intestine (Mycosis Intestinalis).—The anthrax bacillus may lodge in the intestinal mucosa either through food containing the germ or by metastasis through the blood from some infective focus, especially the skin.

The intestinal lesions are most apt to occur in the small intestines and in the upper part of the colon. The mucous membrane is studded with larger and smaller brown or black, frequently elevated patches, or areas of local congestion, or hæmorrhage, or necrosis. The mucous membrane near the inflammatory and necrotic foci may be œdematous. Hyperplasia of the spleen and lymph-nodes is apt to accompany the intestinal anthrax. The anthrax bacillus may be found about the seat of local lesion in the intestine, in the associated lymph-nodes; and when secondary to local infection elsewhere it may be found in the primary lesion and in the blood.

It is believed that other forms of bacteria may cause intestinal lesions somewhat similar to those of anthrax, but the researches in this direction are not yet sufficiently numerous to permit of very definite statements.¹

ACTINOMYCOSIS OF THE INTESTINE.

Actinomycosis involving the intestine is rare, but is most often found in the cæcal region. Several cases of primary actinomycosis of the appendix are recorded.²

The *animal parasites* of the gastro-intestinal canal have been already considered in another part of this book.

The Peritoneum.

Malformations.

Arrest in development of the peritoneum may be manifested in fissures in the mesial line or external to it; in absence of the diaphragm; in fusion with the pleura; and in incomplete formation of the mesentery, the omentum, and the other folds of the peritoneum.

Excess of development occurs in the shape of unusual length of the mesentery, the omentum, and the other folds of the peritoneum; or of supernumerary folds and pouches. These are chiefly found in the hypogastric, iliac, and inguinal regions and near the fundus of the bladder. There may be access to these sacs by a well-defined fissure or ring, which is frequently surrounded by a tendinous band lying in the duplication. These may give rise to internal incarceration of the intestines.

The left half of the diaphragm may have an abnormally high position with upward displacement of the abdominal viscera, particularly the stomach, on the left

¹ For reference to intestinal bacteria see pp. 214 and 681.

² For bibl. see *Burnham*, Johns Hop. Hosp. Bull., vol. xv., p. 136, 1904.

side, and displacement of the heart to the right. This has been called eventration of the diaphragm. It may be mistaken in diagnosis for diaphragmatic hernia.¹

HÆMORRHAGE.

Large hæmorrhage into the peritoneal cavity may result from injuries to the abdominal viscera, ruptured aneurism, etc. Punctate hæmorrhages may accompany various acute infections and toxæmias. Hæmorrhage may occur in acute localized or general peritonitis, in obstruction of the portal circulation, in thrombosis and in embolism of the mesenteric vessels.

ASCITES.

The collection of transudate in the peritoneal cavity may accompany chronic venous congestion, especially with obstruction of the portal circulation in cirrhosis from thrombi, emboli, etc., or with chronic heart and kidney diseases. It often accompanies similar conditions in the pleura and pericardium. It may accompany chronic peritonitis.

Chylous ascites may result from a rupture of the thoracic duct or from a transudation from the chyle vessels.²

Chyliform Ascites.—Most frequently in abdominal carcinoma and tuberculosis, but also in other forms of chronic peritonitis with serous exudate, the peritoneal cavity may contain fluid, milky from cell detritus and fat derived from the disintegration of degenerated mesothelial and other cells. This condition is called *chyliform ascites*.

INFLAMMATION. (Peritonitis.)

Acute Peritonitis.—Acute inflammation of the peritoneum may occur as a primary process, but is much more often secondary. In the latter case it may be associated with wounds and contusions of the wall of the abdomen; wounds, ulcers, new growths, incarceration, intussusceptions, ruptures, perforations, and inflammations of the stomach and intestines; inflammation of the vermiform appendix; injuries, ruptures, and inflammations of the uterus, ovaries, and Fallopian tubes; rupture and inflammation of the bladder; inflammation of and about the kidneys; abscesses and hydatid cysts of the liver; inflammation of the gall-bladder and large bile ducts; thrombosis of the portal vein; inflammations of the spleen, pancreas, lymphatic glands, retroperitoneal connective tissue, vertebræ, ribs, and pelvic bones; pyæmia and other infectious diseases. The inflammation is at first either local or general. A local peritonitis may remain circumscribed, or it may spread and become general.

We may distinguish two anatomical forms of acute peritonitis.

1. **CELLULAR PERITONITIS.**—This form of peritonitis may be induced by any irritant which does not act too energetically. It can be excited

¹ See *Sailer and Rhein*, Amer. Jour. Med. Sci., cxxix., p. 688, 1905.

² For a study of milky fluids in serous cavities consult *Shaw*, Jour. Path. and Bact., vol. vi., p. 339, 1900, bibl.

in dogs by intraperitoneal injections of very small quantities of a solution of chloride of zinc. In the human subject we find it with perityphlitis, with circumscribed abscesses in the peritoneal cavity, in puerperal fever, and in other infectious diseases with early death.

At the autopsy the entire peritoneum may be congested; but there are no exudates and no other lesions visible to the naked eye. Minute examination, however, shows a very marked change in the mesothelial (endothelial) cells. These are increased in size and number and the new cells coat the surface of the peritoneum and project outward in little masses (Fig. 455). This form of inflammation, in many cases, at least if

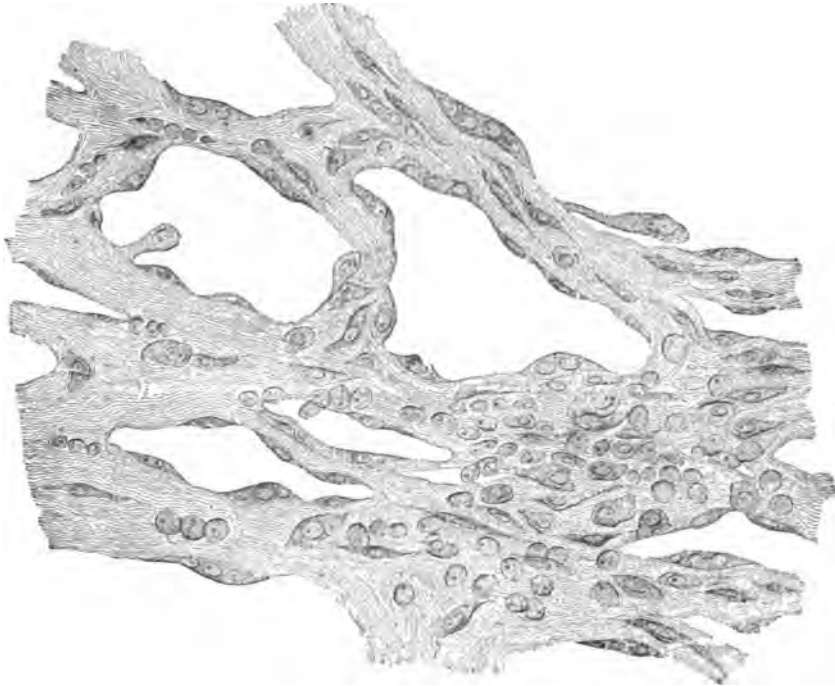


FIG. 455.—ACUTE CELLULAR PERITONITIS—HUMAN OMENTUM.

There are swelling and proliferation of the mesothelial cells as well as of the cells of the fibrillar tissue forming the omental trabeculae.

life be prolonged, passes into the exudative phase, next to be considered.

2. EXUDATIVE PERITONITIS.—This, which is the common form of acute peritonitis, presents lesions similar to those which have been already described in pleuritis and pericarditis. Thus there is a form in which fibrin is the chief exudate with but little serum; or the exudate is sero-fibrinous, or purulent, or hæmorrhagic.¹ When fibrin is present, the intestinal coils may be more or less firmly adherent to the abdominal

¹ For a study of the forms of cells in exudative peritonitis see *Lossen*, Deut. Arch. klin. Med., Bd. xxxvi., p. 217, 1906.

walls or to each other. If putrefactive bacteria be present, as in peritonitis from perforation of the intestine, the exudate may be foul.

In local inflammation of the peritoneum the position may be indicated by the name, thus perihepatitis, perisplenitis, perityphlitis, pelvic, subphrenic, etc.

Acute exudative peritonitis may terminate in recovery with absorption of the exudate, permanent connective-tissue adhesions and thickenings of the peritoneum often remaining. Chronic peritonitis may follow the acute phase.

Bacteria are the usual excitants of acute exudative peritonitis. In primary forms of peritonitis the Streptococcus and Staphylococcus pyogenes are the bacteria most frequently present.

In secondary exudative peritonitis the pyogenic cocci and the colon bacillus have been most frequently found. Of the other bacteria which have been found in the exudate we may name the pneumococcus, the gonococcus,¹ *B. pyocyaneus*, *B. proteus*, *B. aërogenes capsulatus*, *B. typhosus*.

There is abundant evidence that bacteria can pass from the intestinal cavity through its wall into the peritoneum without perforation, especially in regions where the integrity of the tissues is impaired by disturbances in circulation and nutrition, or in necrosis, as in strangulation of the gut.²

ABSORPTION FROM THE PERITONEUM.—In connection with inflammation, recent studies which have been made of the absorption of alien substances injected into the peritoneal cavities of animals, especially rabbits and guinea-pigs, are of extreme interest and importance. Living bacteria as well as various kinds of inert particles may be rapidly disposed of through the action of the body fluids or phagocytic cells. The studies of Buxton and Torrey³ indicate that after an intraperitoneal injection of suspensions of inert particles there may be an immediate rush of these to the lymphatics of the diaphragm, whence they are carried almost immediately by the anterior mediastinal lymph-trunks through the lymph-nodes to the thoracic duct and general circulation. In the earlier stages the transported particles may be free, but later may be taken up by phagocytes in the mediastinal lymph-nodes. But the omentum appears to be of significance in the disposal of inert particles injected into the peritoneal cavity. Buxton and Torrey show that almost immediately after the injection of such particles in the guinea-pig, fibrin is formed on the surface of the omentum in which the particles and phagocytic cells become entangled. The phagocytes taking up the particles may then enter the tissues. These observers have furthermore shown that after intraperitoneal injections of typhoid bacilli in the rabbit, the bacilli may become fixed upon the surface of the omentum where they may be destroyed.⁴

Chronic Peritonitis may follow the acute exudative form or may occur independently. The lesions vary. In one group of cases the peritoneum

¹ See *Cushing* on gonococcus peritonitis, Johns Hopkins Hosp. Bull., vol. x., p. 75, 1899.

² Consult for studies and bibliography of various phases of peritonitis *Tavel* and *Lanz*, "Peritonitis," Mitth. a. kl. u. med. Inst. d. Schweiz, 1 Reihe, Heft 1, p. 1, 1893; *Silberschmid*, *ibid.*, Heft 5, p. 432; *Flechner*, Phila. Med. Jour., November 12th, 1898; *Cullen*, Johns Hopkins Hosp. Rep., vol. iv., p. 411, 1895; *Abramow*, Ziegler's Beitr., Bd. xxiii., p. 1, 1898; *Bullner*, *ibid.*, Bd. xxv., p. 453, 1899.

For special studies on the entrance of micro-organisms into the body from the gastro-intestinal canal see *Opitz*, Zeits. f. Hygiene, Bd. xxix., p. 505, 1898; *Birch-Hirschfeld*, Ziegler's Beitr., Bd. xxiv., p. 304, 1898; *Buchbinder*, Deut. Zeits. f. Chir., Bd. lv., H. 6 and 7, 1900; *Marcus*, Zeits. f. Heilk., Bd. xx., p. 427, 1899; also Wiener klin. Woch., p. 11, 1901; *Ravenel*, Jour. Med. Res., vol. x., 1903, p. 460.

³ *Buxton* and *Torrey*, Jour. Med. Res., vol. xv., p. 5, 1906.

⁴ For a study of the local accumulation of eosinophile leucocytes after intraperitoneal injections of bacteria see *Opie*, Trans. Assn. Amer. Phys., vol. xix., p. 136, 1904.

is beset with minute translucent nodules, sometimes visible, sometimes invisible to the naked eye. These are apparently formed by a local proliferation of the mesothelial and connective-tissue cells. Associated with this there may be a general irregular proliferation of the peritoneal mesothelium. This has been called *chronic cellular peritonitis*.

In other cases there are local or general fibrous adhesions, sometimes firm, sometimes loose, between the intestinal coils or between the intestine and the abdominal wall or the viscera (Fig. 456). In this way sacculated collections of sero-fibrinous or purulent exudate may form in



FIG. 456.—OLD PERITONEAL ADHESIONS BETWEEN THE UNDER SURFACE OF THE LIVER AND THE INTESTINE.

L is the liver turned over to expose the inferior surface. Many delicate fibre cords and bands pass from the liver to the intestine, I. The gall-bladder, G. B., is distended.

the abdominal cavity. Finally chronic peritonitis may result in a dense fibrous thickening of the peritoneum, either local or widespread.

In some cases the parietal peritoneum is principally involved; in others the peritoneum of the stomach, intestines, liver, and spleen. The thickening of the capsule of the liver may be attended with a diminution in the size of that viscus. There may or may not be adhesions; serous or other exudate may be present. Great distortion of the omentum, mesentery, and other abdominal viscera may occur.

Tuberculous Peritonitis may occur in acute general miliary tuberculosis or it may be secondary to tuberculous inflammation elsewhere, as in the lungs or genito-urinary organs or intestines; or it may be an independent process. The process may be local or general in the peritoneum

The lesions may be miliary in character (Fig. 457) or there may be large foci of the new-formed tubercle tissues with considerable necrosis. There may be more or less serous or sero-fibrinous or purulent or hæmorrhagic exudate. Fibrous adhesions may form between the intestinal coils and the peritoneal walls with the encapsulation of exudate. Ulceration of the tubercle tissue may occur, or it may become dense and fibrous and is then

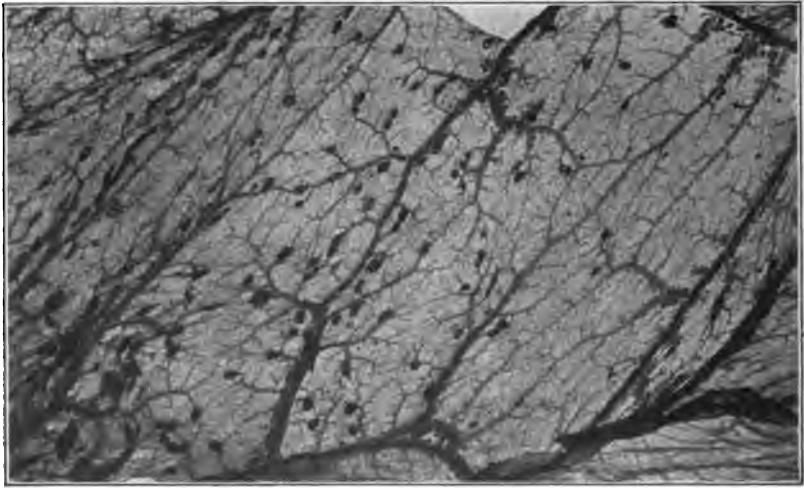


FIG. 457.—MILIARY TUBERCLES OF THE OMENTUM.

often pigmented. The tuberculous inflammation may be limited to the vicinity of tuberculous ulcers of the intestine. It may involve the omentum, which is converted into a hard, thick, dense mass at the upper part of the abdominal cavity.¹

TUMORS.

Fibromata are developed from the subperitoneal connective tissue and project inward into the peritoneal cavity. They are found beneath the parietal peritoneum and that covering the intestines. Such tumors may reach a very considerable size. *Papillary fibromata* of the peritoneum (Fig. 458) may be secondary to papillary fibroma of the ovary.

Lipomata.—Circumscribed tumors composed of fat tissue are formed beneath the intestinal and parietal peritoneum and in the mesentery. These tumors may become changed into fibrous tissue or calcified. Their pedicles may become atrophied so that they are left free in the peritoneal cavity.

When they grow beneath the parietal peritoneum they may form fat

¹ For bibliography with reference to operative treatment see *Bottomley*, Reports Boston City Hosp., ser. 11, p. 118, 1900. For a full critical summary of the literature of peritonitis from 1885 to 1900 see *Brunn*, Centralbl. f. Path., Bd. xii., pp. 1, 65, 1901.

herniæ. At the umbilicus, in the inguinal canal, along the vas deferens, in the crural ring, and in the obturator foramen, fatty tumors may grow, project outward under the skin like herniæ, and, by drawing the peritoneum after them into a pouch, may open the way for a future intestinal hernia. Very large retroperitoneal and perirenal lipomata are of occasional occurrence.¹ **Myxoma, chondroma, osteoma, and angioma** are recorded.

Retroperitoneal **sarcomata** are found both in children and adults. They usually originate behind the peritoneum, covering the posterior

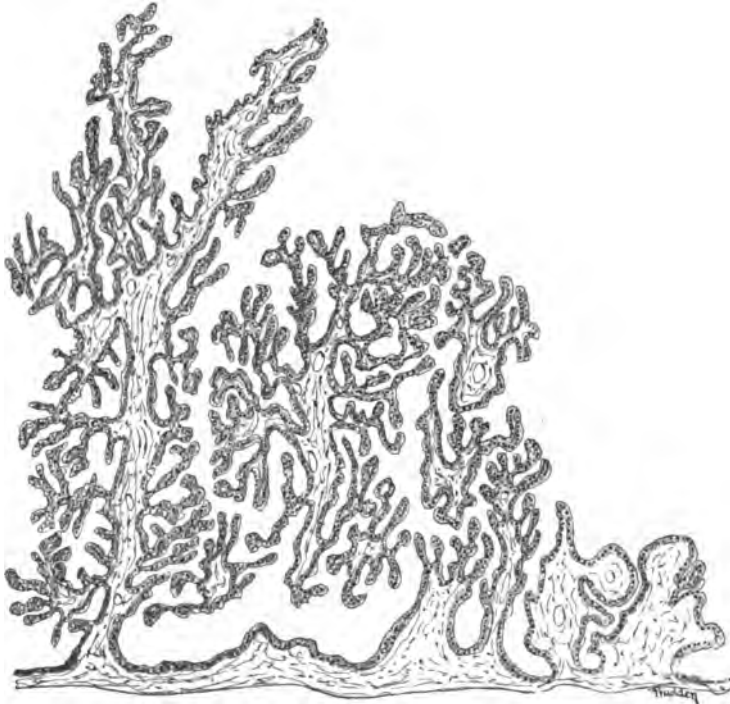


FIG. 458.—PAPILLARY FIBROMA—PAPILLOMA—OF PERITONEUM.

This growth was secondary to a similar tumor originating in the ovary and connected with that organ (see Fig. 565). Detached portions of the original tumor were transplanted to various regions of the peritoneum.

part of the abdominal wall, and may grow between the folds of the mesentery.²

They may be of the small spheroidal-celled type (lympho-sarcoma) or of the fusiform-celled type. They are often very vascular. At first they grow slowly inward, pushing forward the peritoneum and abdominal viscera. After a time they assume a more noxious character, infiltrating the soft parts with which they come in contact, and forming metastatic

¹ For bibliography of such tumors see *Adami*, *Montreal Med. Jour.*, vol. xxv., pp. 529, 620, 1897.

² For a study of the retroperitoneal lymph-nodes and retrograde metastases from the thorax into the abdomen of bacteria, dust, and tumor cells see *Tendeloo*, *Munch. med. Woch.*, p. 1537, 1904.

tumors in the omentum, mesentery, intestinal wall, liver, lungs, and in other viscera.¹

Endotheliomata similar in structure to those originating in the pleura are of occasional occurrence in the peritoneum. They may form single



FIG. 459.—CYSTIC PAPILOMA OF THE OMENTUM.
Secondary to papilloma of the ovaries.

well-defined tumors or flattened masses in the thickened peritoneum. Cuboidal or polyhedral cell masses often grouped along the side of anas-

¹ See for bibliography *Steele*, *Am. Jour. Med. Sci.*, vol. cxix., p. 311, 1900.

For a study of sarcoma and mixed tumors of the greater omentum see *Conforti*, *Centralbl. f. Path.*, Bd. xvii., p. 817, 1906.

tomosing channels in the new-formed or old connective-tissue stroma sometimes lend a glandular appearance to the type of growth.

These tumors apparently originate in the true endothelium of the subperitoneal lymph-channels and not in the flat cells often called endothelial—mesothelium—lining the peritoneum.

Carcinoma of the peritoneum is usually secondary to this disease in adjacent regions, stomach, liver, uterus, etc. Its structural characters correspond with those of the primary growth. It is apt to appear in the form of numerous larger and smaller whitish nodules, sometimes local, sometimes widely disseminated over the peritoneal surfaces. Such tumors, when small and numerous, may readily be mistaken for tubercles.

Gelatinous carcinoma is not infrequent and sometimes seems to be primary in the peritoneum. But in such cases the possibility of an origin in the mucous membrane of the colon, in which such growths are common, and the extension outward without evidence of growth in the gut, is always to be considered. Gelatinous cancer often forms large masses, which widely involve the peritoneum and distend the cavity.

Various forms of tumors of the umbilicus have been described.¹

CYSTS.

Cysts of the mesentery are of occasional occurrence.² They may be filled with chyle, with blood, or with serous fluid, or may be due to the echinococcus.

Multiple *cysts of the omentum* may form by transplantation of papillary cyst-adenomata from the ovary (see Fig. 459).³

Dermoid cysts may be found in the peritoneal cavity. Retroperitoneal cysts have been a few times recorded.

PARASITES.

Echinococci can be formed in their regular way at any part of the visceral and parietal peritoneum, or be free in the peritoneal cavity. These cysts may be small, or so large as nearly to fill the abdominal cavity.

Cysticercus cellulosa may also be developed in the subperitoneal connective tissue.

The Salivary Glands—The Parotid, Submaxillary, and Sublingual.

INFLAMMATION.

Acute Parotitis, occurring as an epidemic disease known as *mumps*, is usually confined to the parotid gland of one side; the submaxillary and sublingual may be at the same time involved. The gland is swollen and

¹ See *Giannettasio*, Arch. gén. de Méd., t. iii., p. 52, 1900.

² For bibliography of cysts of the mesentery see *Dowd*, Annals of Surgery, vol. xxxii., p. 461, 1900; also *Ayer*, Am. Jour. Med. Sci., vol. cxxxi., p. 89, 1906.

³ For bibliography of cysts of the omentum see *Jacobi*, Trans. Assn. Am. Phys., vol. xvi., p. 232, 1901.

there is often œdema of the mucous membrane of the mouth and pharynx. Very little is known of the minute changes which the gland undergoes in this disease.

Suppurative Parotitis may occur as a secondary lesion in many diseases, typhoid and scarlet fever, pyæmia, pneumonia, etc., and by bacterial invasion or extension of inflammation from the mouth. Under these conditions the process is usually suppurative and frequently results in abscess or sloughing. The interstitial tissue of the gland is more or less densely infiltrated with pus cells, and the parenchyma cells may undergo fatty degeneration and disintegration. The inflammation may be confined to the gland or it may spread to adjacent parts, sometimes causing much destruction of tissue, and may give rise to inflammation of the brain or of the inner ear, or even to metastatic pyæmic abscesses in different parts of the body. Healing may occur, with formation of salivary fistulæ.

The **submaxillary gland** may be involved with the parotid in the suppurative inflammation. Acute suppurative inflammation of the connective tissue about the submaxillary gland is sometimes of serious import. Sloughing and gangrene may occur and are apt to spread to adjacent parts. Septicæmia, œdema of the glottis, or pneumonia may complicate the process and cause death.

The **sublingual gland** is not often the seat of inflammation.

Chronic inflammation, leading to the formation of dense interstitial tissue, sometimes occurs in the salivary glands. This may occur by itself or follow an acute inflammation. *Tuberculous inflammation* of the parotid is not infrequent.¹

The **excretory ducts** of the salivary glands may become inflamed from the presence of foreign bodies or of concretions formed in them. They may become occluded from the presence of calculi or as the result of inflammation, and may thus become widely dilated both in the main branches and in the finer ramifications. The dilatation of Wharton's duct to form larger and smaller cysts containing salivary fluid sometimes gives rise to very large and troublesome tumors which constitute one of the forms of *ranula*.²

TUMORS OF THE SALIVARY GLANDS.

Fibromata are of occasional occurrence in the parotid. **Chondromata**, **endotheliomata**, **sarcomata** and **fibro-sarcomata**, and **myxomata**, or more frequently mixed tumors formed of various combinations of these, are of frequent occurrence in the parotid and of occasional occurrence in the submaxillary gland. These complex or mixed tumors are of more frequent occurrence in these glands than in any other part of the body, except possibly the ovary. They are sometimes rendered still more complicated in structure by the formation of cysts, and what has been

¹ Consult *Meslay and Parent*, Gaz. des Hôpitaux, Feb. 11th, 1899, bibl.; also *Wood*, Bull. Univ. Penna., vol. xvi., 1903, p. 368.

² For bibliography of lesions of the salivary glands see *Thorel*, Lubarsch and Ostertag's "Ergebnisse," Jahrg. v for 1898, p. 221.

regarded usually as an atypical glandular growth, lending them an adenomatous character (Fig. 460). Earlier studies upon the mixed tumors of the salivary glands led to the belief that a large part of these complex growths are endotheliomata, especially prone in these regions to undergo secondary degenerative or metaplastic changes.¹ The mixed parotid tumors differ in many respects from those elsewhere in the body and in ways which suggest an origin in congenital malformations. More recent

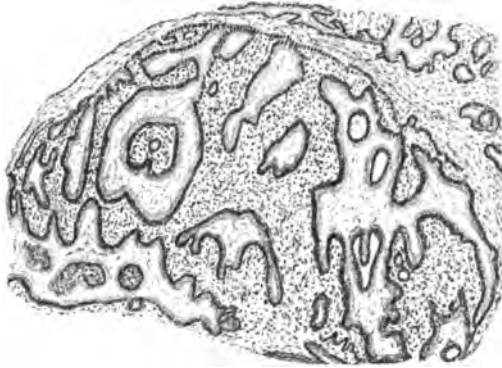


FIG. 460.—ENDOTHELIOMA OF THE PAROTID.

studies indicate that many cell forms formerly interpreted as endothelial are epithelial.² The present view is that these complex tumors of the parotid and other salivary glands are probably largely of epithelial origin, starting in congenital abnormalities about the branchial arches.

Fibro-sarcoma and **melano-sarcoma** have been described.

A case of **rhabdomyoma** of the parotid gland, with evidences of atypical development of portions of the gland, has been described.³ **Primary carcinoma** of these glands is rare.

The Pancreas.

Malformations and Displacements.

The pancreas may be entirely absent in acephalous and double monsters. The pancreatic duct may be double; it may open into the duodenum at some distance from the biliary duct, or into the stomach. The head of the pancreas may be unduly developed and sometimes even completely separated from the rest of the organ, opening into the duodenum with a duct of its own. The gland may be variously lobed and distorted. Occasionally there is a small accessory pancreas situated beneath the serosa of the duodenum or stomach.

The pancreas is so firmly bound down that its position is not often changed. Sometimes, however, it is found pressed downward by tight lacing, displaced by aneurisms, or contained in umbilical and diaphragmatic herniæ.

¹ *Volkman*, *Deutsche Zeits. f. Chir.*, Bd. xli., p. 61.

² For a critical study of the mixed tumors of the salivary gland see *Wood*, *Ann. of Surgery*, vol xxxix., 1904, p. 57, bibl. See also *Krompecher*, "Basalzellenkrebs," 1903.

³ *Prudden*, "Rhabdomyoma of the Parotid Gland," *Am. Jour. of the Med. Sci.*, Apr., 1883.

ATROPHY, DEGENERATION, AND NECROSIS.

Atrophy of the pancreas may occur in old age and as a result of pressure from tumors or other adjacent structures, and may be associated with fatty infiltration. It occurs in a certain proportion of cases of diabetes mellitus.

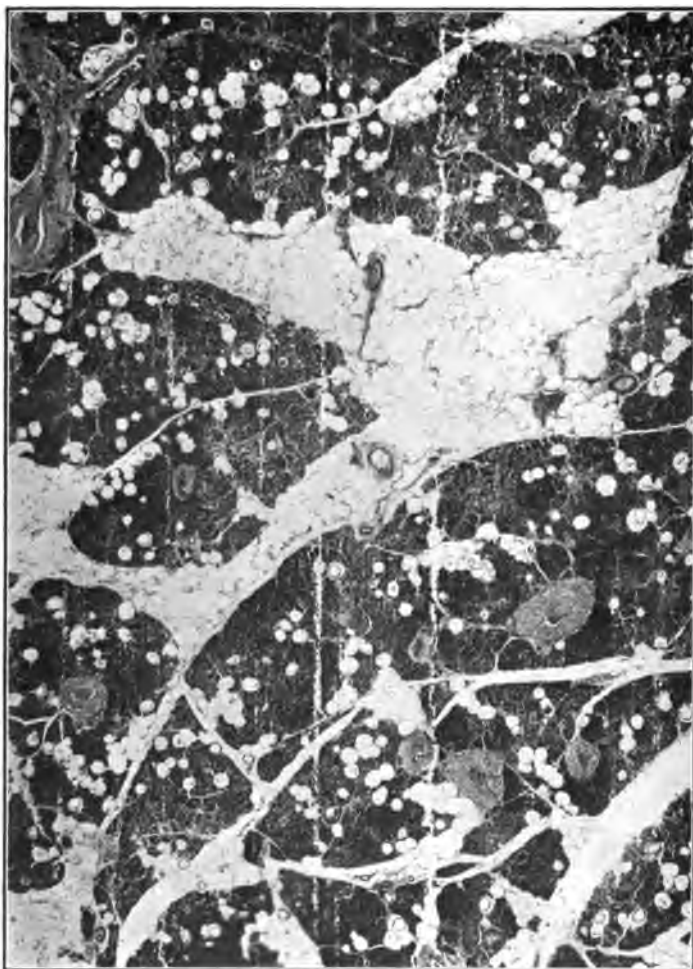


FIG. 461.—FATTY INFILTRATION WITH ATROPHY OF THE PANCREAS.

Auto-digestion of portions of the pancreas, *intra vitam*, has been described, and may, it is believed, lead to localized formation of fibrous tissue in the organ.¹

¹ Chiari, Prager med. Wochenschrift, vol. xxv., No. 14, 1900.

Albuminous Degeneration may occur in acute infectious diseases. The organ may be red, swollen, and œdematous. The most marked minute lesions are swelling and albuminous degeneration of the gland epithelium with hyperæmia and interstitial œdema.

Fatty Degeneration may follow albuminous degeneration and is most common in poisoning, especially by phosphorus.

Fatty Infiltration, which should be distinguished from fatty degeneration, consists in the accumulation of fat in the interstitial tissue of the

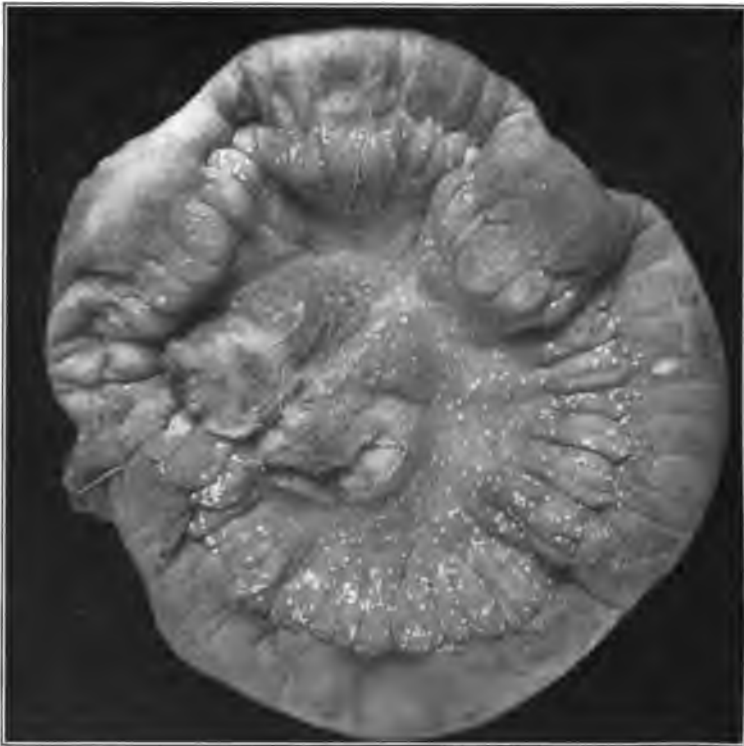

FIG. 462.—FAT NECROSIS IN THE MENENTERY.

From a case of acute hæmorrhagic pancreatitis.

gland (Fig. 461). This when excessive may be associated with almost complete atrophy of the gland structures. Under these conditions the outline of the organ may be preserved, the fat being enclosed by the capsule. It occurs in obesity and in atrophy and fibrosis of the gland.

Amyloid Degeneration.—This usually occurs in connection with similar degeneration in other organs, and is confined to the walls of the blood-vessels and the interstitial tissue.

Hyaline Degeneration, involving and limited to the islands of Langer-

hans, has been described by Opie and others in diabetes without other marked lesions of the pancreas.¹

Fat Necrosis.—This is a peculiar lesion of the fat tissue, most frequently seen about the pancreas or between its lobules, but sometimes in fat tissue in other parts of the body. White or yellowish nodules (Fig. 462), varying from the size of a pin's head to that of a pea or larger, are seen embedded in the fat, the central portion being often soft and grumous. They are sometimes calcified and sometimes surrounded by a connective-tissue capsule. Microscopical examination shows necrosis, degeneration, and disintegration of the fat tissue (Fig. 463).

Fat necrosis is usually associated with lesions of the pancreas—hæmorrhagic infiltration, necrosis, gangrene, and acute and chronic

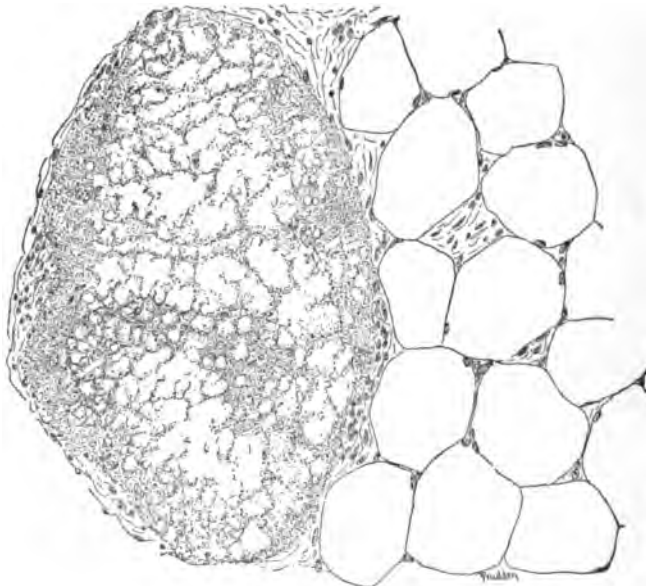


FIG. 463.—FAT NECROSIS IN THE PANCREAS.

inflammatory processes. The lesion has been shown to be due to some ferment in the pancreatic secretion which splits the fat molecule into fatty acids, which may crystallize, and soluble substances; calcification is of later occurrence. Experimental studies have shown that fat necrosis can be induced by such operative procedures as direct the pancreatic secretion into fat tissue either immediately about the pancreas or elsewhere.²

¹ *Opie*, *Jour. Exp. Med.*, vol. v., p. 527, 1901; also *Opie*, "Disease of the Pancreas," in which may be found bibliography of structure, function, and lesions of the pancreas. For a study of the development of the islands of Langerhans in human embryo see *Pearce*, *Am. Jour. Anat.*, vol. ii., 1903, p. 445. For a study of the morphology and physiology of these structures see *Dewitt*, *Jour. Exp. Med.*, vol. viii., p. 193, 1906. For a study of hypertrophy of the islands of Langerhans see *MacCallum*, *Amer. Jour. Med. Sci.*, vol. cxxxiii., p. 432, 1907.

² For studies in fat necrosis, with bibliography, see *Opie*, "Disease of the Pancreas"; also *Wells*, *Jour. Med. Research*, vol. ix., p. 70, 1903.

HÆMORRHAGE.

Hæmorrhage into the substance of the pancreas may occur as the result of injury; in the hæmorrhagic diathesis; in connection with valvular diseases of the heart or interference with the portal circulation; or in connection with extensive fatty degeneration, or with local necrosis, or with fat necrosis of the organ. Such hæmorrhages may be minute or extensive. Several cases of sudden death are recorded in which the only discoverable lesion was an extensive hæmorrhage into the substance of the gland and the tissue about it. The hæmorrhage may be moderate and limited to the pancreas, or it may extend into the subperitoneal tissue for a considerable distance.

Hæmorrhage of the pancreas may be associated with acute inflammatory changes and with more or less extensive *gangrene* of the organ.¹

INFLAMMATION. (Pancreatitis.)

Hæmorrhagic Pancreatitis.—In this form of disease hæmorrhage similar to that above described is associated with suppurative inflammation or gangrene or both. The gangrenous pancreas may be more or less encapsulated; it may be surrounded by pus. Hæmorrhagic pancreatitis is often associated with fat necrosis.

The conditions leading to pancreatic hæmorrhage and hæmorrhagic pancreatitis are not yet fully clear, but experimental studies of Flexner and Opie indicate that in some cases at least the presence of gastric juice or of bile or other substances in the pancreatic duct may be of importance. The frequent association of gall-stones with hæmorrhagic pancreatitis is significant.²

Suppurative Pancreatitis is not very common, and may be primary or due to the extension of a suppurative inflammation from adjacent or distant parts of the body. There may be a diffuse infiltration of the organ with pus cells or larger and smaller abscesses. The abscesses may open into the gastro-intestinal canal or into the peritoneal cavity. The causes of primary suppurative pancreatitis are often obscure. It may accompany fat necrosis and hæmorrhage and gangrene of the pancreas. It is probably usually due to bacterial invasion through the duct.

Various forms of bacteria have been found in the necrotic, hæmorrhagic, and inflammatory lesions of the pancreas, but in most cases the significance of their presence is not clear, since necrotic and hæmorrhagic foci may afford regions favorable to the lodgment and proliferation of micro-organisms which are secondary invaders and whose lesions, if such be induced, are complicating and not primary.³

¹ For a study of Hæmorrhagic Necrosis of the Pancreas, see *Opie and Meakins*, Jour Exp. Med., bibl. xi., 561, 1909.

² For a study of the relationships between cholelithiasis and diseases of the pancreas see *Opie*, "Disease of the Pancreas."

For a study of experimental pancreatitis see *Fleener*, University Medical Magazine, vol. xiii., p. 780, 1901; and Jour. Exp. Med., vol. viii., p. 167, 1906; also *Fleener and Pearce*, Trans. Assn. Am. Phys., vol. xvi., p. 348, 1901; also *Opie, loc. cit.*

³ For a detailed consideration of acute inflammation, hæmorrhage, gangrene, and fat necrosis of

Chronic Interstitial Pancreatitis.—This lesion consists in an increase of interstitial connective tissue, which may be general or confined to some particular portion of the gland. The new-formed tissue may be interlobular or interacinar in distribution.

The organ is sometimes enlarged, sometimes smaller than normal. It is usually dense and hard; secondary atrophy of the parenchyma regularly occurs. It may be associated with chronic inflammatory processes in the vicinity of the organ, and obstruction of the pancreatic duct. It may accompany cirrhosis of the liver.¹

Tuberculous Inflammation.—Larger and smaller tubercles and tuberculous cheesy nodules are occasionally found in the pancreas in connection with acute general miliary tuberculosis or with tuberculous inflammation in some other organ, particularly with that of adjacent lymph-nodes, the lungs, and the intestine.

Syphilitic Inflammation.—Chronic interstitial pancreatitis is frequently found in congenital syphilis of the new-born. The fibrous tissue is increased with atrophy of gland parenchyma, but the islands of Langerhans persist.² It is not definitely established whether or not a similar lesion may be caused by acquired syphilis. Gummata are very rare in the pancreas, but have been described in congenital syphilis in very young children.

TUMORS.

Carcinoma is the most common and important of the tumors of the pancreas. It may be primary or secondary. Primary carcinoma is most frequent in the head of the organ, but may occur in other parts.³ The scirrhus form is most common, but soft and gelatinous forms are found. They often involve adjacent parts by continuous growth, and may form metastases in the liver, adjacent lymph-nodes, etc. Secondary carcinoma in the pancreas may occur in carcinoma of the stomach and duodenum, and of the gall-ducts and gall-bladder. As a result of carcinoma of the pancreas, aside from the extension of the growth, there may be pressure on the ductus choledochus, with jaundice; or on the pancreatic duct, with cystic dilatation; or pressure on the duodenum, with stenosis of the gut; or pressure on the vena cava, or portal vein, or superior mesenteric vein, etc., with disturbances of the circulation.

Adenoma and **sarcoma** are recorded.

Cysts.—These are mostly due to **dilatation** of the pancreatic ducts.

1. The entire duct may undergo a uniform cylindrical dilatation. With this cylindrical dilatation we sometimes find associated small sacculi.

2. There may be sacculated dilatations at some points in the ducts.

the pancreas, with bibliography, consult *Fitz*, Middleton Goldsmith lecture on "Acute Pancreatitis," *Trans. New York Path. Soc.*, 1889. For later bibliography see *Warthin*, *Phila. Med. Jour.*, Nov. 19th, 1898, and *Opie*, "Disease of the Pancreas."

¹ See reference to *Lando*, foot-note, p. 728.

² For a study of the pancreas in congenital syphilis see *Pearce*, *Am. Med.*, vol. vi., p. 1020, 1903.

³ For recent bibliography of primary carcinoma of the pancreas see *Baldwin*, *Phila. Med. Jour.*, Dec. 22d, 1900, *bibl.*

These dilatations form cysts of large size, as large even as a child's head. Their walls frequently undergo degeneration and calcification. These cysts often become filled with blood, and may then be mistaken for aneurisms.

3. The small branches of the pancreatic duct may be dilated so as to form a number of small cysts. These cysts are filled with serum, mucus, pus, or a thick, cheesy material.

Cysts of the pancreas may result from trauma, inflammatory closure or obstruction of the ducts, from old areas of necrosis or hæmorrhage, and in other ways.¹

Concretions of carbonate and phosphate of lime are frequently found in the pancreatic ducts. They are usually multiple, small, whitish, smooth, or of rough and irregular shape. Sometimes, however, they reach a diameter of more than an inch. They consist chiefly of calcium phosphate and carbonate. Besides these free concretions the walls of the ducts are sometimes encrusted with salts of lime. Such concretions may produce dilatation of the pancreatic ducts and large cysts, or more rarely abscesses.

Foreign Bodies.—Gall-stones sometimes find their way into the pancreatic duct. Ascarides have been found in the ducts in a considerable number of cases.

¹ Consult *Tilger*, "Cysts of Pancreas," *Virch. Arch.*, Bd. cxxxvii., p. 348, 1894, bibl.; also *Fitz*, *Trans. Assn. Am. Phys.*, vol. xv., p. 254, 1900.

CHAPTER VIII.

THE LIVER.

Malformations.

Congenital malformations of the liver are not common and are of little practical importance. The organ may be entirely wanting; the lobes may be diminished or increased in number; its form may be altered, so that it is rounded, flattened, triangular or quadrangular. The gall-bladder or gall-ducts may be wanting; the ductus choledochus may be double, both ducts emptying into the duodenum, or one emptying into the duodenum, the other into the stomach. The single ductus choledochus may also empty into the stomach. Owing to abnormal openings in the diaphragm or the abdominal parietes, the liver may suffer displacement upward or forward. In congenital transposition of the viscera the liver is found on the left side, the stomach and spleen on the right side.

Small, isolated bodies, having the same structure as the liver, have been a few times found in the suspensory ligament and in the lesser omentum.

Acquired Changes in Size and Position.

As a result of tight lacing very marked changes are sometimes produced in the shape of the liver. By the narrowing of the base of the thorax the organ is compressed from side to side, and its convex surface is pressed against the ribs. In consequence of this there are found ridges and furrows on its convex surface. In consequence also of the circular constriction, a part of the right, and usually of the left lobe also, becomes separated by a depression (Fig. 15). Over this depressed and thinned portion of the liver the capsule is thick and opaque. In extreme cases the depression and thinning reach such an extent that there is only a loose, ligamentous connection between the separated portion and the liver.

A series of depressions are sometimes found on the upper surface of the right lobe of the liver, running from front to back, apparently caused by folds of the organ.

Structural alterations in the liver may induce changes in its size and shape. It may be increased in size by tumors, hydatid cysts, abscesses, fatty and amyloid degeneration, by congestion, and sometimes by cirrhosis, etc.

It may be diminished in size by atrophy, by cirrhosis, by acute parenchymatous degeneration, etc.

Changes in the position of the liver are produced by alterations in its size, by pressure downward from the thoracic cavity and upward from the abdomen, by the constriction of tight lacing, by tumors or circumscribed serous exudation between the liver and diaphragm, by curvature of the spine.

The liver is readily turned, by pressure from above or below, on its transverse axis. The transverse colon may be fixed above the liver so as to push it backward, downward, and to the right. There are a few cases recorded of dislocated and movable livers. These occurred in women who had borne children and whose abdominal walls were lax. With ascites it is not uncommon to find the liver quite movable.¹

WOUNDS, RUPTURE, AND HÆMORRHAGE.

Wounds of the liver may induce hæmorrhage, which, if life continue, is followed by inflammation. Serious wounds of the liver are usually

¹ See *Graham*, "Displacements of the Liver," *Trans. Assn. Am. Phys.*, vol. x., p. 258, 1895, bibl.

fatal, but recovery may occur even after the destruction of a considerable portion of the organ.

Rupture of the liver may be produced by severe direct contusions or by falls. It may be produced in children by artificial delivery. The rupture usually involves both the capsule and a more or less considerable portion of the liver tissue. It is commonly accompanied by large hæmorrhage, and is usually fatal.

Hæmorrhage.—Extravasations of blood in the substance of the liver, or more frequently beneath the capsule, may be found in new-born children after tedious or forcible labors. In adults, hæmorrhage, except as the result of injury, is uncommon. Extravasations of blood are sometimes seen in malignant malarial fevers, especially in tropical climates; in scurvy, purpura, and phosphorus poisoning; and bleeding may occur in and about soft tumors, abscesses, and echinococcus cysts. It may also occur as a result of thrombosis of the hepatic vein.

ANÆMIA AND HYPERÆMIA.

Anæmia of the liver may be general or partial. It may be due to general anæmia or to local disturbances of the circulation, such as swelling of the cells in parenchymatous or other degeneration, pressure of

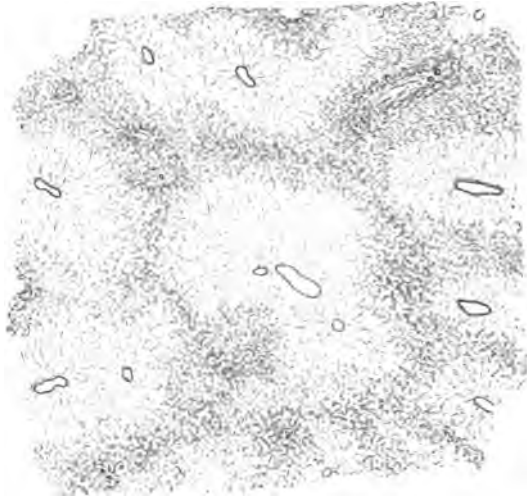


FIG. 464.—CHRONIC CONGESTION OF THE LIVER—"NUTMEG LIVER."

The liver cells are completely atrophied except in the peripheries of the lobules. The central portions of the lobules, which in the fresh organ are darker than the periphery, are lighter in the preserved specimen from which this section was cut, because the hæmoglobin has been dissolved out of the red blood cells.

tumors, etc. The organ appears pale, often of slightly yellowish or brownish color. It may be harder than usual, and smaller.

Hyperæmia of the liver is either an active or a passive process. In health the amount of blood in the liver varies at different times, being

regularly increased during the process of digestion. When the digestive process is unduly influenced by the ingestion of spirits, spices, etc., the hyperæmia assumes abnormal proportions, and when this is often repeated it may lead to structural changes in the organ. Severe contusions over the region of the liver sometimes cause a hyperæmia, which may result in suppurative or in productive inflammation. In hot climates and in malarious districts active and chronic hyperæmia of the liver are frequent and often incite structural lesions. In scurvy, also, the liver is sometimes congested. Cessation and suppression of the menses and of hæmorrhoidal bleeding may be followed by hyperæmia of




FIG. 465.—CHRONIC CONGESTION OF THE LIVER.

Showing a single lobule. The capillaries about the central vein are widely distended with blood—decolorized; the liver cells on the borders nearest the dilated capillaries show various phases of pressure atrophy.

the liver. In all these varieties of active congestion the liver is enlarged, of a deep red color, and blood flows freely from its cut surface.

Passive congestion of the liver is produced by an obstruction to the current of blood in the hepatic veins. Valvular diseases of the heart, emphysema and fibrous induration of the lungs, large pleuritic effusions, intrathoracic tumors, angular curvature of the spine, aortic aneurisms pressing on the vena cava, and constrictions of the vena cava and of the hepatic veins, may all lead to a chronic hyperæmia of the liver. In such cases, since the congestion affects principally the hepatic veins, we find the centre of each acinus congested and red, while its periphery is lighter in color. This gives to the liver a mottled or nutmeg appearance (*nutmeg liver*) (Fig. 464). The liver cells in the centre of each acinus are frequently colored by little granules of red or black pigment, and the cells at the periphery become fatty, so that the nutmeg appearance is still more pronounced. A liver in this condition is usually of medium size, but may be smaller or larger than normal.

When the congestion is long continued the veins at the centre of each acinus may become permanently dilated, and the hepatic cells in their

meshes become atrophied (Figs. 465 and 466), so that the centre of each acinus consists only of dilated capillaries or of these and new connective tissue; or the dilatation and atrophy of the liver cells may, in circumscribed portions of the organ, involve the entire acinus. In long-

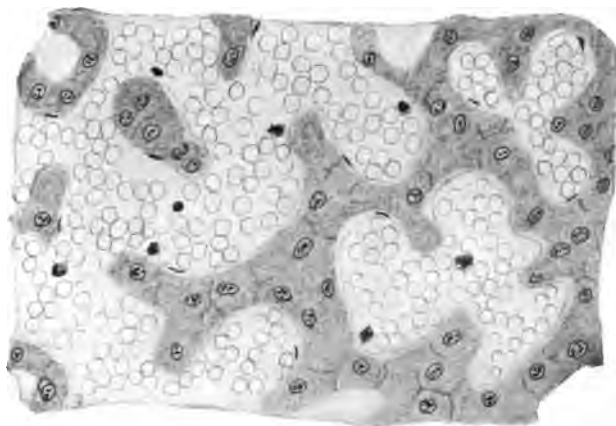


FIG. 466.—CHRONIC CONGESTION OF THE LIVER.
Showing atrophy of the liver cells.

continued congestion the liver is usually small and hard—cyanotic induration—and may be rough or uneven on the surface; but it is sometimes enlarged. The peculiar nutmeg appearance may be very well marked, or it may not be evident, the organ being of a dark-red color.

LESIONS OF THE HEPATIC VESSELS.

THE HEPATIC ARTERY.

The hepatic artery is in rare cases the seat of aneurisms which may attain a large size. Such aneurisms may displace the liver tissue, compress the bile ducts so as to cause jaundice, and may rupture into the stomach or abdomen.

Owing to its abundant anastomoses, emboli of the branches of the hepatic artery usually induce no marked lesions, but they sometimes result in single or multiple anæmic infarcts.¹

THE PORTAL VEIN.

Thrombosis, Embolism, and Inflammation.—*Thrombosis* of the branches of the portal vein may be produced by weakening of the circulation from general debility—*marasmatic thrombi*; by pressure on the vessel from without, as in cirrhosis, chronic peritonitis, tumors, gall-

¹ For a critical summary of recorded cases of anæmic infarcts of the liver see *Baldwin*, *Jour. Med. Res.*, vol. viii., 1902, p. 431. For a study of experimental closure of the hepatic artery and the gall-ducts see *Tischner*, *Virch. Arch.*, Bd. clxxv., p. 90, 1904.

stones, dilatation of the bile ducts, etc.; by injury; by the presence of foreign materials within the vessel; and as a result of inflammation, especially syphilitic, of its wall—phlebitis—or of embolus. The thrombus may form in the vessels in the liver or be propagated into them from without. It may partially or entirely occlude them. The clot may become organized as a result of endophlebitis, and a permanent occlusion of the vessel ensue. If the clot be a *simple*, non-irritating one, leading to occlusion, the consequences are usually more marked in the abdominal viscera than in the liver itself. The branches of the hepatic artery form sufficient anastomoses usually to nourish the liver tissue and prevent its necrosis, even in complete occlusion of the portal vein; and if occlusion occur slowly, the organ may continue to perform its functions. But this obliterative form of thrombosis is usually attended by ascites, enlargement of the spleen, dilatation of the abdominal veins, and sometimes by hæmorrhage from the stomach and intestines.

In another class of cases, in addition to the local and mechanical effects of a thrombus, the latter may be *infectious*, then there are necrotic changes and suppurative inflammation in the walls of the vessels or in the liver tissue about them. The thrombi are apt to soften and break down, and the fragments may be disseminated through the smaller trunks of the portal vein. In this way, by the distribution through the smaller vessels of a disintegrated thrombus from a large trunk, or by the introduction into the branches of the portal vein of purulent or septic material from some of the abdominal viscera or from wounds, multiple foci of purulent inflammation in the portal vein, and multiple abscesses involving the liver tissue, may be produced. In many cases the presence of bacteria may be detected in the inflammatory foci.

These soft thrombi of the portal vein and the accompanying pylephlebitis and abscess are induced in a variety of ways. Ulceration of the intestines and stomach, abscesses of the spleen, suppurative inflammation of the mesentery and mesenteric glands, inflammation and ulceration of the bile ducts from gall-stones, inflammation of the umbilical vein in infants, may all induce thrombi in their respective veins, which may be propagated to the portal vein or may give rise to purulent or septic emboli. Two cases are recorded in which a fish-bone in the portal vein induced suppurative inflammation in that vessel.¹

In infants inflammation of the umbilical vein may induce not only inflammation of the portal vein and abscesses in the liver, but multiple abscesses in various parts of the body, and acute peritonitis may follow.

Infarcts.—Infarcts of the liver seldom form, owing to the abundant anastomosis of its blood-vessels. But under exceptional conditions, as we have seen, *anæmic infarcts* may form as the result of the closure of the hepatic artery or also of small branches of the portal vein. There may then be a larger or smaller mass of dead liver tissue surrounded by a zone of congestive or inflammatory reaction (Fig. 467). Occasionally also, owing usually to the occlusion of branches of the portal vein, lim-

¹ For a study of primary portal thrombosis see Lewis and Rosenow, Arch. Int. Med., iii., 232, 1909, bibl.

ited areas of liver tissue may suffer disturbance of the circulation leading to atrophy of the liver cells and the formation of fibrous tissue. This condition has been called *hæmorrhagic atrophic infarction*. It is apparently rather localized atrophy of the liver than true infarction.

It is probable that the rare occurrence of hepatic infarcts is closely

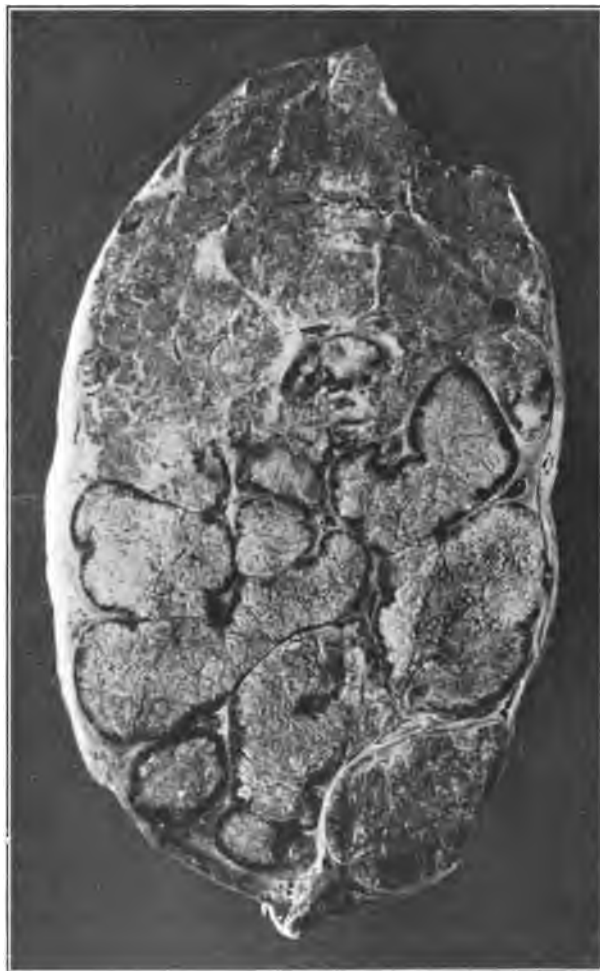

FIG. 467.—INFARCTION OF THE LIVER.

The infarcts, multiple and large, are due to extensive thrombosis of branches of the portal vein.

dependent in most instances upon the development of local thrombosis or embolism, which commonly do not lead to infarction, together with general disturbances of the circulation which prevent the re-establishment of equilibrium in the hepatic vessels.¹

¹ For a study of liver infarcts see summary of *Baldwin*, ref. footnote p. 711 also *Steinhaus*, *Deut. Arch. f. klin. Med.*, Bd. lxxx., p. 364, 1904.

Rupture of the Portal Vein, with fatty degeneration of its walls, has occurred in a few instances.

Chronic Endophlebitis, with atheroma and calcification, may occur in the walls of the portal vein, giving rise to thrombosis.

Dilatation of the Portal Vein, either uniform or varicose, may occur in various parts of the vessel or its branches. It may be caused by destruction of the liver capillaries in cirrhosis, or by occlusion of the vein by thrombi, tumors, etc.

THE HEPATIC VEINS.

The hepatic veins present lesions similar to those of the portal vein and its branches, but they are much less frequent. The veins may be dilated by obstruction to the passage of venous blood into the heart. They may be the seat of acute and chronic inflammation, and soft thrombi and suppurative inflammation may be produced by abscesses in the liver. Rarely there is a localized obliterating phlebitis in the hepatic vein followed by chronic congestion, interstitial inflammation, and thrombosis.¹

ATROPHY OF THE LIVER.

Atrophy of the liver may affect the entire organ or be confined to some part of it. General atrophy may occur in old age as a senile change, or may be induced by starvation or chronic exhausting diseases. The organ is diminished in size, is usually firm, and the acini appear smaller than usual. Microscopically the change is seen to be due to a diminution in size of the liver cells, and hand-in-hand with this there occurs frequently an accumulation of pigment granules within the atrophied cells. The cells may entirely disappear over circumscribed areas, leaving only shrivelled blood-vessels and connective tissue; or, in some cases, there may be an increase of connective tissue associated with the atrophy of the cells. When much pigment is formed in the cells the lesion is often called *pigment atrophy*.

Essentially the same changes may occur in circumscribed portions of the liver, as the result of pressure from new connective tissue in cirrhosis, from tumors, hydatids, amyloid degeneration, gall-stones, etc. In atrophy from pressure the liver cells are apt to become very much flattened and squeezed together as they diminish in size.

NECROSIS.

Necroses in the liver may occur under various conditions and in many forms.²

Minute areas of necrosis of liver cells, *focal necrosis* (see p. 58), are

¹ Consult for obliterating phlebitis of the main trunks of the hepatic vein as a cause of death, *Chiari, Ziegler's Beitr.*, Bd. xxvi., p. 1, 1899, bibl.

² For a study of necroses of the liver see *Mallory, Jour. of Med. Res.*, vol. vi., 1901, p. 264.

found irregularly scattered through the organ in various acute infections, and may be artificially induced in animals by the injection of bacteria or other vegetable toxins, such as ricin and abrin.¹

More extensive necroses of liver cells, especially about the central vein, frequently occur, usually in acute infectious diseases—diphtheria, endocarditis, lobar pneumonia, peritonitis, cerebro-spinal meningitis.² This has been called *central necrosis*.

Necrosis in the liver may, however, be limited to the peripheral zone of the lobule, *peripheral necrosis*. This condition has been described in a few instances, especially in connection with eclampsia.

Finally, the necrosis of parenchyma cells in the liver may be limited to the middle zone of the lobule, "*midzonal necrosis*."

In most of these forms of so-called "zonal necrosis"³ bacterial toxins or infections appear to be the chief determining factor.

Many of the necroses of the liver are doubtless due to the action of bacteria or bacterial toxins. The focal forms may be determined by the local growth of bacteria, by the occlusion of capillaries by swollen and proliferated endothelial cells, as in typhoid fever, or by fibrinous or agglutinative thrombi.

The reason for the topography of the lesion in the various forms of "zonal necrosis" has not yet been definitely determined. Nor is the relation of these to certain phases of so-called acute yellow atrophy of the liver, clear.

Pearce has shown⁴ that by the injection into animals of hæmagglutinative substances contained in various cytolytic immune sera, agglutinative thrombi may form in the capillaries and smaller branches of the portal vein, leading to necrosis of the liver. The position and extent of these areas of hyaline necroses vary with the amount of the serum administered. They are mostly superficial, and may be small and focal or involve nearly all the parenchyma of the lobule, except that in the vicinity of the portal spaces.

Pearce and Winne⁵ have shown that similar lesions may follow the injection of hæmagglutinins of bacterial origin. In these areas of hyaline necrosis the liver cells stain poorly with eosin; the nuclei do not stain and may be seen only as faint outlines, or they are shrunken.

Oertel has described the occurrence of multiple circumscribed necrotic and atrophic foci in the liver not associated with local infective processes and without marks of inflammation or connective-tissue hyperplasia. These are associated with stasis in the blood, and bile capillaries, and local portal sclerosis. These areas contain bile pigment. This lesion is most marked about the central vein, and may vary in extent. It is associated with jaundice. The lesion is diffuse in the liver, often running in streaks which merge into normal liver tissue. Thus the liver becomes tough, pale, bile-stained, with obscured markings. The liver cells in the affected areas apparently lose their cytoplasm, leaving a well-preserved outline, and may contain fat.

For this lesion the designation *multiple non-inflammatory necrosis of the liver with jaundice* is suggested.⁶

¹ Flezner, Johns Hopkins Hosp. Rep., vol. vi., p. 259, 1897; Mallory, Jour. Exp. Med., vol. iii., p. 611, 1898.

² Mallory, Jour. Med. Res., vol. vi., p. 264, 1901.

³ For a study of "zonal necroses" of the liver see Opie, Jour. Med. Res., vol. xii., p. 147, 1904.

⁴ Pearce, Jour. Med. Res., vol. xii., p. 329, 1904; also *ibid.*, vol. xiv., p. 541, 1906.

⁵ Pearce and Winne, Amer. Jour. Med. Sci., vol. cxxviii., p. 669, 1904.

⁶ Oertel, Jour. Med. Res., vol. xii., p. 75, 1904; also Jour. Exp. Med., vol. viii., p. 103, 1906. For a study of changes in necrotic cells in cytolysis in the liver and elsewhere see Symmers, Jour. Exp. Med., vol. ix., p. 64, 1907.

Howland and Richards¹ have shown that chloroform anæsthesia in animals repeated on several successive days induces fatty degeneration or hyaline necrosis or both, of the liver cells in the central portion of the lobules. Whipple and Sperry² found that animals may recover from the chloroform liver necroses with complete restitution of the cells after two or three weeks.

The acute degenerations of the liver occurring in eclampsia, in which condition chloroform is often administered, require careful scrutiny in view of the striking lesions of necrosis induced by chloroform alone.

DEGENERATION.

Albuminous Degeneration.—In the infectious diseases and in certain cases of acute anæmia and phosphorus poisoning, the liver is swollen and, on section, of a dull yellowish gray color, looking as if it had been boiled. It contains less blood than usual, and the outlines of the lobules are indistinct. Microscopical examination shows the lesion to consist of a swelling of the liver cells and an accumulation in them of moderately refractile, finer and coarser albuminous granules. These granules may disappear and the cells return to their normal condition, or fatty degeneration may follow. Fatty and parenchymatous degenerations are often associated.

Acute Yellow Atrophy (Acute Parenchymatous Degeneration).—This rare condition is characterized anatomically by a rapid diminution in the size of the liver as the result of a granular and fatty degeneration, necrosis, and disintegration of the liver cells. It is frequently associated with the clinical condition called *icterus gravis*. The liver, sometimes within a few days, may be reduced to one-half its normal size. On opening the abdominal cavity the organ may be found lying, concealed by the diaphragm, close against the vertebral column. The amount of diminution and the general appearance of the affected organ depend to a considerable extent upon its previous condition—*i.e.*, whether or not it was the seat of other lesions—as well as upon the duration of the process and the degree of degenerative change. In general, if the lesion is well marked, the liver is small, flabby—sometimes almost fluctuating—and the capsule wrinkled. On section the cut surface may show but little trace of lobular structure, but present an irregular mottling with gray, ochre-yellow, or red; sometimes one sometimes another color preponderating.

Microscopical examination shows varying degrees of degeneration and destruction of the liver cells. Most evidently in those parts which have a grayish appearance, the outlines of the cells are preserved and the protoplasm is filled with larger and smaller granules. In the yellow portions the outlines of the liver cells may be preserved, and they may contain varying quantities of larger and smaller fat droplets and granules of yellow pigment. Or the cells may be necrotic or disintegrated, and in their place are irregular collections of fat droplets, hyaline material, pigment granules, red and yellow crystals, and detritus; only the connective

¹ Howland and Richards, Jour. Exp. Med., xi., 344, 1909; see also Opie, ref. page 718.

² Whipple and Sperry, Johns Hop. Hosp. Bull., xx., 278, 1909.

tissue and blood-vessels of the original liver tissue remaining (Fig. 468). The red areas may show nearly complete absence of liver cells and cell detritus, and sometimes irregular rows of cells which are variously interpreted as being new-formed gall-ducts or proliferated liver cells, marking a reparative process which may be extensive.¹ In these areas it appears to be, in part at least, the blood contained in the vessels which imparts the red color. Sometimes the interstitial tissue is infiltrated with small spheroidal cells resembling leucocytes. Crystals of leucin and tyrosin are sometimes found intermingled with the cell detritus. In some cases the liver is not diminished in size. In early stages it may even be larger than normal.

These lesions of the liver are frequently associated with enlargement

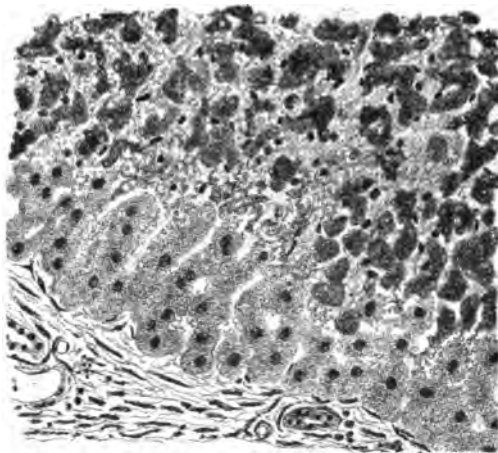


FIG. 468.—ACUTE YELLOW ATROPHY OF THE LIVER.

The liver cells in the periphery of the lobule are little changed; those toward the centre are largely destroyed.

of the spleen and parenchymatous degeneration of the kidney and of the heart muscle. Multiple hæmorrhages may occur in the gastro-intestinal canal, kidneys, bladder, and lungs. There is frequently marked jaundice.

The condition above described as acute yellow atrophy of the liver sometimes occurs in persons previously apparently well, but may accompany infectious diseases—typhoid fever, diphtheria, puerperal infection, etc.—and may be seen in eclampsia and pernicious vomiting in pregnancy. While the nature of the condition is not well understood it seems probable that the lesion is essentially a necrosis and degeneration resulting from toxic substances produced either in bacterial infection or through faulty cell metabolism and followed by more or less pronounced autolysis. It is probably erroneous to consider the lesions of the liver

¹ For a study of regenerative changes in the liver after acute yellow atrophy see *MacCallum*, Johns Hopkins Hosp. Rep., vol. x., 1902, p. 375; also *Pearce*, Jour. Med. Res., vol. xv., p. 99, 1906. See also for repair of liver, *Muir*, Jour. of Path., xii., 287, 1908 and *Milne*, Proc. N. Y. Path. Soc., Oct. and Nov., 1909.

described under the name of acute yellow atrophy as marking a single disease process.

As to the details of the pathogenesis of this condition, opinions differ, and the whole subject is in urgent need of more exact research.

In the forms of this liver lesion which mark the toxæmia of pregnancy, whether these be clinically manifested in eclampsia, pernicious vomiting, or other less well marked abnormal conditions, there appears to be a disturbance of nitrogenous metabolism in the liver, associated with the characteristic rapid destruction of the parenchyma.¹

It should be borne in mind, finally, that while acute yellow atrophy of the liver has been regarded as an especially fatal lesion, there is abundant clinical and morphological evidence that various grades of the lesion may occur and that recovery from many forms with regeneration of liver tissue is not uncommon.²

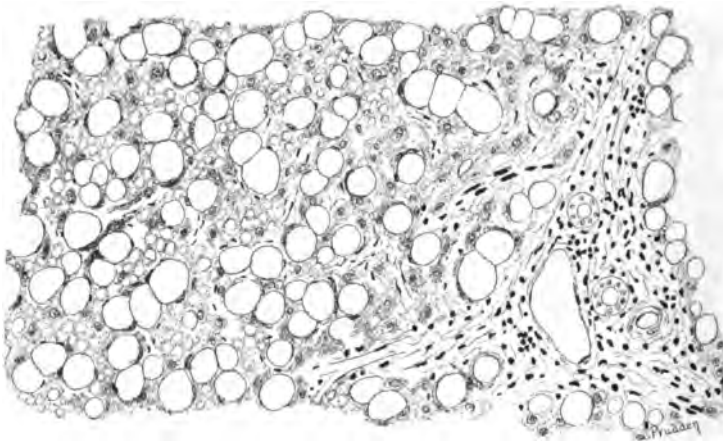


FIG. 469.—FATTY INFILTRATION OF LIVER.

Portion of the periphery of a lobule, showing many liver cells distended with a single large drop of fat, while between these are liver cells with small fat droplets and others flattened by pressure. In this section, hardened by alcohol, the fat has been dissolved, leaving clear spaces.

Experimental Studies.—The experiments of Opie³ in inducing in animals lesions comparable with those of acute yellow atrophy in man are very suggestive. Opie found that after the relatively slight injury of the liver parenchyma induced by repeated doses of chloroform in dogs, the injection of *Bacillus coli*—not itself especially virulent for these animals—may be followed by changes in the liver which neither the chloroform (see p. 716) nor the bacteria alone can induce. For under these conditions he found that the liver cells may be largely destroyed by necrosis, the remainder being fatty, while evidence of reparative changes—new fibrous tissue and new-formed gall-ducts, such as are often seen in acute yellow atrophy in man—was strikingly shown. In view of these experiments Opie calls attention to the possibility that some of the lesions of the toxæmia of pregnancy and acute yellow atrophy in man may in fact be due to the action of bacteria or their poisons on liver cells already vulnerable from metabolic or other forms of intoxication.

¹ For discussion and bibl. see *White*, *Bost. Med. and Surg. Jour.*, 158, 729, 1908.

² For a study of forms of acute yellow atrophy marking the toxæmia of eclampsia and other disturbances of pregnancy see *Strauss*, *Amer. Jour. of Obstetrics*, vol. liii., 1906, bibl.; also *Ewing*, *ibid.*, vol. li., 1905; also *Ewing*, *Proc. Path. Soc., Phila.*, xiii., 65, 1910.

³ *Opie*, *Jour. Exp. Med.*, xii., 367, 1910.

Fatty Infiltration.—In the normal human liver there is usually a certain amount of fat in the liver cells, and this amount varies considerably under different conditions.

The gross appearance of pathological fatty livers varies a good deal, depending upon the amount and distribution of fat and its association with other changes. If the lesion is uncomplicated and considerable, the organ is increased in size, the edges are rounded, the consistence is firm, the color yellowish, and the cut surface greasy. The lobules are enlarged and their outlines indistinct, and the blood content is diminished. The liver is increased in weight. The lesion may be uniform throughout the organ or it may occur in patches. In the latter case the liver has a mottled appearance, irregular yellowish patches alternating with the brownish red, unaffected portions.

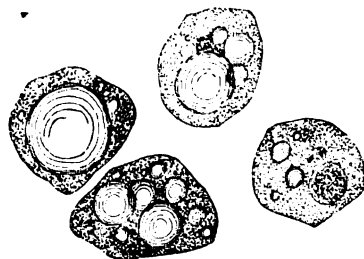


FIG. 470.—FATTY INFILTRATION OF LIVER CELLS.

Fatty infiltration is often associated with chronic congestion (*nutmeg liver*), with cirrhosis and amyloid degeneration; the picture may then present considerable complexity. Fatty livers may be stained brown or greenish with bile pigment.

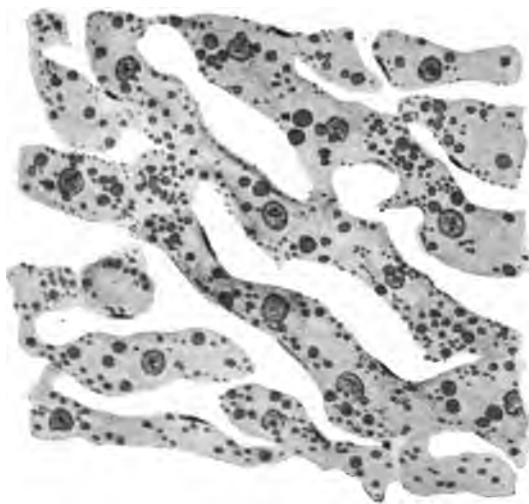


FIG. 471.—FATTY DEGENERATION OF LIVER CELLS.

Microscopically the liver cells are seen to contain larger and smaller droplets of fat (Fig. 469), and frequently large drops of fat occupy nearly the entire volume of the cell, so that the protoplasm may be visible only as a narrow, nucleated crescent at one side, or it may disappear altogether (Fig. 470).

Fatty infiltration of the liver may occur as a result of excessive

ingestion of oleaginous food; in chronic alcohol, phosphorus, and arsenic poisoning; in certain exhausting diseases accompanied by malnutrition, as in pulmonary phthisis, chronic dysentery, etc.; and under a variety of conditions which we do not understand. It is common in children, especially in acute infectious diseases.¹

Fatty Degeneration.—In this condition, which in many cases cannot be distinguished morphologically from fatty infiltration, the fat is believed to be formed by a transformation of the protoplasm of the liver cells (see p. 40). The fat droplets are, for the most part, very small and abundant (Fig. 471), though this is not constant. Fatty degeneration

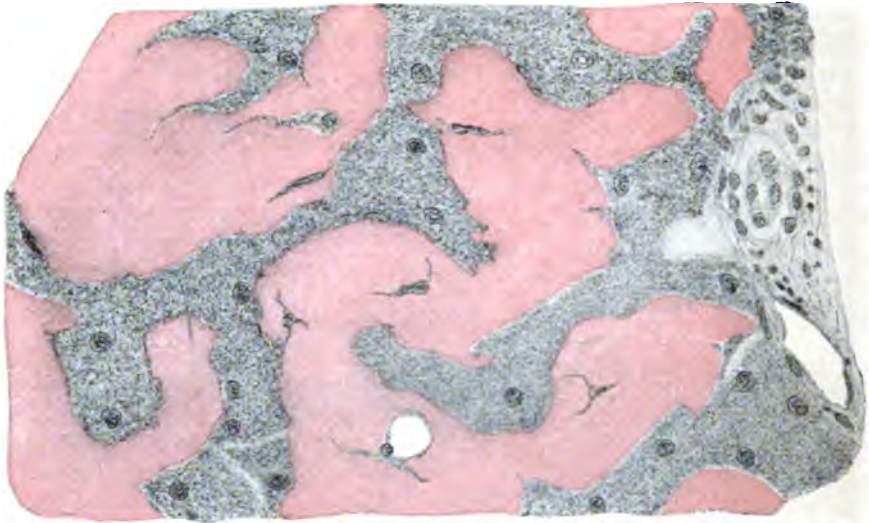


FIG. 472.—AMYLOID DEGENERATION OF LIVER CAPILLARIES.

The capillaries are much enlarged and occluded by the amyloid material; the liver cells between them are atrophied.

of the liver cells frequently follows, and is associated with, cloudy swelling under the varying conditions in which this occurs, or it may appear in profound anæmia and in acute phosphorus and arsenic poisoning.²

Amyloid Degeneration.—In the liver amyloid degeneration may be general or local; so extensive as to give the organ very characteristic appearances, or so slight as to be unrecognizable without the aid of the microscope. It may be associated with other lesions. When the change is extensive and general the liver is enlarged sometimes to more than twice its normal size; the edges are thickened and rounded; the surface is smooth; the tissue tough, firm, inelastic, more or less translucent, and of a brownish yellow color. The lobular structure may be more or less indistinct, or it may become very evident by an associated fatty degen-

¹ See *Freeman*, *Archives of Pediatrics*, vol. xvii., p. 81, 1900.

² For a study of localization of fat in the liver see *McCrae* and *Klotz*, *Jour. Exp. Med.*, xii., 746, 1910.

eration of the peripheral or central cells of the lobules. The translucency and peculiar appearance of the tissue may be best seen by slicing off a thin section and holding it up to the light. When the lesion is less considerable the liver may be of the usual size, and may feel harder than normal, and here and there a translucent mottling may be evident, or the degeneration may be apparent only on the addition of staining agents. When, as is frequently the case, it is associated with cirrhosis, the liver may be small and nodular, and the appearance of the cut surface varies, depending upon the character of the cirrhotic change and the presence or absence of fat.

This degeneration usually commences in the walls of the intralobular blood-vessels, causing them to become thickened and translucent (Fig. 472). Their lumen may be nearly or entirely occluded. The liver cells may be squeezed by the thickening of the vessels and may become partially or completely atrophied, or they may be fatty. Amyloid degeneration may also involve the interlobular vessels, and in advanced stages larger and smaller areas of liver tissue may be almost completely converted into the dense, refractile substance in which here and there flattened liver cells may be seen.

Amyloid degeneration of the liver is usually associated with a similar lesion of other organs.

Glycogen Degeneration.—

This may occur in the liver cells in diabetes.

PIGMENTATION OF THE LIVER.

Pigmentation of the liver cells, from bile and blood derivatives, is to a certain extent normal, but may be greatly increased as a result of atrophy, of localized hæmorrhage, and of obstructive jaundice. Pigmentation of the liver may be marked in hæmochromatosis (see p. 54).

As a result of severe malarial poisoning a variable amount of brown, black, or reddish pigment is often found in the blood. This is usually mostly taken up by the leucocytes and deposited in various parts of the body, chiefly in the liver, spleen, and marrow of the bones. In the liver it is usually found enclosed in the endothelial cells¹ free or in place in the blood-vessels (see Fig. 473), but sometimes in the tissue between them.

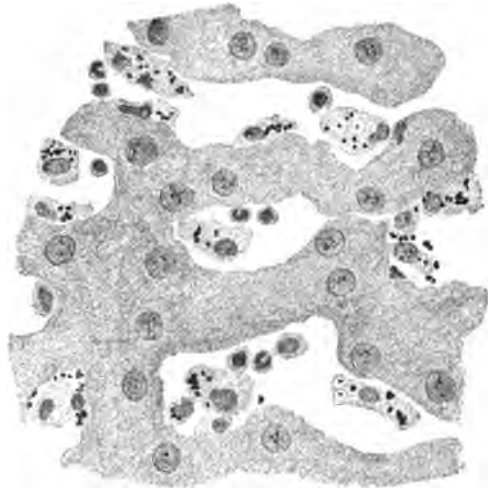


FIG. 473.—MALARIAL PIGMENTATION OF THE LIVER

The pigment is largely in the exfoliated endothelium within the capillaries. Pigmented malarial parasites may be seen in some of the cells.

¹ For a study of the phagocytic powers of the endothelial cells of the blood-vessels of the liver see *Heinz, Arch. f. mik. Anat., Bd. lviii., 1901, p. 576.*

The liver cells frequently contain bile pigment, but usually are free from the melanotic pigment characteristic of this malarial condition. As the result of this accumulation of pigment the liver may have a dark reddish brown, an olive brown, or a black color (sometimes called *bronze liver*).

Pigment similar in character to that which occurs in the lungs from the inhalation of coal dust may be found in the connective tissue along the portal vessels. Inhaled pigment particles may pass the lungs and bronchial lymph-nodes, and be deposited in the liver as they are in the spleen and hepatic lymph-nodes.

CALCIFICATION.

This lesion of the liver is rare. The deposit of lime may be in the vicinity of the arteries or the veins.¹

INFLAMMATION. (Hepatitis.)

Acute Exudative Hepatitis (Purulent Hepatitis).—Purulent or suppurative inflammation of the liver may be the result of injury; it may be secondary to inflammation of the gall-ducts or the branches of the portal vein. It may occur as the result of the presence of tumors and parasites, or from propagation of an inflammatory process from without, as in ulcer of the stomach with adhesions to the liver and secondary involvement of the latter. It is often directly due to the introduction of bacteria into the organ, through the blood-vessels or gall-ducts or otherwise. Purulent inflammation in the liver almost always results in abscess.

Large abscesses of the liver may be traumatic, but are often due to unknown causes. They are not infrequently associated with dysentery, and may then be due to the conveyance of micro-organisms through the veins, or lymph-channels, or peritoneum, or gall-ducts from the intestinal ulcers. Such abscesses may be due to the presence of the *amœba coli*. They occur most frequently in tropical climates—hence the name *tropical abscess*—but are not very uncommon in the temperate zone. They are usually single, but there may be several of them. They are sometimes so large as to occupy a large part of the lobe. They are most frequent in the right lobe, but may occur in any part of the organ. They tend to enlarge, and as they do so they approach the surface of the liver. Here the contents of the abscess may be discharged into the peritoneal cavity. More frequently, however, as they approach the surface, a localized adhesive peritonitis ensues, so that the liver becomes bound to adjacent parts, and thus the abscess may open into the pleural cavity, or, owing to a secondary pleurisy with adhesions, into the lung tissue. They may open into the pericardium. They may open externally through the abdominal wall; into the stomach, duodenum, colon, or pelvis of the right kidney; into the hepatic veins, portal vein, vena cava, or gall-bladder or gall-ducts.

The early stages in the formation of large abscesses of the liver are

¹ See Brill and Libman, Jour. Exp. Med., vol. iv., p. 541, 1899.

but little known. It is probable, however, that in many cases they are the result of the confluence of smaller abscesses (Fig. 488). Their contents, usually bad-smelling, may be thick and yellow like ordinary pus, but more commonly they are thin, reddish-brown, or greenish in color from admixture with the pus of blood, gall pigment, and broken-down liver tissue. Microscopical examination shows the contents to consist of fluid with pus cells, more or less degenerated blood, degenerated liver cells, fragments of blood-vessels, and pigment granules and crystals. The walls of the abscess are usually ragged, shreds of necrotic liver tissue hanging from the sides. Microscopical examination of the liver tissue




FIG. 474.—SMALL ABSCESSES IN THE LIVER CONTAINING BACILLI.

near the abscess shows infiltration with pus, flattening of the liver cells from pressure, cloudy swelling, and necrosis of those lying along the cavity.¹

The amœbic abscesses are usually free from bacteria. Other abscesses may contain the *Bacillus coli communis* or the *Streptococcus pyogenes* or *Staphylococcus pyogenes*.

Not infrequently, however, especially in old abscesses, examination both morphological and cultural fails to reveal the presence of micro-organisms.

After the discharge of the contents of the abscess or without this, if it be not very large, granulation tissue may form in the wall of the cavity and a fibrous capsule be produced, enclosing the contents, which become

¹ See for a study of tropical abscess of the liver *Howard and Hoover, Am. Jour. Med. Sci., vol. cxiv., pp. 150, 263, 1897, bibl.*

thickened and often calcareous, and in this condition may remain for a long time. Or the connective-tissue walls may approach one another and join, forming a fibrous cicatrix at the seat of the abscess.

Small multiple metastatic abscesses are not infrequent in pyæmia. In these abscesses we can readily study the various stages of formation. Suppurative processes in any part of the body—in the head, upper and lower extremities, etc.—may act as distributing centres for micro-organisms.¹ These, entering the circulation, may pass the heart and pulmonary capillaries, with or without inducing lesions in the lungs, and, lodging in the vessels of the liver, induce circumscribed necrosis of the liver tissue (see Fig. 56, p. 89) and suppurative inflammation. Under these conditions we may find on section of the liver larger and smaller yellowish or grayish spots, the larger of which may be soft and present

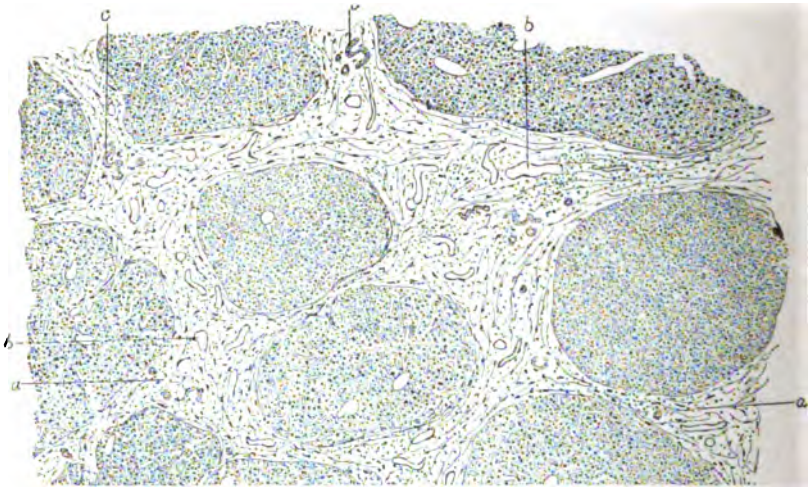


FIG. 475.—CHRONIC INTERSTITIAL HEPATITIS—CIRRHOSIS.

a, New-formed connective tissue; b, dilated blood-vessels of the new tissue; c, gall-duct.

the usual characters of abscesses. The smaller, which may not be larger than a pin's head, may present the usual consistence of liver tissue with the lobular structure still evident; others may be softer, more yellow, and surrounded by a zone of hyperæmic liver tissue. Microscopical examination of the earlier stages often shows the blood-vessels filled with bacteria, scattered and in masses. Around these the liver cells are found in various stages of necrosis; in many the nuclei do not stain and the bodies are very granular, or the entire cell is broken down into a mass of detritus. About these necrotic islets of liver cells pus cells collect and often form a zone of dense infiltration (Fig. 57, p. 90). Thus, by the increase of pus cells and the necrosis of liver tissue, small abscesses are formed whose contents are intermingled with greater or less numbers of bacteria (Fig. 474), which seem to increase in number as the process goes on. By the confluence of small abscesses larger ones may

¹ Kruse and Pasquale, *Zeitschr. f. Hygiene u. Infkr.*, Bd. xvi., p. 1, 1894.

be formed. Death usually ensues, however, before the abscesses attain a very large size.

Chronic Interstitial Hepatitis (Cirrhosis).¹—The most marked result of chronic interstitial hepatitis is the formation of new connective tissue in the liver. The character, amount, and distribution of the new tissue vary greatly in different cases. Secondly there are usually marked changes in the liver cells and in the blood-vessels and gall-ducts. The new tissue is most commonly formed and most abundant in the periphery

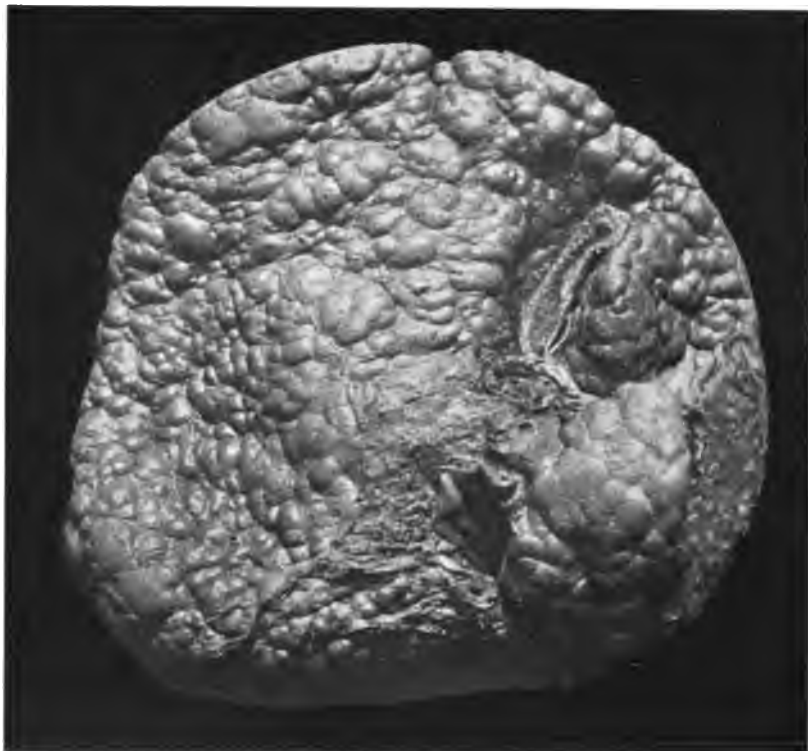

FIG. 476.—CHRONIC INTERSTITIAL HEPATITIS—CIRRHOSIS.
On account of the rough surface such livers are sometimes called "hobnail livers." This cut is a photographic reproduction of a cirrhotic liver of a child.

of the lobules along the so-called capsule of Glisson, but it may extend into the lobules between the liver cells. It may surround single lobules, or more frequently larger and smaller groups of lobules (Fig. 475). It may occur in broad or narrow, irregular streaks or bands and is associated with the old fibrous stroma of the organ. It is frequently more abundant in one part of the liver than in another. The new-formed tissue tends to contract, and thus compromise by pressure the enclosed islets of liver

¹ Various names have been applied to the form of cirrhosis described under this head: Portal cirrhosis, fibrous liver, lacunar cirrhosis, hobnail liver, granular liver. See for details of liver lesions *Rollston*, "Diseases of the Liver," 1905.

tissue, causing them to project, in larger and smaller nodules, from the surface of the organ. The liver cells may be flattened or atrophied from pressure; or, from interference with the portal circulation, they may atrophy or become fatty; or they may become colored with bile pigment. This form of lesion is called atrophic cirrhosis.

The varied appearances which cirrhotic livers present to the naked eye depend largely upon the amount and distribution of the new connective tissue and upon the secondary changes in the liver cells. The surface may be very rough and uneven from the projection of larger and smaller irregular-shaped nodules of liver tissue (Fig. 476) between which are the depressed contracted bands of new-formed connective

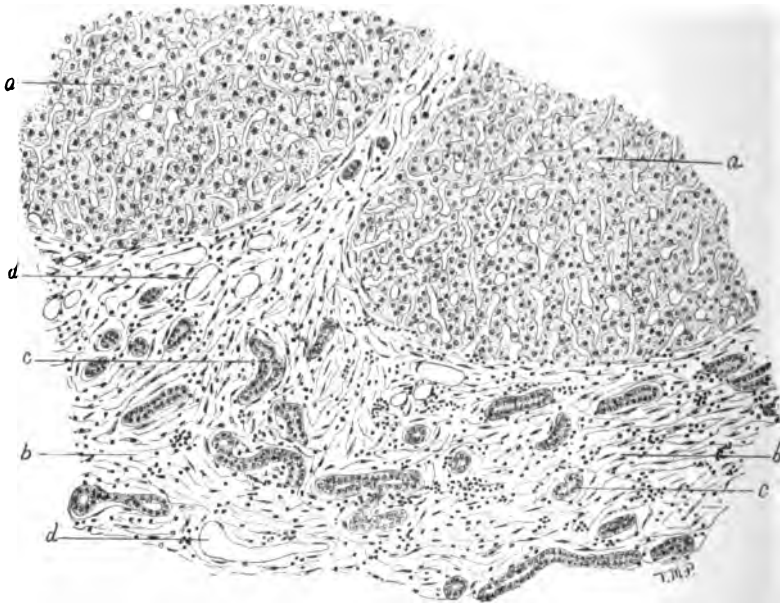

FIG. 477.—CHRONIC INTERSTITIAL HEPATITIS.

Showing a portion of the section shown in Fig. 475, but more highly magnified. *a*, Portions of liver lobules; *b*, new-formed connective tissue; *c*, gall-ducts, apparently new-formed; *d*, blood-vessels in the new tissue.

tissue. On the other hand, the surface of the liver may be smooth, when the new connective-tissue bands are small, evenly distributed, or little contracted. Again the liver may be greatly distorted and misshapen by the atrophy of the parenchyma and the contraction of large and irregular bands or masses of new connective tissue. In sections through cirrhotic livers the new tissue may not be visible to the naked eye, or it may appear as grayish, irregular streaks, or bands, or patches, often sharply outlined against the dark-red, or brown, or yellow, or greenish yellow parenchyma. When, as is often the case, fatty infiltration is associated with atrophic cirrhosis, the liver may not only not be diminished in size, but may be larger than normal.

On microscopical examination the new connective tissue is found in some cases loose in texture and containing many variously shaped cells; or it may be dense and contain comparatively few cells; it is usually quite vascular and contains a relatively large number of elastic fibrils.¹

The connective tissue is most abundant between the lobular masses of liver parenchyma, but it may encroach more or less upon their peripheries. Small gall-ducts, some of them at least apparently new-formed, are usually present in the connective tissue around the islets of parenchyma (Fig. 477). Some of these may usually be found continuous with the old ducts or gall capillaries. Sometimes rows of more or less cuboidal cells in the connective tissue appear to be liver cells which have reverted to a simpler type (Fig. 478).² From the old liver cells or from the cells of the new-formed gall-ducts new liver cells are produced so that here as in certain cases of acute yellow atrophy a reparative process is initiated and a certain amount of new parenchyma may form.³

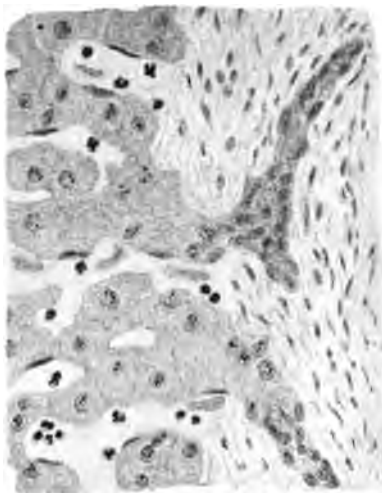


FIG. 478.—NEW-FORMED GALL-DUCTS IN CIRRHOSIS.

The section shows the projection into the new connective tissue from the rows of old liver cells, of cell masses resembling gall-duct epithelium. This may be interpreted as an example of reversion of the differentiated liver cells to a simpler type.

The branches of the hepatic and portal veins, particularly the latter, often become obliterated by pressure from the new connective tissue or from chronic thickening of their walls, so as seriously to interfere with the functions and nutrition of the liver cells.⁴ The bile-ducts also may become obliterated, or there may be catarrhal inflammation, especially of the larger trunks. The branches of the hepatic artery are much less liable to alterations than the other vessels. The capsule of the liver is usually thickened, either uniformly or in irregular patches; or its surface may be roughened by larger and smaller papillary projections. The liver is frequently bound to the diaphragm or other adjacent organs by connective-tissue adhesions. Amyloid and fatty degeneration may be associated with cirrhosis. Cirrhotic livers frequently show an unusual number of leucocytes in the blood-vessels.

The obstruction to the portal circulation induced by cirrhosis usually gives rise to a number of secondary lesions, since collateral circulation is rarely established in sufficient degree to afford much relief. The hæmorrhoidal and vesical veins may be greatly enlarged, and also veins

¹ For a study of the character of the new connective tissue in cirrhosis see *Fleznar*, University Medical Magazine, vol. xiii., p. 613, 1900.

² For consideration of reversion see p. 63.

³ See ref. *Muir*, p. 717.

⁴ For a study of the increase of portal pressure in portal cirrhosis see *Herrick*, Jour. Exp. Med., vol. ix., p. 93, 1907.

of communication between Glisson's capsule and the diaphragmatic veins.

In rare cases a very peculiar dilatation of the cutaneous veins about the umbilicus is observed. The enlarged veins form a circular network around the umbilicus, or a pyramidal tumor beside it, or all the veins of the abdominal wall, from the epigastrium to the inguinal region, are dilated. This condition is said to be dependent upon the congenital non-closure and subsequent dilatation of the umbilical vein and its anastomoses with the internal mammary, epigastric, and cutaneous veins. According to Sappey, it is not the umbilical vein which is dilated, but a vein which accompanies the ligamentum teres.

There is very frequently also a dilatation of the veins of the abdominal wall, which has a different origin. It is produced by the pressure of the fluid of ascites on the vena cava, and is found with ascites from any cause and with abdominal tumors.

Ascites is the most common secondary lesion of atrophic cirrhosis. It usually begins at an early stage of the disease, and is apt to increase constantly. It generally precedes œdema of the feet, but both may appear at the same time. This fluid is of a clear yellow or brown, green or red; it is sometimes mixed with shreds of fibrin, and more rarely with blood. The peritoneum remains normal, or becomes opaque and thick, or there may be adhesions between the viscera.

The spleen is very frequently enlarged, and the enlargement may be considerable. When it is not increased in size this seems usually due to previous atrophy of the organ, or to fibrous thickening of its capsule, or to hæmorrhages from the stomach and bowels occurring just before death.

The pancreas is usually the seat of more or less marked interstitial hyperplasia.¹

The stomach and intestines are often secondarily affected by the obstruction to the portal circulation. Profuse hæmorrhage from the stomach and intestines may occur and sometimes cause sudden death. The mucous membrane is then found pale, or congested, or with hæmorrhagic erosions. The hæmorrhage not infrequently results from rupture of œsophageal varices which are present, especially in the lower portion, in a noteworthy proportion of cases of atrophic cirrhosis.² Sometimes the blood is infiltrated in the coats of the stomach and intestines.

The mucous membrane of the stomach, and of the entire length of the intestines, is frequently the seat of chronic catarrhal inflammation, and is sometimes uniformly and intensely congested and coated with mucus. In other cases both the mucous and muscular coats are pale, but very markedly thickened.

Cirrhosis of the liver is not infrequently accompanied by chronic diffuse nephritis.

Hypertrophic Cirrhosis.—There is a form of interstitial hepatitis in

¹ For a study of pancreas lesions in hepatic cirrhosis see *Lando, Zeits. f. Heilkunde, Abt. f. path. Anat.*, Bd. xxvii., p. 1, 1906.

² For a critical summary of gastro-intestinal hæmorrhage in cirrhosis, with bibliography, see *Preble, Am. Jour. Med. Sci.*, vol. cxix., p. 263, 1900.

which the growth of new tissue not only occurs between the lobules, but extends into the lobule between the liver cells (Fig. 479). Under these conditions even in advanced forms of the lesion the liver may be enlarged, the surface may be smooth or slightly roughened, the parenchyma is often bile-stained. This form of interstitial hepatitis is called *hypertrophic cirrhosis*. There is a form of interstitial hepatitis, usually of the hypertrophic type, in which the growth of connective tissue is most marked in the vicinity of the smaller bile-ducts. This often occurs in connection with obstruction of the bile-ducts, and the lesion is called *biliary cirrhosis*. In "biliary cirrhosis" marked jaundice is said to be common, while ascites is moderate or absent. In certain cases there is a marked difference in the gross and microscopic appearance in atrophic and hyper-

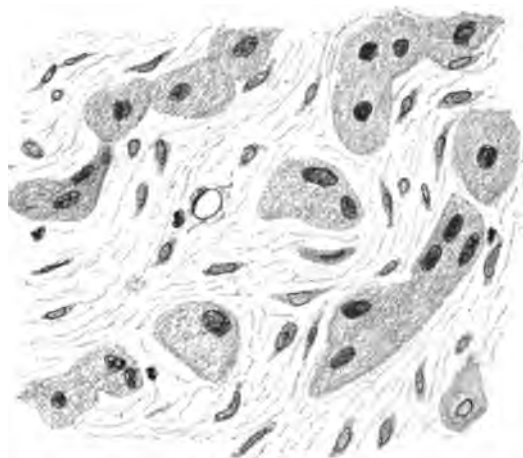


FIG. 479.—HYPERTROPHIC CIRRHOSIS OF THE LIVER.
Showing formation of connective tissue between the liver cells.

trophic cirrhosis, but intermediate forms occur. The difference in the conditions which lead to these two forms of cirrhosis of the liver, the atrophic and the hypertrophic, is not yet clear, and the distinctions which have been made between them, in part clinical, in part morphological, are often unsatisfactory.

The causes of cirrhosis are imperfectly understood. It is a disease of adult life, but exceptionally occurs in children.¹ Congenital cirrhosis with obliteration of the bile-duct is of occasional occurrence.² In adults it seems in many cases to be directly dependent upon the continued ingestion of large quantities of strong alcoholic liquors. It very rarely occurs as a result of beer drinking.

Doubtless many of the irregular cirrhotic lesions are the result of repair in antecedent necroses and profound degenerative processes like the so-called acute yellow atrophy of the liver.

¹ For a *résumé* of cirrhosis in childhood see *Morse*, Boston Med. and Surg. Jour., September 11, 1902.

² See *Rollleston and Hayne*, British Med. Jour., 1901, vol. i., p. 758, bibliography.

There are many cases of cirrhosis for which no primary inciting condition can be discovered.

The Nature of Cirrhosis.—Cirrhosis of the liver was formerly believed to be primarily a productive inflammation of the interstitial fibrous tissue with secondary atrophy of the parenchyma. It is now clear, however, that in most instances it is primarily due to atrophic or destructive changes in the liver cells which precede or accompany the formation of the fibrous tissue, and the regenerative processes in the liver cells and gall-ducts. The lesion is thus more properly considered as a replacement hyperplasia. This marks cirrhosis of the liver as a reparative process.¹

EXPERIMENTAL CIRRHOSIS.

The attempt has often been made to induce cirrhosis of the liver in animals.² Interstitial lesions have been secured in many ways, but in extent and character most of them differ widely from cirrhosis in man.

Recently, however, chloroform has been used for this purpose. Among the most striking results of the action of this agent are those secured by Opie,³ who found that by the administration of chloroform to dogs by the stomach in small doses, frequently repeated so as to thwart the immediate restitution of liver cells (see p. 727), sclerotic changes presently set in, marked by new connective-tissue, new bile-duct formation, etc., so that the lesion is fairly comparable with that of cirrhosis in man.

Opie further found that by associating with the chloroform administration injections of *Bacillus coli*, lesions may be induced still more clearly resembling those of advanced cirrhosis in man, with active new formation of gall-ducts.⁴

Welch⁵ has described the occurrence of small circumscribed areas of fibrous tissue in the liver, replacing liver cells and containing coal pigment. This rare lesion he has called *cirrhosis hepatis anthracotica*.

Syphilitic Hepatitis.—Chronic interstitial inflammation of the liver very frequently results from syphilitic infection, either congenitally or in the later stages of the acquired form. It may occur in a diffuse manner, new connective tissue being formed either between the lobules, or within them between the rows of liver cells. The new tissue may be rich in cells, or dense and firm.⁶ This form is frequently seen in children, and cannot be distinguished, either macroscopically or microscopically, from similar forms of interstitial hepatitis from other causes.

¹ For genesis of liver cirrhosis see Ribbert, *Deutsch Med. Wochenschr.*, 1908, No. 39.

² Herter and Williams, *Proc. Soc. Exp. Biol. and Med.*, iii., 23, 1905.

³ Opie, *Jour. Exp. Med.* xii., 367, 1910.

⁴ For a further study of the reparative phases of cirrhosis see MacCallum, *Jour. Am. Med. Assn.*, vol. xliiii., p. 649, 1904. For a résumé of nature and lesions of cirrhosis see Kelly, *Am. Jour. Med. Sci.*, vol. cxxx., p. 951, 1905. See for studies on experimental cirrhosis of the liver Pearce, *Jour. Exp. Med.*, vol. viii., p. 64, 1906, bibl.; also *Jour. Med. Res.*, vol. xv., p. 99, 1906. For a study of circumscribed lesions of the liver parenchyma in cirrhosis see v. Goureévitch, *Zeits. f. Heilkunde, Abt. f. path. Anat.*, Bd. xxvii., p. 303, 1906.

⁵ Welch, "Cirrhosis hepatis anthracotica, *Johns Hopkins Hosp. Bull.*, vol. ii., p. 32, 1891.

⁶ For a description of congenital liver cirrhosis with giant cells see Binder, *Virch. Arch.*, Bd. clxxvii., p. 44, 1904.

In other cases, particularly in children, there may be numerous small gummata (so-called *miliary gummata*) (Fig. 160, p. 274) scattered through the liver, together with more or less new connective tissue. An extensive formation of giant cells in the liver has been described in connection with congenital syphilis.¹ In adults, gummata are usually larger, varying in size from that of a pea to a hen's egg, and may be surrounded by larger and smaller irregular zones of ordinary connective tissue (Fig. 480). In still other cases in adults there are larger and smaller dense, irregular bands or masses of connective tissue running through the liver, drawing in the capsule and often causing great deformity of the organ (Fig. 481). These bands and masses of new tissue

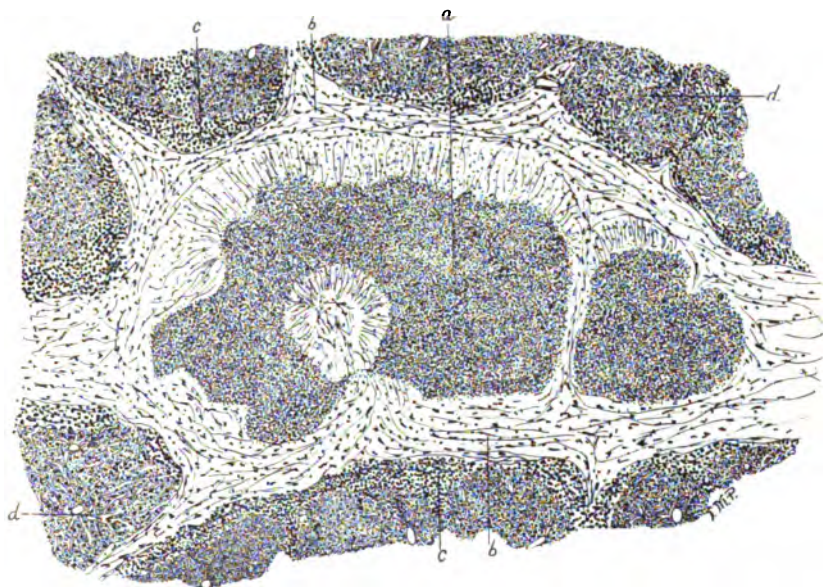


FIG. 480.—GUMMA OF LIVER.

a, Cheesy centre; b, fibrous periphery; c, small-celled peripheral infiltration; d, portions of liver lobules. The drawing is somewhat schematic.

may or may not enclose gummata, either large or small. These deforming cicatrices, either with or without gummata, are very characteristic of syphilitic inflammation of the liver.

This, like the simple interstitial inflammation of the liver, may be associated with fatty and waxy degeneration, and with atrophy of the parenchyma from pressure.

Tuberculous Hepatitis.—This lesion, which is usually secondary to tuberculous inflammation in some other part of the body, or a part of acute general miliary tuberculosis, is most frequently characterized by the formation of larger and smaller miliary tubercles, which may be either within or between the liver lobules or in the walls of the bile-ducts. Many of the tubercles are too small to be seen with the naked eye;

¹ See *Lonicer*, *Ziegler's Beitr.*, Bd. xxxix., p. 539, 1906, bibl.

others may be just visible as grayish points; still others may be from 1 to 3 mm. in diameter, with distinct yellowish-white centres. Microscopical examination shows considerable variation in the structure of the tubercles in different cases, as well as in the same liver. Some of them, usually the smaller ones, consist simply of more or less circumscribed collections of small spheroidal cells, which are not morphologically distinguishable, so far as the form and arrangement of the cells are concerned, from simple inflammatory foci, or from the diffuse masses of lymphatic tissue which occur normally in the liver.

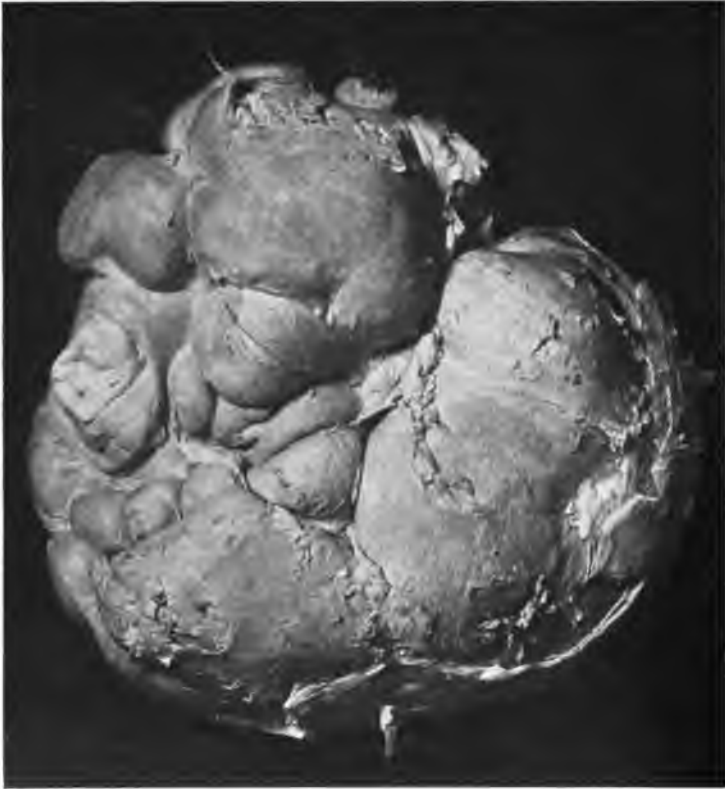

FIG. 481.—SYPHILITIC HEPATITIS.

The liver is greatly deformed by the contraction of new-formed connective tissue. The ragged surface is due to the tearing away of adhesions to surrounding parts.

In other forms we find a well-marked reticulum with larger and smaller spheroidal and polyhedral cells, with or without giant cells. In still other forms there is more or less extensive cheesy degeneration (Fig. 482). The larger forms are conglomerate, being composed of several tubercle granula joined together to form a single nodular mass. The liver cells at the seat of the tubercle are destroyed, and the interstitial tissue and blood-vessels are either destroyed or merged into the tubercle tissue.

In the periphery of the tubercles the liver cells may be in a condition of coagulation necrosis, and the tissue round about may be infiltrated with small spheroidal cells. There is in some cases a new formation of gall-ducts or of structures which resemble these and which in transverse sections resemble giant cells. Tubercle bacilli, frequently in small numbers, but often in great abundance, may be found within the tubercles.

Tuberculosis of the liver may be associated with cirrhosis, or waxy and fatty degeneration.

Much more rarely than the above form there are found in the liver more or less numerous scattered tuberculous masses from the size of a pea to that of a walnut or larger, with cheesy centres and usually a new

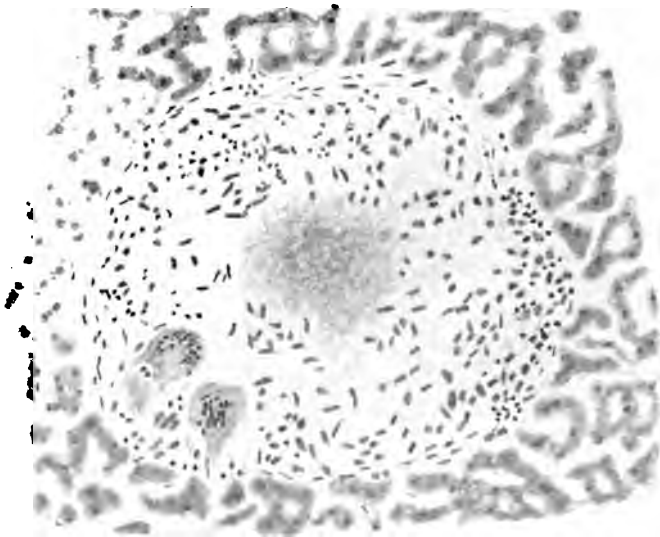


FIG. 482.—A MILIARY TUBERCLE OF THE LIVER.
Shows a cheesy centre and giant cells.

growth of connective tissue in the periphery. These so-called *solitary tubercles* of the liver may be softened at the centres. Tuberculous inflammation of the gall-ducts may give rise to numerous scattered, cheesy nodules, as large as a pea or larger, which may be softened at the centre and stained yellow with bile. Small cavities may thus be formed.¹ This lesion is rare and seems to be more frequent in children than in adults.

Perihepatitis.—*Acute exudative inflammation* of the serous covering of the liver, with the formation of fibrin, may occur as a part of acute general or localized peritonitis, or over the surface of abscesses, tumors, hydatids, etc., of the organ, when these lie near or approach the surface; or it may be secondary to acute pleurisy.

¹ See for a study of tuberculous cavities in the liver *Fletcher, Journal of Path. and Bact.*, vol. vi., p. 147, 1900, bibl.

Chronic perihepatitis, resulting in the thickening of the capsule of the liver, and the formation of new connective tissue in and beneath it may be secondary to an acute inflammation of the capsule, or it may be chronic from the beginning and associated with chronic pleurisy, chronic peritonitis, and cirrhosis. In this way more or less extensive adhesions of the liver to adjacent structures may be formed; or, by contraction of the new-formed connective tissue, considerable deformity of the liver may be produced. The capsule is sometimes uniformly thickened, sometimes the new tissue occurs in more or less sharply circumscribed patches. The surface is sometimes roughened from little, irregular, projecting masses of connective tissue. Microscopically the new-formed tissue is usually dense and firm, but it may be loose in texture and contain many cells. Not infrequently bands or masses of connective tissue run inward from the thickened capsule between the superficial lobules, causing localized atrophy of the parenchyma.

HYPERPLASIA OF LYMPHATIC TISSUE IN THE LIVER.

In some forms of leukæmia and pseudo-leukæmia the liver is not infrequently enlarged and soft and besprinkled with small white spots, or streaked with narrow whitish, irregular bands, or it may be of a diffuse grayish color. Microscopical examination shows this change to be due to an accumulation of cells resembling leucocytes, either along the portal vein, or diffusely through the liver tissue, or in small circumscribed masses. The amount of accumulation of these small cells varies much, but is sometimes so great as seriously to compromise the liver cells. The origin of these new cells is not yet definitely known. They may be, and doubtless in part are, brought to the organ through the portal vein; but they may, in part at least, be formed in the liver itself, possibly from the capillary endothelium.

In typhoid fever, smallpox, scarlatina, diphtheria, and measles, small circumscribed masses of spheroidal cells are sometimes found in the liver. These nodules differ in character, some are due to focal necroses, such as occur in various toxæmias with a later multiplication of cells or invasion of leucocytes. In some, as in typhoid fever, there is necrosis with proliferation of endothelium (see p. 241). Finally, some of the small masses of spheroidal cells encountered in the liver in infectious diseases are doubtless hyperplastic lymph-nodules.¹

TUMORS OF THE LIVER.

Tumors of the liver may be primary or secondary; the latter are most common.

Cavernous Angiomata.—These tumors, usually small, are most common in elderly persons and are of no practical significance. They may be situated at the surface (Fig. 483) or embedded in the organ, and are of a dark red color; sometimes sharply circumscribed by a connective-

¹ For changes in the blood in diseases of the liver consult *Ewing's "Clinical Pathology of the Blood."*

tissue capsule, sometimes merging imperceptibly into the adjacent liver tissue. Microscopically they consist of a congeries of irregular cavities (Fig. 239, p. 394) filled with blood and frequently communicating freely with one another. The walls of the cavities consist of connective tissue, often containing small blood-vessels, and are sometimes thick, sometimes thin. They are believed to be formed by dilatation of the liver capillaries, with subsequent thickening of their walls and atrophy of the adjacent liver cells. By the organization of clots within the blood cavities these tumors may be partially or entirely converted into masses of dense fibrous tissue.¹

Small **fibromata** and **lipomata** have been described, also **fibro-neuromata** of the sympathetic. **Endothelioma** and **hypernephroma** are recorded.

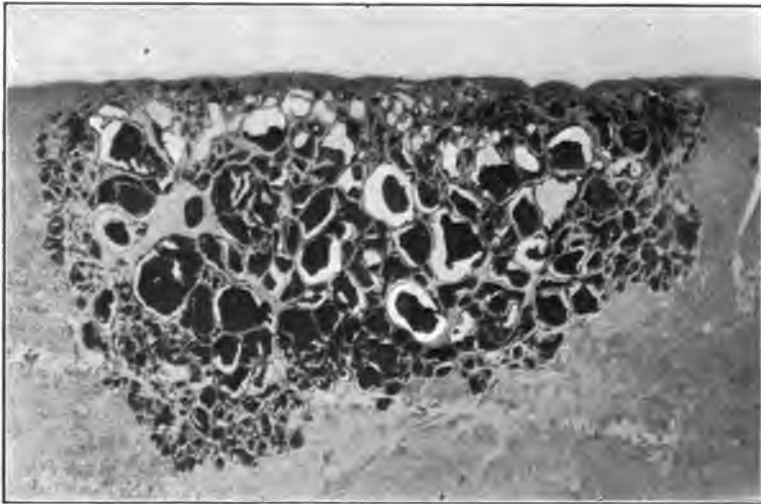


FIG. 483.—CAVERNOUS ANGIOMA OF THE LIVER.

Adenomata of the liver are of not infrequent occurrence. They are sometimes small and circumscribed, sometimes very large and multiple. They present two tolerably distinct types of structure. In one form the tissue presents essentially the same structure as normal liver tissue, except that the arrangement of the cells is less uniform and the cells are apt to be larger. They look like little islets of liver tissue, sometimes encapsulated and sometimes not, lying in the liver parenchyma. In the other form the cells are less like liver cells, are frequently cylindrical, and are arranged in the form of irregular masses of tubular structures with more or less well-defined lumina. These tumors are sometimes large and multiple, and in one case described by Greenfield there were metastatic tumors in the lungs. These tubular adenomata are in some

¹ See *Merkel, Ziegler's Beitr.*, Bd. xxxvi, p. 574, 1904.

cases so closely similar to some of the carcinomata as to be scarcely distinguishable from them, and seem, indeed, to merge into them.¹

Aberrant nodules of adrenal tissue have been found in the liver and may be mistaken for adenomata.² Cysts may develop in adenomata.³

Carcinomata are the most common and important of the liver tumors, and may be primary and secondary. Primary carcinomata of the liver are probably developed from the epithelium of the gall-ducts, and in some cases are arranged along the larger trunks. The cells are usually polyhedral, sometimes cylindrical, and may be arranged irregularly in alveoli or form more or less well-defined tubular structures.⁴

Secondary carcinoma of the liver, which is by far the most common, is usually due to the dissemination in the organ of tumor cells from carci-

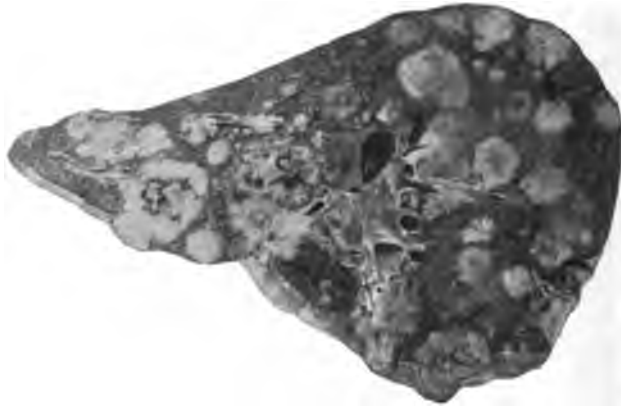


FIG. 484.—SECONDARY CARCINOMA OF THE LIVER.

The section is through the entire organ, showing carcinomatous tumors of various sizes and forms: some are white, some are dark red from hæmorrhage. The larger tumor at the left is softening at the centre.

nomata of the stomach, intestines, pancreas, or gall-bladder. But it may be the result of metastases from the mamma, œsophagus, uterus, and various other parts of the body. In secondary carcinoma the cells resemble more or less closely the type of those forming the primary tumor.

The form in which the carcinoma in the liver occurs varies considerably. Sometimes the tumors are single, but more often multiple (Fig. 484); they may be very large, or so small as to be scarcely visible to the naked eye; very frequently numerous small nodules are grouped in the periphery of a larger one. They are sometimes deeply embedded in the liver, sometimes they project from the surface. The liver is frequently and sometimes enormously enlarged. The nodules are usually whitish or

¹ *Sokoloff* has described an adeno-carcinoma of the liver with ciliated cells, *Virchow's Arch.*, Bd. clxii., p. 1, 1900, bibl. of allied tumors. See also *Herzheimer*, *Cbl. f. Path.*, Bd. xiii., 1902, p. 705. For a study of the origin and growth of liver adenoma see *Watzold*, *Ziegler's Beitr.*, Bd. xxxix., p. 456, 1906, bibl.

² See ref. *Nojes and Beer*, foot-note, p. 515.

³ See for cyst formation in the liver *Dmochowski and Janowski*, *Ziegler's Beitr. z. path. Anat.*, Bd. xvi., p. 102, 1894.

⁴ For a study of retrograde metastases from the stomach see ref. *Jacob*, foot-note, p. 666.

For a study of primary liver carcinoma see *Herzheimer*, *Cbl. f. Path.*, Bd. xvii., 1906, p. 724.

yellowish or pink in color or bile-stained, and they are often the seat of hæmorrhages, and may become softened at the centre, forming cysts filled with degenerated tumor tissue often mixed with blood. The nodules are sometimes hard, sometimes soft and almost diffuent. Fatty degeneration in the tumor is frequent, and may be recognized by yellowish streaks or patches on the sections. Owing to the degeneration and partial absorption of the central portions of the tumors, the nodules on the surface of the liver frequently present a shallow depression at the centre. The tumors may be sharply outlined against the adjacent liver tissue, or may merge imperceptibly into it. They may be so large or numerous as to occupy the greater part of the enlarged organ. The neighboring liver cells may be flattened and atrophic. The tumors may press upon the portal vein or its branches, or upon the gall-ducts, and thus seriously interfere with the functions of the organ. Sometimes, however, the tumors are very large and numerous without apparent interference with the function of the liver. *Melanotic carcinomata* sometimes occur in the liver, most frequently as secondary tumors.

In some cases, instead of forming separate, distinct nodules, the cancerous growth develops in the form of a diffuse infiltration of the organ, so that the often greatly enlarged liver is irregularly mottled with white and reddish brown masses, and may then somewhat resemble certain forms of chronic interstitial hepatitis.

Sarcomata.—Spindle- and round-celled sarcoma and angio-sarcoma are among the more frequent types of the rarely occurring primary sarcomata of the liver.¹ Spindle-celled, melanotic, and telangiectatic sarcomata may occur in the liver as secondary tumors.² Secondary **myxomata** and **chondromata** have also been described, but they are very rare. **Cavernous lymphangiomata** have been described in a few cases.

CYSTS OF THE LIVER.

Cysts, usually of small size, may be formed by dilatation of the bile-ducts. They may be multiple and contain serum, mucus, and degenerated epithelium. Single cysts, apparently unconnected with the gall-ducts, are occasionally found in the connective tissue of the liver. They may be lined with ciliated epithelium.

The liver is sometimes the seat of larger and smaller single or **multiple cysts**, varying from microscopical size up to that of a pea, and sometimes larger. They are sometimes associated with multiple cysts of the kidney and with congenital anomalies in other parts of the body. They may be associated with aberrant bile-ducts within the liver in which the studies of Moschcowitz show that they probably originate.³ A teratoma of the liver has been described by Misick.⁴

¹ *Arnold*, Ziegler's Beitr. z. path. Anat., Bd. viii., p. 123, 1890; also, for later summary of primary liver sarcoma, *Marx*, Cbl. f. Path., Bd. xv., p. 433, 1904.

² See *Hektoen* and *Herrick*, Trans. Assn. Am. Phys., vol. xiii., p. 385, 1898.

³ See for study of non-parasitic cysts of the liver, with bibl., *Moschcowitz*, Am. Jour. Med. Sci., vol. cxxxi., p. 674, 1906.

⁴ *Misick*, Jour. Path. and Bact., vol. v., p. 128, 1898.

Foamy Liver.—Occasionally the liver is found at the autopsy, even if this be made but a few hours after death, more or less completely riddled with small, irregular-shaped cavities, from the size of a pin's head to that of a pea. These holes are due to the accumulation of gases in the liver, formed by the *Bacillus aërogenes capsulatus*. This is the so-called "foamy liver" (Fig. 485).

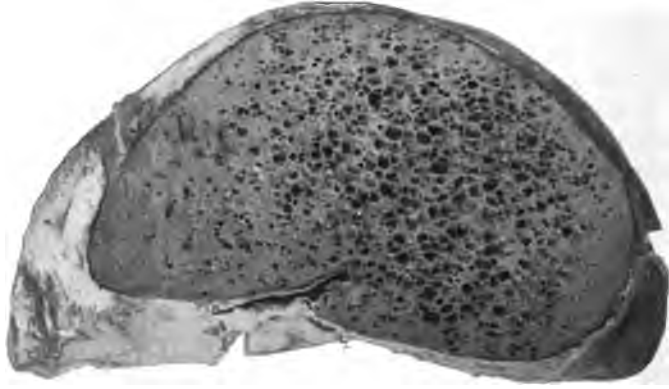


FIG. 485.—"FOAMY LIVER."

The liver is riddled with small holes formed by the accumulation of gas developed by *B. aërogenes capsulatus*—"gas bacillus."

PARASITES.

Echinococcus.—This parasite is the most common and important of those which occur in the human liver. It forms the so-called *hydatids* of the liver. These represent one of the developmental stages of the small tapeworm of the dog, *Tænia echinococcus* (see p. 125). The cysts in the liver may be very small and multiple, but they may be as large as a man's head or larger. The liver may be greatly increased in size, and the tissue about the cysts atrophied. The liver itself furnishes a connective-tissue capsule, within which is the translucent, lamellated membrane furnished by the parasite. On the inside of this we may find a layer of cells, granular matter, and a vascular and muscular system belonging to the parasite. Projecting from this inner capsule are the brood capsules and heads or scolices of the immature tapeworm. The scolices may become detached from the wall and lie free in the cavity, which is filled with a transparent or turbid fluid. Not infrequently the cysts are sterile, and are then simply filled with clear or turbid fluid; or the embryos may have died and disintegrated, and their detritus, including the hooklets, may be intermingled with the fluid contents of the cysts. The contents of the cysts may be mixed with fat, cholesterin crystals, pus, bile, or blood; or form a grumous mass, in which we may or may not be able to find the hooklets of the scolices or fragments of the lamellated wall. The connective tissue of the walls of the cysts may be greatly thickened, or it may be calcified.

In other countries the lesion is much more common and frequently

more formidable than in the United States. The cysts reach an enormous size, the veins of the liver may be compressed and filled with thrombi, the bile-ducts compressed and ulcerated. So much of the liver tissue may be replaced by the hydatids that the patient may die from this cause alone. Very frequently there is local peritonitis, and adhesions are formed between the liver and the surrounding parts. In some cases the cysts rupture, and their contents are emptied into the peritoneal cavity, the stomach, the intestines, the pleural cavity, or the lung tissue. Sometimes the cysts perforate the bile-ducts, the vena cava, or some of the branches of the portal or hepatic veins; or the abdominal wall is perforated and a fistula formed between the cavity in the liver and the surface.

Echinococcus multilocularis (see p. 126), which is apparently an abortive form of the above species, is very rare in the United States (Fig. 486).¹

Distoma hepaticum, **D. sinense**, **D. lanceolatum**, may occur in the gall-ducts and gall-bladder. **D. sinense** occurs especially in the East, and has been found in great numbers in the bodies of Chinamen. **D. hæmatobium** is very common in Egypt and Abyssinia, occurring in the blood-vessels of the liver.

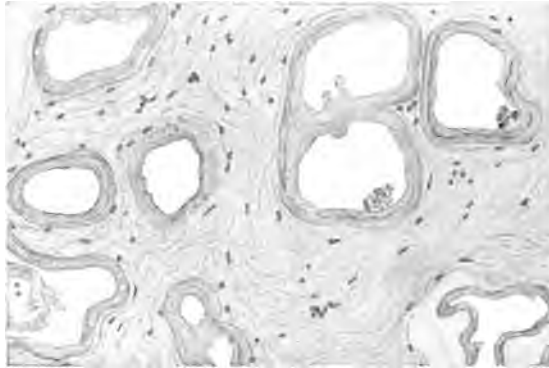


FIG. 486.—ECHINOCOCCUS MULTILOCULARIS OF THE LIVER.

A section of a small portion of the cystic and fibrous growth in the liver. There were no hooklets within the cysts in this case, but the delicately lamellated character of the lining membrane sufficed for a diagnosis.

Pentastoma denticulatum is the undeveloped form of *Pentastoma tænioides*, a parasite which inhabits the nasal cavity of dogs and some other animals. In the liver of man it usually occurs in the form of small, rounded, calcified cysts. The cysts may contain fat, calcareous matter, and the remains of the dead parasite, among which the hooklets may be found.

Ascaris lumbricoides sometimes finds its way from the intestines into the bile-ducts. It may cause no disturbance here, but in some cases the worms have been present in large numbers and caused occlusion, dilata-

¹ See Oertel, Yale Med. Jour., vol. v., p. 233, 1899; consult also monograph by Posselt, 1900.

tion, and ulceration of the biliary passages, and have led to the formation of abscess of the liver.

Coccidium oviforme, the very common parasite in the rabbit's liver, has been found a few times in the liver of man.

LESIONS OF THE BILIARY PASSAGES AND THE GALL-BLADDER.

Perforation and rupture of the gall-bladder may occur under various conditions and is usually followed by peritonitis.¹

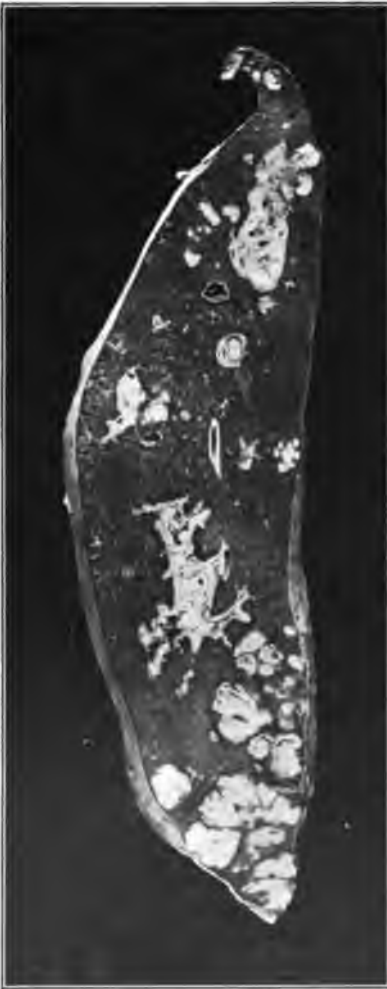

FIG. 487.—SUPPURATIVE INFLAMMATION IN THE GALL-DUCTS—CHOLANGITIS.

Catarrhal inflammation of the gall-ducts (cholangitis) most frequently involves the lower portion of the common duct and the gall-bladder. In the acute form it usually leaves but few changes appreciable after death. An abnormal coating of mucus, and sometimes congestion of the blood-vessels, are almost the only post-mortem lesions. Owing to the swelling of the mucous membrane and the accumulation of mucus in the lumen, the ducts may be temporarily occluded, but this occlusion may not be evident after death. If, however, the inflammation becomes chronic, the walls of the bile-ducts may become thickened and their lumina more or less permanently obstructed (Fig. 487). In consequence of this, dilatation or ulceration of the bile ducts may ensue. Temporary obstruction of the bile ducts may produce marked pigmentation of the liver, owing to the accumulation of pigment granules in the liver cells, particularly in the vicinity of the capsule of Glisson, and jaundice of the entire body.

The *gall-bladder* may be inflamed by itself—*cholecystitis*—or in connection with inflammation of the biliary passages. If the

disease is chronic the wall of the bladder may be thickened and bound to adjacent parts by fibrous tissue; polypoid growths may occur in the

¹ See *Machard*, Arch. gén. de méd., t. iv., p. 159, 1900, bibl.

mucosa; the duct may be occluded; dilatation, ulceration, the formation of gall-stones, calcification, and atrophy may ensue.

Inflammation of the stomach and duodenum, hyperæmia and inflammation of the liver, concretions, and parasites frequently accompany catarrhal inflammation of the biliary passages, but it may occur without these.

Suppurative and Croupous Inflammation of the Bile-Ducts (Cholangitis) and Gall-Bladder (Cholecystitis).—The walls of the ducts may be covered or infiltrated with a fibrinous or a purulent exudate; they may ulcerate.

These lesions occur most frequently in connection with obstruction of the bile-ducts by gall-stones or otherwise, and in typhoid and typhus



FIG. 488.—SUPPURATIVE INFLAMMATION OF THE GALL-DUCTS IN THE LIVER—CHOLANGITIS. The suppurative foci are almost coalescent in the infected region. This lesion was secondary to suppurative inflammation in the larger gall passages with the presence of gall-stones.

fever, pyæmia, and cholera; or they may be due to the extension of inflammatory processes from without. They also occur under unknown conditions.

In many cases of inflammation of the gall-ducts the *Bacillus coli communis*, in fewer the pyogenic streptococcus and staphylococcus, are apparently concerned.

Suppurative inflammation may lead to perforations of the ducts or bladder, with escape of bile and peritonitis; or fistulous openings between the gall-bladder and the duodenum, colon, and stomach, or through the abdominal wall. Or the inflammation may extend to the liver tissue and produce abscesses. Under the latter conditions there may be a series of small abscesses ranged along the walls of the suppurating gall-ducts

(Fig. 488). In more advanced stages the abscesses may become large and communicate with one another, so that a considerable portion of the liver may be occupied by a series of communicating cavities with ragged walls, containing pus and detritus of liver tissue more or less tinged with bile.

Such abscesses may become more or less completely enclosed by connective-tissue walls. The portal vein may also become inflamed, and perforations may be formed between it and the bile-ducts. The excitants of these inflammatory processes in the gall-ducts and gall-bladder are

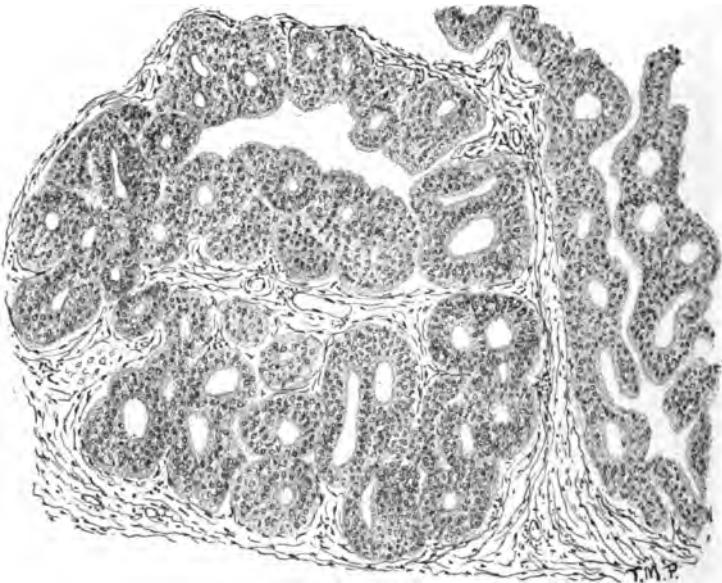


FIG. 489.—ADENOMA OF THE GALL-DUCT.

This section is from a small tumor growing within one of the gall-ducts in the liver.

probably usually bacteria. Those which have been most frequently found are the "pyogenic cocci,"¹ the colon and typhoid bacilli, and the pneumococcus. It should be borne in mind that post-mortem invasion of the gall-bladder and passages by bacteria may take place early.

Constriction and Occlusion of the Bile-Ducts.—This may be produced by inflammation of the ducts themselves, by new growths in their walls, by calculi or parasites in their lumina, by changes in the hepatic tissue in chronic and acute hepatitis, by aneurisms, or by pressure on the duct from without, as by tumors in the head of the pancreas, etc.

The obliteration of the smaller bile-ducts produces no marked lesions. When the ductus communis of the hepatic duct is obstructed, the ducts throughout the liver are frequently dilated and the liver tissue is bile-stained. The liver may undergo atrophy and the whole body be intensely

¹ For a study of gall-bladder infections consult *Cushing*, Johns Hopkins Hosp. Bull., vol. x., p. 166, 1899, bibl. Also *Gilbert and Lippmann*, Comptes rend. de la Soc. Biol., Nov. 8th, 1902, p. 1189.

jaundiced. When the cystic duct is obstructed the gall-bladder is dilated.¹

Dilatation of the Bile-Ducts is usually produced by strictures in the ways just mentioned, or by calculi. When calculi have produced the dilatation this condition may sometimes continue after they have found their way into the intestines. Sometimes, however, there is very marked dilatation of the bile-ducts without evident present or past obstruction. The dilatation may affect only the common and hepatic ducts, or it may extend to the smaller ducts in the liver, which are then dilated uniformly or in sacculated forms. They may contain bile, mucus, or calculi. The liver is at first enlarged, but may afterward atrophy. The gall-bladder may be dilated in consequence of obstruction of the common or the cystic duct. In the latter case it may reach an immense size and form a large tumor in the abdominal cavity. The dilatation is generally uniform, the bladder retaining its normal shape; sometimes, however, there are diverticula, which are usually produced by calculi. If the obstruction to the hepatic duct is incomplete or movable the gall-bladder may contain bile, and often calculi. If the obstruction is complete the contained fluid may gradually lose its biliary character and become a serous or mucous fluid of a light yellow color—*hydrops cystidis felleæ*. The walls of the bladder may be of normal thickness, or thinned, or thickened, or calcified. If the obstruction is due to a calculus, this may pass into the intestine and the gall-bladder be suddenly emptied. Usually the bladder fills again, owing to its loss of contractile power.

TUMORS OF THE GALL-BLADDER AND LARGER GALL-DUCTS.

Small **fibromata** have been described in the gall-bladder and in the common duct, but they are very rare. The most common tumors are **carcinomata**. These may be primary or secondary, and present the usual structural variations. The cells may be cylindrical or polyhedral; or they may present the characteristics of gelatinous cancer. Primary carcinomata and adeno-carcinomata of the gall-bladder and larger gall-ducts are not uncommon, and are frequently associated with calculi.² Not infrequently the pancreatic and common ducts are both involved, and it is difficult to say whether the tumor is primarily in the head of the pancreas or in the gall-duct. The bladder and ducts may also be secondarily involved in carcinomata of the stomach, liver, and duodenum. **Adenoma** and **papilloma** of the gall-ducts are of occasional occurrence (Fig. 489).

BILIARY CALCULI. (Cholelithiasis.)

These bodies are of common occurrence. They are found usually in the gall-bladder, sometimes in the hepatic, cystic, and common ducts; less frequently in the small ducts of the liver. In the gall-bladder from

¹ For a study of changes in the liver consecutive to obliteration of the bile ducts see *Géraudel*, *Jour. d. Phys. et Path. gén.*, t. viii., p. 69, 1906.

² See *Warthin*, *Phila. Med. Jour.*, vol. vi.; pp. 38, 82, and 120, 1900, bibli.

1 to 7,800 calculi have been counted. They vary in size from that of a pin's head to that of a hen's egg, or they may be larger. Single gallstones are usually spheroidal or ovoidal; when multiple they are usually flattened at the sides or faceted (Fig. 490).

They may be composed:

1. Principally of *cholesterin*, and may be of pure white color, or tinged with various shades of yellow or brown by bile pigment. The fractured surface shows a radiating crystalline structure.

2. Of *cholesterin*, *bile pigment*, and salts of *calcium* and *magnesium*. These are usually dark colored, brown, reddish black, or green, and may be spheroidal or faceted, smooth or rough on the surface; the fractured surface is usually radiating crystalline. This is the most common form.

3. Principally of *bile pigment*. Such calculi are rare, usually small, very dark colored, and not numerous.



FIG. 490.—BILIARY CALCULI.

The smaller calculi show the faceted character; the larger, cut across, show the lamellation.

4. Of *calcium carbonate*. These are rare, have a nodular surface, and a clear crystalline, not radiating fracture.

Most calculi are formed around a central mass, sometimes called the nucleus, which may consist of cholesterin, bile pigment, mucus, or epithelium, or more rarely of some foreign body. Thus a dead parasite, a needle, and fruit seeds may serve as nuclei. The body of the calculus may be homogeneous, or lamellated, or crystalline.

Biliary calculi in the gall-bladder may produce no symptoms and be discovered only after death. In the hepatic and common ducts they may obstruct the flow of bile and lead to fatal jaundice; or they may pass from time to time into the intestine, producing biliary colic. If they are impacted in the cystic duct they may lead to dilatation of the gall-bladder. They may get into the duodenum by ulceration through the walls of the ducts or gall-bladder, or in the same way into the peritoneal

cavity. Gall-stones which get into the intestinal cavity usually pass off without doing any further injury, but very large calculi may cause occlusion of the gut with fatal results. The rôle of micro-organisms in the formation of gall-stones has been the subject of significant studies.¹

¹ Consult *Mignot*, Arch. gén. de médecine, 1898, t. ii., p. 129 and 263; also *Cushing*, Johns Hopkins Hosp. Bull., vol. x., p. 166, 1899; also *Mieczkowski*, Mitth. a. d. Grenzgeb. d. Med. u. Chir., Bd. vi., p. 307, 1900.

CHAPTER IX.

THE URINARY ORGANS.

The Kidneys.

Malformations.

BOTH kidneys may be absent in connection with extensive malformation in fœtuses which are not viable.

Absence of one kidney is not uncommon, the left kidney being more frequently absent than the right. The absence of the kidney may be complete, the ureter being also absent; there may be an irregular mass of much-atrophied kidney tissue with connective tissue and fat, or there may be only a little mass of connective tissue and fat representing the kidney, and a ureter running down to the bladder. The single kidney which is present is usually much enlarged. It may be in its natural position or displaced downward. When both kidneys are present one of them may be much larger than the other. One kidney may have two pelves or two ureters.

A frequent malformation is the so-called *horseshoe kidney* (Figs. 183 and 491). The lower ends of the kidneys are joined together by a commissure. The commissure

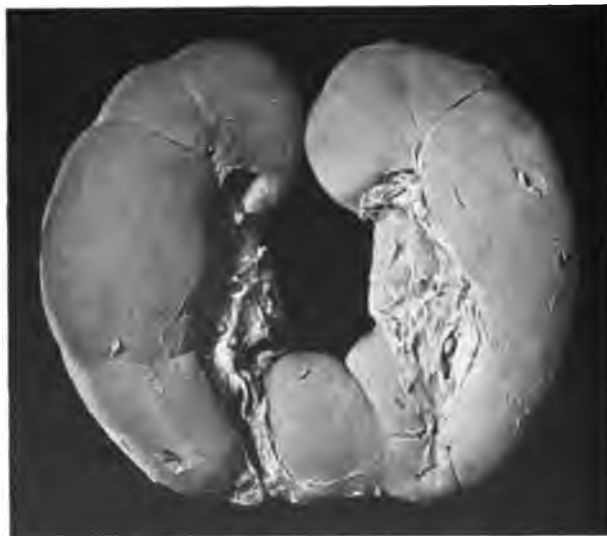

FIG. 491.—HORSESHOE KIDNEY.

is usually composed of kidney tissue, but sometimes of connective tissue. The two kidneys may be normal, except for the commissure; or their shape, the arrangement of the vessels and ureters, and the position may be unnatural. The two kidneys may be united throughout so as to look like a single misshapen kidney with two or more pelves

and irregular blood-vessels. The united kidneys may be both situated on one side of the vertebral column or in the pelvis.

The foetal lobulation of the kidney frequently persists during adult life (Fig. 492).

Changes in Position.

The kidneys may be placed in an abnormal situation, in which they are either fixed or movable.

The change in position is either lateral or downward. When displaced downward the kidney may be over the sacrum or below this in the cavity of the pelvis. The

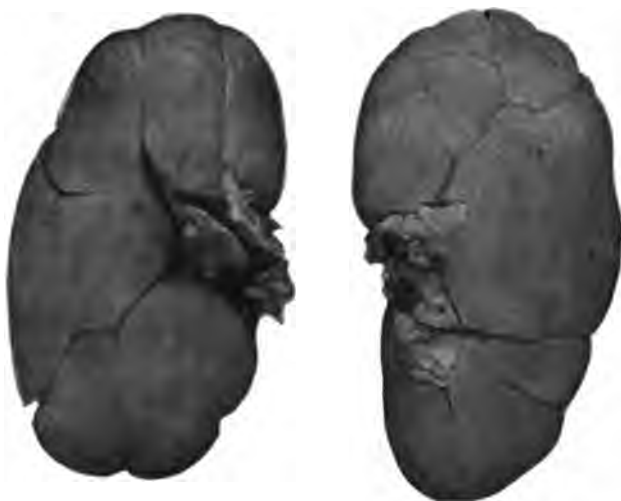

FIG. 492.—FŒTAL LOBULATION OF KIDNEYS IN ADULT.
The kidneys were of normal size.

vessels also have an irregular origin and distribution. The kidney is firmly attached in its abnormal position.

Movable or wandering kidneys are found in adult life as a result of tight lacing, of pregnancy, of overexertion, and of unknown causes. They are more common in females than in males, and the right kidney is most frequently involved. The blood-vessels become lengthened and the attachments of the kidneys longer and looser.

COMPENSATORY HYPERTROPHY OF THE KIDNEY.

In congenital absence of one kidney or in post-embryonal life when one kidney is involved in lesions which seriously interfere with its function, the other organ may increase in functional capacity through an hypertrophy and hyperplasia of its gland cells. A similar alteration may take place in the sound parts of an organ partially compromised by structural lesions.¹ The marks of hypertrophy are not evident in the glomeruli and convoluted tubules. The epithelial cells are larger and increased in number; the tufts of the glomeruli are also enlarged.

¹ For a study of this condition see *Sacerdotti*, *Virchow's Arch.*, Bd. cxlvi., p. 267, 1896, bibl. Consult also for general consideration of hypertrophy *Thoma*, "Text-book of General Pathology," vol. i., p. 448, Eng. trans.

DISTURBANCES OF CIRCULATION.

Anæmia of the kidney occurs in general anæmia: it may be associated with various forms of diffuse nephritis. Local anæmia may be due to thrombosis or embolism.

Acute Hyperæmia—Acute Congestion.—This may occur in early phases of an acute inflammatory process or after the ingestion of irritant poisons. The kidneys may be swollen, the vessels distended, and bloody fluid exude from the cut surfaces. There may be extravasation of red blood cells from diapedesis.

Chronic Hyperæmia—Chronic Congestion.—This may occur in connection with a similar condition in the other viscera when the circulation is impeded through uncompensated lesions of the heart and lungs, such as chronic endocarditis involving the aortic and mitral valves, cardiac dilatation, aortic aneurism, emphysema, large accumulations of fluid in the pleural cavities; or it may be associated with obstruction of the renal vein or inferior vena cava by thrombosis or pressure from tumors, etc. The kidneys in this condition are, when typical, slightly or considerably enlarged, increased in weight, hard, and dark red in color with capsule not adherent and surface smooth. The congestion is most marked in the capillaries of the glomeruli, which are widely dilated, often with thickened walls, in the interlobular veins, the vasa recta, and the stellate veins of the cortical surface.

The epithelium of the convoluted tubules may be swollen; or it may be much flattened so that the lumen of the tubule is enlarged. If the congestion persists, there is hyperplasia of the interstitial tissue of the kidney with degeneration of the epithelium, the formation of casts, atrophy of the tubules, etc. Chronic congestion may lead to chronic diffuse nephritis.¹

Embolism, Thrombosis, and Infarction.—If the renal artery or one of its branches be plugged by an embolus or thrombus, an anæmic infarct of the region is the result. There may be one or several such infarcts which are usually more or less wedge-shaped, the apex directed inward corresponding to the vascular territory compromised. They are pale or yellowish, hard, and, as inflammatory reaction sets in, may be surrounded by a red hyperæmic zone.

Within the limits of the infarct, necrosis of epithelium or of the entire mass of involved tissue may take place with such subsequent alterations as have been already described on page 29.

The seat of old and healed infarcts may be indicated by small fibrous cicatrices.²

Hæmorrhagic infarcts in the kidney are rare. Infarcts may become the seat of gangrene when putrefactive bacteria gain access to them; or suppurative inflammation with the formation of abscesses may occur.

¹ For a study of theories of renal secretion see *Lamy and Mayer*, Jour. de Phys. et Path. gén., t. viii., p. 660, 1906.

² For a study of the regenerative capacity of the renal epithelium in infarcts see *Thorel*, Virchow's Arch., Bd. cxlvi., p. 297, 1896, bibl.; also *Thorel*, Deutsch. Arch. f. klin. Med., Bd. lxxvii., 1903.

Embolism of the renal artery may result in necrosis of the entire kidney. Thrombosis of the renal vein may be induced by the pressure of tumors, either on this vessel or on the vena cava; or it may occur in cachectic conditions.

ALBUMINURIA AND CASTS.

Albuminuria.—Albuminous material or serum not infrequently passes out of the blood-vessels of the kidneys, either through the glomeruli or the tubules, and mingles with the excreted substances. While this may occasionally occur under conditions which cannot be regarded as abnormal, it is common in many diseases of the kidney and is frequent without demonstrable kidney lesions in fevers, infectious diseases, abnormal conditions of the blood, various forms of poisoning, disturbances of the circulation, etc. Albuminous material may also be set free by abnormal metabolism or disintegration of the renal epithelium.

In albuminuria with pronounced kidney lesions there are usually well-defined alterations in the capillaries of the tufts and in their epi-

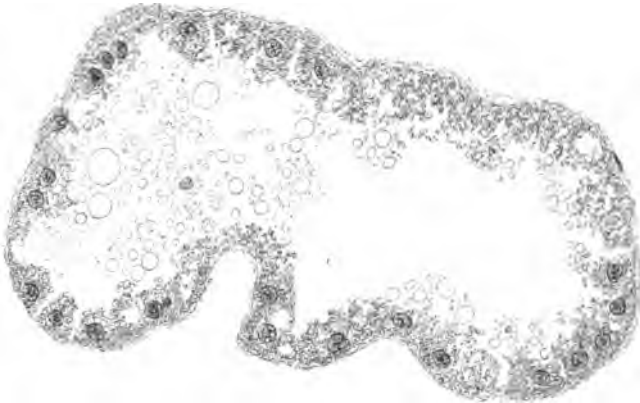


FIG. 493.—HYALINE GLOBULES IN URINIFEROUS TUBULE.
There are also degeneration and disintegration of the epithelium.

thelial investment. There may be thrombi in the capillaries; their walls may be thickened; the flat epithelium covering them may be swollen or fatty, or may peel off, or it may proliferate. In the kidneys of cases of pronounced albuminuria, preserved in alcohol or other fixatives which coagulate albuminous material, this substance may be seen within Bowman's capsule or in the lumina of the tubules as fine or coarse granules. Albuminous material in the tubules may form casts (see below), or when the conditions are favorable fibrillar fibrin may form.

Casts.—Albuminous material which under various abnormal conditions has escaped from the blood-vessels in solution may coagulate, especially in the lumina of the tubules, forming the more or less cylindrical or globular structures called casts. These may be homogeneous in structure—hyaline casts; or the albuminous material of which they

are formed may be mingled with the products of degeneration and disintegration of epithelial cells, either from the glomeruli or from the tubules; or with red blood cells, or leucocytes, or exfoliated epithelial cells. In this way *granular casts*, *epithelial casts*, *blood casts*, etc., are formed. The epithelium of the tubules may peel off in masses, forming cast-like cell structures. Homogeneous globules of various sizes may be formed in the tubular epithelium which is yet in place, and, as the cells degenerate

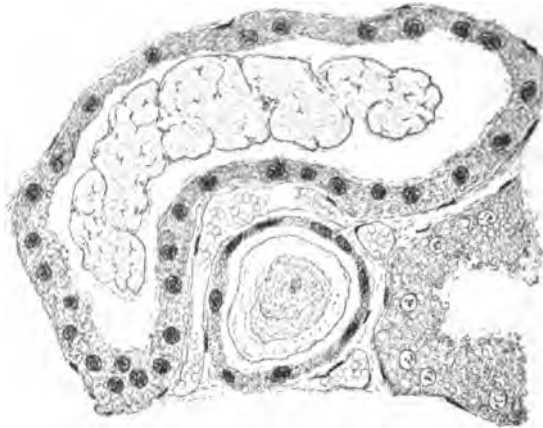


FIG. 494.—HYALINE CASTS IN URINIFEROUS TUBULE.
The epithelium is flattened in the tubules containing the casts.

and disintegrate, such homogeneous globules may collect in the lumina of the tubules (Fig. 493) or they may fuse to form hyaline casts (Fig. 494). Homogeneous casts giving the micro-chemical characters of amyloid are of occasional occurrence in the tubules.

Casts and cell detritus may form both in the cortical and medullary tubules and may pass out of the organ with the urine.

NECROSIS.

Necrosis of the epithelium of the kidney of varying extent may occur in disturbances of the circulation by thrombosis, degenerations, etc., in acute infectious diseases, in various nutritional disorders, such as gout, diabetes, etc., or auto-intoxications, as well as in poisoning by various substances, cantharidin, sublimate,¹ chromates, chlorates, etc. In sublimate and oxalic-acid poisoning, calcification (Figs. 30 and 31) may be associated with the necrotic process.

The extent of the lesion varies greatly. In some instances a large part of the epithelium of the convoluted tubules may be necrotic without marks of inflammation. In other cases the lesion involves the tubules in limited regions. It is suggested that certain forms of extensive necrosis of renal epithelium are the analogues of some forms of acute yellow

¹ For studies on sublimate poisoning see ref. to *Neuberger and Elbe*, foot-note, p. 753.

atrophy of the liver.¹ In fact the kidney lesion may accompany acute yellow atrophy.

DEGENERATION.

Albuminous Degeneration (Parenchymatous Degeneration—Acute Degeneration).—This form of degeneration is most common in the acute infectious diseases, such as diphtheria, scarlatina, measles, typhoid fever, yellow fever, and in many forms of septicæmia and toxæmia. It usually accompanies similar lesions in other viscera. In moderate degrees of the lesion, the epithelium, particularly of the convoluted tubules, is swollen and more coarsely granular than normal (Fig. 495). In more

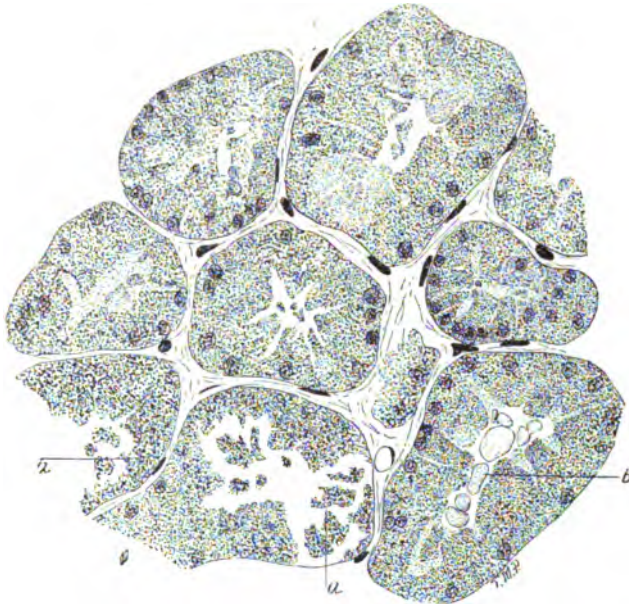


FIG. 495.—ALBUMINOUS DEGENERATION OF THE KIDNEY (Acute Parenchymatous Degeneration). From a case of yellow fever. *a*, The swollen and granular epithelium peeling off and disintegrating; *b*, hyaline material in the lumen of the tubule.

pronounced lesions, in addition to simple albuminous degeneration, the epithelium may become more or less filled with minute fat droplets, or the cells may disintegrate and peel off, or they may become necrotic and the nuclei fail to stain. The cell body may then undergo coagulation or disintegrate.

The gross appearance of the kidneys varies with the degree and extent of the degeneration. The kidney may be slightly or considerably enlarged. On section the cortex is usually thickened and pale with obliteration of the normal cortical markings. The capsule of the kidney

¹ For a *résumé* of necrosis of renal epithelium see *Hewitt*, Johns Hopkins Hosp. Bull., vol. xvii., p. 272, 1906.

is not abnormally adherent. When there are other associated or antecedent lesions in the kidney, the gross appearance of the organ varies.

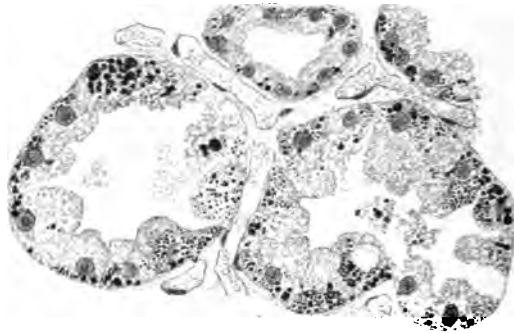


FIG. 496.—FATTY DEGENERATION OF THE EPITHELIUM IN THE CONVOLUTED TUBULES OF THE KIDNEY. The fat droplets are stained black by osmic acid.

Fatty Degeneration.—This may occur in those diseases of the blood or circulatory system in which general nutrition suffers; in infectious diseases often associated with or following albuminous degeneration; in

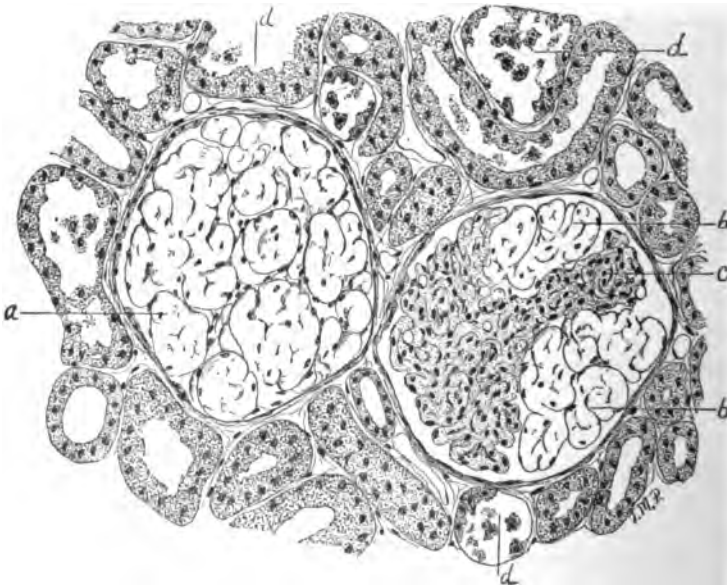


FIG. 497.—AMYLOID DEGENERATION OF TUFT CAPILLARIES IN THE KIDNEY. *a*, The tuft is completely transformed into a waxy mass; *b*, portions of tuft waxy; *c*, tuft capillaries normal; *d*, convoluted tubule with disintegrating epithelium.

various cachexiæ; in acute and chronic forms of diffuse kidney disease, and in poisoning by phosphorus, arsenic, sublimate, etc.

The degeneration may be diffuse and widespread or it may occur in

patches. If diffuse, the cortex in which it is most marked is usually more or less thickened, opaque, and yellowish; if in patches, there are opaque yellow streaks or spots in the cortex. But these appearances are often obscured by various other lesions. If the degeneration be moderate in degree, there are larger and smaller fat droplets, usually most abundant in the basal portion of the epithelium of the convoluted tubules (Fig. 496). In more marked degeneration, the cells of the convoluted tubules may be filled with fat droplets and may peel off, or they may disintegrate, setting the fat free in the lumen of the tubules. The degeneration may involve the tuft and capsule epithelium as well as

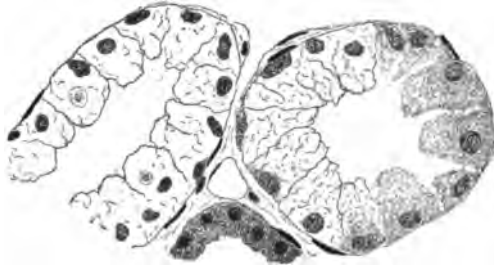


FIG. 498.—GLYCOGEN DEGENERATION OF THE EPITHELIUM OF THE KIDNEY IN DIABETES.

that of the collecting tubes, and fat droplets may be found free or in cells in the interstitial tissue.

Amyloid Degeneration.—This is usually associated with amyloid degeneration elsewhere in the body, and commonly occurs in kidneys which are already the seat of various forms of chronic lesion. Usually the kidney is enlarged, the section is shining or translucent, the cortex is thick and pale, the glomeruli are often unusually plain. The capillaries of the tufts (Fig. 497) and the vasa recta are most often involved. If the kidney be otherwise altered, the gross and microscopic appearances vary.

Glycogen Degeneration of the epithelium may take place in diabetes mellitus. It is usually most marked in the cells of Henle's loops (Fig. 498).

Calcification may occur in chronic inflammatory lesions or in old infarctions, in the intertubular tissue of the medulla in the aged, and in casts in the collecting tubes, and is especially well marked in degenerated and necrotic epithelial cells in sublimate poisoning (Figs. 30 and 31).¹

INFLAMMATION.

General Considerations.

Many of the alterations in the kidney which are commonly considered inflammatory are in fact degenerative, and these degenerative changes are often so important and so conspicuous in the lesions as fairly to dominate the gross and microscopic appearances. The processes in the kidneys which may be properly considered inflam-

¹ See *Neuberger*, *Ziegler's Beitr.*, Bd. vi., p. 429, 1889; also *Elbe*, *Virch. Arch.*, Bd. clxxxii., p. 445, 1905.

matory are either exudative or productive, so that the apparently complex series of kidney changes which are grouped under the name nephritis, or Bright's disease, are really phases of *exudative* or *productive inflammation*, or both, associated with *degenerative processes*.

Whether the kidneys be large or small, white or red or mottled, smooth or rough; whether the disease be acute or chronic, it is always these comparatively simple processes, varying in extent, in duration, in intensity, and in relative predominance, which are to be taken into the account in the study of inflammation of this organ.

There are perhaps no lesions whose classification has seemed beset with such difficulties as those of the kidneys. This is largely due to a failure to realize that the various phases of inflammation and degeneration do not stand apart as independent processes or lesions, but are closely associated and often merge. It is difficult, perhaps impossible, to make a classification which shall meet the requirements of the clinic, the limitations of urinary tests, and at the same time accord with the revelations of the autopsy and the microscope.

One of the difficulties in framing a classification of kidney lesions is that there are many and serious abnormalities in the function of the kidney which do not find expression in such structural changes as we can at present recognize. Our knowledge of such of the minute structural lesions in the renal epithelium as are not manifested by alterations in the size and form and organic integrity of the cell is, in fact, very meagre, so that the attempt to classify inflammatory lesions of the kidney upon both clinical and morphological data often leads to conjecture or confusion, frequently to both. Considering the scope of this book and our present purpose, it seems wiser to set forth here as concisely as possible the essential character of the lesions in acute and in chronic phases of inflammation and degeneration in the kidney based upon morphological rather than upon clinical data.

It is convenient to divide the acute inflammatory processes of the kidneys into two forms, *Suppurative Nephritis* and *Acute Diffuse Nephritis*.

SUPPURATIVE NEPHRITIS.

Suppurative inflammation of the kidney may follow injury with local infection. It is, however, most often due to the presence of bacteria, commonly the pyogenic cocci, which have been brought through the blood-vessels from a remote infective focus, as in ulcerative endocarditis, septic phlebitis, etc.—*embolic infection*. Or, on the other hand, the bacterial excitant may be transmitted to the kidneys through the urinary passages—*ascending infection*.

Traumatic lesions of the kidney may lead to suppurative nephritis either through direct infection of the wound or by the establishment of local vulnerability¹ to the action of bacteria which may later gain access to the injured tissue through the circulation. After infected wounds or injuries of the kidney, large abscesses may develop, or nearly the whole organ may be converted into a mass of pus, blood, and disintegrated tissue.

In the *embolic type* of suppurative nephritis, small abscesses are formed most frequently in the cortex. Where bacteria lodge and grow in the tissue there is at first circumscribed hyperæmia or hæmorrhage and necrosis, with subsequent gathering of leucocytes and finally the disintegration of tissue and the formation of abscess. Such kidneys present to the naked eye on section small spots—or in the medulla, streaks—

¹ See ref. to Cheesman and Meltzer and to Brewer, foot-note, p. 152.

which are red or gray or yellow, depending upon the degree of advancement of the lesion. In such areas the bacteria may be readily demonstrated, sometimes in early stages in dense masses in the capillaries and other smaller vessels, or later scattered through the necrotic and disintegrating tissue (Fig. 119, p. 207). Embolic abscesses are commonly developed in both kidneys and by extensive coalescence may give rise to large abscesses. There is reason to believe that in certain forms of septicæmia bacteria may secure a foothold in the tubules, not as emboli,

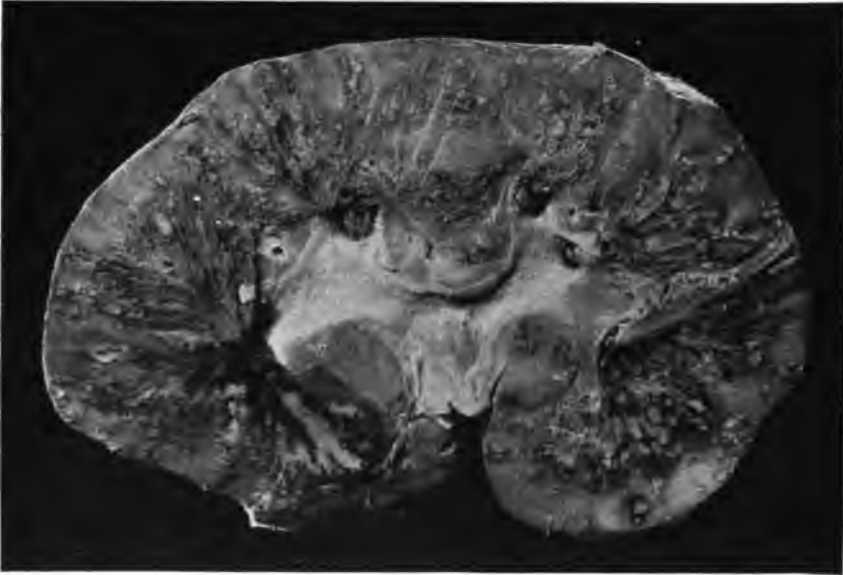

FIG. 499.—SUPPURATIVE NEPHRITIS.

Developed from infection by way of the urinary passages (so-called "surgical kidney").

but through excretion.¹ In such cases the suppurative foci may be at first limited to the medulla.

Ascending Infection.—In suppurative nephritis associated with a similar process in the ureter, bladder, etc., the medullary portion of the kidney is usually earliest involved, and then the elongated form of the suppurative areas (Fig. 499) corresponds to the grouping of the tubules in this region.²

Whatever the form in which it may manifest itself, suppurative inflammation of the kidney is commonly induced by some one or combination of the pyogenic micro-organisms which may lodge within it under favorable conditions. Thus *Streptococcus pyogenes*, *Staphylococcus*

¹ For study of excretion of bacteria by kidney see *Asch*, Cbl. f. Kr. d. Harn- u. Sex.- Org., Bd. xiii., 1902, pp. 249 and 324. Also reference p. 151.

For study of elimination of pigment by kidney see *Carter*, Jour. Am. Med. Assn., vol. xii., p. 1248, 1903.

² For further details concerning suppurative nephritis consecutive to similar processes in adjacent organs see below.

pyogenes, *Bacillus coli communis*, *Bacillus pyocyaneus*, *Bacillus proteus*, the pneumococcus, the typhoid bacillus, and others, may be found in the suppurative foci. Sometimes, however, especially in the more chronic processes, micro-organisms are not demonstrable.

ACUTE DIFFUSE NEPHRITIS.

This process may occur in acute infectious diseases; it is especially common in scarlatina and not infrequent in diphtheria, typhoid fever, the exanthemata, and malaria, and in septicæmia due to various bacterial excitants.

The lesions of acute diffuse nephritis vary greatly in extent, in degree, in the relative involvement of one or other renal structure, as well as with the duration of the process. In this as in other forms of inflammation of the kidney, degeneration is an important and often predominant factor in the morphology of the lesions.

We shall now consider those lesions which in varying degrees are characteristic of an early phase of acute diffuse nephritis, such as fre-

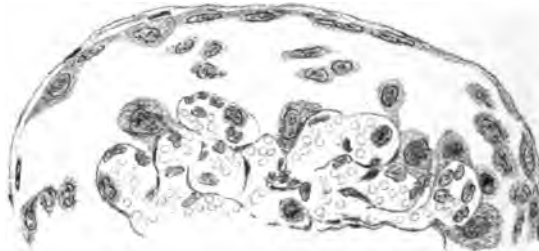


FIG. 500.—ACUTE DIFFUSE NEPHRITIS.

Showing swelling of the cells covering the capillary tufts and lining Bowman's capsule.

quently occurs in the course of the acute infectious diseases. While changes in the different structural components of the kidney may occur simultaneously and are intimately related to each other, we shall study first the lesions of the *glomeruli*, second those of the *tubules*, third those of the *interstitial tissue* and its vessels.

The Glomeruli.—One of the early alterations in the tufts of the glomeruli is the swelling of the cells which cover the capillaries.¹ These cells which in normal conditions are thin and scarcely visible, save by their nuclei, now project from the capillary loops, sometimes remaining closely apposed to the capillary walls, sometimes assuming polypoid shapes (Fig. 500), sometimes forming a continuous thick covering of cuboidal cells over the vessels. The nuclei are larger than normal and mitosis may be evident. Similar changes occur in the epithelium between the capillary loops. The capillaries are sometimes distended and plugged with cells; some of these are leucocytes; others are larger with large

¹ For a study of the development of the glomeruli and its relation to pathological changes see *Herring, Jour. Path. and Bact.*, vol. vi., p. 459, 1900.

nuclei and may be swollen endothelium. Hyaline thrombi are often found in these tuft capillaries. The swollen and proliferating tuft epithelia often undergo fatty degeneration and may peel off into the glomerular space.

In some cases the proliferation and exfoliation are extensive and the cells may collect in crescentic masses within Bowman's capsule, crowding the tuft toward its hilus. The cells in these crescentic masses may be flattened from pressure and in profile appear fusiform (Fig. 501). The capsular epithelium may be swollen or remain apparently intact while there is a large cell accumulation from the tuft; or it may proliferate or become fatty or peel off. Swelling, exfoliation, and proliferation of the glomerular epithelium in some degree are of frequent occurrence

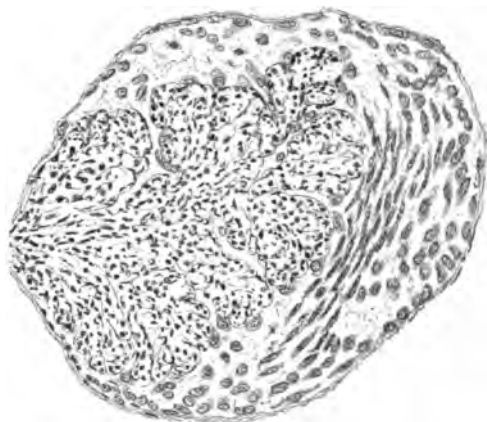

FIG. 501.—ACUTE DIFFUSE NEPHRITIS—FOLLOWING SCARLATINA.

Swollen cells are seen upon the capillary tuft and lining Bowman's capsule. Polyhedral and flattened cells lie in masses between the capsule and the tuft; the latter has been pressed upon by the cells and other exudate within the capsule.

in acute nephritis. They are sometimes so pronounced, especially in acute nephritis following scarlatina, either with or without extensive associated lesions, as to have suggested a name for one phase of the lesion—*glomerulo-nephritis*. There is sometimes a considerable accumulation of albuminous exudate between the tuft and capsule. Such albuminous material in specimens fixed by alcohol is in the form of fine granules and may be mingled with exfoliated and often fatty epithelium or cell detritus.

Leucocytes and red blood cells may be present with other exudate within Bowman's capsule.

The Tubules.—The lesions of the tubules of the kidney in the early phases of acute nephritis are largely degenerative; the epithelium, especially of the convoluted tubules, is swollen and coarsely granular (Fig. 495), or it may contain few or many fat droplets (Fig. 496)—albuminous and fatty degeneration. The epithelium may become necrotic and may disintegrate or peel off over larger or smaller areas. Thus the

lumina of the tubules may contain fragments of epithelium or detritus mingled with albuminous fluid—serum—red blood cells and leucocytes, or hyaline or other forms of casts (Fig. 494). Red blood cells may be extravasated in considerable numbers and collect in the tubules or pass on with the exudates. The casts and other exudates may be present in the cortex or in the collecting tubes of the kidney.

The Interstitial Tissue.—This in early phases of acute nephritis may be œdematous or it may be more or less infiltrated with leucocytes or

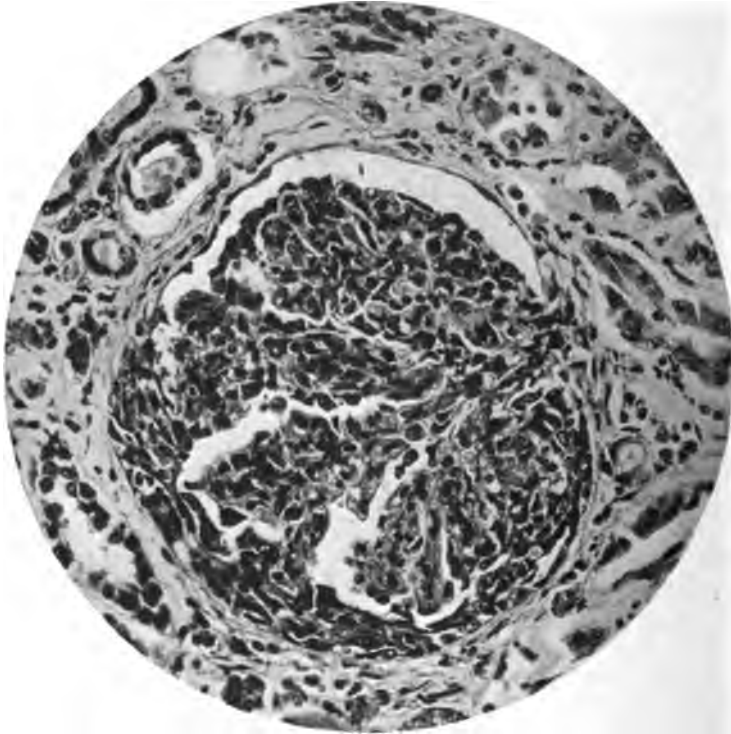


FIG. 502.—ACUTE DIFFUSE NEPHRITIS.

Showing proliferation of cells on the tuft and lining the capsule of the glomerulus and the formation of new interstitial tissue with large polyhedral cells—glomerular and interstitial type.

fibrinous exudate. Patches of new-formed small spheroidal cells, or larger cells with conspicuous excentric nuclei may be present either in the vicinity of the glomeruli (Fig. 502) or near the interlobular veins, or a general thickening of the interstitial tissue may occur even very early in some forms of acute diffuse nephritis, particularly in those following scarlatina and diphtheria.

We have thus seen that in the early phases of an acute inflammation of the kidneys, such as may occur independently or in connection with acute infective processes elsewhere, there is an involvement of all the structural units of the organ, the glomeruli, the tubular epithelium, and

the interstitial tissue. Such a process involving the various kinds of tissue is called diffuse,¹ and the process is therefore designated *Acute Diffuse Nephritis*.

While both kidneys are involved in acute diffuse nephritis, the lesions in each are by no means uniform either in extent or advancement and are often patchy or irregular in distribution.

Variations in Type in Acute Diffuse Nephritis.—There are many variations in the type of the lesions in acute diffuse nephritis, some of which seem to be directly dependent upon the character of the excitant, while in others the variations cannot as yet be associated with known determining conditions.

If one guard himself against the notion of distinct species in the lesions it is convenient to recognize certain structural variants or types. Thus the changes in the glomerular capillaries and epithelium may, as above indicated, be prominent—*glomerular type*—(so-called *glomerulonephritis*) (Figs. 501 and 502); the degenerative process in the tubular epithelium may be extreme—*parenchymatous* or *degenerative type*; there may with other lesions be considerable hæmorrhage into the glomeruli, tubules, and interstitial tissue—*hæmorrhagic type*. With or without marked structural involvement

of the parenchyma and interstitial tissue there may be an exudative inflammation in which serum and leucocytes (Fig. 503) and more or less red blood cells may gather in the glomeruli or tubules and with various forms of casts pass off in the urine. This, which is common, has been called by Delafield the *exudative type* of acute diffuse nephritis. Finally, with any one or more of the above types of lesion there may be early and significant involvement of interstitial tissue of the kidney, so that new and often

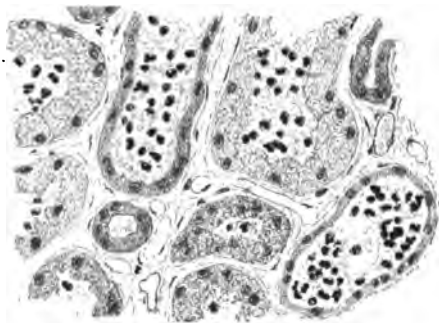

FIG. 503.—ACUTE DIFFUSE NEPHRITIS.

Showing pus cells and granular exudate in the tubules, with flattening of the epithelium; also moderate oedema of the interstitial tissue—exudative type.

very cellular tissue, either in small patches or through a large portion of the organs, may lead to tubular atrophy and to serious and permanent structural alterations. This, which has been called by Delafield the *productive type*, by others the *interstitial type*, of acute diffuse nephritis (Fig. 502), is most frequent as a complication of scarlatina; it may follow diphtheria, or puerperal infections, and may occur as an apparently independent process.²

Between these types of lesion, largely based, as will be seen, upon the

¹ It should be understood that the word "diffuse" is not used in the sense of widespread or uniform, but as indicating involvement of the various structural units of the organ.

² Consult for an interesting study of "acute interstitial nephritis," *Councilman, Jour. Exp. Med.*, vol. iii., p. 393, 1898. Councilman regards the new cells in the interstitial tissue as largely "plasma cells" derived from lymphoid cells of the blood.

relative involvement of the structural units of the kidney, are many intermediate forms which the scope of this book does not permit us to consider.

Kidneys which are the seat of acute diffuse nephritis sometimes appear almost normal on gross inspection. But in more typical forms they are slightly or considerably enlarged, the capsule is free, the cortex is thickened, and either reddened or pale or mottled red and gray. When the interstitial tissue is œdematous the cortex may appear translucent. The glomeruli may be red or pale and conspicuous or normal in appearance. The pyramids may seem unusually red by contrast with the thickened pale cortex. In hæmorrhagic forms of acute nephritis in

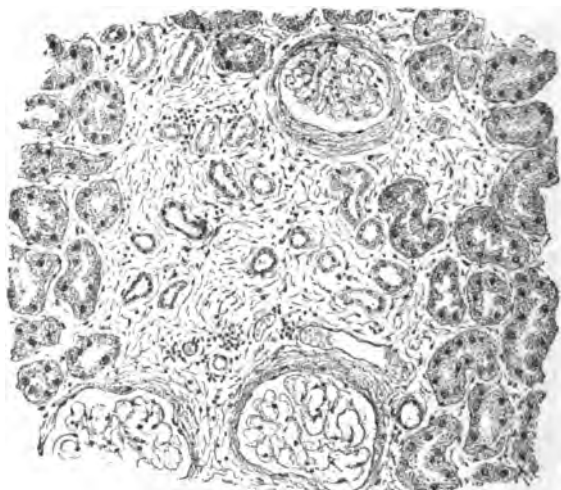


FIG. 504.—DIFFUSE NEPHRITIS.

Showing an advancing lesion following an acute type. Note the formation of a patch of dense fibrous tissue, with thickening of the walls of the glomeruli and atrophy of the tubules.

which blood may collect in the glomeruli, in the interstitial tissue, and in the tubules, the cortex may be mottled with red.

In many forms of acute diffuse nephritis, particularly if the interstitial tissue be not considerably involved, resolution may take place.

The Excitants of Acute Diffuse Nephritis.—In many cases of acute diffuse nephritis, the process seems to be due to toxic substances which are formed under the influence of micro-organisms in other parts of the body and presumably excreted by the kidney with whose cells they come into intimate contact or in whose metabolism they may share. Acute nephritis is also induced by various exogenous poisons, such as corrosive sublimate, carbolic acid, cantharides, and many others; it may occur with extensive lesions of the skin and after exposure to cold. In the acute nephritis following extensive burns, exposure to cold, etc., it is probable that the poisonous products of abnormal body-cell metabolism are the direct excitants.

Bacteria may be eliminated from the body through the kidney sometimes without inducing lesions which are demonstrable with our present technique.¹ The following bacteria have been found by numerous observers in the kidney and in the urine, in acute diffuse nephritis: the typhoid bacillus, pneumococcus, streptococcus and staphylococcus, the colon bacillus, and others. The *Plasmodium malariae* may be present in the kidney in large numbers.² To what extent the kidney lesions are due to the presence of these organisms themselves and to what extent to eliminated toxins is not yet clear.

Persistent and Advancing Lesions Following Acute Diffuse Nephritis.

If we follow the alterations which the kidney in acute diffuse nephritis may undergo, if resolution do not occur, but the process continue, we find that in each of the three structural units of the kidney, the glomeruli, the tubules, and the interstitial tissue, with the blood-vessels, important changes take place which often lead to slight or to marked deformities of the organ, and to such minute changes as are in fact characteristic of what we are wont to call chronic diffuse nephritis.

The capillaries of the tufts may become partly or wholly obliterated by a gradual thickening of their walls and an increase of the connective tissue between them, while at the same time Bowman's capsule is thickened and contracts upon the altered tuft (Fig. 504) with which it may unite so that the glomerulus may finally be represented by a small, dense spheroidal mass of fibrous tissue (Fig. 505).

The interstitial tissue of the kidney may be increased in patches, most often at first near the glomeruli or along the interlobular veins. This tissue may at first be quite cellular, resembling a collection of small spheroidal cells or larger polyhedral cells, among which new fibrillar stroma may develop; or there may be a more diffuse increase of connective-tissue cells and stroma. As this new-formed fibrous tissue grows less cellular it contracts, the tubules which it encloses are atrophied, the epithelium may undergo fatty degeneration and peel off or become flattened, casts may be present in the narrowed lumen, and the tubules may at last be represented by a small cluster of flattened cells with out distinct tubular structure, or they may disappear altogether (Fig. 504). Such islets or masses of new-formed fibrous tissue enclosing variously altered and atrophied remnants of glomeruli and tubules vary greatly in size and usually merge gradually into less altered kidney tissue. When they are formed near the surface of the kidney, the shrinkage of the fibrous tissue, which is continuous with the inner layers of the capsule, may draw the surface inward, leaving between the irregular depressions the areas of less altered, or otherwise altered, kidney tissue somewhat projecting in irregular knobs or granules. Thus arise the granular surface and the adhesion of the capsule which are frequent in some forms of persistent diffuse nephritis.

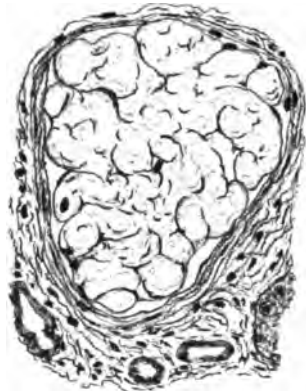


FIG. 505.—ATROPHIED GLOMERULUS IN CHRONIC NEPHRITIS.

The tuft is converted into a dense mass of fibrous tissue.

¹ See *Bicll and Kraus*, *Arch. f. Exp. Path. u. Phar.*, Bd. xxxvii., p. 1, 1896, bibliography; also *v. Klecki*, *ibid.*, Bd. xxxix., p. 173, 1897; also *Sittmann*, *Deut. Arch. f. klin. Med.*, Bd. liii., p. 323 1894. See also references, page 151.

² For a study of malarial nephritis see *Thayer*, *Am. Jour. Med. Sci.*, vol. cxvi., p. 580, 1898. See for the study of a case of acute malarial nephritis with large numbers of parasites in the kidney *Ewing*, *Trans. Assn. Am. Phys.*, vol. xvi., p. 450, 1901.

In the parts of the kidney less involved, or not at all involved in the production of new fibrous tissue, the tubules may undergo marked alterations. Thus the epithelium may be swollen and coarsely granular or fatty; it may become necrotic so that the nucleus fails to stain; it may, when necrotic or degenerated, peel off or disintegrate so that the tubules may be extensively denuded. On the other hand, the epithelium may remain in position but be much thinner than normal, while the lumen is largely dilated. This may take place by the blocking of the tubules below by desquamated cells or by compression of new-formed interstitial tissue. The whole tubule, not merely the lumen, may be dilated and irregular in shape, with well-preserved or fatty or otherwise altered epithelium. Casts of various forms may be present.

CHRONIC DIFFUSE NEPHRITIS.

General Considerations.—We have seen that when the inflammatory process in the kidneys, at first acute, is protracted, both the degenerative and the productive lesions may become more marked and extensive. Thus with a preponderance now of the interstitial alterations and again of the degenerative or other changes in the parenchyma, the kidneys in a condition of chronic diffuse nephritis may present a considerable variety in gross as well as microscopical appearance. They are sometimes larger than normal, as is often though not always the case when the parenchyma is more conspicuously involved; or smaller, as is usual when the interstitial lesions are widespread or advanced.

Although there is no sharp line of separation, either clinical or morphological, to be drawn between acute and chronic diffuse nephritis, it is convenient to group kidney lesions in this way with the understanding that many intermediate forms exist, as must be the case, since, as we have seen, acute nephritis may pass gradually into the chronic form.

While acute diffuse nephritis may be followed by the alterations which have just been summarized and which are characteristic of certain phases of chronic diffuse nephritis, the latter process, it should be remembered, is by no means always or usually preceded by an acute form of inflammation.

In some phases of chronic diffuse nephritis, although interstitial alterations are present, the lesions of the tubules may be the most prominent feature; thus albuminous and fatty degeneration, disintegration, flattening and peeling of the epithelium, the formation of casts, the dilatation of the tubules, etc., may be most conspicuous. In another morphological group of kidneys in chronic diffuse nephritis, while there are many alterations in the tubules, the most marked change is the increase in amount and the subsequent contraction of the interstitial fibrous tissue with atrophy of the tubules and glomeruli and the consequent diminution in size and alteration in shape and consistence of the organ. Between these extremes of lesion there are all intermediate forms, in kidneys which are larger than normal, of normal size, or smaller than normal.

In endeavoring to classify or group the lesions in chronic diffuse nephritis, one encounters difficulties similar to those which beset a like attempt in the acute forms of renal inflammation. But the difficulties are enhanced in the former case by the fact that the conditions under

which the lesions develop are far more diverse and variable and at the same time are often much more obscure.

If we leave out of sight for the moment the conditions under which chronic diffuse nephritis may arise and the direct excitants which with more or less certainty can be fixed upon as important, and confine our attention to morphology, it is at least convenient to place in one group as above indicated kidneys in which, while there may be important changes in the glomeruli and in the interstitial tissue, the most marked lesions are in the *tubular epithelium*. This may conveniently be called the *parenchymatous or degenerative type of chronic diffuse nephritis*.

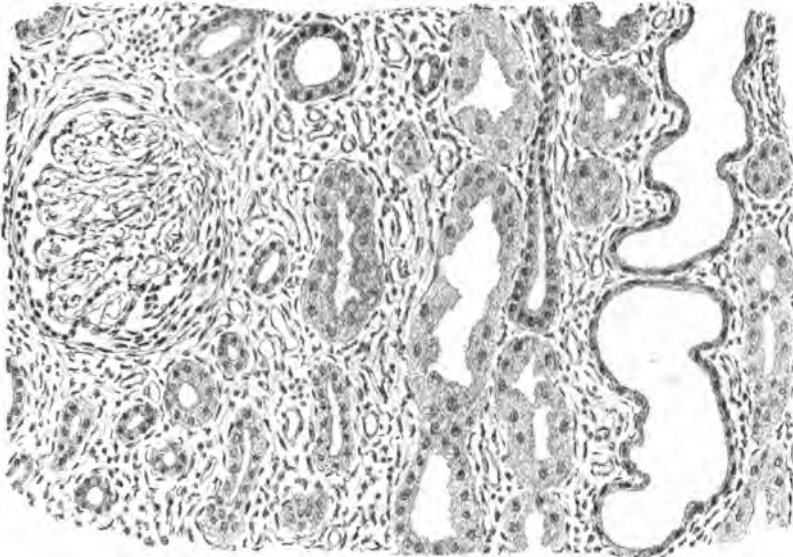


FIG. 506.—CHRONIC DIFFUSE NEPHRITIS—PARENCHYMATOUS TYPE.

At the left is a band of new-formed fibrous tissue with atrophy of tubules and swelling and proliferation of the capsule cells; in the central portions the tubular epithelium is disintegrating at the edges, while at the right the lumina of the tubules are dilated, with flattening of the epithelium.

On the other hand, there is another large and important class of kidneys which are characterized morphologically by a relatively prominent increase in the amount of *interstitial fibrous tissue* with associated destruction by atrophy or otherwise of the tubular structures. This may be called the *interstitial type of chronic diffuse nephritis*.

In considering this in many respects artificial grouping of persistent inflammatory kidney lesions, it should be remembered that while the parenchymatous and the interstitial types of lesion may originate as such and so persist, the lesion of the parenchymatous type may, as the disease progresses, assume the characters of the interstitial form.

Parenchymatous Type of Chronic Diffuse Nephritis.—This may originate in an acute diffuse nephritis, but more frequently develops independently of this. As in other forms of diffuse nephritis, the tubules, the glomeruli, and the interstitial tissue are more or less involved. The

lesions are most marked in the cortex (Fig. 506), and here the epithelium may be swollen and coarsely granular or is often fatty. Droplets of clear fluid may form within the epithelium—so-called “vacuoles.” The epithelium may be flattened or it may peel off or disintegrate and the cells and cell detritus together with leucocytes, red blood cells, and casts may collect in the irregular and often widened lumina. The casts may be hyaline or granular or epithelial, or they may be covered with leucocytes

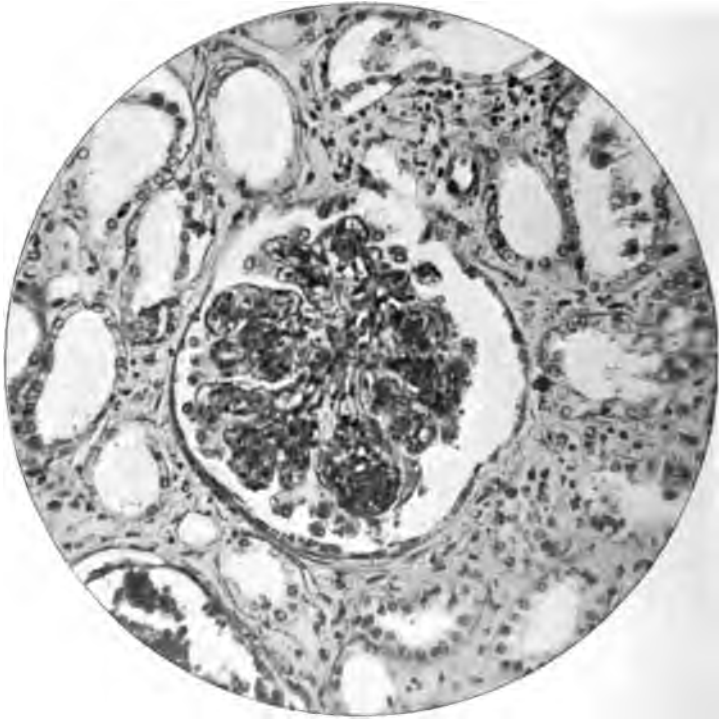


FIG. 507.—CHRONIC DIFFUSE NEPHRITIS.

Showing swelling of tuft and capsule epithelium; flattening of the tubular epithelium and slight increase in the interstitial tissue.

or red blood cells. In the glomeruli, the tuft and capsule cells may swell and proliferate and peel off (Fig. 507); albuminous fluid which in specimens hardened in alcohol is represented by a granular precipitate may be present in the intracapsular space and in the tubules. The interstitial tissue may be increased in amount, usually in circumscribed regions, and here the enclosed tubules are atrophied. Not infrequently more or less extensive hæmorrhages occur.

If the disease have been of long standing the new-formed interstitial tissue may be present in considerable amount with much destruction of the tubules. The glomeruli may be compromised by the thickening of Bowman's capsule and the obliteration of the capillaries, so that at length the tuft and capsule may fuse and the glomeruli may be represented by

dense fibrous nodules (Fig. 505). The growth of interstitial tissue in patches may, when near the surface of the organ, bind the capsule to the kidney so that in its removal small masses of the parenchyma may be stripped off, leaving a rough surface on which grayish depressed areas, corresponding to the interstitial growth, are intermingled with more projecting light or yellowish portions, in which albuminous or fatty degeneration of the tubular epithelium may be marked and extensive. Very often the new fibrous tissue develops along the course of the interlobular vessels so that cylindrical or narrow, wedge-shaped areas are affected, extending inward from the capsule (Fig. 508). Amyloid degeneration

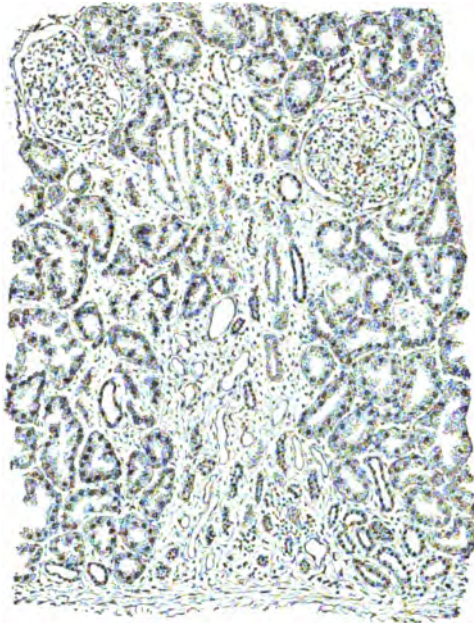


FIG. 508.—CHRONIC DIFFUSE NEPHRITIS—PARENCHYMATOUS TYPE.

Showing a wedge-shaped mass of new-formed tissue extending inward from the capsule of the kidney, to which it is firmly attached. The tubules within the fibrous area are atrophied, while the tubules elsewhere show various degenerative epithelial changes.

involving the capillary tufts, the vasa recta, and the larger arterial trunk is common.

Such kidneys as have just been described present varying gross appearances which are dependent upon the character, extent, and distribution of the lesions. Some are larger than normal with a thickened whitish or yellowish cortex. These are often called *large white kidneys*. But kidneys with essentially similar lesions are not always large, are often nearly normal in appearance, or may be smaller and with a cortex thinner than normal. If hæmorrhage into the tubules or interstitial tissue be a marked feature of the lesion, the cortex may be reddish or mottled red and yellow. Such are the so-called *large red kidneys*.

Arterio-sclerosis and cardiac hypertrophy frequently accompany this type of kidney lesion.

Interstitial Type of Chronic Diffuse Nephritis.—The type of chronic diffuse nephritis in which the growth of interstitial tissue is conspicuous, which may be called the *interstitial* or *indurative* type, apparently sometimes represents a later phase of the parenchymatous type; or it may result from chronic congestion, or be associated with arterio-sclerosis; but it appears to be more frequently an independent process. As the new interstitial tissue which is formed in patches or streaks or large masses gradually becomes less cellular, more dense, and shrinks, the kidneys are usually smaller than normal and, owing to the uneven distribution of

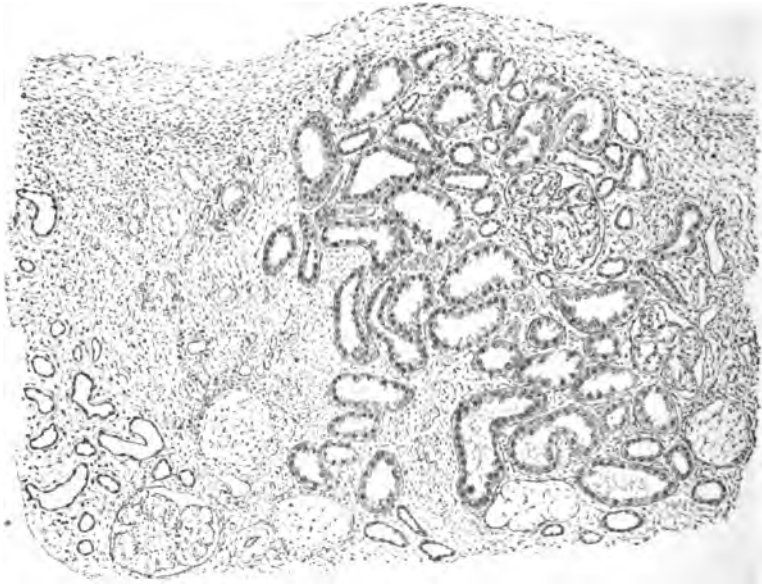


FIG. 509.—CHRONIC DIFFUSE NEPHRITIS—ATROPHIED KIDNEY.

The capsule is thickened and adherent, especially to the dense mass of fibrous tissue at the left of the section in which the tubules are greatly atrophied. At the right the parenchyma is less atrophied, but here the lumina of the tubules are dilated, the epithelium is degenerating and flattened.

the lesion, rough upon the surface when the thickened and adherent capsule is stripped off. The areas of the cortex in which the fibrous tissue is most abundant (Fig. 509) are grayish or translucent and depressed, while the parenchyma between, often fatty, projects as yellowish rounded knobs or granules. This condition is therefore sometimes spoken of as "granular atrophy," and such kidneys are often called "granular kidneys" or "atrophied kidneys." The tissue is firm and resistant to the knife; and on section the cortex is seen to be in general thinned, often extremely so, some portions being much more atrophied than others. Small cysts of various sizes may be formed from dilatation and coalescence of tubules. The cortex is usually more involved than the medulla. The fat with which the kidney is surrounded is often largely increased.

On microscopical examination the new-formed interstitial tissue is sometimes in patches (Fig. 510) or streaks along the course of the interlobular vessels, with less affected regions between them. In these fibrous portions there may be flattening of the epithelium and various degrees of atrophy or complete destruction of the epithelium and the tubules. Between these fibrous regions, little altered tubules may be present, or those with granular and fatty degeneration, exfoliation, and disintegration of the epithelium. Various forms of casts may be present in the tubules; the epithelium may be flattened with enlargement of the lumen. The glomeruli are variously altered; thus there may be thickening of the capillary walls and of Bowman's capsule (Fig. 511), increase

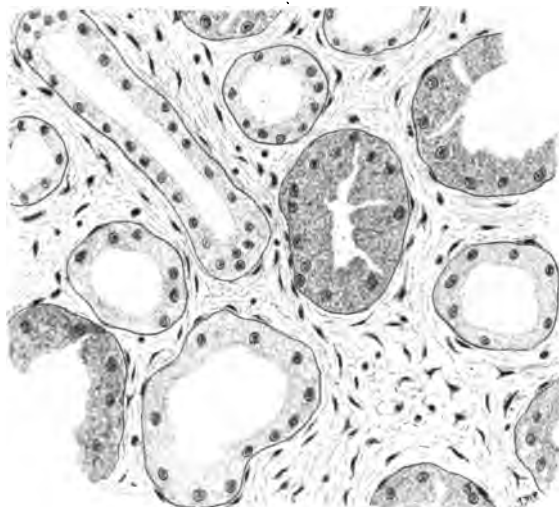


FIG. 510.—CHRONIC DIFFUSE NEPHRITIS.

Showing interstitial tissue, dense and fibrous in type, between the tubules. The epithelium is in part flattened; in places shows albuminous degeneration.

and exfoliation of the tuft and capsular epithelium, or a more or less complete conversion of the glomerulus into a knob of dense fibrous tissue. Occasionally there is partial or complete atrophy of the tuft with more or less dilatation of the capsule. Thus small cysts are formed lined with flat cells and containing a homogeneous or granular fluid and sometimes small masses of calcium salts.¹

In advanced phases of the lesion the kidney may be very small; then a large part of the tissue is involved; and while the atrophy is always more marked in some places than in others, it is often difficult to find any normal structural elements.

Fibrous thickening of the walls of the arteries and veins of the kidneys is usual in this type of chronic diffuse nephritis (Fig. 512). Amy-

¹ For a study of atrophic glomerular cysts see *Beer*, *Amer. Jour. Med. Sci.*, vol. cxxvii., p. 611, 1904.

loid degeneration of the vessels is not infrequent. The heart is often greatly hypertrophied, and general arterio-sclerosis is common.¹

Variations in Type in Chronic Diffuse Nephritis.—There are many variants in the two types of chronic diffuse nephritis which we have briefly described. It is possible to indicate in a general way morphological appearances which are frequently present and more or less characteristic of each of the variants when the kidney lesions occur in connection with either gout or chronic visceral congestion or arterio-sclerosis or syphilis. But these variations in form cannot be further considered here.

The diverse appearances which the kidneys present in chronic diffuse nephritis are, as we have seen, largely due to variations in local and

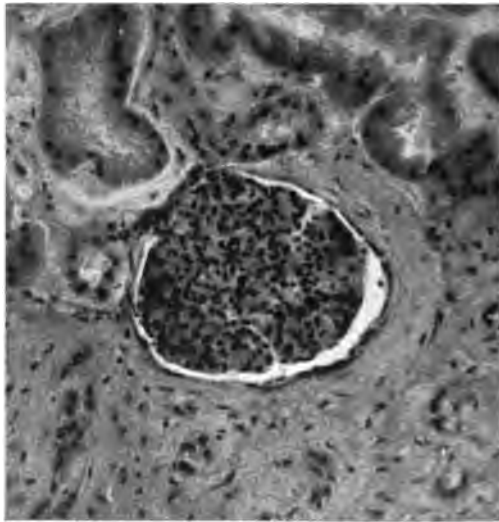


FIG. 511.—CHRONIC DIFFUSE NEPHRITIS.

Showing fibrous thickening of the glomerular tuft with a mass of dense fibrous interstitial tissue at one side (below) of the glomerulus. From an atrophied kidney.

general tissue vulnerability or to the rapidity and to the stage of development of the lesions as well as to the nature of the excitants. But acute inflammatory processes not infrequently supervene in kidneys which are the seat of slowly developed chronic processes; so that lesions typical of both acute and chronic nephritis are not infrequently associated. Finally it is evident that the grouping of the kidneys in chronic diffuse nephritis in accordance with the structural elements of the organ most conspicuously involved is essentially artificial, since this in many cases is simply an indication of the period of the disease at which the patient died.

The Excitants of Chronic Diffuse Nephritis.—The conditions under which chronic diffuse nephritis occurs are most diverse. Thus, judging from the clinical history, it may be a primary process; it may follow

¹ For an experimental study of the relationship between destruction of renal parenchyma and hypertrophy of the left ventricle see *Pässler and Heineke*, Verh. Deut. Path. Ges., Bd. ix., 1905, p. 99.

infectious diseases either with or without a previous acute nephritis; it is not infrequently associated with gout and syphilis, with lead poisoning, with excessive use of alcohol, with arterio-sclerosis, with general chronic congestion of the viscera, with chronic suppurative and tuberculous processes, and appears in many cases to develop under the influence of dietetic excesses and protracted gastro-intestinal disorders. The nature of the excitants under these various conditions is most obscure. Although in gout, lead poisoning, alcoholism, etc., a fairly definite inciting toxic agency may be assumed, the exact mode of action of such extrinsic or intrinsic poisons is almost wholly unknown. In regard to other excitants of chronic diffuse nephritis, the prevalent views as to the importance of disturbed metabolism in the body which may lead to the excretion of abnormal harmful products favor the conjecture that in many cases at least both the degenerative and the productive processes may be the marks of a persistent auto-intoxication.




FIG. 512.—CHRONIC OBLITERATING ENDARTERITIS IN AN ATROPHIED KIDNEY WITH CHRONIC DIFFUSE NEPHRITIS.

The relationship between arterio-sclerosis and chronic kidney lesions is not clear. Nor is it certain, assuming the initial importance of obstructive vascular lesions, whether the new formation of fibrous tissue should be regarded as a primary productive inflammation or as replacement hyperplasia secondary to epithelial degeneration and tubular atrophy. The trend of opinion to-day is rather toward the belief that destructive changes in the epithelium are usually primary, while the new connective tissue formed is reparative.

It should be remembered that in most cases the lesions of chronic diffuse nephritis are not independent, but are usually associated with those of other viscera. The significance of this association varies greatly. While the kidney lesions may be primary they are very often secondary to other visceral abnormalities, or the whole series of lesions may be dependent upon a common known or unknown etiological factor.¹

TUBERCULOUS NEPHRITIS.

Miliary tubercles may be present in the kidney in general acute miliary tuberculosis or in a localized tuberculous inflammation which is most marked elsewhere. Renal tuberculosis is, however, most often associated with tuberculous processes in other parts of the genito-urinary tract. It is not infrequently primary in the kidney and then is often unilateral. If only one kidney be involved the other may become the seat of chronic

¹ For studies bearing on experimental nephritis see *Thorel*, *Deut. Arch. f. klin. Med.*, Bd. lxxvii, p. 29, 1903; also *Coyne* and *Caralié*, *Comptes rend. soc. biol.*, t. lvi., 1904, p. 650. Also *Emerson*, *Arch. Int. Med.*, 1908, i, 485; and *Pearce, Hill* and *Eisenbrey*, *Jour. Exp. Med.* xii, 196, 1910.

diffuse nephritis with waxy degeneration of the walls of the arteries. Tuberculous inflammation may occur in a kidney already the seat of chronic inflammatory changes.

The process is apt to begin in the mucous membrane of the pelvis and calyces, and extend from thence first to the pyramidal and afterward to the cortical portion of the kidney.¹ In the mucous membrane of the pelvis and calyces there is a growth of new cellular tissue studded with tubercle granula, while the epithelial cells proliferate, become deformed,

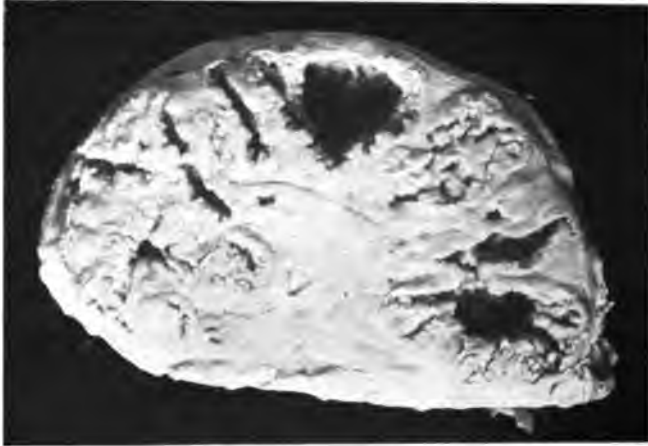

FIG. 513 —TUBERCULOUS NEPHRITIS.

and desquamate. This process is often soon followed by cheesy degeneration of the inflammatory products. Similar changes occur in the kidney which may become extensively involved and largely destroyed. The portions of the organ which do not share directly in the tuberculous process often develop lesions of the interstitial type of chronic diffuse nephritis or of suppuration. Thus the kidney may become hollowed out into a series of ragged cavities with caseous and disintegrating walls (Fig. 513). Sometimes the process comes to a standstill, and then the caseous portions may be infiltrated with salts of lime.²

SYPHILITIC INFLAMMATION.

Gummata of the kidney are of occasional occurrence. A close relationship between syphilitic arteritis and atrophied forms of chronic diffuse nephritis seems probable.³

¹ For a study of ascending urogenital tuberculosis see *Baumgarten*, *Arbeiten Path. Anat. Inst. Tübingen*, Bd. v., p. 372, 1906; also *Kappis*, *ibid.*, p. 379.

² For a study of renal tuberculosis see *Walker*, *Johns Hopkins Hosp. Rep.*, vol. xii., p. 455, 1904.

³ For bibliography see *Delamare*, *Gaz. des Hôpitaux*, May 12th, 1900.

SUPPURATIVE PYELITIS AND PYELO-NEPHRITIS.

Suppurative Pyelitis is often associated with suppuration of the kidney substance, more frequently with a similar process in the bladder or ureters. But it may occur by itself. It is incited by the same microorganisms as are concerned in the induction of the associated lesions in the kidney and bladder; in the latter case, it is most often the *Bacillus coli communis*, the *Streptococcus pyogenes*, and *Staphylococcus pyogenes*.

The mucous membrane of the pelvis may be congested, thicker and more opaque than normal, and coated with pus or with patches of fibrin. The presence of pelvic calculi is to be regarded as a predisposing rather than as a direct inciting agent in suppurative pyelitis.

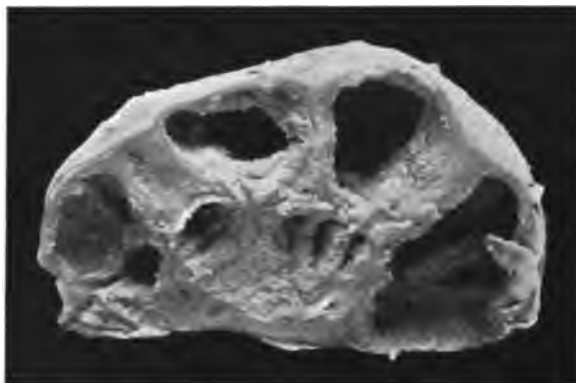

FIG. 514.—CHRONIC PYELO-NEPHRITIS.
Showing dilatation of the pelvis and calyces.

Suppurative Ureteritis.—The conditions under which suppurative inflammation of the ureter occurs are similar, as is the general appearance of its mucous membrane, to those just indicated in the pelvis.

Suppurative Pyelo-Nephritis with Cystitis.—In this association of lesions of the bladder and kidneys, which is usually initiated by the inflammation of the bladder, the affection of the kidneys is commonly bilateral. The suppurative areas in the kidney may be in the form of small abscesses scattered through the kidneys, or in the form of elongated whitish streaks or wedges between the tubules (see Fig. 499). The purulent foci are often surrounded by a red zone of congestion.

The kidney tissue in the vicinity of the abscesses may be necrotic, the outlines of the cells being preserved but their nuclei absent or not revealed by the usual staining agents.

The infective agent may traverse the ureters in passing from the inflamed bladder to the kidneys, leaving the mucous membrane of the ureter intact.

Chronic Pyelo-Nephritis.—Chronic cystitis or calculi in the pelvis of

the kidneys may set up a chronic inflammation which involves both the pelvis and calyces and the kidney tissue. The mucous membrane of the pelvis and calyces is thickened, the epithelial layer is changed, there is a growth of granulation tissue beneath the epithelium, and there may be little polypoid outgrowths. The surface of the mucous membrane is coated with pus or fibrin, or the cavity of the pelvis and calyces is dilated and distended with purulent serum (Fig. 514).

The kidney itself is the seat of a chronic interstitial inflammation with the production of new connective tissue, and sometimes of pus, with obliteration of the renal tubules.

HYDRONEPHROSIS.

Dilatation of the pelvis and calyces of the kidneys may be congenital and may be associated with other malformations. The pelvis and calyces of both kidneys, and the ureters, are distended with urine; the bladder also may be distended and its wall hypertrophied. The urethra may be closed, or no obstruction can be demonstrated.

In adults hydronephrosis may follow mechanical obstruction of the urethra or ureters (Fig. 515), from inflammation, tumors, or calculi. According to the position of the obstruction, either one or both kidneys are involved.

The pelvis and calyces are dilated, sometimes enormously, and filled with urine alone or urine mixed with pus. The kidney tissue is flattened and thinned over the distended cavities. Its texture may remain unchanged, or there may be developed suppurative pyelo-nephritis or chronic diffuse nephritis.

PERINEPHRITIC SUPPURATION.

The loose connective tissue about the kidney may become the seat of suppurative inflammation. This may follow mechanical injury or may be secondary to suppurative or other inflammatory processes, such as caries of the spine, empyema, pelvic cellulitis, puerperal parametritis, perityphlitis, and suppurative nephritis. It may be associated with acute infectious diseases in children. The suppuration may extend backward through the muscles; downward into the iliac fossa, the perineum, the bladder, the scrotum, or the vagina; forward into the peritoneal cavity or the colon; or upward through the diaphragm.

The kidney itself may be simply compressed by the abscess or become involved in the suppurative process.

CYSTS IN THE KIDNEYS.

Cysts are formed in the kidneys both during intra-uterine and extra-uterine life.

Congenital Cystic Kidneys are often striking objects. Either one or both kidneys may be greatly enlarged and converted into a mass of

cysts (Fig. 516). The cysts are of various sizes and are separated from each other by fibrous septa or compressed kidney tissue. They may contain a clear yellow, acid fluid holding in solution the urinary salts; or the fluid is turbid and brown, and contains blood, uric-acid crystals, and cholesterin. The cysts are often lined with a single layer of flat, polygonal cells. Some of them seem to be formed by a dilatation of the tubules and of the capsules of the Malpighian bodies. As causes for such dilatations there may be found obliteration of the tubes in the papillæ,

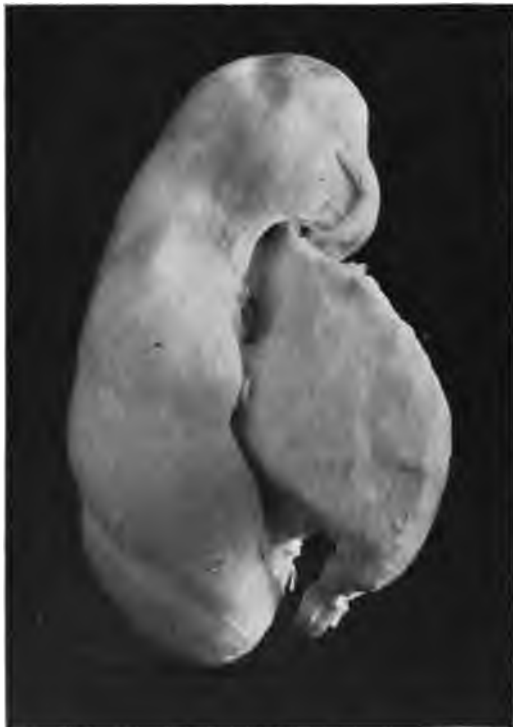

FIG. 515.—HYDRONEPHROSIS.
From obstruction of ureter.

and stenosis of the pelvis, ureters, bladder, or urethra. Other congenital malformations are often associated with this.

Cysts of the Kidney in the Adult may be single and occur in otherwise normal organs. There may be one or more cysts filled with clear or brown serum or gelatinous material (Fig. 517). These cysts do not appear to interfere with the function of the kidneys.

In chronic diffuse nephritis, especially in the atrophic form, groups of tubes may be dilated. Apparently one or more of the larger tubes in the pyramids are obstructed, and this causes dilatation of a corresponding group of tubes. Such a dilatation may be moderate in size, or it

may form cysts visible to the naked eye. Very small cysts of Bowman's capsule may form with atrophy of the vascular tuft.

Occasionally both kidneys are very much enlarged and converted into a mass of cysts containing clear or colored serum or gelatinous material. The nature of these cysts is uncertain; they may be congenital. They are sometimes associated with similar cysts in the liver.¹

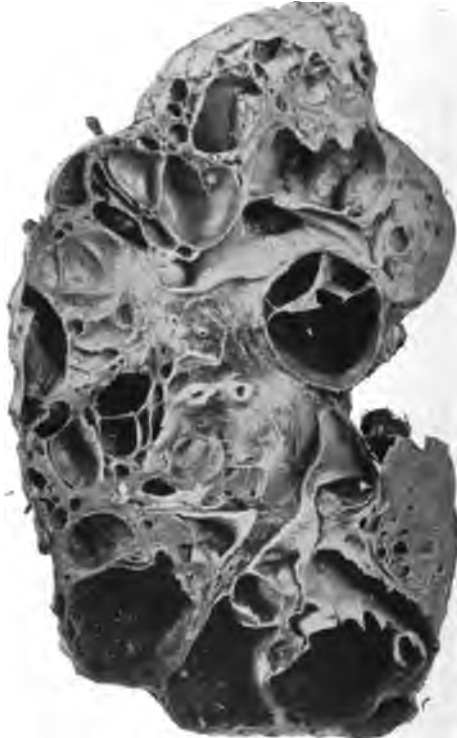

FIG. 516.—CONGENITAL CYSTIC KIDNEY.

Only very small portions of the kidney tissue remain, crowded between the cysts.

Small multiple cysts of the ureter, lined with flattened or cuboidal epithelium, are of occasional occurrence, and may be associated with similar cysts in the pelvis of the kidney. Such cysts in the ureter may be pedunculated.²

RENAL CALCULI.

In the kidneys of new-born children, from the first to the fourteenth day after birth, the large tubes of the pyramids often contain small brownish, rounded bodies composed of the urates of ammonium and sodium. Similar masses may also be present in the calyces and pelves. In still-born children these masses are usually absent. The carbonate

¹ For a study of cystic kidney with extensive bibl. see *Ritchie*, *Laboratory Reports*, Royal Coll. of Phys., Edinburgh, vol. iv.; also *Braunwarth*, *Virch. Arch.*, Bd. cxxxvi., p. 341, 1906, bibl.

² For a résumé of cysts of the ureter with bibl. see *Harris*, *Am. Med.*, vol. iii., p. 731, 1902.

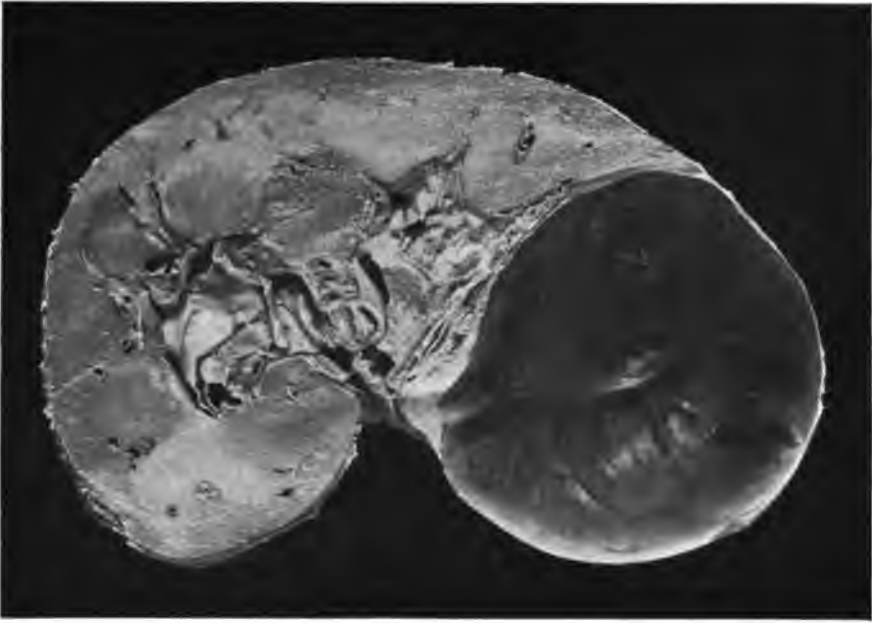

FIG. 517.—SINGLE CYST OF THE KIDNEY.

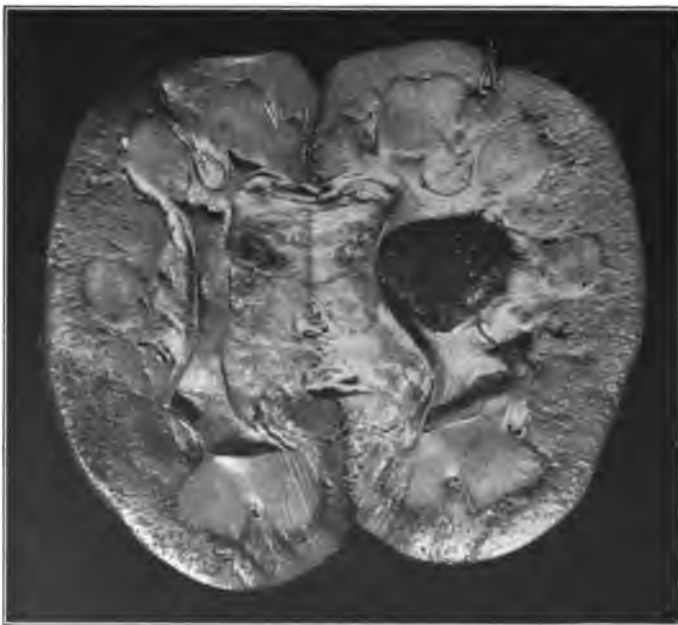


FIG. 518.—CALCULUS IN THE PELVIS OF THE KIDNEY.

and phosphate of lime may be deposited in the tubes of the pyramids, in the form of white linear masses, in the kidneys of old persons and of those who have suffered from destructive diseases of the bones.

Urate of soda in the form of acicular crystals is deposited both in the tubes and stroma of the kidneys of gouty persons.

Concretions of the urinary salts are often formed in the pelves of the kidneys. They may remain there as rounded masses (Fig. 518), or they may attain a large size and be moulded into the shape of the pelvis and calyces. Smaller calculi may pass into the ureter and either become impacted there or pass through it into the bladder. The most common form of calculus is that composed of uric acid. But they may also be formed of uric acid with a shell of oxalate of lime, or of oxalate of lime alone, or of the phosphates, or of cystin.

The most serious result of the presence of these calculi is the occlusion of the ureters or the incitement of pyelo-nephritis.

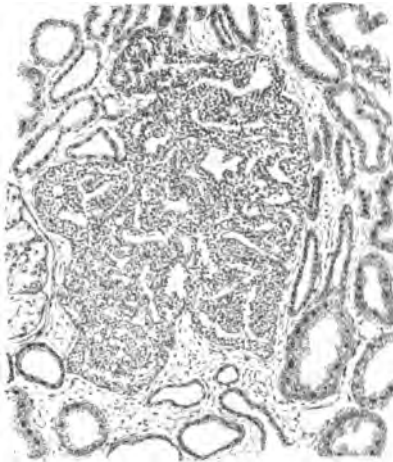

FIG. 519.—SMALL ADENOMA OF KIDNEY.
Situating in the cortex.

TUMORS.

Small **fibromata**, **lipomata**, **myomata**, and **angiomata** may occur in the kidney and with the exception of the fibromata are most common in the cortical portion. **Papilloma** may form in the mucous membrane of the pelvis. **Sarcoma**, **myxosarcoma**, and **endothelioma**, often of large size, may develop in the kid-

ney. These tumors are frequently soft and vascular and are prone to hæmorrhage. Primary sarcoma of the kidney is common in children. Secondary sarcoma of the kidney is not rare.

There are **mixed tumors** of the kidney often occurring in childhood and having a sarcomatous and adenomatous character; or they may contain mucous or elastic or muscle tissue with structures suggesting glomeruli. These tumors are of doubtful origin.²

Adenoma is of frequent occurrence in the kidneys. It usually originates in the cortex and may be invisible to the naked eye (Fig. 519), or, in the form of a well-defined, circumscribed nodule (Figs. 520 and 521), it may invade the medulla or largely replace the kidney. The adenomata are usually light in color save when very vascular with hæmorrhage, and they may be separated from the kidney structure by a fibrous capsule. Such tumors are not rare in children.³

¹ See for studies of lipoma *Urich*, *Ziegler's Beitr. z. path. Anat.*, Bd. xviii., p. 603, 1895; also *Müller*, *Virchow's Arch.*, Bd. cxlv., p. 339, 1896.

² See for a study of the mixed tumors of the kidney *Hedrén*, *Ziegler's Beitr.*, Bd. xl., p. i, 1906, bibl.

³ See *Engelken*, *Ziegler's Beitr.*, Bd. xxv.i p., 320, 1899, bibl.

There are two principal varieties of these tumors, the papillary and the alveolar, which are, however, closely related.

1. *Papillary Adenoma*.—There are cavities of different sizes, from the walls of which spring branching tufts covered with cylindrical or cuboidal epithelium (Fig. 522). These tufts nearly fill the cavities.

2. *Alveolar Adenoma*.—There is a connective-tissue framework enclosing small round, oval, or tubular alveoli, lined or filled with cells (Fig. 523). The cells are usually large and may be cylindrical, cuboidal, or polyhedral, and may be pigmented in a manner similar to the cells of the adrenals.

Fatty degeneration of the epithelium may be excessive, and glycogen may form in the cells of these tumors. The stroma may be present in considerable quantity, the blood-vessels may form conspicuous features, or a cystic distention of the alveoli may occur. Large areas may become necrotic. They may form metastases.

Many of these tumors appear to have developed from adrenal cells astray in the kidneys, and are then called *hypernephroma* (Figs. 520 and 524). Metastases of hypernephroma are not uncommon. These have been found in the liver, lung, intestines, retroperitoneal and other lymph-nodes (Fig. 525), bone and muscle.

The relationship between true adenoma of the kidney, adenomata which appear to develop from strayed adrenal elements, and similar tumors which are regarded by some observers as endotheliomata or endothelial sarcomata, and certain forms of angio-sarcoma, is not yet altogether clear.¹

Primary **carcinoma** of the kidney is rare, adenoma being frequently mistaken for it. Secondary carcinoma is not infrequent.²

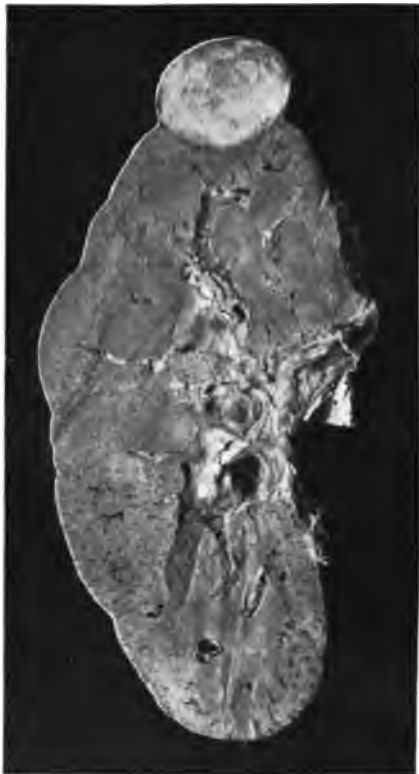


FIG. 520.—ADENOMA OF THE KIDNEY.
(Hypernephroma.)

A tumor of the kidney formed from aberrant adrenal tissue.

¹ For a study of hypernephroma of the kidney see *Kelly*, Phila. Med. Jour., 1898, vol. ii., pp. 223, 283, bibl.; see also summary by *Thorndike and Cunningham*, Boston Med. and Surg. Jour., vol. cxlix., p. 611, 1903; also *Keen, Pfahler, and Ellis*, Amer. Med., vol. viii., p. 1039, 1904.

² For a careful study of tumors and other growths in the kidney see *Kelyack*, "Renal Growths," 1898, bibl.; also ref. to bibl. *Bussé*, Virchow's Arch., Bd. clvii., pp. 346, 377, 1898. For a statistical study of malignant tumors of the kidney in children see *Oshima*, Wiener klin. Woch., p. 93, 1907.

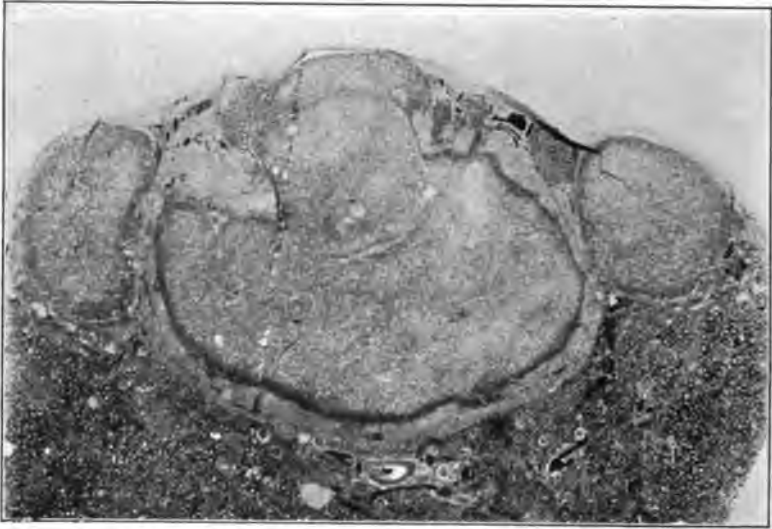

FIG. 521.—ADENOMA OF THE KIDNEY.
Showing encapsulation of the nodules.

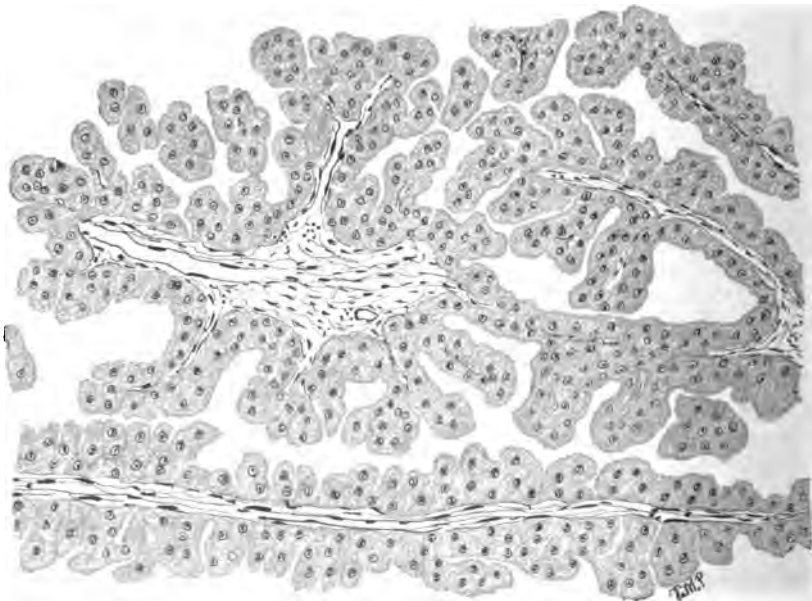


FIG. 522.—ADENOMA OF THE KIDNEY.
Papillary variety.

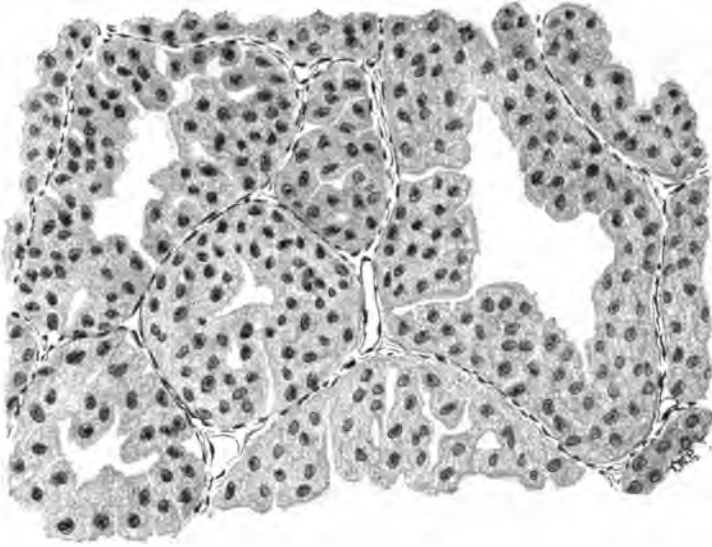


FIG. 523.—ADENOMA OF THE KIDNEY.
Alveolar variety.

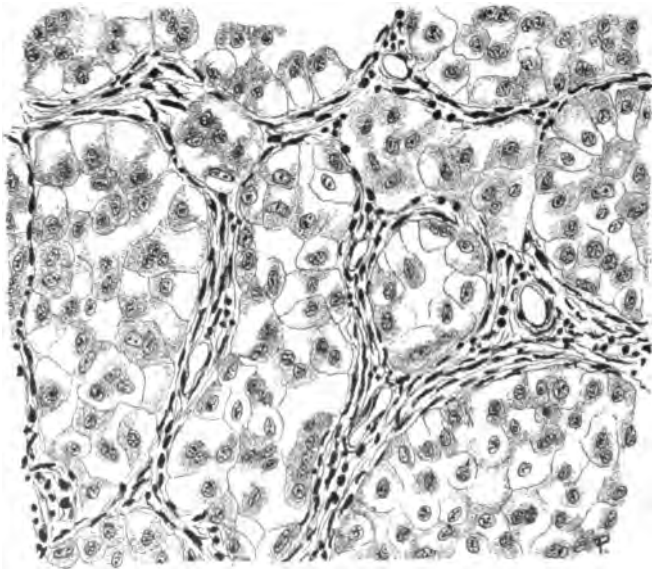


FIG. 524.—HYPERNEPHROMA.
The cells filling the alveoli are in part transparent, resembling those of the adrenal.

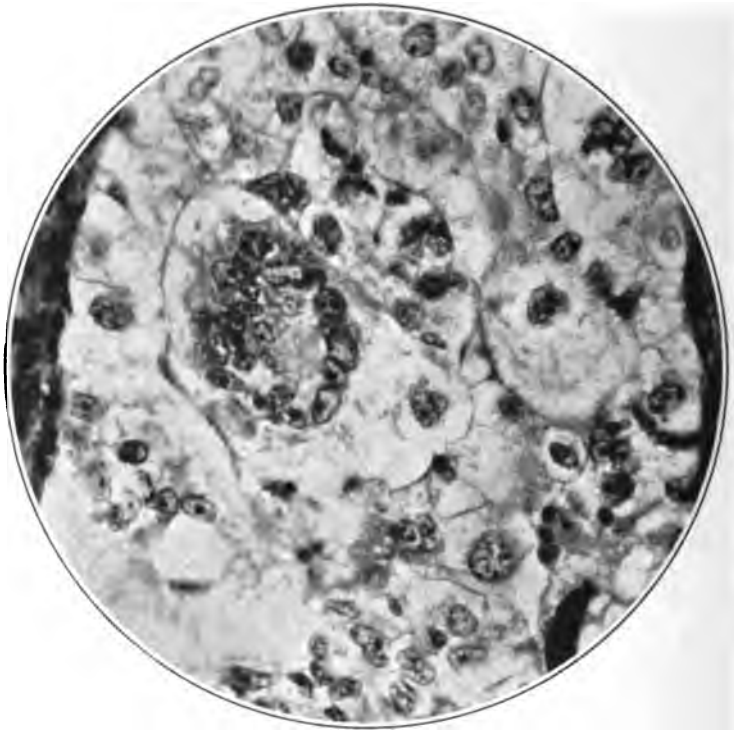


FIG. 525.—HYPERNEPHROMA.
Metastasis in lymph-node of arm. Atypical form with multinucleated cells.




FIG. 526.—DIVERTICULA OF THE BLADDER

PARASITES.

Echinococcus, in its ordinary form of mother and daughter cysts, is sometimes found in the kidney. The cysts may open into the pelvis of the kidney, into the pleura, or through the wall of the abdomen.

Cysticercus cellulosæ is of very rare occurrence. **Filaria sanguinis hominis** is found in the arteries, veins, lymphatics, and stroma, and may pass into the urine. **Strongylus gigas** has been found several times in the pelvis of the kidney.

The Urinary Bladder.

Malformations.

ABSENCE OF THE BLADDER is of rare occurrence. The bladder may be very small, the urine passing almost directly into the urethra. The bladder may be separated into an upper and a lower portion by a circular constriction. It may be completely divided by a vertical septum into two lateral portions. Diverticula of the wall of the bladder are sometimes found in newborn children. Partial or complete closure of the neck of the bladder may occur. This may lead to hydronephrosis, or the urine may be discharged through the open urachus.

EXSTROVERSION of the bladder is one of the most frequent malformations, and may occur in either sex. It presents several varieties:

1. The umbilicus is lower down than usual, the pubic bones are not united at the symphysis, the pelvis is wider and shallower than it should be. Between the umbilicus and pubes the abdominal wall is wanting. In its place is a projecting, ovoid mass of mucous membrane, in which may be seen the openings of the ureters. The penis is usually rudimentary; the urethra is an open fissure (epispadias); the clitoris may be separated into two halves. The ureters usually open normally; sometimes their openings are displaced or are multiple. They may be dilated.

2. There may be a fissure in the abdominal wall, filled up by the perfectly formed bladder.

3. The umbilicus may be well formed, and there is a portion of abdominal wall between it and the exstrophied bladder.

4. The external genitals and urethra may be well formed, and the symphysis pubis united, while only the bladder is fissured.

5. The genitals, urethra, and symphysis may be well formed, the bladder closed except at the upper part of its anterior wall. The bladder is entirely or in part inverted and pushed through the opening in the abdominal wall.

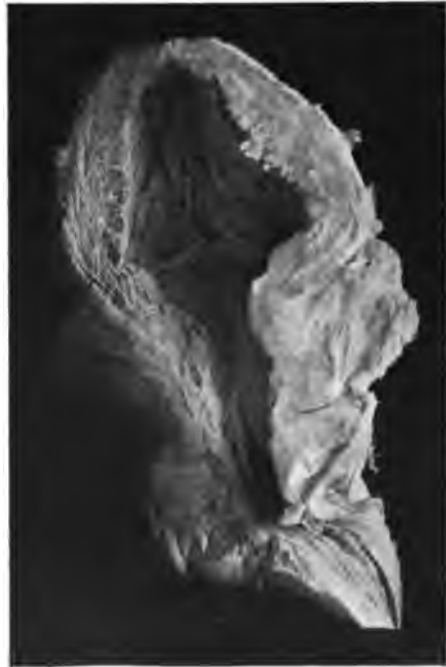

FIG. 527.—HYPERTROPHY OF THE WALL OF THE BLADDER.

The URACHUS normally remains as a very small canal, 5 to 7 cm. long, with a small opening into the bladder, or entirely closed at that point. If there is a congenital obstruction to the flow of urine through the urethra, the urachus may remain open and the urine pass through it. Or the bladder may present, even in the adult, a slender distention reaching close to the umbilicus as the result of a persistent urachus.

Changes in Size and Position.

DILATATION.—This may be *general* or *partial*, leading to the formation of diverticula.

General dilatation of the bladder is produced by the accumulation of urine in consequence of some mechanical obstacle to its escape, or of paralysis of the muscular walls of the organ. The dilatation is usually uniform and may be very great, so that the bladder may reach to the umbilicus. If the walls of the bladder are paralyzed, or the obstruction occurs suddenly or is complete, the wall of the bladder is thinned. When an incomplete obstruction exists for some time the walls of the bladder are apt to hypertrophy, so that, although the bladder is larger than normal, the walls may not only be of the usual thickness, but even very much thicker. In the *fœtus* dilatation of the bladder may reach such a size as to interfere with delivery.

The retained urine in dilated bladders is liable to decomposition, from the presence of bacteria, and this may lead to inflammation or gangrene of the mucous membrane.

DIVERTICULA of the bladder may be produced by the pouching out of circumscribed portions of the wall of the bladder, the wall of the pouch containing all the layers of the bladder wall. More frequently, however, they are produced by a protrusion of the mucous membrane between hypertrophied bundles of muscle fibre. They may be very small (Fig. 526), or they may be as large as a child's head. They may communicate with the bladder by a large or small opening. The decomposition of stagnant urine in diverticula is apt to induce inflammation. Calculi may be formed in them or may slip into them from the bladder.

HYPERTROPHY of the muscular coat of the bladder is usually due to mechanical obstructions to the outflow of urine, such as stricture of the urethra, enlarged prostate, calculi, new growths, etc. The muscular coat is thickened uniformly or assumes a trabeculated appearance (Fig. 527). The organ retains its normal capacity, or is dilated, or becomes smaller. The mucous membrane is frequently the seat of chronic or acute inflammation. Dilatation of the ureters and hydronephrosis frequently accompany this condition.

HERNIÆ of the bladder sometimes accompany intestinal herniæ through the inguinal and crural canals and the foramen ovale. The changes in position of the bladder, produced by displacements of the vagina and uterus, will be mentioned with the lesions of those organs.

In the female the base of the bladder may press downward, causing protrusion of the vaginal wall (*vaginal cystocele*); or there may be inversion and prolapse of the bladder through the dilated urethra.

WOUNDS—RUPTURE—PERFORATION.

Penetrating *wounds* of the bladder may permit escape of urine into the abdominal cavity, or infiltration into the surrounding connective tissue or permanent fistulæ. Such wounds are always serious and frequently fatal, owing chiefly to the severe and often gangrenous inflammation which decomposing urine sets up in the connective tissue, or to the peritonitis induced by the same cause.

Rupture of the bladder may be produced by severe blows and falls when the bladder contains urine. More rarely rupture takes place from overdistention. Death may occur from rupture of the bladder with escape of urine into the peritoneal cavity, without evidences of peritonitis.

Perforations of the bladder may be due to ulceration and gangrene, to abscesses from without, and to cancerous ulceration from the adjoining organs. Fractures of the pelvic bones may be accompanied by laceration of the bladder. Perforations of the bladder may lead to the establishment of fistulæ, communicating with the rectum, vagina, uterus, or opening externally.

DISTURBANCES OF CIRCULATION.

Hyperæmia.—Aside from active hyperæmia of the mucous membrane in acute inflammation, the bladder is not infrequently the seat of chronic congestion from obstruction to the venous circulation. Under these conditions there may be chronic catarrhal inflammation, or a marked dilatation of the veins (vesical hæmorrhoids), which may give rise to hæmorrhage or to obstruction of the opening of the ureters.

Hæmorrhage.—Extensive hæmorrhages into the bladder are commonly due to injury or to the presence of calculi or tumors. Small hæmorrhages into the substance of the mucous membrane may accompany inflammation, the hæmorrhagic diathesis, scurvy, purpura, smallpox, etc. If the hæmorrhage is considerable and occurs rapidly in an empty bladder, a clot is apt to form; but when the blood mixes with urine as it is extravasated it more commonly remains liquid and is discharged as a reddish brown fluid.

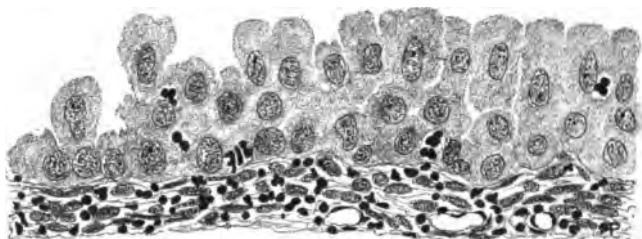


FIG. 528.—ACUTE CATARRHAL CYSTITIS.

There are exfoliation of epithelium and emigration of leucocytes from the submucosa.

INFLAMMATION. (Cystitis.)

Acute Catarrhal and Exudative Cystitis.—This may be incited by the presence of urine which has decomposed under the influence of bacteria; by cantharides or other drugs; by the presence of foreign bodies and calculi; or it may be due to an extension of gonorrhœal urethritis or vaginitis; or it may occur with acute general infectious diseases. The mucous membrane is swollen and congested, although these alterations may not be very evident after death. There may be ecchymosis: the epithelium is granular and may proliferate and peel off. Leucocytes may infiltrate the submucosa and pass out between the epithelial cells

(Fig. 528). Mixed with the urine there may be shreds of mucus, pus cells, epithelial cells of various shapes, usually more or less swollen and granular, or fragments of such cells; red blood cells, bacteria, and various urinary crystals; abscesses may form in the mucous membrane; or there may be phlegmonous inflammation in the submucosa and muscularis of the bladder with formation of abscesses. Thus perforations and fistulæ may occur. Resolution may take place after acute catarrhal and exudative cystitis, but the inflammation very frequently assumes a chronic character.

Chronic Cystitis.—In this form the mucous membrane may be swollen, succulent, grayish, or mottled with spots of congestion or extravasation, and covered with a layer of mucus and pus. Microscopically the membrane may be more or less infiltrated with pus cells, and pus may be




FIG. 529.—HYPERPLASIA OF THE BLADDER EPITHELIUM.

The hyperplastic epithelium is transparent and, dipping into the submucosa, forms gland-like structures.

constantly produced and thrown off into the urine. Later the mucous membrane may become thickened either diffusely or in the form of tufts or polypi. In some cases it becomes atrophied. Owing to decomposition of the hæmoglobin in the extravasated blood the mucosa may become pigmented, brown, or slate-colored. The mucous membrane frequently becomes eroded, especially on the most elevated portions, or deep ulcerations may occur. The muscular coats may become paralyzed and the bladder dilated; or the submucosa or the muscularis, or both, may become hypertrophied. The mucous membrane may become encrusted with urinary salts.

In another class of cases the inflammation assumes a necrotic character. Larger and smaller shreds and patches of the mucosa die, become brown or gray in color, loosen or peel off, and become mixed with the urine and exudations. The gangrenous process may extend to all the

coats of the bladder, so that perforation and fatal peritonitis may occur. The gangrenous form of cystitis is more apt to occur in paralytics.

In still another class of cases the inflammation is suppurative. The submucosa, the intermuscular connective tissue, and the adjacent parts become infiltrated with pus, either diffusely or in the form of larger and smaller abscesses, which may open externally or internally, forming deep ulcers. In all these cases the inflammation may extend to the ureters and kidneys; it may skip the ureters and involve the kidneys.

The small nodules of lymphoid tissue in the mucous membrane of the bladder, especially near the neck, may become enlarged and prominent in cystitis, and may then be mistaken for miliary tubercles (nodular cystitis).

Hyperplasia of the epithelium of the bladder sometimes occurs in chronic cystitis and under other conditions. This may be diffuse or circumscribed and the epithelium may assume an epidermal character. Thus masses of transparent epidermis-like cells may lie between papillary projections of the submucosa, forming structures which resemble glands (see Fig. 529), or layers of flattened epithelium may cover or peel from the surface (see Fig. 530).¹

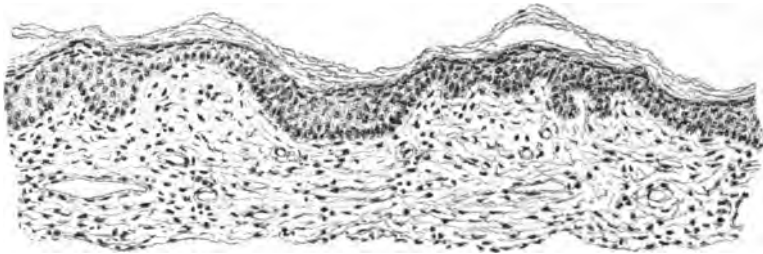


FIG. 530.—HYPERPLASIA OF THE BLADDER EPITHELIUM.
The epithelium has assumed the squamous type and is exfoliating.

A few cases have been described in which scattered over the mucous membrane of the bladder are small thickened areas, from two to fifteen millimetres in diameter, usually surrounded by a hyperæmic zone, and frequently ulcerated. These areas of chronic inflammatory thickening are formed by hyperplasia of the connective tissue with small-cell infiltration and by peculiar large cells which appear to be phagocytes containing red blood cells, fragments of other cells, bacteria, etc. The nature of this lesion is not yet clear. It has been called *malakoplakie* and *cystitis en plaque*.²

Croupous Cystitis.—In connection with any of the above lesions the mucous membrane of the bladder may be covered, in patches or sometimes over a considerable portion of its surface, with a layer of fibrin,

¹ For a study of regeneration in mucous membrane of the bladder see *Lasio*, Virch. Arch., Bd. clxxviii., p. 65, 1904.

² See for a description and discussion of this lesion *Landsteiner* and *Stoerk*, Ziegler's Beitr., Bd. xxxvi., p. 131, 1904.

either granular or fibrillar, enclosing pus and epithelial cells and bacteria. The mucosa may be infiltrated with fibrin.

This form of inflammation may occur in connection with severe infectious diseases—measles, diphtheria, scarlatina, typhoid fever; in connection with similar inflammation of the external genitals, in puerperal fever, noma, and sometimes in the presence of foreign bodies. It rarely occurs independently.

In the so-called **emphysematous cystitis**, due to the presence of *Bacillus aërogenes capsulatus*, larger and smaller gas blebs may be present in the mucosa and underlying tissue.¹

The most common micro-organisms which act as excitants of acute catarrhal and exudative cystitis are *Bacillus coli communis*, *Streptococcus pyogenes*, and *Staphylococcus pyogenes*, the gonococcus and typhoid bacillus,² *Bacillus proteus*, and *Bacillus aërogenes capsulatus*. Many other forms are of occasional occurrence.³

Tuberculous Cystitis.—There may at first be miliary tubercles formed in the submucosa. By the coalescence of these and the degeneration of tissue about them, ulcers are formed, and it is most frequently in the ulcerative stage that the lesion is seen. The ulcers, which may be large or small, are usually most abundant at the base of the organ. Their edges may be cheesy, and miliary tubercles in greater or smaller numbers are usually found in the mucosa about them. Not infrequently large shreds of tissue are loosened and cast off. The mucosa about the ulcers is apt to be infiltrated with small spheroidal cells. Tubercle bacilli are present in many of the tubercles and in the edges and base of the ulcers, and may be found in the urine. Catarrhal inflammation is a very constant accompaniment of this lesion. Tuberculous cystitis may occur in connection with tuberculous inflammation of the lungs and intestines, or of the kidney, uterus, prostate, etc.

TUMORS.

Small nodular **fibromata** may form in the submucosa.

Aside from the polypoid thickenings of the mucosa occurring in chronic cystitis, soft vascular **papillomata** are of frequent occurrence. These tumors vary in size from that of a pea to that of a pigeon's egg or larger. They consist of a fibrous, often very vascular stroma, and are covered on the surface with numerous small, closely set, villous projections, over which are irregular layers of elongated or cylindrical cells (Fig. 531). These tumors are very liable to bleed, are often accompanied by vesical catarrh, and may be covered by a precipitate of urinary salts. The epithelium is liable to peel off from the surface of the villi and appear in the urine. **Sarcoma** of the bladder has been described, but is rare.⁴

¹ See for bibliography *Kedrowsky*, *Centralbl. f. Path.*, Bd. ix., p. 817, 1898.

² See *Curschmann*, *Munchener med. Wochenschr.*, Oct. 16th, 1900, bibl.

³ For a study of bacteria of urinary passages see *Faltin*, *Cbl. f. d. Kr. d. Harn- u. Sex.- Org.*, Bd. xiii., 1902, p. 130, bibl.

⁴ See *Wilder*, *Am. Jour. Med. Sci.*, vol. cxxix., p. 63, 1903.

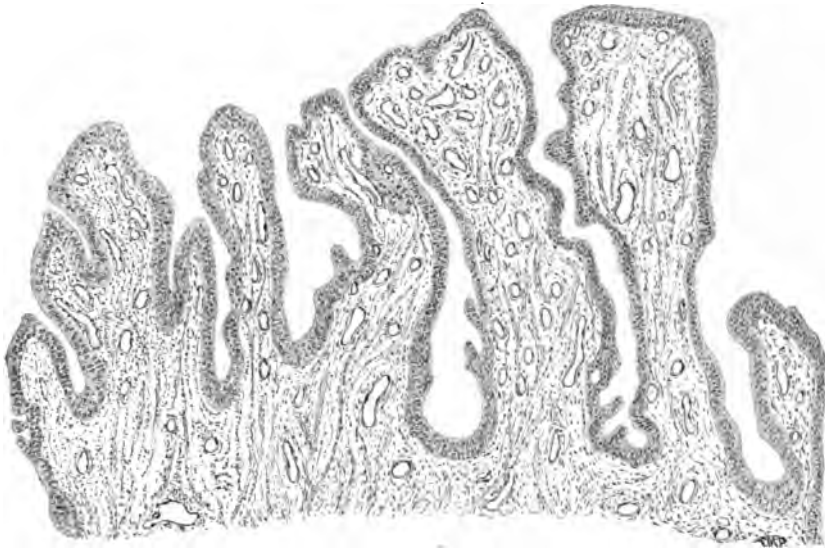


FIG. 531.—PAPILLOMA OF THE BLADDER.

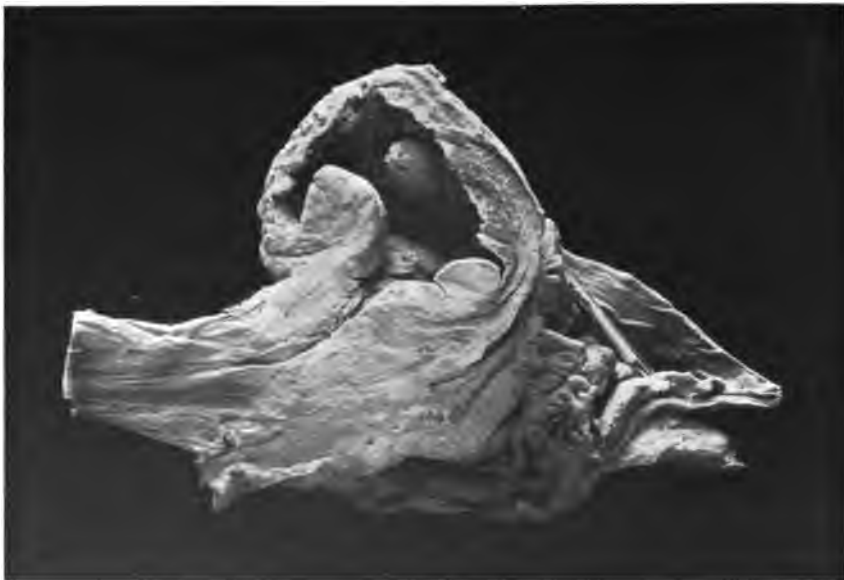

FIG. 532.—CARCINOMA OF THE BLADDER.

Myoma, adenoma, and angioma are recorded.

Carcinoma.—Carcinoma of the bladder is most frequently secondary, and is then rarely due to metastasis, but to an extension of the growth from neighboring parts, as the uterus, vagina, or rectum.

Primary carcinoma of the bladder may occur:

1. As a diffuse *scirrhous infiltration* of the entire wall of the bladder, usually with ulcerations of its inner surface.
2. As a *circumscribed nodule* (Fig. 532) which grows inward and outward, ulcerating on its inner surface, and sometimes producing perforations.

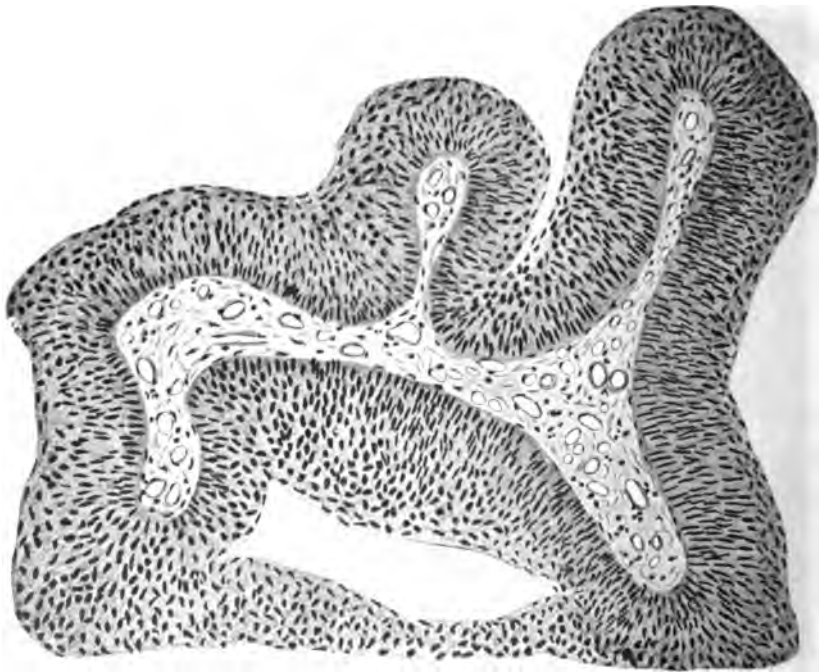


FIG. 533.—PAPILLARY CARCINOMA OF THE BLADDER.

3. As a *villous or papillomatous growth*. The tumor grows from one or more points of the inner surface of the bladder. It is formed of tubular follicles lined with epithelium (Fig. 533), while on its surface are tufts covered with cylindrical epithelium. The new growth may involve the entire thickness of the wall of the bladder.

4. A few cases of carcinoma have been described in which the stroma contained a varying quantity of smooth muscle tissue.¹

Cysts.—*Dermoid cysts* of the wall of the bladder have been described, but are rare.² Small cysts with serous contents sometimes occur in the

¹ For study of carcinoma of the ureter see *Metcalf and Safford*, *Am. Jour. Med. Sci.*, vol. cxxix, p. 50, 1905.

² See case by *Block and Hall*, *Am. Jour. Med. Sci.*, vol. cxxix., p. 651, 1905.

mucous membrane; a part of them, at least, are believed to be due to faulty embryonal development.

PARASITES, FOREIGN BODIES, AND CALCULI.

Among the animal parasites occasionally found in the bladder may be mentioned *Echinococcus*, *Distoma hæmatobium*, *Filaria sanguinis*, *Ascarides*, and *Oxyurides*.

A great variety of foreign bodies may be found in the bladder, particularly in the female. If their stay is long they are apt to become encrusted with urinary salts.

Calculi.

Vesical calculi may occur singly or in great numbers, and vary greatly in size, ranging from small, sand-like particles up to masses four or five inches in diameter; but the usual range is from the size of a pea to that of a hen's egg. They are usually oval, spheroidal, or elongated; or, when several are present, they are apt to be faceted. The surface may be smooth or rough. They are usually more or less distinctly lamellated, and are frequently formed around a central body called a nucleus, which may

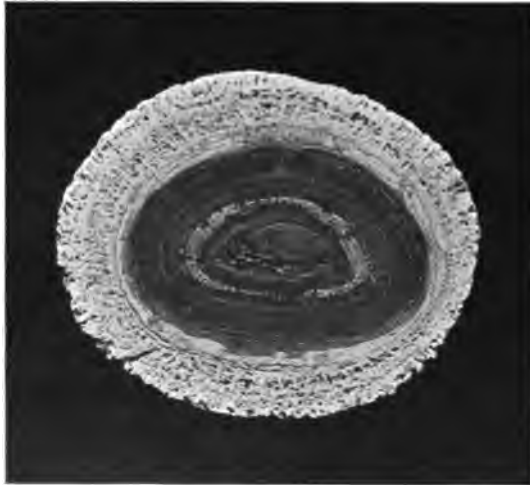

FIG. 534.—VESICAL CALCULUS.

Showing lamellations indicating successive depositions of different texture and composition.

either be formed of urinary salts or some foreign body. Their most common constituents are *phosphates*, *uric acid*, and *urates*, and *calcium oxalate*, or various combinations of these.

URIC-ACID CALCULI.—These are the most common of vesical calculi. In the form of small brownish red, crystalline aggregations they may be passed as "gravel." The larger uric-acid calculi are not commonly of very great size, are frequently finely nodulated on the surface, but may be smooth. The color varies from light yellow to dark reddish brown; they are usually dense and lamellated.

CALCULI FORMED OF URATES.—Calculi composed of pure urates are rare, these salts being more commonly combined with uric acid and the phosphates to form the complex calculi. Sodium urate, in the form of small spined, more or less globular crystalline masses, forms one of the varieties of "gravel."

PHOSPHATIC CALCULI.—Pure *calcium-phosphate* calculi are rarely found as whitish, usually smooth, and small lamellated concretions.

MIXED OR TRIPLE PHOSPHATE calculi are common, and frequently attain large size. These calculi are sometimes pure, but the deposit is more frequently associated with other salts, either as encrusting or intercalated lamellæ. Triple-phosphate calculi are usually rough on the surface, of grayish white color, lamellated, and frequently very friable (Fig. 534).

CALCIUM-CARBONATE CALCULI.—Small gray or white, hard, and usually smooth calculi of pure calcium carbonate occur rarely. Calcium carbonate is sometimes passed as gravel in the form of minute spheroidal bodies, either singly or in clusters.

CALCIUM-OXALATE calculi (mulberry calculi) are comparatively common, either pure or in combination with uric acid or the phosphates. Calcium oxalate may occur in the form of very small, hard, smooth concretions, or as larger, heavy, hard, finely or coarsely nodulated brown or blackish lamellated masses. The nucleus or some of the lamellæ, or both, are often composed of uric acid.

CYSTIN CALCULI are usually ovoidal in shape, of waxy consistence, of clear or brownish or greenish yellow color, with mammillated surface and crystalline fracture. Cystin may be associated in a variety of ways with other calculi.

XANTHIN CALCULI, which are very rare, are usually of moderate size, smooth, of a cinnamon or cinnabar-red color, lamellated, and oval or flattened in shape.

Solid masses of fibrin and blood sometimes occur in the bladder, and may exist as independent structures, or form nuclei for the deposit of urinary salts.

For a detailed account of calculi, the conditions under which they form, modes of analysis, etc., we refer to special works on this subject.

The Urethra.

Malformations.

Some of the malformations of the urethra are described with those of the penis.

The urethra may be impervious or may open at the root of the penis. More commonly there is partial obliteration or stricture of some part of the canal. The entire urethra may be dilated into a sac.

There may be a canal on the dorsum of the penis, formed by the fusion of the spermatic cords, and opening in the glans above the urethra.

There may be two or more openings of the urethra. The canal may be dislocated so as to open in the inguinal region.

A number of cases have been reported in which a valve in the urethra has led to hypertrophy of the bladder, dilatation of the ureters, and hydronephrosis.

Owing to its narrowness, greater length, and peculiar connections with the internal generative organs, the male urethra is much more liable to disease than the female.

Changes in Size and Position.

DILATATION of the urethra may be produced by strictures, or by calculi or other bodies fixed in its lumen. The dilatations are fusiform or sacculated in shape, and may reach the size of an orange or be even larger.

STRICTURES of the urethra are usually due to inflammation of its walls.

The stricture may be *temporary*, and due to a diffuse inflammatory swelling of the mucous membrane, or to the raising of the relaxed membrane into a fold or pocket.

Permanent strictures are produced by structural changes in the walls of the urethra.

1. The mucous membrane and submucous tissue become thickened in inflamma-

tion or as the result of injury and the new-formed fibrous tissue which contracts and narrows the canal.

2. Ulceration of the mucous membrane leaves cicatricial tissue, which contracts, and also produces adhesions and bands of fibrous tissue (Fig. 535).

3. There is fibrous induration of the corpus spongiosum and consequent constriction of the urethra.

The most frequent position of strictures is at the junction of the membranous and spongy portions of the urethra, or close to this point. They also occur at the fossa navicularis and meatus, but more frequently in the prostatic portion. There may be one stricture or several. The consequences of stricture are dilatation of the urethra,



FIG. 535.—STRICTURE OF THE MALE URETHRA.

the bladder, and the ureters, and hydronephrosis; inflammation and ulceration of the urethra behind the stricture, with perforation, infiltration of urine, or the formation of fistulæ.

The urethra may also be obstructed by folds of the mucous membrane; by muscular valves at the neck of the bladder; by wounds; by polypi and swollen glands; by new growths; by changes in the prostate and perineum; by calculi, mucus, blood, and echinococci coming from the bladder; by foreign bodies introduced from without.

PROLAPSE and inversion of the mucous membrane occur occasionally in young girls and women. There is a bluish-red swelling, from the size of a pea to that of a walnut, at the meatus. In the male, invagination of the mucous membrane of the urethra has been seen after injuries of the perineum.

INJURIES—PERFORATION—HÆMORRHAGES.

Wounds of the urethra are produced in many ways, but most commonly by catheters and bougies. The wounds may cicatrize, or there may be infiltration of urine or the formation of fistulæ or false passages.

Ruptures of the urethra are produced by severe contusions and by fracture of the pelvic bones. Extravasations of blood and urine, and gangrenous inflammation of the surrounding soft parts, are the ordinary results. Urethral varices in the female may lead to hæmorrhage.

Ulceration and *perforation* of the urethra may lead to the formation of fistulæ, which open in various directions through the skin.

INFLAMMATION. (Urethritis.)

Catarrhal Urethritis may be due to the action of chemical irritants, and to the extension to the urethra of inflammation from other parts; but its

most frequent excitant is the gonococcus. In its acute form it involves either a portion or the whole of the urethra. The mucous membrane is red, swollen, and covered with muco-pus. The epithelium may be loosened or exfoliated; pus cells are present in the submucosa between the epithelial cells. The gonococcus is present usually in considerable numbers in the exudate, both free and in the pus cells. It may penetrate between the epithelial cells.

Resolution may follow acute gonorrhœal urethritis. But the condition may become chronic and then is often confined to the posterior portions of the urethra. Here the gonococcus may persist for a long time and may be mingled with the exudate, which is now less purulent and consists very largely of mucus which in thread-like forms may be passed with the urine.

Chronic Inflammation of the urethra may exist for a long time with the production of a muco-purulent exudation, but without the occurrence of marked structural lesions. In other cases it leads to ulceration, to fibrous induration of the wall of the canal (see Fig. 535), to induration and swelling of the mucous follicles, to polypoid thickenings of the mucous membrane.

The inflammation may extend to the fibrous wall of the urethra, the corpora spongiosa and cavernosa. This may result in the formation of new connective tissue or of abscesses, especially near the fossa navicularis. There may be involvement of the bladder, the glands of Cowper, the prostate, the spermatic cord, and the testicles. The inguinal glands also may be swollen and inflamed, and the lymphatic vessels on the dorsum of the penis may be involved in the same process.

Membranous Inflammation is sometimes seen in children. Fibrinous casts of a small or large portion of the canal may be formed.

Tuberculous Inflammation occurs rarely in the mucous membrane of the urethra in connection with tuberculous inflammation of the bladder, prostate, or testicles.

Syphilitic Ulcers may be situated at the meatus or as far back as the fossa navicularis. They are apt to produce strictures.

TUMORS.

Aside from the polypoid outgrowths from the mucous membrane of the urethra as the result of chronic inflammation, **fibrous polyps** may occur congenitally, or polyps containing glandular structures or cysts rarely occur. **Carcinoma** may occur as a result of local extension from adjacent organs or metastasis from the bladder.

Cysts may occur in the membrane as a result of the dilatation of the mucous glands. Circumscribed masses of dilated veins occasionally occur in the urethra, forming the so-called **urethral hæmorrhoids**.

The sinus pocularis may be dilated in children by the retention of its secretion, so as to form a mass which may obstruct the exit of urine and lead to hypertrophy of the bladder and dilatation of the ureters.

CHAPTER X.

THE REPRODUCTIVE ORGANS OF THE FEMALE.

The Vulva.

Malformations.

THE external genitals may be entirely absent or imperfectly developed. The fissure between the labia may be unformed, or the labia may grow together, with or without obstruction of the urethra. The clitoris and nymphæ may be abnormally large, or the nymphæ may be increased in number. The clitoris may be abnormally long; at the same time the vagina is narrow, the uterus small and undeveloped or malformed; the ovaries are small, sometimes situated in the labia; the mammæ small, and the body is of a masculine character. Such cases are sometimes called pseudo-hermaphrodites. The clitoris may be perforated by the urethra or may be cleft and apparently double.

The hymen is subject to various anomalies. It may be entirely absent. The opening may be very large or in unusual places; there may be several openings; the free edge may be beset with papillary projections; there may be no opening at all.

HÆMORRHAGE, HYPERÆMIA, ETC.

Hæmorrhage may take place from wounds or ulcers of the vulva, but the most important form of hæmorrhage is that which occurs in the connective tissue of the labia majora. This may occur during labor or result from external injury. One of the labia may be much swollen and distended by the extravasated blood. The blood may be gradually absorbed, or it may decompose with suppuration or gangrene of the surrounding tissue.

Varicose Veins in the labia are not infrequent. **Œdema** of the labia majora may occur in pregnancy or in labor. It frequently accompanies disturbances of the venous circulation, as in certain heart and lung diseases; or it may occur in chronic diffuse nephritis or other wasting diseases; or as a result of thrombosis or other disturbances of circulation in the uterine or perivaginal venous plexuses. The latter may be excessive, leading to the transudation of fluid through the skin, to the formation of vesicles, or superficial erosion, or even of gangrene.

INFLAMMATION. (Vulvitis.)

The skin, mucous membrane, connective tissue, and glands of the vulva may be the seat of inflammation.

Acute Catarrhal Inflammation of the mucous membrane may be induced by a variety of substances, but is most frequently due to gonorrhœal infection. The mucous membrane is swollen and red and covered

with a muco-purulent exudate. The labia may be swollen, the glands of Bartholin are liable to be involved, and abscesses of the labia may be developed.

Chronic Catarrhal Inflammation may lead to superficial or deep ulceration of the mucous membrane, or to papillary outgrowths, or to thickening of the labia. Suppurative inflammation of the tissue of the labia may occur with a similar process in neighboring parts. **Erysipelatous Inflammation** of the skin of the vulva is frequent in young children. In adults it is less common. Inflammation of the vulvo-vaginal glands may be acute and lead to abscesses, or chronic and produce induration of the gland.

Gangrene may follow erysipelatous inflammation, or occur after parturition; it may accompany severe exhausting and infectious diseases. It may follow bruises or other injuries. In some forms, such as those known as *noma* and *hospital gangrene*, the destruction of tissue proceeds with extreme rapidity.¹

Membranous Inflammation may occur, with or without diphtheria and a similar lesion of the fauces or elsewhere, and is frequently associated with gangrene.

Tuberculous Inflammation, usually with ulceration, occasionally occurs in the vulva.

Syphilitic Inflammation and ulceration are of frequent occurrence on the vulva, particularly on the mucous surfaces, and may lead to considerable destruction of tissue and cicatricial contractions.

In one form, the so-called *mucous patch*, there is an infiltration of the papillary layers of the skin or mucous membrane with variously shaped cells and fluid, so that the tissue has a gelatinous appearance. In other cases there is an hypertrophy of the papillæ, so that larger and smaller wart-like excrescences are formed. This is called the *pointed condyloma*.

TUMORS.

Fibroma.—Circumscribed fibrous tumors are found in the connective tissue of the labia, mons veneris, perineum, clitoris, and entrance to the vagina. They may attain a large size, and, attached only by a pedicle, may hang far down between the legs. The skin is usually movable over the surface of these tumors.

Fibroma diffusum (elephantiasis).—This usually involves the clitoris or the labia, or both, and may extend to surrounding parts of the skin. It consists essentially of a diffuse hypertrophy of the skin and subcutaneous tissue, with or without involvement of the papillæ and epidermis. The surface may be smooth or rough. When the papillæ and epidermis are much involved, larger and smaller cauliflower-like excrescences may cover the hypertrophied parts, and the surface be very rough and scaly.

Papillomata.—These growths consist of hypertrophied papillæ covered with thick layers of epithelium. They vary in size from that of a pea to

¹ For a study of noma with bibl. see Blumer and MacFarlane, *Am. Jour. Med. Sci.*, vol. cxxii., 1901, p. 527.

that of an apple, and have a cauliflower appearance. **Lipoma, fibroma, fibro-sarcoma, and angioma** are of occasional occurrence in the vulva. A few cases of **melano-sarcoma** are recorded. **Chondroma** of the clitoris has been described. **Carcinoma** of the vulva may be primary, usually in the form of epithelioma of the clitoris or labia, or it may be secondary to cancer of the uterus, vagina, etc. **Adenoma** of Bartholin's glands is noted.

Cysts are found in the connective tissue of the labia majora and minora. They are from the size of a pea to that of a child's head. They may contain serum, colloid material, purulent or bloody fluid, or they may have the characters of dermoid cysts or atheroma cysts. Their origin is in many cases obscure. In some cases they are doubtless due to dilatation of lymph-vessels. Cysts may be formed by a stoppage and filling with fluid of the canal of Nuck, or by a dilatation of the ducts or acini of the vulvo-vaginal glands.¹

The Vagina.

Malformations.

The vagina may be entirely absent, and the internal organs of generation also absent or imperfectly developed. Either the upper or the lower portion of the canal may be absent while the remaining portion is present.

The vagina may be closed by an imperforate hymen or by fibrous septa at any part of its canal. The canal may be abnormally small without being occluded.

The vagina may be double, in connection with a double uterus; or, while the uterus is normal, the vagina may be incompletely divided by a longitudinal septum.

Changes in Size and Position.

DILATATION of the vagina is produced by tumors, by the prolapsed uterus, and by the accumulation of blood and mucus behind constrictions or obliterations of the canal.

LENGTHENING of the vagina is produced by any cause which draws the uterus upward. **NARROWING** occurs as a senile change, is produced by the pressure of tumors, or may follow ulceration of the wall of the canal through cicatricial contraction.

PROLAPSE of the vagina occurs independently, usually as a result of thickening or laxity of its walls, or in connection with prolapse of the uterus. It may occur soon after parturition. A larger or smaller portion of the canal is inverted and projects through the vulva. The entire circumference of the canal may be inverted and prolapsed, or only the anterior or posterior wall. The prolapse, at first small, may afterward gradually increase in size and drag down the uterus with it. In other cases prolapse of the uterus is primary, and the vagina is inverted by the descent of that organ; or the body of the uterus may retain its normal position, while an hypertrophy and lengthening of the cervix alone drags down the vagina.

HERNIA VESICO-VAGINALIS—CYSTOCELE—may be either the cause or effect of a prolapse of the vagina and uterus. If the cystocele be the primary lesion, it begins as a small projection of the wall of the bladder into the anterior part of the vagina. As the urine accumulates in this sac it increases in size, projects through the vulva, draws down the vagina and the anterior lip of the cervix, and finally the entire uterus. If the cystocele be the secondary lesion, it is produced by the dragging down of the posterior wall of the bladder by the inverted vagina.

HERNIA INTESTINO-VAGINALIS.—A portion of the intestines may become fixed in Douglas' cul-de-sac between the rectum and the uterus. This portion of intestine gradually becomes larger, pushes forward the posterior wall of the vagina, inverts and

¹ For a study of cysts of Bartholin's glands see *Cullen*, Jour. Am. Med. Assn., vol. xlv., p. 204, 1905.

fills up that canal, and finally projects through the vulva. It may drag with it the posterior wall of the vagina and the uterus.

RECTOCELE VAGINALIS.—A sac is formed by the projection of the anterior wall of the rectum and the posterior wall of the vagina. This lesion is of rare occurrence and does not reach a large size.

When the vagina is prolapsed there is usually inflammation of the lining membrane or a thickening of the epidermis.

WOUNDS—PERFORATIONS.

Wounds of the vagina are made by penetrating instruments, by forceps and other obstetrical weapons, by the fœtus during delivery, or may result from coitus. Such wounds may heal, or give rise to large hæmorrhages, or suppurate, and lead to abscesses in the surrounding tissue, or leave fistulous openings into the vagina; or they may by cicatricial contraction in healing lead to constriction or obliteration of its canal.

Vesico-vaginal Fistulæ are usually produced by injuries from instruments or from the fœtus during delivery; less frequently by ulceration of the vagina, bladder, or adjacent connective tissue, or by abscess in the surrounding parts. The fistulæ form an opening between either the bladder or the urethra and the vagina. They allow the urine to pass into the vagina. Spontaneous cure does not take place.

Recto-vaginal Fistulæ are formed in the same way as the last-mentioned. They allow the passage of gas or fæces into the vagina. They sometimes heal spontaneously.

INFLAMMATION, (Vaginitis.)

Catarrhal Inflammation of the vaginal mucous membrane may be acute or chronic. It is most frequently induced by the gonococcus, but may be due to local irritation or accompany active infectious processes. It not infrequently occurs in the new-born. In the acute form the mucous membrane is swollen and frequently covered with a muco-purulent or a purulent exudation. In the chronic form the mucous membrane may be swollen, covered with a purulent exudation; there may be an exfoliation of epithelium, shallow or deep erosions, or ulcers.

Sometimes large shreds or membranes are cast off from the vagina which consist wholly of exfoliated, flat epithelium.¹ In other cases the mucous membrane is thickened, dense, and sometimes pigmented, or it may be roughened, covered with papillæ, or it may be relaxed and prolapsed.

Membranous Inflammation may occur after parturition, in dysentery, typhus and typhoid fevers, diphtheria, scarlatina, measles, and other infectious diseases. The mucous membrane is swollen and covered with a grayish layer of fibrin and pus. The mucosa and submucosa may be infiltrated with fibrin and pus. The infiltrated portions of the mucosa and submucosa may die and become gangrenous, and thus deep and extensive ulcers be formed.

¹ Consult *McFarland*, Proc. Phila. Path. Soc., N. S., vol. ii., p. 115, 1899.

Suppurative Inflammation of the fibromuscular coat of the vagina may occur after injuries or in pregnant and puerperal women. Abscesses may be formed which penetrate into the labia or into the pelvic connective tissue. In other cases the intense phlegmonous inflammation may lead to the death and casting-off of portions of the vaginal wall, or even of the entire wall.

Emphysematous Vaginitis.—Anaërobic bacilli developing in the vaginal wall may give rise to small cysts or blebs.

Gangrene of the vagina may occur as a result of croupous or intense suppurative or syphilitic inflammation, or from unknown causes. In the form of *noma* it may be very extensive and rapidly destructive.

Tuberculous and Syphilitic Inflammation, usually leading to more or less extensive ulceration, may occur in any part of the vagina. Tuberculous inflammation is usually secondary to tuberculosis of other parts. Syphilitic ulcers may heal, sometimes leaving marked cicatrices, and sometimes not.

TUMORS.

Fibroma, fibro-myoma, sarcoma, myoma lævicellulare, are of occasional occurrence in the vagina. **Myoma striocellulare** is of rare occurrence. A **teratoma** has been described and a few cases of **endothelioma**.¹

Papillomata are of frequent occurrence as a result of chronic inflammation. **Carcinoma** of the vagina is usually secondary to cancer of the uterus. It may be primary and nodular, or more often it is papillary and ulcerating and spreads to adjacent parts.

Cysts.—These are not very common and may be small or as large as a hen's egg. They may be lined with flattened epithelium, and contain serous or viscid, dark-colored or transparent fluid.²

PARASITES.

Among the animal parasites **Oxyuris** and **Trichomonas vaginalis** are of occasional occurrence. Among the vegetable forms **Oidium albicans** and **Leptothrix** are occasionally seen, while various forms of **bacteria** are common. **Staphylococcus** and **Streptococcus pyogenes** have been found many times in the normal vagina. While these and other bacteria may be harmless in the normal vagina, should conditions favoring their growth or an increase in their virulence occur, as after delivery for example, serious infectious processes may follow. The rôle of the gonococcus as an excitant of catarrhal inflammation is well established.

The Uterus.

Congenital Malformations.

The uterus, tubes, and vagina may be entirely absent, with or without absence of the external genitals. Or the uterus alone, or the upper part of the vagina also, may be absent.

¹ See *Raschkes*, Cbl. f. Path., Path., Bd. xiv., 1903, p. 657.

² Consult *Stokes*, Johns Hopkins Hosp. Rep., vol. vii., p. 109, 1899, bibl.; also *Cullen*, Johns Hopkins Hosp. Bull., vol. xvi., p. 207, 1905.

The uterus may be only rudimentary while the vagina is normal. It then appears as a flattened solid body with solid cornua. Or there are two cornua joined at their lower extremities so as to form a small double uterus (Fig. 536). Or the uterus is represented by a small sac, which may or may not communicate with the vagina. Or there is a very small uterus, with thin muscular walls and two large cornua.

Only one of the cornua which should form the uterus may be developed while the other is arrested in its growth. The uterus is then a long, cylindrical body, terminating above in one tube. On the side where the horn should have been developed there is no tube, or only a rudiment. Both ovaries are usually present.

The two cornua may be fully developed, but their lower ends remain separated and form a double uterus. An entire separation into two distinct uteri and vaginæ is

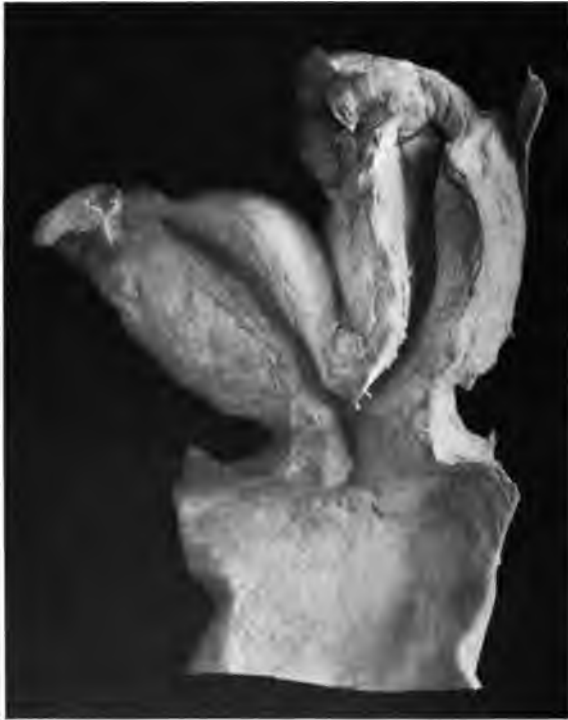

FIG. 536.—UTERUS BICORNIS.

rare. More frequently the uterus consists of one body, divided by a septum into two cavities. There are then two cervical portions of the uterus projecting into a single vagina, or each into a separate vagina. Or there is only a single cervix. The septum in the uterus may be complete or only partial.

The uterus may be abnormal in size or be variously flexed; the cervix may be solid or may be closed by the vaginal mucous membrane. Or the cervix may have an abnormal form with a small opening or canal.

Changes in Size.

In the new-born infant the uterus is small, the body flattened, the cervix disproportionately large. During childhood the organ increases in size, but the body

remains small in proportion to the cervix. At puberty the shape changes and the body becomes larger.

At every menstruation the uterus is somewhat swollen and congested. After pregnancy it does not return to its virgin size, but remains somewhat larger. In old age it gradually becomes smaller; its walls are harder and more fibrous.

ABNORMAL SMALLNESS of the uterus is sometimes found as an arrest of development. It may result, however, from chronic endometritis, from repeated pregnancies, from old age, or from chronic exhausting diseases. Its cavity may be smaller than normal, or distended with mucus. Large myomata sometimes induce atrophy of the uterine wall. Atrophy of the vaginal portion of the uterus is sometimes observed after repeated pregnancies. Narrowing and obliteration of the cavity of the uterus and of the cervix are usually produced by chronic inflammation.

ENLARGEMENT OF THE UTERUS may be due to too early development. It is accompanied by abnormally early development of all the sexual organs and functions. The uterus may be enlarged in connection with heart disease, prolapse and abnormal flexions and versions, chronic inflammations, repeated pregnancies, myomata, and accumulations of blood or mucus in the uterine cavity. Enlargement of the vaginal portion alone may occur. One or both lips of the cervix may be uniformly increased in size, or they may be lobulated.

Dilatation of the uterus is produced by accumulations of blood, mucus, or pus in consequence of narrowing or obliteration of the cervix or vagina. The uterine walls

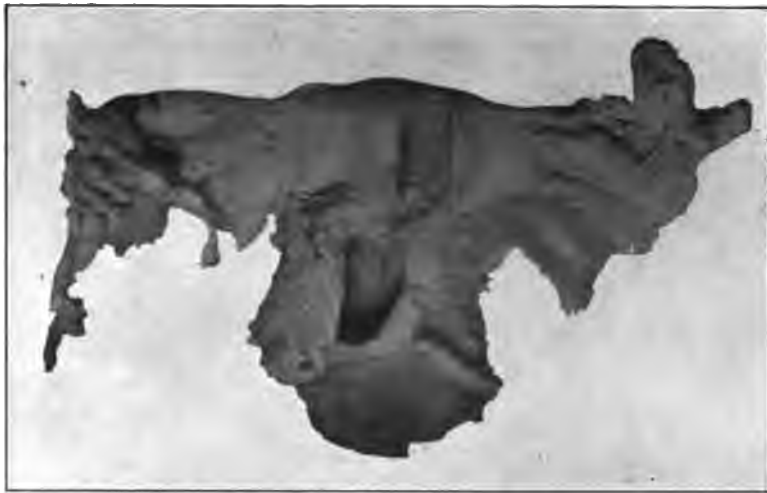

FIG. 537.—**HOUR-GLASS UTERUS.**

Showing a small uterus with distention of the cavities of the body and cervix from fibrous-tissue contraction at the os externum and the os internum.

may retain their normal thickness, be thickened or thinned. The most frequent position of the stenosis is the os internum. The retained contents after a time change in character, forming a thin, serous fluid—*hydrometra*—or they may be mixed with blood. The dilated uterus may be of enormous size. If both os internum and os externum are closed the cervical cavity may be also dilated and the uterus have an hour-glass shape (Fig. 537); or the dilatation may be limited to the cervix. If the obstruction is not complete, the retained fluid may escape into the vagina and be followed by a fresh accumulation. If the obstruction be in the vagina, the uterus and vagina may form a large, flask-shaped body, and the line of demarcation between cervix and vagina be lost.

Accumulation of menstrual blood in the cavity of the uterus—*hæmatometra*—is usually due to congenital stenosis of the cervix or vagina, and may be very great. If the fluid is not evacuated by surgical interference there may be either rupture or ulcerative perforation of the uterus. The blood may escape into the abdominal cavity, or be shut in by adhesions, or perforate into the bladder or intestines. Sometimes the blood passes into the Fallopian tubes, dilates them, and escapes through their abdominal ends.

Changes in Position.

The body of the uterus may become fixed in an abnormal position, while the situation of the cervix is unchanged.

FLEXION.—The body may be bent forward—*anteflexion*; backward—*retroflexion* (Fig. 538); or sideways—*lateral flexion*. The flexion may be slight, or so great that the neck and body form an acute angle. Anteflexion is the most common variety,

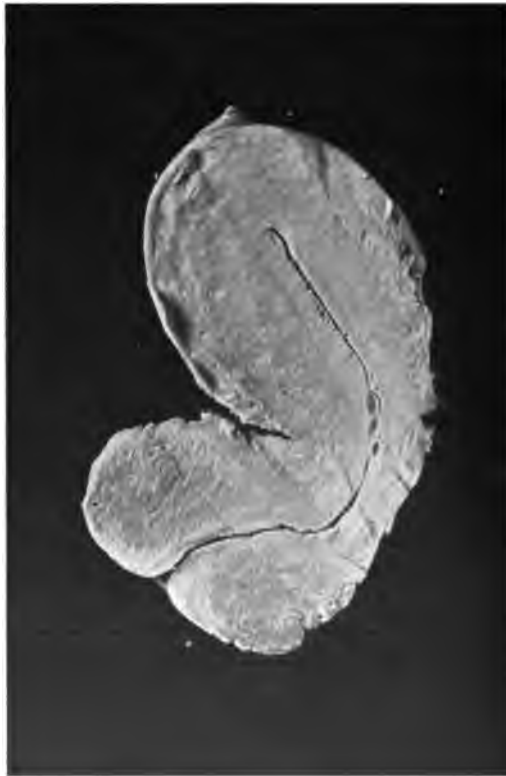

FIG. 538.—RETROFLEXION OF THE UTERUS.

Small cysts may be seen in the mucous membrane of the body.

and that in which the flexion is greatest. Peritoneal adhesions, flaccidity of the uterine walls, particularly after delivery, atrophy of the walls, ovarian and other tumors, etc., are the usual causes of flexion.

VERSION of the uterus consists in an abnormal inclination of the long axis of the organ to that of the vagina. The uterus may be inclined backward, forward, or to one side.

Retroversion is the most common. The fundus uteri is directed backward and downward, the cervix forward and upward. This condition is found in various degrees; in the highest the fundus lies in Douglas' cul-de-sac with the cervix upward, so that the axis of the uterus is parallel to that of the vagina, but in a direction nearly opposite to the normal. Abnormal looseness of the uterine ligaments, abnormally large capacity of the pelvis, enlargement or tumors of the uterus, and pregnancy during the first four months, are some of the more common conditions under which this lesion occurs.

Anteversion.—Inclination of the fundus forward and downward, and of the cervix backward and upward, is not common and seldom reaches a high degree. It occurs under the same general external conditions as antelexion.

Lateroversion is not very common as a simple lesion, but is not infrequently combined with other displacements. It may be produced by congenital shortening of one of the broad ligaments, by adhesions, or by the pressure of tumors.

The greater degrees of version may produce very grave lesions. The urethra and rectum may be compressed. Cystitis, perforation of the bladder, dilatation of the ureters and hydronephrosis, and fatal obstruction of the bowels may follow. If pregnancy exist abortion may take place, or the inverted uterus may be forced through the peritoneum and posterior wall of the vagina and project through the vulva. In the non-pregnant uterus pressure on the veins and consequent chronic inflammation of the organ may follow.

PROLAPSUS UTERI consists of a descent of the uterus into the vagina. The uterus may be only slightly lowered or it may project at the vulva (Fig. 539). In complete prolapse we find a tumor projecting through the vulva, partly covered by the distended vagina, and presenting the opening of the os externum near its centre. The bladder and rectum may be drawn down with the vagina or may remain in place. The exposed cervix and vagina usually become inflamed and sometimes ulcerated, or the mucous membrane may become thickened. The lesion is frequently complicated by hypertrophy of the cervix.

Gradual prolapse, which is most frequent, may be due to an increased weight of the uterus, as in pregnancy, inflammatory enlargement, the presence of tumors, etc.; or to some abnormal condition of the uterine supports. It is frequently due to a vaginal cystocele or rectocele. Sudden prolapse is most apt to occur in an enlarged uterus or one unduly heavy by reason of tumors connected with it. It is most common in subinvolution after parturition.

ELEVATION of the uterus is produced by mechanical causes crowding or dragging it upward, as adhesions, tumors, etc. The vagina is drawn up and lengthened, and the vaginal portion of the cervix may be obliterated.

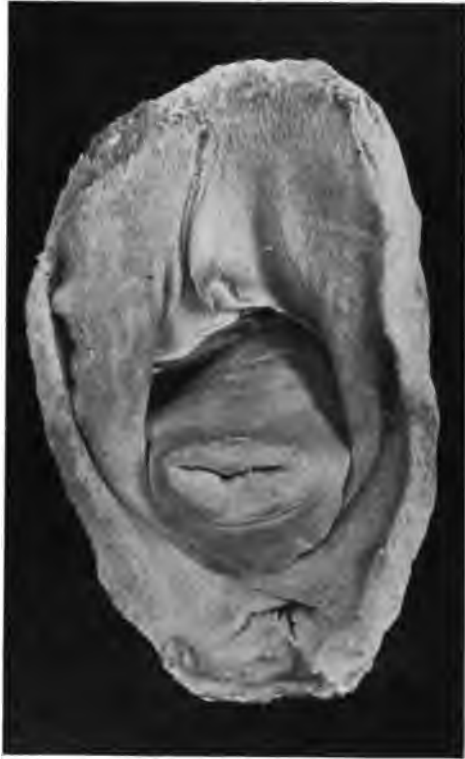

FIG. 539.—PROLAPSE OF THE UTERUS.
The cervix projects from the vulva and there are small ulcerations about the os externum.

INVERSION of the uterus consists of an invagination of the fundus. The fundus may be invaginated in the body, the fundus and body in the cervix, or the entire organ in the vagina. It usually occurs when the uterine walls are relaxed, and may be due to traction on the placenta during parturition. It may take place spontaneously after parturition. It may be produced by intra-uterine tumors. The mucous membrane of the inverted organ is frequently inflamed, particularly when the inversion is complete. The epithelium may become squamous and lamellated in type.

HERNIÆ of the uterus are rare. *Ventral herniæ* may occur during the latter months of pregnancy, the peritoneum, aponeurosis, and skin being forced outward to form a sac in which the uterus lies. *Crural herniæ* are produced by the drawing down of the uterus and ovaries into the sac of an intestinal hernia. *Inguinal hernia* may be produced in the same way or be congenital. *Ischiatic hernia* has been seen. Pregnancy may occur in the uterus while it is within a crural or inguinal hernia.

RUPTURE AND PERFORATION.

Rupture of the unimpregnated uterus is rare. It may, however, occur when the uterine cavity is distended with blood or serum, or in connection with large myomata of the uterine walls.

In the gravid uterus ruptures have been seen in nearly every month of pregnancy, but most frequently toward the end. The rupture may be due to a thinning of the uterine wall by tumors or by violent contusions, or as the result of cicatricial contraction of the os.

It most frequently takes place in parturition. Malpositions of the fœtus, narrowing of the pelvis, protracted labor, thinning of the uterine wall from tumors, forcible use of the forceps and other instruments, are the ordinary causes. The rupture may be in the body of the uterus or the cervix, or both; it may be large or small; it may extend completely or only partly through the uterine wall. The consequences of partial rupture are hæmorrhage, gangrenous inflammation of the edges of the rupture, peritonitis, and usually death. In rare cases the rupture cicatrizes and the patient recovers. Complete rupture usually leads to death in a short time. The fœtus may escape partly or completely into the abdominal cavity. If the patient survive the immediate shock, fatal peritonitis usually soon ensues. In rare cases the fœtus is shut in by adhesions and the patient survives.

Perforations of the uterus may be produced by carcinoma, by abscesses in its neighborhood, and by ovarian cysts.

HYPERÆMIA—UTERINE AND PERI-UTERINE HÆMORRHAGE.

Hyperæmia.—Aside from the active menstrual hyperæmia, the uterus may be hyperæmic in acute and chronic inflammation, as a result of displacement of the organ, and in certain forms of heart disease. The organ is usually enlarged, the mucous membrane swollen, and the veins are more or less evidently dilated. **Edema** may be associated with hyperæmia.

Hæmorrhage.—Effusion of blood into the cavity of the uterus occurs normally at the menstrual periods. For the abnormalities to which this function is subject we refer to works on gynecology. Effusions of blood at other than the menstrual periods may be associated with mechanical

hyperæmia, hæmorrhoids, acute hyperæmia, intrauterine polypi and other tumors, acute and chronic inflammation, typhus fever, scurvy, etc., ulcerating carcinoma, abortions, and miscarriage.

A peculiar form of hæmorrhage results in the so-called *polypoid hæmatoma*, or *fibrinous polyp*. It occurs after parturition and after abortions. The portions of the uterine wall where the placenta was attached, with or without a portion of retained placenta, forms the point of attachment of the pedicle of the thrombus. A bloody mass is firmly attached by a pedicle to the uterine wall; the uterus enlarges with its formation, the cervix is dilated, and the thrombus may project into and fill the vagina. The formation of such a thrombus is accompanied by repeated hæmorrhages.

Hæmorrhage in the substance of the uterus occurs in arterio-sclerosis. The mucous membrane and uterine wall or the cervix are infiltrated with blood, and there may be blood in the uterine cavity.

Peri-uterine or Retro-uterine Hæmatocele consists in an accumulation of blood around the uterus or in Douglas' cul-de-sac. The hæmorrhagic mass may become encapsulated with fibrous tissue, or may soften or suppurate and perforate into rectum or vagina, or may be absorbed. A form of extraperitoneal hæmatocele is described in which the blood lies between the folds of the broad ligament. The extravasation may proceed from hæmorrhage of any of the abdominal viscera or rupture of aneurisms; from vascular new-formed false membranes; from rupture of the varicose veins of the broad ligaments; from rupture of hæmorrhagic cysts of the ovaries; from rupture of the Fallopian tubes in tubal pregnancy or in hæmatometra; or from general causes, such as scurvy, purpura, etc. In some cases the extravasation begins at a menstrual period, and increases at the succeeding periods.

Ante-uterine Hæmatocele is of occasional occurrence, either in connection with the retro-uterine form or when the posterior cul-de-sac is obliterated.

ATROPHY, DEGENERATION, ETC.

Atrophy of the uterus occurs as a physiological process in old age. It may be associated with severe general or infectious diseases or follow removal of the ovaries. It may follow pregnancy apparently as an excessive involution process.

Fatty Degeneration.—This may occur in connection with inflammatory changes, in acute infectious diseases, and in phosphorus poisoning.

Amyloid Degeneration in the uterus is of rare occurrence. It may affect the muscle fibres or the walls of the blood-vessels.

Phagedenic or Corroding Ulcer.—This rare and little understood form of ulceration usually occurs in old age. It begins in the cervix and gradually extends until it may destroy the greater part of the uterus or even invade the bladder and rectum. The ulcer is of irregular form; its base is rough and blackish, its walls are indurated. It should not be confounded with carcinomatous ulcer, which it considerably resembles.

INFLAMMATION. (Metritis and Endometritis.)**I. INFLAMMATION OF THE UNIMPREGNATED UTERUS.**

Acute Catarrhal Endometritis.—In this disease, which in its lighter grades may leave but little alteration after death, the mucous membrane is swollen, hyperæmic, and sometimes the seat of punctate hæmorrhages. The epithelium may be degenerated and may desquamate, and the mucosa contain an undue quantity of small spheroidal cells. The surface is more or less thickly covered with muco-purulent exudate. In severe cases shreds of mucous membrane may be exfoliated. The lesion is usually most marked in the mucous membrane of the body, but may involve the cervix at the same time, or the cervix alone. The body of the uterus may be swollen and hyperæmic.

In *endometritis exfoliativa* (membranous dysmenorrhœa) there may be an expulsion, with more or less blood, of membranous masses consisting of fibrin mingled with blood and pus cells, or consisting of exfoliated superficial layers of epithelium. This exfoliated epithelium is frequently much flattened so as considerably to resemble the vaginal epithelium. When the shreds are large the openings of the uterine glands may be seen as perforations.¹

Acute catarrhal inflammation of the uterus may be due to injury, exposure during menstruation, gonorrhœal infection, local infection with

other bacteria,² or it may accompany the general acute infectious diseases.

Chronic Endometritis.—

This may be a continuation of an acute inflammation or begin as a chronic process. In some of the lesser degrees of inflammation but slight changes are found after death. The mucous membrane, on the other hand, may be swollen, hyperæmic, and covered with muco-purulent exudation. In other cases there is more or less well-marked thickening of the mucous membrane, which may present

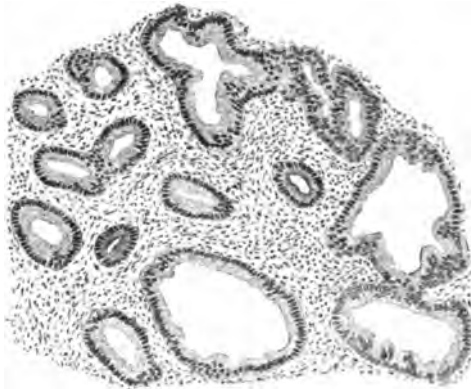


FIG. 540.—CHRONIC ENDOMETRITIS, SHOWING GLANDULAR HYPERPLASIA OF THE MUCOUS MEMBRANE.

The stroma of the mucosa is increased in amount and is dense and fibrous in texture.

a smooth or a rough papillary surface or polypoid outgrowths.

The thickened mucous membrane may show on microscopical examination considerable hyperplasia of the uterine glands. These may be fairly normal and regular in type; or the epithelial cells may be much

¹ See *De Witt*, *Am. Jour. of Obstetrics*, vol. xlii., 1900, bibl.

² For an account with bibl. of the bacteria of the vagina see *Williams*, *Am. Jour. of Obstetrics*, vol. xxxviii., No. 4, 1898; for bacteria of non-pregnant uterus see *Miller*, *Johns Hopkins Hosp. Bull.*, vol. x., p. 29, 1899, bibl.; also ref. to *Wadsworth*, p. 809.

increased and irregularly massed within the tubules (Fig. 540); the hyperplastic glands are often contorted, forming irregular spirals (Fig. 541). The interglandular stroma of the mucosa may be little changed or much thickened; it may be dense or very loose in texture and formed largely of small fusiform and spheroidal cells. It is often extremely vascular and may be the seat of interstitial hæmorrhage. If there be considerable growth of new gland structure the condition is called "*glandular hyperplasia*" of the mucous membrane. It is often difficult, in the microscopical examinations of small portions removed from the uterine mucous membrane by curetting, to decide whether the lesion be a simple glandular

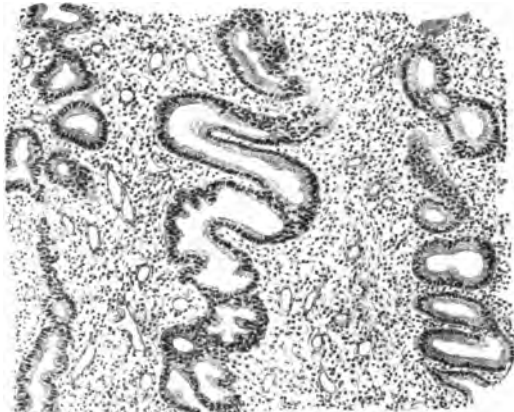


FIG. 541.—CHRONIC ENDOMETRITIS.

Showing glandular hyperplasia of the mucous membrane. The stroma of the mucosa is increased in amount and is loose in texture. The glands are contorted.

hyperplasia or adenoma. In fact glandular hyperplasia may apparently lead to so excessive and unrestrained a growth of glandular structures in the mucous membrane as to justify the designation adenoma or *malignant adenomatous hyperplasia*.

Sometimes a thick layer of new-formed, very vascular tissue develops over the surface of the mucous membrane, largely covering in the uterine glands (Fig. 542). From the decomposition of extravasated blood in the mucous membrane the latter may be mottled with brown or black. The glandular elements of the mucosa may be partially or almost entirely destroyed. Occasionally the glands are dilated, forming numerous small cysts which may project from the surface. The papillæ of the cervix may be hypertrophied, the mucous follicles swollen and their outlets obstructed, leading to the formation of the so-called ovula Nabothi. The uterine wall becomes flaccid and atrophied, or it may be hyperplastic especially in the cervical portion. Ulceration of the mucous membrane, especially of the cervix, may occur. There may be contraction or obliteration of the cervical canal.

Fibrous hyperplasia of the cervix with ectasia of the Nabothian glands and thickening and erosion or ulceration of the mucous membrane

is a frequent condition at the climacteric period (Fig. 543). Under these conditions both the clinical manifestations and the general appearance of the cervix on inspection often suggest the existence of cancer.

Chronic endometritis may occur at any age, but is most frequent after puberty, and is due to a great variety of conditions. It may occur in ill-nourished persons or in those suffering from exhausting diseases.

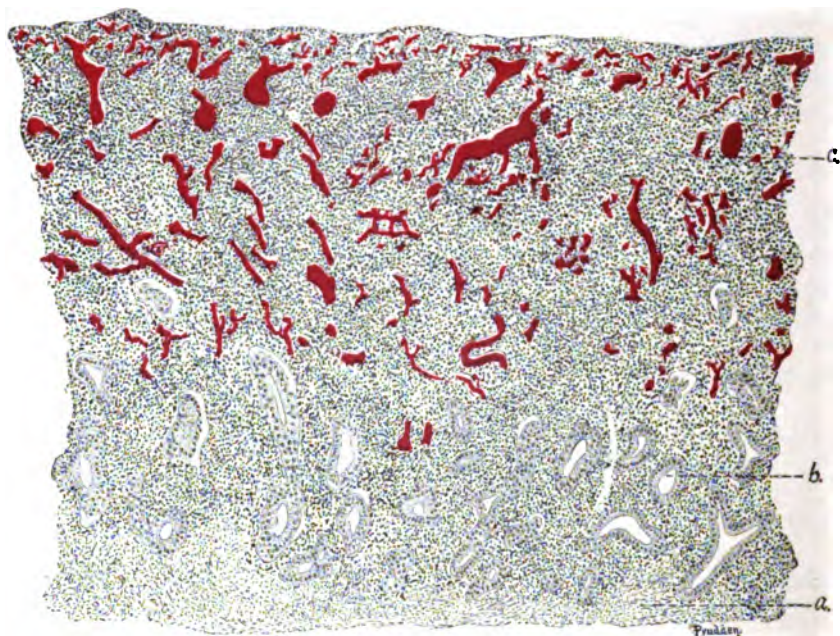


FIG. 542.—CHRONIC ENDOMETRITIS WITH THE FORMATION OF A THICK LAYER OF NEW-FORMED, VERY VASCULAR TISSUE OVER THE SURFACE OF THE MUCOUS MEMBRANE.

a, Uterine muscle tissue; b, mucous membrane of uterus; c, new-formed vascular tissue.

It may follow displacements and tumors of the uterus, subinvolution, injuries, etc.

Membranous Endometritis.—This form of inflammation is not very common. It occasionally occurs in the puerperal uterus, and in acute infectious diseases. It sometimes involves the vulva, vagina, and Fallopian tubes. It may coexist with membranous inflammation of the colon.

Tuberculous Endometritis.—This is rare and usually occurs as part of tuberculous inflammation of the genito-urinary tract. A part or the whole of the cavity of the uterus may be lined with a rough, yellowish or gray, caseous mass, which may deeply involve the muscular walls of the organ. At the edges of the ulcerating caseous areas there may be miliary tubercles, or these may be scattered through the otherwise intact mucosa.¹

¹ For bibl. see Cullen, Johns Hopkins Hosp. Rep., vol. iv., p. 441, 1895.

Syphilitic Endometritis.—This is usually confined to the cervical portion, and is characterized by shallow or deep ulcerations and condylomata of the mucous membrane; or there may be a diffuse thickening of the mucosa.

Acute Metritis is usually associated with acute catarrhal endometritis. The organ is swollen, succulent, congested; the mucous membrane cov-

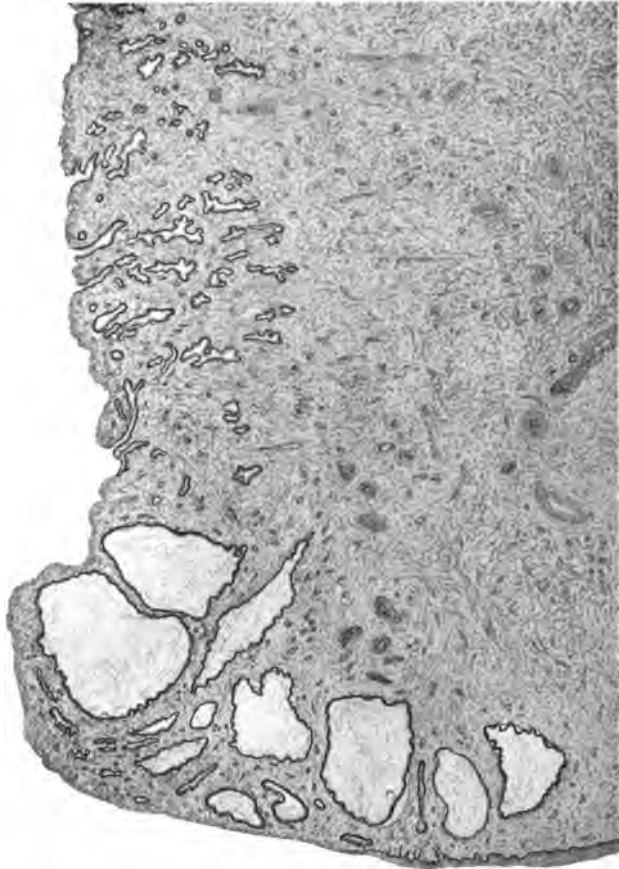


FIG. 543.—FIBROUS AND GLANDULAR HYPERPLASIA OF THE CERVIX UTERI.

The figure shows one side of the cervix in longitudinal section. The fibrous tissue of the cervix is very dense and the walls of the blood-vessels are thickened. There is hyperplasia of the glands of the cervical canal with erosion of the surface epithelium. The Nabothian glands are distended with clear, glairy fluid (ovula Nabothi). There is erosion of the epithelium at the os externum, and this, with the congestion of the small superficial vessels here, gave a rough red appearance to the os, suggestive of a malignant growth.

ered with muco-pus; the peritoneal coat congested. There may be small extravasations of blood in the wall or cavity of the uterus. The inflammation, in rare cases, becomes suppurative, and abscesses are formed in the uterine wall; these may perforate into the peritoneal cavity or into the rectum.

Chronic Metritis may follow acute metritis or accompany acute or chronic endometritis, and is dependent upon similar conditions: subinvolution, displacements, tumors, active irritants, etc. The uterus is enlarged, the wall congested, thickened, and soft, or, owing to the new formation of connective tissue, hard and dense. The lesion may be most marked in the body or in the cervical portion.

Perimetritis.—The peritoneal coat of the uterus may be inflamed, with the production of membranous adhesions or of pus. The adhesions may be small or very extensive, and, owing to their contractions, may cause various distortions and displacements of the pelvic organs. The inflammation is usually an accompaniment of chronic metritis and endometritis. In prostitutes such adhesions are of very common occurrence.

Parametritis.—The connective tissue about the uterus, between that organ and the reflexions of the peritoneum, may be the seat of suppurative inflammation. It most frequently ends in death, but may result in the formation of dense connective tissue about the uterus.

II. INFLAMMATION OF THE PREGNANT UTERUS.

The forms of inflammation which have just been described may also occur in the pregnant uterus. **Catarrhal endometritis** may lead to effusion of serum, extravasations of blood, and abortions. Metritis may lead to softening of the uterine wall, so that rupture takes place during labor. Perimetritis and parametritis produce adhesions and abscesses about the uterus.

Infectious Inflammation (Puerperal Fever).—For a week or more after delivery the inner surface of the still dilated uterus is rough, especially at the insertion of the placenta, and covered with dark shreds of blood, mucous membrane, and placenta. This condition should not, as is sometimes the case, be mistaken for inflammation or gangrene.

As a result of injury to the uterus or vagina during or after delivery, and the action of bacteria which may gain access to the tissues in this vulnerable state, the puerperal uterus is liable to become the seat of a series of severe and often destructive inflammatory and necrotic changes. These may be confined to the uterus; they may induce serious alterations in surrounding parts; they may lead to an involvement of the peritoneum or to septicæmia or pyæmia and its accompanying lesions in the most distant parts of the body. In some cases a more or less extensive gangrenous inflammation of the mucous membrane and the underlying parts may lead to the casting-off of larger and smaller shreds of necrotic tissue and the formation of deep and spreading ulcers, which may be accompanied by severe parametritis and fatal peritonitis. In other cases the inflammation is membranous, and may affect the vagina, leading to necrosis, gangrene, ulceration, or peritonitis.

In connection with either of the above forms of inflammation, or without them, there may be thrombosis of the uterine sinuses, purulent inflammation of the veins, suppuration and abscess in the uterine wall, suppurative inflammation of the ovaries and tubes, and, owing to the

generalization of the infectious material, metastatic abscesses in the lungs, spleen, kidneys, etc. Or acute pleurisy, ulcerative endocarditis, erysipelas, purulent inflammation of the joints, hyperplastic swelling of the spleen and lymph-nodes, thrombosis or thrombo-phlebitis of the saphenous veins, etc., may follow. In some cases which rapidly pass to a fatal termination the local lesions may be but slightly marked, and general alterations characteristic of pyæmia, such as metastatic abscesses, etc., be

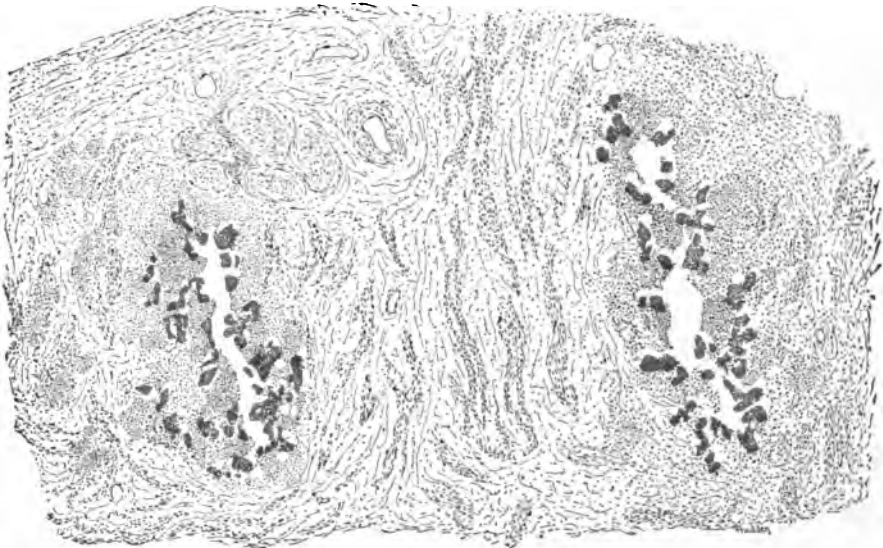


FIG. 544.—UTERINE PHLEBITIS FOLLOWING DELIVERY; WITH RETAINED PLACENTA. Death nine days after delivery. Micrococci in the walls of the inflamed veins stained violet.

entirely wanting. Death is in such cases apparently due to toxæmia or septicæmia.

Bacteria are usually present in the exudate, in the lymph-vessels, veins, and inflamed tissue of the uterus (see Fig. 544); often in enormous quantities in the peritoneal exudation and in the metastatic inflammatory foci. *Streptococcus pyogenes*, the gonococcus, *B. aërogenes capsulatus*, and the colon bacillus are the most frequent excitants of the lesion.¹

TUMORS.

Fibromata.—Dense nodular fibromata of the uterus are rare, the so-called fibromata being in most cases myomata or fibro-myomata. *Fibroma papillare*, on the other hand, is a common form of growth from the mucous membrane. It consists of a more or less vascular connective-tissue stroma covered with epithelium. The surface may be smooth or villous. It may contain very numerous gland follicles, and then approaches the type of adenoma, or even carcinoma. The stroma may be

¹ Consult Wadsworth, "On Puerperal Infection," *Am. Jour. of Obstetrics*, vol. xliii., 1901.

loose and succulent, and resemble mucous tissue, forming the so-called *mucous polypi*. In any of these forms the blood-vessels may be abundant and dilated, forming telangiectatic or cavernous polypi. The adenomatous polypi may become cystic from the dilatation of the gland follicles.

Polypi of the uterus may be multiple or single, small or large. Numerous smaller and larger papillary outgrowths from the mucous membrane may occur in chronic endometritis. Single polypi may grow from the mucosa of the body of the uterus or from the cervix, and hang by a long pedicle down into the vagina.

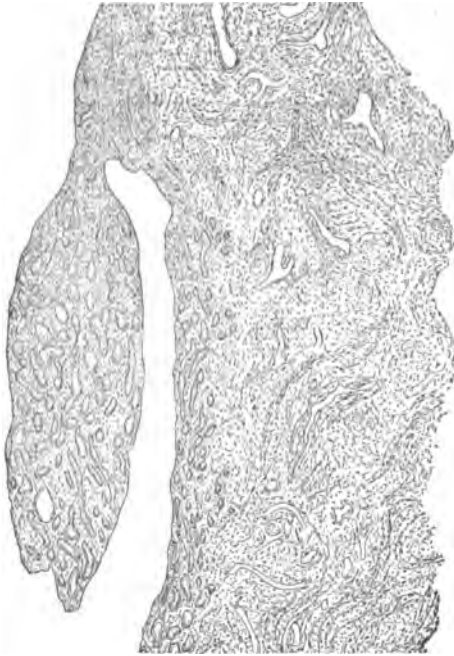

FIG. 545.—UTERINE POLYP—ADENOMATOUS OR GLANDULAR POLYP OF THE UTERUS—POLYPOID HYPERPLASIA OF THE MUCOUS MEMBRANE IN CHRONIC ENDOMETRITIS.

The large number of glandular structures in many of these chronic inflammatory, papillary, and polypoid outgrowths (Fig. 545) often justifies the name of adenomatous hyperplasia of the mucous membrane or of adenomatous papillomata or polyps.

Syphilitic papillary growths in the form of pointed condylo-mata may form finely papillary, wart-like excrescences of variable size, particularly on the cervix.

Myomata.—These tumors, whose characteristic structural elements are smooth muscle cells (Fig. 232), are the most common of uterine tumors and while frequently of little practical importance are sometimes of serious import. They are especially common in negroes.

They are most frequently composed of both muscular and fibrous tissue—fibromyomata—but the relative amount of the two kinds of tissue is subject to great variation. They are most apt to occur after puberty, and usually in advanced life. They may be single or multiple, small or of enormous size; are usually sharply circumscribed, whitish or pink, dense and hard, or sometimes soft, and present on section interlacing bands or irregular masses of glistening tissue. Their favorite situation is in connection with the body of the uterus, but they may occur in the cervix or in the folds of the broad ligaments. According to their position we may distinguish subserous, submucous, and intraparietal forms.

The *subserous myomata*, often multiple, grow from the outer muscular layers of the uterus in the form of little nodules. As they increase in size they may become separated from the uterine wall and remain attached only by a narrow pedicle or by a little connective tissue; or may

even be entirely free. They may work their way between the folds of the broad ligament until they are at some distance from their point of origin. The tumors may become very large, but remain firmly attached to the uterus; this organ may then be drawn upward, the cervix and vagina being elongated and narrowed. The traction may be so great that the body of the uterus is entirely separated from the cervix. The bladder may also be drawn upward. But subserous myomata of considerable size may interfere but slightly with the function of the uterus (see Fig. 546).

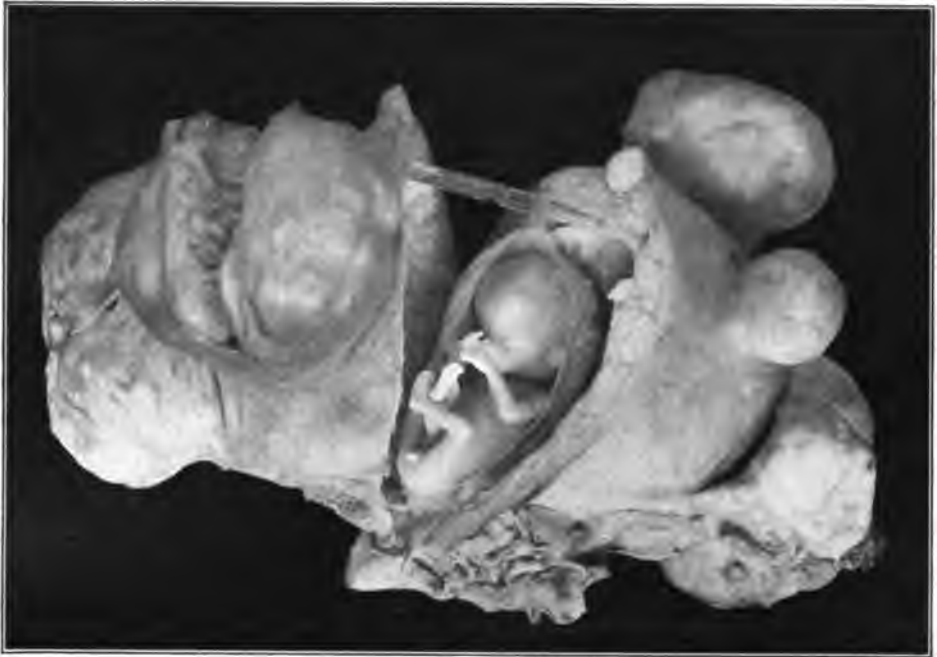

FIG. 546.—EXTRAMURAL MYOMATA.

Shows the uninvolved interior of the uterus containing a well-formed fetus.

The *submucous myomata* grow from the inner muscular layers of the uterine wall, most frequently in the fundus. They may project into the uterine cavity and remain sessile or become pediculated; the uterus dilates with the growth of the tumor, and its wall may also be thickened.

They are usually single, although there may be at the same time subserous and intraparietal tumors. They are frequently soft. If they are of large size and polypoid in form, they may project through the cervix and drag down the fundus of the uterus, producing inversion. The mucous membrane covering them may be atrophied or hyperæmic, with dilated blood-vessels, and may thus give rise to severe and repeated hæmorrhages. In some cases the pedicle of a tumor is destroyed and it is spontaneously expelled.

The *intramural myomata* grow in the substance of the uterine wall, but, if they attain a large size, project beneath the serous or the mucous coat (Fig. 547). They are found in every part of the uterus, but are most frequent in the posterior wall.

The shape of the uterus is altered in a great variety of ways by the presence of these tumors; its cavity is narrowed, dilated, or misshapen; it undergoes flexion or version. The tumors may sink downward and become attached to the posterior wall of the vagina.

Myomata may undergo a variety of secondary alterations. The muscle fibres may undergo *fatty degeneration* and the tumor diminish in size,

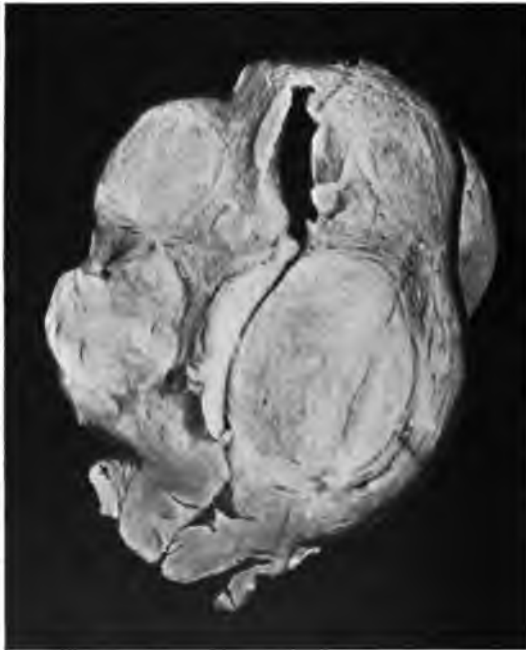

FIG. 547.—INTRAPARIETAL MYOMATA OF THE UTERUS.

or may even, it is said, be entirely destroyed. *Calcification* may occur, converting a part or the whole of the tumor into a stony mass. The intra-parietal and submucous myomata may give rise to profuse hæmorrhages; they may suppurate and become gangrenous.

Sometimes the tumors or circumscribed portions of them are very vascular, constituting the *telangiectatic* or *cavernous* variety. These tumors, which possess some of the characters of erectile tissue, may suddenly change in size from a variation in the amount of blood which they contain. Larger and smaller cysts may develop within these tumors—*fibro-cystic tumors*. These may be multiple and may communicate; they may be filled with a clear or bloody fluid. These cystic myomata may reach an immense size and fill the abdominal cavity. The cysts

may be lined with ciliated epithelium.¹ Combinations of myoma and sarcoma sometimes occur—*myo-sarcoma*. These tumors are sometimes called *malignant myomata*. Such tumors may form metastases.² Lipomyoma has been described.³

Myomata of the cervix are rare. They may grow as polypi beneath the mucous coat, or produce enlargement of the anterior or posterior lips, or may grow outward into the abdominal cavity.

Myomata of the uterus, either subserous, intraparietal, or submucous, containing glandular structures of the type of those in the uterine mucosa, are of occasional occurrence (Fig. 548). These glandular or adenomatous myomata are sometimes directly connected with the uterine mucous membrane, but are often so distant and so entirely separated from it as to justify the conjecture that they are derived from some embryonal abnormality associated with the development of the Wolffian body.⁴ Similar tumors have been described in the round ligament.⁵

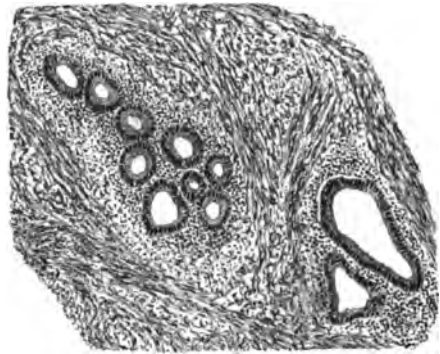


FIG. 548.—ADENOMATOUS OR GLANDULAR MYOMA OF THE UTERUS.

Sarcomata may occur as primary tumors in the mucous membrane of the uterus, either in the form of a diffuse infiltration or as a circumscribed nodular or polypoid mass. They frequently involve the muscular wall, are liable to hæmorrhage and gangrene, and, particularly in the diffuse form, are liable to recur after removal. They may consist largely of spindle or spheroidal cells, or both. It is said that sarcoma of the uterus is more liable to occur at an advanced age than at an early period, as is the rule with sarcomata of other organs. Giant-celled sarcomata have been described.

A few cases have been described in which, situated usually in the upper cervical region, there were lobed or "grapelike" tumors, fibrosarcomatous in character. Some of these contained striated muscle fibres. These tumors are malignant.⁶

Angioma.—Cavernous angiomata of the wall of the uterus have been described. **Endothelioma** is of rare occurrence in the cervix.⁷ **Myoma, lipoma, and chondroma** are recorded.

¹ Consult monograph by *Breus*, "Ueber wahre Epithel führende Cystenbildung d. Uterus-myomen," Leipsic, 1894.

² For references to the occurrence of sarcomatous changes in myomata see *Cullen*, *Jour. Am. Med. Assn.*, vol. xvi., p. 695, 1906.

³ See *Knox*, *Johns Hopkins Hosp. Bull.*, vol. xii., p. 318.

⁴ *Cullen*, *Johns Hopkins Hospital Reports*, vol. vi., p. 133, 1897, bibl.; also *Cullen*, monograph as supplement to *Orth's "Festschrift,"* 1903.

⁵ *Cullen*, *Johns Hopkins Hosp. Bull.*, vol. ix., p. 142, 1898, bibl.; also *Blumer*, *Am. Jour. Obstetrics*, vol. xxxvii., p. 37, 1898.

⁶ For a study of these tumors see *Läwen*, *Ziegler's Beitr.*, Bd. xxxviii., p. 177, 1905.

⁷ *Hurdon*, *Johns Hopkins Hosp. Bull.*, vol. ix., p. 186, 1898, bibl.

Adenoma.—Between a simple adenomatous hyperplasia of the mucous membrane of the uterus, on the one hand (see Figs. 540 and 541), and carcinoma on the other, there is no absolutely sharp morphological distinction. But there is a considerable group of growths, to which the name *adenoma* is properly applied, which lie on the border zone between the distinctly benign and the definitely malignant new epithelial-tissue growths.

Many epithelial cell growths of the uterus, while adenomatous in structure, are so distinctly malignant, and are so liable to develop that structural lawlessness characteristic of carcinoma, that it has seemed wise to many observers to avoid the name adenoma altogether and class all




FIG. 549.—ADENOMA OF THE UTERUS.

the epithelial tumors of the uterus among the carcinomata. Others, recognizing the benign character of many of the epithelial tumors, make a sharp distinction between benign and malignant adenomata.

It seems to the writer wise to preserve here, as elsewhere in the body, the morphological distinction between adenoma and carcinoma. But in doing this it should always be borne in mind that the adenomata of the uterus, as those of the gastro-intestinal canal, may not only be extremely malignant as adenomata, but that the more benign forms are extremely prone to develop, both in structure and malignancy, into carcinomata. In fact, in many cases we can express the peculiarities of structure in these tumors only by calling them **adeno-carcinoma**.

The adenomata of the uterus may begin in a simple hyperplasia of the mucous membrane, in which glandular development is preponderant (see above). When the tumor character becomes established this new glandular growth is commonly in the form of irregular, often dilated follicular structures with a well-marked lumen lined with cylindrical or cuboidal cells. It may develop in irregular papillary masses (Fig. 549), the more or less abundant fibrous stroma being covered with irregular layers of

epithelium (Figs. 550 and 551). The new growth may project from the inner surface of the uterus in the form of ragged lobular masses (Fig. 552), or it may infiltrate the submucous tissues (Fig. 553). Or growth in both directions may occur at once.

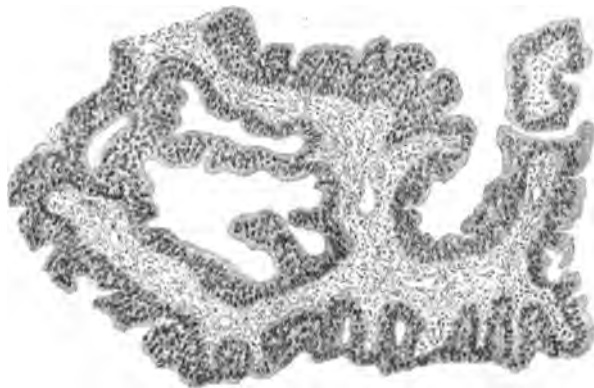


FIG. 550.—ADENOMA OF THE UTERUS.
Showing a small portion of a glandular and papillary growth.

The topographical features and clinical stories of many adenomata of the uterus are identical with those of the infiltrating and ulcerating carcinomata.

Carcinoma.¹—The carcinomata of the uterus commence most frequently in the cervix and portio vaginalis, and the most common form is the epithelioma. The growth of epitheliomata of the cervix uteri proceeds under three tolerably distinct forms, which, however, frequently merge into one another.

1. The flat, ulcerating epithelioma. This form of cancer commences as a somewhat elevated, flat induration of the superficial layers of the cervix, sometimes circumscribed, sometimes diffuse. This induration is due to the growth of plugs and irregular masses of epithelial cells into the underlying tissue (Fig. 554). Ulceration usually commences early and may proceed slowly or rapidly. The edges of the ulcer are irregular, indurated, and somewhat elevated. The ulceration of the new-formed cancerous tissue at the edges is usually progressive, so that the vaginal portion of the cervix, the cervical canal, the vagina, and even the bladder and rectum may be involved. More or less extensive hæmorrhages and necrosis of the base of the ulcer are liable to occur. The entire cervix may be destroyed.

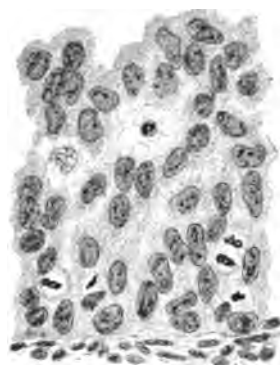


FIG. 551.—ADENOMA OF THE UTERUS.
Showing a small portion of the epithelium in Fig. 550 more highly magnified. Mitotic figures are seen in the deeper layers.

¹ Consult for details *Cullen*, "Carcinoma of the Uterus," 1900.

2. In another class of cases the carcinomatous growth develops under the form of papillary or fungous excrescences, which may form larger or smaller masses composed of epitheliomatous tissue. Hand-in-hand with this projecting growth there may occur an epithelial infiltration of the underlying tissue of the cervix. These growths are often quite vascular and may give rise to severe hæmorrhages. They may ulcerate and thus produce great destruction of tissue.

3. In still another class of cases there is a more or less deep infiltration of the submucous tissue, either diffuse or in circumscribed nodules,

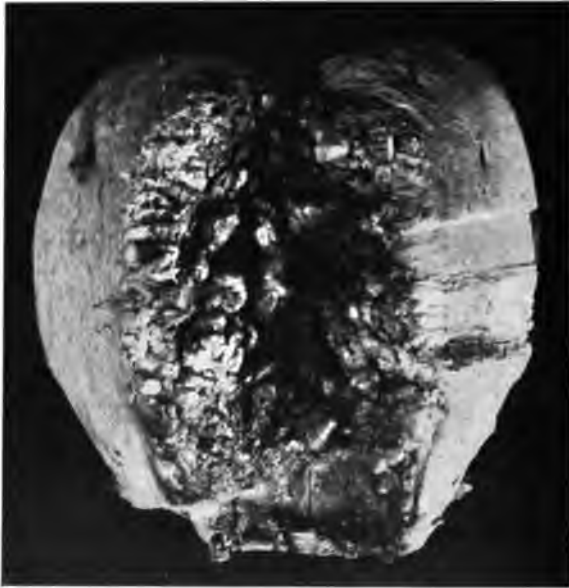

FIG. 552.—ADENOMA OF THE UTERUS.

Showing the gross appearance of the interior of the uterus with an adenomatous involvement of the entire mucosa.

with epithelial cell masses. We find at first, in the vaginal portion of the cervix, in the submucous connective tissue, either nodules or a general infiltration of a whitish new growth. The cervix then appears large and hard. Very soon the mucous membrane over the new growth degenerates and falls off; the superficial layers of the new growth undergo the same changes. After this the formation of the new growth and its ulceration go on simultaneously, producing first an infiltration and then destruction of the cervix and often of a part of the body of the uterus. The growth frequently extends to the vagina, the bladder, and the rectum with the same destructive character, so that we often find the cervix and upper part of the vagina destroyed, and in their place a large cavity with ragged, gangrenous, cancerous walls (Fig. 555). Less frequently the pelvic bones are invaded in the same way. Not infrequently the ureters

are surrounded and compressed by the new growth, so that they become dilated. The dilatation may extend to the pelves and calyces of the kidneys. The new growth may begin in the cervix and extend uniformly over the internal surface of the cervix and of the body of the uterus. The entire uterus is converted into a large sac, of which the walls are infiltrated with the new growth, while the internal surface is ulcerating and gangrenous. In some cases there is a considerable formation of new, dense connective tissue, so that the growth has a scirrhus form.

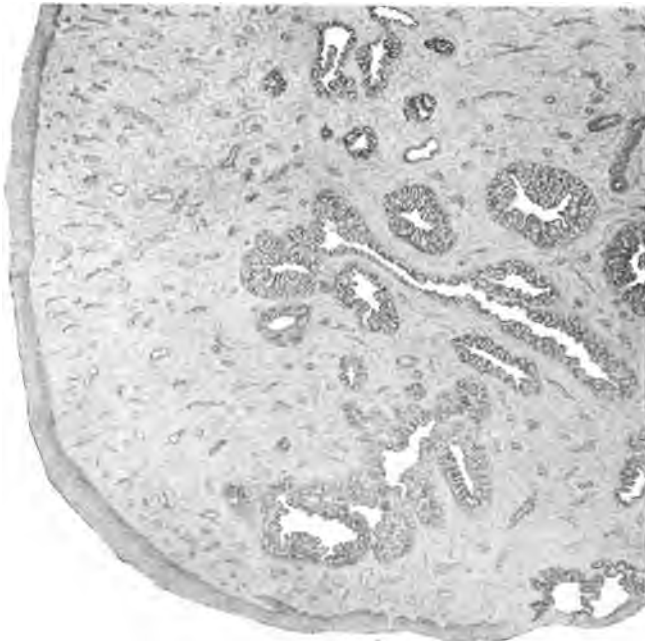


FIG. 553.—ADENOMA OF THE UTERUS.

Showing the extension of the new growth into the deeper portions of the cervix. The section shows one side of the cervix. The epithelium over the portio vaginalis is intact; in the right upper region in the figure is seen a ragged erosion of the epithelium lining the cervical canal, and the exposure of a portion of the tumor growth upon the free surface.

In rare cases the growth begins in the upper part of the cervix or in the body of the uterus, while the lower part of the cervix is not involved. In all of these cases the epithelial cells of the new growth follow more or less closely the type of the epithelial cells of the part from which they spring. But it has been observed that carcinoma developing from the mucous membrane of the body of an inverted uterus, or rarely without inversion, may be of the squamous-celled type.

In still another class of cases, in which the new growth may be in the form of nodules, or diffuse infiltrations, or polypoid masses, or may present more or less extensive alterations, the cells are irregular, polyhedral in shape, the tumor belonging to the class of glandular or medullary

carcinomata (Fig. 556). These also usually commence in the cervix, and, according to the views of many writers, probably in the mucous glands.

In rare cases the entire wall of the uterus is infiltrated with the new growth and the organ is much enlarged. *Gelatinous carcinoma* sometimes occurs, but is rare.

While we may for convenience recognize the above types of carcinoma of the uterus, it should be borne in mind, as above stated, that they are

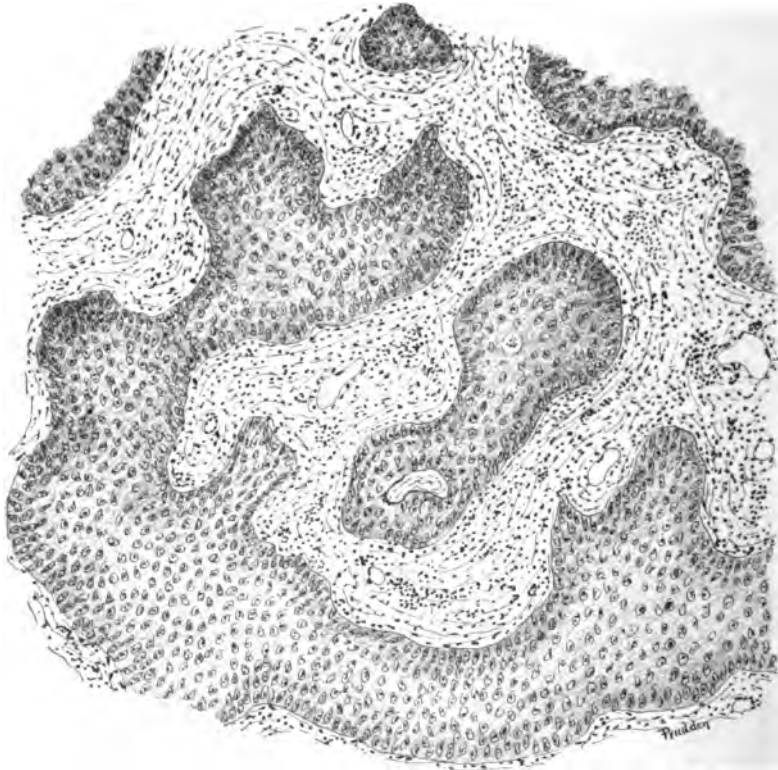


FIG. 554.—CARCINOMA (EPITHELIOMA) OF THE UTERUS.
Showing ramifying epithelial cell masses.

often not distinct, and may merge into one another or exist simultaneously. Exudative inflammation is of frequent occurrence in these as in other tumors of the uterus.

As a result of the ulceration of these various forms of carcinoma, recto-vaginal fistulæ may be formed; the lumbar lymph-nodes may be involved and metastases in distant organs are occasionally, though not often, formed. Frequent and profuse hæmorrhages, gangrenous destruction of tissue, the absorption of deleterious materials, etc., are apt to lead to the development of a more or less profound anæmia and cachexia.

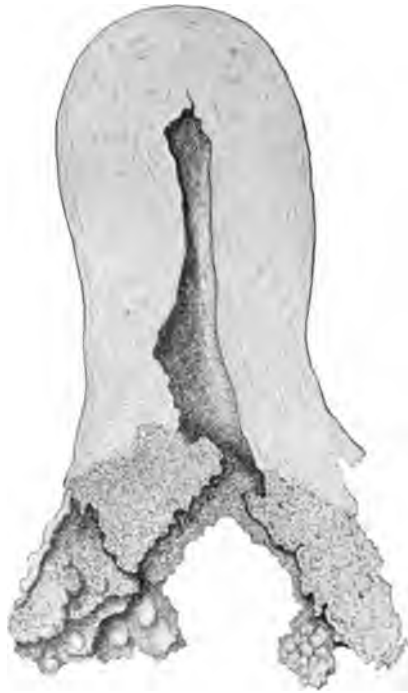

FIG. 555.—CARCINOMA OF THE CERVIX UTERI.
The infiltrating and ulcerating type.

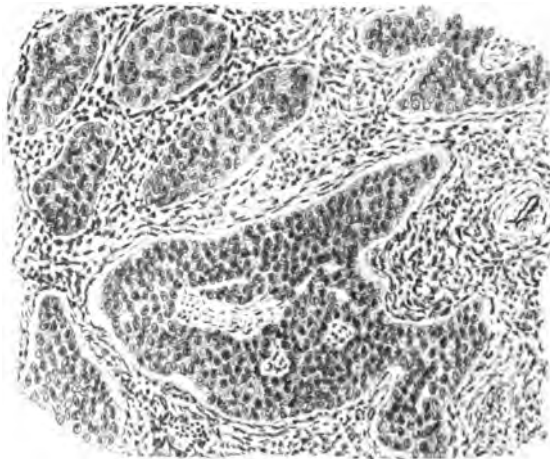


FIG. 556.—CARCINOMA OF THE UTERUS. Medullary type.

Chorionepithelioma of Pregnancy.¹ (Deciduoma Malignum.)

Malignant tumors derived from chorionic villi or from some abnormal form of these, as hydatid moles (see p. 824), and composed of cells more or less closely resembling the various types of chorionic epithelium, are known as *chorionepitheliomata of pregnancy*.²

Characters of the Chorionic Villi.—In order to understand the structure and biological characters of these tumors, one must bear in mind the

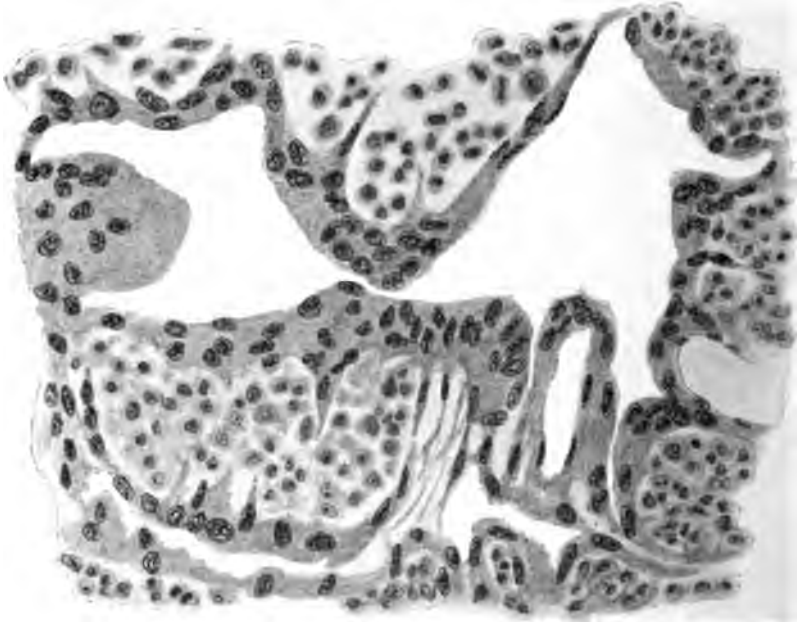

FIG. 557.—CHORIONEPITHELIOMA.

A mediastinal tumor showing the syncytial cells and the Langhans' cells in characteristic relationship to each other.

nature of the normal chorionic villi. These consist of a vascular connective-tissue framework which is covered with two layers of epithelial cells. The inner layer is formed in general of a single layer of sharply defined, polyhedral, transparent cells with oval nuclei. These cells contain glycogen. They are called *Langhans' cells*. The outer layer is composed of a mass of cells whose outlines are in general indistinct, with many nuclei of various shapes, the whole resembling masses of giant cells. This outer layer of cells is called the *syncytium*, and from it small protoplasmic, bud-like processes—syncytial buds—project. In the later

¹ For an admirable summary of these tumors, with a study of new cases and bibl., see *Frank, Jour. Amer. Med. Assn.*, vol. xlv., p. 248, 1906.

² This specific designation is necessary because tumors of similar morphological characters, but differently derived occur in non-pregnant individuals, in the testicle, and elsewhere as parts of teratomata.

periods of pregnancy the cell layers are as a rule less distinct than at an earlier time. The cells covering the chorionic villi penetrate the maternal decidua, mingling with its cells, and may pass into the structures of the uterine wall. Certain of the covering cells of the chorionic villi have remarkable powers of penetrating the maternal tissues, their invasion being apparently secured through lytic action. These are called chorionic wandering cells. They may erode blood-vessels, causing hæmorrhage and thrombosis, and may enter the maternal circulation and be carried as emboli into the viscera—liver, lungs, etc.¹

It is cells of these three types—Langhans' cells, the syncytium, and the chorionic wandering cells—invading the tissues of the uterus, from

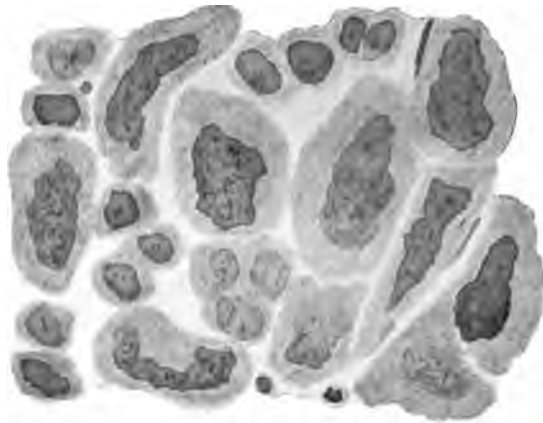

FIG. 558.—LARGE CELLS FROM CHORIONEPITHELIOMA OF THE UTERUS.
Vaginal curettings.

which they directly derive their nourishment, without the development of a special stroma, as is the case of most tumors, that give character and malignancy to chorionepitheliomata when they have become freed from the restraints of normal growth.

In typical cases the chorionepitheliomata of pregnancy (Fig. 557) are formed: first, of large polynuclear cells or cell masses—syncytial masses—appearing in irregular multinuclear strands or branching protoplasmic structures; and, second, of more transparent, sharply circumscribed, polyhedral cells with single oval nuclei, with glycogen-containing protoplasm. They often contain free blood and fibrin, and the stroma is largely made up of the tissue which they invade.

In many instances these tumors are less typical in structure, departing more from the character of the chorionepithelium. The delicately outlined transparent cells may be absent; the syncytial masses may fail; the whole growth being made up of irregularly shaped cells of

¹ See for a study of embolism of chorionic cells *Schmorl*, Verh. deutsch. path. Ges., 1904, Bd. viii., p. 39; also *ibid.*, Centrbl. f. Gynäkol., Bd. xxix., 1905, p. 129. See also *Veit*, Zeit. f. Geburtshilfe u. Gynäkol., Bd. xlix., p. 210.

various sizes with nuclei varying in size, but often very large (Fig. 558). The cells are sometimes multinuclear.

Chorionepitheliomata were at first regarded as sarcomata, but are now known to be derived from cells of the chorionic villi. In many cases they bear an intimate relationship to hydatid moles.

The development of these tumors often follows the discharge of an hydatid mole. In the malignant types there may be invasion of the wall of the uterus and the pelvis with repeated hæmorrhages and cachexia. Vaginal metastases are common and develop early, and there may be general metastasis with secondary tumors, most often in the lungs and liver. They may develop as a sequel to ectopic gestation, but this is rare: they may follow retained placenta.¹

CHORIONEPITHELIOMA WITH TERATOMA.

Several cases are recorded in which females whose age or condition precluded the possibility of pregnancy have developed tumors having the characters of the chorionepitheliomata. These it is believed are all instances in which teratomata furnished the embryonal ectodermal tissues in which the tumors originated. Similarly the so-called chorionepitheliomata of the testicle (Fig. 601), of which several cases have been described, are derived from teratomata.

PARASITES AND CYSTS.

Echinococcus has been found in the body and neck of the uterus, and may rupture into the peritoneal cavity or into the vagina.

Cysts.—Aside from the cysts which develop in tumors of the uterus, the mucous follicles in the cervix are frequently so dilated as to form cysts filled with a gelatinous material and more or less epithelium. These cysts may be large or small, and are frequently called *ovula Nabothi* (Fig. 543). Sometimes there is an inflammatory growth of new connective tissue about these cysts. In other cases the cysts may project from the mucous membrane in the form of polypi. Similar changes are infrequently found in the body of the uterus from the dilatation of occluded uterine glands. Dermoid cysts are rarely found in the walls of the uterus.

Lesions of the Placenta.²

Aside from the variations from the normal in size, shape, and position, for a description of which we refer to the works on obstetrics, we

¹ For a study of clinical and microscopical variations of these tumors, with suggestions for diagnosis see *Frank*, N. Y. Med. Jour., vol. lxxxiii., p. 793, 1906. For experimental studies of *Leo Loeb* on the sensitizing of the uterine mucous membranes in animals by the corpus luteum secretion and the subsequent production through traumatic stimuli of new tissue growths in the submucosa—"deciduoma," see *Loeb*, Jour. Am. Med. Assn., l., 1897, 1908; *Ibid*, li., 1471, 1909, and *Arch. f. Entwicklungsmech d. Organen*, xxvii., No. 1, 1909; also for bibl. of secretion of corpus luteum with exp. study, see *Frank*, *Arch. Int. Med.*, vi., 314, 1910.

² For a study of the placenta, normal and pathological, see *Eden*, *Journal of Path. and Bact.*, vol. iii., p. 449, 1896, and vol. iv., p. 265, 1897, bibl.

may briefly mention here some of the more important structural changes which the placenta may undergo.

DEGENERATION.

Fatty and amyloid degeneration and calcification of the placental tissue are of not infrequent occurrence.

HÆMORRHAGE.

This may occur either on the maternal surface in the decidua, or between the foetal surface and the membranes, or in the substance of the placenta. The latter form of hæmorrhage constitutes the true *placental apoplexy*. This may occur as the result of rupture of a placental sinus. The placental tissue is crowded apart, and a blood-clot, often infiltrating the parenchyma, is formed. This may lead to abortion, or the blood may undergo disintegration and absorption and its place be occupied by a cicatrix. The placental tissue in its vicinity may undergo fatty degeneration. Under other conditions, without evidence of rupture of the vessels, the placental tissue may become infiltrated with blood in the form of an infarction. In this, degenerative changes similar to the above may occur, leading to fibrous induration of the placenta.

The so-called "infarctions" of the placenta vary in size, appearance, structure, and origin. They are most frequently due, according to Williams, to an endarteritis of the vessels of the chorionic villi. They appear to be of little significance when of moderate size.¹

INFLAMMATION. (Placentitis.)

Suppurative Inflammation of the placenta, with the formation of abscesses, is of rare occurrence as the result of injury.

Chronic Indurative Inflammation of the placenta may result in the formation of circumscribed masses of cellular and loose, or dense and cicatricial, connective tissue, or in a diffuse formation of connective tissue which may interfere with the nutrition of the foetus and cause abortion. The new-formed connective tissue may undergo fatty degeneration or calcification.

In another class of cases the new connective tissue is formed mainly in the walls of the vessels, particularly the arteries. This may occur in circumscribed portions of the vessels, leading to nodular growths around the arteries, or it may occur extensively along the various ramifications of the vessels, converting them into thick fibrous cords. The change is primarily in the adventitia, but all the coats of the vessel may become involved, leading to more or less complete obliteration of the lumen.

Various proliferative and indurative changes in the placenta may occur as the result of **sypilitic inflammation**.

Tuberculous Inflammation of the placenta may occur in connection with other tuberculous processes in the mother.

¹ For a study of placental infarcts see Williams, "Welch Anniversary Contr. to the Science of Medicine," 1900, p. 431, bibl.

TUMORS.

Moles.—Under various conditions interfering with its nutrition the foetus may die and be cast off. The placenta and membranes may then dry, forming a fibrous or fleshy or bloody mass—*fibrous mole*; *fleshy mole*; *bloody mole*. These are not genuine tumors.




FIG. 559.—FRAGMENT OF DECIDUA IN CURETTINGS FROM THE UTERUS.

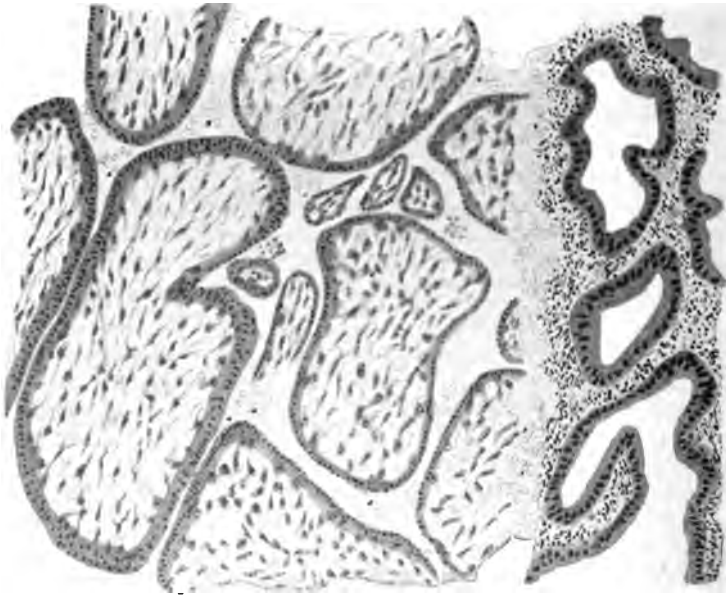


FIG. 560.—CURETTINGS FROM THE UTERINE CAVITY SHOWING PORTION OF RETAINED PLACENTA, AND OF THE MUCOUS MEMBRANE SHOWING GLANDULAR HYPERPLASIA.

Placental Polyps.—Not infrequently, especially after abortions, portions of the placenta (Fig. 559) remain attached in the uterus and may undergo various phases of hyperplasia forming polypoid outgrowths

or diffuse thickening of the mucous membrane, resembling some of the forms of moles in character. This condition is often associated with



FIG. 561.—HYDATID MOLE.
Showing a small portion of the mass.

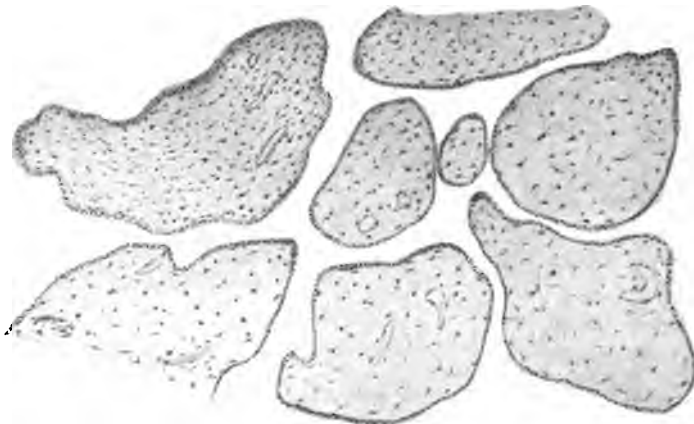


FIG. 562.—HYDATID MOLE.
Section of a small portion showing mucous and slightly fibrous tissue covered with a layer of epithelial cells.

glandular endometritis, and curettings of the uterus may then show both placental structures and glandular hyperplasia of the mucous membrane (see Fig. 560).

Sometimes, however, the placenta, or some part of it, is transformed into an irregular mass of rounded pink or colorless transparent or translucent bodies, from two to ten millimetres in diameter—*hydatid moles* (Figs. 561 and 562). These bodies, attached to the elongated chorionic villi, consist of loose, vascular connective tissue resembling mucous tissue and are covered with chorionic epithelium. The cause of this transformation of the placenta is unknown. It may be cast off with the fœtus or there may be no trace of the embryo. But the hydatid mole may remain after the fœtus is discharged, and through the growth of the chorionic epithelium may give rise to chorionepithelioma¹ (see p. 821), or to chorionepithelial emboli in various parts of the body,² with metastatic growths having the characters of hydatid moles.

Cysts of the placenta are of occasional occurrence; their origin is in most cases obscure.³

The Ovaries.

Malformations.

One or both ovaries may be absent, the other organs of generation being also absent or undeveloped; or they may be only partially developed. Absence or arrest of development of one ovary occasionally occurs in otherwise well-formed individuals, and is sometimes accompanied by a low position of the kidney on the same side. The ovaries may pass into the inguinal canal or into the labia majora, and remain fixed there through life. Less frequently they are found in the crural canal or the foramen ovale.

Changes in Size and Position.

The ovaries may become larger than normal by chronic inflammation, by the formation of cysts and tumors. They may become atrophied in old age, the Graafian follicles disappearing and the organ shrivelling into a small, irregular, fibrous body. Atrophy may be produced by ascites, by chronic inflammation, or from unknown causes. As the result of the maturing and rupture of the Graafian follicles, with and without pregnancy, the surface of the ovary, which before puberty is smooth, may become roughened by irregular cicatricial depressions.

In adult life the ovaries may pass as herniæ into the inguinal or crural canal, the foramen ovale, or the umbilicus. Their position in the abdomen may be changed by the pressure of tumors, the traction of false membranes, etc. This may occur in enlarged ovaries or in those of normal size, and by the compression of the veins may lead to congestion and chronic inflammation of the organs.

HYPERÆMIA AND HÆMORRHAGE.

Aside from the normal hyperæmia of the ovaries during various sexual functions, the vessels may be congested in inflammation, in displacements with interference with the venous circulation, in certain diseases of the heart, etc., and this may then be followed by chronic inflammation.

¹ See *Pick*, Berl. klin. Woch., 1897, pp. 1069 and 1097.

² See *Schmorl*, Verh. d. deut. Naturf. u. Aerzte, Bd. ii., 1897, part 2, pp. 21 and 111; also *ibid.*, Verh. d. deut. Path. Ges., Bd. viii., p. 39, 1904.

³ See *Ahlfeldt*, Arch. für Gynäkologie, Bd. xi., 1877, p. 397; *Fenomenow*, *ibid.*, Bd. xv., p. 343, 1880; *Hofmeier*, "Die menschliche Placenta," 1890; *Biland*, Ziegler's Beitr., Bd. xl., p. 195, 1907, bibl.

The menstrual periods are accompanied by the effusion of blood into a Graafian follicle. Normally the amount of blood is small, becomes solid, is decolorized, and then gradually absorbed. Sometimes the effusion of blood is much greater; the follicle filled with blood is as large as a pigeon's egg. The blood may remain in the follicle, and be absorbed and replaced by a serous fluid, or through rupture it may escape into the peritoneal cavity. Death may ensue from the hæmorrhage, or the blood may collect in Douglas' cul-de-sac and become encapsulated. Hæmorrhages also occur in follicles which have become cystic. Interstitial hæmorrhage in the ovary sometimes occurs without known cause.

INFLAMMATION. (Oophoritis.)

Acute Exudative Inflammation of the ovaries occurs most frequently in the puerperal condition, either as part of a general peritonitis or as a primary affection.

With puerperal peritonitis both ovaries are usually inflamed; they are swollen, congested, soft, infiltrated with serum or pus, or gangrenous. The lesion may involve principally the capsule, the stroma, or the follicles. Inflammation of the capsule results in adhesions and collections

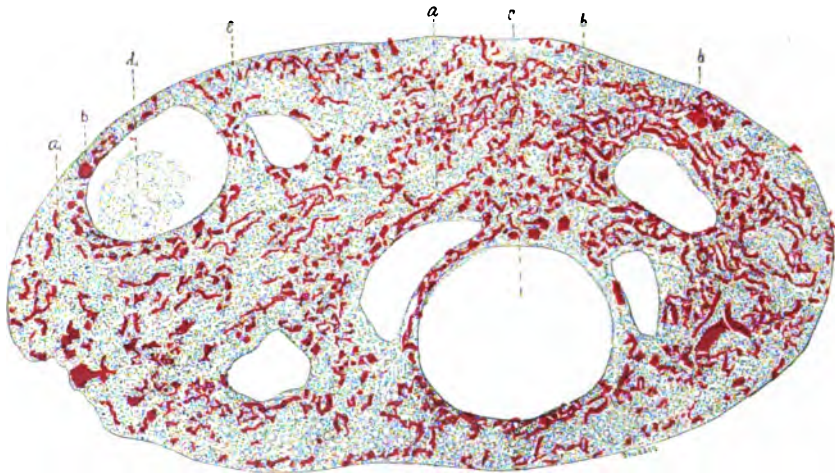


FIG. 563.—CHRONIC OOPHORITIS WITH DILATED BLOOD-VESSELS AND CYSTS.

1, Dense connective-tissue stroma; b, dilated veins; c, cysts; d, cyst with granular contents; e, cortical zone of immature Graafian follicles.

of pus, shut in by false membranes; of the stroma, in abscesses and fibrous induration; of the follicles, in their dilatation with purulent serum.

If the inflammation of the ovary be the primary lesion, it is usually confined to one organ. The stroma of the ovary is infiltrated with serum and pus, and may contain abscesses of large size. In other cases the ovary itself is but little changed, but is surrounded by a mass of fibrinous

and purulent exudation. Such independent forms of ovarian inflammation may terminate in recovery; or the abscesses may perforate into the rectum and vagina; or the ovary is left indurated and bound down by adhesions; or the patient may die.

Acute exudative inflammation of the ovaries unconnected with the puerperal condition is not common, but it may occur in connection with acute or chronic peritonitis or perimetritis, with various infectious diseases, pyæmia, etc. It is usually confined to one ovary.

Chronic Interstitial Oophoritis is not infrequently preceded by an acute inflammation, or it may gradually develop as an independent condition, often determined by some mechanical interference with the blood current. The organ may be increased in size, owing to the formation of loose, cellular, or of dense, firm, new connective tissue. Under these

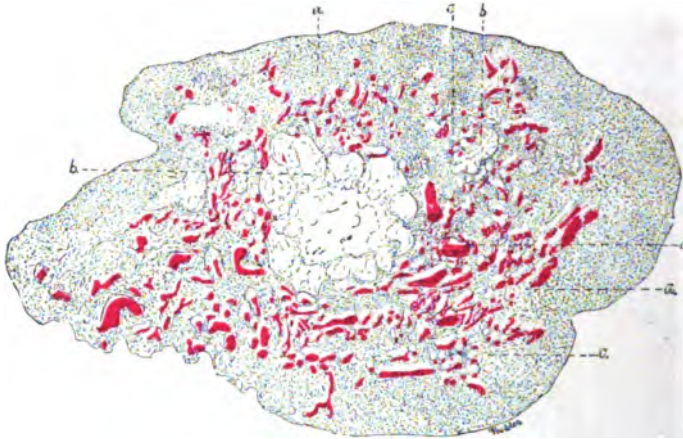


FIG. 564.—CHRONIC OOPHORITIS WITH ATROPHY.

From a case of valvular disease of the heart with chronic metritis and endometritis. *a*, Thickened and dense interstitial tissue; *b*, old corpora lutea; *c*, arteries with greatly thickened walls; *d*, dilated veins.

conditions the blood-vessels, especially the veins, may be widely dilated, and cysts in varying number and size may be present (Fig. 563). Sometimes the new-formed dense connective tissue may be largely limited to the surface of the organ, so that the albuginea may become dense and thick. Under these conditions the surface of the ovary may be smooth or rough.

On the other hand, the organ may be smaller than normal as the result of the formation of dense new interstitial connective tissue, and its surface greatly roughened and distorted (Fig. 564). Sometimes the formation of new dense tissue may be largely confined to the walls of the arteries, which become prominent and tortuous. Obliterating endarteritis is not infrequent. The atrophied ovary may be largely made up of thick-walled arteries and of fibrous masses which are the result of incomplete resolution of the corpora lutea.

Occasionally a more or less extensive hyperplasia of cells in the corpus

luteum leads to the development of larger or smaller new-formed, convoluted, nodular masses in the ovary, which are sometimes regarded as tumors.¹ Sarcomata of the ovary appear to originate in such a hyperplasia (see Fig. 567).

Tuberculous Inflammation of the ovaries is rare, and may accompany tuberculous inflammation of other organs, particularly the peritoneum and Fallopian tubes. It usually results in the production of dense caseous nodules of considerable size.

Syphilitic Inflammation in the form of gummata is uncommon.

TUMORS.

Fibroma is not common nor usually of great importance. Such tumors may be small or large. They are usually dense in texture, and seem often to originate in the tissue formed in the closure of the ruptured Graafian follicle. They may contain cysts or be accompanied by cysts of the surrounding stroma. *Papillary fibromata* of the surface of the ovary are not infrequent (Fig. 565). They may contain cysts (Fig. 566), and the growth may be transplanted from this situation to the general peritoneal surfaces. **Angioma** is described.



FIG. 565.—PAPILLOMA OF THE OVARY.

Chondroma of the ovaries is described, but is rare; cartilage not infrequently occurs, however, in dermoid cysts.

Leiomyoma containing more or less fibrous tissue is of occasional occurrence.

Sarcoma of the ovaries is not common. It is usually primary, and may apparently develop from the new-formed cells of the corpus luteum (Fig. 567), but may be metastatic. It is usually of the spindle-celled variety, but may contain areas of spheroidal-celled tissue or more or less

¹ For a *résumé* of recent studies on the nature of the corpus luteum and its internal secretion see Frank, Arch. Int. Med., vi., 314, 1910, with bibl.

fibrous tissue. The tumors may be hard or soft, and are apt to involve both ovaries. **Endotheliomata** may be found in the ovaries (Fig. 568).

Carcinoma, usually of the medullary variety, may occur as a primary tumor of the ovary. It may be due to a continuous extension from neighboring organs, or more rarely it is of metastatic origin. Although the medullary carcinomata are the most common, scirrhous, melanotic, and gelatinous forms sometimes occur. Some types of carcinoma stand in very close relation with certain of the cystic adenomata (see below).

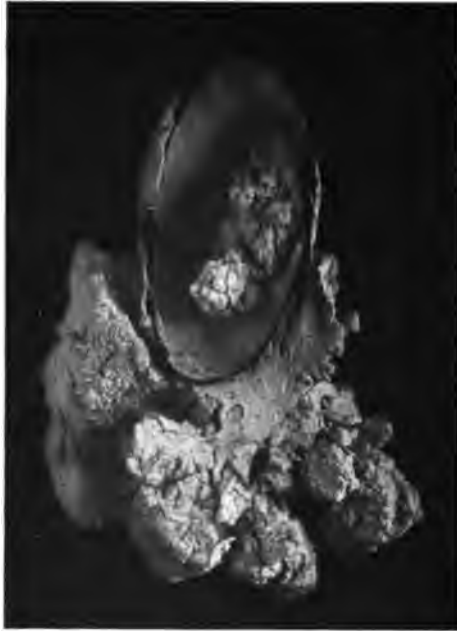


FIG. 566.—PAPILLOMA OF THE OVARY.
Shows cyst with papillary growth within.

Adenoma (Cystic Adenoma; Compound Ovarian Cyst).—These growths, which may occur in one or both ovaries, form one of the most common and important classes of ovarian tumors. They probably originate in the gland epithelium of the ovary either before or after the formation of the Graafian follicles. Some of their most noteworthy and important features depend upon their tendency to the formation of cysts. It should be remembered, however, that the primary lesion is a true new formation of glandular tissue, and not, as in the case of most cysts, a transformation, by retention or otherwise, of pre-existing structures.

The growth primarily consists of a fibrous stroma in which are tubular follicles lined with cylindrical epithelium—*glandular type*. Or, in some cases, it consists of papillary outgrowths from a fibrous stroma, which are covered with cylindrical epithelium—*papillary type*.

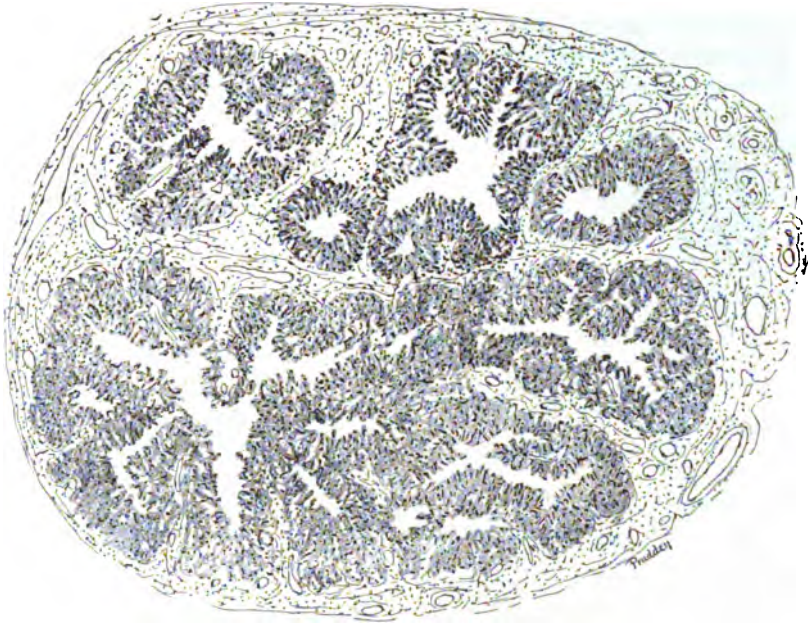


FIG. 567.—COMMENCEMENT OF SARCOMATOUS GROWTH IN THE OVARY.
From hyperplastic cells of corpus luteum.

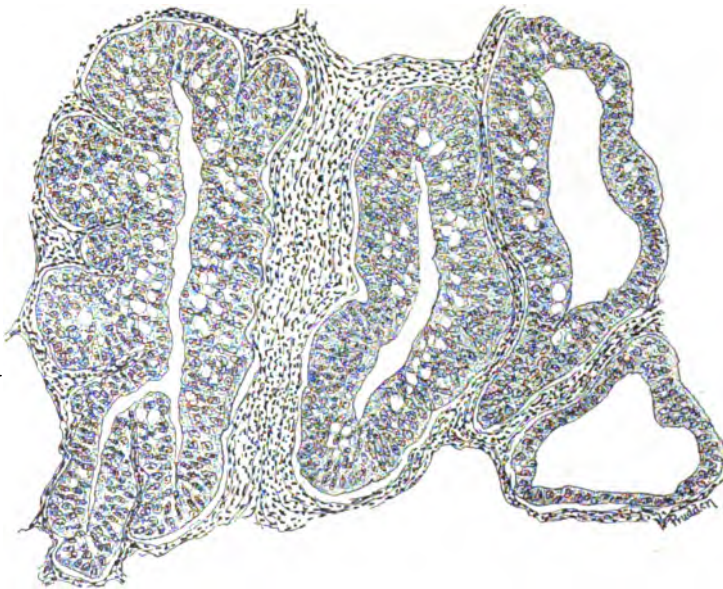


FIG. 568.—ENDOTHELIOMA OF THE OVARY.

Glandular Cystadenoma.—There is, as above stated, a marked tendency, in this form of adenoma, to dilatation of the follicles by a semi-fluid material, and the formation of cysts. There may be a number of follicles equally dilated, so as to form a number of cysts of moderate size (Fig. 569); or a few follicles are greatly dilated to form a large *multilocular cyst* with but few compartments (Fig. 570). The walls of the cysts may fuse together and be absorbed, so as to form one large cyst divided by incomplete septa—*unilocular cysts*. The stroma in which the follicles and cysts are embedded may be largely developed or very scanty.

The walls of the larger cysts are composed of fibrous tissue which is dense in the outer layers, more cellular in the inner, upon which the epithelium is placed. They may be thin and membranous, or there is

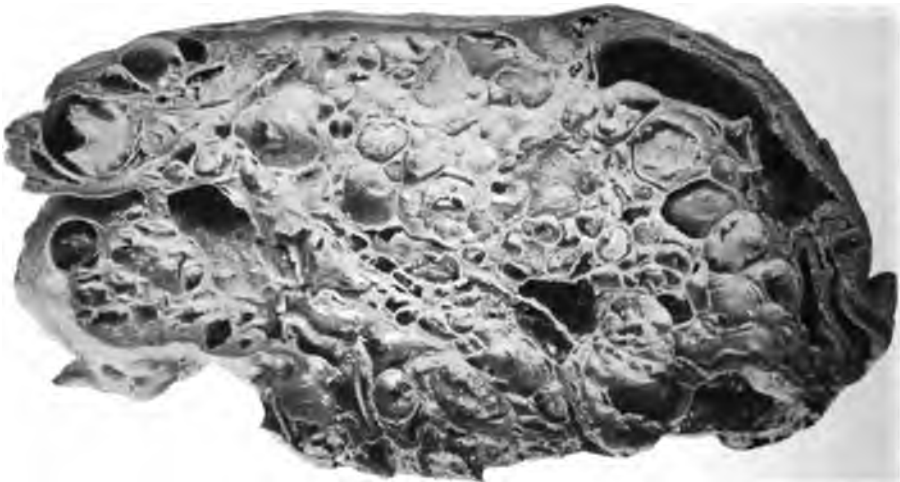

FIG. 569.—CYSTADENOMA OF THE OVARY—(MULTILOCLULAR OVARIAN CYST—ADENO-CYSTOMA).
This photographic reproduction is about four-fifths natural size.

upon their internal surfaces an intracystic growth composed of a fibrous stroma and tubular follicles. These secondary follicles may also be filled with fluid and form larger and smaller cysts. The intracystic growths may be so large as to fill up the original cysts. Sometimes the intracystic growth presents very little dilatation of its follicles, so that the entire tumor has more the character of a solid growth than of a cyst.

The cylindrical epithelium lining the cysts usually forms a single layer (Fig. 571), but several layers often irregular in thickness may form, and owing to the accumulation of fluid the cells may become flattened and atrophied, or they may be fatty or desquamated. The contents of the cysts differ considerably in different cases, and even in different cysts in the same case. They may be tough and ropy, or gelatinous or serous; transparent and colorless, or yellow or reddish, or reddish brown; or they may be turbid and colorless, or variously colored—red, brown, or chocolate.

Chemically the cyst contents, when thick and ropy, include mucin or paralbumin, and perhaps other less well-known compounds belonging to the same class. It is probable that the contents of these cysts are, so far as the mucin and paralbumin are concerned, produced by a metamor-

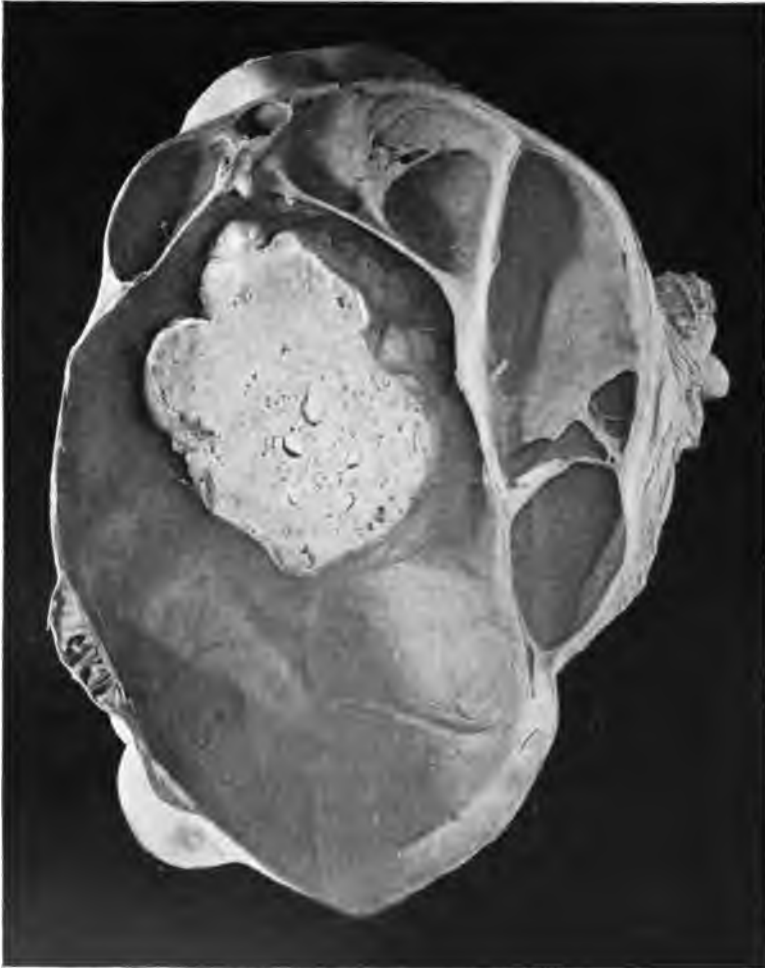

FIG. 570.—CYSTADENOMA OF THE OVARY.
Showing large cysts, with a glandular mass within one of the cysts.

phosis of the protoplasm of the lining cells, similar to that by which the mucin is produced in the mucous glands and in mucous membranes. The cylindrical cells often present the form of the so-called "beaker cells," and in some cases the mucous contents of the cysts are seen to be continuous with the similar contents of the beaker cells. It is probable

that much of the fluid contents of the cysts comes from simple transudation.

Microscopically the contents of these cysts present also considerable

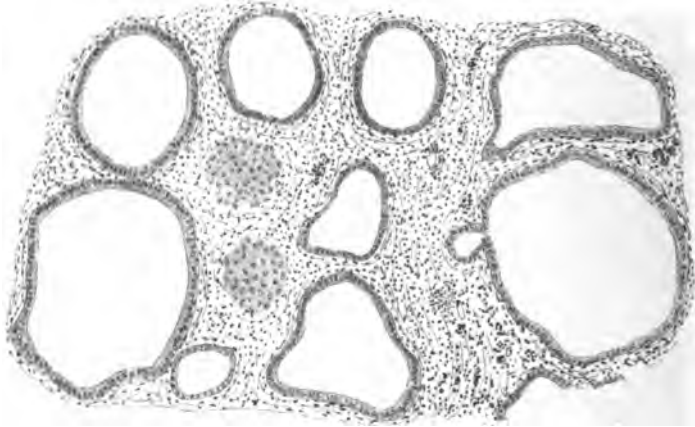


FIG. 571.—CYSTADENOMA OF THE OVARY—GLANDULAR TYPE.

variation. We may find almost no structural elements, or there may be red blood cells in variable quantity, and leucocytes in various stages of granular or fatty degeneration or of disintegration. There may be

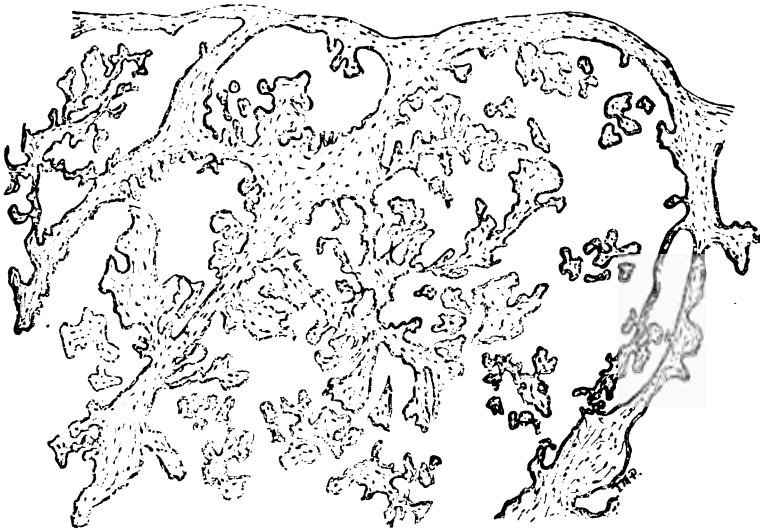


FIG. 572.—CYSTADENOMA OF THE OVARY—PAPILLARY TYPE.

cylindrical, or flattened, or polyhedral cells, either well preserved, swollen, or in a state of fatty degeneration, or fragments of these cells. It is these various forms of cells, often more or less swollen and in a con-

dition of more or less well-marked granular and fatty degeneration, which have been considered characteristic of the ovarian cysts and are sometimes called *Drysdale's* corpuscles. While, however, they are of frequent occurrence under these conditions, they are by no means pathognomonic, since we find them in the contents of various kinds of cysts and cavities where the cells are undergoing degeneration. In addition to the above structural elements we may find free fat droplets, cholesterin crystals, pigment granules, and more or less granular detritus. The gelatinous material filling these cysts is sometimes called colloid, and the cysts are frequently called colloid cysts.

Numerous secondary changes are liable to occur in these cysts. The cells may peel off, the walls of the cysts atrophy or become calcified.

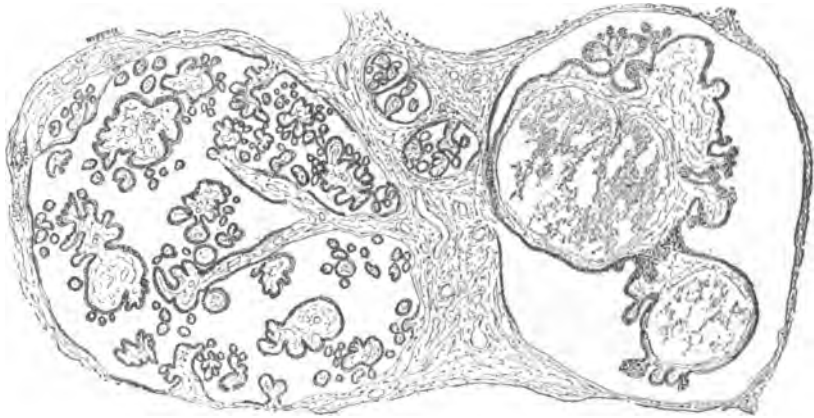


FIG. 573.—MULTIPLE PAPILLARY CYSTS OF THE OMENTUM, SECONDARY TO A SIMILAR GROWTH IN THE OVARY.

The papillary outgrowths are themselves becoming softened at their centres, forming accessory cysts.

Suppurative inflammation, perforation into the peritoneum, bladder, vagina, or rectum; hæmorrhage, gangrene, etc., may occur. As a result of chronic productive processes, the cyst walls may become thickened and extensive adhesions form. Carcinoma may develop from these tumors.

Papillary Cystadenoma.—This type of cystadenoma was formerly regarded as but a variety of the form above described—a variety characterized by papillary outgrowths in cauliflower-like tufts from the walls of the cysts, which often in large degree fill the cyst spaces (Fig. 572). There appears, however, to be sufficient evidence, both anatomical and clinical, to justify the separation of the papillary from the glandular form of cystadenoma.

The papillary cystadenomata are not, as a rule, as large as the glandular form. The cysts are fewer and they do not contain colloid material. The papillary outgrowths often break through the cyst walls, and may

be transplanted to the peritoneal or other surfaces in the form of multiple cystic or papillary tumors (Fig. 573). The papillæ and cyst walls may be lined by cylindrical and often by ciliated epithelium.¹

Follicular Cysts of the Ovary.—The Graafian follicles may be dilated so as to form cysts. This may occur in one or both ovaries, and the cysts may be small or large, single or multiple (Fig. 574). They are usually found after middle life, but may occur during youth, childhood, or even in the fœtus. The follicles dilate from the accumulation of fluid within them; the ovum is destroyed, the epithelium flattened. The contents are usually serous and colorless, but may be viscid, turbid, purulent, or variously colored, red, yellow, or brown. The ovary may be crowded

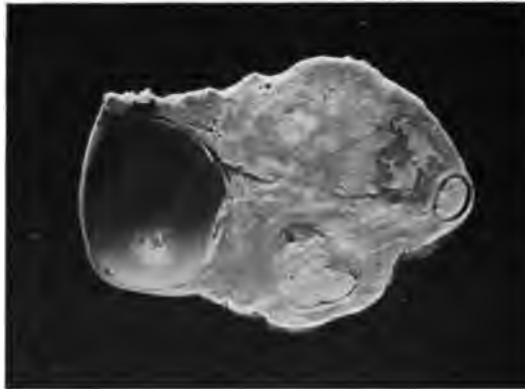

FIG. 574.—FOLLICULAR CYSTS OF THE OVARY.

These cysts are associated with chronic inflammation. At the right an old corpus luteum is visible.

with numerous cysts of moderate size, whose adjacent walls may coalesce and atrophy, forming communications between them.²

A variety of this type of cyst is formed by the dilatation of a corpus luteum either with or without the hyperplasia of the wall.

Dermoid Cysts (Teratomata).—These cysts may be uni- or multilocular, are usually of moderate size, but sometimes become as large as a man's head or larger. Their fibrous walls may be thick or thin, and portions of the internal surface may present more or less completely developed cuticular structures, such as corium, papillæ, epidermis, hairs and hair follicles, sebaceous glands, etc. The cavity may contain a thick, whitish, greasy material composed of flattened epithelium, fat, or cholesterin crystals. Or the cavity or walls may contain masses of irregularly formed hair (Fig. 575), teeth, bone, cartilage, striated muscle, thyroid gland,³ and nerve fibres and cells.⁴ Such embryonal growths,

¹ For reference to bibliography of these ovarian cysts see *Russell*, Johns Hopkins Hosp. Bull., vol. x., p. 10, 1899.

² v. *Kahlden*, Ziegler's Beitr., Bd. xxvii., p. 1, 1900, bibl. .

³ For a *résumé* with case of thyroid tissue in the ovary (struma ovarii) see *Frank*, Am. Jour. Obstet., lx., No. 3, 1909.

⁴ For a study of the origin of dermoid cysts of the ovary see *Arnsperger*, Virchow's Arch., Bd. clvi., p. 1, 1899, bibl.

may exist for many years without causing inconvenience; but inflammatory changes may occur in them, leading to adhesions and perforations into adjacent organs. They may form the nidus for the development of carcinoma, chorionepithelioma (see p. 820), and other tumors, or they may calcify.

In addition to the above-described adenoid, dermoid, and simple follicular cysts, there are a number of composite forms of not infrequent occurrence. Thus, in connection with dermoid cysts or separately, there may be simple ciliated cysts or those which partake of the characters of both adenoid and dermoid cysts. These may be multilocular and be lined with flattened, cylindrical, or ciliated epithelium, and may contain epidermal cells, cholesterol or

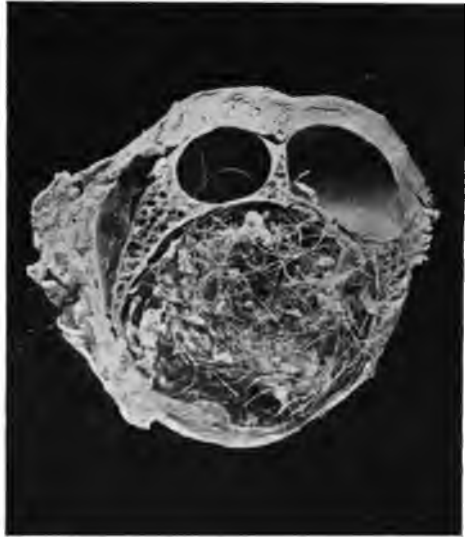


FIG. 575.—DERMOID CYST OF THE OVARY.
One of the cysts contains a mass of hair and sebaceous material.



FIG. 576.—SMALL PEDICULATED CYST GROWING FROM THE BROAD LIGAMENT.

mucin, etc.

Small cysts, sometimes pediculated, sometimes not, of doubtful origin and usually of no special significance, are frequently found growing from the broad ligament near the ovary. The walls are usually very thin, lined with flattened epithelial cells, and the contents serous (Fig. 576).

Teratomata not cystic are of occasional occurrence in the ovary.¹

Cysts of the Parovarium, lying between the peritoneal layers of the broad ligament, are usually small, but may be as large as a man's head. They are usually lined with ciliated epithelium, but sometimes with flattened non-ciliated cells. The contents may be serous, or may be thick and contain mucin and paralbumin.

¹ Consult *Wilms, Ziegler's Beitr., z. path. Anat., Bd. xix., p. 367, 1896*; for a summary of views see *Anspach, Bull. Univ. Pa., xvi., 1903, p. 337*

The Fallopian Tubes.

Malformations.

Absence of both tubes occurs with absence of the uterus. One tube may be absent, with arrested development of the corresponding side of the uterus. Both tubes may be imperfectly developed; either of their ends may be closed; they may be inserted into the uterus at an abnormal place; they may terminate in two or three abdominal ostia.

Changes in Position and Size.

The Fallopian tubes may participate in the various malpositions of the uterus and ovaries; but they are most frequently displaced by the contraction of adhesions formed in perimetritic and periovarial inflammations.

The lumen of the tube may be partially or completely closed as the result of inflammation of the mucous membrane; of peritonitis about the fimbriated extremity;

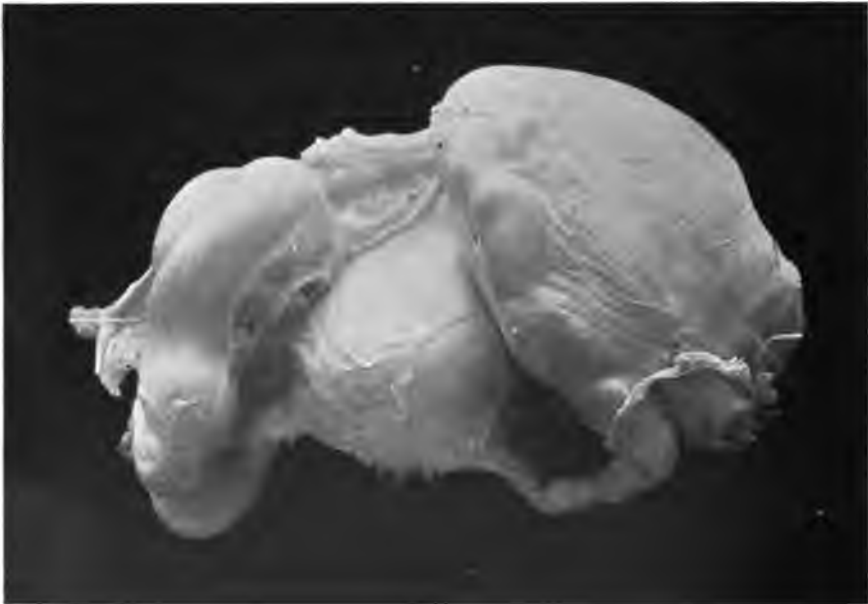

FIG. 577.—HYDROSALPINX.

The tube at the left is much distended, but still tubular. The tube at the right is dilated to cystic form. Between the distended tubes is the fundus of the uterus.

of tumors or inflammation of the uterus; or by pressure from without, or by adhesions, tumors, etc. It may become stopped by plugs of mucus or pus.

Dilatation of the tubes may be produced by an accumulation of catarrhal or other exudation, when there is partial or complete stenosis at some portion of the tube. The dilatation may be moderate, converting the tube into a tortuous, sacculated canal containing mucous or serous fluid; or, more rarely, large cysts may form containing several pounds of serous fluid—*hydrosalpinx*¹ (Fig. 577). As the fluid collects the

¹ For a study of hydro-salpinx with full bibliography see *Cullen*, Johns Hopkins Hosp. Rep., vol. iv., p. 351, 1895.

epithelium may become flattened or fatty or may desquamate. Inflammation may take place in the walls of the dilated tube and the contents may be mixed with pus or blood. Rupture of the dilated tube sometimes occurs; or severe and even fatal hæmorrhage may take place into its cavity. Papillary growths are sometimes found springing from the inner wall of the cyst.

HÆMORRHAGE.

Hæmorrhage into the tube may occur in puerperal women with retroversion of the uterus, with abortions; hæmatometra and tubal pregnancy; in acute infectious diseases. The blood may undergo degenerative changes and be largely absorbed, or it may escape into the peritoneal cavity and incite peritonitis.

INFLAMMATION. (Salpingitis.)

Catarrhal Inflammation of the mucous membrane of the Fallopian tubes commonly occurs in connection with endometritis, frequently in the puerperal condition. In the **acute** stage the mucous membrane is hyperæmic and swollen, and covered with a mucous or muco-purulent, often

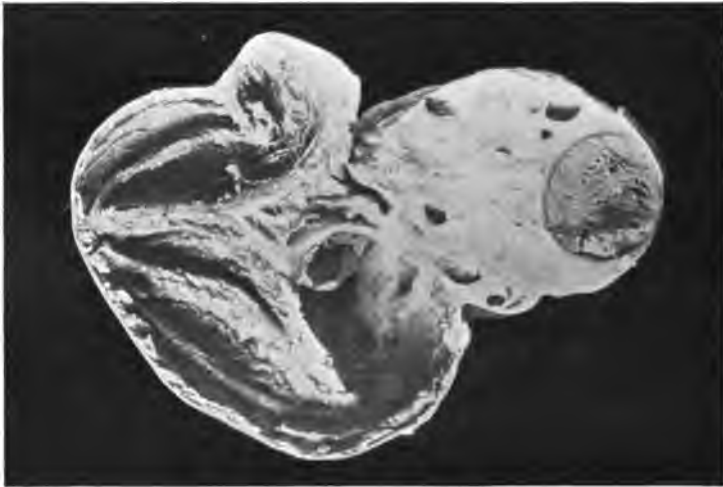

FIG. 578.—PYOSALPINX.

The distended tube containing pus is attached to the ovary.

bloody exudate. The inflammation may subside, leaving no lesions, but it more frequently becomes **chronic**, and may then result in peritœnea, adhesions, thickening of the walls, obliteration of the tubes, dilatation etc.; or the mucous membrane may undergo hyperplasia with papillary outgrowth. Such papillary masses may partially coalesce, forming, on the accumulation of fluid, cyst-like cavities lined with epithelium. Hyperplasia of the muscle wall of the tube may be associated with these conditions.¹

¹ Consult *Ries*, *Jour. Exp. Med.*, vol. ii., p. 347, 1897, bibl.

Suppurative Salpingitis.—Catarrhal inflammation of the mucous membrane may assume a suppurative character, sometimes in connection with puerperal metritis and peritonitis, and often as a result of gonorrhœal infection.¹ Under these conditions the wall of the tube may be involved and pus may exude from the abdominal ends. It is difficult, in many cases of suppurative salpingitis associated with peritonitis, to say which is the primary lesion.

If the abdominal end of the tube be closed by adhesions or otherwise there may be a considerable collection of pus in the tubes, causing dilatation—*pyosalpinx* (Figs. 578 and 579). Such a collection may rupture into the peritoneal cavity, or the pus may escape into a cavity shut in by

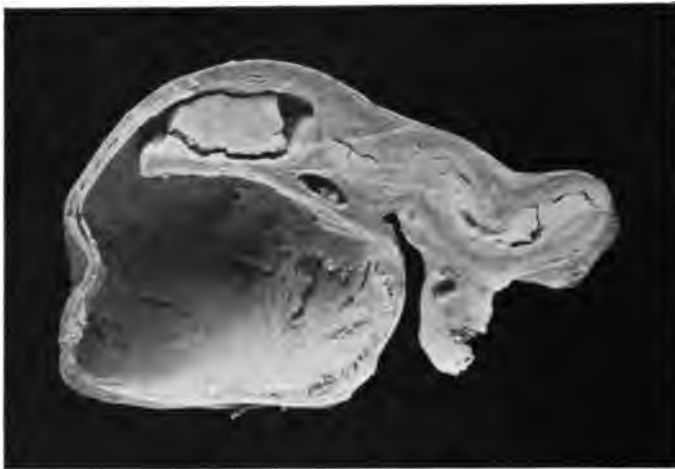

FIG. 579.—PYOSALPINX.
Showing a cyst-like distention of the occluded tube.

adhesions, or may perforate into the intestine or bladder. Or it may dry and finally become calcified.

Suppurative salpingitis is most commonly incited by the gonococcus or the pyogenic bacteria.

Tuberculous Salpingitis.—The lesions are most frequently seen in the later stages of the process, when the mucous membrane is partially or entirely converted into a thick, caseous, often ulcerating layer (Fig. 580). The lumen of the tubes may be dilated, and the walls thickened from chronic inflammation. This lesion may occur by itself, or may be associated with tuberculous inflammation of the lungs, or of the other genito-urinary organs, or of the peritoneum. It usually commences at the abdominal ends of the tubes, and both tubes are apt to be involved.

Syphilitic Inflammation, manifested by a diffuse fibrous thickening of the wall, has been described.

¹ For a study of gonorrhœal salpingitis, see *Gurd*, *Jour. Med. Res.* xxiii., 151, 1910.

TUMORS.

Small **fibromata** and **fibro-myomata** sometimes occur in the wall of the tubes or in the fimbriæ. Small **lipomata** have been seen between the folds of the broad ligament in close connection with the tubes. **Papillomata** are rare. **Myxoma** is recorded. **Sarcoma** is rare.

Carcinoma of the tubes is usually, if not always, secondary to carcinoma of the uterus or the ovaries.

Cysts, usually of small size, sometimes pediculated and with thin

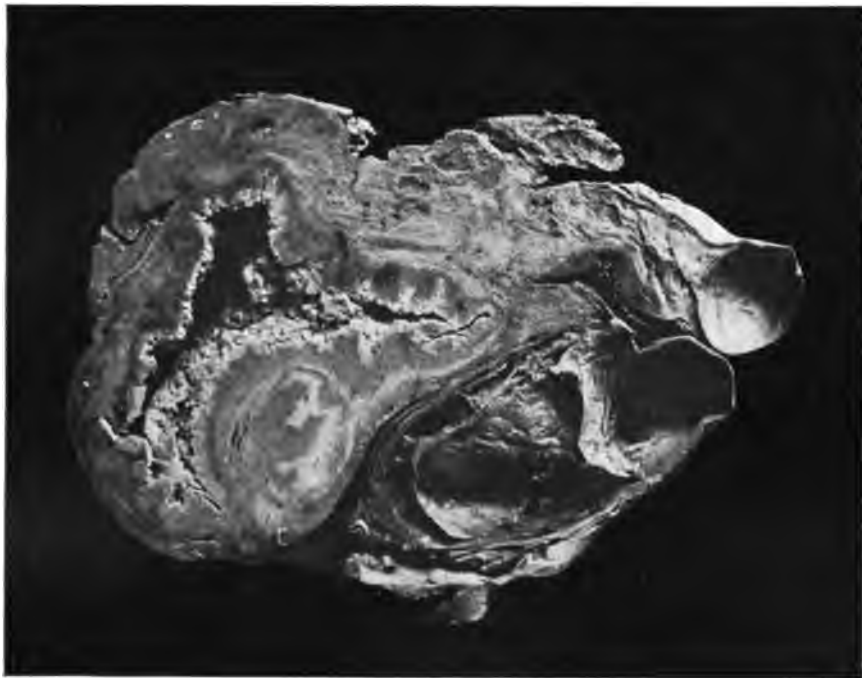


FIG. 530.—TUBERCULOUS SALPINGITIS.

The wall of a portion of the tube is converted into a dense mass of fibrous and necrotic tissue which is disintegrating.

walls, are frequently seen in the peritoneal covering of the tubes or in the fimbriæ. They are believed to be of embryonal origin. Combination cysts of the tubes and ovaries are of occasional occurrence—retro-ovarian cysts.¹

Dilatation of the tubes, as above described, may convert them into cyst-like structures.

Extra-uterine Pregnancy.

TUBAL PREGNANCY.—The impregnated ovum, in some way hindered from passing into the uterus, may become fixed in the tube, and there develop. The villi of the chorion grow into the mucous membrane of the tube, forming an incomplete placenta.

¹ See *Orthmann*, *Virch. Arch.*, Bd. clv., p. 220, 1899, bibl.

Rare cases are recorded in which the placenta was situated in the uterus while the fœtus was developed in the tube. The embryo and its membranes are developed until they reach such a size that the tube surrounding them ruptures. This may occur in the first month or not until much later. In rare cases, when the wall of the tube was extensively involved in the formation of the placenta, the development has gone on until term. The ovum may remain in the tube after the rupture, or may escape into the peritoneal cavity, still enveloped in its membranes; or the membranes may be ruptured and left in the tube. The rupture is generally attended with fatal hæmorrhage. In some cases death is caused by the rupture of a dilated vein while the tube is still intact. Hæmorrhage into the sac may occur before its rupture.

In rare cases death does not take place and the fœtus is shut in by adhesions and false membranes. The embryo soon dies. There may be a slow absorption of the soft parts of the fœtus, the bones are separated and left embedded in a mass of fibrous tissue, fat, cholesterin, and pigment; or the fœtus retains its shape and becomes mummified, and may then be encrusted with the salts of lime (lithopedion).

On the other hand, degeneration and gangrene of the fœtus may take place rapidly, with inflammation and suppuration of the surrounding tissue. There may be perforation and escape of the broken-down fœtus through the rectum, vagina, bladder, or abdominal wall. The patient may die from peritonitis or exhaustion, or may recover after the escape of the fœtus. In some cases the fœtus may escape through a rupture of the tube into the space between the folds of the broad ligament.

IN TUBO-ABDOMINAL PREGNANCY the development of the ovum is in the fimbriated extremity of the Fallopian tube. Adhesions are formed, so that the fœtus is partly in the end of the tube and partly in the abdomen.

INTERSTITIAL PREGNANCY.—The ovum in these cases is arrested and developed in the portion of the tube which passes through the wall of the uterus.

ABDOMINAL PREGNANCY.—The ovum, after escaping from the ovary, may not enter the Fallopian tube, but may become fixed to the peritoneum, usually near the ovary, and develop in that position.

OVARIAN PREGNANCY.—The existence of this form of pregnancy is doubtful and difficult to prove, but there are some cases in which it seems probable that the ovum develops in its Graafian follicle. The placenta may be attached to the tube or to the abdominal wall.

The Mamma.

Malformations.

Arrest of development of the mammæ occurs with arrest of development of the other reproductive organs, and less frequently alone.

One or both mammæ may be absent. Absence of the nipple is more common.

Supernumerary mammæ and nipples have been observed in a number of cases; the glands may all secrete milk during lactation.

Too early development of the mammæ is sometimes found in young children in connection with abnormal development of the organs of generation.

HÆMORRHAGE.

In young women who suffer from amenorrhœa or dysmenorrhœa, small hæmorrhages sometimes occur in the mammæ at the time of menstruation. The blood may find its way into the milk ducts and exude in small quantities at the nipple.

Contusions of the breast may produce extravasations of blood in the mammary gland or the surrounding connective tissue. This may become absorbed, or may remain and be surrounded by fibrous tissue or be converted into cysts.

INFLAMMATION. (Mastitis.)

During lactation the nipple is liable to become inflamed, and ulcers and fissures may form.

There is a form of eczematous inflammation of the nipple and areola

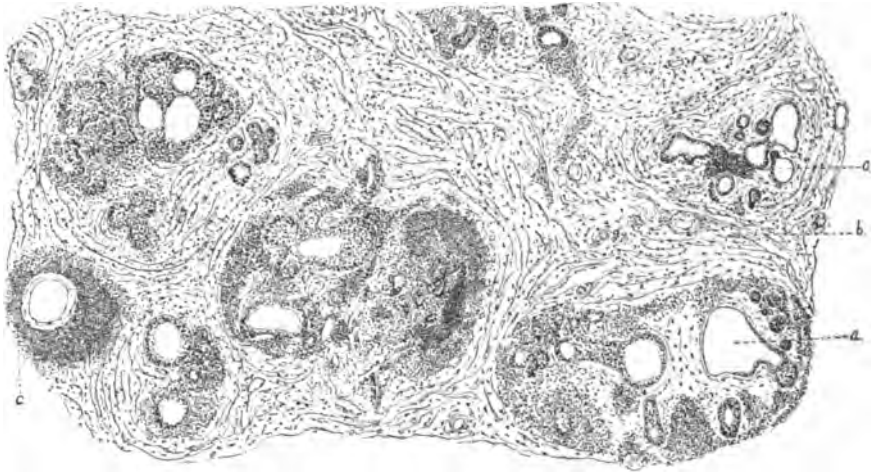


FIG. 581.—SUPPURATIVE MASTITIS IN THE NON-FUNCTIONING GLAND.

a, Milk duct; *b*, interstitial tissue; *c*, dense collections of pus; *d*, diffuse infiltration of lobule with pus.

which tends to ulcerate and in which carcinoma may originate. This is known as Paget's disease, and was at one time thought to be due to the presence of coccidia.

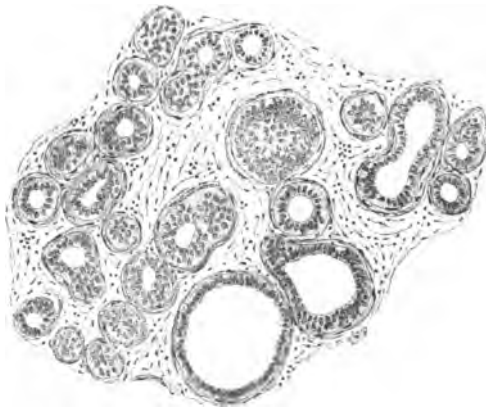

FIG. 582.—CHRONIC INFLAMMATION OF MAMMARY GLAND.

Acute Exudative Inflammation (Mastitis).—This occurs most frequently during lactation; it also occurs during pregnancy, and occasionally in women who are neither pregnant nor nursing.

The process may involve the subcutaneous connective tissue, the gland itself, or the connective tissue between the gland and the wall of the thorax. The inflamed tissues are at first congested, swollen, hard, and painful. The inflammation may stop at this point and resolution may take place, but more frequently it is succeeded by suppuration. If the inflammation involves the subcutaneous connective tissue the abscess may be superficial and may soon open through the skin. If the gland be involved one lobule after another may become affected (Fig. 581), so that

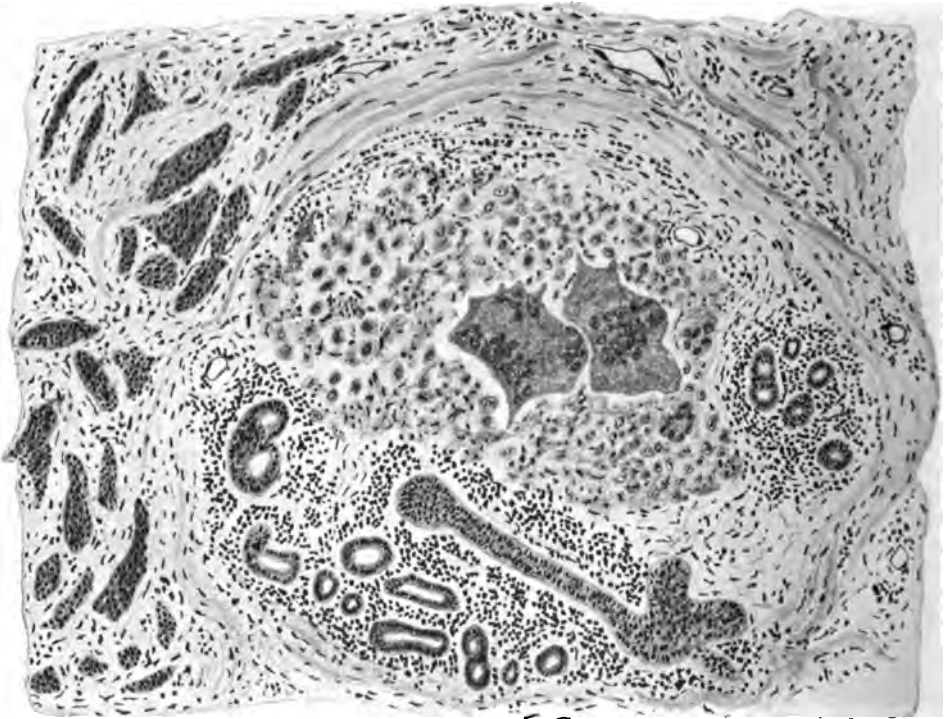


FIG. 583.—CARCINOMA AND TUBERCULOSIS OF THE MAMMA.
The occurrence of these lesions together is unusual.

successive abscesses are formed. If the connective tissue beneath the gland be inflamed a deep abscess of large size may be formed, which usually perforates through the skin, but sometimes into the pleural cavity. In both these latter forms of abscess there is apt to be necrosis of large portions of tissue. These abscesses may cicatrize, or they may pass into a chronic condition and remain for a long time as suppurating, fistulous tracts. Suppurative mastitis is usually due to the presence of *Streptococcus* and *Staphylococcus pyogenes*.

In new-born children there is often a painful swelling of the breasts, which usually subsides in a few days, but may go on to suppuration.

Epidemic parotitis is sometimes complicated by mastitis.

Chronic Inflammation of the interstitial connective tissue of the mammary gland may result in the formation of dense connective tissue (Fig. 582), with or without cystic dilatation of the milk ducts and atrophy of the glandular elements. Acute exudative inflammation may occur in a gland which is the seat of chronic inflammation, and abscesses may be formed.

Cystic Hyperplasia.—About the time of the menopause, when the mammary gland undergoes involution, the fibrous tissue is apt to increase. This fibrous hyperplasia may be excessive, and is then frequently asso-

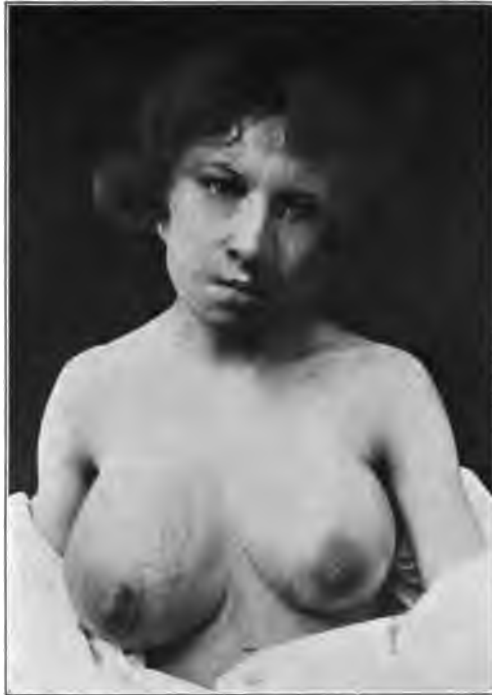

FIG. 584.—HYPERTROPHY OF THE MAMMA.

ciated with a cystic dilatation of the smaller ducts. The epithelium may become atrophied or it may proliferate, and frequently forms papillary projections into the dilated ducts. This cystic hyperplasia of the mamma, when the epithelial changes are marked, is scarcely to be differentiated from adenoma, to which indeed it probably frequently leads.¹

Tuberculous Inflammation of the mammary gland and its excretory ducts is of occasional occurrence. It may manifest itself in the form of miliary tubercles, larger and smaller caseous masses of new-formed tissue,

¹ For a study of this lesion with bibliography see *Greenough and Hartwell, Jour. of Med. Res., vol. ix., p. 416, 1903.*

or cold abscesses.¹ The association of tuberculosis with carcinoma of the mamma (Fig. 583) is rare.

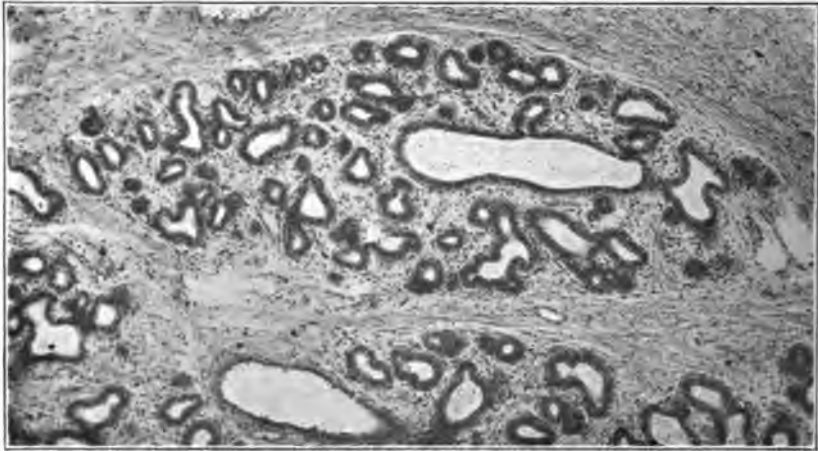


FIG. 585. HYPERTROPHY OF THE MAMMA.
From case shown in Fig. 584. Low power showing topography.

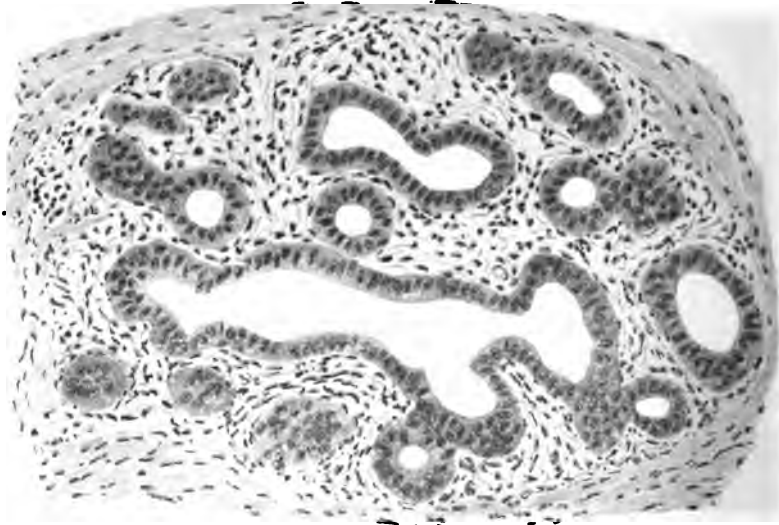


FIG. 586.—HYPERTROPHY OF THE MAMMA.
Showing structure of the enlarged breasts of Fig. 584.

Syphilitic Ulcers may occur in the nipple either as primary chancres or as mucous patches. Gummy tumors have been observed in the mamma.

¹ See a bibliographic summary of tuberculosis of the breast by *Scudder*, *Am. Jour. Med. Sci.*, vol. cxvi., p. 75, 1898.

Hypertrophy.—There may be a general hypertrophy of one or both breasts. This is usually found in young, unmarried women, but sometimes in women in advanced life. The glands may be symmetrically and excessively enlarged (Fig. 584). There is an increase in both the glandular and the connective-tissue elements of the organ¹ (Figs. 585 and 586).

TUMORS.

Fibroma.—Circumscribed tumors composed of connective tissue are sometimes found in the breast. They are dense and hard, and may enclose some of the gland ducts and acini.

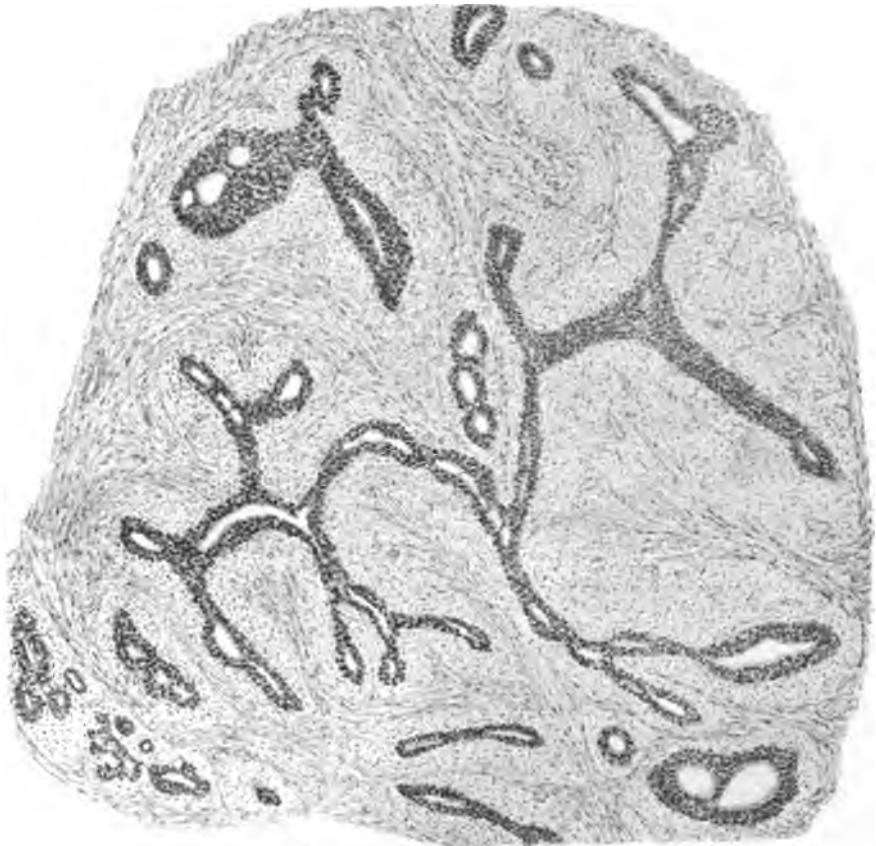

FIG. 587.—INTRACANALICULAR FIBROMA OF THE MAMMA.

Intracanalicular Fibroma.—These tumors are formed by a diffuse growth of connective tissue, and a growth of polypoid fibrous tumors from the walls of the milk ducts into their cavities leading to dilatation.

¹ For a study of hypertrophy of the breast see *Kirchheim*, *Arch. f. klin. Chir.*, Bd. lxxviii., 1903, bibl.

The glandular acini may be atrophied, or enlarged, or cystic. A section of such a tumor looks like a solid mass of fibrous tissue, divided by clefts and fissures lined with cylindrical or cuboidal epithelium (Fig. 587), or fibrous tissue containing cysts into which project polypoid fibrous outgrowths from the walls. Sometimes the new-formed fibrous growths into the dilated ducts are adenomatous in character, containing many new-formed irregular acini (Fig. 588). Such tumors may be called *intracanalicular fibro-adenomata*. These tumors grow slowly, but if left to themselves may reach an enormous size. The skin over them may ulcerate and the tumor project through the opening in fungous masses. They may be associated with interstitial fibrous hyperplasia of the gland.

Pericanalicular Fibroma.—Sometimes the new connective tissue forms a more or less thick cylindrical investment of the duct without growing

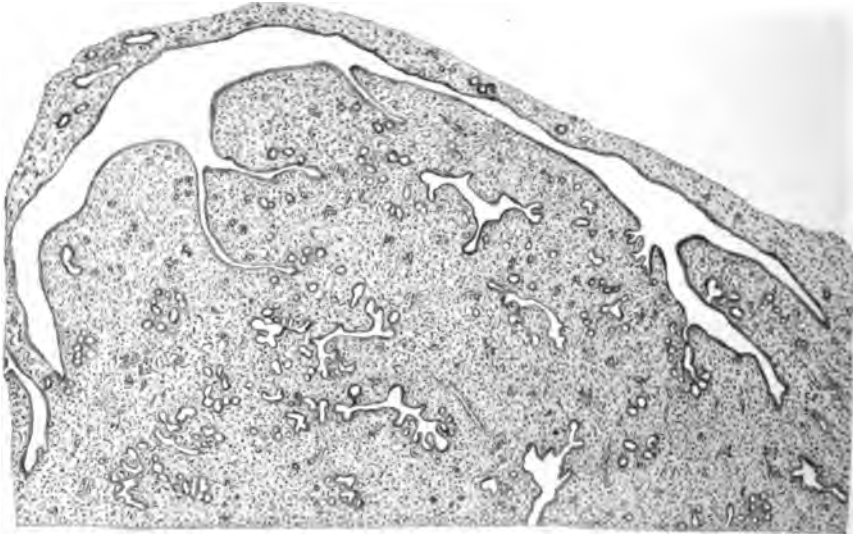


FIG. 588.—INTRACANALICULAR FIBRO-ADENOMA OF THE MAMMA.
Showing new-formed gland acini in the fibrous-tissue mass growing into a duct.

into its lumen. This formation, which is shown in Fig. 589, is sometimes called *pericanalicular fibroma*.

Myxoma.—This may be a circumscribed growth replacing part of the mamma, or it may form in the same way as the intracanalicular fibromata. It is not uncommon in these intracanalicular tumors to find a combination of fibrous, mucous, and sarcomatous tissue in the same tumor.

Osteoma and Chondroma are rare forms of tumor in the mamma. A few cases have been described in which they were combined with carcinoma or with sarcoma. **Osteochondroma** is described.¹

Lipoma, myoma, and angioma are described.

¹ For a study of the cartilaginous and bony tumors of the breast see *St. Arnold*, *Virch. Arch.*, Bd. cxlviii., p. 449, 1897

Adenoma.—Tumors composed of glandular acini and ducts surrounded by connective tissue are of frequent occurrence in the mamma (Fig.

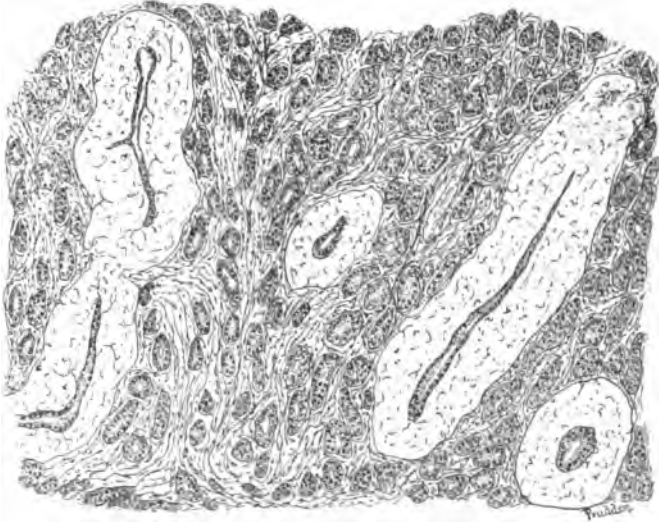


FIG. 589.—PERICANALICULAR FIBROMA OF THE MAMMA.

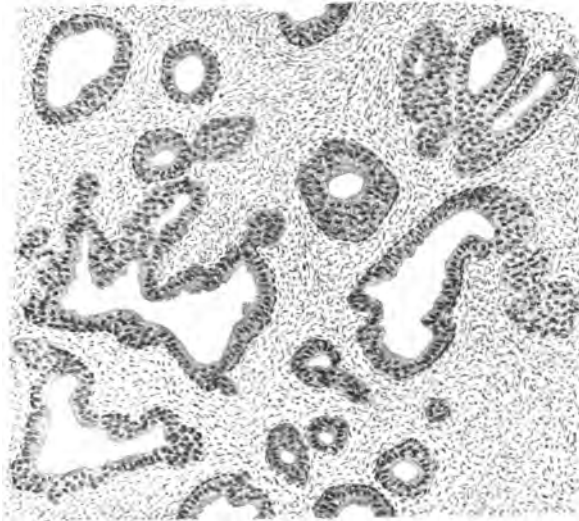


FIG. 590.—ADENOMA OF THE MAMMA.

These new-formed acini, while maintaining the gland character, are still quite atypical in form and grouping and in the irregularity of the epithelium.

590). They are either single or multiple, or several may be developed successively in the same breast. They grow, as a rule, at first slowly,

afterward more rapidly. Their structure may be further complicated by the dilatation of one or more of the ducts which compose the tumor into cysts, and the ingrowth of connective tissue from the walls of these cysts. This growth is often in papillary form—*papillary cystadenoma*—(Fig. 591). A case of cystic adenoma with ciliated epithelium has been described.¹

While preserving the gland type the adenomata present great variation in the form and grouping of the epithelial cells of the ducts and acini, so that here as elsewhere various intermediate forms may be found between adenoma and carcinoma.² The new-formed glandular epithelium often presents two types, one in which the cells are fairly distinct and cuboidal or cylindrical (Fig. 592), and the other in which the cells project into the lumina in irregular masses (Fig. 593).

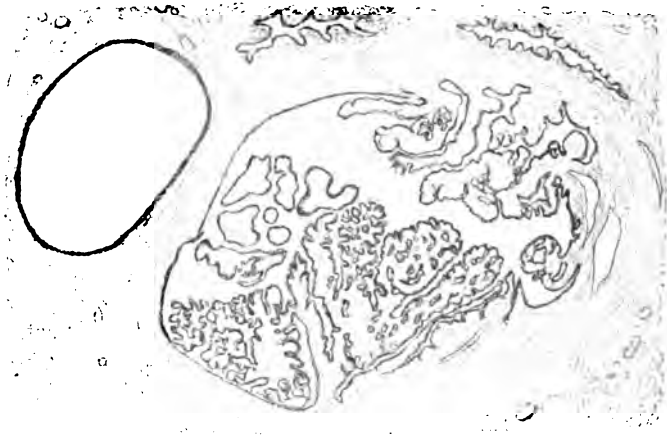

FIG. 591.—PAPILLARY CYSTADENOMA OF THE MAMMA.

Sarcoma.—These tumors may develop in a nodular or diffuse form and may largely replace the gland, or may form intracanalicular growths. They may be of the round or spindle-cell type; they often become very large, and ulcerate. Metastasis in the axillary lymph-nodes is usual.³

Primary Carcinoma of the mamma is most common in women between the ages of thirty-five and fifty-five, but it sometimes occurs in women not over twenty, and sometimes in old persons. It occurs in either breast, in the right rather more frequently than in the left, but sometimes in both. The growth begins more frequently at the periphery of the gland than at its centre, and more frequently in the upper edge of the gland than in any other place.

The growth most frequently begins as a small, circumscribed nodule,

¹ *Buday*, Virchow's Arch., Bd. clvi., p. 395, 1899.

² See Cystic hyperplasia, p. 845.

³ For a case of giant-celled sarcoma and carcinoma in the same breast see *Schlagenhauser*, Cbl. f. Path., Bd. xvii., 1906, p. 385.

which enlarges and involves more and more of the breast; sometimes, however, it is diffuse from the first, and sometimes it begins in the nipple.

It may infiltrate the adjacent tissues and the axillary and cervical glands, and form metastatic tumors in different parts of the body.¹

The local extension of carcinoma often takes place through the lymph-vessels which pass along the fibrous trabeculæ of the periglandular fat;




FIG. 592.—ADENOMA OF THE MAMMA.
Type of acini lined with duct epithelium.

so that bands of fibrous tissue harboring tumor cells, with their active capacity for growth, may extend far from the central mass (Fig. 594). Fibrous bands of such significance are, in the early stages of extension, not to be differentiated from the normal, either by the touch or by the eye. Even with the microscope it is often impossible to determine whether small spheroidal or polyhedral cells which are not characteristically grouped in these fibrous bands are epithelial in character or not.



FIG. 593.—ADENOMA OF THE MAMMA.
Type of acini lined with irregular epithelial cell masses.

It is such cells, frequently left behind in other than thorough operations, which give rise to local recurrence.

The *medullary* and *fibrous* types are most common; the *gelatinous* is rare. In any of these forms of cancer there may be cystic dilatations of the ducts and acini. *Epithelioma* may form at the nipple. *Secondary carcinoma* of the mamma is rare. Retraction of the nipple is common in later stages of fibrous types of mammary cancer (see Fig. 594).

¹ For a study of dissemination of carcinoma of the breast see *Stiles*, Brit. Med. Jour., vol. i., p. 1452, 1899.

Cysts of the mamma seem to be for the most part retention cysts, formed by the dilatation of the gland ducts or acini. During lactation such retention cysts are sometimes formed, and then contain milk. They may reach an enormous size. At other times retention cysts are formed containing serous or viscid, brownish fluid, which often exudes

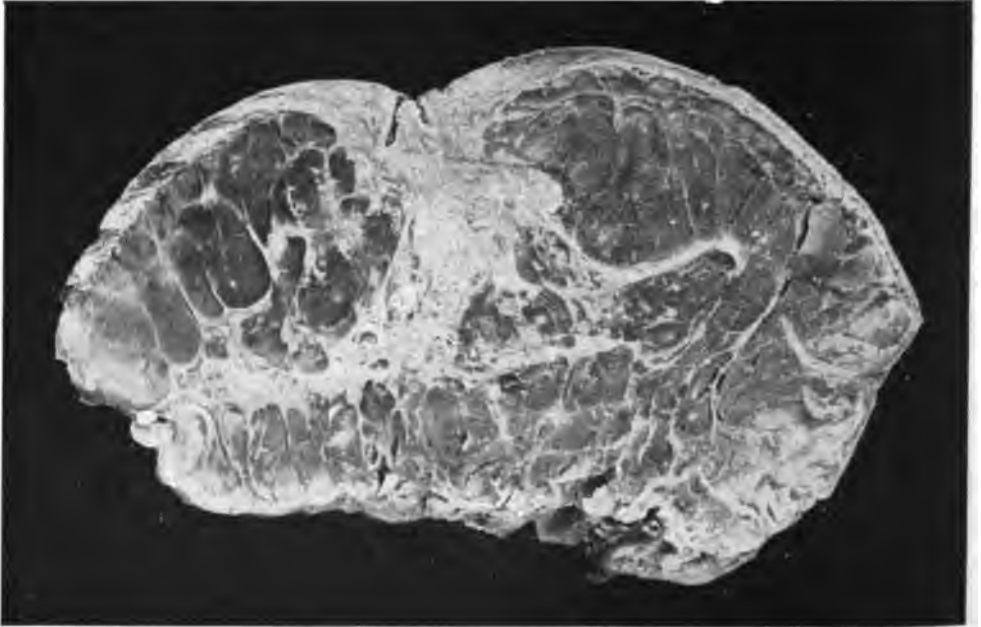

FIG. 594.—CARCINOMA OF THE MAMMA—FIBROUS TYPE—SCIRRHUS.

The nipple is retracted by the shrinkage of the fibrous tissue. The growth is extending along the fibrous bands of the mammary fat and at the left has reached the plane of excision. The darker portions in the figure are lobules of fat.

through the nipple. These cysts may be large or small, single or multiple. There are usually at the same time some growth and induration of the connective tissue of the gland. In some cases there are polypoid outgrowths of connective tissue from the wall of the cyst. These cysts are not to be confounded with the cysts which are developed with the intracanalicular tumors, described above.

CHAPTER XI.

REPRODUCTIVE ORGANS OF THE MALE.

The Penis.

Malformations.

THE penis may be absent with great defects of development of the rest of the body. The urethra then usually opens into the rectum.

An abnormally small penis may be associated with absence or arrested development of the testicles. The prepuce may be rudimentary or absent.

Congenital phimosis is not uncommon.

HYPOSPADIAS is an arrest of development of the penis and scrotum. In its highest degree the penis is short, the glans penis small. On the lower side of the penis is a deep cleft lined with mucous membrane. Into this cleft the urethra opens at the root of the penis. The scrotum remains separated into two halves, resembling labia majora. The testes may descend into their proper position on each side or remain in the abdomen. If the testicles continue to develop normally the individual has the appearance and capacities of a man; if their development is arrested the individual is apt to be of feminine type.

In lesser grades of hypospadias the two halves of the scrotum are joined and the penis is larger, but a part of the urethra remains open as a cleft at some point of the penis.

EPISPADIAS is an opening of the urethra on the upper side of the penis. It presents various grades and forms.

HERMAPHRODITISM.—This is a union of two sexes in the same person, the test of which is the presence of the secreting organs, the ovaries and testicles. True hermaphroditism is rare, but it does occur, while most of the conditions called hermaphroditism are in reality due to varying malformations of the external generative organs.

Pseudo-hermaphroditism.—In the male, normally, the greater part of Müller's canal disappears and its lower end forms the vesicula prostatica. In this malformation Müller's canal is changed, as it is in the female, into Fallopian tubes, uterus, and vagina, while at the same times the testes, epididymides, vesiculæ seminales, and spermatic cord are formed as usual. In the lesser degrees of this malformation we find, in the place of the vesicula prostatica, a pear-shaped sac as large as a pigeon's egg, with muscular walls and an epithelial lining. This sac may be incompletely divided into a uterus and vagina, and it opens into the urethra. In the higher grades we find a well-formed vagina and uterus. The uterus may or may not have Fallopian tubes. The testicles are usually retained in the abdomen or inguinal canals, and are small. The spermatic ducts run on the sides of the uterus and open into the urethra or are closed. The penis and scrotum appear as in hypospadias, or are well formed. The appearance of the individual varies with the development of the testicles.

True hermaphroditism may be lateral. In this condition there is hypospadias; a vagina and uterus and a Fallopian tube and ovary are on one side, and a testicle and spermatic cord on the other.

In certain cases, which may be called *bilateral hermaphroditism*, there is a testicle on one side and an ovary on the other.¹

ENLARGEMENT OF THE PENIS is sometimes caused by venous congestion from

¹ For a detailed consideration of the malformations of the male and female generative organs consult *Klebs*, "Handbuch der pathologischen Anatomie," and more recent cases of hermaphroditism by *Heppner*, *Arch. f. Anat. u. Physiol.*, 1870, and by *Hofmann*, *Wien. med. Jahrb.*, 1877.

heart disease; by long-continued masturbation, as a result of which the corpus cavernosum may lose its contractility; and in rare cases by hyperplasia of the stroma of the corpus cavernosum.

INJURY AND HÆMORRHAGE.

Injuries to the penis are liable to give rise to severe hæmorrhage on account of its peculiar vascular character; suppurative inflammation, gangrene, infiltration with urine and its consequences, are also liable to occur. The contractions of the cicatricial tissue by which wounds are healed frequently give rise to various distortions of the organ.

INFLAMMATION.

Balanitis—inflammation of the glans penis and the prepuce—is usually due to gonococcal or syphilitic infection, or it may be incited by foul accumulations of smegma. The parts are red and swollen and may ulcerate. Condylomata may be formed, and adhesions between the prepuce and glans. The glans may ulcerate and the prepuce may be much thickened. If the prepuce be long, *phimosis* may occur with the accumulation of exudate beneath. The prepuce may become gangrenous.

Paraphimosis is produced by the retraction of a narrow prepuce behind the glans, with consequent stricture, inflammation, and sometimes gangrene.

Inflammation of the Corpora Cavernosa may be the result of injury, may follow fistulæ, may occur in connection with inflammation of the connective tissue of the penis, and may accompany the acute infectious diseases. It may result in fibrous induration of portions of the corpora cavernosa; rarely in abscess or diffuse purulent infiltration; sometimes in gangrene. Larger and smaller masses or plates of very dense fibrous tissue sometimes form in the sheath of the corpora cavernosa without history of antecedent lesion.¹

Tuberculous Inflammation of the penis has repeatedly followed circumcision performed by uncleanly tuberculous persons.

Syphilitic Ulcers frequently occur in the glans penis and prepuce. The indurated chancre is formed either from an excoriation in which a pustule is formed or from a little nodule. The pustule breaks and its walls are infiltrated with small round cells. The nodule softens, breaks down, and forms an ulcer whose walls are infiltrated with cells. Syphilitic condylomata are of frequent occurrence on the glans.

Herpes of the prepuce occurs in the form of small vesicles, which may later become ulcers. **Erysipelatous and furuncular inflammation** sometimes involves the skin of the penis.

TUMORS.

Papilloma is found on the prepuce and glans penis. It occurs in the form of little warty growths, or of composite, cauliflower masses, even as large as a fist. In either case the structure is the same—hypertro-

¹ For a study with bibliography of indurations in the corpora cavernosa penis see Sachs, Wiener klin. Wochenschr., Jan. 31st, 1901.

phied papillæ covered with epithelium. Sometimes the epithelial layers become thick and horny, forming large, dense projections.

Fibroma diffusum, or elephantiasis of the prepuce, may occur, leading to great thickening. It is due to a diffuse growth of fibrous tissue in the cutis. **Lipoma, angioma, circumscribed fibroma, and sebaceous cysts** may occur in the penis. **Carcinoma** is usually of the epitheliomatous type. It is most frequent in the prepuce and glans penis. It may have the form of a flat ulcer, or of infiltrating, ulcerating nodules, or it may be papillary. Such growths may attain great size, ulcerate, or undergo a variety of inflammatory changes. Carcinoma may involve the entire skin of the penis or may invade deeper parts. The inguinal glands may be involved. Distant metastases are not frequent. Medullary or glandular carcinoma of the penis is not common. It may be secondary to carcinoma in some other part of the body.

Sarcoma is described.

Dermoid tumors of the penis are of occasional occurrence.¹

Calcification and **ossification** of the connective tissue of the corpora cavernosa sometimes occur. Large and small **preputial calculi** are occasionally found between the prepuce and the glans. These may be formed *in situ*, may come from the bladder or from without, and may later increase in size.

The Scrotum.

The skin of the scrotum is subject to the various forms of lesions which may occur in any part of the integument.

Elephantiasis of the scrotum consists in the main of a development of new connective tissue in the cutis, which is sometimes accompanied by dilatation of the lymph-vessels; thus the thickened scrotum may form a large tumor, often rough upon the surface, which may entirely cover in the penis.

TUMORS.

Lipoma and **fibroma** occur. **Epitheliomata**, in the form of flat or papillary ulcerating tumors, are of frequent occurrence among chimney sweepers, and may lead to extensive ulcerations of the adjacent parts and involvement of neighboring lymph-nodes.

Dermoid Cysts and Teratomata of the scrotum are not uncommon. In very rare cases tumors containing a considerable portion of a foetal skeleton have been found in the scrotum. Occasionally the skin of the scrotum is beset with numerous larger and smaller sebaceous cysts, which raise the surface into little globular or wart-like projections.

The Testicles.

Malformations.

Absence of both testicles, either with or without absence of the epididymides, spermatic cords, and vesiculæ seminales, occurs in rare cases. The scrotum is only

¹ Gerulanos, Deut. Zeits. f. Chir., Bd. lv., p. 326, 1900.

indicated or may contain the epididymides. The penis is small, and the individuals are small and poorly developed.

The testes may be imperfectly developed. The individuals are effeminate. Absence of one testicle with healthy development of the other, is more frequent. The corresponding epididymis and cord may be absent or present.

The spermatic cords and vesiculæ seminales may be absent or imperfectly developed on one or both sides, while the testes are normal.

CRYPTORCHISMUS.—Either one or both testicles may remain permanently in their fetal position, or may not descend into the scrotum for several years after birth (cryptorchismus), or not at all. This condition may be due to an arrest of development in the testes or the gubernaculum testis; adhesions produced by antenatal peritonitis; narrowing of the inguinal canal; narrowing or shortening of the vaginal process of the peritoneum; or to abnormal size or position of the testicle. Usually the malformation is confined to one testicle, and then is more frequent on the left side. The testicle is usually found in the abdomen close to the mouth of the inguinal canal, or in the inguinal canal just below the external ring; but it may be beneath the skin in the perineum, or in the crural canal with the femoral vessels, or elsewhere. The retained testis is usually not fully developed, or undergoes fatty degeneration or fibrous hyperplasia. The retention of one or even of both testicles does not preclude the possibility of procreation. Retained testicles are prone to inflammatory changes and liable to become the seat of malignant tumors.

Sometimes, while the testis is retained, the epididymis and spermatic cord descend into the scrotum. In rare cases the position of the testis may be changed so that the epididymis and cord are in front. The occurrence of supernumerary testicles is described.

Varicocele.

In varicocele the veins of the spermatic cord are dilated, often forming tortuous masses of considerable size (Fig. 595).

Hydrocele.

In *hydrocele* of the *tunica vaginalis* there is an accumulation of fluid in the cavity of the sac. It is usually unilateral and is commonly associated with acute or chronic inflammation of the *tunica vaginalis*, varicocele, or general dropsy. The serum is

present in small or in large quantity; it is usually transparent, may contain cholesterolin, or be purulent or mixed with blood. The *tunica vaginalis* remains unchanged, or is thickened, or contains plates of bone, or is covered with polypoid fibrous bodies which may fall off and be found free in the cavity of the sac. There may be adhesions between the layers of the *tunica vaginalis*, and in this way the fluid becomes sacculated. The testis is pushed downward and backward; it remains unchanged or is atrophied.

In *hydrocele* of the *processus vaginalis* there is an accumulation of serum in the cavity of the vaginal process of the peritoneum, which remains open after the descent of the testicle. There are several varieties.



FIG. 595.—VARICOCELE.

The distended and tortuous vessels have been filled with wax.

(a) The vaginal process is entirely open and there is a free communication with the peritoneal cavity. The serum may originate in the cavity of the peritoneum or of the vaginal process, and passes freely from one to the other.

(b) The processus vaginalis is closed in the inguinal canal, while its lower portion is filled with serum.

(c) The processus vaginalis is closed about the testis and the visceral layer of the tunica vaginalis is formed. The serum accumulates in the upper part of the vaginal process which communicates with the peritoneal cavity.

(d) The vaginal process is closed in the inguinal canal and over the testis; the serum accumulates so as to form one or more sacs between these two points. Inguinal hernia may complicate this form of hydrocele.

In *hydrocele of the spermatic cord* there is general œdema or the development of circumscribed cysts in the connective tissue of the cord.

A peculiar type of hydrocele is formed by the accumulation of serum in the sac of an inguinal hernia from which the intestine has become retracted.

Hæmatocele.

In hæmatocele of the tunica vaginalis there is an effusion of blood into the cavity of this sac. It may occur in injury; in scurvy, or with the hæmorrhagic diathesis; or it may complicate a pre-existing hydrocele. The effused blood usually soon degenerates, and the sac is filled with a brownish fluid or a thick, grumous mass. The tunica vaginalis may be thickened. The testis remains normal or is atrophied.

Effusion of blood into the loose connective tissue of the scrotum is often called *extravaginal hæmatocele*.

Hæmatocele of the spermatic cord occurs in rare cases as a diffuse infiltration of blood in the connective tissue of the cord. Or blood may be effused into a hydrocele of the cord.

Spermatocele.

Cysts containing spermatic fluid not infrequently arise from the epididymis or from the rete testis. These sometimes acquire a large size and crowd the tunica vaginalis before them, so that they simulate a collection of fluid in the cavity of the latter. The wall of the cyst may be lined with ciliated or with flattened epithelium. The contents are sometimes simply serous, but more frequently opalescent, and may contain spermatozoa.

ATROPHY.

Atrophy of the testicle may occur in old age or in persons who are in a condition of premature senility; or as the result of injury or of pressure from herniæ, hydrocele, or inflammatory products. Fatty degeneration and the accumulation of various degeneration products in the lumen of the tubules may accompany atrophy.

INFLAMMATION. (Orchitis.)

Inflammation of the testicles may follow injuries, exposure to cold, and inflammation of the urethra; it may occur in parotitis or with syphilis and various other infectious diseases. The testes, epididymis, or tunica albuginea may be principally involved. Usually only one testicle is inflamed, sometimes both. The inflammation may extend to the vas deferens.

Acute Exudative Orchitis is most frequent in the epididymis and tunica albuginea. When the testis is involved the organ is congested and infiltrated with serum or pus. From this condition it may return to the normal state; or small abscesses may form which may be absorbed, or

increase in size so as to involve nearly the entire organ. They may perforate externally, and then healing may occur by means of granulation tissue; or extensive gangrenous destruction of the scrotum may occur. Abscesses may become enclosed in a fibrous capsule, when the contents may dry and become caseous or calcified, and so persist for a long time. The acute inflammation may become chronic.

Acute epididymitis is frequently the result of gonorrhœal infection, and may or may not be associated with inflammation of the testis. The products of inflammation may collect in varying quantity in the lumina of the seminiferous tubules and in the ducts of the epididymis, and the epithelium of these structures may degenerate.

Chronic Orchitis occurs as a sequel of acute inflammation or as an independent process. It may involve the testis, the epididymis, or the

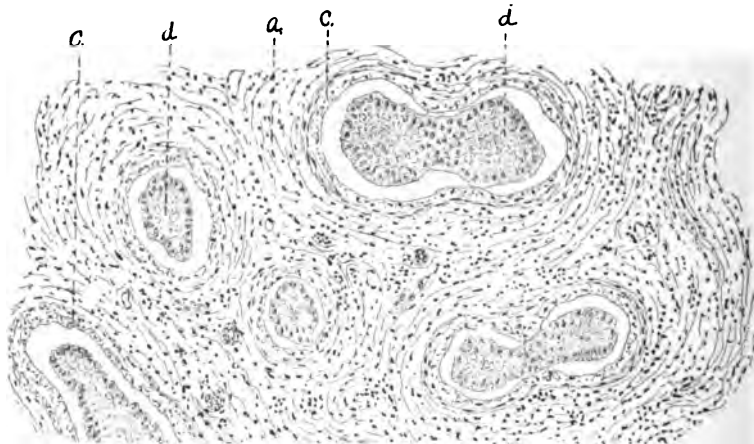

FIG. 596.—CHRONIC INTERSTITIAL ORCHITIS WITH ATROPHY OF THE SEMINIFEROUS TUBULES.
a, Thickened interstitial tissue; b, thickened membrana propria of the tubules; c, separated epithelial cell mass in the lumen of the tubules.

spermatic cord. The seminiferous tubules may be filled with desquamated and degenerated epithelium; they may be atrophied, or their walls may be greatly thickened so that they are converted into dense fibrous cords, with partial or complete obliteration of their lumina. There is usually a marked increase in the interstitial tissue, which causes atrophy of the tubules (Fig. 596). The albuginea may be greatly thickened. In some cases the testis is converted into a mass of dense fibrous tissue, in which but little trace of the original structure can be made out. The new-formed fibrous tissue may become calcified. A periorchitis may lead to thickening and union of the layers of the tunica vaginalis testis. Abscesses are not infrequent in connection with chronic orchitis.

Tuberculous Orchitis may occur in connection with tuberculosis of the other genito-urinary organs or the lungs, in acute general miliary tuberculosis, or independently. It usually originates in the epididymis, and may extend from there to the testis; or it may commence in the testis.

The appearance which the testicles present, when they are the seat of this form of inflammation, are exceedingly varied and often difficult of interpretation. This is partly due to the complex structure of the organ, partly to the varied complicating simple inflammatory changes which the different parts of the organ undergo in connection with the tuberculous lesion.

We may find in the testicle small circumscribed masses of cells, visible to the naked eye as whitish spots, which are sometimes composed of small spheroidal cells or of larger polyhedral or fusiform or round cells. These occur in the walls of seminiferous tubules and blood-vessels, and in the interstitial tissue. Sometimes associated with these smaller nodules, and sometimes not, we find larger, irregular, yellowish or gray cheesy masses, which may be formed by the confluence and degeneration

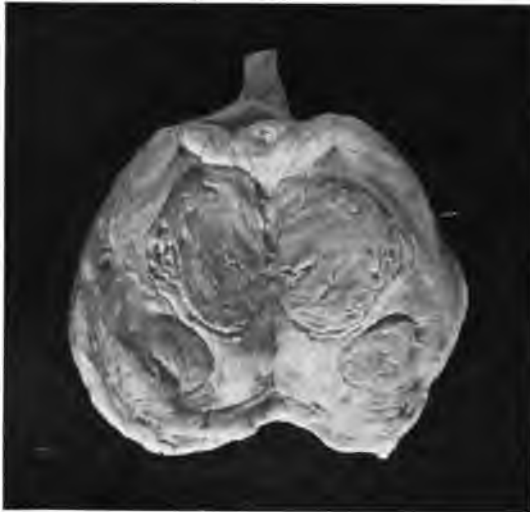

FIG. 597.—TUBERCULOUS ORCHITIS.

of the smaller nodules (Fig. 597). The cheesy masses may break down and open externally, giving rise to fistulæ, gangrenous inflammation, etc.

Hand-in-hand with this distinctly tuberculous nodular formation of tissue, which is disposed to degenerative changes, there are various more or less diffuse alterations of the parenchyma and interstitial tissue of the organ which often constitute a most prominent feature of the lesion. The interstitial tissue may be more or less densely and diffusely infiltrated with small spheroidal cells. The arteries are often the seat of obliterating endarteritis. The walls of the seminiferous tubules may be very much thickened, so that the lumen may be entirely obliterated. The epithelium lining the tubules may be fatty, disintegrated, and peeled off, or it may have largely disappeared. The lumen of the tubules may be filled with a granular, nucleated mass which in transverse sections looks like a giant cell. The thickened walls of the tubules may be infil-

trated with small spheroidal cells, so that the underlying stroma is scarcely visible. When this occurs in connection with a similar infiltration of the interstitial tissue and the formation of giant cells in the lumina, we have structures which present the greatest resemblance to some forms of tubercle granula (Fig. 598).

Tuberculous inflammation may extend from the testis to the vas deferens, vesiculæ seminales, and prostate.

Syphilitic Orchitis.—This may occur in the form of a diffuse new formation of connective tissue, which may be localized or be widely dis-

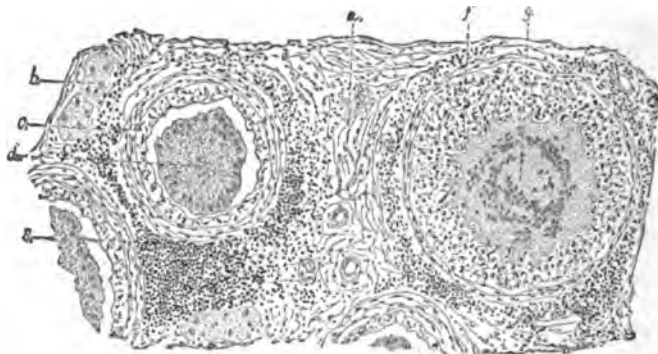


FIG. 598.—CHRONIC ORCHITIS WITH THE FORMATION OF STRUCTURES RESEMBLING MILIARY TUBERCLES
a, Thickened interstitial tissue; *b*, mass of granular cells in the interstitial tissue; *c*, thickened membrana propria of seminiferous tubule; *d*, mass of separated epithelium in tubule; *e*, accumulation of small spheroidal cells around tubules; *f*, thickened membrana propria enclosing *g*, a multinuclear mass resembling a giant cell.

tributed. This organ becomes dense and firm. Morphologically there is no difference between this form of orchitis and chronic indurative orchitis from other excitants. It may occur in children affected with congenital syphilis. Gummata may form in connection with the interstitial induration. These may disappear, leaving irregular cicatrices.

In leprosy, inflammatory foci in the testicle are common.¹

TUMORS.

Fibromata occur in the form of small dendritic or polypoid growths of the visceral layer of the tunica vaginalis. These sometimes become free and are found in the sac, usually in connection with hydrocele. Small nodular fibromata occasionally occur in the albuginea and in the spermatic cord.

Lipoma, either pure or in combination with myxoma and sarcoma, may arise from the connective tissue of the spermatic cord or from the tunica albuginea.

Chondroma, sometimes in a pure form, but more frequently combined with myxoma and sarcoma, occurs in the testicles and may attain a large size. **Osteoma** has been described.

¹ For a summary of orchitis, consult *Sébileau*, Arch. gén. de méd., t. i., pp. 636, 757, 1899, bibl.

Sarcomata occur in the testes and epididymis, most frequently in the former. They may be composed of spheroidal or spindle-shaped cells; they may be soft or contain much fibrous tissue; they are very frequently combined with myxoma, chondroma, lipoma, etc. Owing to the occlusion of the seminiferous tubules, cysts may be formed in these sarcomata. In such cysts sarcomatous tissue may occur in the form of intracanalicular polypoid growths. Thus the so-called *cysto-sarcomata* of the testicle are formed. The walls of these cysts may coalesce, so that large, irregular cavities may be formed. When the cysts are not filled by polypoid outgrowths from their walls they may contain a mucous, serous, or bloody fluid, or masses of flattened cells, fat, and cholesterol. The cysts may be lined with cylindrical, ciliated, or flattened cells.

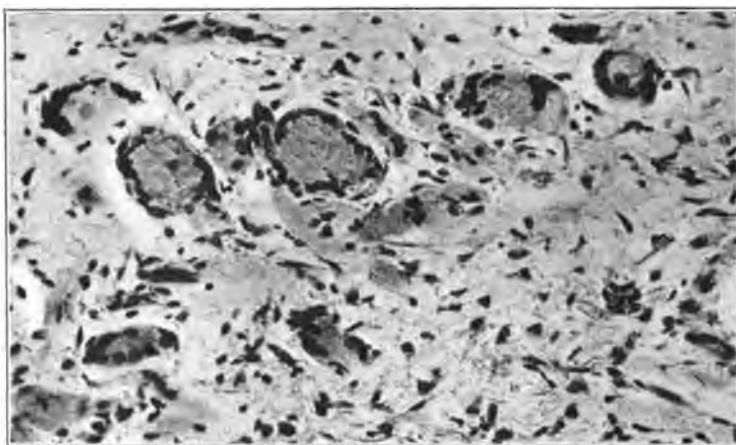


FIG. 599.—RHABDOMYOMA OF THE TESTICLE.
Imperfect striated muscle fibres lie in an embryonal connective tissue.

Rhabdomyoma has been several times observed, frequently in combination with cysts.¹

Myoma and **angioma** are described.

Adenoma is occasionally found, usually in combination with sarcoma or carcinoma, or with cyst formation.

Carcinoma of the testicle is commonly of the soft medullary form, of rapid growth, and usually primary. It may commence in the testis or epididymis. Usually only one testicle is involved. Frequently the entire glandular portion of the organs is replaced by the new growth. The albuginea expands with the growth of the tumor, and may continue to enclose it even when of large size. The tissues are often very vascular, and hæmorrhages, areas of softening, fatty and mucous degeneration are frequent. The inguinal and lumbar lymph-nodes are apt to become involved, and distant metastasis may occur. Rarely the growth assumes a scirrhus form.

¹ For study of rhabdomyoma see *Becker*, *Virchow's Arch.*, Bd. clxiii., p. 244, 1901, bibl.

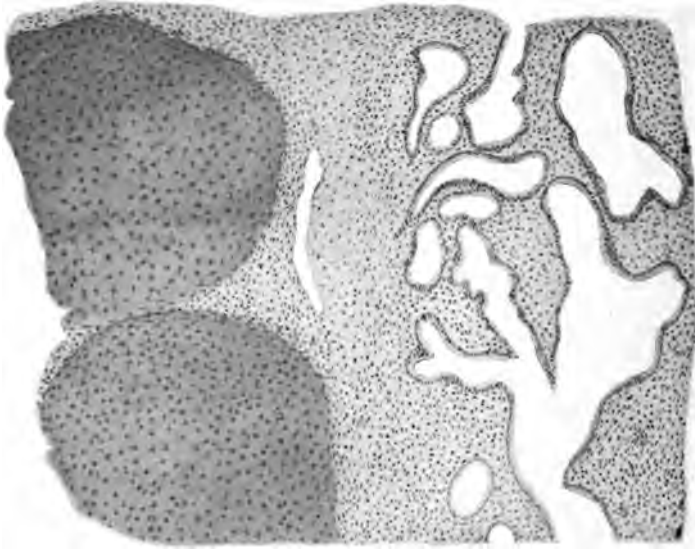


FIG. 600.—TERATOMA OF THE TESTICLE.
Masses of hyaline cartilage at the left; new-formed atypical glandular structures at the right.

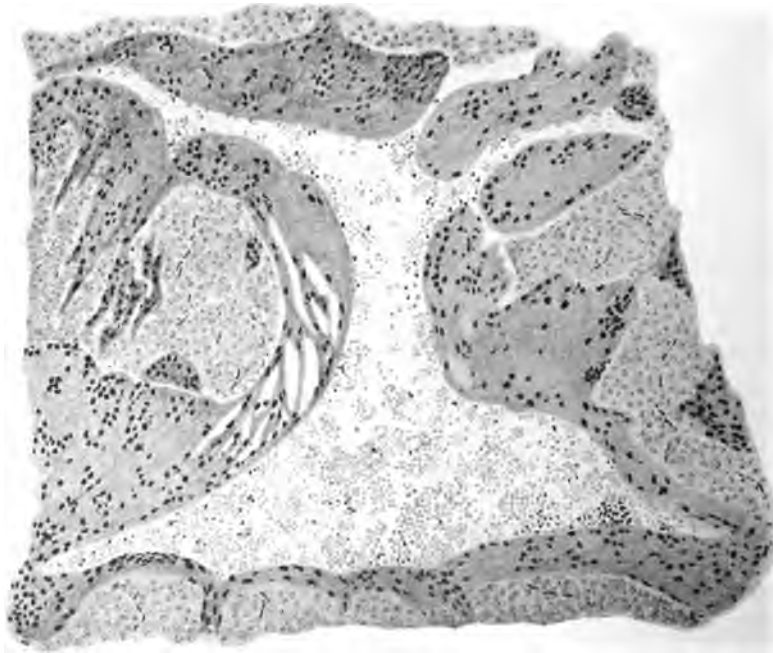


FIG. 601.—CHORIONEPITHELIOMA OF THE TESTICLE.
Showing syncytium and Langhans' cells and their relation to blood sinuses.

Cysts.—Aside from the above-mentioned cysts, which occur in connection with tumors and spermatocele, cysts may be formed from persistent remnants of Müller's canal in the epididymis, or from obstruction of the seminiferous tubules or ducts by inflammatory products or tissue.

Teratomata of various kinds, with or without cysts, are of infrequent occurrence, and are sometimes quite complex in character (Fig. 600). They may be embedded in the substance of the gland.¹ Probably some of the above-mentioned cystic rhabdomyomata belong here.

Chorionepithelioma.—Several cases of chorionepitheliomata of the testicle have been described. These tumors (Fig. 601) resemble those occurring in the uterus and elsewhere (see p. 820), the various forms of cells, syncytium, Langhans' cells, and wandering chorionic forms, being in some instances typical in character. They are malignant and form metastases. They are associated with teratomata.²

PARASITES.

Echinococcus may occur in the testis or epididymis.

The Seminal Vesicles.

The seminal vesicles may be the seat of **acute or chronic inflammation**, which is most frequently associated with inflammatory changes in adjacent parts, prostate, urethra, etc. As a result of chronic inflammation the vesicles may be atrophied, or they may be greatly dilated, forming cysts due to constriction of the ducts. **Tuberculous inflammation** is usually secondary.

TUMORS.

Carcinoma of the rectum or other genito-urinary organs may secondarily involve the seminal vesicles. Small **concretions**, sometimes containing masses of spermatozoa, are occasionally found in the seminal vesicles.

The Prostate.

DEGENERATION, ATROPHY, AND HYPERTROPHY.

Fatty and hyaline degeneration of the muscle may occur in the prostate, with or without hypertrophy. **Atrophy** of the prostate may follow lesions or removal of the testicle, inflammation of the prostate itself, and may occur as a senile process. Dilatation of the ducts may accompany the atrophic process.

Hypertrophy.—Enlargement of the prostate—so-called hypertrophy—is of frequent occurrence in advanced years. It may involve the entire

¹ Consult for teratoid tumors of the testicle *Wilms*, Ziegler's Beitr. z. path. Anat., Bd. xix., p. 233, 1896.

² See for a summary and discussion of these tumors *Frank*, Jour. Amer. Med. Assn., vol. xlv., p. 248, 1906.

organ or be partial; it may be nodular (Fig. 602) or diffuse. The middle lobe is most frequently involved, and this may press upon the urethra, leading to difficult urination and such secondary alterations in the bladder as are associated with this, *i.e.*, hypertrophy and dilatation of the bladder, or cystitis, not infrequently with involvement of the ureter and kidneys.

Hypertrophy of the prostate may be due to hyperplasia of the muscle and fibrous tissue of the organ; at the same time the gland tissue may be increased (Fig. 603), or the latter may be alone involved. The increase in gland tissue has usually the character of glandular hyperplasia.

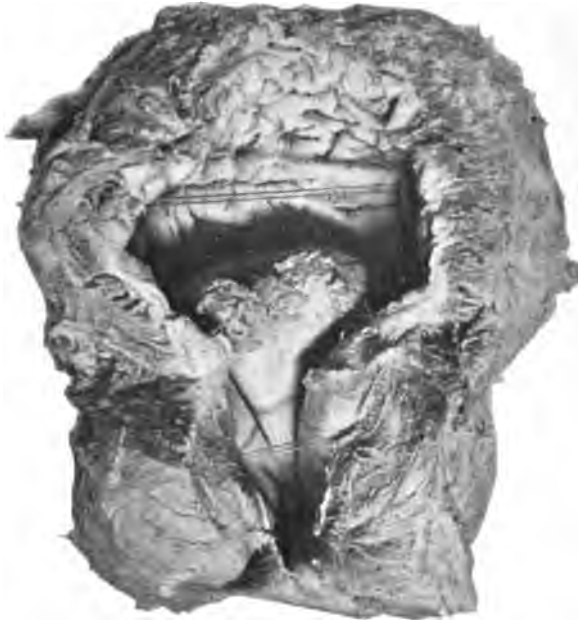

FIG. 602.—HYPERTROPHY OF THE PROSTATE.

But genuine adenomata may form both with and without hyperplasia of the connective tissue, muscle, and glands.

In partial hypertrophy there are circumscribed nodules of muscle tissue or of muscle and gland tissue. These are usually situated at the periphery of the organ and project into the bladder. They may become detached from the prostate, and be found as small, movable tumors beneath the mucous membrane of the bladder.

INFLAMMATION. (Prostatitis.)

Acute Exudative Inflammation of the prostate is induced by gonorrhoea, by injuries, or, more rarely, is independent. It may be acute or chronic. The gland may after a time return to its normal condition, or be gradu-

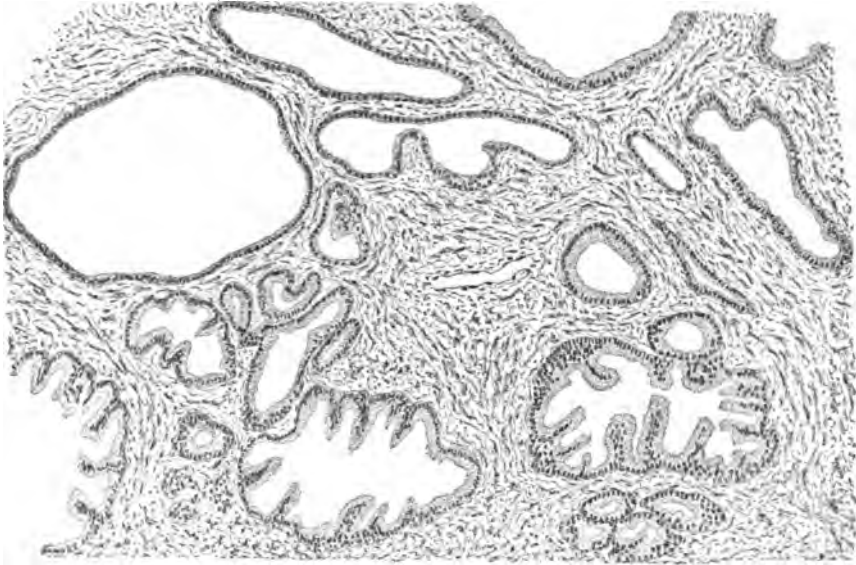


FIG. 603.—“HYPERTROPHY”—HYPERPLASIA—OF THE PROSTATE.
There is a glandular hyperplasia as well as hyperplasia of the fibro-muscular stroma.

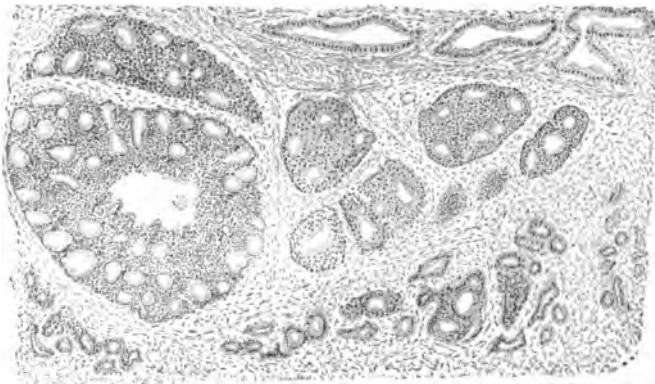


FIG. 604.—ADENOMA OF THE PROSTATE.

In the upper portion of the cut, at the right, are three nearly normal acini of the prostate, while the remainder shows various phases of new gland formation. The prostate, in addition to the circumscribed tumor growth, was the seat of the usual glandular and interstitial hyperplasia.

ally converted into a mass of fibrous tissue filled with abscesses. The abscesses may perforate into the bladder, urethra, vesiculæ seminales, rectum, or peritoneum. Or the inflammation may extend to the connective tissue of the scrotum or beneath the pelvic peritoneum. The pus may become thickened and cheesy, or even calcified.

Tuberculous Inflammation of the prostate usually accompanies a similar lesion of some of the other genito-urinary organs. Large cheesy masses are often formed, which may break down and open into the bladder or rectum.

TUMORS.

Sarcoma of the prostate has been described. **Adenoma** (Fig. 604) occurs either with or without an increase in the fibro-muscular interstitial tissue and gland hyperplasia.

Carcinoma is of occasional occurrence, and may be primary or secondary.

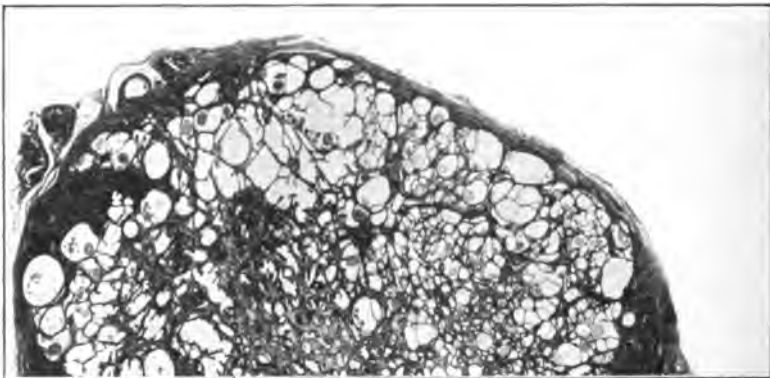


FIG. 605.—GLANDULAR HYPERPLASIA OF THE PROSTATE WITH CYSTIC DILATATION.
Some of the dilated glands contain corpora amylacea.

Cysts of the prostate (Fig. 605) are sometimes found either as a result of occlusion of the ducts by hypertrophy of the interstitial tissue, tumors, etc., or as a result of faulty development.¹

PARASITES AND CONCRETIONS.

Echinococcus of the prostate has been described, but is rare.

Concretions.—Small ovoidal or spheroidal, often brown or black bodies, having the characters of corpora amylacea (Fig. 606), are of very frequent occurrence in the alveoli of the prostate, particularly in old persons. We find a certain number of them in the prostate of nearly all old men, but they are sometimes present in great numbers. Larger, irreg-

¹ The occurrence of squamous epithelium in the ducts and sinuses of the prostate has been described see Schmidt, Ziegler's Beitr., Bd. xl., p. 120, 1906.

ular concretions, apparently formed by the coalescence or growth of the smaller ones, are less frequently found, and may be encrusted with lime salts. These concretions may give rise to ulceration of the ducts of the gland or to interference with the passage of urine, but usually they are of no practical importance.

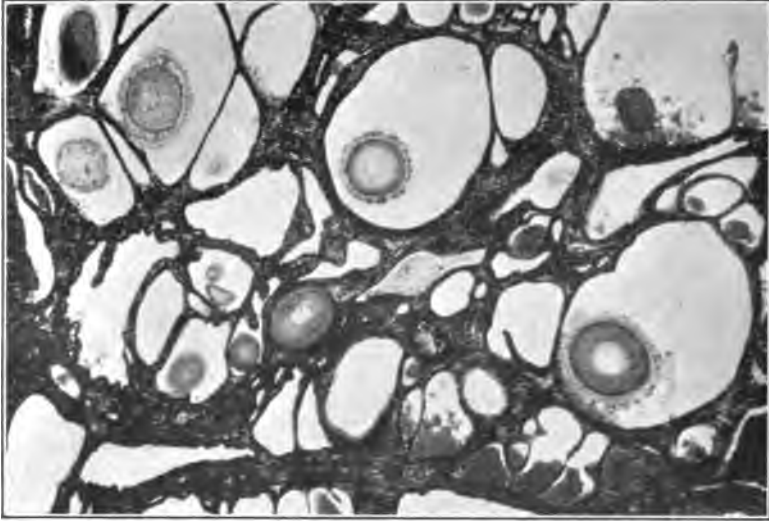


FIG. 606.—CORPORA AMYLACEA IN GLANDULAR HYPERPLASIA OF THE PROSTATE.

Cowper's Glands.

Inflammatory processes, acute or chronic, may occur in these organs in connection with urethritis or prostatitis. Abscesses may form; the glands, either in acute or chronic inflammation, may become enlarged and encroach upon the lumen of the urethra. *Retention cysts* formed by the closure of the excretory ducts may also project into the urethral canal.

The Male Mamma.

There may be an abnormal number of mammæ. In boys, at about the time of puberty, the mammæ may be swollen and inflamed or they may secrete milk. Cases are recorded in which adult males possessed large mammæ which secreted milk. The breasts may be enlarged from an increase of fat or of connective tissue.

Fibroma, sarcoma, cysto-sarcoma, myxoma, and various forms of **carcinoma**¹ may occur.

Cysts of the male breast are not very infrequent.

¹ For bibliography of carcinoma of the male breast see *Warfield*, Johns Hopkins Hosp. Bull., vol. xii., p. 305, 1901.

CHAPTER XII.

VOLUNTARY MUSCLE.

NECROSIS.

NECROSIS of muscle may be the local result of mechanical or chemical injury; it occurs in inflammatory foci, and may follow serious local disturbances of the circulation, as from pressure by tumors or cicatrices, etc. The muscle fibres may gradually lose their striations, become granular and disintegrate, or the muscle substance may become homogeneous and strongly refractile and break into irregular masses. Necrotic muscle fibres are finally removed by the direct action of phagocytes or after various transformations leading to their solution.

ATROPHY AND HYPERTROPHY.

Simple Atrophy.—This may occur in old age, in prolonged exhausting diseases, or as a result of pressure from a foreign body, tumors, etc. The muscle fibres grow narrower, the degree of narrowing frequently

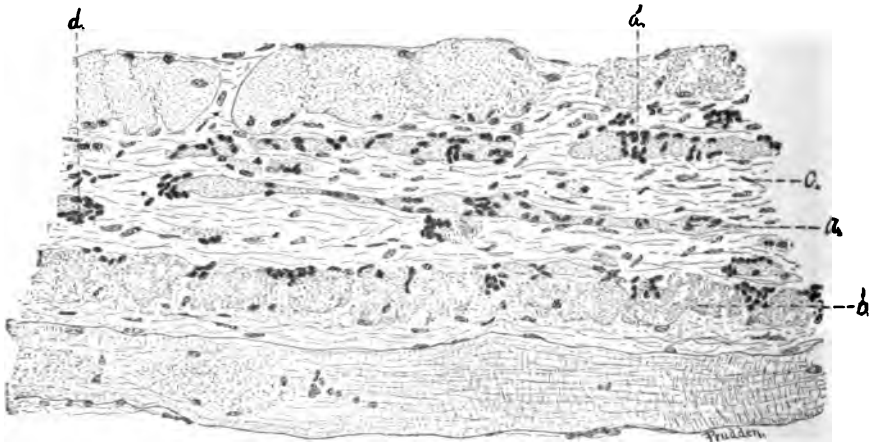


FIG. 607.—PROGRESSIVE MUSCULAR ATROPHY (Soleus muscle, longitudinal section).
a, Atrophied muscle fibre; b, degenerated muscle fibre; c, interstitial tissue; d, clusters of proliferated muscle nuclei.

varying considerably in different parts. They usually retain the striations, but these may be obscured by degenerative changes. The sarcolemma may become thickened, and there may be a considerable increase in connective tissue between the muscle fibres and bundles. Brown pigment particles may accumulate in the atrophied fibres.

Progressive Muscular Atrophy.—This lesion consists essentially in a combination of simple or degenerative atrophy of the muscle fibres with chronic interstitial inflammation, and is sometimes associated with proliferative changes in the muscle nuclei. In the earlier stages of the disease the muscles may be pale and soft, but exhibit otherwise to the naked eye but little alteration. Gradually, however, the muscle substance becomes replaced by connective tissue, so that in marked and advanced cases the muscles are converted into fibrous bands or cords, whose cicatricial contraction may induce great deformities.

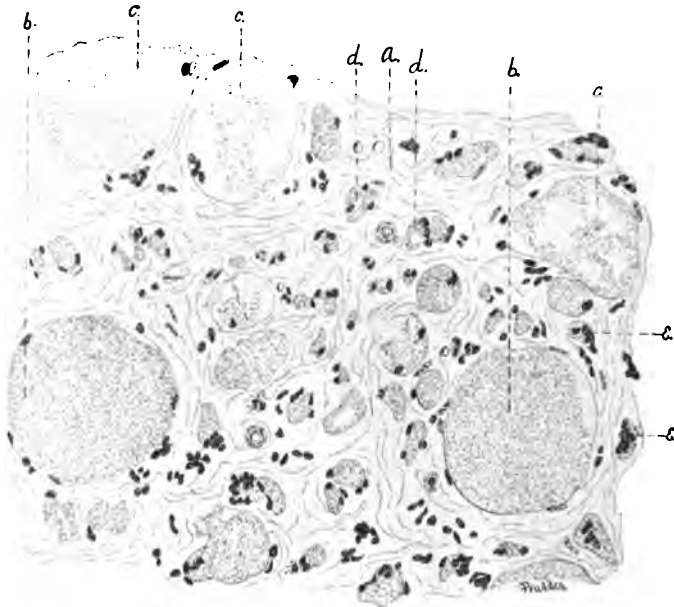


FIG. 608.—PROGRESSIVE MUSCULAR ATROPHY (Soleus muscle, transverse section).
a, Increased interstitial tissue; *b*, nearly normal muscle fibres; *c*, degenerated muscle fibres; *d*, atrophied muscle fibres; *e*, clusters of proliferated muscle nuclei.

Microscopical examination shows in the early stages of the disease a proliferation of cells in the interstitial tissue, so that this may have the appearance of granulation or embryonal tissue; also in some cases marked proliferative changes in the muscle nuclei (Fig. 607), leading to the formation of new cells which may more or less replace the contractile substance within the sarcolemma. The new interstitial tissue increases in quantity and grows denser, and may crowd the muscle fibres apart (Fig. 608). The walls of the blood-vessels may also become thickened. Hand-in-hand with these interstitial alterations the atrophy of the muscle fibres proceeds. These may simply grow narrower, retaining their striations; or they may split up into longitudinal fibrillæ, or transversely into discoid masses, and in this condition disappear. In other cases a certain amount of fatty or hyaline degeneration may be present. These

degenerative and proliferative changes do not, as a rule, occur uniformly in the affected muscles, but some parts are affected earlier and more markedly than others. The atrophied muscle may be replaced by fat.

Progressive muscular atrophy is apt to commence in the small muscles of the extremities, in many cases in the muscles of the ball of the thumb. It may commence in the muscles of the shoulder, the arms, or the back. It may have a continuous extension, or it may jump single muscles or groups of muscles. Death may be induced by the affection of the muscles of respiration or deglutition.

The causes of this lesion are in many cases unknown, and there is considerable lack of unanimity of opinion as to whether it is primarily a

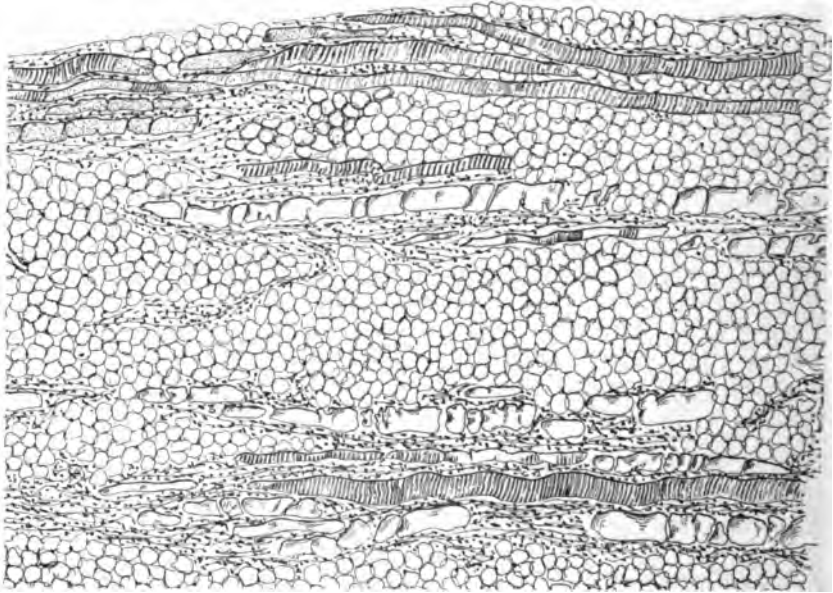


FIG. 609.—PSEUDO-HYPERTROPHY OF GASTROCNEMIUS MUSCLE (FATTY INFILTRATION).
The specimen is from the case mentioned on page 871, accompanying multiple neuroma.

disease of the muscles or of the nervous system. In a considerable proportion of cases the muscle lesion is associated with atrophy of the ganglion cells in the anterior cornua of the spinal cord and the development of connective tissue about them. See for the relationship between nerve lesions and special groups of muscle the chapter devoted to Diseases of the Nervous System. In other cases these changes in the cord may apparently be absent.

Muscle atrophy is sometimes accompanied by atrophy of the nerves which are distributed to the muscles, and atrophy of the anterior roots has been described.

It is probable that there are several varieties of progressive muscular atrophy, which our present knowledge does not enable us clearly to dis-

tinguish. Muscular atrophy in some cases follows overstraining of groups of muscles, or injuries, and may occur as one of the sequelæ of typhoid fever and diphtheria.

Hypertrophy.—True hypertrophy of muscle as a pathological condition is rare, but it has been described in a few cases. It is usually confined to circumscribed groups of muscles. On microscopical examination the diameter of the fibres is increased, sometimes considerably, though not uniformly. The transverse striation is unaltered and the muscle nuclei are in some cases enlarged. The cause of the change is unknown.

Atrophia Musculorum Lipomatosa (Pseudo-hypertrophy of the Muscles).—In some cases, hand-in-hand with the production of new connective tissue in the muscles and the atrophy of the muscle fibres, or after these changes have made considerable progress, there occurs a development of fat tissue between the fibres (Fig. 609) which may prevent any apparent diminution in the size of the muscles, or in some cases may even give them the appearance of a great increase in size. This condition is of most frequent occurrence in children, and is most apt to appear in the gastrocnemii muscles. In the upper extremities the deltoid and triceps are most frequently involved. The lesion may be symmetrical, affecting similar muscles on both sides of the body, or it may be unilateral. Parts of muscle bellies may be affected.

The cause of this form of atrophy is not definitely known. Various lesions of the spinal cord have been described as occurring with it; but, in many cases at least, alterations of the nervous system cannot be detected. The writer has described a case¹ in which this lesion was marked in the gastrocnemii in connection with multiple false neuromata.

DEGENERATION.

Albuminous Degeneration of striated muscle occurs as a mark of toxæmia in acute infectious diseases, and may lead to fatty degeneration.

Fatty Degeneration, with greater or less destruction of the muscles, may commence with a simple swelling and fine granulation of the fibres. As the process goes on, smaller and larger fat droplets appear in the contractile substance, which loses its striations and becomes friable, and may be entirely destroyed, leaving within the sarcolemma a mass of fatty detritus which may finally be absorbed and disappear. This alteration may occur in acute parenchymatous myositis in connection with various forms of atrophy, in prolonged exhausting diseases, and in phosphorus poisoning.

Fatty Infiltration of the muscle may occur in obesity and in alcoholics.

Hyaline Degeneration.—Under a variety of conditions the muscle fibres undergo a series of changes, leading to their conversion into a translucent, highly refractile material, somewhat resembling amyloid, but not giving its microchemical reactions, and apparently more nearly allied to hyaline material. The lesion in the muscle which we are considering is

¹ Prudden, *Am. Jour. of Med. Sci.*, July, 1880, p. 134.

often called *waxy degeneration*, from the peculiar appearances which the muscles present.¹ When the lesion is far advanced and extensive the muscles are brittle and have a grayish-yellow, translucent appearance. Microscopical examination of various stages of hyaline degeneration of muscle shows that the contractile substance of the fibres becomes at first swollen and granular, and gradually converted into hyaline material which may present the outlines of the swollen fibres, but is more frequently broken into larger and smaller shapeless clumps (Fig. 610), which may disintegrate and finally be absorbed. Hand-in-hand with these changes there usually occurs an increase in the interfibrillar connective tissue, and in certain cases there may be a proliferation of the muscle nuclei and a new formation of variously shaped cells within the sarcolemma which lead to the regeneration of the fibres. As a result of

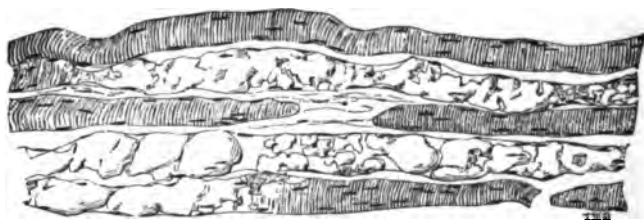


FIG. 610.—HYALINE DEGENERATION (SO-CALLED WAXY DEGENERATION) OF ABDOMINAL MUSCLE IN TYPHOID FEVER.

the brittleness of the degenerated muscles they are apt to rupture, and in this way hæmorrhage may occur.

This form of degeneration may occur in progressive muscular atrophy, in various infectious diseases, in trichinosis, with local inflammation, injuries, freezing, etc. It is, however, most marked and frequent in typhoid fever. In this disease the rectus abdominis and the abductors of the thigh are most frequently affected.

Experimental investigations have shown that, under certain conditions, very similar appearances may be produced in the muscles by post-mortem changes. Various changes—some of them necrotic—are at present included under the name “hyaline degeneration of the muscles.”

True **amyloid degeneration** is rare.

Hoën has described a peculiar degeneration with atrophy of the striated muscle of the uvula, in which a series of bleb-like structures form along the fibres, which they may finally replace.²

Calcification of muscle is of rare occurrence.

Serous or Hydropic Infiltration of muscle fibres occurs under various conditions in association with other lesions. Larger and smaller spaces filled with clear fluid are present between the fibres and often over small areas largely replacing them. Such fluid-filled spaces are often called vacuoles.

¹ For a study of the so-called waxy or Zenker's degeneration of muscle see *Thoma, Virch. Arch., Bd. clxxxvi., p. 64, 1906.*

² *Hoën, Jour. Exp. Med., vol. iii., p. 549, 1898.*

INJURIES, HÆMORRHAGE, AND INFARCTION.

Wounds and Rupture.—When the muscle fibres are severed by wounds or rupture there is more or less degeneration of the divided fibres, and the wound may heal by the production of granulation tissue, which gradually becomes converted into cicatricial tissue, thus binding the severed parts together. In some cases there is a moderate new formation of muscle fibres (see p. 70). When the wound does not gape, so that the severed ends are not much separated, there may be, it would seem, a direct re-establishment of muscular continuity by new development of muscle, without the formation of much new connective tissue.

Hæmorrhage.—This may occur as a result of mechanical injury; from rupture of the fibres by convulsive contraction, as in tetanus; or it may occur when the muscle fibres are degenerated, as in typhoid fever; or in connection with certain general diseases, as scurvy, purpura, hæmorrhagic diathesis, septicæmia, etc. The blood is usually readily absorbed.

Embolic Infarction of Muscles in connection with heart disease has been described in a few cases, but it is rare.

INFLAMMATION. (Myositis.)

Suppurative Myositis.—In the early stages of this lesion the muscle is hyperæmic and œdematous, and the interstitial tissue more or less infiltrated with small spheroidal cells. If the inflammation becomes intense there may be an excessive accumulation of pus cells, either diffusely in the interstitial tissue or in larger and smaller masses. Hand-in-hand with this cell accumulation occur degenerative changes in the muscle fibres. By pressure their nutrition is interfered with and they undergo granular, fatty, or hyaline degeneration and necrosis. They may completely disintegrate; or gangrene may occur, so that larger and smaller masses of the infiltrated muscle tissue become soft, foul-smelling, and converted into a mass of detritus in which but little muscle structure can be detected and which is intermingled with bacteria. In other cases there may be larger and smaller abscesses formed in the muscle, the muscle tissue itself degenerating and disintegrating and mixing with the contents of the abscess, or being pressed aside and undergoing atrophy and degeneration. In some cases, when the formation of pus is moderate in amount, there may be restoration by formation of granulation tissue between the muscle fibres. This becomes gradually dense and firm, and leads to more or less atrophy of the muscle fibres by pressure.

Acute suppurative myositis may accompany wounds; it is very common in acute phlegmonous inflammations of the skin and subcutaneous tissue, and often accompanies acute infectious diseases, such as pyæmia, erysipelas, etc. In most cases the "pyogenic" cocci are present in the inflammatory foci. Suppuration not infrequently occurs in the muscles adjacent to the inflamed mucous membranes in diphtheria.

Chronic Interstitial Myositis.—In this lesion there is a new formation of connective tissue between the muscle fibres or bundles of fibres. This

new tissue is sometimes very cellular, resembling granulation tissue, and this probably represents an early stage of the disease. In other cases (Fig. 611) dense cicatricial tissue crowds the muscle fibres apart, inducing atrophy in them, and sometimes leading to their complete destruction. This lesion, the analogue of chronic interstitial inflammation of the internal organs, may occur in muscles which are adjacent to other parts

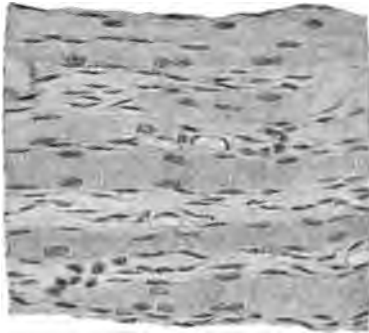


FIG. 611.—CHRONIC INTERSTITIAL MYOSITIS.

which are the seat of chronic inflammatory processes. It may occur in muscles which are not used. The new formation of fibrous tissue seems in some cases to be secondary to atrophy of the muscle fibres. In this case it would more appropriately be called *replacement fibrous hyperplasia*.

Primary Acute Polymyositis.—

Several observers¹ have described an affection involving swelling of the muscles of the tongue, back, and extremities, with local pain and fever. Voluntary movement is lost, and various rashes of the skin may occur.

The muscles are brownish red in color, with yellowish spots, hæmorrhages and foci of hæmorrhagic exudates. There is degeneration of the muscle fibres. The disease may become chronic and may be fatal. It is believed to be due to some form of auto-intoxication and may be associated with some infective focus in the body.

Myositis Ossificans.—Under conditions and for reasons which we do not understand, there occasionally occurs, usually in young persons, a new formation of bone in the interstitial tissue of muscles, and in tendons, ligaments, fasciæ, and aponeuroses. This sometimes apparently starts as outgrowths from the periosteum, sometimes not. The bone formations are apt to commence about the neck and back, and may become very widespread over the body. So far as the muscles are concerned, there is usually an increase of connective tissue between the fibres and bundles, in which new bone is formed, usually in elongated and sometimes in spicula-like masses. The muscle fibres undergo secondarily a greater or less degree of atrophy or degeneration. There may be fatty infiltration between the fibres, and various deformities are produced by the shortening and progressive immobility of the affected parts.

While the above disease is a progressive and frequently a general one, there may be new formation of bone in muscle as a result of prolonged or repeated mechanical irritation. Thus in the adductors of the thigh in persons who are constantly in the saddle, or in the deltoid muscle of soldiers who strike this part with their weapons in drill, there may be a formation of bone.²

¹ See v. Strümpel, *Deutsch Zeits. f. Nervenkr.* i., 479, 1891.

² Consult for a study of myositis ossificans *De Will*, *Am. Jour. Med. Sci.*, vol. cxx., p 295, 1900, bibl.

Tuberculous and Syphilitic Inflammation in the muscle is of occasional occurrence; the active processes are in the connective tissue and blood-vessels, the muscle fibres being secondarily involved in various phases of atrophy and degeneration.

TUMORS.

Tumors of muscles usually develop in the connective tissue. **Fibroma, chondroma, lipoma, myxoma, sarcoma, angioma,** may occur as primary tumors. **Carcinoma** and **sarcoma** may occur secondarily in the muscles as a result of local extension from adjacent parts.

Rhabdomyoma has been described. **Teratomata** and **dermoid cysts** are recorded in various parts of the body.

The muscle fibres are, as a rule, only secondarily affected by pressure, etc., in tumors of the muscles, but there exist observations which point to the possibility of a proliferation of the muscle nuclei and the new formation from them of cells which may take part in the growth of the tumor.

PARASITES.

Trichina spiralis is the most common parasite in the muscles. **Cysticercus cellulosæ** and **echinococcus** occasionally occur.

CHAPTER XIII.

THE BONES AND JOINTS.

The Bones.

General Considerations.

It is not possible to understand the changes which the bones suffer under various abnormal conditions unless one hold in mind the physical peculiarities of this form of connective tissue and the ways in which the dense and solid structure is formed and dissolved and re-formed in the processes of development and growth.

The striking character of bone, adapting it to serve as the supporting framework of the body, is the association with its organic tissue of the inorganic salts to which its hardness and solidity are due. But it is through connective tissue and blood-vessels and under the agency of highly specialized connective-tissue cells—*osteoblasts*, the “bone-builders,” and *osteoclasts*, the “bone-destroyers”—that bone is formed and during development ceaselessly remoulded.

The general pathological processes to be observed in bone are fundamentally similar to those in the soft tissues of the body. Disturbance of circulation, necrosis, degenerations, inflammation, tumors, etc., are common. But their manifestations are modified and often complicated and obscured in part by the hardness of texture and durability of bone tissue, but especially by the frequent participation in the processes of the osteoblasts and osteoclasts. Thus it is that many abnormalities of the circulation and their sequelæ are less obvious than in other parts of the body; necrosis is masked by appearances due to the inorganic elements; while many of the inflammatory processes and tumors are regularly associated with the formation of new bone in such mass and measure as often to distort the bone and greatly complicate the picture.

We have seen repeatedly, in studying the lesions of the viscera, that the primary pathological processes are modified by the tissues in which they are active. Attention is called to this feature in bone only because the regional modification is here so conspicuously marked that one is liable to lose sight of the unity of the fundamental processes and erroneously to conceive that the pathology of bone is a subject especially obscure, complex, and difficult.

ATROPHY.

In old age or in senile conditions the bones may become atrophied by the absorption of the hard tissue; the medullary spaces are enlarged, the marrow tissue contains less fat and is often gelatinous in appearance. As the result of the lack of use, or from any cause which interferes with the nutrition, of the bone, such as paralysis of the muscles or diseases of the joints, the bones may atrophy. In connection with atrophy there may be an ossifying periostitis, which results in making the bone look even larger than normal. Many of the conditions commonly called atrophy, such as the erosions of bones from tumors, etc., pressing upon them, are really due to a rarefying osteitis.

The bones, sometimes as the result of atrophy and sometimes from

causes which we do not understand, are unusually brittle and liable to fracture. This disposition is sometimes hereditary.

DISTURBANCES OF CIRCULATION.

Hyperæmia.—The evidences of this condition are most marked to the naked eye in the periosteum and marrow, particularly the latter. It should be remembered that the color of the marrow varies considerably under normal conditions, depending upon age and situation. In the bones of the fœtus and new-born, and near the areas of ossification in the young, the marrow is normally red in color. In adults the marrow of the sternum, vertebræ, and to a certain degree that of the ribs, pelvic and cranial bones, and the cancellous tissue of the ends of the long bones, is red or reddish in color. But most of the marrow, particularly in long bones of the extremities, is of a yellowish color from the presence of fat cells. In old age the marrow of all the bones is apt to become pale, and to assume a more or less translucent or gelatinous appearance.

Hyperæmia usually occurs as an accompaniment of inflammatory processes in the bone, and, when marked, the periosteum is swollen and red; the compact bone tissue may appear of a pink color, while the marrow, either by an increase in the amount of blood or absorption of its fat, or both, may be of a uniform dark red color or mottled with red and reddish yellow.

Hæmorrhage.—This may be due to wounds and injuries and to inflammatory and necrotic processes; and small hæmorrhages often accompany scurvy, purpura, hæmorrhagic diathesis, and leukæmia. Clots of considerable size between the periosteum and bone may lead to serious consequences, by cutting off the blood supply to the superficial layers of bone and thus inducing necrosis. But when not infected through contact with the air or by micro-organisms brought in the circulatory channels, they are not usually of serious import, and are readily absorbed. The smaller hæmorrhages of the medulla are not usually of much importance. The decomposition of the extravasated blood may lead to extensive pigmentation of the marrow.

HEALING OF WOUNDS AND FRACTURES OF BONE.

The process of healing in bone after fracture is, when uncomplicated, at first similar to that in ordinary healing by second intention in fibrous tissue. The blood and other exudates and the tissue detritus are gradually absorbed or disposed of by phagocytes. By a proliferation of connective-tissue cells of the region a larger or smaller mass of granulation tissue is formed. This granulation tissue does not at first differ in appearance from similar tissue formed elsewhere in the body in the reparative phase of exudative inflammation.

But soon, under the influence of the specially endowed cells of cartilage or bone or periosteum, but especially of the latter, the granulation tissue becomes partially replaced either by cartilage or by a substance

resembling bone in general appearance but containing no lime salts. This is called *osteoid* tissue. These new cartilaginous and osteoid tissues, which are apt to occur together, form irregular masses or interlacing trabeculae in the stroma of granulation tissue. This constitutes the so-called callus of a uniting fracture (Fig. 612).

Gradually the osteoid tissue becomes osseous, and the masses of cartilage and bands of periosteal and other fibrous tissue, under transformations practically identical with those seen in normal development, are

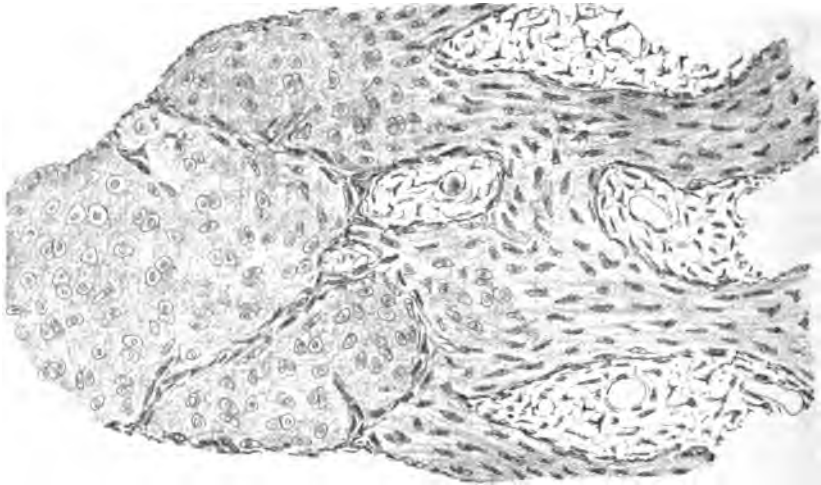


FIG. 612.—NEW-FORMED CARTILAGE AND OSTEOID TISSUE FROM CALLUS AFTER FRACTURE OF THE FEMUR.

converted into bone. Thus by gradual absorption and re-formation of bone in the usually redundant provisional bony mass, and by the re-adjustment of its vascular channels, the healing, with more or less permanent deformity, is accomplished (Fig. 613).

If the conditions be not favorable, the healing of fractures may occur only by fibrous-tissue formation, so that so-called "false joints" may result. The healing of other injuries and losses of substance occurs by a process similar to that described in Fractures.

INFLAMMATION.

The periosteum, bone tissue, and marrow are so intimately connected that in most cases they all share to a greater or less degree in the pathological alterations of the bones. But as sometimes one, sometimes another is most markedly involved, it is convenient to consider separately here the inflammatory changes by which they are respectively affected.

PERIOSTITIS.

Exudative inflammation in the periosteum is essentially similar to this form of inflammation in other parts of the body, except as it is

modified by the relationships of the connective tissue and blood-vessels to the hard bone and by the presence and performances of the osteoblasts and associated cells peculiar to bone.

We may distinguish several forms of periosteal inflammation.

Simple Exudative Periostitis.—This is apt to occur in children and ill-nourished persons after comparatively slight injuries or from unknown causes. The periosteum is thickened, succulent, congested, and more or less abundantly infiltrated with leucocytes. It becomes less firmly adherent to the bone, and the cells of the inner layers are increased in number. This form of inflammation may terminate in resolution, or it may lead to other phases of inflammation.

Suppurative Periostitis may begin as a simple or as a purulent inflammation. The pus is formed in the inner layers of the periosteum, and between it and the bone. The outer layers of the periosteum may for a long time resist the suppurative process. The accumulation of pus may dissect up the membrane from the bone and leave the latter bare. The pus thus formed may remain in this position for a long time, or be absorbed, or become dry and cheesy, or it may burst through the periosteum and lead to abscesses in the soft parts. The bone, if separated from its nutrient membrane, may remain unchanged, but more frequently necrosis or inflammation of the bone itself is set up. Such a periostitis may run an acute or a chronic course.

Sometimes suppurative periostitis takes on a very malignant character. Pus is developed not only beneath, but in the periosteum, forming abscesses filled with foul pus. The periosteum breaks down into a gangrenous, foul-smelling mass, and the same change may affect the neighboring soft parts. The medulla may take part in the process and break down into a purulent, gangrenous mass. Hæmorrhages may complicate the process. The lymph-nodes are enlarged and swollen; abscesses may form in different parts of the body, and the patient may die with the symptoms of pyæmia. The Streptococcus and

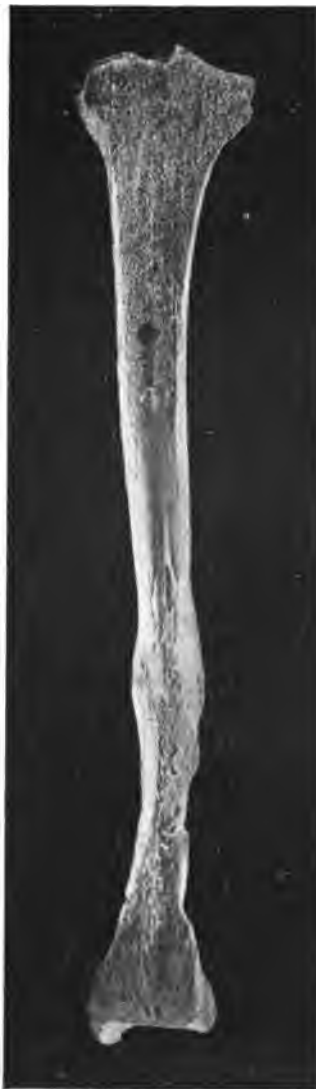

FIG. 613.—HEALED BONE AFTER FRACTURE.
Shows redundant hard bone about seat of fracture.

Staphylococcus pyogenes are the most common excitants of suppurative inflammation.

Fibrous Periostitis.—This is a chronic form of inflammation, resulting




FIG. 614.—OSSIFYING PERIOSTITIS.

An irregular layer of new bone is forming between the periosteum and the old bone.

in the development of new connective tissue in the periosteum, which becomes thickened and dense and usually adherent to the bone. It may accompany necrosis, chronic arthritis, chronic ulcers of adjacent soft




FIG. 615.—OSSIFYING PERIOSTITIS—TIBIA.

Large exostoses at the end of the bone. The process involves the joint, and the bone is enlarged.

parts, etc., or follow simple acute periostitis. It may in many instances be regarded as a conservative process of a reparative character.

Ossifying Periostitis results in the formation of new bone from the inner layers of the periosteum. The masses of new-formed bone, called

osteophytes, are of variable shape. They may form a thin, velvet-like, villous layer (Fig. 614); or they are little spicula; or form larger, rounded masses (see Figs. 615, 616), or a thick, uniform layer extending over a large part of a bone. They may have at first a loose, spongy character, and be loosely connected with the old bone. But layers of compact bone tissue are formed within their medullary spaces, which are thus gradually filled, and they join the old bone so that they may finally become as compact as or even more compact and dense than normal bone to which they are firmly joined. The hyperostoses and exostoses thus formed may remain indefinitely, or they may gradually become smaller and finally disappear by absorption.

The formation of new bone in osteophytes, or in dense masses beneath and in the periosteum, occurs as a result of the same process by which

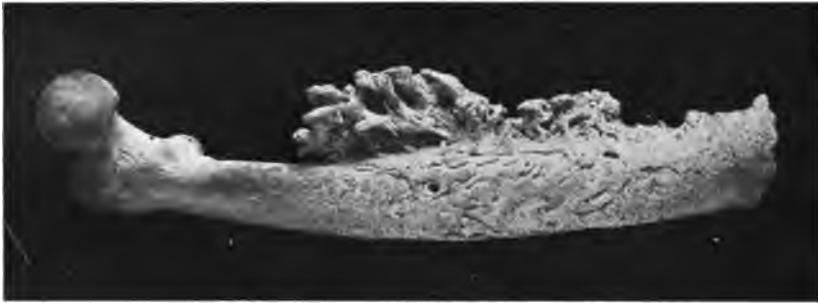

FIG. 616.—OSSIFYING PERIOSTITIS WITH LARGE EXOSTOSES—FEMUR.

A large part of the shaft is thickened and covered with ragged platelets of new-formed bone, while above large rough exostoses project. This bone has been the seat of rarefying and formative osteitis.

bone tissue is normally formed. Certain large cells, called *osteoblasts*, which are developed along the blood-vessels, possess the power of depositing osseous basement substance about themselves and so forming bone. Pathological new formation of bone differs from the normal mainly in the conditions under which it occurs. The blood-vessels around which the pathological bone develops, which grow out of the old vessels, as in the formation of granulation tissue, are irregularly arranged and subject to a variety of abnormal nutritive and mechanical conditions, so that the new bone is usually formed, not in a series of definite systems of lamellæ, but, as above described, in a series of irregular spicula or masses. Moreover, as will be seen further on, the conditions under which it is formed being liable to change, and itself serving no definite purpose in the economy, as does normal bone, pathological new bone is often an evanescent structure. The details of its disappearance will be considered below.

Syphilitic Periostitis.—Syphilitic infection may excite simple, purulent, fibrous, or ossifying periostitis. In addition to these, gummata (see p. 273) may be developed in the periosteum in long bones, most frequently on the shaft, where they cause a more or less fusiform enlargement. The

bone tissue is usually more or less involved. The gummata may be absorbed or undergo cheesy degeneration, or be converted into fibrous tissue, or they may suppurate.

Tuberculous Periostitis.—In badly nourished persons, particularly in children suffering from scrofula, chronic purulent periostitis is frequently associated with the formation of miliary tubercles. Abscesses are apt to form in and about the periosteum, and when these are evacuated gran-

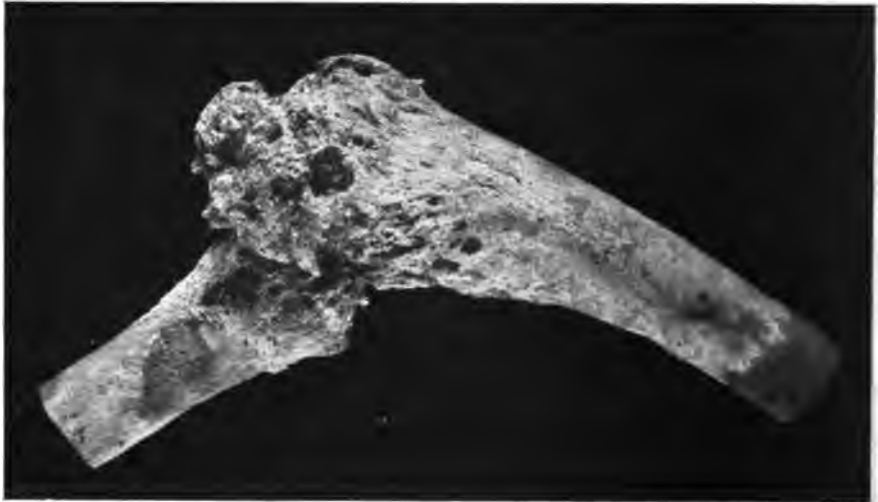

FIG. 617.—TUBERCULOSIS OF THE JOINT.
Shows caries with extensive destruction of the bone.

ulation tissue may develop, which contains miliary tubercles. The bone is apt to be involved to a greater or less extent in simple inflammatory changes or caries (Fig. 617).

OSTEITIS.

Inflammation in bone tissue is dependent upon the same general conditions and presents essentially the same series of phenomena as inflammation in other kinds of connective tissue. But it is variously modified in detail by the peculiar dense and unyielding character of the basement substance, and by certain peculiarities of the blood supply and the nutritive conditions under which the cells are placed. In simple exudative inflammation the same series of phenomena occur in connection with the blood-vessels as in other tissues, resulting in the production of serum, fibrin, and pus; but the extent to which these changes occur is limited and constantly associated with striking alterations in the basement substance. It is these secondary alterations in the basement substance which lend to inflammations of the bone their most peculiar characters, and in the prominence which these assume the fundamental alterations

are often overlooked. The most common of these secondary alterations are the absorption of the hard basement substance of the bone and its replacement by, or conversion into, young cellular forms of fibrillar connective tissue or marrow tissue, and the new formation, in a more or less typical manner, of new bone. The active phenomena of inflammation in bone are processes of the blood-vessels and the fibrillar connective tissue as in other parts of the body, the hard bone substance being in a certain sense only secondarily involved.

As a result of these changes the bone in simple inflammation becomes more vascular, and, with an increase of spaces filled with granulation or marrow tissue, more porous at the expense of the dense basement substance. Or the new-formed spaces or the marrow cavities may be constantly encroached upon by the new-formed bone lamellæ on their walls, so that the bone becomes more compact. Or, as is frequently the case, both series of changes occur either simultaneously in different regions, or follow each other, or are variously associated together. Very frequently one or the other of the opposing forms of alteration predominates, or one may occur to the exclusion of the other, and we thus have two prominent forms of inflammation, which are called *rarefying osteitis* or *osteo-porosis*, and *condensing osteitis* or *osteo-sclerosis*. The exact nature of the conditions under which in one case the bones become more, in another less dense, we do not understand. Nor is the exact way in which the osteoclasts dissolve hard bone, or the osteoblasts secure and deposit inorganic salts and become bone cells as yet clear. Furthermore, more or less characteristic forms of inflammation may occur in syphilitic and tuberculous infection—*syphilitic* and *tuberculous osteitis*. Suppurative osteitis may further complicate the process.

In addition to these phases of inflammation in bone, and in frequent and varied association with them, there are alterations leading to death and destruction of bone tissue in greater or less amount, which are called *caries* and *necrosis*. Finally, any of these forms, and commonly several of them at once, are variously associated with more or less marked inflammatory or degenerative alterations of the periosteum on the one hand, or the marrow tissue on the other, or of both combined.

Rarefying Osteitis consists essentially in the formation in the marrow spaces, Haversian canals, or beneath the periosteum, of new, very cellular and vascular tissue, resembling granulation of young marrow tissue, under whose influence the basement substance of the bone is absorbed. This absorption of the bone takes place largely as bone is absorbed in normal growth, namely under the influence of certain large cells, which are grouped around the blood-vessels. If a thin section of bone which is undergoing absorption be examined (Fig. 618), the edges of the bone which border on the vascular surfaces are found irregularly indented by deep or shallow depressions, sometimes simple, sometimes quite complex. These are called *Howship's lacunæ* and are usually filled or lined by larger and smaller granular, frequently multinuclear cells—the so-called *osteoclasts*. In the larger lacunæ there may be granulation tissue with loops of blood-vessels, with or without osteoclasts. Under the influence of the

osteoclasts or of the new vascular tissue, the bone is gradually absorbed.

On the other hand, there may be irregular branching channels through the bone across the lamellæ, which appear to be due to the enlargement and coalescence of the lacunæ and canaliculi, without the direct influence of blood-vessels or other cells than the fixed cells of the bone.

The tissue which replaces the absorbed bone may be very rich in small spheroidal cells, or it may be more or less fibrillar.

As a result of this process irregular islets of bone tissue may be entirely separated from adjacent bone and surrounded by a more or less

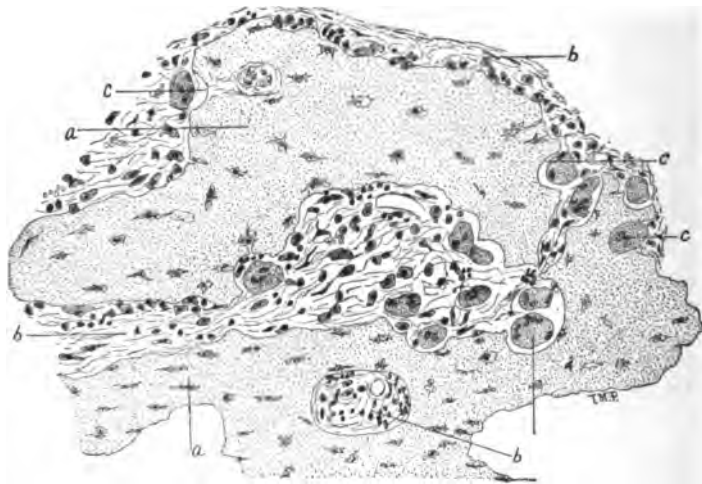


FIG. 618.—RAREFYING OSTEITIS IN ULNA OF CHILD.

a, Isolated bone fragment with rough edges; *b*, marrow tissue; *c*, Howship's lacunæ with osteoclast.

fibrillar vascular tissue; this is most apt to occur in the cancellous tissue. Or the originally compact bone may become traversed by a series of larger and smaller irregular branching, communicating channels with ragged walls. These progressive alterations may cease, and be succeeded by a new formation of bone along the edges of the channels or cavities.

Rarefying osteitis may occur as an independent process from unknown causes; it is often associated with scrofula, with diseases of the joints, with fractures or other injuries to the bone; it often forms a predominant feature in tuberculous inflammation of the bones. It is chiefly by a rarefying osteitis that bone tissue is eroded and destroyed in the vicinity of tumors, aneurisms, etc., which exert pressure on the bones. By the same process the sharp ends of fractured bones may be rounded off as healing proceeds.

When this form of inflammation occurs in cancellous bone tissue the marrow is red or gelatinous, and the bony septa may disappear altogether, so that in extreme cases there may be, instead of cancellous bone, a mass of granulation tissue. When the process occurs in the articular extrem-

ity of a bone the granulating medulla may send little offshoots through the articular cartilage. These may become fused together and inflammation of the joint may follow. The walls of the shafts of the long bones may be converted into spongy tissue. If, as is sometimes the case, an ossifying periostitis occurs at the same time, the bone is thickened but spongy; or sometimes there are concentric layers of compact bone tissue, separated by rarefied bone.

Condensing Osteitis (Osteo-sclerosis).—This lesion is characterized by the new formation of bone in the walls of the marrow cavities or Haversian canals. The bone is formed under the influence of the blood-vessels and osteoblasts, as in normal bone formation, but with less regularity. It may result in the conversion of cancellous tissue into compact bone, in the filling up of the medullary cavity of long bones with more or less dense bone tissue. The compact bone, owing to the filling of its Haversian canals, may become very dense and ivory-like. When the medullary

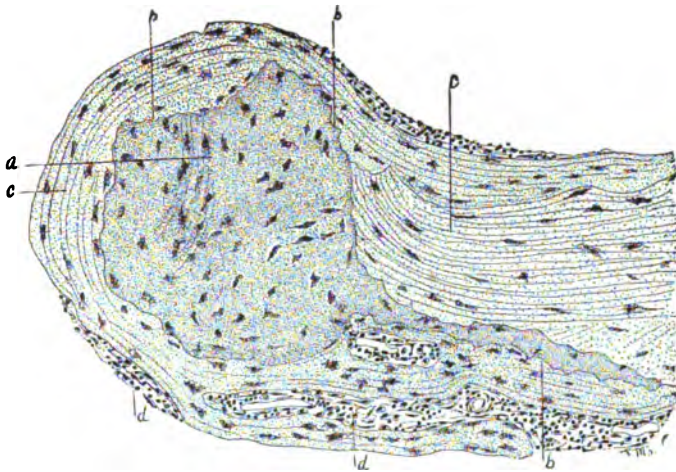


FIG. 619.—CONDENSING OSTEITIS, OR OSTEO-SCLEROSIS, IN ULNA OF CHILD.

a, Fragment of old bone with roughened, sinuous edges; *b*, old Howship's lacunæ covered with more recently formed bone lamellæ; *c*, *d*, new Haversian canals.

cavities of long bones are involved the yellow marrow is converted into red marrow by the absorption of fat and increased vascularity.

Osteo-sclerosis is frequently associated with ossifying periostitis. It often follows rarefying osteitis, and then the Howship's lacunæ resulting from the original absorption process may be filled and covered in with new bone lamellæ (Fig. 619). It is apt to occur in connection with necrosis or chronic inflammation of adjacent soft parts, and is then a reparative and conservative process, but it sometimes occurs independently under unknown conditions.

Suppurative Osteitis (Abscess of Bone).—This process occurs usually in the ends of the long bones, and is associated with rarefying osteitis. As

the bone tissue is absorbed, a circumscribed cavity may be formed in the bone, filled with pus and lined with granulation tissue.

Less frequently abscesses are formed in the shaft of a long bone by circumscribed suppuration of the medulla. Such abscesses may occur in old people and may be of long duration. They may gradually enlarge and be accompanied by an ossifying periostitis, so that the bone is expanded. The abscesses in suppurative osteitis sometimes develop rapidly and may perforate. On the other hand, instead of abscesses, there may be a diffuse infiltration with pus of the Haversian canals or of the spaces formed by rarefying osteitis (see Osteomyelitis, below.)

Osteomyelitis.—The tissues of the medulla so frequently share in the inflammatory processes in bone that many conditions described as osteitis are really osteomyelitis. It is customary, however, to reserve the latter name for those cases in which the medulla is primarily or chiefly involved.

ACUTE INFECTIOUS OSTEOMYELITIS.—This may occur as the result of a local injury which permits the access, or favors the development, of pyogenic micro-organisms; it may be metastatic, resulting from the transportation of infectious material from other parts of the body in septicæmia and pyæmia, in typhoid fever, in the exanthematous fevers, and under other conditions; or it may occur without evidence of local predisposition or of infectious processes in other parts of the body.

The lesions of acute infectious osteomyelitis are, in the large majority of cases at least, due to the presence and action of the pyogenic cocci, the *Staphylococcus pyogenes* and the *Streptococcus pyogenes*, and in many of its forms it may be regarded as one of the phases of septicæmia or septico-pyæmia.

While the lesions vary widely, the following general description is applicable to a considerable proportion of the cases:

At the commencement of the disease, which usually begins in the shaft of one of the long bones, there are hyperæmia and œdema of the medulla, so that if the bone be opened the marrow is soft and of a dark red color. A diffuse suppuration now rapidly ensues, and the marrow becomes streaked or mottled with gray. Occasionally, though not often, larger and smaller abscesses may form in the marrow. The inflammatory areas may be circumscribed; or, in the more malignant cases, the entire marrow may become rapidly involved. The cancellous tissue of one or both of the epiphyses usually becomes affected. The disease, however, is not commonly confined to the medullary spaces. The periosteum becomes œdematous and infiltrated with pus, and the surrounding soft parts may become the seat of intense inflammatory changes. Abscesses of the periosteum or surrounding tissues are apt to form. As a result of these changes, necrosis of greater or less portions of the bone may ensue with the formation of larger or smaller sequestra (see p. 890). The medullary cavity may become enlarged as pus accumulates, and the wall of the bone may be broken through, permitting the discharge of pus outward. Sometimes several bones are involved at once. Secondary involvement of the joints is very frequent. Here there may be only a serous or purulent exudation; or the acute and destructive inflammatory

process may extend beneath the joint and produce extensive alterations. In young persons the epiphyses very frequently become separated from the shaft by the destruction of the cartilage which binds them together.

In the severer cases, which are often called, *par excellence*, malignant osteomyelitis, the changes may be very rapid and destructive. The medulla is disintegrated and gangrenous; the joints are soon involved; necrosis of large portions of the bone, sometimes of the whole shaft, occurs, the periosteum and surrounding parts become gangrenous; the veins contain thrombi, and pyæmic infarctions and abscesses may form in various parts of the body.¹

CHRONIC OSTEOMYELITIS.—In prolonged cases of osteomyelitis there is apt to be more or less ossifying periostitis and osteo-sclerosis, and fistulæ may form in the bone, through which the exudates are discharged.²

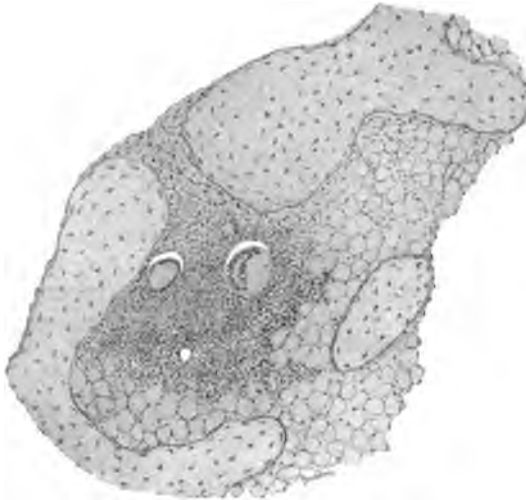


FIG. 620.—TUBERCULOSIS OSTEITIS.

A miliary tubercle formed in the cancellous tissue near the joint in tuberculous arthritis.

Tuberculous Osteitis is primarily a tuberculous inflammation of the soft parts of bone with associated rarefying and formative processes in the hard bone. The tubercles are sometimes small and scattered (Fig. 620), sometimes they unite to form larger foci or large diffuse caseous masses. There may be extensive involvement of the medulla. Rarefying and condensing osteitis and necrosis often accompany the tuberculous process. Thus the bone frequently becomes spongy or fragile (Fig. 617). Much of the new tissue formed in tuberculous of the bones is simple granulation tissue or fibrous tissue of reparative character.

¹ Consult for an elaborate treatment of acute osteomyelitis in its relationship to other forms of inflammation, with bibl., *Jordan*, Beitr. z. klin. Chir., Bd. x., p. 587. For a study of this condition in childhood see *Koplik* and *Van Arsdale*, Am. Jour. Med. Sci., vol. ciii., pp. 422 and 535, 1892.

² For a résumé of the deformities resulting from osteomyelitis consult *Park*, Medical Record Nov. 2, 1895.

Not infrequently an exudative inflammation occurs with the formation of the so-called cold abscesses. This abscess formation in bone as well as in soft parts may be due to the tubercle bacillus alone. But concurrent infection of tuberculous areas often takes place, the pyogenic or other organisms gaining access to the involved region either through the blood channels or by surface openings, fistulæ, sinuses, etc.

Tuberculous inflammation is most frequent in early life and, save for the smaller bones, such as the phalanges, metacarpal, metatarsal, it rarely involves the shafts of bones.¹ It is often associated with tuberculous involvement of the joints (Fig. 617).

Syphilitic Osteitis.—*Syphilitic infection* may lead to one or other of the forms of osteitis just described, or gummatous nodules may form. Syphilitic osteitis usually commences in the periosteum, which becomes thickened and infiltrated with cells, so that there may be a circumscribed thickening of the periosteum, with or without distinct gummata. The vessels which extend from the periosteum into the bone become surrounded by new cellular tissue, which causes an enlargement of the canals. At this stage, if the periosteum be stripped off, it drags with it the vessels surrounded by the new cell growth, leaving the bones beneath with numerous small perforations extending inward. As the disease progresses the channels in the bone enlarge by a rarefying osteitis and coalesce, forming large, irregular defects filled with new fibrous tissue. In these masses of new tissue, cheesy degeneration may occur, so that the new growth has more or less of the character of a gumma. In the vicinity of these gumma-filled spaces a condensing osteitis may occur, both in the substance of the bone and on the surface, in the form of osteophytes, so that the opening in the bone may be surrounded by an elevated, irregular ring of bone tissue. All this may occur beneath the uninvolved skin, or the skin may participate by a suppurative inflammation, resulting in ulceration. These processes may be circumscribed or involve a large part of a bone. It is not infrequently associated with necrosis of larger and smaller portions of bone. The syphilitic tissue may be absorbed and its place be more or less filled with fibrous tissue. Syphilitic osteitis is most frequent in the cranial bones, but may occur elsewhere, as in the sternum, clavicle, tibia and fibula, the ribs, etc.

Congenital Syphilis.—The bones of young children in this condition may show increased density or evidences of periostitis, or irregular thickenings, particularly of the skull. Characteristic lesions are frequently found in the long bones in still-born or young children who are the victims of hereditary syphilis. These lesions are found for the most part along the border zone between the epiphysis and diaphysis. In normal ossification of the long bones, the border line between the calcification and ossification zones is narrow, sharply defined, and straight, or lightly and evenly curved. In the syphilitic bones, on the contrary, this line is broader, uneven, and presents various modifications, which merge into

¹ For the relationship of blood supply in bone to the location of tuberculous lesions, see *Lezer, Kuliga u. Turk*, "Unters. in Knochenarterien, etc.," *Arch. f. klin. Chir.*, Bd. lxxi., p. 9, 1903, and *ibid.*, Bd. lxxiii., p. 41, 1904. For a review of this see *Bloodgood*, *Progressive Medicine*, vol. vi., p. 195, 1904.

one another, so that all intermediate forms may be seen. In a lesion of moderate grade there may be, between the cartilage and the new-formed spongy bone, a white or reddish-white zone, about two millimetres in breadth, with very irregular borders, consisting of calcified cartilage, in which the linear groups of cartilage cells are more abundant than normal. In more pronounced lesions the calcified zone, still containing an unusual number of cartilage cells, is broader and still more irregular and less sharply outlined against the ossification zone. The cartilage just beyond it is softer and almost gelatinous, and may contain numerous blood-vessels, islets of connective tissue or of calcification, or irregular ossification. Finally the bone may be pouched out at the sides around the ossification and calcification zones, and the perichondrium and periosteum thickened. The whitish, irregular calcified zone is hard and friable. Between this and the new-formed bone there is an irregular, soft, gray or grayish yellow zone, from two to four millimetres in thickness, which forms a loose, readily separated connection between the cartilage and the diaphysis. The white, friable zone consists mainly of irregular rows of degenerated and distorted cartilage cells lying in a calcified basement substance, of irregular masses of atypical bone tissue, and of blood-vessels surrounded by variously shaped cells. The soft zone consists of more or less vascular tissue with homogeneous basement substance, and round and spindle-shaped cells. This soft zone is not sharply outlined against the adjoining new-formed spongy bone, which, instead of consisting of the normal marrow spaces with bony lamellæ between them, is largely composed of granulation tissue.

Different phases of this faulty development may be seen in different bones in the same individual. According to Wegner the lesion is usually most advanced in the lower end of the femur, then in the lower ends of the leg bones and of the forearm, then in the upper ends of the tibia, femur, and fibula.

Not infrequently there is fatty degeneration of the marrow cells and blood-vessels giving the marrow a reddish yellow color: These alterations of the bones may occur, not only in children who have gummata in other parts of the body, but also in those in whom other evidences of syphilitic infection are absent. So uniform is their occurrence that their presence alone suffices for the establishment of a diagnosis.

NECROSIS.

Necrosis is the death of a larger or smaller portion of bone. This may be induced by conditions which deprive the bone of its proper vascular supply from the periosteum and medulla. It may be associated with suppurative periostitis, osteomyelitis, and osteitis, traumatic separation of the periosteum, ulcers of neighboring soft parts, emboli, the action of phosphorus vapor, and exhaustive infectious diseases. Necrosis is a pure form of gangrene, differing from gangrene of soft parts in that the dead bone has at first, and may retain for a long time, the general outward characters of the normal bone; while in dead soft parts rapid

absorption may occur, or, should bacteria of various forms be present or gain access to the dead tissue, putrefaction, with complex changes, may ensue.

When a portion of bone has died, inflammation occurs at the dividing-line between the dead and living bone. This inflammation has the characters of a rarefying osteitis (see above), and finally separates the dead from the living bone. The dead bone, or *sequestrum*, may remain smooth and unaltered (Fig. 621), or it may be eroded by the influence of surrounding pus or granulation tissue or osteoclasts. In this way it is possible for the sequestrum, if it be small, to be entirely absorbed. More frequently there is a production of new bone around the sequestrum,

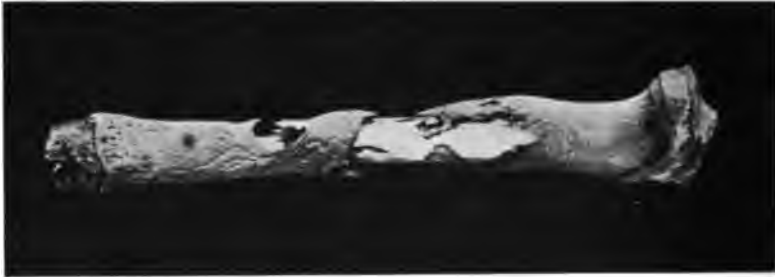

FIG. 621.—NECROSIS OF BONE.

Showing sequestrum of dead bone partially surrounded by new-formed subperiosteal bone, with thickening of the shaft.

either beneath the periosteum or in the substance of the bone, and this becomes lined with granulation tissue, from which pus may continue to be formed, bathing the sequestrum.

Necrosis may involve the superficial layers, or the entire thickness of the wall of a long bone, or only the spongy tissue and inner layers, or an entire bone, or a number of different portions of the same bone, but it is most apt to occur in compact bone.

The death and separation of the bone may be soon followed by the growth of new bone to repair the loss. The periosteum, the medulla, and the surrounding soft tissues may all take part in this new growth. The new bone is usually irregular, rough, and perforated with openings through which pus formed around the sequestrum may be discharged. If the sequestrum be removed, healing may occur by the formation of new bone; but the bone is usually more or less distorted by the irregular new ossification.

Phosphorus Necrosis.—Under the influence of phosphorus vapor, periostitis and osteitis, particularly of the jaw, are apt to occur, which usually lead to more or less extensive necrosis, generally associated with prolonged and often extensive suppuration.

CARIES.

Caries of bone is essentially an *ulcerative osteitis* resulting in progressive molecular destruction of the bone tissue. It differs from necrosis in that, in the latter, larger and smaller masses of bone die, while in caries the destruction is molecular and gradual (Fig. 622). It may occur in connection with any form of osteitis, with periostitis and osteomyelitis, or it may be secondary to inflammatory or destructive processes in the joints or adjacent soft parts. The depressed surfaces of bones in which caries is progressing are rough and more or less finely jagged, and may be covered with granulations. The minute changes by which ulceration and destruction of the bone are produced in caries are somewhat analogous with those in rarefying osteitis, but there are marked degenerative changes in the bone cells, which may become fatty or converted into a granular material. Moreover, the basement substance of the bone, instead of being absorbed, may disintegrate, with the formation of larger and smaller masses of detritus. Sometimes the lime salts are removed from the basement substance, which is converted into atypical fibrillar tissue and fatty and granular detritus. Very extensive suppurations and necrosis may be associated with caries.

Long-continued caries, especially in badly nourished individuals, is apt to become complicated with tuberculous inflammation.

There is very little tendency to spontaneous healing in caries, but it may occur, and the defects produced may be more or less supplied by means of new-formed bone.

RACHITIS. (Rickets.)

Rickets is a developmental disease of bone, in which the proper ossification does not take place. The disease usually occurs during the first two years of life, but may be congenital,¹ or may occur as late as the twelfth year.

¹ *Salvetti*, *Ziegler's Beitr. z. path. Anat., etc.*, Bd. xvi., p. 29, 1894, bibl.

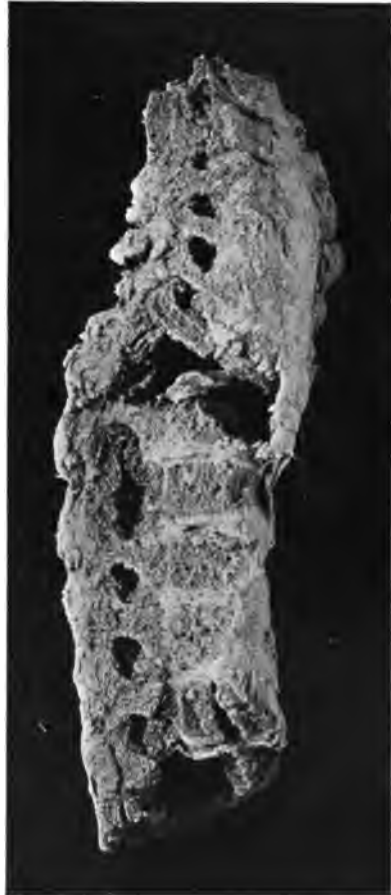

FIG. 622.—CARIES OF THE VERTEBRÆ.

The physiological growth of bones presents three phases. They grow in length by the production of bone in the cartilage between the epiphysis and diaphysis; in thickness, by the growth of bone from the inner layers of the periosteum. At the same time the medullary canal is enlarged, in proportion to the growth of the bone, by the disappearance of the inner layers of bone.

In rickets these three phases of growth are abnormal. The cartilaginous and subperiosteal cell growth, which precedes ossification, goes on with increased rapidity and exuberance and in an irregular manner, both between the epiphyses and diaphyses and beneath the periosteum, while the actual ossification is imperfect, irregular, or wanting. At the same time the dilatation of the medullary cavity goes on irregularly and often to an excessive degree.

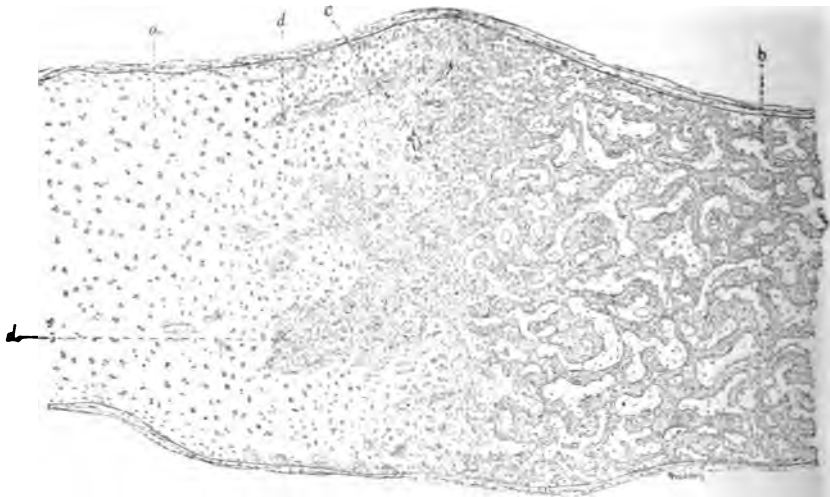


FIG. 623.—RACHITIC BONE.
Showing ossification zone in a longitudinal section of a rib.

If one examine microscopically in a rachitic bone the region between the epiphysis and diaphysis (Fig. 623), he finds that the cartilage cells are not regularly arranged in rows along a definite zone in advance of the line of ossification, as in normal development, but that there is an irregular heaping-up of cartilage cells, sometimes in rows, sometimes not, over an ill-defined and irregular area. The zone of calcification also, instead of being narrow, regular, and sharply defined, is lacking in uniformity. Areas of calcification may be isolated in the region of proliferating cartilage cells, or calcification may be altogether absent over considerable areas.

Corresponding to these irregularities the ossification zone is also irregular. New-formed bone and marrow cavities containing blood-vessels may lie in the midst of the cartilage, or masses of cartilage may lie deep in the region which should be completely ossified. In other places it

seems as if the cartilage tissue were directly converted into an ill-formed bone tissue by metaplasia or direct transformation. It will readily be seen from this that the medullary spaces of the new-formed bone are irregular, and this abnormality is enhanced by the premature intra-medullary absorption of the bone.

Similar irregularity in the bone formation may be seen beneath the periosteum. An excessive proliferation of cells in the inner layers of

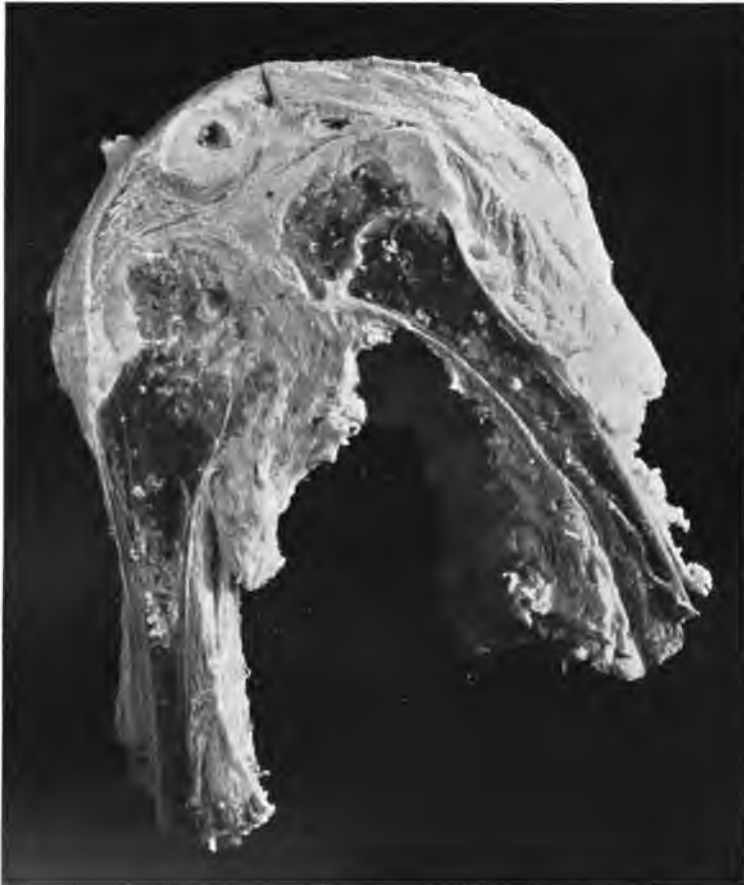

FIG. 624.—RICKETS.

Showing irregular ossification and bending of the long bones.

the periosteum, the irregular calcification which occurs about them, and the absence of uniformity in the elaboration of ill-structured bone, conspire to produce an irregular, spongy bone tissue instead of the compact, lamellated tissue which is so necessary here for the solidity of the structure. The increased cell growth between the epiphyses and diaphyses produces the peculiar knobby swellings which are characteristic of

rickets. At the same time the medullary cavity increases rapidly in size and the inner layers of the bone become spongy. The medulla may be congested, and fat, if it has formed, may be absorbed, and a modified form of osteitis may ensue.

The result of these processes is that the bones do not possess solidity and cannot resist the traction of the muscles or outside pressure. The epiphyses may be displaced or bent, especially in the ribs, less frequently in the long bones. The long bones and the pelvic bones may be bent into a variety of forms (Fig. 629). Incomplete fractures are not infrequent. Complete fractures do not usually occur until the later stages of the disease, when the bones have become more solid. In the head, the

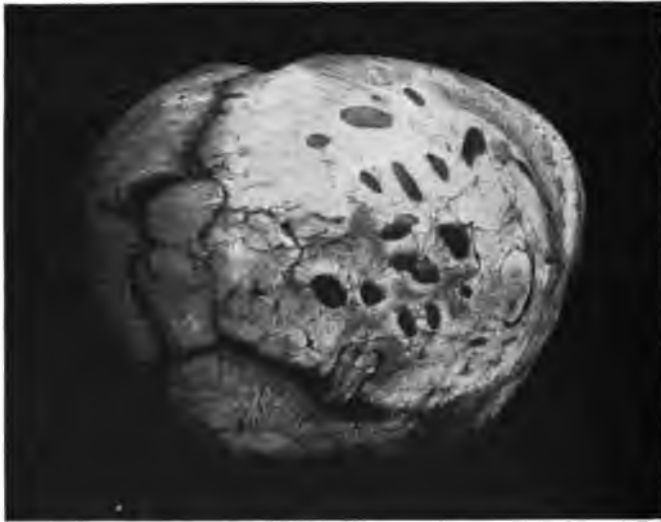

FIG. 625.—CRANIOTABES.

This skull of a child is large, its bones are thin, with holes due to faulty development and covered only by a thin, fibrous membrane.

cranium may be unnaturally large for the size of the face; the fontanelles and sutures may remain open; the bones may be soft, porous, and hyperæmic, while at their edges there may be rough, bony projections beneath the pericranium. Sometimes, especially in the occipital bone, there are rounded defects in the bone, filled only with a fibrous membrane; this constitutes one of the forms of so-called *Craniotabes* (Fig. 625).

It does not fall within the scope of this work to describe the various deformities which may occur as a result of this disease. The familiar pigeon breast; the rows of knobs along the sides of the chest from bending and dilatation of the ribs at the point of junction of cartilage and bone (Fig. 626); the knock-knees, bow-legs, spinal curvatures, etc., may all be the result of rachitic weakening of the bones.

After a time the rachitic process may stop and the bones take on a more normal character. The porous bone tissue becomes compact and



FIG. 626.—THORAX OF RACHITIC CHILD.

View of interior of chest showing knobs on the ribs projecting inward. (Photograph by Dr. Northrup.)

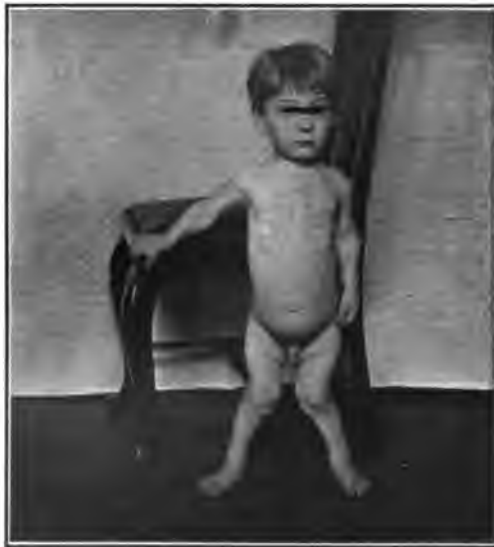

FIG. 627.—ACHONDROPLASIA.

Showing shortened and deformed arms and legs, the trunk and head being approximately normal.

even unnaturally dense; the swellings at the epiphyses disappear; many of the deformed bones may become of a normal shape. In severe cases,

however, the deformities continue through life; especially there is a cessation of the growth of the bones in their long axis, so that the persons affected are dwarfed.

The disease may have an acute or a chronic character. The acute form begins usually during the first six months of life. The children are apt to suffer from vomiting, diarrhœa, profuse sweating, chronic bronchitis and pneumonia, general anæmia, and wasting. They either die or the rachitic process is gradually developed. The chronic form is seen in older children, and often in those apparently healthy. The changes in the bones may take place without constitutional symptoms, though there are often catarrhal bronchitis, pneumonia, and anæmia.

Achondroplasia (Fœtal Rickets).—This disease of fœtal life is of obscure nature, perhaps allied to rickets.

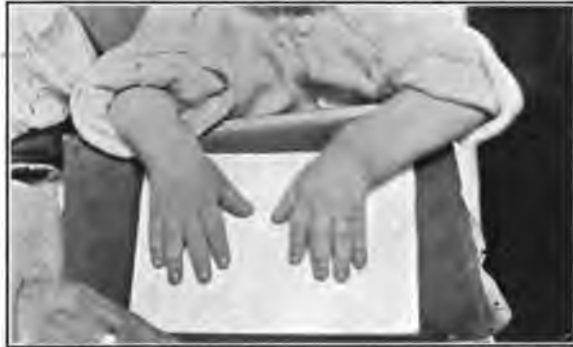

FIG. 628.—ACHONDROPLASIA.
Showing characteristic deformity of the hands. (Photograph by Dr. Northrup.)

Bones which are of intra-membranous origin, or which in late fœtal life are chiefly cartilaginous are least involved, while the long bones chiefly suffer, through failure in ossification at their ends, together with various defects in their cartilage.

This condition is marked (see Fig. 627) by abnormalities in the length, shape, and consistency of the bones of the limbs, which in general are short and thick. The head may be normal or rachitic in type. The trunk may be of normal size. The fingers are often stumpy (Fig. 628). These with other bone changes lead to the characteristic "dwarf" type of body.

The characteristic lesions of achondroplasia are often associated with various developmental malformations of ordinary type.

OSTEOMALACIA.

This lesion consists in the softening of fully formed hard bone tissue by the removal of its inorganic salts. It is to be distinguished from rickets, whose lesions are due to a faulty development of bone, although in certain external characters the two diseases sometimes present consid-

erable similarity. Osteomalacia usually occurs in adults, most frequently in females during pregnancy and after parturition; more rarely it occurs in males, and in females unassociated with the above conditions. Its cause is not known.

Microscopical examination shows that the decalcification occurs first in the periphery of the Haversian canals and in the inner layers of the walls of the marrow spaces. As the salts of lime are removed the basement substance at first remains as a finely fibrillated material, still preserving the original lamellation. The bone cells may be changed in shape or degenerated. After a time the decalcified tissue may disintegrate and be absorbed, and its place occupied by new-formed marrow or granulation tissue. As the disease goes on, the marrow tissue is congested and red, the fat absorbed, and there is a great accumulation of small spheroidal cells; or the marrow may assume a gelatinous appearance. The decalcification and absorption of the bone from within may proceed so far that the bony substance in the cancellous tissue almost entirely disappears, and the compact bone is reduced to a thin, soft, decalcified tissue. The disease is not always continuously progressive, but may be subject to temporary cessation.

As a result of this softened condition of the bones, the weight of the body and the actions of the muscles may induce a series of deformities which are sometimes excessive: curvatures of the spine, complete and incomplete fractures of the bone, distortions of the pelvis, sternum, etc. There is a tendency in this disease to a general involvement of the bones, but the changes are sometimes confined to single bones or groups of bones. The cranium is rarely much affected.

ALTERATIONS OF THE BONE MARROW IN LEUKÆMIA AND ANÆMIA.

In certain forms of leukæmia the marrow of the bones is very markedly altered. The change consists mainly in an accumulation in the marrow tissue of spheroidal cells, often in a condition of fatty degeneration, which lie in the meshes of reticular connective tissue and in and along the walls of the blood-vessels. There may also be absorption of the fat, and sometimes enlargement of the marrow cavity from absorption of the bone. These alterations seem to be primarily due to a hyperplasia of the marrow cells. The new cells which accumulate in the marrow under these conditions are of various forms. Most characteristic are colorless, spheroidal cells which considerably resemble the large lymphocytes of normal blood. But they are usually larger, though varying much in size, have one large, often vesicular nucleus staining less strongly than the lymphocyte nuclei, while the protoplasm usually contains neutrophile granules. These cells are called *myelocytes*. In addition to these the marrow may contain, mingled with its usual elements, nucleated red blood cells, spheroidal cells containing red blood cells, and not infrequently considerable numbers of small octahedral crystals (called Charcot's crystals).

The degree to which this accumulation of cells occurs varies much in

different cases, and the gross appearances of the marrow are consequently very diverse. In some cases the marrow is soft and has a uniform red appearance, or it is variously mottled with gray and red. Occasionally circumscribed hæmorrhages are seen. In another class of cases, in which

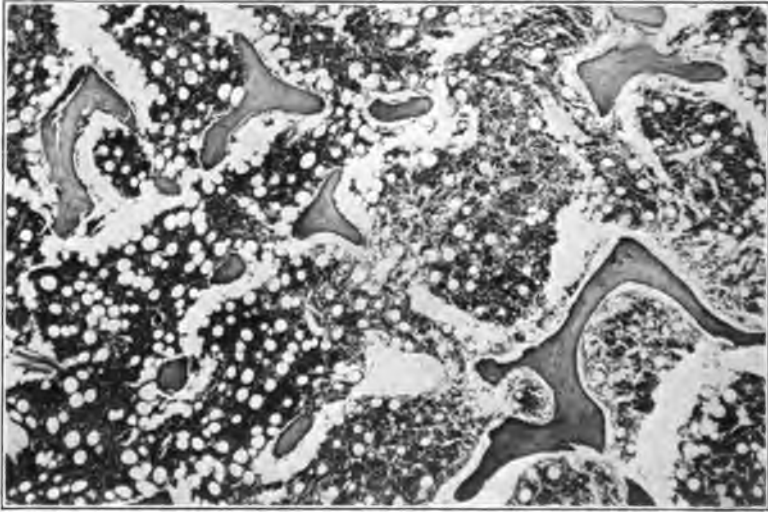


FIG. 629.—HYPERPLASTIC BONE MARROW OF RIB.
From a case of purpura hæmorrhagica.

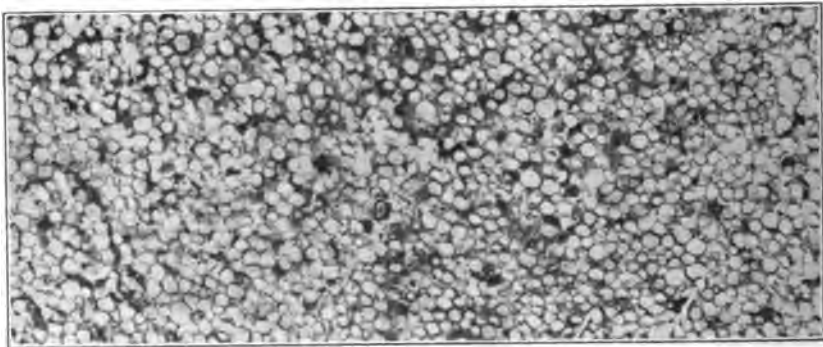


FIG. 630.—NORMAL BONE MARROW FROM SHAFT OF FEMUR.
The marrow shows little but fat tissue with occasional darker patches containing either a few red cells, often nucleated, or one of the characteristic megalokaryocytes of the marrow.

the cell accumulation is more excessive, the marrow may be gray, grayish yellow, or puriform in appearance (Fig. 629).

These changes may occur in the central marrow cavity, as well as in the marrow spaces of the spongy bone. They may be present in several or many of the bones. They are usually accompanied by analogous changes in the spleen and lymph-nodes (Fig. 630).

In certain cases of acute and chronic *anæmia*, particularly in the pernicious and progressive varieties, the marrow, especially of the larger long bones, may lose its yellow color from absorption of the fat, and become red. Microscopical examination of the marrow under these conditions may show myelocytes and sometimes an abundance of developing nucleated red blood cells and Charcot's crystals.

In many of the acute infectious diseases, typhus fever and typhoid fever, ulcerative endocarditis, recurrent fever, etc., the bone marrow has been found hyperæmic, and may, it is asserted by Ehrlich, contain myelocytes in increased numbers.

All these lesions of the marrow, although our knowledge of them is still very incomplete, together with what is known of the physiological functions of the marrow, point to a close relationship between the marrow and the spleen and lymph-nodes as blood-producing organs.

TUMORS.

Tumors of the bone may involve either the periosteum, or the compact bone, or the medulla; or, as is more frequently the case, two or more of these structures may be involved at once. Tumors of the bone are usually accompanied by various secondary and sometimes very marked alterations of the bone tissue, osteo-porosis, osteo-sclerosis, ossifying periostitis, etc. The new growths are very apt to undergo calcification and ossification.

Fibromata may grow from either the periosteum or the medulla. Their most common seat is in the periosteum of the bones of the head and face. They are apt to form polypoid tumors projecting into the posterior nares, pharynx, mouth, and antrum of Highmore. Central fibromata, *i.e.*, those growing from the medulla, are rare. They usually occur in the lower jaw, but have been found in the ends of the long bones, the phalanges of the fingers, and the vertebræ. The fibromata may calcify or ossify, contain cysts, and not infrequently occur in combination with sarcoma.

Myxomata are of occasional occurrence in bone.

Osteomata.—New formations of bone as a result of inflammatory processes are, as we have already seen, of frequent occurrence in bone, and although not, strictly speaking, tumors, some of their forms are very closely allied to them, and they may therefore be conveniently mentioned here. New growths of bone which arise from the surfaces are called *exostoses* (see Fig. 616) or *enostoses*, according to their origin from the external surface or from the interior of the bone. They may contain all the constituents of normal bone: bone, medulla, vessels, periosteum, and cartilage. The new bone may be compact and like ivory, or spongy, or contain large cavities filled with marrow.

The shape of exostoses varies greatly; they may be in the form of sharp, narrow spicula and processes, and, occurring in connection with periostitis, are called *osteophytes*. They may be polypoid in shape, or form rounded tumors with a broad base. They may form a general

enlargement of the bone with much roughening of the surface; this condition is often called *hyperostosis*.

The bone beneath these new growths may be normal, or sclerosed, or rarefied, or the medullary cavity of the bone may communicate with that of the exostosis. Exostoses are usually developed from the periosteum, sometimes in the insertion of tendons and ligaments. They are very frequently multiple, and may occur at all ages, even during uterine life.

Enostoses are developed in the interior of bones from the medulla. They may increase in size, with absorption of the surrounding bone, until they project from the surface like exostoses. Their most frequent situation is in the bones of the cranium and face.

Chondromata.—These tumors may be single or multiple, and most frequently grow from the interior of the bone, but sometimes from the periosteum. They are prone to form various combinations with other forms of tumors, as fibroma, myxoma, sarcoma, etc. They are frequently congenital, and are most common in young people. They occur most frequently in the bones of the hand and foot.

There is a form of chondroma, called *osteoid chondroma*, which develops beneath the periosteum, most frequently in the femur and tibia near the knee-joint, forming a club-shaped enlargement of the bone. The characteristic of the tissue composing these tumors is that it resembles somewhat the immature bone tissue which is seen beneath the periosteum in developing bone. It differs from cartilage in the irregular shape of its cells, in the fibrillation and density of the basement substance, and in its general vascularity. On the other hand, it has not the inorganic contents or appearance of true bone. It resembles considerably the callus tissue forming about fractures of the bones. It may, however, and most frequently does, become converted, in some parts of the tumor, into true bone. On the other hand, combinations with sarcomatous tissue are of frequent occurrence (see below).

Sarcoma is especially common in the bones. It grows from the inner layers of the periosteum or from the medulla, so that we may distinguish a *periosteal* and a *myelogenic* sarcoma. Sometimes the tumor involves the bone itself so early that it is impossible to say whether the tumor began in the periosteum or in the medulla. There is also a variety which grows close to the outside of the periosteum and becomes connected with it—*parosteal* sarcoma.

The *periosteal sarcomata* usually belong to the varieties fibro-, myxo-, chondro-, and osteo-sarcoma, more rarely to the medullary variety. They commence in the inner layers of the periosteum, pushing this membrane outward. After a time the periosteum is involved and the tumor invades the surrounding soft parts. The bone beneath may remain normal, or may be eroded and gradually disappear until the tumor is continuous with the medulla. Portions of the tumor may be calcified, or a growth of new bone may accompany its growth. The new bone usually takes the form of plates, or spicula, radiating outward (Fig. 631). The minute structure of these tumors is very variable. The simplest—the fibro-sarcomata—are composed of fusiform, round, stellate, and some-

times giant cells (myeloplaxes), in varying proportions, packed closely in a fibrous stroma. In the medullary form the stroma is diminished to a minimum and the round cells are most numerous. In the chondro- and myxo-sarcoma the basement substance may be hyaline or mucous, and the cells follow the type of cartilage and mucous tissue more or less closely. There is a mixed form of tumor, called *osteoid sarcoma*, which is very apt to spread and to form metastases. The growth consists in part of tissue corresponding to fibro-sarcoma and round-celled sarcoma. In addition to this there occurs, in greater or less quantity, immature bone tissue, called osteoid tissue, which may in part become calcified, the calcification usually occurring in the central portions, leaving a softer peripheral zone. This form of tumor is most apt to occur at the ends of the long bones, and may form tumors of large size. It is often called

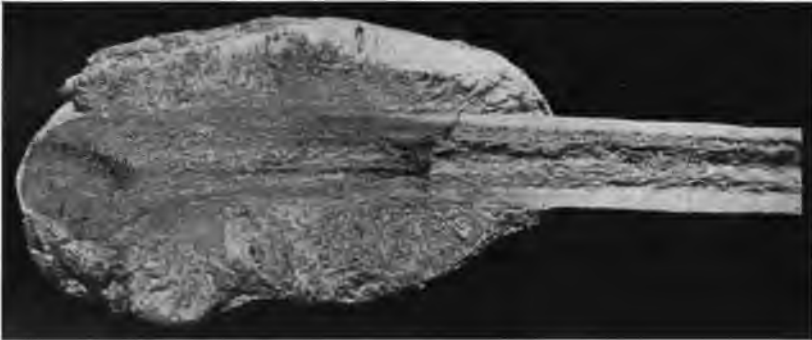

FIG. 631.—SARCOMA OF THE BONE—PERIOSTEAL.

The growth has invaded the shaft of the bone, which is fractured. Spicula of bone, new formed in the tumor, may be seen below, passing outward from the periosteum.

on account of its tendency to extend and to form metastases, *malignant osteoma* or *osteoid cancer*. *Angio-sarcomata* are of frequent occurrence in bone.

Sarcomata may originate in the medulla—*myeloid sarcoma*—and may grow rapidly. The bone surrounding them is destroyed and they project as rounded tumors. Most frequently new bone is formed beneath the periosteum, so that the tumor is enclosed in a thin, bony shell (Fig. 632); sometimes there are also plates of bone in the tumor; sometimes the periosteum is unaltered; sometimes it is perforated and the tumor invades the surrounding soft parts. The tumors are frequently very soft, vascular, and hæmorrhagic in parts, or may enclose cysts filled with tumor detritus and blood. They are usually of the spindle- or round-celled variety, and not infrequently contain giant cells.

Sarcomata may originate in the outer layers of the periosteum—*par-osteal*. They may be as firmly connected with the bone as is the periosteal form. The periosteum may remain intact between the tumor and the bone, or it may disappear and leave them in apposition. **Endothelioma** of bone is not uncommon. **Lipoma** is rare.

Myeloma.—Under this name is included a peculiar group of tumors, which, while they resemble the sarcomata in many respects, are distinct from them in their histogenetic relationships; that is, they are derived from the special cells of the bone marrow, and not from the periosteum. These tumors are usually multiple, appearing simultaneously in many parts of the bony structures.¹ They form grayish or reddish masses in the spongy bone or in the medullary canal and as they grow excite active resorption of the bone. Spontaneous fractures are frequent and bending of the bone from loss of lime salts is occasionally seen. Metastases in other organs are extremely rare. Another interesting point is the presence in the urine in many of these cases of a peculiar proteid called Bence Jones' proteid, which coagulates on heating, and dissolves on further heating in the boiling liquid, only to reappear again as it cools. This proteid is not absolutely characteristic of myeloma as it has also been found in some of the leukæmias.

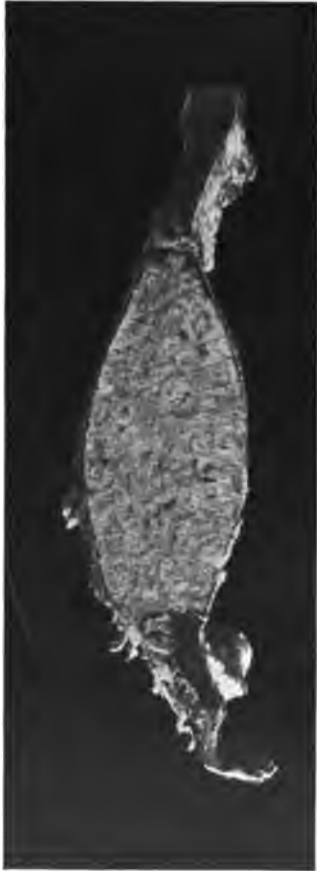

FIG. 632.—MYELOGENIC SARCOMA OF THE STERNUM.

Microscopically, the tumors are composed of three varieties of cells: myelocytes, or myeloblasts, red cells, and plasma cells. In the first type of tumor, which may very well be designated myelocytoma, the cells are large, with oval or irregular nuclei, and many of them show characteristic granulations of the neutrophile myelocytes. Tumors formed largely of red cells (erythrocytoma or erythroblastoma) are extremely rare,² while new growths largely composed of plasma cells are the most frequent variety. In such cases the plasma cells often appear in the circulating blood during life.

Angioma.—A very large number of the tumors which have been described under this name are really very vascular sarcomata. Cavernous angiomata may form

between the periosteum and bone and be intimately connected with the latter. There are several cases described of cavities filled with blood in the interior of bones, which it is difficult to interpret. They have mostly been found in the head of the tibia. They are said to have consisted of single sacs composed of thickened periosteum, lined with

¹ Wright, "Multiple Myeloma," *Trans. Assn. Am. Phys.*, 1900, xv., 137; Hoffmann, *Ziegler's Beitr.*, 1904, xxxv., 317; Jellinek, *Virchow's Arch.*, 1904, clxxvii., 96 (bibliography); Christian, *Jour. Exper. Med.*, 1907, ix., 325.

² Norris, *Proc. N. Y. Path. Soc.*, 1906, vi., 128.

plates of bone, and filled with fluid and clotted blood. No large vessels communicated with the sacs, but their walls were covered with a rich vascular plexus, branches of which opened into the cavity of the sac.

Carcinoma.—Primary carcinoma is of doubtful occurrence in the bones. Most of the structures thus named have doubtless been sarcomata or endotheliomata. Secondary carcinoma, on the other hand, as a result of metastases or local extension, is not infrequent. Metastatic carcinoma may occur in the bones of various parts of the body at the same time, and are most apt to be secondary to carcinoma of the mamma.

Cysts.—These most frequently occur in the maxillary bones (p. 415) in connection with the teeth. They may be unilocular or multilocular, and contain clear serum or a mucous or brown fluid, and sometimes cholesterin. They may be lined with epithelium. They begin in the interior of the bone, and, as they increase in size, expand it until they may be covered with only a thin shell of bone. They may reach a large size, even as large as a child's head.

Dermoid cysts are occasionally found in connection with the bones, particularly of the skull.¹

The Joints.

For a description of the dislocations, misplacements, and injuries of the joints we refer to works on surgery.

DEGENERATION.

Fatty degeneration of the cartilage cells, mucous degeneration, and fibrillation of the stroma with softening, and often roughening, of the joint surfaces, calcification and amyloid degeneration, may occur in inflammation, or as a senile alteration, or under other conditions. The cartilage is usually, under these conditions, whiter and more opaque than normal.

INFLAMMATION. (Arthritis.)

Exudative Arthritis.—The earlier stages of acute inflammation of the synovial membranes are better known from experiments on animals than from post-mortem examinations. Among the early changes are swelling and congestion of the membrane, with increased growth and desquamation of the lining cells, and infiltration of the membrane with lymphoid cells. These conditions are soon followed by an exudation. The exact origin of much of the exudate is not clear.

In **Serous Arthritis** the accumulation of serum within the synovial sac is the most prominent lesion. The disease may terminate in recovery, or become chronic, or pass into the suppurative form. It may be incited

¹ For a *résumé* and bibl. of the pathology of bone see *Schmidt* in Lubarsch and Ostertag's "Ergebnisse." Jahrg. iv., for 1897, p. 531; also Jahrg. v. for 1898, p. 895.

For a *résumé* of cysts of bone see *Bloodgood*, *Progressive Med.*, vol. vi., p. 181, 1904.

by contusions, penetrating wounds, gonorrhœa, rheumatism, or it may occur without evident cause.

Sero-fibrinous Arthritis may occur under the same conditions as those which lead to simple serous inflammation. The fibrin may be present largely as flocculi in the serum, or it may form false membranes over the surfaces of the joint.

Suppurative Arthritis may follow or be associated with the above forms of inflammation. The synovial membrane is thickened and cloudy, and there may be but a moderate amount of pus in the joint, and a slight degree of infiltration of the synovial membrane with pus cells. Under these conditions resolution may occur.

In other cases the accumulation of pus in the cavity may be great, the synovial membrane and its surrounding tissue densely infiltrated with pus cells. Under these conditions granulation tissue is apt to form and the cartilages of the joints are apt to become involved. There are swelling and proliferation or degeneration of the cartilage cells; the basement substance becomes disintegrated, ulcerates, and exposes the bone, in which osteitis, caries, rarefaction, etc., may occur. The new-formed granulation tissue may penetrate the cartilage, absorbing the basement substance, and by metaplasia the cartilage tissue may be converted into embryonal or granulation tissue. The pus may break through the capsule of the joint and form large abscesses in the adjacent soft parts. Sometimes the inflammation is not only suppurative but gangrenous, and runs a rapidly fatal course. The synovial membrane, articular cartilages, and ends of the bone all undergo a rapid suppuration and gangrene. Acute arthritis may be incited by trauma, or it may be associated with pyæmia, smallpox, measles, scarlet fever, pneumonia,¹ gonorrhœa,² diphtheria, mumps, typhus fever, glanders, the puerperal condition, or other infectious diseases. In these cases the process is apt to be suppurative, and is induced by various forms of bacteria.

Chronic Arthritis may begin as such, or it may be the result of previous acute inflammation. There is an increase of fluid in the joint. This fluid is thin and serous, or is thickened with flocculi of fibrin and epithelial and lymphoid cells, or is thick, syrupy, or even gelatinous. The synovial membrane is at first congested, its tufts are prominent. Later it becomes thickened, sclerosed, and anæmic; the lining cells are destroyed, and the tufts become large and projecting. From the distention of the capsule there may be subluxations or luxations of the joint, or the capsule may be ruptured.

Rheumatic Arthritis.—An acute inflammation, usually exudative in character and involving one joint after another, is characteristic of acute articular rheumatism. The exudate is usually serous.

A chronic form of so-called rheumatic arthritis is most common in elderly persons, usually affecting several joints and advancing slowly and steadily. There is a fibrous thickening of the synovial membrane and the adjacent tissue. Fluid accumulations are not common. The artic-

¹ For bibliography of pneumococcal arthritis see *Cave, Lancet*, 1901, vol. i., p. 82.

² See bibliography, p. 223.

ular cartilages are apt to degenerate or ossify, or become softened and fibrillated, and they may disappear. The contracting synovial membranes and fibrous tissue render the joints stiff and may cause considerable deformity. Not infrequently fibrous and bony ankyloses are formed between the ends of the bones.

Arthritis Deformans.—This name has been applied to a variety of chronic inflammation of the joints which, combined with degeneration of parts of the joint and the new formation of bone, may result in marked deformities of the part.

It usually occurs in elderly persons and is apt to involve several joints, most frequently the hip, knee, fingers, and feet. It may be idiopathic, or due to rheumatism or to injuries, or follow an acute arthritis. The capsules of the affected joints are thickened and sclerosed. The synovial fluid is at first increased in quantity; later, diminished and thickened. The tufts of the synovial membrane become much enlarged and vascular; they may be converted into cartilage. Sometimes the capsule becomes ossified. The new bone grows from the edge of the cartilage within the capsule and its articular surface is covered with cartilage. The articular cartilages are much changed. The basement substance splits into tufts, while the cartilage cells are increased in number. Or the basement substance becomes fibrous; or it is split into lamellæ and the cartilage cells are multiplied; or there are fatty degeneration and atrophy.

As a result of these changes, larger or smaller portions of the cartilage are destroyed and the bone beneath is laid bare. The exposed bone may become compact and of an ivory smoothness. The ends of the bones are much deformed. They are flattened and made broader by irregular new growths of bone, while at the same time they atrophy. The new growth of bone starts from the articular cartilages. The cartilage cells increase in number and the basement substance grows in quantity. This growth is most excessive at the edge of the cartilage, so that a projecting rim is formed there. This projecting rim may ossify next the bone, and at the same time new cartilage may form on its surface, so that we may find large masses of bone covered with cartilage. All these changes occur in various combinations and sequences, so that joints in this condition present the greatest variety of appearances.¹

Arthritis Uritica (Gouty Arthritis).—This lesion is characterized by the deposit of salts of uric acid in the cartilages, bones, and ligaments, and also in the cavities of joints. The deposits may be in the form of stellate masses of acicular crystals in and about the cartilage cells or in the basement substance; or they may be deposited in the fibrillar connective-tissue structures of the joint in single crystals, or in the subcutaneous tissue about the joint as white concretions. The deposits may occur in repeated attacks of the disease, and are accompanied by acute inflammatory changes. They may lead to various forms of chronic inflammation of the joints.

¹ For a valuable study of arthritis deformans see *Nichols and Richardson, Jour. Med. Res., xxi, 149, 1909.*

Tuberculous Arthritis.—This process may commence in the synovial membrane of the joint, or may extend to the joint from adjacent bone. It is characterized by the formation of tubercle tissue and granulation tissue, sometimes in great quantity, and is usually associated with secondary inflammatory and degenerative changes of surrounding parts. According to the prominence of one or other of these secondary alterations, several forms of tuberculous arthritis may be distinguished. If there is an excessive growth of granulation tissue without much suppuration, this constitutes a *fungous form*. Sometimes there is extensive *suppuration*, so that the cavity of the joint may be filled with pus, which may be discharged through openings in the skin; or there may be more or less extensive formation of abscesses, or infiltration of the soft parts about the joint with pus. In other cases there is disintegration of the new-formed tuberculous tissue and of the tissues of the joint—*ulcerative form*. The cartilage basement substance may become split into fragments and the cells degenerate, and thus deep and destructive ulcers of the cartilage may be formed. Or the new tissue may work its way through the cartilage into the bone beneath, by absorption of the basement substance of the cartilage, with or without proliferation of its cells. Caries and necrosis of the underlying bone may lead to extensive destruction. Hand-in-hand with these alterations subperiosteal new formation of bone may occur, or sclerosis of the adjacent bone tissue. There may also be a great increase of fibrous tissue about the joint. The type of lesion depends in considerable degree upon the joint involved.

This disease is most common in children and young persons. The so-called scrofulous diathesis is said to foster it, but local injuries are frequently the predisposing factors. It is most common in the large joints. It may occur in connection with tuberculous inflammation in other parts of the body, but it is frequently quite local, and may remain so for a very long time or permanently, since general infection from tuberculous arthritis is comparatively infrequent.

The process is usually slow, and may end in death. If recovery takes place before the cartilages and bones are involved, the topography of the joint is maintained; but it may be stiffened, or even immovable, from the contraction of the new fibrous tissue around it. If the cartilages and bones are diseased the joint is destroyed, and either bony or fibrous ankylosis results. Sometimes, from the change in the articulating surfaces and the contraction of the muscles and the new fibrous tissue, partial or complete dislocations are produced.

Occasionally miliary tubercles occur in the synovial membranes in cases of general miliary tuberculosis, with but little accompanying simple inflammatory change.

TUMORS.

Secondary tumors of the joints as a result of local extension from the adjacent parts are not uncommon, and the tumors may be of various

kinds. Primary tumors of the joints, on the contrary, are not very common.

Lipoma.—A new growth of fat tissue may begin in the other portions of the synovial membrane, push this inward, and project into the joint in a mass of tufts—*lipoma arborescens*.

Fibroma occurs as a hypertrophy of the little tufts and fringes of the synovial membrane. In this way large polypoid and dendritic bodies are formed. The pedicles of these growths may atrophy and even disappear, so that the growths are left free in the cavities of the joints.

Corpora aliena Articularum (Loose Cartilages in the Joints).—This name is given to bodies, of various structure and origin, which are found free or attached by slender pedicles in the cavities of the joints. They are most frequently found in the knee; next in order of frequency, in the elbow, hip, ankle, shoulder, and maxillary joints. They may be single or in hundreds. Their size varies from that of a pin's head to that of the patella. They are polypoid, rounded, egg-shaped, or almond-shaped; their surface is smooth or faceted, or rough and mulberry-like. They are composed of fibrous tissue, cartilage, and bone in various proportions.

These bodies are formed by hyperplasia of the synovial tufts and the production in them of cartilage and bone.

More frequently the small plates of cartilage form on the inner surface of the synovial membrane, which increases in size while their outer layers ossify. These may remain fixed in the synovial membrane; or they project and become detached from it, and they then appear as flattened, concave bodies composed of bone covered with cartilage on one side.

On the other hand, cartilage and bone may form outside the synovial membrane from the periosteum or the edges of the articular cartilages, and, pushing inward, may later become detached.

Rarely portions of the articular cartilages may be detached by violence or disease; or fibrinous and other concretions may form in arthritis, or under conditions which we do not understand.¹

¹ For a detailed consideration of lesions of the bones and joints consult Ziegler, "Lehrbuch der Pathologie," vol. ii.

CHAPTER XIV.

THE NERVOUS SYSTEM.

The Membranes and the Ventricles.

The Dura Mater Cerebralis.

THE dura mater is a dense connective-tissue membrane which serves the double purpose of a periosteum for the inner surface of the cranial bones, and of an investing membrane for the brain. It is itself but poorly supplied with blood-vessels, but it contains the large venous sinuses which carry the blood from the brain. Lesions of the dura mater, therefore, are apt to be associated with lesions of the cranial bones, of the pia mater, or of the venous sinuses.

In young children the dura mater adheres closely to the inner surface of the cranial bones, in adults it is more readily detached, and in old persons it is again more adherent. Chronic inflammation of the external layers of the dura mater also renders it more adherent to the bones.

HÆMORRAGE.

Extravasated blood may lie between the dura mater and the cranial bones, in the substance of the membrane, or between the dura mater and the pia mater.

Hæmorrhages between the dura mater and the cranial bones are usually due to blows and injuries of the head, are often of considerable size, separating the membrane from the bones, and may compress the brain. They are often associated with laceration of the brain, and with hæmorrhages between the dura mater and pia mater.

Hæmorrhages between the dura mater and the pia mater may take place from the vessels of either membrane. Those from the vessels of the dura may result from chronic pachymeningitis.

Hæmorrhages into the substance of the dura mater are not frequent and are usually small.

Pressure on the head of the infant in delivery may cause extravasations of blood between the bones and the dura mater, as well as between the bones and the pericranium.

THROMBOSIS.

Thrombosis of the venous sinuses is not uncommon. It is often associated with inflammation of the dura mater and with injuries and inflammations of the brain and pia mater, of the cranial bones, of the middle ear, and of the scalp. Like thrombosis in other parts of the body, it may occur in the infectious and exhausting diseases. It may occur in apparently healthy persons without discoverable cause. The thrombi may be red or white, and firm. They may induce no secondary changes,

or they may extend into the veins and induce hæmorrhagic softening of the involved areas of the brain.

INFLAMMATION. (Pachymeningitis.)

This may involve the external layers of the membrane, *pachymeningitis externa*, or the internal layers, *pachymeningitis interna*. It may be either acute or chronic. The tissues of the substance of the dura mater participate to a greater or less degree in these changes, but the chief lesions are upon the surfaces.

Acute Pachymeningitis Externa is usually secondary to injuries or diseases of the cranial bones; thus it may be incited by fractures of the skull, either depressed or not, osteitis, caries, suppurative inflammation of the internal and middle ear and of the mastoid cells. The dura mater

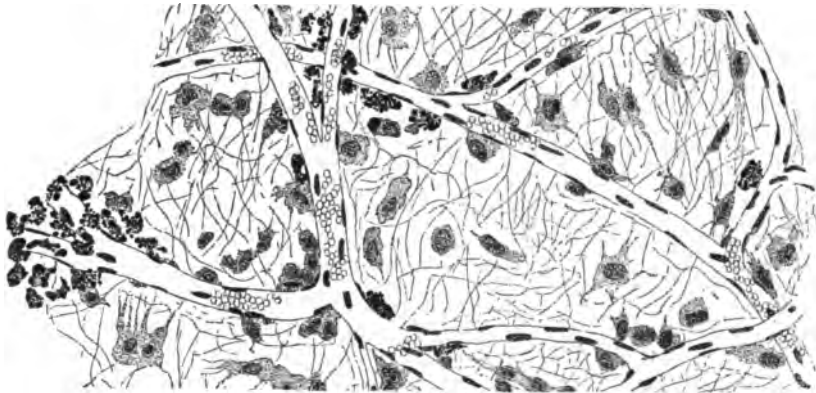


FIG. 633.—PACHYMENINGITIS INTERNA HÆMORRHAGICA—CHRONIC.
At the left near the vessels are connective-tissue cells containing blood pigment.

is commonly congested and swollen, and may contain small ecchymoses. The inflammation is usually suppurative, and pus may accumulate between the membrane and the bone, or in the substance of the membrane. The areas of inflammation are not usually extensive. It sometimes leads to thrombosis of the venous sinuses, and sometimes gangrene of the dura mater occurs. The inflammation may extend to the inner surface of the dura mater, to the pia mater and brain, or it may remain localized and undergo resolution.

Acute Pachymeningitis Interna may be secondary to inflammation of the external surface, or it may occur as a complication in pyæmia, puerperal fever, chronic diffuse nephritis, in the exanthemata and erysipelas, or independently. There is a general or circumscribed production of fibrin and pus, so that the internal surface of the membrane is lined with a layer of soft, yellow exudate.

Simple Chronic Pachymeningitis consists in the formation of new connective tissue in the dura mater, by which it becomes thicker and in

many cases abnormally adherent to the bones of the skull. This thickening may be general or circumscribed, and may involve the entire thickness of the membrane. Not infrequently, when the external layers are especially involved, firm adhesions to the skull occur, with ossification of the outer layers, so that shreds of the membrane containing little masses of bone (osteophytes) remain sticking to the skull when the membrane is stripped off.

Pachymeningitis Interna Hæmorrhagica.—This is an important form of chronic inflammation of the internal layer of the dura mater, characterized by the formation of layers of new delicate connective tissue with numerous very thin-walled blood-vessels from which the blood is prone to escape. The membrane may at first appear as a delicate fibrinous pellicle, with small red spots scattered through it, or it may look like a simple reddish or brown staining of the inner surface of the dura mater. Microscopical examination shows this membrane to consist of numerous blood-vessels, mostly capillaries with very thin



FIG. 634.—BRAIN SAND FROM PACHYMEINGITIS INTERNA.

walls, which may be distended or pouched, and which have grown out from the vessels of the dura mater (Fig. 633). Between the vessels is a homogeneous or slightly differentiated basement substance, containing a variable number of spheroidal, fusiform, or branching cells. Red blood cells in variable quantity, blood pigment in various forms, frequently enclosed in the new cells, and small calcareous concretions (brain sand) (Fig. 634), also lie in the intervascular spaces. In more advanced stages the new membrane may become greatly thickened, its outermost layers being changed into dense fibrous tissue with obliteration of the vessels; while the more recently formed layers are similar in structure to those at first developed. Considerable blood usually escapes by diapedesis from the vessels of the new membrane in all stages of its formation. The vessels are also very liable to rupture, giving rise to extensive hæmorrhages either into the substance of the membrane or between it and the pia mater. Sometimes masses of new tissue and blood, from half an inch to an inch or more in thickness, are formed in this way, greatly compressing the brain. These new membranes are most frequently formed over the convexity of the brain, but may extend over nearly the entire surface of the dura mater. Sometimes, when old, the entire membrane, densely pigmented and firm, lies loosely beneath the dura mater without compressing the brain or giving any clinical indication of its presence. The membrane may induce chronic changes in the pia mater, with or without accompanying changes in the cortical portion of the brain.

Rarely, serum accumulates between the layers of the new membranes and in this way cysts of large size may be formed. In rare cases diffuse suppuration of the entire new membrane occurs.

The slighter degrees of this form of inflammation may occasion no symptoms during life. They are not infrequently found in persons suffering from various chronic brain lesions and from chronic alcoholism,

but they may occur unassociated with complicating lesions. The more advanced forms of the lesions are frequently found in idiots, epileptics, etc.

Tuberculous Pachymeningitis may occur secondarily to that form of inflammation in the pia mater or the bones, or as a part of general miliary tuberculosis. The tubercles may be situated on either surface of the membrane or in its substance, and may be single, or aggregated forming large masses.

Syphilitic Pachymeningitis manifests itself by the formation of so-called gummy tumors upon either the external or internal surface of the dura mater. These tumors may be single or multiple, and vary greatly in size. They may be accompanied by simple inflammatory changes in the dura mater in their vicinity. They may undergo suppuration with the formation of abscess. The inflammation may extend to the pia mater, inducing simple or syphilitic meningitis and adhesions between the dura mater and pia mater. The gummata may, on the other hand, when occurring on the outer surface of the membrane cause absorption and perforation of the bones of the skull.

TUMORS.

Fibromata and **lipomata** occur rarely in the dura mater and are of small size.

Small **chondromata** are sometimes found connected with the dura mater at the base of the brain.

Osteomata.—In addition to the formation of osteophytes in chronic external pachymeningitis, plates and, more rarely, globular masses of bone may be formed in the dura mater, unconnected with the bones of the skull. They are most frequently found in the falx cerebri, but may occur elsewhere. The new bone may be dense or loose in texture, and usually produces no symptoms.

Endotheliomata.¹—These tumors may grow inward or outward, causing pressure on the brain or absorption and perforation of the bones; they often attain considerable size. Some of these tumors somewhat resemble certain forms of epithelioma, and have often been described as primary carcinomata. They vary in character, being sometimes formed of densely packed masses of flattened cells with little fibrous stroma (Fig. 219), sometimes lobulated with considerable dense stroma in narrow or broad bands. In other cases, the polyhedral or cuboidal cells are conspicuously grouped around blood-vessels. Again, the cells form concentric, densely packed masses, either around vessels or around a central cell group (Fig. 220). These form one of the types of psammoma, and the concentric borders are often calcified.

Sarcomata are the most common tumors of the dura mater, and of these the spindle-celled forms are of more, the round- and polyhedral-celled forms of less, frequent occurrence. They may grow from either

¹ For a consideration of tumors of the dura mater allied to the endotheliomata consult *Dagonet*, Arch. de méd. exp., t. iv., p. 361, 1892.

surface of the membrane. Some of the round- and polyhedral-celled forms are soft and very vascular, and are apt to involve the neighboring pia mater and brain tissue, or the bones of the skull, which they may perforate. They sometimes project through the opening in the skull in fungous, bleeding masses.

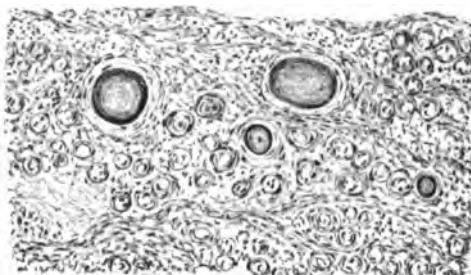


FIG. 635.—PSAMMOMA OF THE DURA MATER.

Psammomata are small globular tumors, often multiple and pediculated, growing from the inner surface of the dura mater. They are usually composed of tissue, fibrous, sarcomatous, or endotheliomatous in character, and contain variously shaped calcareous concretions similar in appearance to the so-called brain sand¹ (Fig. 635).

The Pia Mater Cerebralis

General Characters of the Pia Mater.

The external surface of the brain is invested by a connective-tissue membrane which covers the convolutions, dips down into the sulci, and extends into the ventricles. This membrane is abundantly supplied with blood-vessels, and from it numerous vessels extend into the brain, so that any disturbance in the circulation of the blood in the pia mater involves a disturbance in the circulation of the blood in the brain also.

The connective tissue which makes up the pia mater is arranged in a series of membranes and fibres reinforced by elastic tissue, so arranged as to form a spongy membrane containing numerous cavities more or less filled with fluid. These cavities are continuous with the perivascular spaces which surround the vessels that pass from the pia mater into the brain. The outer layers of the pia mater are the most compact, and are covered on their outside surface by a continuous layer of endothelial cells. This external layer of the pia mater is often described as a separate membrane called the "arachnoid," but it is really only part of the pia. The deeper layers of the pia contain the blood-vessels. The membranes and fibres which compose the pia mater are partly coated with cells which have irregular and delicate cell bodies and large, distinct nuclei.

Along the borders of the longitudinal fissure, and, more rarely, on the under surface of the brain, are a number of small, white, firm, irregular bodies, the *Pacchionian bodies*. They vary in size, number, and in the extent of the surface of the hemispheres which they cover. They may perforate the dura mater, or, more rarely, the wall of the longitudinal sinus, and may produce erosions of the skull bones. They are composed of fibrous tissue and may undergo fatty or calcareous degeneration. We are ignorant as to their origin, and as to the causes of their variations in size and number.

¹ For a study of psammoma consult *Ernst*, "Ueber Psammome," in *Ziegler's Beiträge zur path. Anatomie*, Bd. xi., p. 234, 1892.

The frequency of their occurrence, and the absence of any known pathological significance, warrant our regarding them as essentially normal structures.

The pia mater is frequently thickened, opaque, and white, either in diffuse patches or, more commonly, along the course of the vessels. In other cases single or multiple small white spots, of the size of a pin's head or smaller, may be seen in the membrane, not appreciably elevated above the surface, but due to localized thickening. These slight opacities of the pia mater are commonly believed to be dependent upon repeated congestions of the membrane or upon chronic meningitis, but there is no evidence that this is always the case. They are most frequently found in old persons, but may exist at any age, and do not necessarily indicate the pre-existence of disease.

The amount of blood contained in the vessels of the pia mater after death varies greatly, and is by no means a reliable indication of the amount present during life. In general anæmia the vessels of the pia mater may contain little blood, but, on the other hand, they sometimes seem to contain a relatively larger amount than other parts of the body. In œdema of the brain and pia mater the vessels of the latter may contain but a small amount of blood.

ŒDEMA.

The quantity of serum beneath the pia mater and infiltrating its tissue is very variable in amount. It may accumulate as a result of atrophy of the brain substance or of venous hyperæmia, and sometimes is, and sometimes is not, accompanied by œdema of the brain substance. It may be diffuse or localized. It is not infrequent to find in hospital patients suffering from chronic nephritis, cardiac or pulmonary disease, or chronic alcoholism, a very considerable amount of serum in this situation, though the patient has been free from cerebral symptoms. In other cases a serous effusion may accompany grave cerebral symptoms. It is necessary to be very careful in judging of the importance of this accumulation of fluid, especially in determining the cause of death in the absence of other marked lesions.

It should always be borne in mind that an accumulation of fluid beneath the pia mater and in its meshes may occur as a result of post-mortem changes.

HYPERÆMIA AND HÆMORRHAGE.

Hyperæmia.—The pia mater may be hyperæmic in early stages of meningitis, in delirium tremens, in epileptic convulsions, in infectious diseases, and in poisoning. It may be due to the pressure of exudates or tumors on the veins, or to general or local lesions of the circulatory system. The time which elapsed between death and the autopsy, the position in which the body has lain, the coagulability of the blood, may have an important bearing upon the amount and situation of blood in the pia.

Hæmorrhage.—This may occur either into the space between the dura mater and the pia mater—*intermeningeal hæmorrhage*—or in the meshes of the pia or between the latter and the brain. It may be due to injury, to rupture of aneurisms or otherwise diseased blood-vessels, to thromboses of the venous sinuses, or to conditions which we are unable to ascertain. Hæmorrhages without known cause not infrequently occur in

the substance of the pia mater in young children, but in adults they are apt to be the result of injury. Multiple ecchymoses, however, in the substance of the pia mater sometimes occur in infectious diseases and also in acute inflammation of the pia mater. Hæmorrhages in the brain substance may lead to the accumulation of blood beneath or in the meshes of the pia mater. Intermeningeal hæmorrhage in infants as a result of injury during birth is not uncommon. Small, or sometimes considerable, extravasations of blood may occur from diapedesis, and sometimes, as a result of chronic congestion, degenerated blood pigment collects along the walls of the vessels. The extravasated blood in meningeal hæmorrhage, if small in quantity, may be largely absorbed, leaving a greater or smaller accumulation of pigment at the seat of the hæmorrhage. Such pigmentations may last for a long time.

INFLAMMATION. (Meningitis—Leptomeningitis.)

We distinguish acute, chronic, tuberculous, and syphilitic meningitis.

Acute Meningitis may occur as the characteristic lesion of epidemic cerebro-spinal meningitis; it is a not very infrequent complication of pneumonia, typhus and typhoid fever, the exanthemata, and of chronic diffuse nephritis; it may be secondary to injuries and inflammation of the cranial bones, of the dura mater, and of the middle ear, and it sometimes occurs as an independent infectious process.

In acute meningitis the inflammatory process is apt to extend downward and involve the pia mater of the cord. It may also involve the ependyma of the ventricles, and cause the distention of these cavities with serum. This latter condition is especially frequent in young children.

It is convenient to consider two varieties of acute meningitis, one in which there is cell proliferation with little or no exudate, the other in which exudate is present. In many cases at least, the first may be the early stage of the latter form.

1. **ACUTE CELLULAR MENINGITIS.**—The pia mater is congested, its surface is dry and lustreless, and it is somewhat opaque. The changes in the gross appearance of the membrane are not marked and are easily overlooked, but the minute changes are more decided. There is a proliferation of the endothelial and connective-tissue cells of the pia, and often a moderate collection of fluid and leucocytes in the meshes of the pia. This cell proliferation may involve the pia mater over most of the surface of the brain. This form of meningitis is of frequent occurrence and is attended with the ordinary clinical symptoms of acute meningitis.

2. **ACUTE EXUDATIVE MENINGITIS** is characterized by the accumulation, chiefly in the meshes of the pia mater and along the walls of the blood-vessels, of variable quantities of serum, fibrin, and pus. Sometimes one, sometimes another of these preponderates, giving rise to serous, fibrinous, or purulent forms of the inflammation. The absolute quantities of the exudations also vary greatly. In some cases death may occur with so slight a formation of exudate that to the naked eye

the pia mater may look quite normal or perhaps only moderately hyperæmic or œdematous; the microscope, however, in these cases will reveal pus cells in small numbers, newly formed connective-tissue cells (Fig. 636 and Fig. 637), and sometimes flakes of fibrin in the meshes of the pia and along the walls of the vessels. In other cases turbid serum in the meshes of the membrane is all that can be seen and the microscope shows the

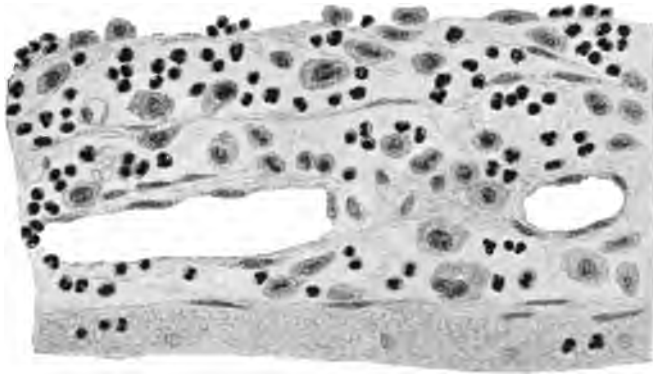


FIG. 636.—ACUTE EXUDATIVE MENINGITIS.

Showing distention of the meshes of the pia mater of the brain with fluid, in which are leucocytes and exfoliated endothelium, the latter undergoing proliferation.

turbidity to be due to pus cells or to a small amount of fibrin. Again, either with or without marked œdema of the pia mater, yellowish stripes are seen along the sides of the veins, sometimes appearing like faint turbid streaks, at other times dense, opaque, thick, and wide, and almost concealing the vessels. These are due to the accumulation of pus cells and fibrin in large quantities along the vessels, and are best

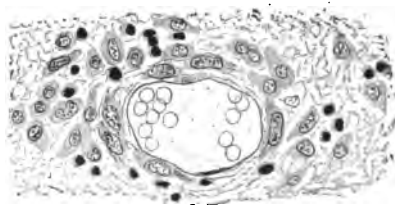


FIG. 637.—ACUTE EXUDATIVE MENINGITIS.

Proliferation of connective-tissue cells and extravasation of leucocytes in the adventitia of a small blood-vessel of the pia mater.

seen and most abundant around the larger veins which pass over the sulci. In still other cases the infiltration with pus and fibrin is so dense, thick, and general, that the brain tissues, convolutions, and most of the vessels of the pia mater themselves are concealed by it. This pus is usually of a greenish yellow color, and is sometimes so thick as to form a sort of cast of the brain surface at the seat of the lesion (Fig. 638).

Sometimes extravasated red blood cells are mingled with the other exudations, as the result of diapedesis. Microscopical examination shows numerous white blood cells sticking in the walls of the veins and capillaries, or the vessels may be blocked with them. It is evident that a large part of the pus cells accumulate as the result of emigration. The connective-tissue cells of the pia mater may be detached from their places or degenerated. The endothelial cells and other connective-tissue cells may proliferate. In some cases there are considerable accumulations of pus between the pia mater and the brain substance and along the vessels which enter the latter. More rarely pus is found upon the free surface of the membrane. The brain substance may be com-

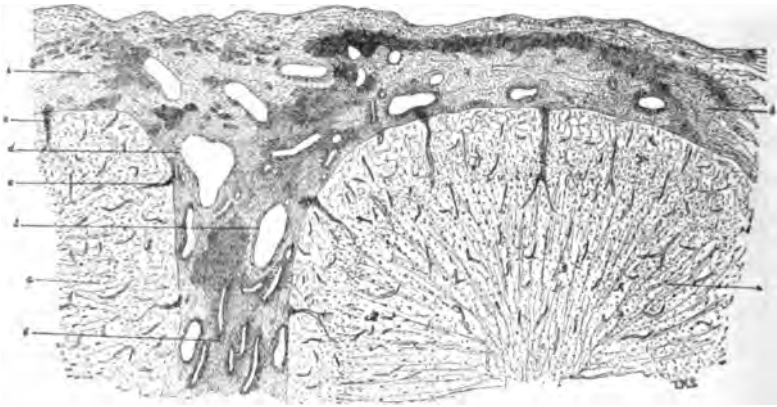


FIG. 638.—ACUTE EXUDATIVE MENINGITIS.

a, Convulsions of cerebrum; *b*, pia mater thickly infiltrated with pus; *c*, blood-vessels entering brain from pia and surrounded by a zone of pus cells; *d*, congested blood-vessels of pia mater; *e*, smaller blood-vessels of pia, around which pus cells are collected in dense masses.

pressed by the accumulated exudate, so that the convolutions are flattened. The cortical portion of the brain may be simply infiltrated with serum—œdematous—or it may undergo degenerative changes, or it may be the seat of punctate hæmorrhages. Not infrequently the inflammation extends to the ventricles which may contain purulent serum, and to the pia mater of the cord. This form of inflammation is most frequent on the convexity of the brain, but may extend or even be confined to the base. It may be localized, but frequently extends widely over the surfaces of the hemispheres.

When recovery from acute exudative meningitis occurs there may be fatty degeneration of the cells which have accumulated in the pia mater, particularly along the vessels (Fig. 639), and this may produce white patches in the membrane and threads along the blood-vessels, which resemble the appearance of an accumulation of exudate in the acute stage. Fatty degeneration of the blood-vessels and cells of the pia mater may also occur without acute inflammatory changes.

Sometimes, in children and young adults, inflammatory changes in

the ventricles persist for days and weeks after the subsidence of the inflammation of the pia mater.

For a discussion of the bacterial excitants of exudative meningitis see page 223.¹

Chronic Meningitis.—The entire pia mater may be involved or the inflammation may be confined to the base alone (basilar meningitis), or to the convexity alone, or to circumscribed patches of the membrane. The pia mater is thickened and opaque, the thickening being sometimes very considerable. There is a formation of new connective tissue and this may be associated with accumulation of pus, fibrin, and serum; the relative quantity of these inflammatory products varies in different cases.

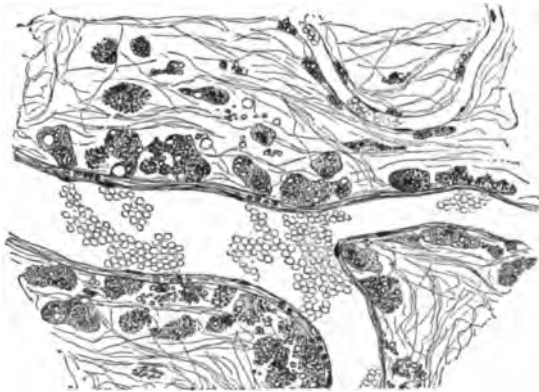


FIG. 639.—FATTY DEGENERATION OF CELLS ALONG THE BLOOD-VESSELS OF THE PIA MATER AFTER EXUDATIVE MENINGITIS.

From the pia mater of a child five years old.

Firm and sometimes extensive adhesions may be formed between the dura mater and the pia mater. Not infrequently the cortical portions of the brain participate in the process, and there is an infiltration of small spheroidal cells around the blood-vessels, thickening of the walls of the vessels, and degenerative changes and atrophy of the nerve tissue. New connective tissue may also form in the brain substance, which may become closely adherent to the pia mater. The ventricles of the brain also may contain an increased amount of serum and may be dilated, the ependyma may be thickened and roughened. This form of inflammation may be the result of injury or disease of the cranial bones, or secondary to chronic pachymeningitis or to inflammation of the brain substance. It may occur in the vicinity of tumors of the brain or meninges. It may be a complication of chronic diffuse nephritis or the result of chronic alcoholic poisoning. It may occur in marked form in general paresis of the insane.

¹ The close topographic relationships which the nasal cavities and the middle ear bear to the meninges are significant in this connection on account of the possibility of the transmission to the brain membranes of bacteria not uncommonly present and usually harmless in the former situations.

Tuberculous Meningitis.—This is especially characterized by the formation in the pia mater of miliary tubercles, associated with more or less well-marked exudative inflammation. It may occur in adults or in children, but is more common in the latter. The dura mater may be unchanged, or its inner surface may be sprinkled with miliary tubercles. The pia mater may or may not be congested; it may look dry on the surface or it may be œdematous. Usually the brain seems to fill the cerebral cavity to an unusual degree, and the convolutions are flattened. If the pia mater be œdematous the serum may be clear, or turbid with pus and fibrin. The membrane may present any of the general appearances of exudative meningitis, but always in addition to these, and sometimes without them, are found miliary tubercles. These may be few and widely scattered, or present in great numbers. They are most numerous along the blood-vessels, but may occur anywhere. They are usually abundant at the base of the brain. On the convexity they are most common along the surfaces of the sulci. Some of the tubercles are so small as to be scarcely visible or entirely invisible to the naked eye; others are as large as a pin's head or larger. They may be formed in the membranous prolongations of the pia mater which dip into the sulci, around the ves-

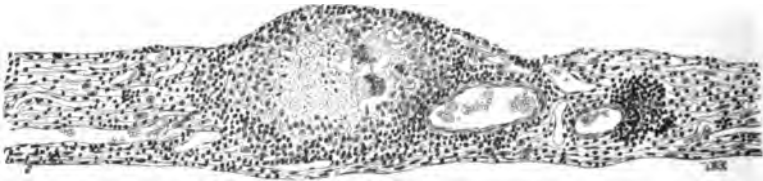


FIG. 640.—MILIARY TUBERCLE OF THE PIA MATER OF A CHILD.

There is an area of caseation at the centre; on the right of this are two giant cells; there is a peripheral zone of small cells. The leucocytes are increased in the meshes of the pia.

sels which enter the brain substance, in the choroid plexus and ependyma of the ventricles, and may exist in the spinal cord.

The miliary tubercles have the usual structural characters of focal tuberculosis in connective tissue (Fig. 640).

In children the ventricles are usually more or less distended by an accumulation of transparent or turbid serum, and the walls of the ventricles may be studded with miliary tubercles (see Fig. 641). In adults the ventricles are less frequently involved. The brain tissue around the ventricles is often softened. The central canal of the spinal cord may also be dilated. It is the dilatation of the ventricles which causes the flattening of the convolutions, and the flattening is usually in direct proportion to the amount of accumulated fluid.

Owing to the frequency of the dilatation of the ventricles with serum in children, the disease is often called *acute hydrocephalus*.

In both children and adults the tuberculous inflammation may produce large masses of tuberculous tissue, which undergo cheesy degeneration, and may involve the brain tissue.

In almost all cases of tuberculous meningitis there is tuberculous inflammation in other parts of the body.

Miliary tubercles in the choroid of the eye are present in a considerable proportion of cases.

The cortex of the brain may be hyperæmic, and punctate hæmorrhages may be present in the cortex and in the pia mater.

Syphilitic Meningitis.—In this form of inflammation, which is usually circumscribed, there is a development of gummy tumors of variable size, frequently associated with simple inflammation of the membrane, either with the formation of serum, fibrin, and pus, or with the development

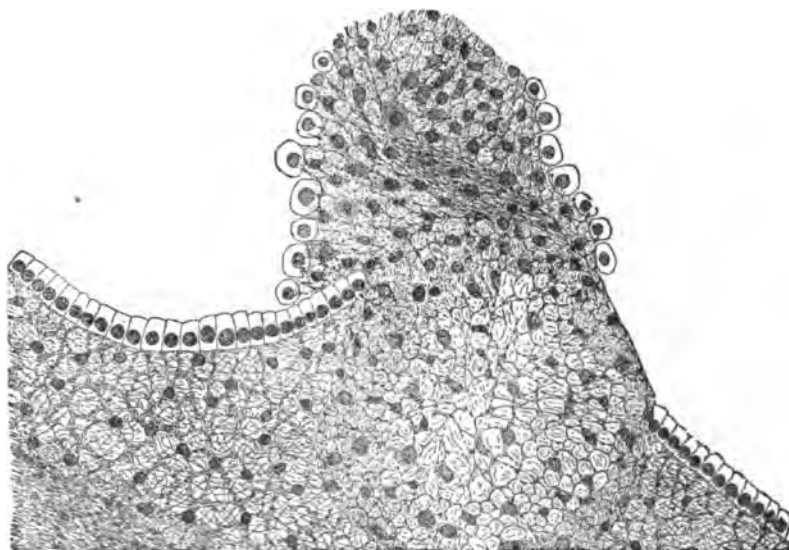


FIG. 641. —A MILIARY TUBERCLE OF THE EPENDYMA OF THE LATERAL VENTRICLE.
This shows an early stage of tubercle formation on the ependyma without marked caseation.

of new connective tissue and consequent thickening of the membrane. The gummata may form in the pia mater covering the convexity, or at the base of the brain. They may grow outward, involving the dura mater; or inward, encroaching upon or involving the brain tissue. Although usually circumscribed, syphilitic inflammation may occur as a diffuse thickening of the membrane. The syphilitic nodules, including the gummata and new-formed connective tissue, are often very small, but may be as large as a hen's egg.

TUMORS.

Hæmatoma.—In chronic pachymeningitis of long standing the new connective tissue may form large, flat cysts between the dura mater and the pia mater, which may compress the surface of the brain. The blood originally contained in these cysts may be absorbed and replaced by serum, the attachments to the dura mater may disappear, and the whole appearance becomes that of an independent cyst between the dura mater

and the pia mater. **Fibroma, lipoma, myxoma, chondroma, and osteoma** are of rare occurrence.

Endotheliomata.—These tumors are of not infrequent occurrence, and may grow from the pia of the cerebrum or cerebellum or from the choroid plexus. They may be single or multiple. They may be small or so large as seriously to compress the brain.

Some of them are composed of a connective-tissue stroma which encloses regular spaces filled with large, flat, nucleated cells. These may resemble carcinoma. Some of them are composed of a connective-tissue

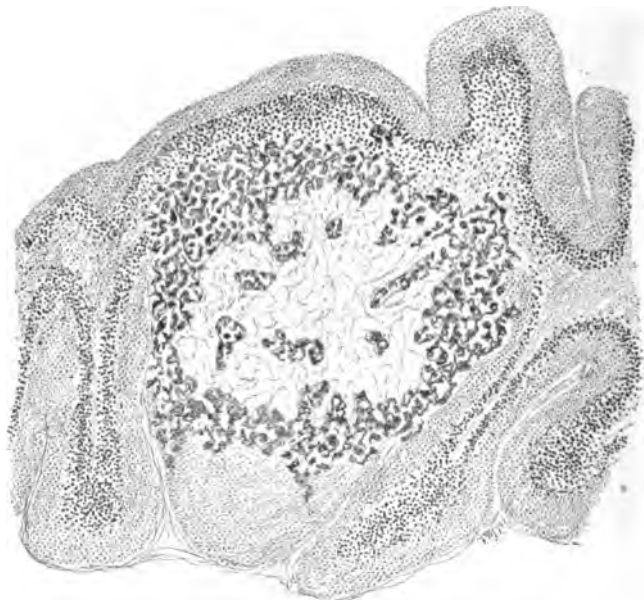

FIG. 642. —ENDOTHELIOMA OF THE CEREBELLUM ORIGINATING IN THE PIA MATER
Showing general appearance of the tumor (see Fig. 643).

stroma which forms cavities lined with cylindrical epithelium. In such tumors the stroma may grow so as to form papillæ covered with cylindrical epithelium; or in addition there may be mucous degeneration of the stroma. In some of them there is a connective-tissue stroma which contains large numbers of blood-vessels. Around these blood-vessels are arranged regular masses of polyhedral cells (Figs. 642 and 643).

In some endotheliomata the stroma is scanty. The cells are numerous, large, flat, and arranged in little globular masses or nests (Fig. 219). If in these little nests there is a deposition of the salts of lime, forming concretions like the so-called "brain sand," the tumor is called a "psammoma." Some of the tumors seem to be formed of very thin, nucleated membranes arranged concentrically like the layers of an onion.

Some of the tumors are composed of balls or nests of large, flat cells, with which are found crystals of cholesterin—"cholesteatoma."¹

¹ For a critical review of these and other pial tumors, with bibliography, see *Bostroem, Centrbl. f. allg. Path. u. path. Anat., Bd. viii., p. 1, 1897.*

Sarcoma.—Tumors belonging to the ordinary types of round- and fusiform-celled sarcoma, and of myxo-sarcoma, are occasionally found in the pia mater.

Cysts.—Small cysts are often found in the choroid plexus. Rarely such cysts reach a larger size, even as large as a pigeon's egg.

Cysts of the pia mater containing serum, with walls and septa of connective tissue, and compressing the brain, have been described.

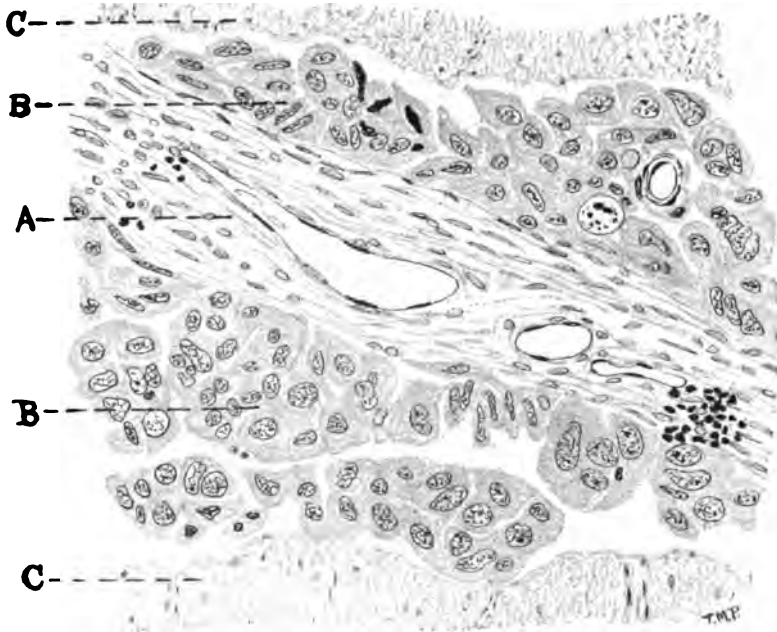


FIG. 643.—ENDOTHELIOMA OF THE PIA MATER OF THE CEREBELLUM.

From specimen shown in Fig. 642 more highly magnified. A, Section of pia mater dipping into a sulcus; B, tumor cells growing at each side of the pia; C, surface of cerebellar convolutions.

Variously shaped **pigment cells** not infrequently occur in the pia mater either scattered or sometimes in considerable masses; they seem to have little pathological significance. Not infrequently thin plates of newly formed **bone** are found in the pia mater, associated with a thickening of the membrane.

PARASITES.

Cysticercus has been observed in the pia mater.

The Dura Mater Spinalis.

The dura mater spinalis, unlike that of the brain, does not serve as periosteum to the bones forming the cavity, so that the lesions of the two membranes differ somewhat.

HÆMORRHAGE.

Hæmorrhage may occur, as the result of injury, between the dura mater and periosteum, or it may occur in tetanus, as a result of circulatory changes induced by muscular spasm, or in the asphyxia of newborn children. Small hæmorrhages on the surfaces of the membrane may occur as the result of inflammation.

Serous fluid may accumulate outside of the dura mater as a result of post-mortem changes, or in connection with circulatory or inflammatory changes in the membranes.

INFLAMMATION. (Pachymeningitis.)

Acute external pachymeningitis is usually secondary to disease or injury of the spinal column, and may result in collections of pus between the dura mater and periosteum, usually most abundant posteriorly. **Hæmorrhagic pachymeningitis** occurs in the dura mater spinalis, with the formation of products similar to those observed in the brain, in the chronic insane, and in drunkards. **Simple chronic pachymeningitis interna**, with the formation of new connective tissue containing brain sand, is not infrequent. The new tissue may form minute projections from the surface, or, when more abundant, may take the form of **psammomata**. **Tuberculous inflammation** of the dura mater spinalis may occur in connection with tuberculous meningitis, or be secondary to tuberculous inflammation of the vertebræ.

TUMORS.

Fibromata, lipomata, chondromata, myxomata, endotheliomata, and adenosarcomata occur in the dura mater spinalis as primary tumors. **Carcinomata** and **sarcomata** may be found as secondary tumors. Small plates of newly formed **bone** are of rare occurrence.

PARASITES.

Echinococcus developing outside of the spinal canal may perforate the dura mater; or the cysts may lie between the dura mater and the pia mater.

The Pia Mater Spinalis.

It is difficult in most cases in the pia mater, as well as in the dura mater spinalis and in the spinal cord, to judge with certainty, from the appearances after death of the blood contents of the vessels, of these parts during life. The same is true of abnormal quantities of serum found after death. The veins of the pia mater, especially in the posterior region, may be greatly distended with blood after death, without pre-existing disease; and the intermeningeal space may contain much fluid under the same condition.

HÆMORRHAGE.

Hæmorrhages may occur from injury, in connection with severe convulsions, or in general diseases such as the hæmorrhagic diathesis, scurvy,

smallpox, etc. The hæmorrhages under these conditions, except from injury, are not usually extensive. But in some cases of injury or cerebral apoplexy, from the bursting of aneurisms of the basilar or vertebral arteries, or in cases in which we cannot find a cause, a very large quantity of blood may collect between the dura and pia mater, and in the meshes of or beneath the latter.

INFLAMMATION. (Meningitis.)

Acute exudative spinal meningitis occurs under essentially the same conditions and with essentially the same post-mortem appearances as acute cerebral meningitis, though it is less frequent. The exudate is apt to be most abundant in the posterior portions. It may be associated with a similar inflammation of the pia mater cerebri, and the inner surface of the dura mater may be involved. The disease may be circumscribed, but usually affects the entire length of the membrane.

Chronic spinal meningitis is not infrequent, manifesting itself in the formation of larger or smaller patches of new connective tissue or in

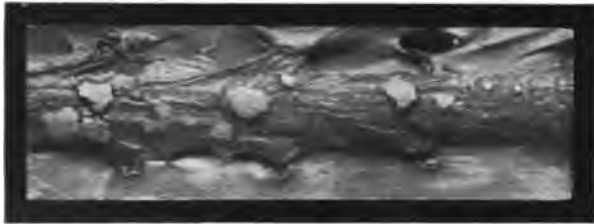


FIG. 644.—PLATES OF BONE IN THE PIA MATER SPINALIS.

thickenings of the pia mater. The pia and dura mater may thus be firmly united in places by adhesions, or the pia mater may become closely adherent to the substance of the cord.

Not very infrequently large numbers of pigment cells are found in the pia mater spinalis, sometimes giving it a distinct gray or blackish color.

Tuberculous inflammation is usually associated with a similar condition of the pia mater cerebri, in which case the lesion is most marked in the upper portions of the cord; but it may extend over the entire membrane. The conditions under which it occurs and the character of the lesions are similar in both.

TUMORS.

Fibromata, myxomata, sarcomata, and endotheliomata have been found.

Small plates of **cartilage** and **bone** (Fig. 644) are sometimes found in the pia mater.

PARASITES.

Cysticercus sometimes occurs in the meshes of the pia mater.

THE VENTRICLES OF THE BRAIN. THE EPENDYMA AND CHOROID PLEXUS.

GENERAL CONSIDERATIONS.

As the lymph-spaces of the pia mater and the ventricles of the brain are in communication, it might be supposed that they would share alike in the accumulation of fluids. This, however, is not the case. The membranes of the brain may be highly œdematous while the ventricles contain about the normal quantity of fluid; or, on the other hand, the ventricles may be widely dilated and the pia mater unusually dry. Many of these varying conditions may be understood by remembering that the skull and spinal canal form a closed cavity, and that accumulations of fluid in one part must be at the expense of some material occupying other parts, either blood, serum, or brain tissue. It is not always easy to see, however, exactly how the compensation occurs.

There may be an unusual amount of fluid in the ventricles of the brain as a result of post-mortem change; in connection with senile or other atrophy of the brain, or in the general vascular changes which lead to œdema of the brain; in connection with inflammation of the meninges or of the ependyma; or under conditions which we do not understand, as in some cases of congenital and acquired hydrocephalus. Accumulations of fluid in the ventricles are often called *internal hydrocephalus* to distinguish them from accumulations in the meninges—*external hydrocephalus*.

INFLAMMATION. (Ependymitis.)

Acute Ependymitis.—In this condition, which may occur by itself, but is usually associated with inflammation of other parts of the brain, the ependyma is congested, the vessels are more prominent than usual and are often tortuous. The ependyma and the adjacent brain tissue may be thickened and infiltrated with pus cells, and the surface of the ependyma covered with fibrin and pus in variable quantity (Fig. 645). The cavities of the ventricles may contain purulent serum. Small hæmorrhages may also be present in the tissue of the ependyma. This, as well as other forms of inflammation, is more common in the lateral ventricles than in the others, but not infrequently involves the fourth ventricle. The choroid plexus may participate in the inflammatory changes of the ependyma. Tuberculous inflammation of the ependyma is, as above mentioned, a not infrequent accompaniment of tuberculous meningitis.

Chronic Ependymitis.—This lesion, which is much more common than simple acute inflammation of the ependyma, occurs under a variety of conditions, and its nature and causation are in general very obscure. The ependyma is thicker, whiter, and more opaque than normal, so that the vessels may be nearly or quite invisible. The thickenings may occur in patches or diffusely, and the surface of the ependyma may be smooth, or roughened and granular. On microscopical examination the surface of the ependyma may be covered with the usual epithelium, but the new connective tissue which forms beneath it often raises it up in

places, causing the roughness of the surface. The new tissue is usually rather loose in texture and may contain many small spheroidal cells; but it may be dense in texture and contain few cells. The brain tissue beneath the thickened ependyma may be softened or infiltrated with cells. The sides of the ventricles may be grown together in places by the adhesion of the thickened and roughened ependyma. The ventricles usually contain more serum than normal, and sometimes this accumulation is so great as to cause an enormous dilatation of them. While these are in general the prominent lesions in chronic inflammation of the epen-

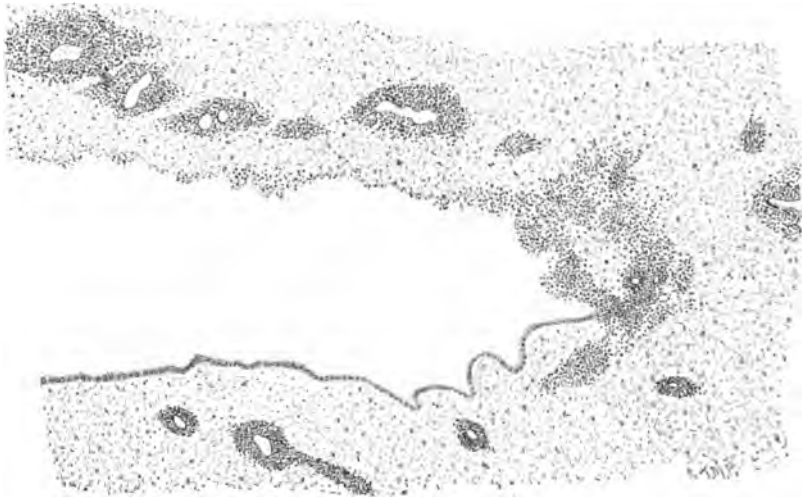


FIG. 645.—ACUTE EPENDYMITIS.

Showing replacement of the epithelium of the ventricle by inflammatory exudate: collections of pus cells near the epithelium and about the adjacent small blood-vessels.

dyma, the comparative development of the several lesions varies greatly in different cases.

The accumulation of fluid and the dilatation of the ventricles being the most marked feature in all this class of lesions, they are often called *chronic hydrocephalus*, but in many cases we have no evidence that the change in the ependyma is an important or even an actual primary factor.

Hydrocephalus.—We may, for convenience of study, consider three classes of cases of hydrocephalus: first, *congenital hydrocephalus in young children*; second, *secondary hydrocephalus in children and adults*; third, *primary hydrocephalus in adults*.

1. **CONGENITAL HYDROCEPHALUS.**—The lesion may be in an advanced stage at the time of birth, or it may be scarcely evident or but moderately developed. It may progress rapidly and cause the early death of the child, or it may develop gradually or come to a standstill. In the more marked forms of the disease the ventricles are widely dilated

(Fig. 646) and filled with serum, which is usually transparent. Not only the lateral ventricles, but also the third and fifth, may be involved; the fourth is less apt to participate in the lesion, although it is sometimes dilated, as well as the central canal of the cord.

The distention, especially of the lateral ventricles, may be so great that the brain tissue over the vertex is crowded up into a thin layer beneath the dura mater, or it may be entirely destroyed. When the dilatation of the ventricles is considerable, the convolutions are flattened and may be almost entirely obliterated. The skull bones may be thin and bulging over the forehead and vertex; the fontanelles and sutures

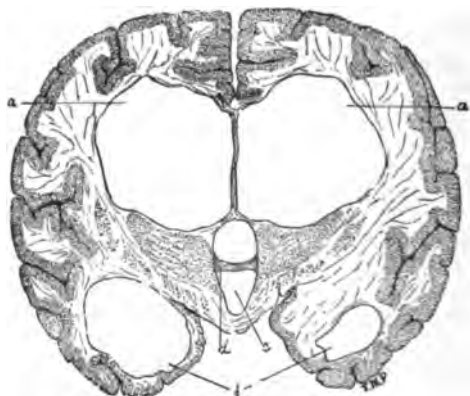

FIG. 646.—CONGENITAL HYDROCEPHALUS IN CHILD. About half natural size.
a, a, Dilated lateral ventricles; b, cornua, unequally dilated; c, third ventricle; d, middle commissure.

widely open. The ependyma in these cases is usually thick and rough, but it may be softened, and the blood-vessels may be dilated. The basal portions of the brain may be flattened, but are usually much less affected than the upper portions. The brain tissue is usually soft and anæmic.

2. SECONDARY HYDROCEPHALUS.—This may occur in children and adults, and may be a result of epidemic cerebro-spinal meningitis, or of acute meningitis, or of chronic meningitis. It sometimes occurs in chronic alcoholic poisoning and in general paralysis of the insane. The amount of dilatation of the ventricles varies greatly in these cases, but it is never so great as in congenital hydrocephalus, and is not accompanied by the changes in the shape of the skull which form so prominent a feature in the latter disease, since the bones are firmer and the sutures united. In this form of chronic hydrocephalus the changes in the ependyma above described are usually more or less well marked, and they may be associated with the production of fibrin and pus.

3. PRIMARY HYDROCEPHALUS IN ADULTS.—The conditions leading to this form of lesion are not understood. It is apt to occur in persons over thirty years of age. Sometimes one, sometimes both lateral ventricles are dilated. The dilatation is usually moderate, sometimes very slight and never as great as in congenital hydrocephalus. The ven-

tricles usually contain transparent serum, and the *ependyma* is thickened and roughened. In some cases it is the only lesion found to account for the death of the patient.

TUMORS.

New formations of connective tissue in the *ependyma*, although usually diffuse, may be circumscribed, and form small, projecting connective-tissue nodules, which may be classed among the **fibromata**. Small fibromata are sometimes detached from the walls of the ventricles and lie free in the cavity. Small **lipomata**, **angiomata**, and also **sarcomata** and **gliomata** occur rarely. **Chondromata** and **angiomata** may occur in the *choroid plexus*, the latter sometimes being as large as a hen's egg. The choroid plexus is not infrequently the seat of transparent **cysts**, usually of small size; they may contain a clear fluid, or colloid material, or droplets of fat, or calcareous particles. A small **dermoid cyst** containing hairs has been described. The cysts have no special pathological significance.

Primary **carcinomata** sometimes involve the ventricles.

The calcareous bodies called **brain sand**¹ (see Fig. 634) occur frequently in the choroid plexus, and **corpora amylacea** may occur here and beneath the *ependyma*.

PARASITES.

Cysticercus and **echinococcus** cysts are sometimes attached to the walls of the ventricles or may be free in their cavities.

The Brain and Spinal Cord.

Malformations of the Brain.

CYCLOPIA.—This malformation consists in an arrest of development affecting the cerebrum, which, instead of separating into two hemispheres, remains single, with one ventricle, the rudiments of the eyes usually uniting to form one eye (Fig. 177). This single eye is in the middle of the face, near the place of the root of the nose, in a single orbit. Over this is an irregular body representing the nose. The rest of the face is well formed. The eyeball may be wanting entirely, or there may be two eyes joined together, or, more seldom, two separate eyes. The orbit is surrounded by rudiments of four eyelids. The frontal bone is single, the nasal bones are undeveloped; the ethmoid, vomer, and turbinate bones are absent. The optic nerve is double, single, or absent. There may be hydrocephalus. Such children are incapable of prolonged existence.

ANENCEPHALIA.—This malformation may be of various degrees. The brain may be entirely absent, the base of the cranium being covered with a thick membrane, into which the nerves pass. The membranes may form a sort of cyst containing blood and serum or portions of brain. Of the cranial bones, only those which form the base of the skull are present (*acrania*). The scalp is usually partly or entirely absent over the opening in the skull; the eyes are prominent, and the forehead slopes sharply backward. This malformation may occur in otherwise well-developed children.

HYDROCEPHALUS.—This lesion has been already considered above. It is probable that in some cases *hydrocephalus internus* is due to a primary *partial anencephalia*,

¹ The little, hard masses called *brain sand* consist of aggregations of small particles of carbonate and phosphate of lime with a small amount of phosphate of ammonia and magnesium. With these there is more or less organic matter.

and that the accumulation of fluid is of secondary occurrence. In rare cases, only part of one lateral ventricle is hydrocephalic, giving to the head a protuberance on one side. The viability of the fœtus depends upon the degree of the hydrocephalus. *Hydrocephalus externus* is an accumulation of serum beneath the pia mater, or, according to some authors, between the pia and dura mater. It causes dilatation of the cranium and compression of the brain. It is of very rare occurrence, and may also be secondary to partial anencephalia.

CEPHALOCELE, OR BRAIN HERNIA.—When abnormal openings exist in the skull from malformation, the contents of the cerebral cavity are apt to protrude in the form of larger or smaller sacs. This may occur in cases of well-marked anencephalia or in cases in which the brain is well developed. The protruding sac formed of the meninges may or may not be covered with skin. If the contents of the sac are simply fluid, the lesion is called *hydromeningocele*; if composed of brain substance, *encephalocele* (Fig. 181); if the sac contain both fluid and brain substance, it is called *hydrencephalocele*. The sacs may be very small or as large as a child's head. They may protrude from the top of the skull in acrania. They most frequently protrude through openings in the occipital bone, often hanging down in large sacs upon the neck; also at the root of the nose, along the line of the sutures, at the base of the skull, and elsewhere.

MICROCEPHALIA.—This is an abnormally small size of the brain, with a correspondingly small cranium. The diminution in size affects principally the cerebral hemispheres, though the other parts of the brain are also small. Thus the cerebellum may be of extremely small size. The cord may be smaller than normal, in which case the diminution in size is apt to show a direct dependence upon the cerebral lesions, the direct and the crossed pyramidal tracts being most affected. There may also be present imperfect development of the posterior columns and of the direct cerebellar tracts. The convolutions are few and simple, the cavities often dilated with serum; on the membranes there may be traces of inflammation. The cranium is small, the face large, the rest of the body small. This malformation is in some cases caused by inflammation or dropsy of the brain during foetal life. It is endemic in some countries, but single cases may occur anywhere. The fœtus is viable. Absence or incomplete development of portions of the brain may occur, not only in idiots, but in persons whose minds are perfect.¹

Malformations of the Spinal Cord.

The malformations of the spinal cord may be conveniently classed as follows (Van Gieson²):

I. CONGENITAL DEFORMITIES ASSOCIATED WITH MONSTROSITIES, AND INCOMPATIBLE WITH EXTRA-UTERINE LIFE.

These may be divided into:

1. *Amyelia*, or absence of the spinal cord. This is almost invariably associated with absence of the brain.
2. *Atelomyelia*, or partial development of the spinal cord. This is often seen in the anencephalous or acephalic monsters, where, corresponding to the incompletely developed brain, there may be various degrees of defective development of the cord.
3. *Diastematomyelia*, a condition in which a portion or the whole of the cord is split into two lateral halves. Each half of the cord is developed in its own membranes and gives rise to its own nerve roots. There may be union at one or more points to form a single cord.
4. *Diplomyelia*, or a formation of two spinal cords—a duplication of the spinal cord. This happens in the various kinds of double monsters.

¹ For a general consideration of malformations of the central nervous system consult *Thoma*, "Text-book of Pathological Anatomy," vol. i., p. 206 et seq., also *Ernst* in *Schwalbe's morphologie d. Missbildungen des Menschen u. Tiere*, 1909.

² *Van Gieson*, "Artefacts of the Nervous System," *New York Medical Journal*, vol. lvi., pp. 337, 365, 421, 1892.

II. MINOR CONGENITAL MALFORMATIONS NOT INCONSISTENT WITH THE MAINTENANCE OF LIFE.

1. *Hydrorrhachis interna* is a defective closure or arrangement of the divisions of the primary foetal central canal often resulting in the dilatation of the central canal by fluid (*Hydromyelia*) (Fig. 647). This dilatation may be moderate, or so extreme that but little of the substance of the cord is left as a thin shell around the central cavity. When they have not been destroyed by atrophy epithelial cells may be found lining the cavity.

This condition may be accidentally found after death. Its presence may also be indicated by its association with spina bifida.¹

2. *Heterotopia*, or misplacement of the substances of the cord.

(a) There may be misplaced portions of the gray matter.

(b) Portions of the white matter may be arranged in an unusual manner.

3. *Anomalies of the Spinal Nerve Roots*.

4. *Asymmetries of the Spinal Cord*.

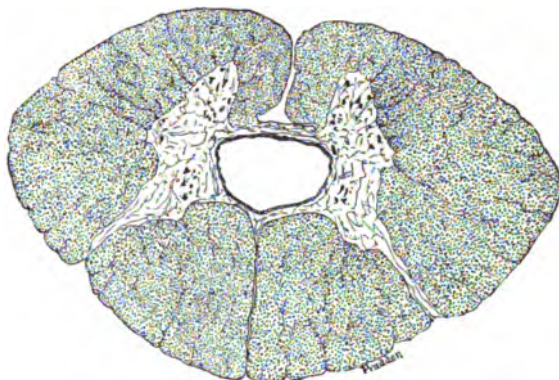


FIG. 647.—HYDROMYELIA.

In the section from which this drawing was made, the epithelial cells surrounding the dilated central canal were well preserved.

III. MALFORMATIONS OF THE SPINAL CORD ACQUIRED DURING EXTRA-UTERINE LIFE OR SECONDARY TO DEFECTIVE DEVELOPMENT IN OTHER PARTS OF THE BODY.

1. Distortions following other cord lesions.

2. Asymmetry of the cord due to arrested development after birth or to secondary atrophy of portions of the cord in association with defective development or absence of some other part of the body.

3. Asymmetry of the cord with congenital defects of the extremities or muscles, such as intra-uterine or other amputations, clubfoot, etc.

4. Variations in the volume of the cord as a whole.

FALSE HETEROTOPIA.—Congenital displacement of the gray or white matter of the spinal cord—*heterotopia*—has been frequently described. Van Gieson² has shown, however, that in a large proportion of cases the so-called heterotopia is an artefact (Fig. 648) and has been caused by bruises or careless handling of the cord during its removal from the body or in the process of examination or hardening.

SPINA BIFIDA.—In the majority of cases hydrorrhachis is accompanied by a more or less complete lack of closure of the spinal canal posteriorly, so that the collections of fluid within may pouch outward through the opening in the form of a sac. The sac may be covered by skin, or this may be absent, either from the beginning or as a result

¹ Under this subdivision the condition known as *hydrorrhachis externa* may be conveniently alluded to, which consists in an abnormal congenital accumulation of fluid between the meninges of the cord, causing more or less diminution in the volume of the latter.

² *Van Gieson*, New York Medical Journal, vol. lvi., pp. 337, 365, 421, 1892.

of thinning and rupture. The walls of the sac may consist of the dura mater and the pia mater, or, in cases of *hydrorrhachis externa*, of the dura mater alone. When both are present they are usually more or less fused together. Inside of the membranes of the sac there may be a shell of distended nerve tissue of the cord; or the spinal cord may be split posteriorly and the sides crowded sideways; or there may be a rudimentary fragment of the cord suspended in the sac or attached to the walls; or the cord may be but little changed and remain inside the spinal canal. The openings in the spinal canal may be due to the complete or partial absence of the vertebral arches, or

more rarely the sac may protrude through openings between the completely formed arches. *Spina bifida* most frequently occurs in the lumbar and sacral regions, but it may occur in the dorsal or cervical regions, or the canal may be open over its entire length. Very rarely it is open on the anterior surface. The protruding sac may be very small or as large as a child's head. The fluid in the sac is usually clear, but may be turbid from flocculi of degenerated nerve tissue.

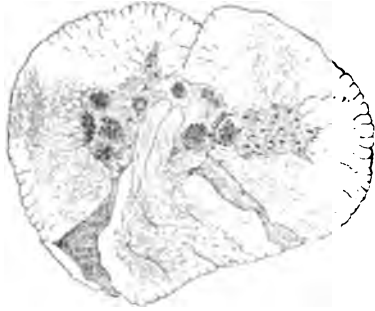

FIG. 648.—FALSE HETEROTOPIA. SECTION FROM CERVICAL REGION OF SPINAL CORD.

Showing artificial displacement of the structures by an experimental bruise ("false heterotopia") after the removal of the cord from the body. (Van Gieson.)

INJURIES OF THE BRAIN.

The brain may be directly wounded by a foreign body, or indirectly by fragments of bone driven into it, or it may be lacerated by severe contusion without fracture or solution of con-

tinuity of the skull. Very severe injuries of the brain are often caused in parts of the organ remote from the seat of violence. Thus blows on the skull frequently cause laceration of the brain on the opposite side. This is called injury by *contrecoup*. It is very difficult to estimate the degree of injury which must cause death, since some persons die from slight, and others recover from very severe, wounds of the brain. In incised wounds of the brain more or less hæmorrhage occurs at the seat of lesion, and the brain tissue in the vicinity soon undergoes degenerative changes. These may be comparatively slight or extensive. Inflammatory reaction may occur in the vicinity, and the adjacent brain tissue, as well as the hæmorrhagic and degenerated area, may become infiltrated with pus cells. After a time the injured and degenerated area may become surrounded by new-formed connective tissue, and the decomposed extravasated blood and detritus of brain tissue, more or less fatty, may be absorbed. In this way the part heals, leaving a somewhat pigmented cicatrix. The healing is in most cases very slow and may occupy months or even years. The pia mater may participate to a marked degree in the inflammatory healing process. Abscesses may form near the seat of injury.

After wounds which involve the removal of portions of the cranial bones, it is not uncommon after a few days to see a bleeding fungous mass projecting through the opening. This mass, sometimes wrongly called *hernia cerebri*, consists of degenerated brain tissue, blood, and granulation tissue, with more or less pus. The brain tissue below it is degenerated, soft, broken down, and purulent, and there is often abscess

in the adjacent brain tissue. Such wounds may finally heal by the absorption of the broken-down brain tissue and blood, and its replacement by granulation tissue.

Lacerations of the brain tissue without fracture may appear shortly after the injury as simple more or less circumscribed areas of capillary hæmorrhage; the brain tissue about these may degenerate, pus may form, and abscesses be developed; or the degenerated and lacerated tissue may be gradually replaced by granulation tissue which finally forms a cicatrix. The process of degeneration and softening and of healing in such lacerations of brain tissue may occur very slowly indeed, even occupying years, and not infrequently the degenerative changes are very extensive and progressive. In many cases, of course, the injury is so extensive, or involves such important parts of the organ, that very little or no inflammatory or degenerative change takes place before death.

INJURIES OF THE CORD.

The spinal cord may be compressed or lacerated by penetrating wounds, by fracture or dislocation of the vertebræ, or by concussion without injury to the vertebræ. The spinal cord is found simply disintegrated, or there may be much hæmorrhage and the disintegrated nerve tissue be mixed with blood. If life continue, the nerve elements may degenerate; Gluge's corpuscles and free fat droplets may form; blood pigments may be formed; and when inflammation supervenes more or less pus may be intermingled with the degenerated material. There may be marked changes in the minute structure of the cord, without any change being evident to the naked eye.

INJURIES OF THE NERVES.

The secondary effects of injuries to nerves are described in the section on degenerations following injury. After amputation of a limb, there often occur swellings of the peripheral ends of the divided nerve trunks. These bulbous ends are called false or amputation neuromata. They are made up almost entirely of fibrous tissue, although nerve fibres have been found in them.

HYPERTROPHY AND ATROPHY OF THE BRAIN.

True Hypertrophy of the brain is rare, and probably always congenital. An increase in the size of the brain from the proliferation of the neuroglia sometimes occurs in children either before or after birth, less frequently in youths, and very seldom in adults. The white substance of the hemispheres is increased in amount. If it takes place before the ossification of the cranium, the bones are separated at the sutures and fontanelles; if after this, the inner table of the skull may be eroded and thinned. When the cranium is opened the dura mater appears tense and anæmic, the convolutions of the brain are flattened, the brain substance

is firm and anæmic, the ventricles are small, the ganglia and cerebellum are either of normal size or compressed.

The disease is usually very chronic, and destroys life with symptoms of compression of the brain. There may, however, be acute exacerbations.

Atrophy.—This may occur as a senile change, or, in chronic alcohol, opium, or lead poisoning, in chronic insanity, and in chronic meningitis, or from local interference with the circulation. In children who are much reduced by chronic diseases atrophy of the brain may accompany atrophy of the rest of the body.

The atrophy affects principally the cerebral hemispheres, and may be uniform or more marked in some parts than in others, involving the

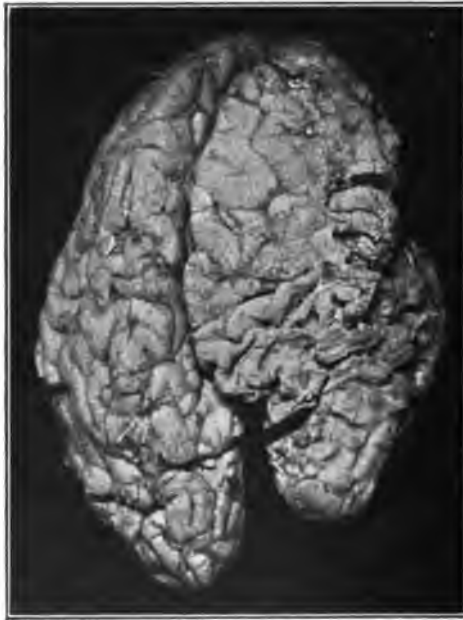

FIG. 649. ATROPHY OF A CIRCUMSCRIBED PORTION OF BRAIN CONVOLUTIONS IN A CHILD.
From a lesion of the corresponding blood-vessels.

whole of a hemisphere or of a lobe or only single convolutions or groups of these (Fig. 649). The convolutions are small, the sulci broad, the ventricles usually dilated, the brain tissue is firm, the gray matter discolored, the white substance grayish in color; the blood-vessels may be dilated. The basal ganglia may be small. Serum accumulates in the pia mater and in the ventricles; the pia mater, and often the skull, become thickened; the brain tissue may be œdematous or contain small hæmorrhages. The nerve elements of the brain tissue are those most involved in the atrophy, the diminished areas being usually harder and firmer than normal.

PIGMENTATION OF THE BRAIN.

This may occur in any portion of the brain or its meninges from the decomposition of extravasated blood. In persons affected by malaria the gray matter of the brain has sometimes a dark or even blackish appearance. This color is due to the presence of black pigment granules within the capillary blood-vessels. The obstruction to the vessels by masses of these pigment granules may cause capillary apoplexies. The pigment may also be found in the walls and in the lumina of the vessels of the pia mater.

Pigment patches of congenital origin are not infrequently seen in the pia mater. They may be due to the presence of branching pigmented cells.

CIRCULATORY AND VASCULAR CHANGES IN THE BRAIN AND SPINAL CORD.

Anatomical Considerations.

In studying the circulatory changes in the brain and cord certain peculiarities in that circulation should be borne in mind. The vessels which nourish the brain arise from a remarkable anastomosis of large arterial trunks at its base, known as the circle of Willis (see diagram Fig. 650). From this "circle" pass off to each hemisphere three main branches—the anterior, the middle, and the posterior cerebral. These arteries ramify in the pia, where they anastomose freely. From this anastomosis small branches are given off which penetrate the brain substance, the shorter breaking up into capillaries in the gray matter, the longer passing to the underlying white matter. After entering the cortex there is no further anastomosis, the capillaries of a cortical artery passing directly over into a venous system of capillaries without communicating with capillaries of other arteries. They are thus "terminal arteries." In addition to these arteries, which supply the hemispheres, branches from the circle of Willis are distributed to the basal ganglia. These arteries are much larger than those which pass from the pia into the cortex, and beyond the circle of Willis do not form anastomoses with one another. Thus it is that occlusions of the arteries supplying the basal ganglia are much more serious, aside from the importance of the parts involved, than of those passing to the cortex.

Three main arteries furnish blood to the cord: the anterior spinal, lying along the opening of the anterior median fissure, and two posterior spinal, lying near the entrances of the posterior roots. Branches of these arteries anastomose in the pia, and from this pial network branches pass directly into the substance of the cord. The largest, a branch of the anterior spinal, passes into the pia of the anterior fissure, and, penetrating the cord, is distributed to the gray matter of the anterior horn, and to the median gray matter as far back as Clarke's column. Smaller arteries from the posterior spinal supply the posterior regions of the cord. These arteries, like those in the brain, are terminal in the sense that, while anastomosing freely in the pia, after penetrating the substance of the cord there are no further anastomoses.

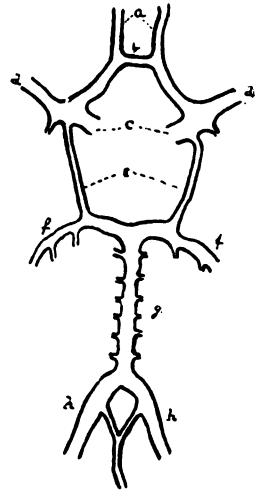


FIG. 650.—DIAGRAM OF THE CIRCLE OF WILLIS AND ASSOCIATED VESSELS.

a, Anterior cerebral; *b*, anterior communicating; *c*, internal carotids; *d*, middle cerebral; *e*, posterior communicating; *f*, posterior cerebral; *g*, basilar; *h*, vertebral.

HYPERÆMIA AND ANÆMIA.

The appearance of the brain tissue after death does not always furnish reliable indications of its blood contents during life, though it is perhaps more to be depended on than the appearance of the meninges.

Some of the more common conditions determining *hyperæmia* which are mentioned above as influencing the meninges apply also to the substance of the brain.

Active hyperæmia may occur in various inflammatory conditions of the brain. Hyperæmia of the brain is quite common in deaths from insolation and after conditions accompanied by acute delirium. **Passive hyperæmia** may occur in conditions similar to those which determine congestions in other organs of the body, such as chronic diseases of the heart or lungs. It may be induced by anything which prevents venous return, such as intracranial tumors which compress the sinuses, or by thrombosis.

In sections of hyperæmic brains the small blood-points from the cut ends of small vessels are more numerous and conspicuous than under normal conditions, and the brain tissue, particularly the gray matter, may have a diffuse red color. If excessive, the convolutions may be somewhat flattened, the brain tissue and pia mater may be œdematous, and the ventricles contain fluid. The congestion of the vessels may be general or localized.

The most constant lesion of what is known as caisson disease, a condition resulting from exposure to sudden changes in atmospheric pressure, is a congestion of the brain, cord, and meninges. Areas of softening in the brain and cord are not infrequent and there may be effusion into the meninges.

Anæmia of the brain may be either local or general. It may depend upon a general anæmia or upon general disturbances of the circulation, such as mitral stenosis or regurgitation; or upon local interference with the arterial blood supply, such as complete or partial obstruction of the arteries from thrombi, emboli, inflammatory changes, spasmodic contractions, etc., or from tumors, exudations, and blood extravasations pressing upon the vessels from without. In œdema of the meninges, and in the presence of internal hydrocephalus, the brain tissue is apt to be anæmic. The brain tissue in anæmia looks whiter than usual, the contrast between the gray and the white matter is less marked, and the small blood-points usually seen on section from divided vessels may be very inconspicuous or almost entirely absent.

ŒDEMA.

Œdema of the brain tissue may accompany either general or localized hyperæmia, or it may accompany anæmia, and it seems in most cases, though not always, to be dependent upon conditions which induce these alterations in the blood contents of the brain. It is, perhaps, most common in conditions which determine a passive hyperæmia. In some cases

of marked impoverishment of the blood a so-called *hydræmic œdema* of the brain is found.

In œdema the brain tissue appears unusually wet and shiny. The same underlying condition is apt to determine an exudation into the membranes and ventricles. There is usually considerable distention of the perivascular lymph-spaces.

Marked œdema of the brain may exist without brain symptoms. On the other hand, persons may die comatose with no other gross lesion than œdema, either with or without œdema of the pia mater. This is seen with especial frequency in acute and chronic alcohol poisoning, but may occur under other conditions. A careful microscopical examination of the brain under these conditions will frequently reveal structural lesions of more serious import than the œdema.

Under the designation of "serous apoplexy," œdema of the brain was formerly considered of importance, in the absence of other lesions, as a cause of death. But increased knowledge has led to the general belief that simple cerebral œdema as an independent condition has not the significance formerly ascribed to it, and it should be accepted, if ever, with great reserve as a cause of death.

HÆMORRHAGE.

Hæmorrhages in the substance of the brain may be very small and punctate, and are then usually called *capillary hæmorrhages*; or they may result in the collection in the brain tissue of masses of blood of considerable size, which are called *apoplectic foci* or clots. These forms of hæmorrhages may be associated, or a number of capillary hæmorrhages may join to form an extensive clot.

Capillary hæmorrhages may appear, on section of the brain, like the severed ends of hyperæmic blood-vessels, or the tissue about them may be more or less tinged with blood. Microscopically, the perivascular spaces are distended with blood, which may have escaped into them. This is associated with more or less broken-down brain tissue. The hæmorrhages may be single, but are frequently multiple, so that the brain tissue is besprinkled with blood-points. Degeneration of the extravasated blood may give rise in later stages to reddish or brown or yellowish circumscribed discoloration of the brain tissue, due to granules and crystals of blood pigment intermingled with broken-down brain tissue, with more or less fatty degeneration of its elements. Capillary hæmorrhages may be due to fatty degeneration of the vessels leading to rupture; or the extravasation may be due to diapedesis, or it may depend upon conditions which we do not understand. They frequently occur in the vicinity of apoplectic clots and tumors, they may be due to thrombosis of the veins or of the sinuses of the dura mater; they not infrequently occur in acute encephalitis, in congestive hyperæmia, in acute mania, and in delirium tremens; and they may be associated with general diseases, such as scurvy, purpura hæmorrhagica, typhus fever, pyæmia, ulcerative endocarditis, etc.; they may be associated with embolic softening.

Apoplectic foci may result from the coalescence of numerous capillary hæmorrhages; from injury; or from rupture of diseased arteries, either with or without changes in the blood pressure. Hæmorrhages from injury to the skull may occur as well without as with fracture, and may be situated over the vertex or at the base of the brain. They vary in extent and location, depending upon the character and point of the injury and the size of the vessels involved. The so-called spontaneous hæmorrhages, other than those of capillary origin, which give rise to masses of blood and broken-down brain tissue, may vary in size from that of a pea to those occupying a large part of a hemisphere. They are due, in a very considerable proportion of cases, to the rupture of small arterial aneurisms, but may arise from weakening of the walls of the arteries, from arteritis, atheroma, or fatty degeneration. These latter forms of lesions doubtless give rise in most cases to the formation of the aneurisms whose rupture is in so many cases the immediate cause of the hæmorrhage.

Aneurisms of the cerebral arteries may be as large as a pea or hazelnut, but those most frequently met with and causing apoplexy are usually small—called miliary aneurisms—and may be microscopic in size, varying from this up to that of a large pin's head or larger. They may be sacculate or fusiform, and frequently exist in considerable numbers. They may occur in any of the small arteries of the brain, but are said to be most frequent on the branches of the middle cerebral artery. It is asserted that the bursting of miliary aneurisms is the nearly, if not quite, exclusive cause of the formation of spontaneous apoplectic clots, but this we do not believe to be true.

As to the immediate cause of rupture, either of aneurisms or otherwise diseased blood-vessels in the brain, we are in many cases entirely ignorant. In some cases it seems to be due to an increased arterial tension in such diseases of the heart as induce this change, as in the cardiac hypertrophy which may accompany some forms of chronic diffuse nephritis; or it may result from unusual exertion or mental excitement.

Hæmorrhages most frequently occur in the corpora striata and optic thalami (Fig. 651), and in the brain tissue in their vicinity, and here they are most common in the parts supplied by the branches of the middle cerebral artery. The possibility of hæmorrhage in the floor of the fourth ventricle should be borne in mind in investigating cases of sudden death from obscure causes.

Hæmorrhages frequently seriously affect other portions of the brain than those immediately supplied by the ruptured vessels. Thus hæmorrhages in the cortical substance or beneath the pia mater may force their way deep into the brain substance; or, in hæmorrhage in the brain substance, the blood may burst into the ventricles or work its way into the intermeningeal space, and, either at the seat of its occurrence or in the situations into which it is forced, may give rise to serious compression of the brain. Portions of the brain containing large extravasations may be enlarged, the tissue anæmic from pressure, the convolutions flattened, and the surface dry. As the blood is poured out, the brain tissue is usually torn and lacerated, so that the apoplectic clot usually consists of

detritus of brain tissue intermingled with blood. If, however, the blood is poured out from a single vessel, the lacerated brain tissue may be pressed aside, and the greater portion of the red mass may consist of pure blood clot.

The appearances presented by hæmorrhages in the brain vary greatly, depending upon the time which has elapsed since their occurrence. If life continue, the œdema which usually soon occurs in the vicinity of the

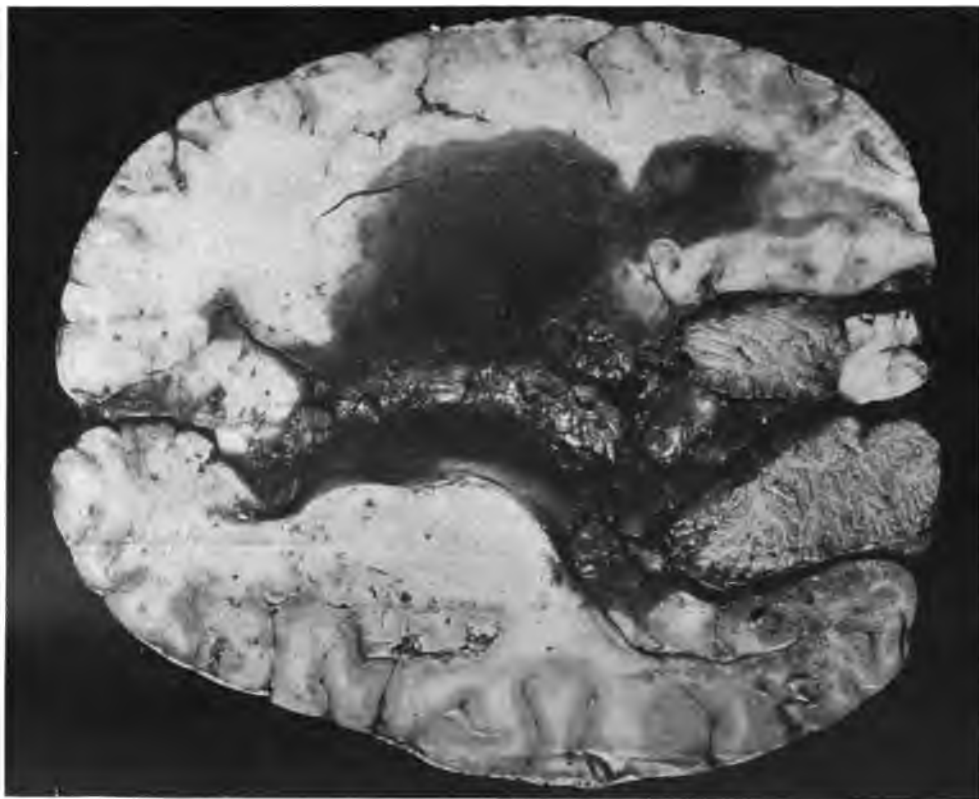


FIG. 651.—LARGE HÆMORRHAGE IN THE BRAIN. "CEREBRAL APOPLEXY."

The hæmorrhage involves the right basal ganglia and adjoining brain tissue. The blood is in both lateral ventricles. The right side of the brain (the upper side in the figure) is pressed out with flattening of the convolutions.

hæmorrhage disappears and the clot becomes drier and firmer; gradually the blood undergoes the usual series of changes seen in extravasation; the hæmoglobin decomposes, forming granules and crystals of blood pigment; the blood cells and fibrin undergo degeneration and absorption; the detritus of brain tissue undergoes fatty degeneration. As these alterations occur the color changes to reddish brown, orange, or yellow, and the adjacent brain tissue may be discolored by imbibition.

Inflammatory reaction may occur in the vicinity, leading either to the

formation of a more or less pigmented cicatrix, or to a cyst with yellowish fluid contents and a fibrous, more or less pigmented wall. The process of degeneration and absorption of the blood and broken-down brain tissue, and their replacement by a cyst or by a cicatrix, is a slow one, and the cysts and cicatrices may resemble those formed at the seat of embolic softening. Not infrequently we find in the brain of a person dead from recent apoplexy the remains of old clots presenting some one of the above-described stages of absorption. The apoplectic cysts and cicatrices persist for a long time after their formation.

Secondary degenerations (see p. 953) following hæmorrhages depend entirely upon the cells destroyed or the fibre tracts interrupted. Most common are degenerations of the pyramidal tracts from hæmorrhages

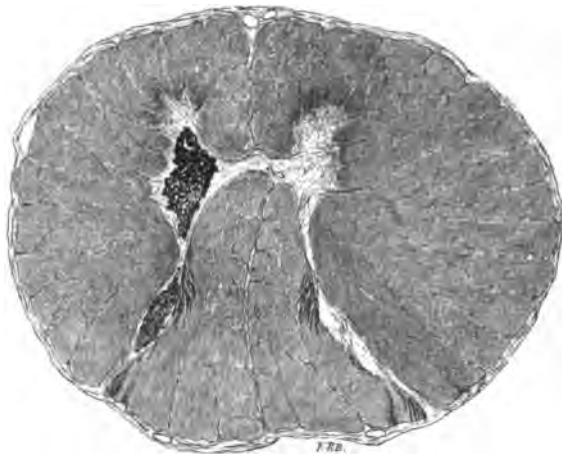

FIG. 652.—SECTION OF THE SPINAL CORD SHOWING HÆMORRHAGE INTO THE GRAY MATTER AND EXTENDING LENGTHWISE OF THE CORD. (An early phase of hæmatomyelopathy.)
This lesion is sometimes called "hæmatomyelia."

into the sensory-motor region of the cortex, or from hæmorrhages into the internal capsule (lenticulo-striate artery). Hæmorrhages involving the optic centres or the optic fibres lead to degeneration in the optic tracts. Hæmorrhages into other portions of the brain, by destroying commissural cells or interrupting their fibres, lead to degeneration of intracranial fibre tracts.

Hæmorrhage in the spinal cord is much less frequent than in the brain, but may occur either as capillary apoplexy or as larger apoplectic clots. Capillary hæmorrhages, similar in appearance to those of the brain, may occur as the result of injury, or near areas of softening or tumors, or may accompany severe convulsions, as in tetanus. Apoplectic clots, which are comparatively rare in the spinal cord, are usually small, commonly not more than one centimetre in diameter, and are similar in their appearance, and in the changes subsequent to their formation, to those in the brain. They are usually the result of injury; but may occur spontaneously. These so-called "spontaneous hæmorrhages" are undoubtedly

in most cases the result of inflammation. They may occur in any acute disease of the cord, and are an especially frequent complication of acute myelitis. Hæmorrhage into the cord, occurring in the course of an acute infectious disease, is probably, as a rule, due to an unrecognized myelitis or acute degeneration. Hæmorrhages in the course of a chronic myelitis are not common, and are probably due to a softening dependent on interference with nutrition. Hæmorrhages into the cord have been reported in syphilitic myelitis, in syringomyelia, and in tumors of the cord. Gliomata especially are often very vascular, and their thin-walled vessels are subject to rupture. Sometimes, however, hæmorrhagic foci are found in the spinal cord without traumatism or evidence of inflammatory change.

Larger hæmorrhages naturally follow the lines of least resistance, and their long diameter corresponds to that of the cord. To such columnar

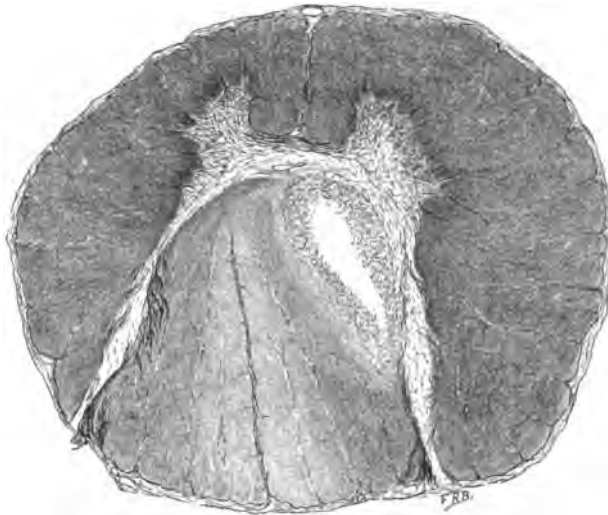


FIG. 653.—HÆMATOMYELOPORE.

The section shows at one point a cyst-like cavity in the spinal cord, originating in a hæmorrhage in the posterior root (see Fig. 652) and extending nearly the entire length of the cord. The cavity is lined by tissue detritus and neuroglia.

hæmorrhages, usually traumatic in origin, the name *hamatomyelia* has been applied (Fig. 652). The term is being now more properly used to cover the general subject of hæmorrhage into the spinal cord.

The smaller capillary hæmorrhages may be entirely absorbed. They may, on the other hand, form microscopic sclerotic areas. The larger hæmorrhages determine a considerable destruction of tissue. They may be absorbed and replaced by fibrous tissue, or the central area may break down into a fluid or semi-fluid mass of blood and tissue, with a more or less definite fibrous wall (Fig. 653). To these columnar cavities or canals the term *hæmatomyelopore* has been applied by Van Gieson.¹ To a

¹ Van Gieson, "Hæmatomyelopore—a New Spinal-Cord Disease," New York Polyclinic, 1897, vol. x., p. 87.

similar condition in which proliferation of the neuroglia is the most marked feature, the name of "false or secondary syringomyelia" has been given.

THROMBOSIS AND EMBOLISM.

Thrombi may form in the arteries as a result of any degenerative or inflammatory process in their walls leading to a roughening or death of the intima, or from pressure from without, or they may occur in vessels in whose walls we can detect no primary lesion. The most common causes are atheroma and simple endarteritis. Thrombi may also form around an embolus which does not entirely occlude the vessel.

Emboli of the cerebral arteries most commonly arise from acute or chronic endocarditis or cardiac thrombi; they may arise from aneurisms or atheroma of the aorta, from the carotid or vertebral arteries, or from the pulmonary veins. The materials constituting emboli vary greatly, depending on their mode of origin (see p. 28). The effects on the brain tissue of emboli and thrombi of the arteries are essentially the same in their main features. In some cases, however, in which large emboli, usually from endocarditis, suddenly block up a large vessel, the individual may die almost instantly without other apparent lesion than the stoppage of the vessel.

In general, the first effect of the occlusion of an artery is to deprive the region to which it is distributed of blood. In arteries whose branches anastomose, the affected area is soon supplied with blood by the establishment of a collateral circulation. In terminal arteries, on the other hand, the blocking of the vessel is followed, as a rule, by degenerative changes and softening in the brain tissue. The appearances which these degenerated areas present vary greatly, depending upon the stage of the degeneration and the amount of blood which may be extravasated. Dense infiltrations of the brain tissue with blood, as in hæmorrhagic infarctions from emboli in other parts of the body, do not usually occur, although considerable blood may be extravasated. Areas of softening in which there is little extravasation of blood are usually white or yellow in color, *white or yellow softening*. When much blood is present the process is frequently called *red softening*. Yellow softening is probably often only a secondary stage of the red, resulting from absorption of most of the pigment. The term "white softening" is often used interchangeably with "yellow." It is also applied to that condition into which the latter passes after more complete liquefaction, and after fatty changes have taken place. Young proliferating neuroglia tissue often give a glistening white appearance to the lesion.

The tissue in the affected area gradually softens and may become diffluent. Microscopically, the softened tissue is seen to consist of more or less fluid with broken-down brain tissue, fragments of nerve fibres, droplets of myelin, nerve cells, shreds of neuroglia tissue and blood-vessels, and red and white blood cells. The evidence of degeneration is seen in the presence of fat granules and droplets, larger and smaller cells

densely crowded with droplets of fat (so-called *Gluge's corpuscles* or *compound granular corpuscles*). Various kinds of cells and cell fragments, more or less granular and fatty, and also corpora amylacea, blood pig-

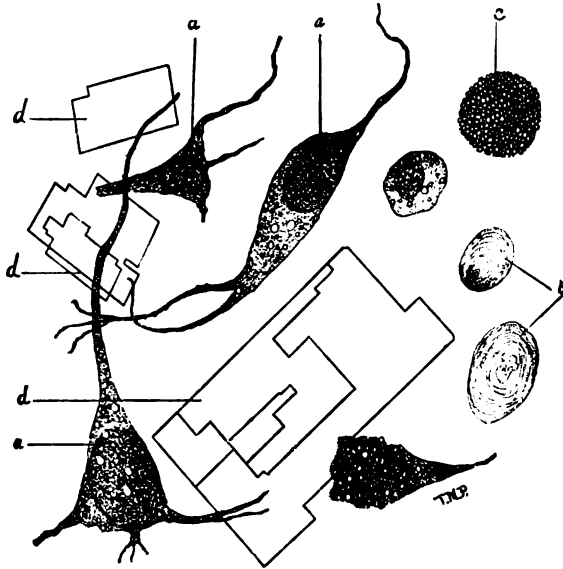


FIG. 654.—DEGENERATED CELLS, CHOLESTERIN CRYSTALS, AND CORPORA AMYLACEA FROM BRAIN TISSUE IN EMBOLIC SOFTENING.
 a, Fatty ganglion cells; b, corpora amylacea; c, cell containing very large number of fat droplets (compound granular or Gluge's corpuscles); d, cholesterol crystals.

ment, fat crystals, and cholesterolin crystals, may be found (Fig. 654). The walls of the blood-vessels may also be in a condition of fatty deg-

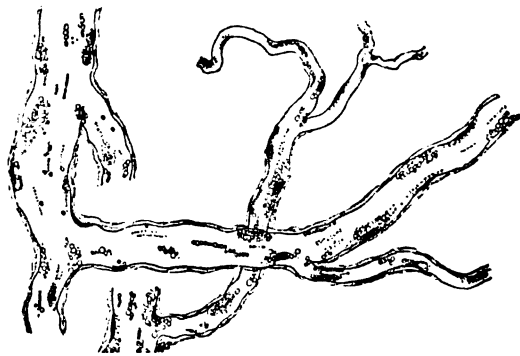


FIG. 655.—BLOOD-VESSELS FROM AN AREA OF EMBOLIC SOFTENING OF BRAIN.
 The walls of the vessels, particularly the endothelial cells, contain fat granules and fat droplets.

eration (Fig. 655). The color of the softened mass will of course depend upon the relative amounts of these elements.

The tissue may remain for a long time in the soft condition, or it may be absorbed and replaced by a connective-tissue cicatrix which may be more or less pigmented; or a wall of connective tissue may form about it, converting it into a well-defined cyst, with or without pigmented walls; or the mass may dry and form a dense, structureless nodule. Acute inflammatory changes may occur about the dead tissue. In cases of infectious emboli numerous abscesses may be formed in addition to their mechanical action.

Thrombi are most frequent in the internal carotids, less frequent in the middle cerebral, basilar, and vertebrals. They may occur, but still less frequently, in other cerebral arteries. Emboli are most common in the middle cerebral artery, next in the internal carotid, and then in the basilar. The relative frequency with which embolism occurs in the middle cerebral artery is attributable to the directness with which the blood passes into this artery from the heart. The great significance attaching to embolism of the middle cerebral artery is evident when we remember that its branches within the brain are terminal arteries, and are distributed to such important structures as the lenticular and caudate nuclei, the internal capsule, and the optic thalamus.

Thrombosis and embolism also occur in the vessels of the spinal cord, though less frequently than in those of the brain. As in the brain, when they involve terminal arteries, they determine areas of softening and consequent secondary degenerations.

LESIONS OF THE VESSEL WALLS IN THE BRAIN AND CORD.

The mural changes in the vessels are not peculiar to the nervous system: the most frequent is that known as atheroma or arterio-sclerosis. It is especially common in the system of arterial trunks which make up the circle of Willis. Fatty degeneration is often found in the vessel walls coincident with the increase in the connective-tissue elements. Calcification may occur and may be so extensive that the whole or a greater part of the circle of Willis is converted into a series of hard tubes usually somewhat larger than normal. More commonly the calcareous areas are irregular in their distribution, giving to the vessels a nodular appearance. Fatty degeneration may also occur, though more rarely, as an independent lesion. It affects particularly the muscular coat. Hyaline degeneration may also occur either as an independent lesion, which is quite frequent in the brains of idiots, or as the initial lesion of a sclerosis.

DEGENERATION AND INFLAMMATION IN THE BRAIN, SPINAL CORD, AND NERVES.

Review of Normal Morphology.

While the scope of this work does not warrant a detailed description of the morphology of the nervous system,¹ our appreciation of the pathological changes to which it is subject is so dependent upon an accurate knowledge of its morphology, that, before proceeding further, a brief *résumé* of some of the more fundamental points in its structure and architecture cannot wisely be omitted.

¹ For this the reader is referred to such works as "The Nervous System," by *Barker*, and the "Anatomie du Système Nerveux de l'Homme," by *Van Gehuchten*.

The studies of Golgi and of his successors in the use of his technique have led to the so-called neurone conception of nervous-system structure. According to this view, the neurone represents the structural unit of the nervous system. The neurone is the nerve cell with all its prolongations, and the nervous system *in toto* is but an orderly association of an immense number of these neurone units. Although these neurones differ from one another as to details of structure they still present an essential similarity.

The neurone is first distinguishable as a small round cell in the epiblastic lining of the embryonic neural canal. Such a cell is entirely devoid of processes. It soon, however, becomes pyriform, and from the tip of the pear grows out a process, which is the axis-cylinder process or axone. Later other processes appear as outgrowths of the cell body. These are the protoplasmic processes or dendrites. Each adult neurone then consists of a cell body, and passing off from this cell body two kinds of processes (Figs. 656 and 657).

The Cell Body.—Our knowledge of the internal structure of the nerve cell has been greatly increased in the last few years by the application of a special technique devised by Nissl.¹ Subjected to this technique nerve cells present two very different types of reaction. Certain cells, such, for example, as the cells of the granule layers of the cerebellum and of the olfactory lobe, stain only as to their nuclei, the cell bodies themselves remaining entirely unstained. To such cells Nissl has given the name of *caryochromes*. It is obvious that the method of Nissl gives no insight into the structure of these cells. The majority of nerve cells, however, react both as to their nuclei and as to their cell bodies to the Nissl stain. These cells Nissl designates as *somatochromes*. Such a cell presents the following appearance (Plate XIII., 1). There is a nucleus identical in structure with nuclei found in other cells. It is bounded by a nuclear membrane and traversed by a network which takes a comparatively light blue stain. Within the nucleus is a nucleolus staining an intense blue. In the cell body two distinct elements appear: a clear ground substance, unstained; and scattered through it deep staining masses, known as *chromophilic bodies*. These chromophilic bodies are granular, and differ in size, shape, and arrangement. These differences have served as a basis of classification. Presenting variations in different types of cells, their appearance in a given type remains constant. Most investigators, while differing in details, agree in ascribing to the unstainable substance a definite structure. This structure is usually described as composed of a fibrillar or reticular network lying in a more or less homogenous ground substance. With the use of the ordinary technique of Nissl, all of the cell body, excepting the chromophilic bodies, remains unstained and apparently structureless. Our ideas as to the physiology of these different elements of the nerve cell rest largely upon a theoretical basis. It has been shown that the nerve cell represents the genetic centre of the neurone. From the behavior of the processes, when cut off from the nerve cell, it is evident that the cell body represents the nutritive or trophic centre of the neurone. It seems probable that from the standpoint of neurone activity, the cell body represents the functional centre of the neurone, while the processes act as organs of reception or distribution. Certain facts, such as the entire absence of the chromatic substance in many nerve cells, in the axones of all nerve cells, and its diminution during functional activity and in fatigue, together with its behavior under certain pathological conditions, lend weight to the view that the stainable substance of Nissl represents a food element of the cell. The achromatic element, on the other hand, is continuous with the fibrillæ of the axone, and is considered by most investigators as representing the essential nervous mechanism of the cell. The relation of the Nissl picture to the conditions existing in the protoplasm of the living cell still remains an unsolved problem. The importance of the Nissl method from the standpoint of pathology lies in the fact that when subjected to a given technique, a given type of nerve cell presents always the same appearance, and that this appearance furnishes a norm of comparison with cells showing pathological changes which have been subjected to the same technique.

Pigment.—In addition to the elements already described, more or less pigment in the shape of fine brownish yellow granules is often present in nerve cells. It is not

¹ See Nissl's method of staining, p. 982.

found in cells of the new-born. It increases with age, and in old age often fills up a large part of the cell body. Its significance is not known.

The *protoplasmic processes* or *dendrites* are—at least the larger trunks—of the same structure as the cell body (Plate XIII., 1). That these larger trunks have functions similar to those of the cell body seems probable from the fact that the axone not infrequently takes origin from a large dendritic trunk instead of directly from the body of the cell. The chromatic substance is present in the dendrites, as elongated rods with triangular masses at the points of bifurcation. The achromatic elements are apparently of the same character as in the body of the cell. The protoplasmic processes divide dichotomously, becoming rapidly smaller, and end at a comparatively short distance from the cell body.¹ Stained by the method of Golgi, the dendrites are seen to be covered with minute projections or "gemmules," often ending in a small bulb. These processes are cellulipetal in character, carrying impulses always toward the cell.

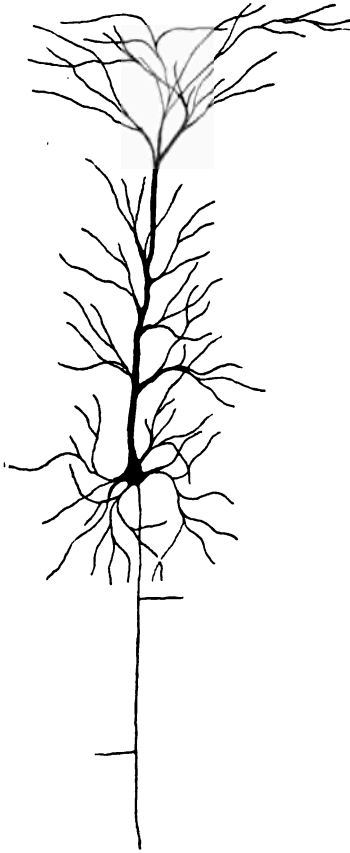


FIG. 656.—NEURONE (NERVE CELL OR GANGLION CELL AND PROCESSES) FROM HUMAN CEREBRAL CORTEX.

Showing main or apical dendrite passing upward and numerous smaller dendrites coming off from the main dendrite and from the body of the cell. A single axone (axis-cylinder process) passes downward from the base of the cell, giving off two collaterals.

The *axis-cylinder process* or *axone*—so called from its often becoming the axis cylinder of a nerve fibre—is usually single. It generally arises directly from the body of the cell, but may arise, as already mentioned, from one of the larger protoplasmic trunks. It is differentiated from the dendrites in Nissl preparations by always taking origin from an area in the cell body free from chromatic substance, and by being itself entirely achromatic (Plate XIII., 1); in Golgi specimens, it is recognized by its straight course, uniform diameter, and smooth outline (Fig. 656). It sends off few branches, and these at right angles (collaterals). This axone may extend a great distance from the cell body; for example, the axones of certain motor cells of the spinal cord extend to the muscles of the hands or feet. Both the axone proper and its collaterals end in terminal arborizations. Their conductivity is cellulifugal—that is, they always carry impulses from the cell. In certain cells the axis-cylinder processes branch rapidly and end in the gray matter in the vicinity of their cells of origin (Fig. 657). An axone may pass from its cell of origin to its termination uncovered by any sheath. Such axones are found in certain portions of the gray matter. An axone may be enveloped only by a thin membrane, the sheath of Schwann, as, e.g., the fibres of Remak found mainly in the sympathetic system. An axone may be surrounded by a myelin sheath alone, as in the white matter of the brain and cord, or by both a myelin

sheath and a sheath of Schwann, as in the fibres of the peripheral nerves, with the exception of the olfactory and optic.

According to the strict neurone conception of nervous-system structure, each neurone is considered a complete morphological and, to a lesser degree, physiological entity. It has no anatomical connection with any other neurone. Association between neurones takes place by contact or contiguity, and never by continuity of

¹ Exception, peripheral arm of spinal ganglion cell.

EXPLANATION OF PLATE XIII.¹

1. **NORMAL GANGLION CELL.** Large motor cell from anterior horn of human spinal cord, showing the nucleus in its normal central position with its nucleolus. In the body of the cell are seen the chromophilic bodies of various shapes and sizes. Three main protoplasmic trunks or dendrites pass off from the upper portion of the cell. In these the chromophilic bodies are rod-shaped. The largest process branches at a short distance from the cell. To the left is seen the axone or axis-cylinder process free from chromatic substance, as is also that portion of the cell from which it takes origin (axone hill).
2. **GANGLION CELL FROM THE ANTERIOR HORN OF THE HUMAN SPINAL CORD OF A CASE OF ALCOHOLIC NEURITIS.** Showing eccentricity of the nucleus and a large central area of the cell body free from chromatic substance (central chromatolysis), with an arrangement of the remaining chromophilic bodies around the periphery. (The similarity between the appearance of this cell and the one shown in Fig. 6 should be noted.)
3. **GANGLION CELL FROM THE ANTERIOR HORN OF THE SPINAL CORD OF A RABBIT INOCULATED WITH RABIC VIRUS AND KILLED SHORTLY AFTER THE ONSET OF SYMPTOMS.** Shows an early stage of chromatolysis; the chromophilic bodies being pale, ragged, and vacuolated.
4. **GANGLION CELL FROM THE ANTERIOR HORN OF THE SPINAL CORD OF A RABBIT WHICH DIED ON THE NINTH DAY AFTER INOCULATION WITH RABIC VIRUS.** Shows extreme chromatolysis, only a few fine granules of chromatic substance remaining at the periphery. The cell is swollen, the nucleus has disappeared, and the cell body and processes are stained more deeply with the erythrosin than is the case in normal cells.
5. **NORMAL GANGLION CELL FROM A HUMAN SPINAL GANGLION OF THE POSTERIOR ROOT.** Showing central position of the nucleus and the concentric arrangement of the chromophilic bodies.
6. **GANGLION CELL FROM THE POSTERIOR ROOT GANGLION OF A RABBIT THREE WEEKS AFTER SECTION OF THE SCIATIC NERVE.** The cell shows extreme eccentricity of the nucleus with central chromatolysis and a peripheral arrangement of the remaining chromophilic bodies—axonal degeneration. (There also remains in the central portion of the cell some chromatic substance in the shape of fine granules forming an irregular reticulum. The similarity between this picture and the one shown in Fig. 2 is apparent.)
7. **PORTION OF A POSTERIOR ROOT GANGLION FROM A CASE OF TABES DORSALIS.** Showing degeneration in the ganglion cells with increase in the interstitial connective tissue.
8. **TWO PYRAMIDAL CELLS FROM THE NORMAL HUMAN CEREBRAL CORTEX.** While the pyramidal cells in the human cortex vary considerably in the amount of chromatic substance which they contain, these are of an average type.
9. **TWO PYRAMIDAL CELLS OF THE HUMAN CEREBRAL CORTEX FROM A CASE OF ECLAMPSIA.** These cells show marked chromatolysis.

¹ In the staining of the specimens from which these drawings were made, Held's modification of Nissl's method was used. This consists essentially in a preliminary staining of the sections with a one-per-cent. aqueous solution of erythrosin.

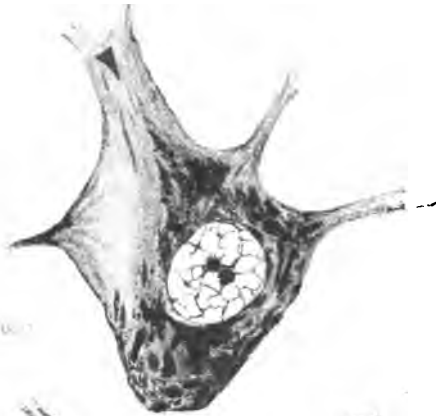

FIG. 1.

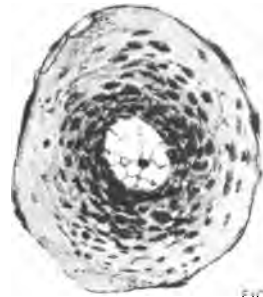


FIG. 5.

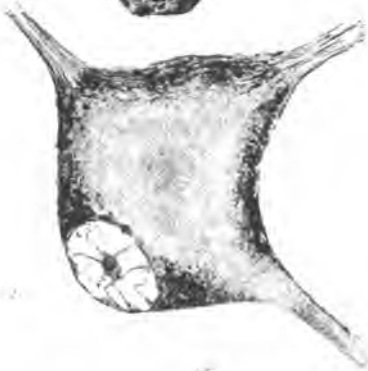


FIG. 2.




FIG. 6.

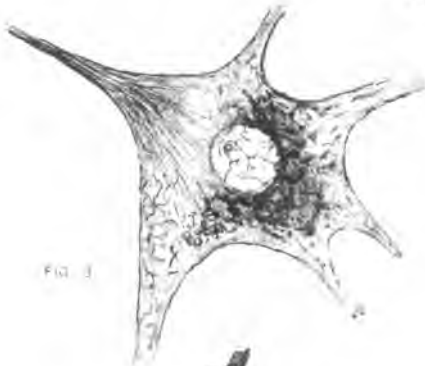

FIG. 3.

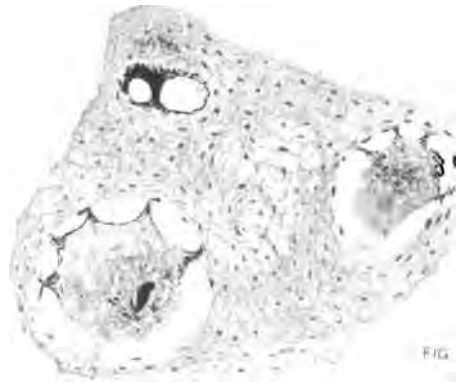


FIG. 7.

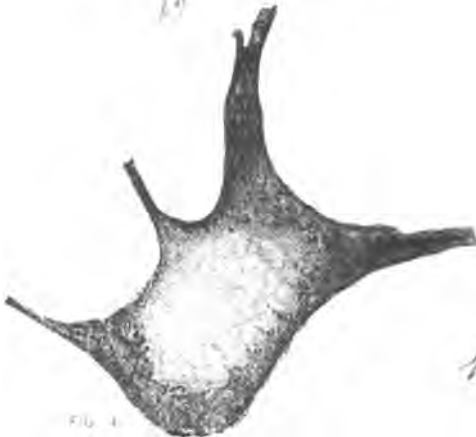

FIG. 4.

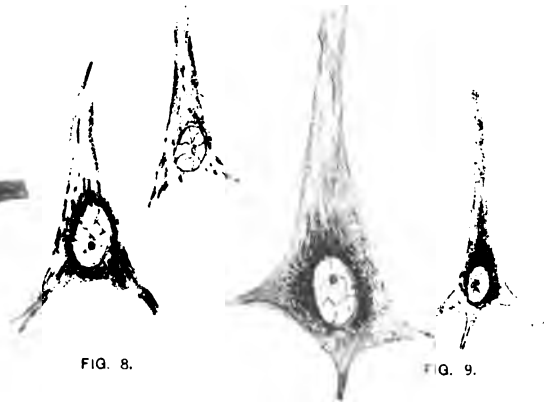


FIG. 8.

FIG. 9.

Lesions of Ganglion Cells.—(Stained by Nissl's Method.)

Drawn by F. R. Bailey.

their protoplasm. The passage of an impulse is always from the terminal arborizations of axones or collaterals to the dendrites or cell body of the other neurone.

The validity of the neurone theory has been recently called in question by such prominent neurologists as Held, Apathy, Bethe, and Nissl,¹ on the ground that in many cases axones pass directly into the protoplasm of another neurone and that the neurofibrils are sometimes continuous throughout a series of neurones. Nissl in a critical review upon the present status of the neurone theory announces his belief that the entire neurone concept has been proved fallacious and must be abandoned.

Admitting that the discovery of anastomoses between neurones and of the continuity of the neurofibrils must be accepted as invalidating some of our ideas as to the separateness of the neurone units, it can still hardly be considered as overthrowing the entire neurone theory. Embryologically, morphologically, and physiologically the neurone shows a marked degree of individuality, and the fact that neurones sometimes, usually, or even always, anastomose no more warrants the giving up of the neurone as essentially a unit than did the discovery of the fact that the protoplasm of epithelial cells was continuous through intercellular "bridges" necessitate the giving up of the epithelial cell as the structural unit of epithelium.

The cell bodies of neurones are grouped mainly in the gray matter of the brain and cord, in the ganglia of cranial, spinal, and sympathetic nerves, and in the peripheral end organs of certain of the nerves of special sense. Protoplasmic processes ramify mainly within the gray matter.² While some terminate in the gray matter in the immediate vicinity of their cells of origin, it is the axones that make up the bulk of the white matter of the brain, cord, and peripheral nerves.

Neuroglia.—In addition to the extensions inward of the pia mater and the connective tissue of the blood-vessels, there is found in both gray and white matter a tissue, probably supportive in function, and peculiar to the nervous system—the neuroglia. Like the neurone, it originates in the epiblastic cells lining the embryonic neural canal. These cells, at first morphologically identical, soon differentiate into neuroblasts or future neurones, and spongioblasts, or future neuroglia cells. In the adult two main types of neuroglia cells are found, spider cells (Fig. 658), with spine-like, straight, unbranching processes, and mossy cells (Fig. 659) with thick, rough, branching arms. The former are found chiefly in the white matter, the latter in the gray matter in connection with blood-vessels. As in the case of the nerve cell, the processes of these cells do not anastomose, but interlace, forming a dense feltwork. By a special stain, Weigert demonstrates neuroglia cell nuclei and separate fibrils.

It seems probable that this method fails to show the body of the cell, while staining its nuclei and the fibrils which pass through it.

It would thus appear that the architecture of the central nervous system, considered as an organ, is analogous to that of other organs. It has in the neurone its parenchyma, and this parenchyma is supported and bound together by a framework of

¹ For a critical view of the opinions of these writers consult the last edition of *Van Gehuchten's* "Anatomie du Système Nerveux."

² Exception, peripheral arm of spinal ganglion cell

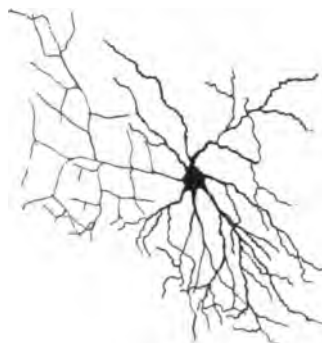

FIG. 657.—NEURONE (NERVE-CELL OR GANGLION-CELL PROCESSES). FROM THE GRANULAR LAYER OF THE CEREBELLAR CORTEX OF A GUINEA-PIG.

The short axone passes off to the left and terminates near its cell of origin.

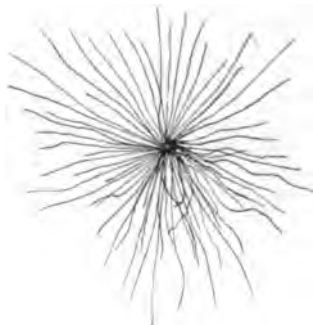


FIG. 658.—NEUROGLIA CELL—SPIDER TYPE—HUMAN CEREBRUM.

connective tissue. The essential difference lies in the fact that in the neurone is the highest morphological differentiation which protoplasm has attained, representing chemically the most complex molecules known. In the axone, sometimes a metre or more in length, of a cell of microscopic dimensions, there is a distribution of cell protoplasm, such as occurs in no other tissue or organ. The neuroglia also, while without question a tissue supportive in function, is embryologically and morphologically different from other forms of connective tissue.



FIG. 659.—NEUROGLIA CELL—MOSSY TYPE—HUMAN CEREBRUM.

DEGENERATION.

NEURONE DEGENERATION.

Degenerative changes may affect the entire neurone or any of its parts. Such changes may result from direct injury to some part of the neurone, to diminution or modification of its nutritive supply, to various toxic conditions, etc.

I. Changes in the Neurone from Injury to One of Its Parts.—(a) **CHANGES IN THE AXONE RESULTING FROM SEPARATION FROM ITS CELL BODY.**—That changes, presumably of a degenerative character, occur in the peripheral end of a nerve when its connection with the central nervous system is broken has long been known. This degeneration takes place as well in the central as in the peripheral nervous system, and is complete, involving every portion of the axone distal to the point of section. The changes are not progressive from the point of lesion, but occur at nearly the same time in all parts of the distal stump. These changes consist in a breaking up of the medullary sheath into segments (Fig. 660), which in turn disintegrate, forming variously shaped masses of myelin, among which may be seen the axis cylinder, the whole being enclosed by the neurilemma. The method of Marchi (see p. 981), which differentiates between fat and myelin, shows that coincident with the breaking up of the myelin there is an appearance of fat droplets. These fat droplets increase in number *pari passu* with the decrease in myelin, but also ultimately disappear. During the progress of these changes in the medullary sheath, the axis cylinder at first segments and then undergoes dissolution. The neurilemma, on the other hand, appears to take no part in the degenerative process. On the contrary, it and its nuclei remain intact to take part later in regenerative changes, should these occur. If there is no reunion of the severed ends of the axone, the peripheral portion completely disappears, its place being taken by connective tissue.




FIG. 660.—NEURONE DEGENERATION AFTER INJURY.

Tensed nerve fibres from distal portion of sciatic nerve of rabbit three weeks after division of the nerve. Osmic-acid stain. The large and small black masses represent disintegrated myelin and fat droplets.

(b) **CHANGES IN DENDRITES RESULTING FROM THEIR SEPARATION FROM THEIR CELL BODIES.**—If we consider, as does Van Gehuchten,¹ that

¹ Van Gehuchten, "Anatomie du Système Nerveux de l'Homme," p. 213.

the peripheral arm of the spinal ganglion cell is a protoplasmic process, making a physiological rather than a morphological differentiation, we find that the same law holds good for dendrites as for axones when separated from their cell bodies. Thus in the divided peripheral nerve those fibres which are the processes of the spinal ganglion cells undergo the same degenerative changes as do the fibres which are processes of cells of the anterior horn. Most dendritic processes are, however, so short and terminate in the gray matter so near the cells from which they originate that experimental separation of the process from its cell body is impracticable. In view of the fate of the axone, however, and the relation of the dendrites to the cell body, there can be little doubt that as complete degeneration follows the severance of a protoplasmic process from its cell of origin as follows in the case of the axone.

(c) CHANGES IN THE PROXIMAL STUMP AND IN THE CELL BODY RESULTING FROM LESION TO THE AXONE.—The fundamental principle of the law of Waller was the complete degeneration of the distal portion of the divided nerve, while the proximal stump remained intact. Our present conceptions, however, of the interdependence of the different parts of the neurone, and of the axone as the outlet for neurone energy, would lead us to expect certain changes of an atrophic nature in the proximal stump and in the cell body, as a result of separation from its axone and consequent inability to functionate. That such changes take place recent improvements in cytological technique have enabled us to determine. The method of Marchi shows that degenerative changes occur, not only in the distal, but in the proximal end of the divided nerve. These changes take place more slowly than in the distal portion, but are apparently identical in character.

In the body of the cell the method of Nissl demonstrates marked changes after section of the axone. These changes may be observed within twenty-four hours after the injury. They consist in a diminution in the chromatic elements of the cell, chromatolysis. This is most marked in the central portion (central chromatolysis), a distinct ring of chromophilic bodies around the periphery often remaining. The nucleus usually migrates toward the periphery and may even bulge from the cell. In the case of the hypoglossal nerve in the rabbit, these changes reach their maximum in from two to three weeks. The future of some of these cells is complete degeneration. Others apparently undergo regeneration. The intensity of the reaction of the nerve cell to injury to its axone depends upon the severity of the injury. Thus cutting the nerve is followed by more prompt and marked changes in the nerve cell than simple compression, while pulling out the nerve roots is followed by a still more intense reaction. Again, there is a difference in the resisting-powers of different types of cells. Thus the motor cells of the anterior horn are peculiarly resistant to injury to their axones, as are also the spinal ganglion cells to injury to their central processes. Again, between cells of the same type there are marked variations in re-

sisting-powers. Thus the motor cells of the anterior horn are much more resistant than the cells of the motor cranial nuclei.¹

(d) CHANGES IN THE CELL BODY RESULTING FROM LESIONS TO ITS DENDRITES.—In the study of the effect upon the cell body of a lesion depriving it of one or all of its dendritic processes, we meet with the same experimental obstacles already mentioned in connection with changes in the dendrites. It is, again, only in the peripheral arm of the spinal ganglion cell that we have a cellulipetal process of any considerable length. Section of this process results in changes in the spinal ganglion cell quite similar in character to the so-called "axonal" degeneration (Plate XIII., 6). If we consider that a cell's dendrites probably furnish its most important avenue for the reception of impulses, it follows that a neurone may be thrown as completely out of circuit, as it were, by injury to its dendrites as by injury to its axone. The experiments of Warrington² are interesting in this connection. He attempted to bring about the same functional effect as would result from section of a cell's dendrites, by inhibiting afferent impulses. Cutting the posterior roots, he noted changes in the cells of the anterior horn. The inference was that these changes were induced by an inhibition of the customary normal stimulation by means of the afferent impulses reaching the cells through their dendritic processes.

II. Changes in the Neurone from Interference With Its Nutrition.—

Changes apparently of a degenerative character have been described in neurones as a result of interference with nutrition. Thus Brieger and Ehrlich³ found that by temporarily applying a ligature to the abdominal aorta, they induced an acute necrosis of the cells of the lumbar cord. Later experiments of a similar nature followed by the Marchi staining showed that the degenerative process affected not only the cell bodies, but the entire neurone. Similar degenerative changes have been induced by experimentally produced multiple emboli, cells in the vicinity of the occluded vessels being in marked contrast to cells from regions whose vessels remained patent. Ewing⁴ describes definite degenerative changes in nerve cells as a result of anæmia consecutive to pressure from cerebral hæmorrhage and to thrombosis of the basilar artery. Less marked changes have been observed in cases of general malnutrition and in severe anæmias.

III. Effects of Toxins upon Neurones.—Changes of a degenerative character occur in neurones as a result of the action of toxins. These toxins may be introduced into the body from without, for example, such poisons as alcohol, arsenic, lead, strychnin, etc.; they may be elaborated within the body as the result of faulty metabolism, for example, in uræmia, eclampsia, etc., or as a result of the action of bacteria, as in tetanus, rabies, (Plate XIII., 3, 4, and 8), diphtheria, etc., or of the Plasmodium

¹ For review and bibliography of changes in the nerve cell and in the proximal stump after section of a peripheral nerve consult Barker, "The Nervous System," p. 229 *et seq.*

² Warrington, W. B., "On the Structural Alterations in Nerve Cells," *Jour. of Physiol.*, London, vol. xxiii., p. 112, 1898.

³ Brieger and Ehrlich, "Ueber die Ausschaltung des Lendenmarkgrau," *Zeitschr. f. klin. Med.*, Berlin, Bd. vii., Suppl., 1883 84.

⁴ Ewing, J., "Studies on Ganglion Cells," *Arch. of Neur. and Psychopath.*, vol. i., 1898.

malariae. The effects of these poisons upon the neurone vary with different poisons and in different types of neurones. The effects of the same poison upon a given type of neurone also vary according to its rapidity of action, whether rapidly fatal or extending over a considerable period of time. Again, given the same poison and the same time of action, not all neurones even of the same type show an equal susceptibility. There seem to be marked individual differences among neurones of the same type as regards their resisting powers.

These changes in the neurone from the action of toxins may affect one or all of its structural elements, and vary from the slightest appreciable loss of staining qualities of the chromophilic bodies to complete destruction of the neurone. In the chromophilic bodies the essential change seems to be a decrease in the amount of chromatic substance, *chromatolysis*. This may be evidenced merely by a decreased staining intensity, the chromatic masses appearing abnormally pale; the bodies may have a ragged or frayed-out appearance at their edges; they may be shrunken, or, retaining their normal shape and size, become vacuolated (Plate XIII., 3); they may completely disintegrate, giving to the cell a diffuse granular appearance; they may disappear, leaving the cell entirely devoid of chromatic substance. The chromatic masses in the dendrites seem in many cases to be more resistant or less exposed than are those in the body of the cell, often remaining unchanged at a time when the latter show an advanced degree of chromatolysis. During these changes in the chromatic element the cyto-reticulum may remain apparently normal or it may more or less completely disintegrate. This disintegration usually marks the more advanced degenerative changes (Plate XIII., 4).

In the truly achromatic element of the cell or cytoplasm, our present methods of staining fail to demonstrate lesions. Diffuse staining of this basement substance is a common phenomenon of chromatolysis, but seems more properly referable to a diffusion of the fine granules resulting from disintegration of the chromatic masses than to any changes in the cytoplasm itself. Disappearance of the formed elements of the cell often leaves clear holes or vacuoles in the cell body or gives the appearance of cracks or fissures. The nucleus may remain normal; it may swell and its contour become abnormally distinct; it often takes a diffuse stain; later it shrinks, becomes crenated, its reticulum and limiting membrane break up and its outline is lost. During these nuclear changes the nucleolus may also disintegrate. It is often extremely resistant, remaining apparently unchanged after most of the other parts of the cell have become unrecognizable. Concurrent with these changes in internal structure are changes in the shape and size of the cell. Its contour becomes irregular, and its edges present an eroded appearance; the cell body shrinks away from its cell space, breaks up, and ultimately disappears. The dendrites undergo alterations similar to those in the body of the cell. They shrink, become separated from the cell body, and finally disintegrate.

That part of the neurone which shows most marked evidences of its effect is not necessarily the part upon which the poison is most directly

acting. Thus a toxin affecting directly the cell body may cause the earliest and most pronounced changes far out in its dendritic or axonal processes, *i.e.*, in those parts of the neurone farthest removed from the trophic centre.

To the action of a specific poison certain neurones seem less resistant than others. Thus, to the action of lead those neurones governing the extensor muscles of the wrist seem especially susceptible. The cells of the motor nucleus of the trigeminus seem to be less resistant than other motor cells to the poison of tetanus. Again, the frequency with which *tabes dorsalis* is associated with a syphilitic history seems to indicate a special susceptibility to the syphilitic poison on the part of the peripheral sensory neurone.

Comparing the changes in the nerve cell in toxæmias (Plate XIII., 3 and 4) with those induced by lesions to its axone—axonal degeneration (Plate XIII., 6)—we note that while in the latter the chromatolysis is central in character, beginning in the region of the axone hill and nucleus, in the former the changes begin at the periphery, the portion of the cell in most direct relation to the surrounding lymph. In axonal degeneration the nucleus is usually eccentric. In toxæmia it usually remains central, at least until the process of degeneration is far advanced. While this distinction holds good in general and while the phenomena of central chromatolysis and eccentricity of the nucleus regularly follow injury to the axone, we are not yet warranted in stating that such changes never occur except after some injury, or that the presence of such changes in the cell can be explained only on the basis of injury to its axis-cylinder process.

IV. Effects of Fatigue upon Neurones.—Studies upon the effect of fatigue upon the neurone have been made in animals after prolonged muscular activity and after electrical stimulation. While the results are not in complete accord, there seems to be little doubt that definite morphological changes occur in the neurone as a result of fatigue. These changes consist in a decrease in the size of the cell body, a decrease in the size of the nucleus, often with distortion, and a marked decrease in the amount of chromatic substance with more or less diffuse staining of both cell body and nucleus.

It seems not at all improbable that the clinical pictures presented by certain psychoses and neuroses are the expression of the effects upon the neurones of prolonged fatigue. Certain local expressions of neurone exhaustion, as, for example, writer's cramp, may possibly also be placed in the same category.

As to the significance of those changes in the nerve cell, which are marked by diminution in the chromatic substance alone, and to which the term "chromatolysis" has been given, there is a considerable difference of opinion. Marinesco¹ considers them of the nature of degeneration. Van Gehuchten² is inclined to look upon the phenomenon as conservative in character, a means by which the neurone assumes a condition most advantageous for self-defence. It has been shown that even an extreme degree of chromatolysis is not incompatible with function. Marinesco insists that so long as the changes are confined to the chromatic substance recovery is possible, no matter how extensive the alterations, while changes in the achromatic elements are always permanent in character. It seems quite probable that a comparatively easy method

¹ *Marinesco, G.* See Van Gehuchten's "Anatomie du Système Nerveux," p. 339.

² *Van Gehuchten, loc. cit.*, p. 339.

of investigation has led to an overestimation of the significance of changes in the chromatic substance of the neurone, and to a neglect of probably more important but less easily studied changes in the achromatic element.

REGENERATION.

Regeneration of nerve tissue in the sense of an actual reproduction of neurones probably never occurs in the adult human nervous system.¹ As has been noted, extreme chromatolysis may be succeeded by complete recovery. In the case of axonal chromatolysis, the degenerative process usually reaches its maximum in about three weeks. Regeneration of chromophilic bodies then begins. This reconstructive process is slow, the cells often requiring months to return to a normal condition. At some stage of the process there is usually an overproduction of chromatic substance, and the cells appear darker than normal.

Primary union between the ends of divided nerve fibres does not occur. Complete degeneration of the distal portion always precedes the regenerative process. In this reconstruction the nuclei of the neurilemma seem to play an important part. They increase in number, and there is also an increase in the protoplasm which surrounds them. With union of the divided ends, the axones of the central stump may grow out again, if the ganglion cells be intact, and ultimately resume function. The myelin first reappears as droplets which coalesce and finally form a complete sheath. This reconstructive process in the nerve fibre is extremely slow, often requiring many months for its completion.

REPLACEMENT NEUROGLIA HYPERPLASIA.—Under various conditions in which there is destruction of the parenchyma, as, *e.g.*, in ascending and in descending degeneration of the spinal cord, there occurs a compensatory increase in the interstitial elements. This new tissue is at first cellular, most of the cells being of the spider variety. Later there is an increase in the neuroglia fibres, and the tissue often becomes dense and hard. What part the mossy cells or other less common types of neuroglia cells take in the proliferative process is as yet unknown. With the increase in fibres there are often shrinkage and the formation of dense fibrous tissue. This replacement hyperplasia in neuroglia seems quite similar in nature to replacement connective-tissue hyperplasia in other organs, and is often wrongly considered inflammatory.

DEGENERATIONS AFFECTING SYSTEMS OF NEURONES.

General Considerations Concerning Neurone Systems.

Before considering the subject of systemic degeneration we may refer briefly to the situation in the nervous system of certain of the more important groups of neurones and the paths which their axones take.

That the cell bodies of neurones are grouped in the gray matter of the brain, cord, and ganglia, and in the end organs of certain nerves of special sense, has already been mentioned. This grouping of neurones serves definite physiological ends. Their cell bodies form centres or nuclei, while their axones are collected into bundles or fibre

¹ For review and literature on "Regeneration" see *Barker*, "The Nervous System," p. 245 *et seq.*

tracts. Thus, in the region of the fissure of Rolando are grouped the centres of those neurones which have to do with voluntary motion, and what is known as cerebral localization means the grouping of cell bodies of neurones for specific function. After the known localizations are eliminated, there still remains unaccounted for the greater part of the cerebral cortex, and our present belief is that these neurones are neurones of association by which the various centres are brought into physiological relationship. Some understanding of this neurone grouping, and especially of the arrangement of their neuraxones as fibre tracts of the cord, is essential to an appreciation of those degenerations which affect definite systems of neurones.

PERIPHERAL MOTOR NEURONES.—These neurones have their cell bodies in the gray matter of the anterior horn and in the motor nuclei of the cranial nerves. Their neuraxones pass out as the motor fibres of the cranial and of the spinal nerves. The entire neurone lies upon the same side of the body; that is, the peripheral motor neurone is "direct."

THE UPPER OR CORTICO-SPINAL MOTOR NEURONES have their cell bodies situated mainly in the cerebral cortex near the fissure of Rolando. Their neuraxones converging, pass through the internal capsule, pons, and medulla, sending off fibres to the motor nuclei of the cranial nerves. In the medulla the tract comes to the surface as the *anterior pyramids*. At the junction of medulla and cord occurs the pyramidal decussation in which most of the fibres of the tract cross to the opposite lateral region of the cord, to be known as the *crossed pyramidal tract*, while a minority remain on the same side, to pass down the cord as the *direct pyramidal tract*. As the tracts descend, fibres continuously leave them to terminate, those of the crossed tract in the gray matter of the same side, those of the direct tract, after passing through the anterior commissure, in the gray matter of the opposite side. The cortico-spinal motor tract is a crossed tract.¹ These tracts present variations in size and length. They are often asymmetrical. The crossed tract extends to the lower sacral cord. The direct tract usually ends about the mid-dorsal region, though it has been followed as low as the second lumbar segment.

THE SENSORY (AFFERENT) TRACT, like the motor, consists of two segments, an upper and a lower.

The lower or peripheral sensory neurone tract has its cell bodies in the ganglia of the spinal and of the cranial nerves. Their peripheral arms, which Van Gehuchten considers protoplasmic processes, are axis cylinders of cranial or of spinal nerves. Their central processes or axones pass into the cord as the fibres of the posterior roots and enter the posterior columns. Here they divide into ascending and descending arms. The descending arm is short, and with its collateral branches soon terminates in the gray matter of the same side of the cord. The ascending arm may also be short, and with its collaterals terminates as does the descending. It may pass a considerable distance up the cord and then end in the gray matter. It may, as one of the long fibres of the posterior columns, continue upward to the medulla, where it terminates in one of the posterior column nuclei. These long fibres pass inward as they pass upward, so that the lower the origin of the fibre the more mesial is its position in the upper part of the cord. The entire neurone lies upon the same side of the cord. The lower sensory, like the lower motor neurone, is direct.

Upper Sensory Neurones.—The arrangement of these neurones is extremely complex, and only those whose axones enter into the formation of distinct tracts of the cord will be here mentioned. Of the above-described central arms of the peripheral sensory neurones, some of the shorter enter the gray matter of the cord and with their collaterals terminate around motor cells (reflexes). Others terminate around cells whose axones cross to the opposite side of the cord and pass upward as the antero-lateral ascending tract, or tract of Gowers. Other fibres terminate around cells of the column of Clarke, the axones of which pass upward as the direct cerebellar tract.

In addition to these main fibre tracts, there are in all regions of the cord fibres which are commissural in character. These fibres are the axones of cells situated in the gray matter of the cord, and after passing a short distance up or down and sending

¹ Certain recent observations tend to show that there may be a small number of "direct" fibres in the so-called crossed pyramidal tract.

collaterals into the gray matter, themselves re-enter the gray matter and terminate there. These short fibres make up the so-called ground bundles or fundamental columns of the cord. They attain their greatest development in those regions of the cord where the reflex centres are most extensive, *i.e.*, in the lumbar and cervical enlargements.

Secondary Degenerations.

Secondary degenerations are dependent upon the fact already noted, that, the cell body being the trophic centre of the neurone, the axone when separated from its cell body dies.

DESCENDING DEGENERATION.—Any cortical lesion, such as embolic softening and apoplectic clots, which destroys the nerve cells, or any lesion of the brain or cord which interrupts the axone tracts of the cortico-

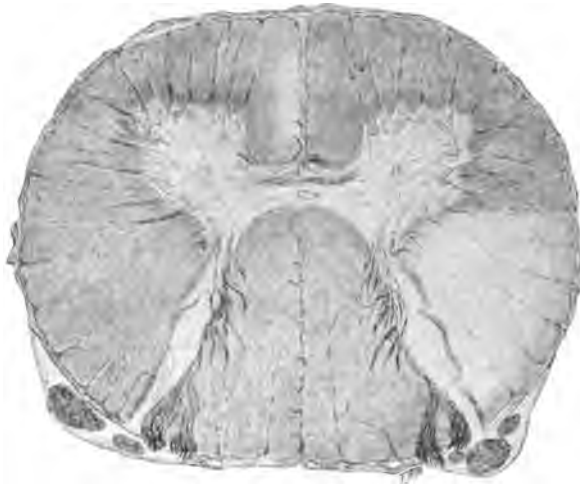

FIG. 661.—SECONDARY DESCENDING DEGENERATION.

From hæmorrhage into the internal capsule, almost complete degeneration of the direct pyramidal tract on the same side as the lesion and of the crossed pyramidal tract on the opposite side. There were a few degenerated fibres in the crossed tract on the same side as the lesion.

spinal system of neurones, determines a complete degeneration of the affected axones (Fig. 661). The course of these axones has been described. Thus a lesion of the brain affecting motor neurones is followed by a degeneration in the motor tract of the same side down to the pyramidal decussation, and below that point, in the direct motor tract on the same side and in the crossed tract on the opposite side, the number of degenerated fibres being proportionate to the number of cells destroyed or axones interrupted. In a number of cases of descending degeneration due to cerebral lesions, degenerated fibres were found in the crossed pyramidal tract on the same side as the lesion. This degeneration was not present in all cases, and in no case was it as marked as the degeneration in the opposite lateral tract. The explanation is that in some cords a small number of fibres instead of decussating pass down into the cord in the lateral tract of the same side.

In descending degeneration due to a lesion below the pyramidal decussation a somewhat different picture is presented. In a complete transverse lesion there is degeneration of both crossed and of both direct pyramidal tracts. If the lesion is unilateral the degenerations are upon the same side as the lesion. The areas of degeneration are also larger and less sharply defined than in cerebral lesions. Then in addition to the degeneration of the pyramidal tracts there is a degeneration of a considerable number of fibres in a crescent-shaped area lying near the periphery of the antero-lateral region and extending from the crossed to the direct tract. Degeneration of these fibres has been described by Marchi¹

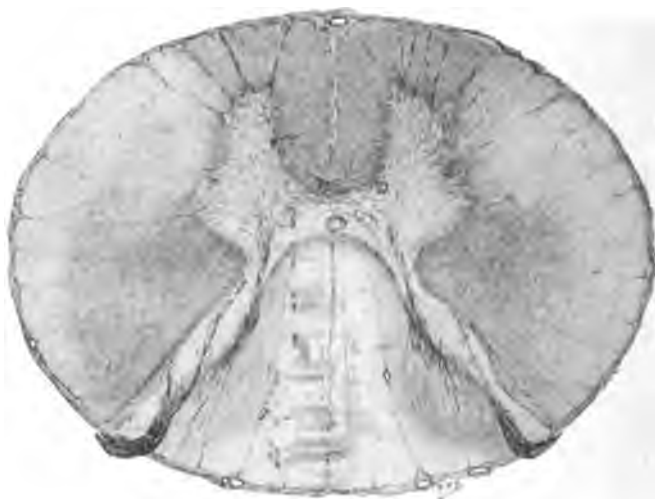


FIG. 662.—SECONDARY ASCENDING DEGENERATION.

Following complete crushing of the cord about two segments below the level at which the section was taken. Degeneration is almost complete in the columns of Goll, of Gowers, and the direct cerebellar tracts. A few normal fibres are seen in the columns of Burdach. These are the ascending axones of spinal ganglion cells between the point of injury and the level of the section, and are seen to occupy that part of the posterior columns adjacent to the posterior horns.

after removal of the cerebellum. He considers them descending cerebellar fibres. The so-called comma-shaped degeneration in the posterior columns is sometimes present. Schultze² regards these fibres, which are situated about the middle of the posterior columns, as descending axones of spinal ganglion cells. Tooth³ thinks that they are more probably descending branches of commissural neurones. In the fundamental columns the degeneration extends but a short distance below the seat of injury, and of course affects only those axones which descend.

ASCENDING DEGENERATION.—Any lesion which destroys the spinal ganglion cells or which interrupts their axones determines a secondary ascending degeneration in the posterior columns (Fig. 662). Any lesion

¹ Marchi, "Origine e decoroso dei peduncoli cerebellari." *Rev. Sper. de Fren. e Med. e leg.*, Bd. xvii., p. 367.

² Schultze, "On Comma-shaped Degeneration of the Posterior Columns," *Arch. f. Psych.*, 1883.

³ Tooth, "Goulstonian Lectures on Secondary Degeneration of the Spinal Cord," London, 1889.

of the cord which interrupts the tract of Gowers or the direct cerebellar tract is followed by degeneration of the fibres of these tracts above the lesion (Fig. 662). Immediately above the lesion there is complete degeneration of the tracts. As we pass upward new undegenerated fibres from the spinal ganglia above the lesion enter the column of Burdach, so that there appears in the posterior columns a constantly increasing number of normal fibres. Also in the column of Gowers undegenerated fibres appear as one passes upward from the lesion. Some of these fibres probably have their origin in the gray matter of the cord, and the number of normal fibres is in proportion to the number of these cells between the lesion and the point at which the section is taken. Descending fibres in these columns have already been mentioned. They, of course, do not degenerate. If the lesion be above Clarke's columns the degeneration in the cerebellar tracts remains complete; if not, the number of normal fibres is in proportion to the number of Clarke's column cells between the lesion and the point of section. The ascending fibres of the fundamental columns also degenerate, but are so short that they cannot usually be traced beyond the area of direct action of the traumatism.

Primary Degenerations.

DEGENERATION OF THE PERIPHERAL MOTOR NEURONES.

Progressive spinal muscular atrophy is the clinical designation of a disease, the underlying lesion of which is a progressive atrophy or degeneration of the lower motor neurones. There is a degeneration of the large motor cells of the anterior horns and of their processes. This degeneration goes on to complete destruction of some neurones. With the loss of nerve tissue proper there is a compensatory growth of neuroglia. In a well-advanced case, section of the cord shows a marked diminution in the number of anterior horn cells and an atrophic condition of the horn itself and of the anterior roots. The lesion usually begins in the cervical region. More rarely it starts in the lumbar cord. The degeneration may extend to the motor cranial nerve nuclei, giving the picture of a progressive bulbar paralysis. The medullary nuclei most commonly involved are the hypoglossal and the spinal accessory. Less often the degeneration affects the cells of origin of the fifth and seventh. Degeneration of the peripheral nerves has been described. The muscular lesions correspond to the lesions in the cord, the muscles of the hand and arm being usually first affected. For the degenerative changes in the muscles see page 869. This lesion is sometimes described as a chronic anteropoliomyelitis. Both its clinical history and its pathology, however, indicate the degeneration as the initial lesion and the neuroglia increase as secondary—a replacement hyperplasia.

DEGENERATION OF THE CORTICO-SPINAL MOTOR NEURONES.

Spastic Paraplegia—Spastic Spinal Paralysis.—This may be described as a primary lesion of the upper or cortico-spinal motor neurones. It

is probable that the lesion affects the entire neurone. As a distinct pathological entity the condition is extremely rare. Whether it originates in a degeneration of the cell bodies of these neurones in the cortex is not known. The clinical picture of spastic paraplegia, due to compression, to a transverse myelitis, or to a multiple sclerosis, is not uncommon. Marie¹ considers spastic paraplegia as a disease appearing in childhood, and due to a faulty development of the cortico-spinal motor neurones, rather than to their degeneration.

DEGENERATION OF BOTH PERIPHERAL AND CORTICO-SPINAL MOTOR NEURONES.

Amyotrophic Lateral Sclerosis.—This is a primary progressive degeneration involving both cortico-spinal and spino-peripheral motor neurones. The appearance of the transverse section of the cord is a combination of that in spastic paraplegia and that in progressive muscular atrophy. There is a degeneration of the cells of the anterior horn with atrophy of

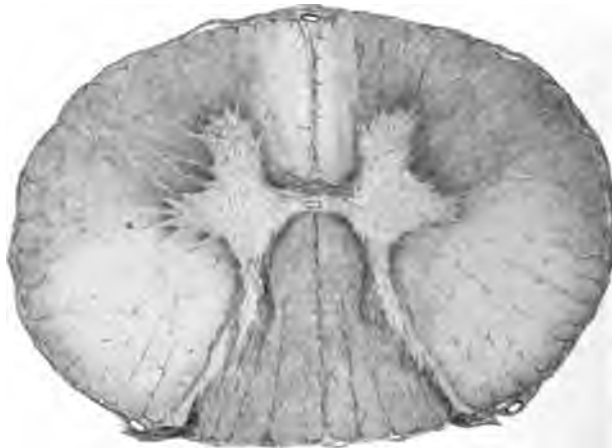


FIG. 663.—AMYOTROPHIC LATERAL SCLEROSIS.

Degeneration of the crossed pyramidal and of the direct pyramidal tracts. In this case there was but little atrophy of the anterior horns. Very few cells, however, were present in the anterior horns and there was an increase in the connective tissue of the horns.

the horn itself, and a degeneration of the fibres of the direct and of the crossed pyramidal tracts (Fig. 663). The lesion in the horns is usually most pronounced in the cervical region. The extent of involvement of the motor tracts of the cord is extremely variable. The degeneration, which is the initial lesion, is accompanied by a replacement connective-tissue hyperplasia, and the picture presented on section of the cord is that of a sclerosis of the motor tracts and of the anterior horns. Quite frequently the sclerosis is not wholly confined to the motor tracts, but extends into the neighboring anterior and lateral tracts, especially in

¹ Marie, "Lectures on Diseases of the Spinal Cord," London, N. S. Soc., 1895.

the cervical region. The degeneration in these tracts has been traced through the medulla, pons, and crus to the cortex, where changes have been observed in the large pyramidal cells. In the gray matter of the medulla are also found changes analogous to those in the anterior horns, consisting in degeneration of the cells of the motor cranial-nerve nuclei (hypoglossal, spinal accessory, pneumogastric, glosso-pharyngeal, and facial). The atrophy of the muscles innervated by these nerves gives the clinical picture of glosso-labio-laryngeal paralysis or progressive bulbar paralysis. The medullary lesion may occur without any corresponding lesion of the cord, thus giving rise to a bulbar paralysis without any spinal symptoms. The seat of the initial lesion, whether in the cell bodies in the cortex or in their axones, is as yet undetermined. The fact that disturbances of nutrition acting primarily upon the cell body are frequently most evidenced by changes in parts of the neurone farthest from the trophic center has already been mentioned. The muscle changes are those of a progressive muscular atrophy.

DEGENERATION OF THE PERIPHERAL SENSORY NEURONES. (*Tabes Dorsalis—Posterior Spinal Sclerosis—Locomotor Ataxia.*)

The essential lesion of tabes is a primary progressive degeneration of the peripheral sensory neurone system. As its older title indicates, the clinical picture of locomotor ataxia had been attributed to a primary sclerosis of the posterior columns. This was not because in these columns was the only lesion, but because, owing to the close packing together here of the sensory axones, this lesion was the most conspicuous. The distribution of the lesion is coextensive with the peripheral sensory neurone system (p. 952). Any part of the system may be affected or the lesion may involve practically the whole system. Again, the entire neurone may be affected, or only part of the neurone, or one part more than other parts. In general it may be said that it is the central process of the neurone, which enters the cord in the posterior nerve roots, that shows the earliest and most extensive changes.

It is convenient to classify the lesions of tabes according to the anatomy of the peripheral sensory neurone system, as follows:

1. *The Peripheral Processes.*—(a) The sensory nerve endings. Changes of a degenerative character have been described in the sensory nerve endings of the skin, joints, and muscle. Especially well marked are lesions of the (sensory) muscle spindles which are almost constantly present.

(b) The peripheral nerves. Degenerations of the peripheral nerves are common. Like similar conditions due to toxic agents, they are usually referred to as a neuritis. The changes in both axones and medullary sheaths are, however, degenerative in character and similar to those of a Wallerian degeneration. The lesion is confined wholly to the sensory fibres, the motor fibres remaining intact. It is usually most pronounced in the smaller peripheral branches of the nerves. Degeneration of the optic nerve—so-called optic neuritis—occurs in from ten to twenty per

cent. of cases. Degeneration of the auditory nerve and of the sensory fibres of the pneumogastric, glosso-pharyngeal, and trigeminus is of less frequent occurrence.

2. *The Cell Bodies*.—Marked degenerative changes in the cells of the spinal and analogous cranial ganglia have been described. In a number of cases they have been found early in the disease. There is a reduction both in number and in size of the ganglion cells, with a replacement connective-tissue hyperplasia. Chromatolysis with nuclear eccentricity as demonstrated by the method of Nissl has also been observed. Similar changes have been noted in the nerve cells of the retina.¹

3. *The Central Processes*.—(a) The sensory nerve roots, consisting as they do of the central processes of the spinal ganglion cells, show more or less complete degeneration. It is, in fact, in this part of the neurone that the earliest and most conspicuous changes are usually found. The extent and location of the degeneration vary. In the more common type of the disease—lumbar tabes—the earliest lesions appear in the posterior roots of the lumbar nerves. Only a few of the roots are at first affected, and only some of the fibres in these roots. With the progress of the disease more fibres are involved and the degeneration extends downward to the sacral roots and upward to those of the dorsal and cervical nerves. In specimens stained by Weigert's method the contrast between the darkly stained anterior root fibres and the almost unstained posterior root fibres is often marked.

(b) The spinal cord. On removing the cord in a case of advanced tabes, certain changes are usually apparent to the naked eye. The pia mater between the two posterior horns is apt to be thickened, of a dull appearance, and adherent to the cord. This, in contrast to the normal condition of the rest of the pia, gives the effect of a narrow band extending the length of the cord. The posterior columns may be depressed, of a grayish color, and firmer than the rest of the cord. On section the contrast between the posterior columns and the rest of the white matter of the cord is often very distinct. In cords removed from cases dying during the earlier stages of the disease there are often no macroscopic lesions.

The microscopic appearances vary, depending on the stage, extent, and location of the lesion (Fig. 664).

In a case which comes to autopsy early in the disease the appearance of the lesion differs from that in a case of advanced tabes. As already noted, the most marked changes are in the posterior columns. In the more common type of the disease in which the degeneration begins in the lumbar region, sections of the cord at this level show certain quite well-defined areas of degeneration. The zone of Lissauer early shows marked degenerative changes. This zone extends across the entering fibres of the posterior root which divide the zone into two parts. The degeneration of the outer part has been wrongly described by some writers as a lateral-column degeneration. It will be remembered that these

¹ In Plate XIII., 7, is seen a portion of a spinal ganglion from a case of advanced tabes. In addition to a degeneration of the cells present, there was a marked reduction in the number of cells in the ganglion.

fibres are short fibres which have entered the cord in the nearest posterior root. Degeneration usually appears early in that part of the column of Burdach which borders the posterior horn. The column of Goll varies as to the extent of involvement. In many cases it is only slightly affected, in others the degeneration is marked. As the fibres of this column come mainly from the last lumbar and first two sacral segments, it is seen that its condition depends entirely upon the integrity of these roots. The fibres of the posterior columns have two sources: (1) entering fibres of the posterior roots; (2) fibres from cells in the gray matter

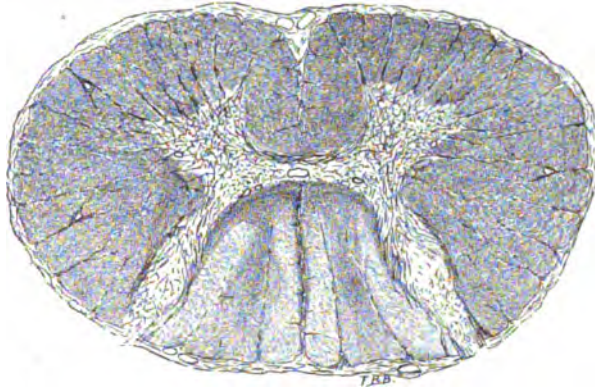


FIG. 664.—TABES DORSALIS.
Cervical region, showing an early stage of the lesion.

of the cord. The latter are situated mainly in a narrow strip behind the posterior commissure and in the median oval area of Flechsig. These fibres are unaffected in tabes.

The degenerations seen in sections of the dorsal and cervical cord in lumbar tabes are dependent upon an ascending degeneration of the fibres affected below. The columns of Goll are thus usually affected, while the columns of Burdach are often only slightly involved. If at any level of the cord degenerated root fibres enter the cord, there results a degeneration in the zone of Lissauer and in the band of fibres lying along the posterior horn at that level.

Rarely the tabetic process begins in the cervical region. In these cases section of the cervical cord shows not only normal endogenous fibres, but a normal condition of the column of Goll and of such part of the column of Burdach as originated below the level of the lesion. Sometimes the dorsal roots are affected with the cervical. In cervical tabes the cord below the affected region is normal, while above is the lesion of an ascending degeneration. The lesion may in any case be asymmetrical, one root of a segment being affected while the other remains normal. Marie describes a variety of tabes in which the lesions begin in the cranial nerves.

In cases of advanced tabes (Fig. 665) there are often almost no normal nerve fibres in the posterior columns; the columns of Goll, of Burdach, and of Lissauer presenting little but dense fibrous tissue. The

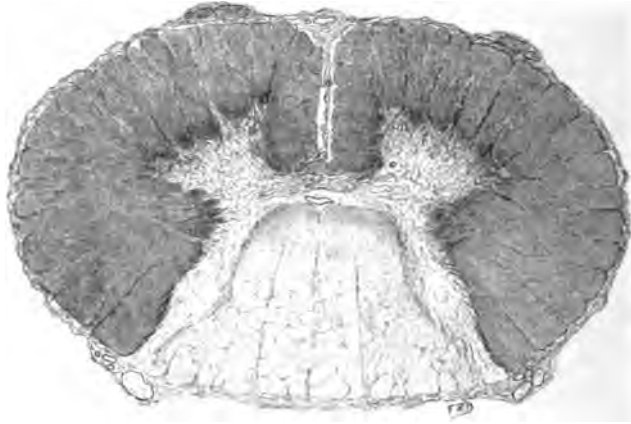


FIG. 665.—TABES DORSALIS.
Cervical region, showing an advanced stage of the lesion.

posterior fissure may be completely obliterated. There usually remain, however, even in advanced tabes, undegenerated fibres bordering the posterior commissure and the adjacent parts of the posterior horns. The

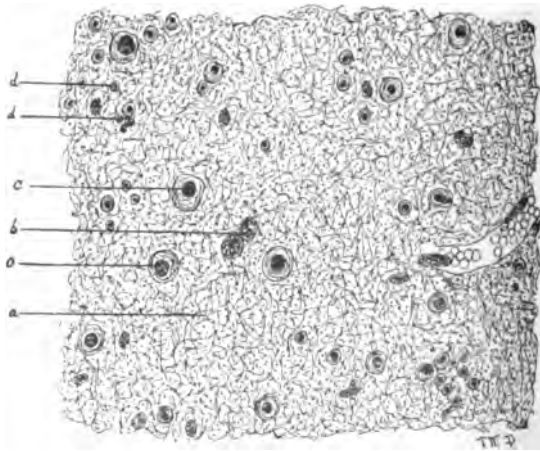


FIG. 666.—POSTERIOR SPINAL SCLEROSIS. (TABES DORSALIS.)
A portion of sclerosed area in the posterior columns of the spinal cord. *a*, New-formed connective tissue; *b*, blood-vessels; *c*, nerve fibres; *d*, atrophied nerve fibres.

median area of Flechsig also remains intact. As already noted, these fibres are endogenous.

The microscopical appearance of the degenerated areas varies with the stage of the process (Fig. 666). The new connective tissue may be at

first quite cellular; later the fibrillar elements predominate and the tissue becomes dense and firm. Of the nerve roots some have disappeared, others show degeneration of their medullary sheaths and axis cylinders. Some few normal fibres are usually present even in advanced sclerosis. The blood-vessels often have thickened walls. There may be corpora amylacea and fat globules, the latter either free or collected in cells.

The lesion of tabes is not, however, confined to the posterior columns. The fibers of these columns are constantly sending collaterals and terminals into the gray matter. Most of these pass into the posterior horns, an especially well-marked group entering Clarke's cell column. The posterior horns are therefore usually smaller than normal, with a marked reduction in the number of fibres entering them from the posterior columns, while the columns of Clarke show a diminution in the number of delicate fibrils which normally surround the ganglion cells.

Changes have also been described in the spinal root of the fifth cranial nerve and in the fasciculus solitarius which consists of afferent fibres of the vagus and glosso-pharyngeal nerves. These fibres are analogous to those of the posterior columns, and the changes in them are similar.

Degenerations of a secondary character may occur in those systems of neurones which are more or less dependent upon the peripheral sensory neurone system for their impulses. Thus the cells of Clarke's column may be affected, with resulting degeneration of their axones which make up the direct cerebellar tract. This degeneration extends through the restiform body to the termination of the tract in the cerebellum. The cells of the gray matter whose axones form Gowers' tract may be degenerated with consequent degeneration of the fibres of this tract. In the medulla the cells of the nucleus gracilis and nucleus cuneatus may be affected, thus determining an ascending degeneration along the tracts followed by their axones. Similar in character is the degeneration of the cells of the anterior horns noted by Condoléon. These changes in the anterior-horn cells have been accepted by some investigators as explanatory of the various trophic disturbances which so frequently occur during the course of tabes. Similar changes have been found in the nuclei of two of the motor cranial nerves, the oculomotor and the hypoglossal. Others ascribe the trophic disturbances to a peripheral neuritis. Marie¹ describes a case interesting in this connection, in which there was marked hemiatrophy of the tongue with distinct changes in both main and accessory nuclei of the hypoglossal nerve on the same side, the opposite nuclei being normal. Oppenheimer describes a similar case of tabes with laryngeal crises in which there were pronounced degenerative changes in the pneumogastric nucleus and in the ascending root of the glosso-pharyngeal. Changes have been described in the cells of the cerebral cortex. They are similar to those found in dementia paralytica, but less marked.

Although various hypotheses have been advanced in explanation of the tabetic lesion, and especially in reference to the fairly constant selection of certain groups of

¹ Marie, *loc. cit.*, p. 956.

neurones, doubt still exists as to the origin and essential nature of the process. Earlier writers look upon the lesion as a primary sclerosis of the posterior columns, probably of vascular origin. Flechsig¹ and Trepinski² describe the posterior columns as made up of several distinct systems of fibres, each system distinguishable from the others by its period of ripening or myelinization. They assert that the tabetic process affects these different systems successively. As the systems overlap one another, this would explain the admixture at certain stages of tabes of normal and abnormal fibres. Present knowledge favors the view that tabes is a primary degeneration of the peripheral sensory system of neurones, the degeneration affecting the entire neurone, and that the picture presented by the tabes cord varies with the particular neurones affected. The cell bodies of these neurones are in the spinal ganglia and their cranial analogues. Thorough examinations of spinal ganglion cells have as yet been made in too few cases to warrant any general conclusions. Degeneration of spinal ganglion cells in tabes has been reported even in cases dying early in the disease. Such

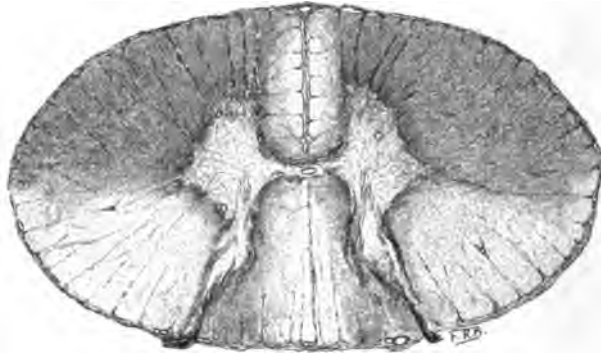


FIG. 667.—COMBINED SYSTEM DISEASE.

Showing degeneration and sclerosis in the columns of Goll, the direct and the crossed pyramidal tracts, and the direct cerebellar tract.

degenerations are best shown by the method of Nissl, the general application of which is comparatively recent. Certain it is that a degeneration which affects both peripheral and central processes of the neurone, and yet is most pronounced in those parts of the neurone farthest removed from its nutritive centre, is most easily explained on the basis of some agent affecting the general metabolism of the neurone. A majority of the cases of tabes give a syphilitic history. Our knowledge of the effects of toxins upon neurones is certainly not opposed to the consideration of such a toxin as the etiological factor in tabes.

COMBINED SYSTEM DEGENERATION—ATAXIC PARAPLEGIA.—This is a disease of uncertain etiology, in which there are degenerative changes in both motor and sensory neurone systems (Fig. 667). The tracts usually involved are those of Burdach and of Goll, the direct cerebellar tracts, and the crossed pyramidal tracts. Less commonly the degeneration extends to the tracts of Gowers and to the direct pyramidal tracts. It seems probable that the lesion in the cord is not always the expression of the same pathological process, and that in many cases it is not the result of a true systemic degeneration. In perhaps the minority of cases

¹ *Flechsig*, "Die Leitungsbahnen im Gehirn und Rückenmark," Leipsic, 1878. "Ist die Tabes Dorsalis eine System-Erkrankung?" *Neur. Cent.*, Bd. ix.

² *Trepinski*, "Die embryonalen Fasersysteme in den Hintersträngen und ihre Degeneration bei der Tabes Dorsalis," *Arch. f. Psych. und Nerv.*, Bd. xxx., 1897.

the lesion corresponds to the tract systems of the cord and probably represents a combined sensory-motor degeneration. Such are those rare cases in which the degeneration affects all of the above-mentioned tracts.

According to Dejerine, the appearance of a combined system disease may be induced by the chronic meningitis, which exists over the posterior columns in tabes, extending forward over the direct cerebellar tract, the productive inflammation finally spreading to this tract and to the crossed pyramidal. In these cases that part of the latter tract which lies deepest, *i.e.*, close to the gray matter, usually remains uninvolved. Marie lays particular stress upon the arterial systems of the cord as the prime factor in many cases, calling attention to the fact that the lesion, as it is most commonly found, coincides almost exactly with the distribution of the posterior spinal arteries. By others the lesion is ascribed to a multiple sclerosis, the restriction of the degeneration to definite tracts being only apparent. It is possible that in some cases the pathological picture of a combined sclerosis may be due to secondary degeneration following myelitis.

A subacute type of combined system degeneration has been described by Russell.¹ The degeneration involved the same tracts affected in the more chronic type, and was often very extensive at some levels of the cords studied, there being only a thin layer of normal fibres covering the gray matter.

Under the name of diffuse degeneration of the spinal cord, Putnam and Taylor² describe a somewhat similar condition, leaving open the question as to the systemic nature of the process.

FRIEDREICH'S ATAXIA. (*Hereditary Ataxia*).

This disease, while often referred to as hereditary ataxia, has more of a family than of a distinctly hereditary character. Its pathology is marked by a decrease in the size of the spinal cord, the diameter of which is often not more than three-quarters that of the normal cord. Degeneration of the columns of Goll is usually quite complete. Less marked degeneration is found in the columns of Burdach, in the direct cerebellar and in the crossed pyramidal tracts. The marginal tract of Lissauer may or may not be affected. In the posterior horns and in the columns of Clarke the condition resembles that in tabes. There may be atrophy of the cerebellum.

Marie notes in addition, atrophy and disappearance of the cells of Clarke's column. Bloq and Marinesco³ describe degeneration of the posterior root fibres similar to that found in tabes. Friedreich⁴ and Rüttimeyer⁵ find atrophy of the anterior horn cells. The determining cause of the disease and the nature of the morbid process are as yet undetermined. It seems probable that the condition of the cord may be more properly considered an abnormality of development rather than a degeneration.

CEREBELLAR ATAXIA.

Atrophy of the cerebellum was noted as sometimes occurring in Friedreich's ataxia. In that disease, however, the cord lesion was most

¹ Russell, Batten, and Collier, *Brain*, vol. xxiii., p. 39, 1900.

² Putnam and Taylor, *Journal of Nerve and Ment. Disease*, vol. xxviii., pp. 1 and 74, 1901.

³ Bloq, P., and Marinesco, G., "Sur l'Anatomie Pathologique de la Maladie de Friedreich," *Compte rend. Soc. de Biol.*, 1890.

⁴ Friedreich, N., *Virchow's Archiv*, Bd. lxxxvi., 1881.

⁵ Rüttimeyer, L., *Virchow's Archiv*, Bd. cx., 1887.

marked. In cerebellar ataxia the lesion of the cord is slight or absent, the chief lesion being an atrophy of the cerebellum. This atrophy is accompanied by little or no sclerosis, the organ being simply smaller than normal.

INFLAMMATION.

INFLAMMATION OF THE BRAIN. (*Encephalitis.*)

Acute Encephalitis.—Inflammatory processes in the nervous system, whether of an exudative or of a productive type, are frequently consecutive to or coincident with the more severe forms of degeneration or other lesions, thus making differentiation of the processes often extremely difficult. It has been already mentioned that the brain tissue about hæmorrhages and areas of embolic and thrombotic softening may undergo inflammatory changes leading to the formation of new connective tissue. There is a class of cases in which localized areas of the brain undergo softening, with more or less extravasation of red and white blood cells and hyperæmia, so that the softened material consists, as seen under the microscope, of detritus of brain tissue in a condition of fatty degeneration, often with more or less pus cells and pigment. When such areas are red in color from intermingled blood cells or pigment, the condition is called *red inflammatory softening*. When fatty degeneration prevails, and the red blood cells or their derivatives are not abundant, the softened area looks yellow or yellowish-white, and this is often called *yellow inflammatory softening*. The origin of these processes is very obscure and their inflammatory nature not well defined.

ABSCESS OF THE BRAIN.—Small multiple abscesses of the brain may occur in pyæmia. Large abscesses of the brain are usually single; they may attain a large size. They are most frequent in the cerebral and cerebellar hemisphere, rare in the basal ganglia, the pons, and the medulla oblongata.

There may be an irregular cavity containing thin pus and softened brain tissue. The walls of the cavity are ragged and infiltrated with pus, and outside of the walls is a zone of œdematous and softened brain tissue. If the abscess be near the pia mater, meningitis may follow; if it be near the lateral ventricles, it may rupture into them; if it be near the sinuses of the dura mater, it may induce thrombosis. An abscess may in time become enclosed in a capsule of connective tissue.

Abscess of the brain is most frequently secondary to chronic suppurative otitis (42.5 per cent., Gowers), much less frequently to acute otitis. With the otitis there may also be caries of the temporal bone, suppuration of the mastoid cells, and inflammation of the dura mater. The abscess is usually situated deep in the brain, commonly in the temporo-sphenoidal, the frontal, the occipital or the parietal lobes, or in the cerebellum; rarely it is continuous with the inflamed dura mater and bone. Abscess may follow chronic lesions in the orbit or caries of various parts of the cranial bones.

Abscess of the brain frequently follows traumatism, blows, or falls on the head. Such injuries may not damage the skull, or may produce fractures or necrosis. There is often a considerable interval between the time when the injury is inflicted and the development of the symptoms.

When the cranial bones are uninjured the abscess is usually deep in the brain; when there is necrosis of the bones the abscess may be superficial; when the bones are fractured the abscess may be either superficial or deep. The abscess develops rarely in the opposite side of the brain.

In acute exudative meningitis from various excitants there may be an infiltration of the brain with leucocytes; this may be especially marked in the perivascular tissue and around the ganglion cells.

An Acute Disseminated Encephalitis,¹ hæmatogenous in character, may develop during the progress of an infectious disease. It is most common in infective endocarditis, in pyæmia, and in epidemic cerebro-spinal meningitis. It may be associated with acute anteropoliomyelitis, apparently due to the same obscure etiological factor. The lesion consists of disseminated foci of inflammation, or minute multiple abscesses. Some of these are microscopic in size, others may be seen with the naked eye. The smallest show simply small-round-cell infiltration of the walls of one or more small vessels and of the surrounding tissue. The larger spots, which undoubtedly take origin in the same way, are seen to be softer than the rest of the tissue, and resemble red or yellow softening, according to the amount of red-blood-cell extravasation. Congestion is usually marked. There may be distinct hæmorrhages. Degenerative changes with disintegration of the exudate usually set in and determine destructive changes in the neighboring neurone and neuroglia elements. At the periphery of one of these abscesses the neuroglia, instead of being in a degenerating condition, usually shows proliferation. The more minute inflammatory foci may undergo complete resolution with absorption of the exudate. In the larger abscesses there may be absorption of the exudate and of the products of degeneration, and a replacement neuroglia hyperplasia, ultimately resulting in a sclerotic patch.

Suppurative encephalitis may occur as a result of traumatism or from extension of suppurative meningitis.

A form of encephalitis which has been designated acute non-suppurative hæmorrhagic encephalitis, has been described by Strümpell, Leichtenstein, Oppenheim, Putnam,² and others. The lesion consists in the occurrence of multiple hæmorrhagic, inflammatory foci, which are non-suppurative, and which are accompanied by leucocytic infiltration. These foci may occur in any part of the brain, but are most numerous in the white matter of the brain and basal ganglia. Some of these hæmorrhages may be quite large.

¹ Under the head of "Acute Parenchymatous Encephalitis" has been described a lesion of the ganglion cells without vascular or interstitial changes. These lesions are the result of toxæmias of either endogenous or exogenous nature. They are more properly classed as parenchymatous degeneration.

² Putnam, *Jour. of Nerv. and Ment. Dis.*, vol. xxiv., 1897, bibliography.

ACUTE INFLAMMATION OF THE SPINAL CORD. (*Acute Myelitis.*)

Inflammation in the spinal cord is quite analogous to inflammation in the brain.

Acute Disseminated Myelitis¹ runs a rapid course and proves fatal in a short time. The inflammation may involve nearly the whole length of the cord, but is usually more intense in some places than in others. The cord is swollen and congested, it is infiltrated with pus cells, the connective tissue is swollen, and there is degeneration of the nerve elements proper.

More frequently an acute myelitis is localized. It involves but a small portion of the length of the cord, while laterally it may completely cross it, and is hence spoken of as a *transverse myelitis*. When the cord is removed and laid upon the table, if the lesion is marked, a flattening of the cord at its seat may be observed; or on passing the finger gently along the organ, the affected segment will be found softer than the rest of the cord, sometimes almost diffuent. On making a section through the affected portion the nerve tissue may appear white or red or yellowish or grayish.²



FIG. 668.—DEGENERATED TISSUE FROM ACUTE MYELITIS.

Microscopical examination shows different appearances, depending upon the stage of the degenerative or inflammatory process. There may be much blood, or, if the lesion has existed for some time, blood pigments; also fragments of more or less degenerated nerve fibres and ganglion cells (Fig. 668), myelin droplets, free fat granules, larger and smaller cells filled with fat granules (Gluge's corpuscles), pus cells, granular matter, neuroglia cells, and sometimes corpora amylacea. The various proportions of these elements give rise to the different gross appearances which the diseased part presents. In earlier stages of the lesion the blood-vessels may be dilated, the nerve fibres and cells swollen; or the walls of the blood-vessels may be thickened or fatty, or surrounded by a sheath of leucocytes and cells derived from the connective-tissue cells of the adventitia.

The lesion is apt to commence in the gray matter or at its edge, and then extend first laterally and afterward upward and downward.

In a certain number of cases the degenerated material may be

¹ Acute parenchymatous myelitis, like its analogue in the brain, is a lesion of the ganglion cells, and is more properly classed as a degeneration. Embolic and thrombotic softenings are more rare in the cord than in the brain, and are necessarily much more restricted in extent. When of an inflammatory character they resemble the similar brain lesion and are red or yellow according to the amount of extravasation.

² It should be remembered that the mechanical injury to the cord in removal, such as crushing or bruising, may reduce the injured portion to a pulpy consistence and thus produce appearances somewhat similar to those of some forms of inflammatory softening. See reference to *Van Gieson*, on "Arteries of the Nervous System," p. 928.

absorbed and a cicatrix or cyst formed. After the least extensive forms of the lesion there may be a restoration of the functions of the cord.

Secondary degeneration, both ascending and descending, may occur in this form of myelitis, varying in extent according to the size of the primary lesion. The terms *central myelitis*, *peripheral myelitis*, and *unilateral myelitis*, are sometimes used to designate localizations of the lesion.

Poliomyelitis Anterior—Myelitis of the Anterior Horn.—This name is applied to a group of cases which are characterized by clinical symptoms indicating changes in the anterior horns. The disease is most common in children, under the name of *infantile spinal paralysis*, but occurs also

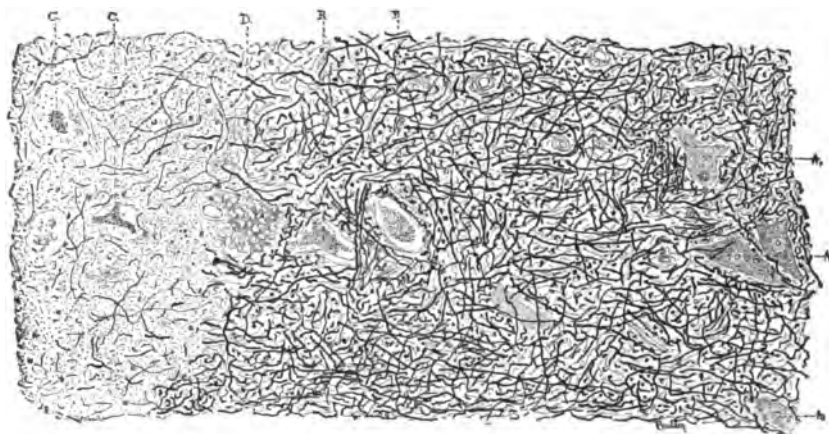


Fig. 669.—POLIOMYELITIS ANTERIOR.

A, Normal ganglion cells surrounded by nerve fibres; B, degenerated ganglion cells; C, granular masses at place of ganglion cells; D, small cavity containing fluid.

in adults. It usually begins with symptoms of an acute infectious disease, the paralysis supervening after a few days. It varies in acuteness, severity, and duration. In many cases there is complete recovery, and then we must suppose that the changes in the nervous tissue were not destructive in character. In other cases the symptoms are more permanent, indicating a destructive lesion.

At first a considerable group of muscles, usually of the arms or legs, is affected. Resolution taking place, there may be complete disappearance of the paralysis. More commonly there is return of function in most of the muscles, while some few remain permanently paralyzed and become atrophied. The lesion is most frequent in the lumbar and cervical enlargements, but may occur anywhere, and is often found in scattered patches. Earlier autopsies were in cases of long standing, and the changes found consisted in degeneration (Fig. 669), shrinkage, pigmentation, and atrophy of the ganglion cells of the anterior horns, an increase in the connective tissue of the cornua and of the adjacent white matter, often with destruction of considerable portions of the horns, atrophy of the anterior roots, and distortion of the cord.

Instead of this shrinkage and atrophy of the horns there is sometimes found, especially if the case come to autopsy not too long after the onset, a gelatinous condition of the horns, the place of the horns being occupied

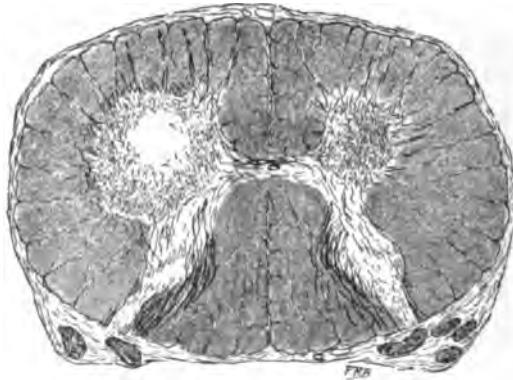

FIG. 670.—ACUTE ANTERIOR POLIOMYELITIS.
Death seven weeks after onset. Showing gliomatous tissue in both horns, with cavity formation in one of them.

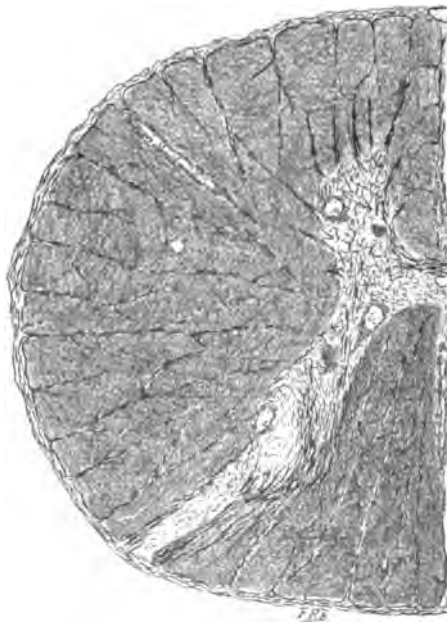


FIG. 671.—LANDRY'S PARALYSIS.
Section of spinal cord showing acute inflammatory process about the blood-vessels.

by young neuroglia tissue with many branching cells and fine delicate fibrils resembling glioma (Fig. 670). This gliomatous tissue may break down, forming a cavity surrounded by young neuroglia tissue. More

recently autopsies made early in the course of the disease show that the changes described above represent only later stages of what originated as an acute inflammatory process. Examination of the cords from such early cases shows congestion, œdema, the presence of mononuclear cells in the perivascular and nerve-cell spaces, and proliferation of the neuroglia. Degeneration of the nerve cells occurs, probably secondary to the inflammatory lesion. The inflammation is similar to that of an ordinary acute myelitis, but is usually confined largely to the area of distribution of the anterior spinal artery. The brain, the posterior root fibres, and the spinal ganglia may be involved in the exudative process. It is an acute infectious communicable disease, whose infective agent has not yet been isolated but concerning which much knowledge has recently been gained through experimental studies. see page 299.¹



FIG. 672.—LANDRY'S PARALYSIS.
Showing blood-vessels from Fig. 671,
more highly magnified. There are con-
gestion and infiltration of the walls
with leucocytes.

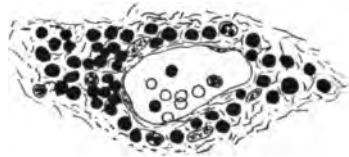


FIG. 673.—LANDRY'S PARALYSIS.
Showing blood-vessels from Fig. 671,
more highly magnified, leucocytes in the
walls.

Acute Ascending Paralysis—Landry's Paralysis.—This is a rare disease characterized clinically by a rapidly ascending paralysis, beginning in the lower extremities and progressing upward to involve the body, arms, and head. Until recently no pathological changes were known to explain the symptoms. Within the last few years a number of cases have been reported in which the lesion was an acute myelitis with or without an accompanying polyneuritis (Fig. 671).

Bailey and Ewing² reported a case in which the cord showed congestion with capillary hæmorrhages and circumvascular small round-cell infiltration (Figs. 672 and 673). The ganglion cells were in various stages of degeneration. Similar lesions have been reported by Marie and Marinesco, by Hertz and Lesné, and by others. Mills and Spiller report in some cases a polyneuritis in addition to myelitis. Krewer finds an acute myelitis and neuritis, and considers the lesion due to a non-specific infection. Brault reports three cases in which symptoms of Landry's paralysis followed lymphangitic abscesses from excoriation of lower limbs. He considers these cases of "myelic localization of a streptococcus infection." Remlinger describes a case in which the streptococcus was detected in the spinal-cord substance by cultivation and by stained sections. Remlinger also states that he has induced symptoms of an acute ascending paralysis in rabbits by inoculating them with pus from a septic abscess.

¹ For a *résumé* of recent studies on acute poliomyelitis by various authors, especially *Straus* and *Flexner*, see *Pediatrics*, August, 1910.

² Consult *Bailey and Ewing*, *New York Medical Journal*, July, 1896.

INFLAMMATION OF THE NERVES. (*Neuritis.*)

In the nerves, as in the brain and cord, degenerative changes commonly accompany inflammation, and a distinction is often difficult. The difficulty in sharp differentiation lies in the fact that degenerative changes in nerves, when intense or long continued, often lead to inflammations, and that inflammatory conditions in nerves often determine secondary degenerative changes in the nerve fibres.

Acute Exudative Neuritis.—Acute inflammation of the nerves may occur as the result of injury, or it may be secondary to an inflammatory process in their vicinity, although, owing to the dense lamellar sheaths and the special blood supply, the nerve trunks may escape participation even in very severe inflammatory processes in surrounding tissues. The inflamed nerve may be red and swollen and infiltrated with serum and pus cells. The process may undergo resolution or terminate in destruction of the nerve, or it may become chronic and result in the formation of new connective tissue. Degeneration and regeneration of the nerve fibres, similar to those described as following division of nerve trunks, may occur in acute neuritis.

“Multiple Neuritis” (Degeneration).—While for convenience of reference described under its usual title, this lesion is probably always a degeneration, and would be properly classified under the head of neurone degenerations of toxic origin. It is caused by the action of certain mineral poisons, for example, alcohol and lead. It occurs as a complication of, or succedaneum to, certain infectious diseases, for example, diphtheria, septicæmia, measles, smallpox, etc. It is sometimes apparently idiopathic. Changes of a degenerative nature are found in the peripheral nerves, and are more marked near the peripheral than near the cord. Thus the most common nerves affected are the anterior tibial and the radial. The most marked changes are in the nerves themselves, there



FIG. 674.—DEGENERATION OF NERVE FIBRES IN MULTIPLE NEURITIS.

From a case of alcohol poisoning. Specimen stained with osmic acid. The broken-down medullary sheath and fat droplets are stained deep black.

being little or no change in the connective tissue. More rarely, especially in very acute cases, there are reddening and swelling with some inflammatory reaction in the interstitial tissue. The fibre lesion shows best in specimens treated with osmic acid and teased in glycerin (Fig. 674). Here the myelin sheath is seen to be broken up, and instead of a continuous envelope of black stained myelin, the myelin is represented by larger or smaller black droplets scattered along a broken or degenerated axis cylinder. There may be some increase in the connective tissue. The sheath of Schwann is usually intact. It is of interest to note that in a number of cases (as yet too few to warrant general conclusions) changes have been found in the cells of the anterior horn analogous to those

found after injury to motor nerves. The muscles supplied by the affected nerves show various stages of atrophy. The cord and meninges usually remain normal. In some cases a spinal meningitis and more or less myelitis have been described.

CHRONIC INFLAMMATION OF THE BRAIN, CORD, AND NERVES.

While this term should be applied only to a primary increase in the neuroglia elements at the expense of the parenchymatous, thus making the degeneration of the nerve tissue proper entirely secondary, it is often difficult to eliminate the possibility of a primary degeneration of the nerve cells. Histologically the lesion consists in a proliferation of the neuroglia elements. The neuroglia cells increase in number, some of the new-formed cells having many processes, others few. In the early cellular stage of its formation the proliferative area is soft and gelatinous, and tends to increase the size of the part. With further progress of the sclerosis, there is a disproportionate development of fibres attached to the cells, and finally of fibres independent of cells. With the increase of fibres the affected area becomes firmer, making a sort of dense felt-work of interlacing fibrils. In this meshwork are found nerve fibres in various stages of degeneration.

Chronic Interstitial Encephalitis—Sclerosis.—This lesion of the brain tissue may occur diffusely occupying an entire lobe or more or less of the whole brain, or in circumscribed small areas. It consists essentially in an increase of the connective-tissue elements, the neuroglia, and an atrophy of the nerve elements, particularly the ganglion cells and the medullary sheaths of the nerves. With these changes are usually associated the formation of Gluge's corpuscles, corpora amylacea, granular and fatty degeneration of the nerve elements, and thickening and proliferation of cells of the walls of the blood-vessels. The areas of sclerosis may be very dense and hard, or gelatinous in consistence.

The diffuse form of sclerosis is most frequently seen in general paresis of the insane, and not infrequently in the brains of drunkards.

A peculiar feature of disseminated sclerosis is that the patches, whether in the brain or cord, do not induce the expected secondary degeneration. It is, in fact, uncommon to find secondary degeneration resulting from even a large patch of sclerosis. This is believed to be due to the fact that in nearly all of the patches the axis cylinders persist even after complete destruction of the medullary sheaths.

The circumscribed form of sclerosis, multiple sclerosis (*sclérose en plaque*), is much more common than the diffuse form, and may occur in the brain alone, or more commonly is associated with a similar lesion in the spinal cord. The areas of sclerosis vary in size from that of a pea to that of an almond. They may be few or numerous, they may be white, grayish, or grayish red in color, and are usually but not always sharply outlined by the unaltered brain tissue. Although in many cases the increase in the connective-tissue elements seems to be the primary lesion, and the degeneration of the nerve elements secondary

to this, it is quite possible that in some cases the increase in connective tissue may be secondary to a degeneration of the nerve elements from loss of nutrition or from other causes.

There is reason for the belief that multiple sclerosis may sometimes be the result of disseminated local necrotic lesions of acute infectious diseases—scarlatina, for example, occurring at an early period of life.¹

Encephalitis in the New-born.

This condition, first described by Virchow, is said to consist in the formation of circumscribed collections of cells of various sizes containing many fat granules (granular corpuscles) and forming yellowish masses, from 1 millimetre to 6 millimetres in diameter, in the brain tissue. A more diffuse occurrence of granular corpuscles is also described, but this is said by some observers to be physiological. The nature of this lesion is but little understood, and is still the subject of controversy.

LESIONS OF THE BRAIN IN GENERAL PARESIS OF THE INSANE.

The changes in this disease are in the main those of chronic diffuse encephalitis, but appearances vary greatly and depend to some extent upon whether the brain is examined in early or late stages of the disease. According to Meyer, in the early stages of the disease the convolutions, particularly of the anterior cerebral lobes, are swollen, the gray matter is congested and softened in places. The brain tissue is more or less infiltrated with leucocytes. Fatty degeneration of the walls of the capillaries, and punctate hæmorrhages, are also common.

In later stages of the disease a great variety of changes may be observed: hæmorrhagic pachymeningitis, thickening of the dura mater, and close adhesions to the skull; thickening and opacities of the pia mater, adhesions of the latter to the dura mater and to the brain tissue. The brain tissue is apt to be atrophied, is often very soft, and the ventricles are dilated and filled with fluid. The pia mater may be œdematous, the ependyma thickened and roughened. On microscopical examination the neuroglia is found to be increased in amount, the ganglion cells are shrunken and sometimes pigmented; the nerve fibres may also be atrophied, and the blood-vessels in a condition of fatty or hyaline degeneration. There may be an accumulation of fatty and granular cells along the walls of the blood-vessels. Secondary degenerations in the spinal cord are not infrequently observed.²

Chronic Interstitial Myelitis.—Under this heading are embraced a variety of lesions which probably differ from one another somewhat in the nature of the changes involved, but more in the seat of the disease. We shall consider without special classification the most important forms.

¹ See *Oppenheim*, Berl. klin. Wochenschrift, p. 184, 1896.

² It is very difficult to make positive and definite statements regarding many such lesions of the brain as those just indicated, or in general of brain lesions whose nature must be revealed by microscopical study, because our technical procedures in the study of the brain, even in normal conditions, are still in many respects quite unsatisfactory and incomplete. The brain tissue is so delicate and so liable to post-mortem changes, and the effects of different preservative agents are so liable to variations, that great caution is necessary in arriving at conclusions regarding the more minute lesions affecting the nerve tissue of the brain.

Chronic Transverse Myelitis.—In certain cases of pressure on the spinal cord from a tumor or from displacement of the bones of the vertebral column, etc., the cord, instead of becoming softened or undergoing acute inflammatory changes, becomes the seat of a localized formation of new connective tissue with consecutive atrophy of more or less of the nerve elements in the gray and white matter. The cord becomes in this way harder, and sometimes shrunken at the seat of lesion, and gray in color. This change may be followed by ascending and descending degeneration.

Chronic Disseminated Myelitis—Multiple Sclerosis.—This lesion, similar in its nature to multiple sclerosis of the brain, often occurs with it. It consists in the formation, in more or less numerous scattered, circumscribed areas, of new connective tissue, apparently derived from the neuroglia. The formation of new connective tissue is preceded or accompanied by degeneration and atrophy of the nerve fibres and ganglion cells. The new connective tissue consists of the characteristic branching neuroglia cells, surrounded by a more or less dense network of fine fibrillæ, many, if not most, of which seem to be branches of the neuroglia cells. Corpora amylacea and sometimes fat droplets, either free or contained in cells, may be present in the sclerosed areas.

The areas of sclerosis may involve both gray and white matter, and may be very small or large (Fig. 675). If very small or in early stages

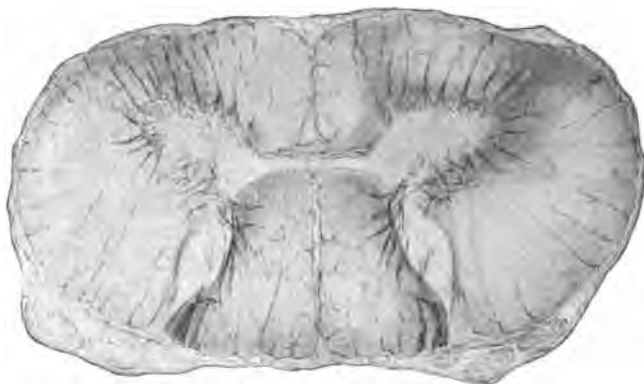

FIG. 675.—MULTIPLE SCLEROSIS IN THE SPINAL CORD.

Showing irregular areas in which there are atrophy of the nerve fibres and their replacement by connective tissue.

of formation, they may not be recognizable by the naked eye, but when visible they are grayish, translucent, and firmer than the surrounding tissue, and may or may not present a depressed surface; they sometimes project above the general level. The cause of this as of all other forms of so-called idiopathic interstitial myelitis is very obscure. As noted in multiple sclerosis in the brain, secondary degenerations are rare, and probably for the reason there given.

Chronic Interstitial Neuritis.—This is essentially a chronic interstitial inflammation resulting in an increase of the connective tissue in the nerve

sheaths and intrafascicular bands. As a result of this the nerve fibres undergo atrophy from pressure; the medullary sheaths and finally the axis cylinders being in many of the fibres partially or completely destroyed.

Tic Douloureux.—Changes in the peripheral branches of the fifth cranial nerve removed from obstinate cases of trifacial neuralgia have been reported in a considerable number of cases. These changes consist in degeneration of the axis cylinders and of their medullary sheaths. In a smaller number of instances changes have been reported in Gasserian ganglia removed from such cases. The changes in the ganglia consist in atrophy and disappearance of the nerve cells with increase in the connective-tissue elements. A peculiar shrunken condition of the cell in which the cell retracts to one side of its cell space is a fairly characteristic feature.

TUBERCULOUS LESIONS IN THE NERVOUS SYSTEM.

Tuberculous inflammation whether of the brain or cord is usually secondary to tuberculous inflammation in other organs, and is most frequent as an extension of tuberculosis of the meninges. In the brain substance

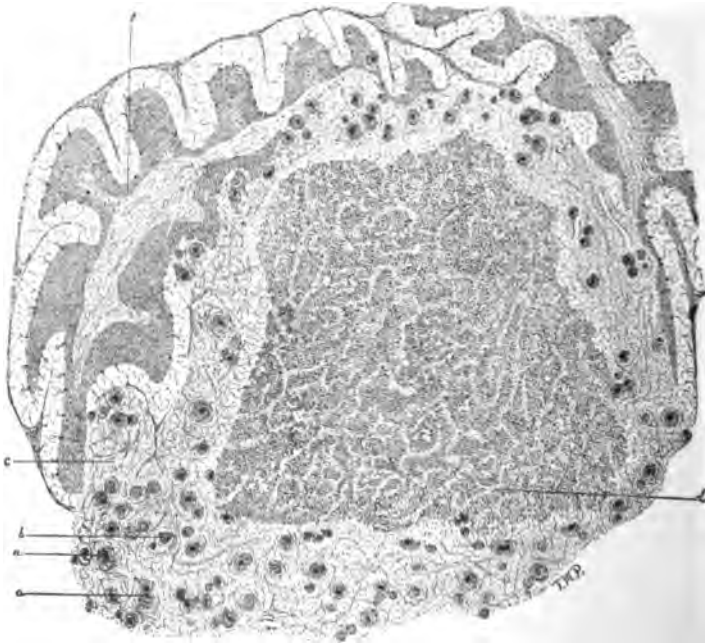

FIG. 676.—SOLITARY TUBERCLE OF CEREBELLUM.

a, a, Miliary tubercles with giant cells; *b, b*, miliary tubercles without giant cells; *c*, diffuse tubercle tissue; *d*, central cheesy mass; *e*, nerve tissue of the cerebellum.

it usually manifests itself in the formation of circumscribed masses of new tissue from 0.5 to 1 centimetre in diameter, or larger. These may be single or multiple, are most common in young persons, and very fre-

quently occur in the cerebellum (Fig. 676). They are apt to occur in connection with tuberculous inflammation of other organs. They are frequently solitary tubercles, each consisting of a dense central cheesy mass, around which is a grayish zone containing tubercle granula, numerous small spheroidal cells, with occasionally larger polyhedral cells and giant cells. They do not, as a rule, seem to be formed by an aggregation of miliary tubercles, although these may be present at the periphery. They sometimes suppurate and break down, and then they simulate simple abscesses. Tubercle bacilli have been found in these solitary tubercles.

Conglomerate and scattered miliary tubercles of the ordinary form sometimes occur in the brain, usually in connection with tuberculous inflammation of the meninges or ependyma.

In the spinal cord solitary nodules may determine extensive secondary degenerations. Multiple tuberculous foci may occur in the cord. They are rare and usually secondary to tuberculosis of the spinal meninges.

Tuberculous inflammation of nerves is rare except at their origins, where it is due to an extension from tuberculous meninges. When a nerve traverses tuberculous tissues, it may be involved in the inflammatory process.

SYPHILITIC LESIONS OF THE NERVOUS SYSTEM.

Syphilitic lesions of the nervous system may occur in either the inherited or the acquired form of the disease. In the former they usually show themselves early in life, though cases have been reported after puberty. Gasne in an examination of twenty-six fœtuses of syphilitic parents found well-marked syphilitic lesions in four. More commonly it is a tertiary manifestation of the acquired disease occurring from ten to twenty years after the initial lesion. Less commonly cerebral symptoms make their appearance within a few months after the chancre. The lesion sometimes appears in the brain as the so-called gummy tumors. These are most frequently found near the periphery of the brain, are usually connected with the meninges, and may be sharply circumscribed. The central portion of the tumor is apt to be in a condition of cheesy degeneration, while at the periphery is fibrous tissue or a dense infiltration of small spheroidal cells.

Syphilitic inflammation of the brain very frequently occurs in a diffuse form, characterized by the formation of a gelatinous, grayish tissue, consisting of a more or less homogeneous or granular basement substance, with numerous small round cells. The neighboring nerve elements are apt to be atrophied. A most common syphilitic lesion is a specific arteritis with or without the formation of small gummatous tumors in the walls of the vessels.

Syphilitic inflammation in the cord is usually secondary to a similar process in the spinal meninges. The size and shape of the gummata are modified by the restriction of the vertebral canal. The tumors are mainly significant from the more or less extensive secondary degenerations which they induce.

The relation of syphilis to multiple cerebral and spinal sclerosis is still uncertain. Its relation to tabes and to dementia paralytica has been noted under their respective titles. It is probable that most or all of those rare cases of tabes occurring in children are the results of inherited syphilis.

Syphilitic inflammation of the peripheral nerves is, like tuberculous inflammation of nerves, usually dependent upon an extension of the process either from the meninges or from some tissue through which the nerves pass.

ACTINOMYCOSIS.

Actinomyces of the brain has been described. It is a rare form of brain infection, and is usually secondary to actinomyces of the neck or face. The condition is apt to lead to suppuration and abscess formation. A case has been reported by Bollinger in which the disease was apparently primary in the brain.

LEPROUS INFLAMMATION.

This occurs in the peripheral nerves and consists in the formation within the nerves of masses of new-formed tissue somewhat resembling granulation tissue. In the cells of this tissue multitudes of characteristic bacilli are uniformly found (see Leprosy). It constitutes the variety of leprosy known as *lepra anæsthetica*.

TUMORS.

Tumors occurring in the nervous system may be of the types found in the other organs or of types peculiar to nervous tissue. They may be primary, or secondary to similar growths in other parts of the body.

TUMORS OF THE BRAIN.

Myxoma, fibroma, lipoma, and osteoma are rare forms of brain tumor.

Neuroglioma Ganglionare.—This is a form of tumor probably due to disturbances in the development of the brain. It is peculiar to nervous tissue and occurs in the form of circumscribed tumors or of diffuse enlargements of portions of the brain. The pia mater over these tumors is unchanged and the convolutions retain their shape. The tumors are formed of neuroglia, in which are contained little groups of ganglion cells (Ziegler).

Glioma.—This is the most common tumor of the brain, and like the preceding is found only in the nervous system. It occurs with especial frequency in children and young adults. Such tumors occur in all parts of the brain, but are found most frequently in the cerebrum. There may be a single tumor, or there may be several such tumors in different parts of the brain; some of them attain a large size. Bramwell

reports a case in which considerably more than one-half of a hemisphere was involved. These tumors may be sharply circumscribed, or merge imperceptibly into the brain substance; sometimes the tumor is arranged so as to form the wall of a cyst which contains clear serum. They may be white and hard; gray, soft, and gelatinous; infiltrated with small hæmorrhages or partly degenerated and softened. The centre of a glioma may break down and become soft and necrotic or even fluid. In this way a cyst is formed having a wall of gliomatous tissue. The brain tissue around these tumors may be inflamed or necrotic. These tumors arise from the neuroglia. The relative quantity of cells and fibrils varies in different tumors. They are composed of neuroglia cells and their delicate interlacing processes (for minute structure see "Glioma"). If the tissue is of a loose formation with wide meshes between the fibres it presents a myxomatous appearance, and has been described as *myxoglioma*. When the cellular elements are very numerous the tumor is often referred to as a *glio-sarcoma*. In some cases the vascularity is such a marked feature that the name of *telangiectatic glioma* is applied to it. (According to Ziegler, a simple preponderance of cells, so long as they are of the neuroglia type, does not warrant classing the tumor as a sarcoma, and he insists that the latter term should be reserved for those gliomata in which an active proliferation of the connective tissue of the walls of the blood-vessels occurs.) Osler reports three out of five cases of gliomata as made up of large cells in contradistinction to the small-cell variety.

Sarcoma occurs in any part of the brain. It may be single or multiple. The tumors are composed of round or fusiform cells with more or less basement substance.

Endothelioma is found in the substance of the brain. The tumors are of the types described as occurring in the pia mater.

Angioma.—Small collections of dilated vessels are found in the substance of the brain. They seem to be congenital like the nævi of the skin.

Carcinoma occurs in the brain. It is usually, if not always, secondary to carcinoma in some other organ.

TUMORS OF THE CORD.

In the pia mater of the cord are sometimes found small **fibromata**, **osteomata**, and **lipomata**. Multiple fibromata occasionally occur in the cord in connection with multiple fibromata of the peripheral nerves.

Endotheliomata of the types described as existing in the pia mater of the brain are much more rarely found in the pia mater of the cord.

A fatty **sarcoma**¹ of the pia mater, which infiltrated the cord, formed a tumor as large as a filbert, and had for twelve years caused gradually increasing paraplegia, has been described.

Two curious cases² of diffuse sarcoma and one of endothelioma of the

¹ Turner, Trans. London Path. Soc., vol. xxxix., p. 25, 1888.

² Coupland and Pasteur, Trans. London Path. Soc., vol. xxxviii., p. 26, 1887; Arch. für Psych., 1885.

pia mater of the whole length of the cord are recorded. They occurred in girls of four-and-a-half, sixteen, and twenty-two years of age. In each case the pia mater of the whole length of the cord was diffusely thickened and studded with nodules. In two of the cases the growth was composed of round cells, in the third case of large endothelial cells arranged in alveoli. In two of the cases the clinical symptoms lasted only for about three weeks, in the third case for five months. The acuteness of the symptoms was such as to indicate the existence of spinal meningitis.

In the spinal cord itself **gliomata**, **fibromata**, **sarcomata**, **glio-sarcomata**, and **angio-sarcomata** occur, but are rare.

When gliomata or glio-sarcomata do occur in the spinal cord, the new growth is apt to extend for some distance lengthwise in the cord and to

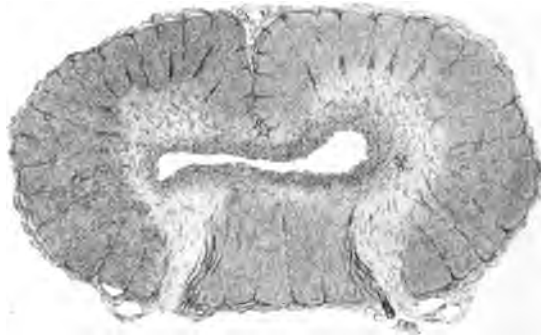

FIG. 677.—SYRINGOMYELIA.

An irregular cavity in the gray matter of the spinal cord, lined by a thick layer of gliomatous tissue.

be attended with the formation of a cavity; this condition is usually described under the name of *syringomyelia*.

Cysts may occur as a result of softening or from unknown causes. Sometimes very long, narrow canals are found in the spinal cord, even reaching nearly its whole length. Some of these are evidently the dilated central canal, as they are lined with epithelium. Others, however, doubtless originate in hæmorrhages (see *Hæmatomyelopathy*, p. 939).

Syringomyelia.—This lesion of the spinal cord consists in the formation of gliomatous or glio-sarcomatous tissue in the vicinity of the central canal, and its subsequent partial disintegration with the formation of one or more cavities within the substance of the cord (Fig. 677). These cavities, which are filled with fluid, vary greatly in size, shape, and extent, and, while usually situated in the central region of the cord, may involve the anterior and posterior cornua and invade the posterior columns. There may be two communicating cavities, and these may, but usually do not, open into the central canal. The longitudinal extent of these cavities varies greatly. The lower cervical and upper dorsal regions are most frequently involved. The cavity is usually lined with tissue somewhat denser than that which makes up the bulk of the tumor. The gliomatous

or glio-sarcomatous tissue which forms the basis of the lesion in syringomyelia probably originates from the layer of neuroglia which surrounds or extends away from the central canal.

Syringomyelia is frequently mistaken for hydromyelia, which is a congenital malformation, in which the longitudinal cavity in the cord is at some period lined with epithelial cells. Syringomyelia has also been confused with hæmatomyelopore.

There seems, furthermore, to be a class of lesions of the cord, usually classed as syringomyelia, in which cavities of various forms coexist with a tumor in the vicinity of the central canal. But these cavities do not appear to be formed by a breaking down of the tumor tissue, but in some other way as yet little understood.

TUMORS OF NERVES.

The tumors of the nerves may be divided into those consisting largely of or containing new-formed nerve tissue, **true neuromata**, and the so-called **false neuromata**, which are for the most part fibromata or myxomata originating in the connective tissue of the nerve (see Neuroma). **Myxo-sarcomata** are less common, and primary **sarcomata** rare. The nerves may be secondarily involved in sarcomata, or in **carcinomata** through which they pass, though not infrequently nerves pass through these tumors without being in the least involved in their peculiar structure. Paltauf has described as **endotheliomata** rare tumors of the glandula carotica.

PARASITES.

Cysticercus and more rarely **echinococcus** occur in the brain.

HOLES AND CYSTS IN THE BRAIN.

Larger or smaller holes may be found in the brain tissue from dilatation of the perivascular lymph-spaces, or well-formed cysts may exist as a result of hæmorrhage, inflammatory softening, hydatids, etc.

PORENCEPHALUS

is a term which has had a wide range of application to various defects of the brain substance. By some writers the term has been used to cover almost any congenital absence of brain tissue. By others, brain defects not congenital are included. Its most common application is to certain quite well defined congenital conditions in which there is an absence of a considerable portion of one or both hemispheres. These holes may lie deep in the substance of the brain. More commonly they come to the surface making conical depressions in the cortex, which the dura mater bridges over, but into which the pia extends. There may or may not be communication with the ventricles. This condition may coexist with various mental aberrations, hydrocephalus, etc. Similar defects may occur in the cerebellum.

Pineal Gland.

This little body, about the size of a cherry stone, is composed of connective tissue enclosing cavities which are filled with reticulated tissue and round cells. The cavities often contain brain sand.

A small number of **tumors** belonging to the class of teratoma have been described as originating in the pineal gland.

Weigert¹ describes a tumor, about 3.5 centimetres in diameter, composed of epidermis, hair follicles, hair, sebaceous glands, cartilage, fat, smooth muscle, and cylindrical epithelium.

Falkson² describes a chondro-cysto-sarcoma, 5.8 centimetres in diameter, which apparently originated in the pineal gland.

Turner³ describes a tumor of the pineal gland, projecting into the third ventricle and the left lateral ventricle, of the size of a kidney. The tumor was composed of fusiform cells, of nerve-ganglion cells, of tubules and acini lined with cylindrical epithelium, and of more irregular spaces filled with large polygonal cells.

Coats⁴ describes a tumor, three inches in diameter, growing into the third ventricle, the aqueduct of Sylvius, and the fourth ventricle. It was composed of fusiform cells, of tubules lined with cylindrical epithelium, of irregular masses of epithelium, of cartilage, and of smooth muscle.

Hypertrophy with cystic degeneration may occur.

Hæmorrhage into the substance of the gland has been described.

Hypophysis Cerebri. (The Pituitary Body.)

This organ consists of three lobes: an anterior, of epithelial cells and blood vessels; an intermediary, of epithelial cells and neuroglia; and a posterior, of neuroglia cells and fibers. The cells of the anterior lobe are basophile or chief cells, and eosinophile or chromophilic cells.

Tumors.—Weigert⁵ describes a tumor, as large as a hen's egg, which resembled in its structure the normal anterior lobe of the pituitary body, and which he regards as a hypertrophy of that body. Weigert also describes a gummy tumor of the pituitary body as large as a hazelnut. Weichselbaum describes an adenoma of the pituitary body as large as a pigeon's egg, closely resembling the structure of the normal anterior lobe of this body; a small lipoma; and a pituitary body with colloid cysts, lined with ciliated epithelium.⁶

Methods of Preparation of Nerve Tissue for Microscopical Study.

The general methods of hardening will be found in Part III. For minute study there is no one method of staining and mounting upon which we can rely exclusively for the study of all lesions. A preliminary examination of areas of *inflammatory*

¹ Weigert, Virch. Arch., Bd., lxx., p. 212, 1875.

² Falkson, *ibid.*, Bd. lxxv., p. 550, 1879.

³ Turner, Trans. London Path. Soc., vol. xxxvi., p. 27, 1885.

⁴ Coats, Trans. London Path. Soc., vol. xxxviii., p. 44, 1887.

⁵ Weigert, Virch. Arch., Bd. lxx., p. 219, 1875.

⁶ For an extended study of tumors of the hypophysis see monograph of Erdheim, Sitzungsber. d. kais. Akad. d. Wiss. in Wien, Math.-naturw. Kl., Bd. cxiii. Abth., 3, 1904.

softening, or of the disintegrated tissue in *apoplectic clots*, or of the new-formed tissue in *chronic hæmorrhagic pachymeningitis interna*, may be made by teasing portions of the affected tissues in 0.5-per-cent. salt solution. Or the tissues in these lesions, or in any others in which fatty degeneration is suspected, may be placed for twenty-four hours in 1-per-cent. aqueous solution of osmic acid, and then washed and teased in glycerin. In this way the myelin and the fat will be stained brown or black. Secondary and other degenerations of medullated nerves may be studied by soaking the nerves for twenty-four hours in 1-per-cent. solution of osmic acid, and then staining with picrocarmine and teasing and mounting in glycerin.

To demonstrate the presence of miliary aneurisms in or about apoplectic clots, it is usually necessary to macerate the brain tissue in water until the nerve elements disintegrate, and they may then be washed away under a stream of water, leaving the blood-vessels with their aneurisms exposed.

Marchi's Method.—For studying early stages of degeneration in medullated nerve fibres this method is invaluable. It depends upon the fact that while myelin and fat both stain black when the fresh nerve fibres are placed directly into osmic acid, a preliminary soaking in a solution of potassium bichromate so affects the tissue that the myelin sheaths of normal fibres no longer impregnate with osmium, the fat droplets alone staining.

Tissues are first hardened from one to three weeks in Müller's fluid, or simply in a 2- or 3-per-cent. aqueous solution of potassium bichromate. They are then transferred to a mixture of 1-per-cent. aqueous solution of osmic acid one part, Müller's fluid two parts, where they remain from three days to a week.

By following the lines of fat droplets, degenerative changes in nerve fibres may be traced either in the peripheral nerves or in the central nervous system.

Eosin-Hæmatoxylin Staining.—Suppurative inflammation of the central nervous system and its membranes, or the connective-tissue changes in general, may be studied in sections from the tissues hardened in Müller's fluid and alcohol, stained double with hæmatoxylin and eosin (see p. 1035), and mounted in Canada balsam.

Weigert's Method.—A very useful method of staining sections of nerve tissue, especially of the brain and cord, is that known as *Weigert's hæmatoxylin method*. The tissue is first well hardened in Müller's fluid.

Blocks of the hardened tissue are embedded in celloidin and sections made in the usual way. The sections are first soaked for twenty-four hours in a saturated aqueous solution of neutral cupric acetate diluted with an equal bulk of water, or, if the material has been kept some time and takes the hæmatoxylin stain with difficulty, a better result is often obtained by soaking the sections for from twelve to twenty-four hours in a 3- to 5-per-cent. aqueous solution of bichromate of copper before staining. They are now thoroughly washed twice in water, then in alcohol, and then are transferred to the hæmatoxylin solution, made as follows:

Hæmatoxylin crystals	1 gm.
Alcohol, 97 per cent.	10 c.c.
Water	90 c.c.
Saturated aqueous solution lithium carbonate	1 c.c.

In this solution the sections remain for two hours. (If the finer fibres of the cerebral cortex are to be brought out, the sections must remain for twenty-four hours in the hæmatoxylin solution.) The sections are now thoroughly washed in two or three waters and transferred to the bleaching solution, composed as follows:

Potassium ferricyanide	2.5 gm.
Sodium bichromate	2 gm.
Water	200 c.c.

In this fluid the sections discharge a brownish color, and they remain in it until the gray matter has a distinct yellow color and the white matter is bluish black. The time required to produce this effect varies considerably, and is usually from half an hour to an hour. The sections are now washed, dehydrated with alcohol, cleared up in oil of cloves or oil of organum, and mounted in balsam. The sections may be

stained in alum carmine before dehydration, to bring out the nuclei. In sections stained by this method the gray matter, connective-tissue elements, and ganglion cells have a yellow or yellowish brown color, the axis cylinders are uncolored or have a slight yellowish tint, while the medullary sheaths are bluish black or black.

Nissl's Staining Method.—There are several variations of this method, but the following gives good results in most cases:

The essential feature of the so-called Nissl's method is the application of the anilin dyes to the staining of certain structural elements in the nucleus and cytoplasm, which are distinguished from the other structures of the cell by a differentiating decolorization with alcohol.

Methylene blue is the most generally useful of the anilin dyes for this purpose.

The specimens should have been carefully hardened in sublimate solution or in alcohol or in formalin.

Very thin sections are stained in 1-per-cent. solution of methylene blue. The staining may be effected on a slide on which the sections are floating in the blue solution by gently heating over a lamp until the fluid steams.

The sections are now transferred to a mixture of absolute alcohol 90 parts, with anilin oil 10 parts, in which the differentiation is effected by the use of successive fresh portions of fluid until slight but distinct differentiation in color is seen between the gray and white matter of the nerve tissue. The exact degree of decolorization which gives the best pictures will be learned by practice of the method. In most cases the use of alcohol alone without anilin oil is preferable to the mixture, and in any case the sections should always be washed in strong, pure alcohol before passing on to the xylol. The sections are now freed from the bulk of the alcohol upon the slide, cleared in xylol, and mounted in dammar varnish, in which the color is apt to be preserved better than in balsam. By this procedure the chromophilic bodies in the cytoplasm of ganglion cells are sharply differentiated, and thus abnormal conditions may be detected in them (see Plate XIII.).


A contrast stain with erythrosin (Held¹) is useful in demonstrating cell structures which are not visible with the simple Nissl staining. This may be secured as follows:

The sections are first warmed from one to two minutes in the following solution: erythrosin, gm. 1; acetone, gtt. ij.; aqua dest., 150 c.c. They are then washed thoroughly in water and transferred to a solution consisting of equal parts of Nissl's methylene-blue solution and a 5-per-cent. aqueous solution of acetone. In this they are warmed until the odor of acetone ceases to be given off. The sections are decolorized in a 0.1-per-cent. solution of alum until they appear red in color, and are then dehydrated in alcohol and cleared and mounted in the usual way.

¹ *Held, Arch. f. Anat. und Phys., Anat. Abt., 1895, p. 396, 1897, p. 204.*

PART III.

THE METHOD OF MAKING POST-MORTEM EXAMINATIONS:
AND THE METHODS OF PRESERVING AND
EXAMINING PATHOLOGICAL TISSUES.



CHAPTER I.

THE METHOD OF MAKING POST-MORTEM EXAMINATIONS.

General Considerations.

THE object in making a post-mortem examination may be to determine whether a person has died from violence or poisoning; to account for a sudden death; or to study the lesions of disease. In any case the examination should include all the important parts of the body, not merely a suspected organ, and the results should be recorded at the time the examination is made.

Great care is necessary in endeavoring to ascertain the cause of death when the clinical history is imperfect or unknown. Mechanical injuries which destroy life by abolishing the function of one of the important viscera, are relatively infrequent. Most of the lesions found after death are rather the marks of disease than the cause of death. We do not know, for example, how great a degree of meningitis, or of pneumonia, or of endocarditis, or of cirrhosis, or of nephritis necessarily leads to death. On the contrary, one patient may recover with an extent of lesion which is sufficient to destroy the life of another. So with accidents; there is often no evident reason why fractures of the skull or of the pelvis should destroy life, yet they usually do. In some of the infectious diseases, such as typhoid fever, the visible lesions cannot always be called the cause of death. Sudden deaths of persons apparently in good health are often particularly obscure. In many of them we have to acknowledge that we can find no sufficient cause for the death. This is of course due to our imperfect knowledge, but it is much better in such cases to avow ignorance than to attribute the death to some trifling lesion. The brain and the heart are the organs which are especially capable of giving symptoms during life, without corresponding lesions after death. Very well-marked cardiac or cerebral symptoms may continue for days or months, and apparently destroy life, and yet after death we find no corresponding anatomical changes.¹ But it should be remembered that recent advances in our knowledge of the cell, which an improved technique in hardening and preparation has greatly fostered, have already shown that under various abnormal conditions the cells, especially of the nervous system, may undergo morphological changes of great significance, without perceptible alteration in the gross appearance of the affected part, changes which even the microscopical examinations of the past have failed to disclose. So that while there often appears to be a wide discrepancy between symptoms and lesions, with the increase

¹ See Sudden Death, p. 446.

of knowledge the scope of this discrepancy is steadily narrowing. It is the novice in post-mortem examinations who is particularly apt to mistake for lesions ordinary post-mortem alterations or the effects of embalming processes.

The cause of death is not always to be found in the organ primarily affected or which shows the most pronounced lesions. Thus chronic diffuse nephritis may exist for years with more or less marked symptoms of disease. But death may finally be due to a weakened heart which was secondarily involved, or occur in uræmic convulsions, the brain showing no lesions at all. It is desirable, therefore, and in the majority of cases possible, to differentiate between obvious lesions and the cause of death.

External Inspection.

Before commencing the examination of the internal viscera an inspection should be made of the external surface of the body. The minuteness of this inspection will depend upon the character of the case. In the case of an unknown person, or of one suspected to have died from unnatural causes, it is necessary to search for and record not only all contusions, wounds, etc., their size, situation, and condition, but also deformities from disease and any physical peculiarities of hair, eyes, teeth, moles, etc., by which the person may be identified. In such cases it is well, if possible, to photograph, weigh, and measure the body. In cases of doubtful identity it is sometimes wise to make a wax or plaster cast of the outside of the teeth and jaws. In ordinary examinations we note the general nutritive condition of the body, and look for evidences of external injury, for skin diseases, ulcers, œdema, gouty deposits, abscesses, enlarged lymph-nodes, etc. The external organs of generation should be searched for syphilitic lesions.

It is well to weigh the body, since the significance of the weight of the individual organs is often closely dependent upon the relationship of their weight to that of the entire body.

Cadaveric Lividity.—It is usual to find certain changes in the external appearances of the body, which are due to the cessation of life and the commencement of decomposition. We speak now of bodies which have not been buried, but which have been kept in the ordinary way, lying on the back, and loosely covered with a shroud or dressed with the ordinary clothing.

After life becomes extinct, and before the blood coagulates, it changes its position chiefly in two ways: first, it is driven by their contraction out of the arteries into the veins; second, it settles in the veins and capillaries of the more dependent parts of the body, inducing usually within a few hours after death a mottling of the surface with irregular livid patches. These patches may coalesce, forming a uniform dusky red color over the back of the trunk, head, and extremities, and sometimes over the ears, face, and neck. The same effect is observed on the anterior aspect of the body if it has lain on the face. At points of pressure, from folds in the clothing, or from the weight of the body on the table, the red color is absent or less marked. These changes occur

before putrefaction sets in. This cadaveric lividity or hypostasis should not be mistaken for ante-mortem ecchymosis, from which it may usually be readily distinguished by its position and extent, by the fact that the surface of the skin is not elevated, and by the fact that on incision no blood is found free in the interstices of the tissues. Not infrequently the subcutaneous tissue in the vicinity of these post-mortem hypostases becomes infiltrated with reddish serum. Very soon after death, particularly in warm weather, the tissues immediately around the subcutaneous veins of the neck and thorax, and in other situations, may become stained of a bluish red color from the decomposition and escape from the vessel of the coloring matter of the blood. If the epidermis has been detached at any point, the skin beneath soon becomes dry and brown.

Putrefactive Changes.—Usually in from one to three days, depending upon circumstances, a greenish discoloration of the skin appears, at first upon the middle of the abdomen, over which it gradually spreads, assuming a deeper hue and often changing to a greenish purple or brown. Greenish patches may now appear on different parts of the body, earliest upon those overlying the internal cavities; this discoloration is probably produced by the action on the hæmoglobin of gases developed by decomposition. The eyeballs now become flaccid, and if the eyelids are not closed the conjunctiva and cornea become brown and dry. The pressure of gases developed by decomposition in the internal cavities not infrequently forces a greater or less quantity of frothy, reddish fluid or mucus from the mouth and nostrils, distends the abdomen, and, if excessive, may lead to changes of position of the blood in the vessels, and even a moderate amount of displacement of the internal organs.¹

After a varying period, sometimes within five or six days, the entire surface of the body may be discolored, green or brown. Then the epidermis may become loosened by the accumulation of gases and fluids beneath and the tissues become flaccid. The abdomen may be greatly distended and the features distorted from swelling. The rapidity with which these changes occur depends upon various conditions. Thus an elevated temperature and the presence of air and moisture hasten the advent and progress of putrefaction.

The bodies of infants usually decompose more rapidly than those of adults, fat bodies more quickly than lean ones. The infectious diseases, intemperance, and the puerperal condition promote rapid decomposition, as does also death from suffocating gases. Poisoning by arsenic, alcohol, antimony, sulphuric acid, strychnin, and chloroform may retard the progress of decomposition. Burial in dry soil and submersion in water also retard the progress of decay.²

¹ In cases with the early and marked formation of gas in the tissues and organs, especially in the liver, the possibility of infection with *Bacillus aerogenes capsulatus* should be borne in mind. See p. 289.

² For a study of bacteria in the blood of the cadaver see *Ottolenghi*, Vierteljahresschrift. f. gerichtl. Medicin, Bd. iv., Suppl.; see also *Babes*, "Les maladies infectieuses en médecine légale," Annales d'Hygiène Publique, t. xli., p. 193, 1899.

Concerning the conversion of the body into adipocere see *Ewing, Peterson and Haines*' "Text-book of Legal Medicine," vol. i., p. 138; see also *Ascarelli*, Vierteljahresschrift f. gerichtl. Med. xxxii., p. 219, 1906.

Cooling of the Body.—After death the chemical changes upon which the maintenance of the temperature depends rapidly diminish, and the body gradually cools to the temperature of the surrounding medium. This usually occurs in from about fifteen to twenty hours, but the time required depends upon a variety of conditions. Immediately after death there is, in nearly all cases, a slight elevation of internal temperature, owing to the fact that the metabolic changes in the tissues still continue for a time, while the blood ceases to be cooled by passing through the lungs and peripheral capillaries. After death from certain diseases—yellow fever, cholera, rheumatic fever, and tetanus—a considerable elevation of internal temperature has been repeatedly observed. The time occupied by the cooling of the body may be prolonged after sudden death from accidents, acute diseases, apoplexy, and asphyxia. A number of cases are recorded in which the body retained its heat for several days, without known cause.

After death from wasting chronic disease, and in some cases after severe hæmorrhages, the cooling of the body is very rapid, the internal temperature being reduced to that of the surrounding air within four or five hours. Fat bodies cool less quickly than lean ones, the bodies of well-nourished adults less quickly than those of children or old persons. The temperature of the surrounding medium, and the degree of protection of the body from currents of air, of course, modify the progress of cooling; and the internal organs naturally retain their heat longer than the surface of the body. The rate at which cooling occurs is most rapid, as a rule, during the hours immediately following death, notwithstanding the post-mortem rise which may ensue.

It will thus be seen that, if required to pronounce upon the time which has elapsed since death in a given case, we can do so only approximately. It is necessary to take into account all of the above-mentioned conditions which modify the rate of cooling of the body, and then we may be able to state only the probabilities of the case. It is furthermore unsafe in any case to infer the cause of death from the rate of cooling of the body.

Rigor Mortis.—Death is usually succeeded immediately by a period of complete muscular relaxation. The jaws drop and the limbs become flaccid. The muscles may retain for two or three hours, however, the capacity of contracting, on the application of appropriate stimuli. On the average, within six hours the muscles become firm and rigid. This post-mortem rigidity is called *rigor mortis*. On the occurrence of the rigor mortis the muscles become fixed in whatever position they may have had at the time of its occurrence. It usually begins in the muscles of the eyelids, extends to those of the back of the neck and lower jaw, then to the face and neck, and thence passing downward affects the muscles of the thorax and lower extremities. It usually disappears in the same order. Although commencing on the average six hours after death, it may set in at once or be delayed for twenty-four hours or more. It may pass off very rapidly, in rare cases in from one to three hours; or it may persist for two or three weeks or longer. It may be said in gen-

eral that the average time of its disappearance is within twenty-four or forty-eight hours after its occurrence, depending on temperature, its intensity, the mode of death, the period of its advent, etc. Caspar states that in foetuses before term he has never observed rigidity, and that in young children it is feeble and of short duration. Its occurrence and phenomena may be in some cases of the highest medico-legal importance; but its careful observation does not, with our present knowledge of its significance, appear essentially to further the aims of the practical pathologist.¹

Contusions.—It is often important to determine whether violence has been inflicted upon a body before death. In regard to this point, we must remember, first, that blows and falls of sufficient violence to fracture bones and rupture the viscera may leave no marks on the skin, even though the person has survived for several days; and, second, that there are post-mortem appearances which simulate ante-mortem bruises. A severe contusion during life may present, at first, no mark or only a general redness. After a short time the injured part becomes swollen and of a red color; this color may be succeeded by a dark blue, and this in turn fade into a greenish yellow or yellow; these later appearances are due to an escape of blood from the vessels and to a subsequent decomposition of hæmoglobin. If therefore we cut into such an ecchymosis after death, we find extravasated blood or the coloring matter of the blood, in the form of pigment granules, free in the tissues. Post-mortem discolorations, on the other hand, although their external appearance may resemble that of ante-mortem ecchymosis, are not formed by an extravasation of blood, but by a circumscribed congestion of the vessels or by an escape of blood-stained serum. If we cut into such discolorations, therefore, we find no blood outside the vessels. Care should be taken not to mistake the lesions of hæmorrhagic infection for traumatic ecchymoses.

Blows on the skin of a body which has been dead for not more than about two hours may produce true ecchymoses with extravasation of blood, such as can be distinguished with great difficulty or not at all from those formed during life. If putrefactive changes be present, the difficulty of distinguishing between ante-mortem and post-mortem bruises is greatly enhanced.

Hanging and strangulation are attended with the formation of marks on the neck which are described in works on forensic medicine. These marks must not be confounded with the natural creases of the skin of the neck. Many adults during life have creases of the skin of the neck, one or more in number, running downward from the ear under the chin or encircling the neck. After death these creases may be much more evident than during life, and may be rendered more decided by the position of the head and the freezing of the body. They usually persist until the skin putrefies.

¹ For further details concerning rigor mortis, putrefactive changes, particularly the later stages, and the phenomena of cooling of the body, see *Tidy*, "Legal Medicine," vol. i., or other works on medical jurisprudence.

Wounds.—We should notice the situation, extent, and direction of a wound, the condition of its edges and the surrounding tissues. If it be a deep, penetrating wound, its course and extent should be ascertained by careful dissection rather than by the use of a probe.

If the edges of a wound be inflamed and suppurating, or commencing to cicatrize, it must have been inflicted some time before death. In a wound inflicted a short time before death, the edges are usually everted; there may be more or less extravasation of blood into the surrounding tissues, and the vessels contain coagula; but sometimes none of these changes are observed. The chief characteristics of a wound inflicted after death are absence of a considerable amount of bleeding, non-retraction of the edges, and the absence of extravasation of blood into the tissues. But a wound inflicted within two hours after death may resemble very closely one received during life. In general, unless a wound is old enough for its edges to present inflammatory changes, we must be very careful in asserting its ante-mortem or post-mortem character.

Fractures.—It may be important to determine whether a bone was fractured before or after death. This point cannot always be decided. Fractures inflicted during life are, as a rule, attended with more extravasation of blood and evidences of reaction in the surrounding tissues; but fractures produced within a few hours after death may resemble these very closely. Usually a greater degree of force is necessary to fracture bones in the dead than in the living body.

Scars and Tattoo Marks.—The presence and character of cicatrices should be noticed. Scars produced by any considerable loss of substance may become very much smaller and less conspicuous, but never entirely disappear. Slight and superficial wounds, however, leave marks which may not be permanent. The discoloration produced by tattooing may, although it rarely does, disappear during life.

Internal Examination.¹

After completing the external inspection of the body, we commence the internal examination. In order that this examination may be made both thoroughly and rapidly, we should follow a regular method. The method should be such as will enable us to examine the relations of parts to one another, without seriously disturbing them, and to remove and inspect the organs in such an order and manner as will not interfere with the examination of parts which are to follow. In certain cases it may be necessary to depart from the regular method;² but, as a rule, the following plan will be found most advantageous.

It is important to remember the difference between the distribution of the blood in the body during life and after death. During life the

¹ For sizes and weights of various organs, and other data, see *Vierordt's "Anatom. Physiol. und Physikalische Daten u. Tabellen,"* 3d ed., 1906. For a study of the weights of the viscera in infancy and childhood see *Bovaird and Nicoll, Arch. of Pediatrics,* vol. xxiii., p. 641, 1906.

² Sometimes the thoracic or abdominal viscera or both together may wisely be taken out in mass. See for advantages of this method *Heller, Vierteljahrssch. f. gerichtl. Med.,* Bd. xxvii., p. 110.

blood is in constant motion and is distributed in a regular way in the heart, capillaries, arteries, and veins. Inflammations and obstructions to the circulation may disturb this natural distribution and produce congestion of particular parts of the body. After death the blood ceases to circulate; it leaves the left cavities of the heart, the arteries and capillaries, and collects in the veins and the right cavities of the heart. According to the character of the disease which causes death, coagulation of the blood takes place more or less extensively and at an earlier or later period. The local congestions which existed during life often disappear after death. On the other hand, local congestions are found after death which did not exist during life. Thus, after death the scalp often contains a large amount of venous blood. The veins of the pia mater and the sinuses of the dura mater may be filled with blood. The mucous membrane of the larynx and trachea may appear to be deeply congested. The lungs are congested if the patient has been comatose for some hours before death. All the tissues of the back and the membranes of the spinal cord are often gorged with venous blood. The right auricle and ventricle of the heart may contain fluid or clotted blood in considerable quantity.

THE HEAD.

The scalp is divided by an incision across the vertex, from ear to ear. The flaps are dissected forward and backward, taking up the temporal muscles with the skin and leaving the pericranium attached to the bone. The internal surface of the scalp and the pericranium are to be searched for ecchymoses and inflammatory lesions.

A circular incision is now made through the cranium with a saw. The incision should, in front, pass through a point about three and one-half inches above the bridge of the nose; behind, through the occipital protuberance. Care should be taken not to cut through the dura mater with the saw. When the roof of the cranium is thus entirely loosened, a stout hook is introduced under the upper edge of the calvarium, and this is wrenched off with a jerk.

Sometimes the dura mater is so firmly adherent to the calvarium that the latter cannot be torn from it without injury to the brain. In this case, and also if the dura mater should have been accidentally cut through by the saw in making the circular incision, the dura mater may be cut through at the level of the cranial incision, and the brain removed with the calvarium and separated afterward. Or, which is better, in addition to the circular incision, a longitudinal incision is made, from front to back, about three-quarters of an inch to one side of the median line of the skull, and a segment of bone removed. The knife blade may now be inserted from the open side, and the dura cut away from the skull-cap along the line of the longitudinal sinus, where the adhesions are apt to be most firm.

We should notice whether or not the calvarium is symmetrical. The cranial bones increase in size by a growth of bone at the edges of the

sutures. If any suture becomes completely ossified and closed prematurely, the bones will be unequally developed. The thickness and density of the cranial bones vary considerably within the limits of health. There are often deep depressions on the inner surface of the skull along the sagittal suture, caused by the pressure of the Pacchionian bodies, and of no pathological significance. We should observe the blood content of the bone, determine the existence or absence of fractures, inflammatory lesions, exostoses, etc.

The dura mater is now exposed. It is more or less adherent to the calvarium; a moderate amount of adherence, especially in old persons, does not denote disease. Very extensive and firm adhesions are usually produced by inflammation. Near the median line the Pacchionian bodies often project through the dura mater and may produce indentations in the internal surface of the calvarium. We must look for clots and for tumors and for inflammatory lesions on the external surface of the dura mater. The longitudinal sinus should be laid open and its contents examined. A circular incision is then made through the dura mater in a line corresponding to the cranial incision; the falx is divided between the anterior lobes of the brain, and the entire membrane drawn back. We should observe the existence of abnormal adhesions of the dura mater to the pia mater, bearing in mind that a moderate amount of adhesion along the longitudinal fissure is normal. The internal surface of the dura mater is to be examined for the products of inflammation and for tumors.

The pia mater covering the convex surface of the brain is now exposed. The degree of congestion, and the existence of serum, pus, or blood, beneath, within, or upon it, are now to be ascertained before the brain is removed. The pia mater in old persons frequently loses its transparency and becomes thick and white; this change is most marked along the longitudinal fissure and large vessels. Marked and general thickening of the pia mater is the result of chronic inflammation. Along the longitudinal fissure, and sometimes at a considerable distance from it, we usually find small, elevated, whitish nodules, which are the *Pacchionian bodies* and are normal in the adult.

The amount of serum beneath the pia mater varies. A considerable amount, especially in cachectic persons, may exist without brain disease. Clear serum, raising the pia mater and separating the convolutions of the brain, may be simply dropsical or due to chronic meningitis. Turbid and purulent serum, beneath and in the pia mater, is due to acute or chronic meningitis. The degree of flatness of the surface of the convolutions should be observed before removing the brain; for, when marked, it affords an important indication of pressure, from hæmorrhage, inflammatory products, internal fluid effusions, and tumors. The pia mater should be carefully examined for miliary tubercles.

The Brain.—After examining the convex surface of the brain, the anterior lobes of the cerebrum are to be pulled gently backward, the nerves, vessels, and tentorium severed, and the medulla cut squarely across, as low down as possible. The brain is now removed from the

cranium by passing the fingers of one hand down, beneath, and behind the lobes of the cerebellum, and drawing the brain out, supporting the convexity with the other hand.

The adult brain in the male weighs on the average about 1,400 grams; that of the female, about 155 grams less. The average proportional weight of the brain to that of the body is about one-forty-fifth, although in this, as in the absolute weight, there is considerable variation.¹

The exact situation of any lesion which is apparent externally should be described by its relation to the lobes, fissures, convolutions, and sulci (Fig. 678).

The brain is first laid upon its convex surface, and the anterior, middle, and posterior cerebral arteries, as well as the basilar and the carotids,

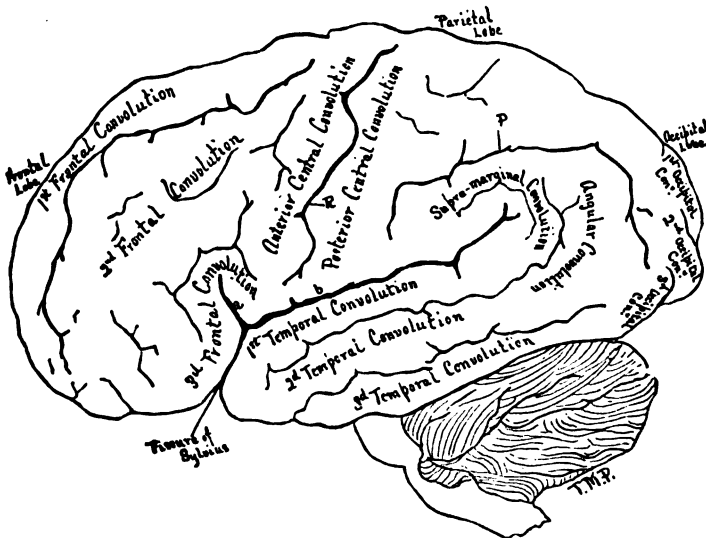


FIG. 678.—SIDE VIEW OF THE HUMAN BRAIN, SHOWING ITS FISSURES AND CONVOLUTIONS.

are to be examined for emboli, thrombi, atheroma, and aneurisms. Evidences of extravasations of blood, tumors, and inflammatory lesions are now to be looked for. The brain is next turned over on to its base. An incision is made through the pia mater, over the convex surface of the cerebrum. The membrane is stripped up, and its adherence to the brain and its thickness are noted.

The more common method of opening the brain is as follows: The halves of the cerebrum are to be separated until the superior surface of the corpus callosum is exposed (Fig. 679). A longitudinal incision is made through the junction of the corpus callosum and the cerebrum, and downward into the ventricle. The incision should be made carefully, so as not to cut through the ventricle into the ganglia below. The incision

¹ For a study of the weight of the brain at various ages see *Handmann*, Arch. f. Anat. u. Phys., Anat. Abth., Jahrg. 1906, p. 1.

thus made through the roof of the ventricle is prolonged backward and forward in the direction of the cornua, so as to expose the entire ventricle. A longitudinal incision is then made outward and backward into the hemisphere, from the outer edge of the lateral ventricle nearly to the pia mater. A second incision is then made through this cut surface outward, and this is repeated until the hemisphere is divided into a number of long, prism-shaped pieces, held together by the pia mater

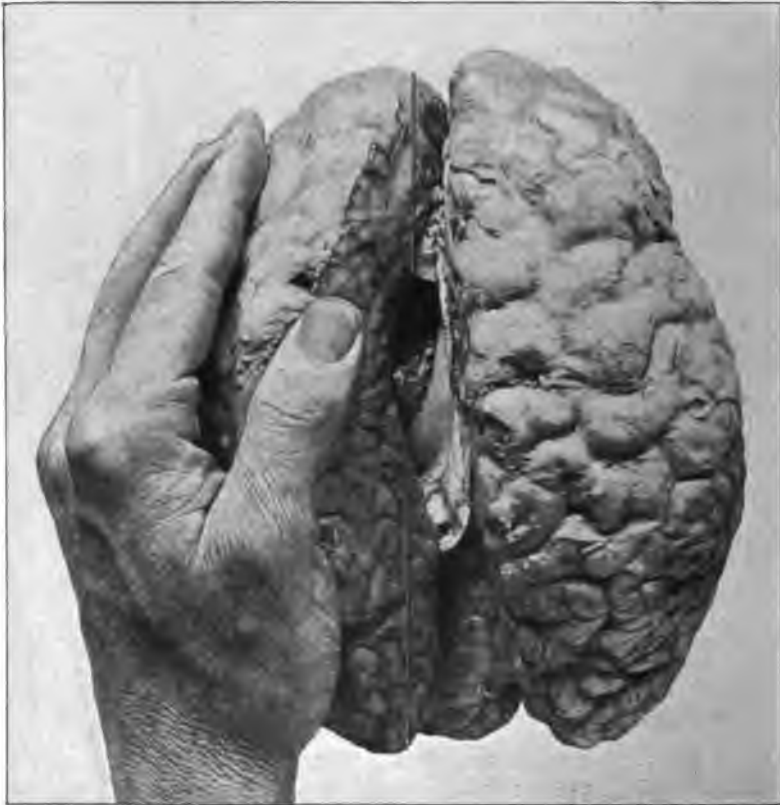


FIG. 679.—METHOD OF OPENING THE BRAIN, SHOWING THE DIRECTION OF FIRST INCISION.

and a small portion of the cortex. The brain is now turned around so as to bring the other hemisphere under the hand, and the operation is repeated on the other side.

The size, shape, and contents of the ventricles should be noticed, and the thickness and appearance of the ependyma.

The fornix and the central portion of the corpus callosum are cut across by passing the point of the knife through the foramen of Munro and cutting upward. They are then drawn backward, one of the posterior cornua of the fornix being severed and laid to one side. The

velum interpositum and the choroid plexus are now dissected up, the blood contents and the general appearance noted, and the third ventricle examined. Not infrequently small cysts of the choroid are found, which seem to have little or no pathological significance.

The fourth ventricle is now opened by a longitudinal incision through the vermiform process. Each hemisphere of the cerebellum is divided first into two parts, by an incision through the upper and inner convex border, and then each segment is further divided by incisions in the same direction.

Thin transverse sections are now made through the cerebral ganglia, commencing in front (Fig. 680). The ganglia are supported, and the sec-

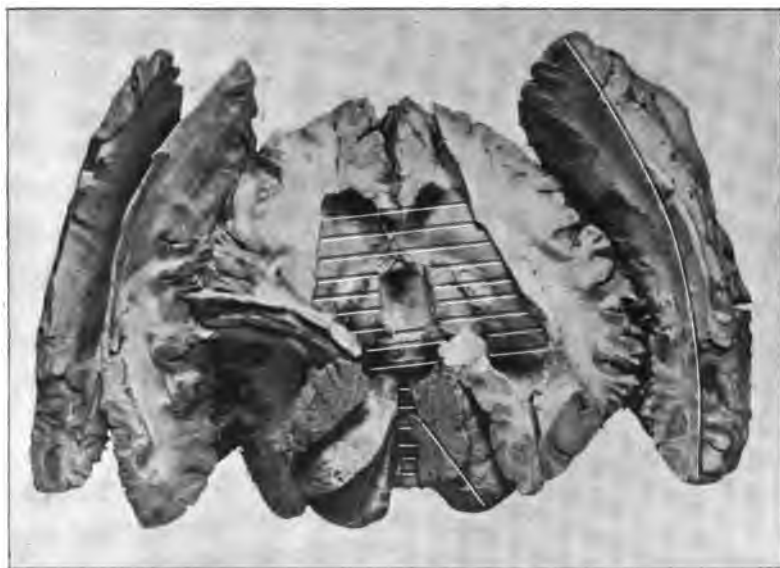

FIG. 680.—METHOD OF OPENING THE BRAIN, SHOWING THE UNFOLDED SEGMENTS OF THE CEREBRUM AND LINES OF TRANSVERSE INCISION OF THE BASAL GANGLIA AND DIRECTIONS OF THE INCISIONS OF THE CEREBELLUM.

tions caused to fall apart as they are cut, by carrying the fingers of one hand under the brain, and gently lifting the ganglia at points just beneath where the sections are made. It is important to observe the exact position of any lesion which may be discovered in the cerebral ganglia, their relations to the external and internal capsule and to the caudate and lenticular nuclei.

Finally, the segments of the cerebrum and cerebellum are folded up together into their original positions, the whole is turned over on to the vertex, and thin sections are made through the medulla. Small clots in the medulla should not be overlooked.

In case of the discovery of apoplectic clots, areas of softening, etc., either in the hemispheres or in the basal ganglia, after their location and

extent are determined, they should be carefully searched for lesions of the blood-vessels, minute aneurisms, areas of degeneration, and ruptures. For this purpose it may be necessary to allow a stream of water to run over the affected portion, so as to wash out the brain substance

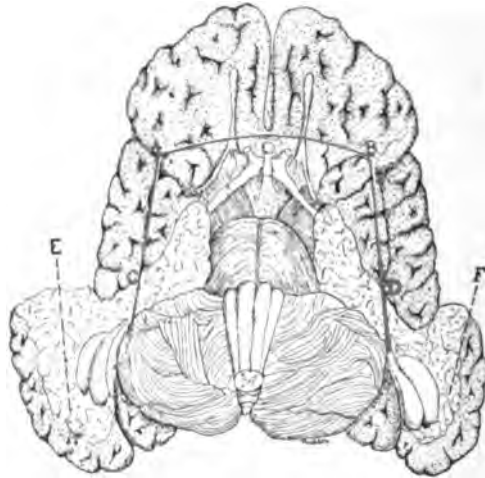


FIG. 681.—SCHEMATIC PICTURE OF BRAIN, SHOWING THE METHOD OF DISSECTION FROM THE BASE (Meynert's method).

E and *F*, Temporal lobes turned backward and outward; *AB*, *AC*, *BD*, line of incision to remove basal piece.

and expose the vessels. In some cases the blood-vessels are best exposed by macerating the brain tissue at the seat of the lesion for some hours in water, and then washing out the brain substance under the faucet.

While the above mode of dissecting the brain gives a very complete view of the seat and extent of lesions in general, when a more exact localization of lesions with a microscopic examination is to be made, the following—called Meynert's method—is a better method of opening the brain:

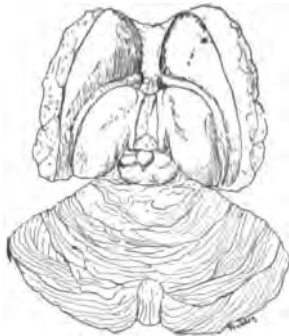

FIG. 682.—THE BRAIN AXIS SEPARATED FROM THE BRAIN MANTLE, AS SEEN FROM ABOVE.

After completing the external examination, as detailed above, the brain is laid on its vertex, the cerebellar end toward the operator. The cerebellum is raised by the fingers of the left hand, and the pia cut through along the sides of the corpora quadrigemina, around the crura and along the inner margins of the temporal lobes, to the middle cerebral artery on both sides (Fig. 681). Then, raising the

temporal lobes, in turn, by their apices, the pia is cut through along the course of the middle cerebral artery into the Sylvian fissure, and along the course of its posterior branch to its end. Now, drawing the temporal lobes one after the other upward and outward, their junction with the

base is cut, the knife being held horizontally so as not to injure the basal ganglia until the descending horn is opened. The point of the knife being in the descending horn, the incision through the brain substance then passes outward and backward well into the posterior horn, thus partially severing the lateral surface of the brain, the junction of the occipital and temporal lobes. The temporal lobes are then turned outward and backward (Fig. 681).

The operculum is now pulled well outward, completely exposing the island of Reil, and a slightly curved transverse incision is made, deep enough to pass into the anterior horns of the ventricles, connecting the anterior sulci of the island of Reil (Fig. 681, *A*, *B*).

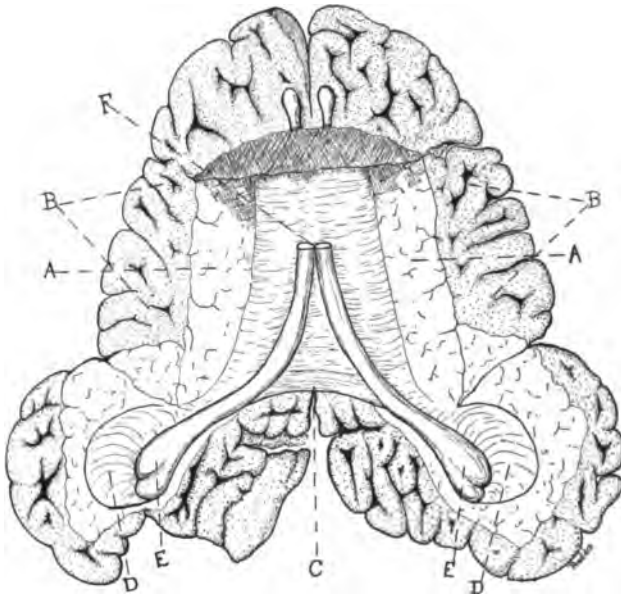


FIG. 683.—THE BRAIN MANTLE, AS SEEN FROM BELOW.

A, Internal capsule; *B*, operculum; *C*, posterior border of corpus callosum; *D*, descending horn; *E*, cornu ammonis.

Now raising the cerebellum and inserting the point of the knife into the ventricle, with short incisions from within outward, cut through the internal capsule on either side from back to front (Fig. 681, *CA* and *DB*), care being taken not to injure the basal ganglia. Then cut across the crura of the fornix and the septum lucidum, leaving the fornix lying on the corpus callosum.

The square basal piece (Fig. 682) thus freed—the *brain axis*—includes the island of Reil, the basal ganglia, the crura, pons, medulla, and cerebellum. The remaining portion—the *brain mantle*—includes the convolutions, corpus callosum, and fornix (Fig. 683).

The basal piece may be further examined by a series of transverse incisions, from one-half to three-quarters of an inch apart, and it may be

hardened either with or without the cerebellum. The convolutions may be cut into small pieces by longitudinal and transverse incisions, made from within and not reaching quite to the pia mater, which will then serve to hold the pieces together in their proper relations to one another.¹

The Base of the Cranium.—We now return to the skull. The remaining sinuses of the dura mater should be opened, and this membrane then entirely stripped from the bone. The bones at the base of the skull are to be examined for fractures, inflammatory lesions, and tumors. In cases of acute purulent meningitis, the temporal and frontal bones should be carefully examined, as the inflammatory process is sometimes transmitted from the internal ear, or mastoid cells, or frontal sinuses.

The eyes may be removed by breaking the roof of the orbit with a hammer, removing the fragments of bone, and dissecting away bone and muscles, so as to expose the optic nerve and posterior segment of the eye. That portion of the globe which is not covered by conjunctiva can now be cut away with scissors and removed with the optic nerve, or, when permissible, the whole eye may be cut out.

The examination of the internal ear may be made by removing its entire bony encasement with the saw and chisel, or by the exposure of special parts by hammer and chisel, and by suitable opening of the removed parts with a fine saw.

HARDENING AND PRESERVATION OF THE TISSUES FOR MICROSCOPICAL EXAMINATION.

For the study of *tumors* and *inflammatory lesions* of the bones of the skull and ossifications of the dura mater and pia mater, the affected portions should be cut into small pieces, fixed in 5-per-cent. formalin or in Orth's fluid (see p. 1029), and decalcified. The dura mater should be stretched on a flat piece of wood or cork with pins, before hardening.²

The *pia mater* is so delicate that if it be separated from the brain when quite fresh its tissues are apt to be injured. The portions of the pia mater which are to be preserved should therefore be removed by cutting off slices of the brain substance about half an inch thick, with the membrane still attached, and placing the whole in Orth's fluid. After twenty-four hours, the pia mater will have become sufficiently hard to permit of its being stripped off without injury, and it is then spread loosely on a flat cork with pins, the free surface outward, and the cork floated, specimen side down, in 80-per-cent. alcohol, changing to strong alcohol after twenty-four hours.

When sections are required showing the pia in its relationship to the underlying brain tissue, small blocks of the brain and pia together should be cut out and hardened in Orth's fluid or in formalin (10 : 100) solution (see p. 1029).

When the *ependyma* is to be studied apart from the associated nerve tissue, it may be sliced off with a sufficient quantity of underlying brain substance to prevent its folding, and hardened in Orth's fluid. The *brain*, for general purposes, may be hardened in Orth's fluid, or in 5-per-cent. formalin. The pieces of brain tissue should not be more than 1 centimetre thick; it is better if they are thinner than this. They should be suspended in gauze or rest upon a layer of absorbent cotton on the bottom of the jar, the pieces, if these are numerous, being held apart by a little cotton. Thus the preservative fluid, which should be abundant, is in contact with the surfaces of the pieces of tissue. Ordinarily, with a change of fluid on the second day, the fixation by formalin or Orth's fluid is complete in a week, when the fixatives are thoroughly

¹ For further details of this method of opening the brain, and a consideration of its advantages, see Van Gieson, "Laboratory Notes," etc., New York Medical Journal, July 20th, 1889.

² For details of the methods of hardening, decalcifying, staining, etc., see p. 1029.

washed out and replaced by 50-per-cent. alcohol, which, in turn, is replaced after forty-eight hours by 80-per-cent. or by 95-per-cent. alcohol.

When *degeneration* in nerves is to be studied, the specimens of nerve tissue may, by Marchi's method, be hardened for a week in Müller's fluid, and then transferred to the following solution:

Müller's fluid	2 parts.
Osmic acid, 1 per cent.....	1 part.

After a week the specimens are washed and transferred to 95-per-cent. alcohol. In such specimens the fat droplets in the degenerate areas are black, while the myelin is yellowish in color.

Certain lesions, particularly the softenings of the brain, are best studied by teasing, when fresh, in 0.5 per-cent. solution of sodium chlorid, or in frozen sections of the fresh tissue. The blood-vessels may be stretched on cork with pins and hardened with Orth's fluid or formalin. The eye and portion of the optic nerve, if removed, should be fixed by Orth's fluid and the hardening completed by alcohol.

For many methods of fixation and study which are useful for special purposes, we refer to special works on technique.

THE SPINAL CORD.

The examination of the spinal cord is usually most conveniently made after the removal of the brain.

The body should be placed face downward, with a block under the thorax and the head hanging over the edge of the table. An incision is made through the skin and muscles along the entire length of the spine, and the soft parts are dissected away on each side so as to expose the laminae of the vertebral column. The laminae are then divided, close within the articular processes, with the saw.

The saw should be so directed in severing the laminae that the incision shall touch the outer border of the spinal canal, as otherwise the laminae and spinous processes are not easily separated. Great care should be taken on the one hand not to injure the cord with the saw, and on the other completely to loosen the portions of bone to be removed. These, which are the spinous processes and laminae, are now torn away together, with a stout hook, exposing the cord.

By means of a long, curved chisel, made for this purpose, the bodies of the vertebræ may be removed from the front after the thoracic and abdominal viscera are taken out, and the cord thus exposed and removed. But in this anterior method of removing the cord, as well as by the use of chisel and mallet, bone-shears, etc., in the ordinary method, there is great liability of injuring the delicate tissues of the cord and producing, as Van Gieson has shown,¹ mechanical alterations which are likely to be mistaken for malformations or the results of disease.

When the body has lain on the back, the membranes of the cord may be found considerably congested, without indicating the pre-existence of disease. If the body has lain for some time, especially in warm weather, serous fluid may have accumulated within the membranes, as a result of post-mortem change.

¹ *Van Gieson, "A Study of the Artefacts of the Nervous System," New York Medical Journal, vol. lvi., pp. 337, 365, 421, 1892.*

The roots of the nerves are now to be cut across, as far away as possible from the cord, and the cord removed in its membranes, care being taken not to press it in any way. It is the safest plan not to grasp the cord itself, but with a forceps to seize the dura mater and thus lift it up at once as it is freed from its attachments. It is now laid on the table,

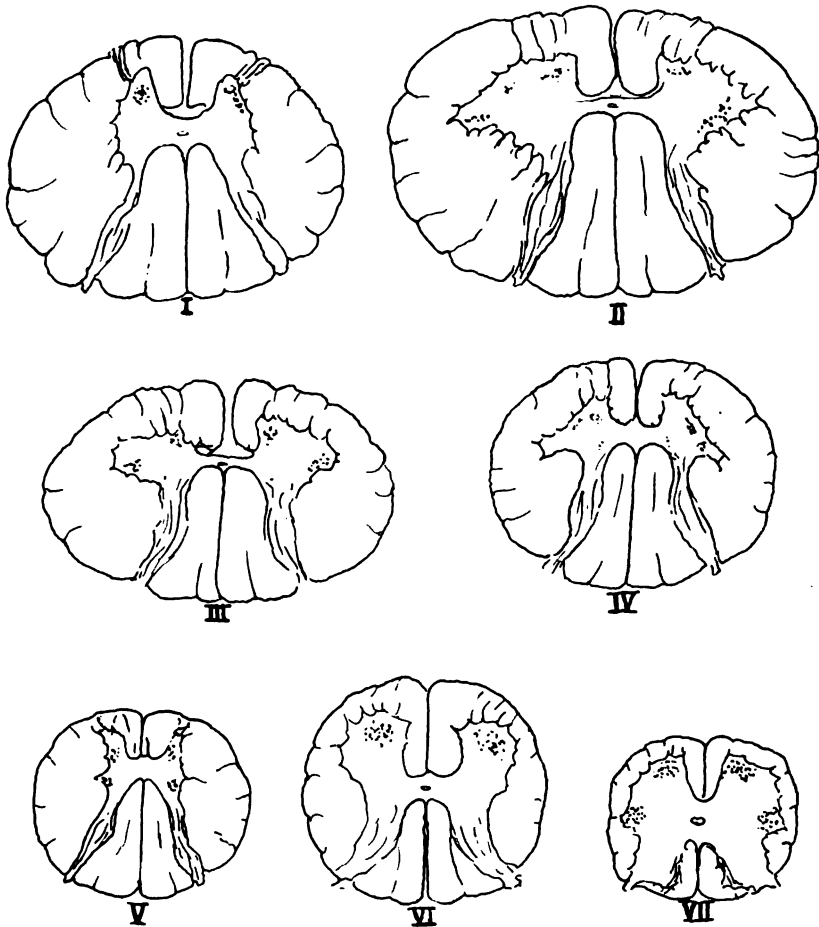


FIG. 684.—OUTLINES OF SECTIONS OF THE SPINAL CORD AT DIFFERENT LEVELS.

Copies of these outlines may be used for memoranda of the situation of lesions of the spinal cord. *I*, Second cervical; *II*, fifth cervical; *III*, eighth cervical; *IV*, first dorsal; *V*, eighth dorsal; *VI*, third lumbar; *VII*, fourth sacral.

and the dura mater laid open with scissors on the anterior and posterior surfaces over its entire length, and searched for tumors, inflammatory lesions, etc. The finger should be passed gently along the cord as it lies on the table, so as to detect any marked softening or sclerosis. The weight of the spinal cord is from 30 to 38 grams. It should now be held lightly over the fingers, and smooth transverse incisions made, with a

very sharp knife or razor, about half an inch apart through its entire substance between the segments, leaving these attached to the pia mater.

The segments of the spinal cord are those parts from which the spinal nerves arise, and it is convenient for the location and description of lesions to number the segments in correspondence with the nerves which arise from them, and to indicate on outline diagrams of the cord (Fig. 684) the exact seat of small lesions.

The cut surfaces should be carefully examined for abnormal blood contents, hæmorrhages, inflammatory lesions, softening, scleroses, and pigmentations. Important lesions of the cord may be invisible to the naked eye, and hence, if disease be suspected, the organs should be preserved for microscopical examination. The spinal ganglia may now be removed and preserved for further examination. After removal of the cord, fractures and displacements of the vertebræ are easily recognized.

PRESERVATION OF THE SPINAL CORD AND ITS MEMBRANES, AND OF PERIPHERAL NERVES.—After the removal of the spinal dura, the entire cord with its nerve roots—the segments into which it has been cut for gross examination being left in place—should be laid on a wad of absorbent cotton in a large jar of Orth's fluid or formalin, the segments being slightly separated from each other by a little absorbent cotton. Van Gieson recommends the careful rolling of the segmented cord into a loose spiral and laying this coil on a wad of absorbent cotton in the fixative. In this way the cut ends of the segments are held apart, accessible to the fluid, and harden with little distortion.

The hardening and preservation of the cord may be done by the same methods as suggested above for the brain. If the dura mater of the cord alone is to be preserved, it should be treated in the manner suggested for the dura mater cerebri. The pia mater spinalis is best studied in sections through the entire cord, the membranes being left *in situ*.

Peripheral nerves may be hardened in Orth's fluid or in formalin.

For the hardening of the peripheral nerves, osmic acid is very useful, especially when changes in the myelin are to be sought after. As osmic acid does not readily penetrate the lamellar sheath so as to come in contact with the nerve fibres, in trunks of any considerable size, the following procedure, as suggested by Van Gieson, will be found useful: A piece about one-half inch long is cut from the nerve to be examined; one end of this segment is held with a forceps, while with another forceps the individual nerve fibres, or small clusters of these, are pulled out of the lamellar sheath and put at once in a 1-per-cent. aqueous solution of osmic acid, in which they remain twenty-four hours, and are then washed and transferred to glycerin, to which 25-per-cent. alcohol is added. In this mixture they may be preserved. Marchi's method is useful for the study of degeneration in peripheral nerves.

THE THORAX AND ABDOMEN.

The body is replaced on its back, and a single straight incision is made from the top of the sternum to the pubes, passing to the left of the umbilicus. For this purpose a large knife should be used, held firmly in the whole hand, and the movement should be mainly from the shoulder. The first incision should divide everything down to the sternum and peritoneum. A short incision should then be made through the peritoneum, just below the ensiform cartilage. Into this opening two fingers of the left hand are introduced and separated from one another, and, the parietes being raised and the sides of the opening being held

apart by the fingers, the peritoneum is divided to the pubes, care being taken to hold the knife horizontally so as not to cut the intestines. The skin and muscles are then dissected off from the thorax on both sides as far back as the false ribs.

This dissection should be made by long sweeps of the knife, which should be made to cut with the full blade and not with the point only; and if the skin and muscles be pulled strongly away from the chest with the left hand, it may be done very rapidly and with a few strokes of the knife. We notice here the amount of subcutaneous fat and the condition of the muscles. In order better to expose the abdominal cavity, the rectus should be divided transversely beneath the skin just above the pubes, and the abdominal flaps may then be turned freely outward.

General Inspection of the Abdominal Cavity.—We first notice the position and general condition of the viscera. It is best at this stage of the examination to note the condition of the vermiform appendix, and to look over the peritoneal cavity for serum, inflammatory lesions, evidences of perforation, and for the existence of invagination, incarceration, and herniæ of the intestines. A small quantity of reddish serum is frequently found in the abdominal cavity, particularly in warm weather, as the result of commencing decomposition.

It should be remarked here that various striking changes in the character and appearance of the internal organs are produced by putrefaction—changes which are often mistakenly regarded as evidences of disease, and much experience is required, in judging correctly of their significance. These changes are, in general, softening and discoloration, both of which may occur as the result of disease. It may be said in general that the post-mortem reddening, or hypostases, are most marked in the more dependent parts of the organs. Post-mortem softening usually affects entire organs, not being limited to a part, as is often the case in disease. Gray or grayish-brown post-mortem discolorations are apt to appear in those organs or parts of organs which lie in contact with the intestinal canal. Parts of internal organs, such as the liver, which have been the seat of localized congestion during life, may after death assume a dark greenish color.

The *omentum* is usually spread over the surface of the small intestines, but it may be rolled up and displaced in a variety of ways, or may be adherent at some point to the small intestines or to the abdominal wall.

The surface of the *small intestines* should be smooth and shining. They may be greatly distended with gas, and thus so completely cover the other abdominal viscera that it becomes necessary to let out some of the gas by a small puncture. The transverse colon passes across the abdomen through the upper part of the umbilical region. It may be lower than the umbilicus, or higher up against the liver and diaphragm; it may be distended with gas or contracted.

The *liver* is situated in the right hypochondriac and epigastric regions, filling the concavity of the diaphragm. Its upper border reaches, in the *linea mammillaris*, to the fifth intercostal space; in the *linea axil-*

laris, to the seventh intercostal space; close to the vertebral column, to the tenth intercostal space. At the median line the upper border of the liver corresponds to the lower border of the heart. The left lobe extends about three inches to the left of the median line. The lower border of the right lobe usually reaches to the free border of the ribs, while the left lobe is visible for about an inch below the ensiform cartilage. In women the liver is usually lower than in men.

The position of the liver is affected by changes in the thoracic cavity, forcing it downward; by changes in the abdominal cavity, forcing it upward; by constriction of the waist in tight lacing, forcing it either upward or downward; by changes in the size of the organ itself. The liver may not only be displaced downward, but dislocated so that its convex surface faces the abdominal wall and its posterior edge is turned upward against the diaphragm.

The *stomach* is situated in the left hypochondriac and epigastric regions, extending also into the right hypochondrium; it lies in part against the anterior wall of the abdomen, in part beneath the liver and diaphragm, and above the transverse colon. Its anterior surface, which is directed upward and forward, is in contact above with the diaphragm and the under surface of the liver, and lower down with the abdominal wall opposite to the epigastric region. Its posterior surface is turned downward and backward, and rests on the transverse mesocolon, the pancreas, and the great vessels. To its lesser curvature or upper border are attached the gastro-phrenic ligament and the gastro-hepatic omentum. To the greater curvature or lower border is attached the gastro-colic omentum. Its cardiac orifice communicates with the œsophagus, its pyloric end with the duodenum.

When the stomach is distended the greater curvature is elevated and carried forward, the anterior surface is turned upward and the posterior surface downward. When distended with food or gas the organ is prominent; when empty it may hardly be visible below the ribs; when the intestines are dilated it may be entirely covered by them.

Before opening the thorax the hand should be passed up against the under surface of the diaphragm on either side, to determine its height. According to Quain, the vault of the diaphragm rises, in the dead body, on the right side to the level of the junction of the fifth rib and sternum, on the left side as high as the sixth rib. Both the relative and the absolute height of the diaphragm vary under a variety of pathological conditions.

If the existence of air or gas in the pleural cavities be suspected, the abdominal cavity should be filled with water and the diaphragm punctured below the level of the fluid. If air be present, it will escape in bubbles through the water.

THE THORAX.

We now leave the abdominal viscera and proceed to the examination of the thorax. With a costotome or a strong knife the costal cartilages

are divided close to the ribs, the clavicles are disarticulated from the sternum, and the latter is removed, care being taken not to wound the large veins. We first examine the position of the heart and lungs.

The Heart.—The upper border of the heart is on a level with the third costal cartilage; the lower border extends from 1.3 centimetres below the lower end of the sternum to the fifth left intercostal space. The left boundary of the heart is situated to the left of the junction of the fifth rib with its costal cartilage, and behind or to the left of a vertical line drawn downward from the left nipple. The right boundary extends 2.5 centimetres to the right of the right edge of the sternum. The portion of the heart uncovered by the lungs is of an irregular quadrangular shape. Its lateral diameter is from 8.3 centimetres to 11.1 centimetres; its upper boundary varies from the level of the second costal cartilage to that of the fifth, but it is usually behind the third or fourth cartilage or fourth space.

The area of the heart which is found uncovered will, however, vary much, according to the degree to which the lungs collapse after opening the chest. Any disease which diminishes the size of the lungs, or pleuritic adhesions which retract or bind them down, may increase the area of exposed heart. On the other hand, emphysema, pneumonia, or any disease which increases the size of, or retains the air in, the lungs, may diminish the area of exposed heart. The exposed area varies also with the size of the heart itself.

The *pericardium* is now opened by a slightly oblique incision on its anterior surface. The existence of serous, fibrinous, or purulent exudate, and of adhesions, is to be noted. A small quantity of clear serum exists normally in the pericardial sac, and this serum may be blood-stained from beginning decomposition. White thickenings of the pericardium on the surfaces of the heart are often seen; they do not indicate important disease.

Now that the pericardial sac is open, the position of the heart can be clearly seen. It lies obliquely in the chest, its long axis at an angle of about sixty degrees with that of the thorax. The portion of the heart which is first seen is the anterior surface of the right ventricle; upward and to the right of this is the right auricle, which lies about two-thirds on the right of the sternum and about one-third behind it. Its upper border usually corresponds to the plane of the middle of the anterior end of the second intercostal space on the right side. Its size varies with the amount of blood which it contains. The left auricle lies behind the root of the pulmonary artery, so that only its appendix is visible. The middle of the auricle corresponds to the third costal cartilage. Of the left ventricle only a narrow rim is seen, on the left side of the right ventricle. The pulmonary valve is usually entirely or in part on the left side of the sternum, behind the second space or third costal cartilage.

The aortic valve is usually at the level of the third cartilage or the third space, and behind the left two-thirds or half of the sternum. The mitral valve is oblique, the upper end of the left. It is on the level of

the third to the fourth cartilage, near the middle of the sternum. The tricuspid is oblique, its upper end to the left; the upper end is at the level of the third cartilage, the third space, or the fourth cartilage. The valve is opposite the middle of the sternum.

The hand should now be passed over the arch of the aorta, to ascertain whether or not an aneurism is present. The heart is then grasped at the apex, raised out of the pericardium, tilted upward, and removed unopened by cutting through the great vessels at its base. It is advisable in many cases to remove with the heart the arch of the aorta and as much as is practicable of the associated great vessels. In some instances, for example when thrombosis of the pulmonary artery is suspected, it is well to remove the heart and lungs together.¹

One may gain some knowledge of the sufficiency of the aortic and pulmonary valves if the heart is held horizontally by both auricles, so as not to pull the valves open, and water is poured into the aortic and pulmonary arteries. One observes how well the valves support the column of liquid. To ascertain the sufficiency of the mitral and tricuspid valves, the auricles are first laid open so as to expose the upper surfaces of the valves. A large pipe is passed through the aorta or pulmonary artery beyond their valves, and a small stream of water allowed to flow into the ventricles. The auriculo-ventricular valves will be swollen upward, and one may observe their degree of sufficiency. The tricuspid valve is normally somewhat insufficient. These water tests, however carefully applied, are not very reliable, since under the most favorable conditions the natural bearings of the valves are not perfectly preserved.

To ascertain the size of the different valvular openings, we introduce the fingers, held flat with their sides in contact, into each of the orifices, and then measure the width of the fingers at the point where they fill the orifice. In this way we find that, under normal conditions in the adult, the aortic measures about 2.5 centimetres, the mitral valve about 4.5 centimetres, the pulmonary about 3.1 centimetres, the tricuspid about 5 centimetres.

In order to examine *the interior of the heart*, one first makes an incision through the anterior wall of the *left ventricle* close by and parallel to the septum, and reaching to the apex of the ventricle (Fig. 685). Through this opening the blade of the enterotome is passed up into the aorta, the pulmonary artery being drawn aside with the fingers, and the ventricle and aorta are laid open (Fig. 685). With a little care the incision may be made to pass through one of the points of junction of the aortic valves.

The auricles and ventricles may be empty, or may contain fluid blood or the so-called *heart clots*. These heart clots are of two kinds—those which are formed some time before death, and those which are formed during the last hours of life and after death. The clots which are formed some time before death are usually associated with organic disease of the heart, especially with dilatation of the ventricles. They are firm, dry,

¹ The opening of the heart *in situ* is recommended by many, but we are of the opinion that if care be exercised in the removal of the organ from the body and a sufficient portion of the great vessels at the base be included there is little risk of premature disturbance of thrombi, etc., on the valves, while the examination of the interior may be much more thoroughly, conveniently, and safely done.

and of whitish color; they may be infiltrated with the salts of lime. They are free in the cavities of the heart, or entangled in the trabeculæ, or firmly adherent to the endocardium. They are usually composed of coagulated fibrin, blood platelets, leucocytes, and red blood cells, and are often lamellated. The clots which are formed during the last hours of

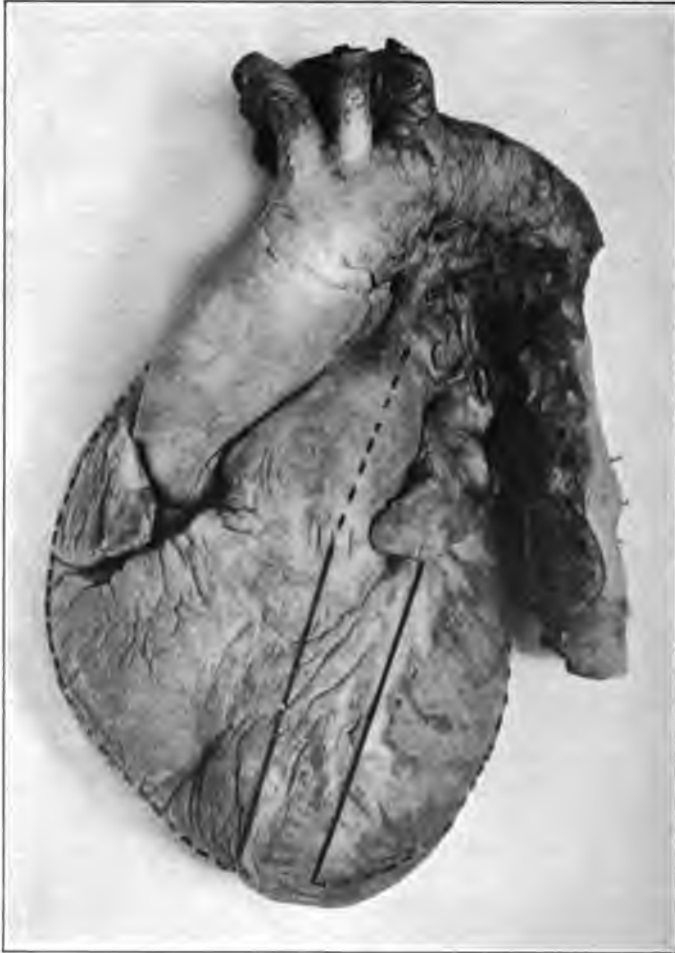

FIG. 685.—HEART SHOWING LINES FOR INCISION IN OPENING.

life and after death are red, yellow, or white. They may be soft or succulent or quite firm. They may be free in the heart cavities, or be adherent to the trabeculæ, or extend into the large vessels. They are usually most constant and of largest size in the right auricle and ventricle. Such clots may be formed within two hours after death. Clots of this character are common. If, then, the blood coagulates in the heart

within twenty-four hours before death, this coagulum may not be distinguishable from the ordinary post-mortem clots. If it is supposed, therefore, that a person dies from heart clot developed a few hours before death, the proof of this must be derived largely from the clinical symptoms, and not from the autopsy.

The condition of the aortic valves and of the endocardium, and the thickness and appearance of the walls of the left ventricle, papillary muscles, chordæ tendineæ, etc., are now noticed.

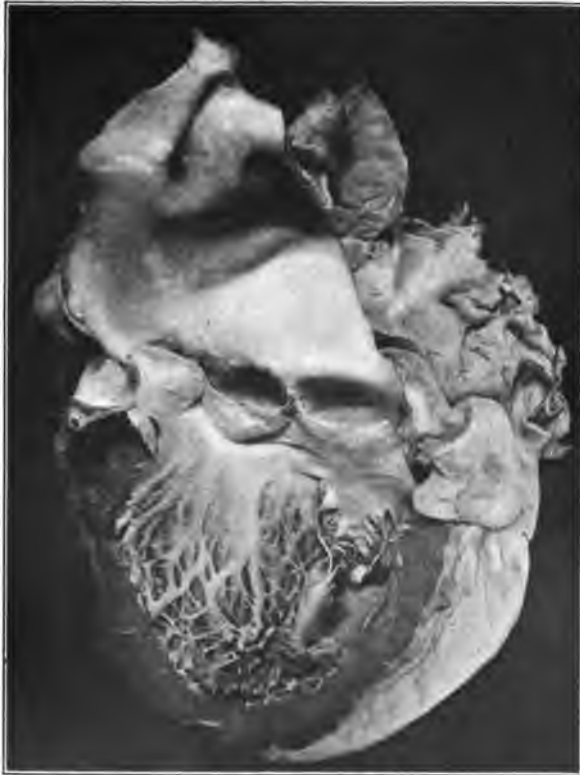

FIG. 686.—HEART OPENED, EXPOSING THE AORTIC VALVES.

The *right ventricle* is now opened by an incision through its anterior wall, close to the septum (Fig. 685), and examined in the same way. The endocardium of the upper part of the left ventricle is sometimes thick and white, without the existence of valvular lesions or clinical history of disease. The endocardium and valves are often stained red, particularly in warm weather, by imbibition of coloring matter of the blood, set free by decomposition. This discoloration is especially marked in cases of infection with *Bacillus aerogenes capsulatus*.

To complete the examination of the cavities the enterotome is passed

into each auricle, carried down into the corresponding ventricle, and an incision made along the outer border of both auricle and ventricle to the apex of the latter. In this way the auriculo-ventricular valves are completely exposed (Fig. 687). The coronary arteries should be opened through all their main trunks, with fine probe-pointed scissors, and carefully examined for marks of inflammation, emboli, thrombi, etc.

In cases of Stokes-Adams' disease look for lesions involving the auriculo-ventricular bundle of His.¹

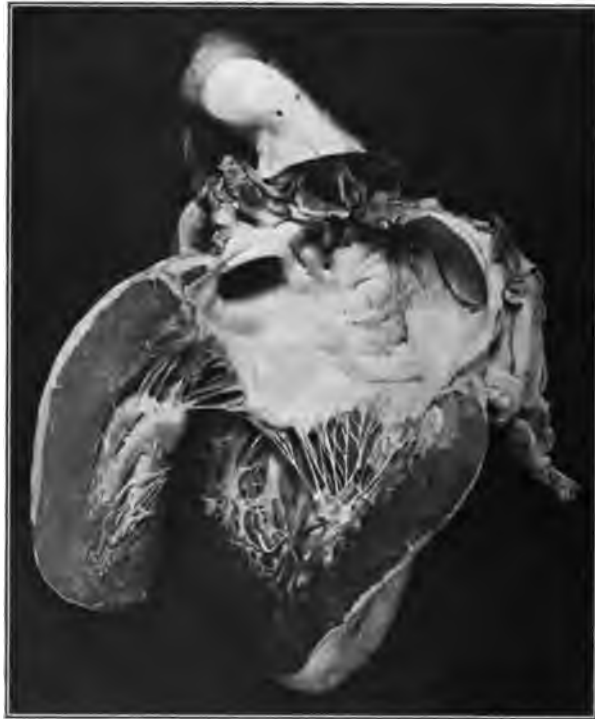

FIG. 687.—HEART OPENED, EXPOSING THE MITRAL VALVE.

After removing the blood, the heart should be finally weighed. The normal average weight of the heart in adults is, according to an estimate of H. D. Arnold,² in males about 290 grams; in females about 260 grams.

The weight of the heart relative to that of the body is in males about 1 : 158 to 178; in females, about 1 : 149 to 176. According to Buhl, the average thickness of the wall of the left ventricle at about the middle of the cavity is from 1.6 centimetres to 1.7 centimetres; of the right ventricle, from 0.4 to 0.6 centimetre.

The size of the heart, speaking generally, corresponds to the size and

¹ See *Erlanger*, *Jour. Exp. Med.*, vol. viii., p. 8, 1906.

² *Arnold*, "Observations on the Weight of the Normal Heart in Adults, in Two Hundred and Sixteen Cases." *Reports of the Boston City Hospital*, tenth series, 1899, p. 83.

the development of the individual. In judging of an increase or decrease in its size we must consider the weight of the organ and the thickness of its walls. If the person die while the heart is contracted, the walls of the ventricles will appear thicker, their cavities smaller than usual.¹ If he die of some exhausting disease like typhoid fever, or if decomposition have commenced, the heart walls will usually be flabby and the cavities will appear larger than usual.

PRESERVATION OF SPECIMENS.—Parenchymatous and fatty degeneration of the heart may be studied microscopically by teasing the fresh muscle in 0.85-per-cent. salt solution, or by examining in the same solution fresh sections made with the freezing microtome, or by hardening small pieces of the muscle in 1-per-cent osmic acid and teasing in equal parts of glycerin and water.

The heart valves may be stretched on a flat cork with pins and hardened in Orth's or Zenker's fluid or alcohol. For the methods of detecting bacteria in ulcerative endocarditis see section on Staining Bacteria. When the presence of bacteria is suspected cultures should be made and the tissues should be preserved in strong alcohol.

The pleural cavities are next examined. The hand is passed into each, and the existence of serous or fibrinous exudation or of old adhesions ascertained. The method of detecting the presence of air has been given above. After the commencement of putrefaction reddish serum may accumulate in the pleural cavities. This should not be mistaken for the result of disease.

The Lungs.—Each lung is lifted up in turn, the vessels, etc., at its base are divided, and the organ is removed. If the pleura is very adherent it is better to strip off the costal pleura with the lung. After inspecting the external surface of the lung, observing its size, shape, color, and consistency, and the condition of the bronchial lymph-nodes, the bronchi are opened with scissors having long, narrow, blunt-pointed blades, one blade a little longer than the other. The lung is held in the left hand with its base upward, the large bronchi which run on the inner side of the lower lobe being first opened, afterward those of the upper lobe. Each bronchus should be followed to its smaller ramifications.

We should observe the contents of the bronchi and the appearance of their walls. In the larger and medium-size bronchi the cartilages in their walls do not form complete rings, but appear shining through the mucous membrane like irregular white patches. This appearance should not be mistaken for a pathological change. In bodies which have been dead for some time, especially in cold weather, the bronchial mucous membrane may be red and swollen as a post-mortem change. The contents of the stomach are sometimes forced, after death, into the pharynx, and thence find their way into the trachea and bronchi, giving them a peculiar reddish and even gangrenous appearance. Bronchitis does not always leave lesions which can be seen after death. The large vessels should now be examined for thrombi, emboli, or other lesions.

After the examination of the bronchi the lung is turned over, the vessels, etc., at its root, are grasped with the left hand, and a long, deep in-

¹ For method of determining hypertrophy of the heart see ref. to Müller, p. 554.

cision is made from apex to base. We observe the appearance and texture of the lungs, whether the air vesicles are dilated (emphysematous) or filled with serum, blood, or inflammatory exudation. Fluid can be pressed out of the air vesicles without breaking down the lung tissue. Solid inflammatory exudation, on the other hand, renders the lung more resistant and easily broken down. Attention should be paid to the oozing of purulent or other fluid from the smaller bronchi when the lung is squeezed near the cut surface. It is the rule to find the lower lobes more congested than the upper.

PRESERVATION OF THE LUNGS AND BRONCHI.—If the lungs have been cut, small pieces from the affected portions of lung tissue or bronchi should be hardened in Orth's fluid, care being taken not to squeeze or handle them unnecessarily. It is better, when the microscopical examination is more important than the macroscopical, not to open the lungs at once, but to fill the air spaces with preservative fluid by means of a funnel attached to a short rubber tube and cannula, which is tied into the main bronchus. In this way not only are the minute structures better preserved, but the air vesicles are filled out and hardened in an approximately natural condition. Care should be taken not to have too great a pressure from the inflowing fluid, since then exudations might be displaced or the lung distorted or ruptured. While the lung is being filled it should be immersed in a vessel of the same preservative fluid, in which, after closing the cannula or ligating the bronchus, it lies for twenty-four hours. It is then cut into small pieces and the hardening completed. For the display of certain gross lesions, such as tuberculous and other cavities of the lungs and bronchi, tumors, etc., the lungs filled in this way are opened by an incision along the posterior surface, from apex to base and hung in jars. For this purpose 5-per-cent. formaldehyde solution may be used for both fixation and preservation in the jars. A variety of hardening agents may be used: Orth's fluid or formalin solution (10 : 100) is on the whole the best. If, however, the lung is commencing to decay, strong alcohol will stop the process most quickly and give as good results as are possible under the circumstances. Alcohol should be used when the lungs are to be examined for bacteria.

It is often desirable, and particularly in cases in which the topography of lesions is to be studied, as in acute miliary tuberculosis, acute and chronic phthisis, infarctions, etc., to inject the blood-vessels with colored gelatin. The lung should, after the injection, be hardened in alcohol.

The Pharynx, Larynx, Œsophagus, and Thyroid Gland.—For the removal of these parts the incision through the skin should be carried upward as far as practicable—when permissible, to a point 1 inch below the chin, the head being allowed to hang backward over the edge of the table.

The soft parts are dissected from the larynx, taking care not to cut the thyroid body, and an incision is made through the floor of the mouth, following the internal surface of the inferior maxilla. Through this incision the fingers are introduced into the mouth, the tongue is drawn down, the posterior wall of the pharynx is divided above the tonsils, and the tongue, pharynx, and larynx are drawn out together. These organs are then pulled downward, and with the aid of the knife the trachea and œsophagus are removed entire, the œsophagus being cut just above the stomach. If the contents of the stomach are to be preserved, as in cases of suspected poisoning, a ligature is put around the œsophagus just below the point at which it is to be cut off.

With the enterotome the pharynx and œsophagus are now slit open upon their posterior surfaces. The mucous membrane thus exposed is examined for evidences of caustic poisons, of inflammation, tumors, strictures, varices, etc. The enterotome is next introduced into the larynx, and this organ and the trachea are laid open along the posterior wall. Here we look for œdema of the aryteno-epiglottidean folds (œdema of the glottis), for evidences of catarrhal, croupous, ulcerative, and syphilitic inflammation, and for tumors and lesions of the laryngeal cartilages. Œdema and redness of the larynx may result from post-mortem changes, especially in bodies which have been kept for several days in cold weather. A well-marked œdema glottidis during life may leave no trace after death. Putrefactive changes usually commence early in the larynx and trachea.

The thyroid gland is dissected off and examined. Its weight varies considerably, being, according to Krause, somewhat over 30 grams.

PRESERVATION OF THE PHARYNX, LARYNX, TRACHEA, ETC.—These structures are freed from superfluous tissue and suspended entire by a thread in a large quantity of Orth's fluid or Flemming's osmic-acid mixture, after which the hardening is completed in the usual way. The œsophagus should be stretched loosely on sheet cork with pins, and hardened in either of the above fluids. The thyroid may be cut into small pieces and similarly hardened.

THE ABDOMEN.

Returning now to the abdominal cavity, we first dissect off the omentum. Tubercles of the peritoneum may be best seen in the omentum. The colon is then raised and dissected free, to the cæcum on one side and to the rectum on the other. The colon and small intestines are then drawn first to the right and then to the left side, so as to expose in turn the right and left kidneys. As each kidney is brought into view an incision is made through the peritoneum over the track of the ureter. The ureter is followed through its entire length and its condition ascertained.

Sometimes one, more rarely all, of the abdominal viscera are unusually movable, owing to a relaxation of their ligamentous or other supports. This condition—enteroptosis—is common in the liver, more frequent in the spleen, and especially so in the kidneys. It has been occasionally described in the stomach and intestines.

The Kidneys.—These organs are now removed, the peritoneum and fat being separated from them with the hand, and the vessels being divided with the knife. The adrenals, at the upper end of each kidney, are removed at the same time. The kidneys may be softened by putrefaction, or the surface may have a greenish gray color, caused by the post-mortem action of putrefactive gases on the hæmoglobin.

An incision is made through the capsule along the convex border of the kidney, and the membrane stripped off. We notice the degree of adherence of the capsule to the kidney, and also the surface of the latter, whether smooth or roughened, pale, congested, or mottled; an incision is made along the convex surface down to the pelvis, so that the organ

is divided into halves. We observe the relative thickness of the cortical and pyramidal portions, as well as the size of the entire organ. To ascertain the latter point, it is well to weigh each kidney; the normal weight is from 130 to 150 grams. The left kidney is, according to Orth, from five to seven grams heavier than the right. At from twenty to thirty-five years of age, according to Thoma, the weight of the heart is to the weight of both kidneys as 1 : 1.1. The weight of the kidneys of adults is given by Vierordt in general as about 0.48 per cent. of that of the entire body.

It is necessary to remember that in a kidney which is much atrophied there may be an increase of fat in the pelvis, which gives the organ nearly its normal size and weight, while the kidney tissue proper may have in great measure disappeared.

We now inspect the kidney tissue more closely, especially the cortical portion. The pyramids consist largely of tubes running in nearly straight lines from the apex to the base of each pyramid. These straight tubes pass from the pyramids into the cortex in bundles, called medullary rays, many of them retaining their straight course until they nearly reach the surface of the kidney. These straight tubules send off branches on all sides of the rays, which become convoluted, form Henle's loops, and finally terminate in the glomeruli or Malpighian bodies. In this way the cortex of the kidney, as seen in section, is divided into alternate bands of straight tubes, and convoluted tubes, with glomeruli; both sets of bands being perpendicular to the surface of the kidney, and called respectively medullary rays and labyrinths. About the convoluted tubules and glomeruli is a rich venous plexus; and since after death the blood usually remains in this plexus and in the glomeruli, the bands containing the convoluted tubules, *i.e.*, the labyrinths, usually appear red, while the medullary rays are grayish white. In a normal kidney, therefore, the cortex should be regularly striped in narrow alternating red and whitish bands.

The average thickness of the cortex of the kidney is from four to six millimetres.

If there be extensive congestion, the entire cortex is red. If the epithelium of the tubules degenerates and fills them up, or if there are considerable changes in the interstitial tissue, the regular bands are lost and the cortex is irregularly mottled. If the tubular epithelium becomes filled with fat globules, this is indicated by an opaque yellow color of the affected parts; in many cases, therefore, the existence of a kidney lesion can be recognized with the naked eye.

If waxy degeneration be present to a marked extent, it may be manifested by a peculiar translucent appearance of the affected parts, but in most cases it is necessary to apply reagents to demonstrate it satisfactorily. The cut surface of the kidney is washed with water, to free it from blood, and repeatedly brushed with an aqueous solution of iodine (iodine 1 part, potassium iodide 3 parts, water 100 parts). The glomeruli and the blood-vessels are most frequently affected, and, if so, they may appear as mahogany-colored dots and lines on a yellow ground.

But this reaction is not constant, and, for accurate detection of amyloid substance, recourse should be had to other reagents applied to sections of the hardened tissues (see p. 50).

The pelvis of the kidney should be examined for inflammatory lesions and calculi. Sometimes a whitish fluid is seen in the pelvis and can be squeezed from the papillæ; this is produced by a post-mortem desquamation of the epithelium, but is likely to be mistaken for pus.

PRESERVATION OF THE KIDNEY.—If the kidney be not opened, the blood-vessels may be injected through the renal artery, slowly and under a low pressure, with Orth's fluid or Flemming's osmic-acid mixture. After the vessels are filled with either of the above fluids, they are tied, and the entire organ is placed in a large quantity of the injecting fluid for twenty-four hours. The kidney is then cut into small pieces, and the hardening is completed in the usual way.

In most cases, however, the kidneys will have been opened for inspection at the autopsy. Then small pieces are removed from the various regions and hardened in the above fluids.

Kidneys which are to be examined for the presence of bacteria should be cut into small pieces and placed at once in strong alcohol, which should be changed once or twice, and in which they are permanently preserved.

The Adrenals—Suprarenal Capsules.—These are, in the fœtus, of an ovoidal, in the adult, of a triangular shape. They are situated at the upper and inner border of the kidney, to which they are loosely attached by connective tissue. On the anterior surface is an irregular fissure, called the hilus, from which the veins emerge. The size of the adrenals varies considerably, but in the adult the average vertical diameter is from 3.2 cm. to 4.5 cm., the transverse diameter about 3.2 cm., and they are from 4.2 mm. to 6.4 mm. in thickness. They weigh in the adult from 4 to 8 grams. They are relatively larger in children than in adults. They are composed of a cortical and a medullary portion, the cortex forming a yellowish shell around the dark red or brown medulla. They are enclosed in a connective-tissue capsule, from which fibrous processes extend inward, dividing the gland into a series of irregular chambers. Those in the cortex are mostly elongated, giving this portion a striated appearance, while those in the medulla are polyhedral. It is in these spaces that the parenchyma cells lie. The adrenals readily decompose; the inner layer of the cortex may soften and break down, so that the outer zone forms a sort of cyst filled with reddish brown broken-down substance. Hypertrophy, tuberculosis, and cheesy degeneration, fatty degeneration, and tumors are to be looked for.

PRESERVATION.—The adrenals should be hardened in Orth's fluid or in strong alcohol.

The Spleen.—This organ has, when removed from the body, the general shape of a flattened ellipsoid, most curved on its external and posterior surface. It is situated in an oblique position on the left side of the stomach, and between its cardiac end and the diaphragm. The vessels are given off from its inner surface, which is crossed by a more or less well-marked vertical ridge. The point of emergence of the vessels

is called the hilus. Its long diameter extends from the seventh intercostal space to the eleventh rib. Its upper portion is separated from the ribs by the lungs; its lower portion, by the diaphragm.

It is, according to Vierordt, on the average, from 12 to 13 cm. long; from 7 to 8 cm. broad, and about 3 cm. thick. Its average weight is about 171 grams. The dimensions of the spleen as given by Krause are somewhat greater than the above. But its measurement and weight vary considerably within the limits of health. It is in these respects the most variable organ in the body. In old age the average weight gradually diminishes.

The spleen is enclosed in a fibrous capsule covered with peritoneum. The parenchyma is formed of blood-vessels and fibrillar connective tissue, and of a soft, dark red pulp in which are embedded whitish spheroidal or elongated bodies, the glomeruli, or Malpighian bodies. In the normal human spleen the glomeruli are usually hardly perceptible to the naked eye, but sometimes they are very plain. Sometimes the fibrous stroma is very apparent, sometimes not.

The size, consistence, and color of the organ vary a good deal within normal limits; it may soften in decomposition. Thickenings of the capsule and abnormal adhesions are very common, and often occur without any clinical history indicating disease. We should look for changes in size, color, and hardness; for pigmentation, hyperplasia of the connective tissue, amyloid degeneration, tubercles, and infarctions.

Not infrequently one or more spheroidal or flattened so-called accessory spleens are found in the vicinity of the spleen; they vary in size from that of a pea to that of a walnut.

PRESERVATION.—In certain diseases of the pulp, anæmia, leucocythæmia, etc., the tissue should be teased, when fresh, in 0.85-per-cent. salt solution, or examined by the staining methods described under the Lesions of the Blood. For general purposes small pieces of the organ are hardened in Orth's fluid, Flemming's osmic-acid mixture, or in alcohol.

The Intestines.—The rectum is divided, the intestine is seized with the left hand, and, being kept stretched, is separated from its attachments by repeated incisions through the mesentery close to the gut, until the duodenum is reached, where the intestine is again cut off. The operation is more cleanly if, before dividing the gut, ligatures are placed around it at either end. The entire length of the gut is now laid open with the enterotome along the mesenteric attachment; the mucous membrane is cleaned with a stream of water and then examined.

In cases of suspected poisoning, a ligature should be placed around the rectal end of the gut and two around the duodenal end, and it should then be cut off below the former and between the latter ligatures. The gut is now opened and the contents are emptied into a clean glass jar for delivery to the chemist, care being taken that they be not allowed to touch anything but the inner surface of the jar. After washing the intestine in pure, fresh water and examining it, it should be placed entire in another clean jar and the jar sealed.

Cadaveric lividities are very common in the intestines, and are usually most marked in the dependent portions. They are apt to occur in patches, but may be diffuse and very extensive. If the wall of the gut be stretched, they are often seen to be discontinuous, owing to the pressure of the blood from the parts which are squeezed by folds. Small patches of arborescent or diffuse red staining are often seen, formed by the imbibition from the vessels of decomposing hæmoglobin. In the more advanced stages of decomposition the mucosa may be softened and loosened. A dark purple or brownish discoloration of the entire intestinal wall is frequently seen, either diffuse or in patches. Much experience and careful observation are requisite in forming a correct judgment regarding the significance of changes of color in the intestines. Caution is necessary in distinguishing normal digestive hyperæmia from abnormal congestion. A very considerable congestion may exist without disease.

The lesions ordinarily to be looked for are catarrhal, croupous, and ulcerative inflammations, perforations, hæmorrhages, strictures, tumors, amyloid degeneration, swelling and ulceration of the solitary follicles and Peyer's patches, and pigmentation. For the detection of amyloid degeneration of the mucosa this structure should be carefully washed and brushed with a solution of iodine.

PRESERVATION.—For the general purposes of microscopic study, portions of the gut should be gently stretched on cork (the mucosa side free) and hardened in Orth's fluid or in Flemming's osmic-acid mixture.

For obvious reasons the mucous membrane should be handled as little as possible, for, in the majority of cases, decomposition and softening have already set in at the time of the autopsy, and, under the most favorable conditions, the epithelium is very easily rubbed off.

In cases in which the most perfect preservation of the topographical features, as well as the minute structure of the intestinal mucosa, is desired, even at the expense of an inspection of the fresh tissue, another mode of procedure is to be recommended. Selected segments of the gut are, after removal from the body, allowed to remain unopened on the table while ligatures are tied around the ends. The isolated segments, or the whole gut, may now be moderately filled—not distended—with one of the above fluids by means of a syringe with a needle cannula; or one end of the segment may be tied and the fixative introduced through a funnel at the other, which end is then ligated. The segments to be preserved should now be placed unopened in the fixative solution. After twenty-four hours they may be opened with scissors or a sharp knife, cut into suitable pieces, and kept permanently in 80-per-cent. alcohol.

The Stomach and Duodenum.—We now introduce the enterotome into the duodenum at its transverse portion, and open it on the convex border.

When the pylorus is reached the incision is carried obliquely over to the greater curvature of the stomach, along which it is extended as far as the œsophageal opening, and the organ examined *in situ*; or, if a more careful examination of the stomach is called for, after ascertaining whether or not the bile duct is pervious (see below), the duodenum and stomach may be removed together, and the stomach opened and examined on the table. Alterations in size and form, the presence of tumors, ulcers, etc., may now be sought for.

If poisoning be suspected, a ligature should have been placed, earlier in the examination (see above), around the lower end of the œsophagus and the duodenum. The stomach and duodenum are now removed together unopened. They are to be opened in a carefully cleansed glass jar, and after an inspection of the mucous membrane and the contents with the naked eye and a hand lens, stomach, duodenum, and contents are to be sealed in the jar for the chemist.

We now look for the orifice of the bile-duct, which will be found about the middle of the descending portion of the duodenum on its concave border. Pressure on the gall-bladder or on the common duct will usually cause the bile to flow into the intestine if the ducts are pervious. But a sufficient degree of stoppage may exist in the ducts to give rise to marked symptoms of disease, without preventing the flow of bile under these conditions, even with a moderate pressure. A long director is now passed into the gall-duct, which is laid completely open; ulcerations, cicatrices, gall-stones, inflammatory lesions, and tumors are looked for. In stricture of the gall-duct the mucous membrane above will often be found bile-stained, while below it is colorless. At this point, should there be any special reason for doing so, the portal vein, which lies close behind the ductus choledochus, should be opened and examined for periphlebitis, phlebitis, and thrombosis. The mucous membranes of the duodenum and stomach are now examined. Acute inflammation from caustic poisons, chronic catarrhal inflammations, hæmorrhages, ulcers, erosions, swelling of the solitary follicles (lymph-nodules), and tumors are lesions most frequently seen. We sometimes find a diffuse congestion of the stomach, similar to that produced by irritant poisons, as a result of doses of croton oil given just before death.

PRESERVATION.—The same methods should be used as for the intestines (see above). Tumors should be cut into small pieces and hardened in Orth's fluid or 5-per-cent. formaldehyde.

The Liver.—To remove the liver, the diaphragm is first divided on one side of the suspensory ligament as far back as the spine; the suspensory ligament is then divided; then the right and left lobes being in turn raised, the lateral ligaments are severed. Then, the left lobe being seized, the organ is dragged obliquely downward into the abdominal cavity, the remaining attachments being dissected away. The liver is first laid on its superior surface and the gall-bladder and its contents are examined. The character of the gall is to be determined, and gall-stones, inflammatory lesions, and tumors are to be sought for. To determine the actual size of the organ, it should be both measured and weighed. Its size varies greatly in different healthy individuals, but in general it may be said that it measures from 25 to 30 cm. transversely, from 15.3 to 18 cm. antero-posteriorly, and from 9 to 12 cm. at its thickest part; its ordinary weight is between 1,550 and 1,860 grams. In children its weight relative to that of the body is greater than in adults. The liver is increased in size and weight during digestion and by congestion from any cause.

The convex surface of the right lobe of the liver not infrequently shows several grooves running from front to back, approximately parallel with the suspensory ligament of the liver. These grooves, which may be found in persons of all ages, are believed by some to be usually congenital, by others to be the result of pressure of the diaphragm and the abdominal muscles on a relaxed atrophic liver. They seem in any event to be of no practical importance. On the other hand, a transverse groove running at right angles to the axis of the body is a not infrequent result of tight lacing, and is usually associated with local connective-tissue thickening of the capsule and underlying tissue of the liver. In this way the liver may become much distorted and the gall-bladder compromised.

The capsule of the liver is now examined; the organ is then laid on its lower surface and several deep incisions are made from above downward. The color and consistence of the liver tissue should be noticed, also the distinctness with which the lobular outlines can be seen; whether or not the centres of the lobules are congested or their peripheries lighter in color than usual; the presence of tumors, tubercles, abscesses, ecchinococcus, new connective tissue, and pigmentation. Suspected amyloid degeneration should be tested for by iodine solution.

We often find the surface of the liver of a greenish or very dark brown color; less frequently the same color extends into the substance of the organ. This discoloration, which is entirely post mortem, is, like the similar discoloration of other internal organs, produced by the action of the gases of putrefaction on the coloring matter of the blood.

PRESERVATION.—For the study of parenchymatous degeneration, sections of the fresh frozen tissue or small teased fragments should be examined in 0.85-per-cent. salt solution. For general purposes small pieces should be hardened in Orth's fluid or in formalin solution (10: 100) or in alcohol. Tumors should be treated in the same way.

The Pancreas.—This organ, of a light yellowish red color, is elongated, irregularly prismatic in shape, and flattened antero-posteriorly; the right end, called the head, is broader than the rest and lies in the concavity of the duodenum. The remainder of the organ, the body and tail, are usually tapering and lie transversely in the abdominal cavity, the tail reaching to the spleen. Its size and weight vary considerably; its usual length is from 15.3 to 23 cm.; its breadth about 3.8 to 4.5 cm.; its thickness about 1.3 to 3.8 cm.; its weight is usually from 70 to 108 grams. The organ may be rounded instead of flattened; the head and tail may be disproportionately large; the tail may be unusually long or may be divided or curved. The superior mesenteric artery and vein, which pass behind the gland, are usually partly embedded in it, but are sometimes completely enclosed.

A longitudinal incision should be made through the whole gland, and its substance and duct should be searched for calculi, tumors, malformations, and evidences of acute and chronic inflammation, fat necrosis, and amyloid degeneration of the blood-vessels. The pancreas is frequently of a dark red color from post-mortem staining.

PRESERVATION.—Portions of this organ should be hardened in strong alcohol, Orth's fluid, or in Flemming's osmic-acid mixture.

The examination of the **thoracic duct**, which lies to the right and posterior to the aorta, may now be made. Among the most important of its lesions is tuberculosis, since it has been shown that from a tuberculous lesion here the generalization of bacilli not infrequently occurs. Inflammatory lesions, carcinoma, partial or total occlusion from pressure may be found.

The **solar plexus**, which surrounds the origin of the celiac axis and the superior mesenteric artery and lies between the adrenals, may now be sought. Lesions of the *semilunar* and other *ganglia* are to be noted—atrophy, pigmentation, and degenerations.

The condition of the hæmolymp nodes in the prevertebral fat should be ascertained (see p. 497).

The Aorta.—The size of the lumen of this vessel should be determined. The average circumference of the ascending aorta in the adult may be taken in general as about 69 millimetres.¹ Either *in situ* or after removal the aorta should be opened by an incision extending its whole length and continued into its larger branches.

THE GENITO-URINARY ORGANS.

The Male Organs.—If the urine is to be examined it may be drawn off with a catheter; or a vertical incision may be made into the bladder just above the symphysis pubis, and some of the urine dipped out. The cut end of the rectum should now be grasped with the left hand and raised up, and this and the bladder, prostate gland, etc., dissected away from the pelvis, the knife being carried close to the bone. The bladder is now drawn backward and the loose tissue close under the symphysis pubis cut. The body of the penis is then shoved backward within the skin and dissected away from behind, beneath the symphysis, and finally cut off just behind the glans penis. The penis and bladder are now drawn backward and upward, and the pelvic organs removed together. Or, the penis may be removed by sawing away the bones above the pubic arch, and then dissecting away the penis, whose root is thus exposed.

The pelvic organs are then laid on the table, the bladder uppermost; a long director is passed into the urethra, which is opened on its upper surface through its entire length, and the bladder widely opened. In the *urethra* the presence of strictures, diverticula, ulcers, inflammatory lesions, is to be noticed; in the *bladder* inflammatory lesions, hypertrophies, congestion and ecchymosis of the mucous membrane, hyperplasia and ulcers of the lymph-nodules, and tumors. The organs are now turned over; the *rectum* is opened and examined for varicose veins, hæmorrhages, ulcers, strictures, and tumors. The *prostate gland* is then cut into and the presence of calculi, inflammatory lesions, hypertrophies, and tumors sought for. Lastly, the *vesiculæ seminales* are examined, in

¹ See Vierordt's Tables; also v. *Ritók*, *Zeits. f. klin. Med.*, Bd. lxi., p. 36, 1907.

which, though rarely, we may find evidences of tuberculous inflammation and dilatation.

The testicles may be removed, when necessary, without cutting the scrotum, by enlarging the inguinal canals from within and crowding the glands through them and cutting them off. The average weight of the adult testicle with its epididymis is, according to Krause, from 15 to 24.5 grams. Inflammatory lesions, tuberculosis, abscesses, and tumors are the most frequent lesions.

PRESERVATION.—The urethral canal and bladder may be pinned open and hardened in Orth's fluid or in Flemming's osmic-acid mixture. The prostate, vesiculae seminales, testicles, and tumors may be hardened in the same fluids.

The Female Organs.—The position and general condition of the pelvic organs should first be determined by inspection. Abnormal adhesions of the ovaries, broad ligaments, Fallopian tubes, and uterus; malpositions of the uterus; subserous tumors of the uterus, and ovarian tumors, are frequently observed. Hæmorrhage into the posterior *cul-de-sac* is sometimes found. The urine should be collected, if necessary, as above directed; the organs should be dissected away laterally, as in the male, care being taken not to injure the ovaries and Fallopian tubes. The bladder is then drawn strongly backward and upward, and dissected away from the symphysis and the pubic arch, and, the point of the knife being carried forward and downward, the vagina is cut off in its lower third, the rectum severed just above the anus, the remaining attachments cut, and the pelvic organs are taken out together. If it be necessary to remove the external generative organs, after freeing the lateral surfaces of the internal organs and the bladder, the legs are widely separated and the vulva and anus circumscribed by a deep incision. The tissues close beneath the pubic arch are now dissected away from below, and the vulva is thrust back beneath the symphysis; it is now seized above the bone, and together with the anus dissected away and removed with the other organs.

The bladder is first opened and examined. The *vulva* may now be examined for hypertrophies, inflammatory lesions, ulcers, cicatrices, cysts, and tumors. The *vagina* is opened along the anterior surface; its more common lesions are inflammations, fistulæ, ulcers, tumors, and rarely cysts.

The Uterus.—Before opening this organ its size and shape should be determined. The adult virgin uterus is a pear-shaped body, flattened antero-posteriorly; the upper portion, or body, is directed upward and forward, while the lower portion, the cervix, is directed downward and backward. It is covered anteriorly by peritoneum to a point a little below the level of the os internum; posteriorly, to a point a little below the level of its junction with the vagina. The peritoneal investment separates from the organ at the sides to form the broad ligaments. The uterus is held in position by the broad and round ligaments and by its attachments to the bladder and rectum and vagina. The upper end, the fundus, does not extend above the level of the brim of the pelvis.

Its average length is about 7.6 cm.; its breadth about 5.1 cm.; its thickness about 2.5 cm.; its average weight is about 31 to 46 grams. During menstruation the uterus is slightly enlarged, the mucous membrane of the body becomes thicker, softer, and its vessels are engorged with blood; while its inner surface is more or less thickly covered with blood and cell detritus. A description of the complicated changes in the uterus which pregnancy entails may be found in the works on obstetrics. After pregnancy the uterus does not return to its original size, but remains somewhat larger; the os is wider and frequently fissured.

We not infrequently find in the mucous membrane of the lower part of the cervix small, transparent, spheroidal structures, called ovula Nabothi; these are small retention cysts caused by the closure of the orifices of the mucous glands. The more common lesions observed in the uterus are malpositions, malformations, lacerations, ulcerations of the cervix, acute and chronic inflammation of the mucous membrane or muscularis, or both, thrombosis and inflammation of the veins, and tumors.

In the infant the uterus is small, the body flattened, the cervix disproportionately large. During childhood the organ increases in size, but the body remains small in proportion to the cervix. At puberty, the shape changes, and the body becomes larger.

The ovaries are flattened, ovoidal bodies, situated one on each side, and lying nearly horizontally at the back of the broad ligament of the uterus. Their size is variable, and they are usually largest in the virgin state. They measure about 3.8 cm. in length, 1.9 cm. in breadth, and nearly 1.3 cm. in thickness. Their average weight is from 3.9 to 6.5 grams. The sides of the ovary and its posterior border are free; it is attached along the anterior border; to its end is attached the ovarian ligament, to its outer extremity one of the fimbriæ of the Fallopian tube. The ovary is covered on its free surface by cylindrical epithelium, and its surface is less glistening than the general peritoneum. The surface of the ovary is smooth in the young, but becomes rougher and depressed in spots as the process of ovulation goes on. In adult females we usually find corpora lutea in their various stages. We should seek for evidences of acute and chronic inflammation, for tumors and cysts.

The Fallopian tubes, lying in the upper margin of the broad ligaments, are from 7.6 to 10 cm. in length. The length often differs considerably on the two sides. They commence at the upper angles of the uterus as small perforated cords, which become larger farther outward, and bend backward and downward toward the ovary. They terminate in an expanded fimbriated extremity about 2.5 cm. beyond the ovary. They are covered by peritoneum, and the mucous membrane lining them, continuous with that of the uterus, is thrown into longitudinal folds. Malpositions by adhesions, closure, inflammations, and cysts are the more common lesions. The possibility of tubal pregnancy should be borne in mind.

PRESERVATION.—All of these organs and their tumors may be hardened in Orth's fluid or in Flemming's osmic-acid mixture. The vagina should be stretched flat on

cork, and the cavity of the uterus laid wide open. Great care should be taken not to touch either the internal surface of the uterus or the external surfaces of the ovaries, since in both the epithelium is very easily rubbed off.

It is better, after opening them by a transverse incision, to suspend the ovaries by a thread in a jar of the preservative fluid than to let them lie on the bottom, since the epithelium is thus less likely to be rubbed off. Larger cysts of the ovary for exhibition purposes should be distended with preservative fluid.

The Closure of the Body after the Post-mortem Examination.

At the end of the autopsy the body should be restored as nearly as possible to its natural external appearance.

Fluids should be removed, vacant spaces filled with absorbent material, such as cotton, jute, or sawdust, and the incisions closed by sutures.

Bacterial Examination of Post-mortem Specimens.

It is often important to make a thorough post-mortem examination by cultures as well as morphologically of the blood and of all the viscera. This is important not only in those cases which during life gave clinical evidence of general infection, but also in many forms of disease whose nature is still wholly obscure.

In the interpretation of the result of all such examinations, however, it should be borne in mind that after death a new distribution of germs may occur, and that from the gastro-intestinal canal and from other surfaces or cavities of the body micro-organisms may, as decomposition progresses, penetrate the tissues and the viscera.

A careful consideration of the general conditions under which the body has been kept and its state of decomposition is of special importance in the interpretation of the significance of the *Bacillus coli communis*, which is always present in such enormous numbers in the intestinal canal, and which is not only apt to effect wide distribution in the body after death, but as a result of careless manipulation is likely to be accidentally brought in contact with other viscera after the opening of the gut. The preparation of cover-slips for staining and the making of cultures is, as a rule, best done at the autopsy table.

It is well as each organ is exposed—commencing with the heart—to sear the surface of the organ to be examined with a broad-bladed knife heated over a flame, and then, making an incision through the seared surface with a sterilized scalpel, to press a sterilized cotton swab into the opening and absorb the juices which exude, or to pick out a small fragment of the solid tissue from the depths of the opening, or to secure some of the blood or fluid on a sterilized platinum loop; and then with the material thus procured make the required cultures and afterward the cover-slip smears for staining.

If it be necessary to transport the material to the laboratory before making cultures, it is well to reserve the unopened organs, or large portions of these in the case of the solid viscera, and to wrap each separately in a cloth saturated with sublimate solution, or to put each in a separate sterile receptacle for transportation.

It is well to remember that in the last hours of life the safeguards of the body against the entrance and growth of micro-organisms may be ineffective, so that the determination of the significance of bacteria in the tissues a short time after death requires care and experience.¹

Autopsies in Medico-legal Cases.

While every autopsy should be made as carefully and completely as circumstances permit, it should be always borne in mind that in examinations which may have medico-legal bearings it is of the highest importance to examine thoroughly both macroscopically and microscopically every part of the body from which light may be derived as to the cause of death, for in medico-legal cases it is not infrequently as important to be able by a complete examination to declare the absence of lesions which could cause death, as to determine the presence of those upon which the opinion as to the actual cause of death in a particular case rests. Bearing this in mind, the technic of autopsy-making is essentially the same whatever the ends which the facts elicited may be destined to serve.

Autopsies in Cases of Suspected Poisoning.

In cases of suspected poisoning which may possibly have a medico-legal bearing, the examination should be made with extreme care and thoroughness. The inspection of the body and the examination of *all* the viscera should be thorough and detailed. Every appearance should be noted at the time, and nothing left to the memory. It is well to have an assistant record the observations as they are made. The disposition of the parts and organs in jars should be also noted at the same time.

It is important to remember that many poisons destroy life without producing appreciable lesions, and also that many cases of sudden death occur, not due to poisons, and without any discoverable cause.

In bodies which are exhumed for examination, the tissues may be so changed by decomposition that it is impossible to say whether lesions have or have not existed. In such cases the careful and separate preservation of the viscera and other parts for chemical examination, is often all that can be done.

It is always best, in cases of suspected poisoning, to preserve for the chemist not only the stomach and intestines, but the entire liver and brain; or, if only portions of these can be saved, these portions should be carefully weighed, as well as the entire organs, and the relative amount of tissue reserved carefully noted at the time. It is even well, particularly in cases in which the administration of the readily diffusible poisons, such as arsenic, strychnia, etc., is suspected, to preserve the whole of all the internal organs, together with a large piece of muscle and bone; since with large quantities of tissue the results of the chemical

¹ For details of bacterial flora of the human body see references pp. 150 and 319.

analysis depend less upon calculations, and are hence more comprehensible to the average jury. In all such cases jars should, if possible, be procured which have never been used before, and these should be carefully washed and rinsed with distilled water. They should have glass stoppers and be sealed at once and carefully labelled before leaving the hands of the operator. If they can be delivered to the chemist without much delay, no preservative fluid should be added. If they are to be kept for a considerable time, pending the action of a coroner's jury or for some other reason, a small quantity of pure strong alcohol may be poured over them. In this the operator should be particular to preserve a quantity, at least half a pint, of the specimen of alcohol used, in a clean, sealed, and labelled bottle, so that this may be tested by the chemist and be proven to be free from the poison. It is better in all cases, however, to avoid, if possible, the use of alcohol. In all autopsies which may have medico-legal importance full notes should be taken by an assistant as the operation proceeds, carefully read over immediately afterward and dated, and kept by the operator for future reference. The labelling and disposition of the jars should be recorded in the notes. The specimens should not for a moment be out of the sight of the operator until they are placed under lock and key and seal, or are delivered to some authorized person, so that there may be no question of their identity should the case come into court.

Examination of the Bodies of New-born Children.¹

In examining the bodies of new-born children, we may have to determine, besides the ordinary lesions of disease, the age of the child, whether it was born alive, how long it has been dead, what was the cause of death.

SIZE, AGE, AND CHARACTERS OF THE NEW-BORN CHILD.—The fresh corpse of a new-born child at term no longer resembles that of the immature foetus. The skin is firm and pale, like that of an adult. The lanugo has disappeared except on the shoulders. In the majority of cases the hair on the head is 1.5 to 2 cm. long. The great fontanelle is, in the average, 2 to 3 cm. long. As determined by an analysis of 661 cases, the average length is 50 cm., the weight 3,256 grams. The nails are hard and reach to the tips of the fingers, but not to those of the toes. The cartilages of the ears and nose are hard. The labia are more nearly closed. An ossification centre in the lower epiphysis of the femur should be sought for, as its presence is one of the most reliable signs of the maturity of the foetus. If it is absent, the foetus is, as a rule, not more than thirty-seven weeks old; but in rare cases it may be absent at term. A centre of ossification 1 mm. in diameter indicates an age of thirty-seven to thirty-eight weeks, if the child was born dead or died soon after birth. Rarely it is no larger than this at term. A diameter, at birth, of 1.5 to 9 mm. indicates an age of 40 weeks. A diameter of more than 9 mm. indicates, as a rule, that the child has lived some time after its birth; a less diameter than 7 mm., however, does not prove the contrary.

Twenty-four hours after the birth of the child the skin is firmer and paler. The umbilical cord is somewhat shrivelled, although still soft and bluish in color. From the *second to the third day* the skin has a yellowish tinge and the cuticle sometimes appears cracked. The umbilical cord is brown and dry. From the *third to the fourth*

¹ The human embryo, according to the estimate of *His*, measures in length approximately at 4 weeks from 7–8 mm.; at 5 weeks 13 mm.; at the end of the second month 25–28 mm. *Schröder* estimates the approximate length of the foetus at later lunar months as follows: 3d, 70–90 mm.; 4th, 100–170 mm.; 5th, 180–270 mm.; 6th, 280–340 mm.; 7th, 350–380 mm.; 8th, 425 mm.; 9th, 467 mm.; 10th, 490–500 mm. Consult for further data McMurrich, "The Development of the Human Body," 1903, p. 108, bibl.

day the skin is yellowed, and the cuticle is apt to separate from the skin. The umbilical cord is of a brownish red color, flattened, semi-transparent, and twisted. The skin around its insertion is red and congested.

GENERAL INSPECTION.—The head should be examined for the marks of injuries. Very commonly some portion of the scalp will be found swollen and infiltrated with blood and serum. This may be the *caput succedaneum* formed during delivery. The mouth and nose should be examined for the presence of foreign bodies which might have caused suffocation.

The neck should be examined for marks of strangulation. The umbilical cord may be twisted around the child's neck and strangle it. The mark left by the cord is usually continuous, broad, not excoriated, sometimes accompanied by ecchymoses in the skin.

The surface of the body should be examined for the presence of vernix caseosa, blood, marks of injury, and the existence of putrefaction. It should be remembered that putrefaction is apt to commence earlier in the bodies of young children than in those of adults.

The umbilical cord may be cut or torn. It usually separates by the fifth day, sometimes not until the tenth. If the umbilicus is cicatrized and healed, the child has probably lived for three weeks. A zone of redness around the insertion of the cord may exist previous to birth. Redness and swelling (which may disappear after death) with suppuration can be found only in a child which has lived for several days. The drying and mummification of the cord may take place as well in dead as in living children. It is possible for a child to die by hæmorrhage from a cut or torn cord, either before or after it has breathed. The umbilical vessels should be examined, as they may be the seat of umbilical infection.

The extremities may exhibit fracture of the bones. These may occur during intra-uterine life, from injuries to the woman or from unknown causes; or may be produced by violence in delivery, or by injuries after birth.

INTERNAL EXAMINATION.—*The Head.*—The fontanelles and sutures should first be examined as to their size and for penetrating wounds. An incision should then be made through the scalp across the vertex, and the flaps turned backward and forward as in the adult. With a small knife the edges of the bones should be separated from the membranous sutures and the dura mater, beginning low down in the frontal and going back into the lambdoidal suture on either side. The bones are then drawn outward and cut through around the skull with strong scissors. The brain is removed and examined as in the adult.¹

Effusions of blood—cephalæmatoma—may be formed, soon after birth, between the pericranium and bone, or, more rarely, between the dura and bone. Clots are also found between the dura mater and skull; between the dura and pia mater; more rarely in the substance of the brain, as the result of protracted or instrumental deliveries, or of injuries after birth.

The cranial bones may be malformed, or exhibit the lesions of rickets or caries, or be indented, fissured, or fractured. These latter lesions may be produced during intra-uterine life by injuries to the mother, by unknown agencies, by difficult deliveries, or by direct violence after birth.

In cases of chronic internal hydrocephalus in young children, in which the ventricles are much dilated and the brain substance is thinned over the vertex, the brain is very apt to be torn in removal, and the amount of dilatation thus becomes difficult of determination. It is, therefore, better in such cases to place a pail of water beneath the head, or even immerse the latter in it, and remove the brain in the water. In this way it floats after removal, supported on all sides. It may now be opened in the water and the extent of the lesion determined at once, and parts saved for microscopic examination.

If it be desired to preserve the brain for demonstration of the lesion or for a museum specimen, it should be transferred unopened to a large jar containing 5-per-cent. formalin. A portion of the ventricular fluid should now be removed with a syringe provided with a small cannula, and replaced by formalin. This may be done

¹ Or an incision through the bones with a fine saw may be made as in the adult.

by puncturing the ventricles from below. The fluid in the jar, as well as in the ventricles, should be changed in forty-eight hours. The brain may then be cut transversely across, when the degree of dilatation of the ventricles, etc., will be revealed. The weight of the brain, according to Bischoff, is 380 grams.

It is normally much softer and pinker than in the adult, the pia more delicate; both may be much congested or anæmic without known cause. The ventricles contain very little serum. Malformations, apoplexies, hydrocephalus, simple and tuberculous inflammatory lesions, are to be looked for.

The Spinal Cord.—Extravasations of blood between the membranes of the cord may occur from the same causes as those in the brain. Spina bifida is the most frequent malformation.

The Thorax and Abdomen.—These are opened as in the adult. The *peritoneal cavity* contains a very little clear serum. A red fluid may be produced by decomposition. The peritoneum is often the seat of intra-uterine inflammation.

The Diaphragm.—In still-born infants its convexity reaches to the fourth or fifth rib. After respiration it reaches a point between the fourth and seventh ribs. Its position is, however, so variable that it is of little diagnostic importance.

The Thorax.—The *thymus gland*, at this period very large, occupies the upper portion of the anterior mediastinum, covering the trachea and large vessels. Its average weight is about 15.5 grams. It is usually about 5 cm. long, 3.8 cm. wide at its lower part, and about .63 to .85 cm. in thickness. It may be hypertrophied and compress the large vessels, or be inflamed and suppurating.

The *heart* lies more nearly in the median line than in the adult. It weighs from 20 to 24 grams. The ventricular walls are of nearly equal thickness. The pericardium contains very little serum. A considerable quantity of red fluid may accumulate here as a result of decomposition. There may be small extravasations of blood beneath the pericardium in still-born children and in those born alive. Pericarditis with effusion of serum and fibrin, and endocarditis with consequent changes in the valves, may exist before birth. Malformations and malpositions of the heart and large vessels are not infrequent. Small soft reddish nodules may be present on the edges of the valves which are remnants of the foetal mucous tissue, but may be mistaken for the marks of endocarditis. The time of closure of the foramen ovale and the ductus arteriosus varies very widely in different cases.

The *pleural cavities* contain very little serum, but decomposition may lead to the accumulation of a considerable quantity of red fluid. Small extravasations of blood in the subpleural tissue may be found in children who have died before birth and after protracted labors. Inflammation, with exudation of serum, fibrin, and pus, may exist before birth.

The *lungs* in a still-born child are small, do not cover the heart, are situated in the upper and posterior portions of the thorax, are of a dark red color and of firm, liver-like consistence, and do not crepitate. In a child born alive, and which has respired freely, the lungs fill the thoracic cavity, but do not cover the heart as much as in the adult; they are of a light red or pink color, and crepitate on pressure. If respiration has been incompletely performed, we find various intermediate conditions between the foetal and inflated states.

If any doubt exists as to respiration having taken place, it is customary to employ the *hydrostatic test*. This is done by placing the lungs, first together, then separately, and afterward cut into small pieces, in water. It is commonly said that if they sink the child has not breathed; if they float it has. This test is not, however, a certain one.¹

The lesions of inflammation, and vesicular and subpleural emphysema, may be found in the lungs of new-born children.

The *pharynx* should be opened and examined for foreign bodies.

The *larynx* and *trachea* should be examined for the lesions of inflammation and for injuries to the cartilages.

The *thyroid gland* weighs about 12 grams. It may be so enlarged as to interfere with respiration.

¹ See works on medical jurisprudence.

The Abdomen.—The *kidneys* are lobulated and proportionately larger than in the adult. Thoma estimates the average weight of both organs together as 23.6 grams. There may be ecchymoses on their surface; inflammation; deposits of uric acid and urates in the tubules of the pyramids; cystic dilatation of the tubules, sometimes reaching an enormous size. There may be absence or retarded development of one kidney. Malformations and malpositions of the kidneys are of frequent occurrence.

The *adrenals* are large. They may be dilated into large cysts filled with blood.

The *spleen* is large and firm. Its average weight is about 11 grams. It may be abnormally enlarged, and its surface is sometimes covered with fresh inflammatory exudations.

The Intestines.—In the small intestines, inflammation and swelling and pigmentation of the solitary and agminated follicles (lymph-nodules) are sometimes found. The large intestine usually contains meconium, but this may be evacuated before or during birth. The sigmoid flexure is not as marked as in the adult.

The formation of gas in the stomach and intestines does not usually take place until respiration is established. If decomposition has commenced, however, gas may be formed as a part of the process.

The *liver* is of a dark red color, is large, and contains much blood. Its size diminishes after respiration is established. Its average weight is 118 grams. The size is so variable, before and after respiration, that it gives little information as to the age of the child. Large extravasations of blood are sometimes found beneath the capsule of the liver without known cause. A variety of pathological conditions, fatty and waxy degeneration, gummy tumors, etc., may be found.

The *bladder* may be full or empty, both in still-born children and in those which have breathed. Dilatation and hypertrophy may exist during intra-uterine life.

Generative Organs.—The external generative organs in both males and females are more prominent than in adults. The ovaries are high up in the pelvis and large; the cervix uteri is long; the body small and lax, resting forward against the bladder. Phimosis in the males is the normal condition. Malpositions and retarded development of the testicles should be noticed. It should be observed whether the anus is perforate.

The bones, in suspected cases, should be examined for the lesions of inflammation, rickets, and syphilis.

PRESERVATION.—The various foetal tissues may be preserved by the same methods as are employed for those of the adult; but as they are very delicate they should be handled with great care and the preservative fluids changed with sufficient frequency.

CHAPTER II.

GENERAL METHODS OF PRESERVING PATHOLOGICAL SPECIMENS AND PREPARING THEM FOR STUDY.

It is not our purpose in this section to give a complete account of the technical procedures required in the study of pathological specimens, since the methods are for the most part identical with those employed in the study of normal tissues, with which the student or practitioner is presumably already familiar. We wish simply to give a few brief hints as to the most useful methods for the ordinary purposes. Additional suggestions will be found in parts of the book dealing with special tissues and organs; but for the technical details of many methods which are invaluable for special purposes, one may consult the "Pathological Technique" of *Mallory and Wright*, *Wood's* "Chemical and Microscopical Diagnosis," or other works on clinical pathology.

The Study of Fresh Tissues.

Although for the most part the conditions for the minute study of tissues are more favorable after these have been fixed and hardened by a suitable chemical agent, it is yet in many cases very important to examine them in the fresh state.

In this condition many of the degenerative changes in cells are more clearly seen than after fixation, while the study of living cells in indifferent fluids with various stains may throw much light upon vital phenomena and the changes which supervene when life ceases and the cell falls under the sway of the simple physical and chemical forces.

Fresh tissues may be teased apart, mounted and studied in physiological salt solution (sodium-chlorid solution 0.85 per cent.), which may also be used to separate by dilution the structural elements of exudates, pus, etc. For the more delicate studies, blood serum, or ascitic or hydrocele fluids, maintained in a sterile condition, may be used.

The study of living cells is often greatly facilitated by the addition to the physiological salt solution of a small proportion of some stain—from 0.01 to 0.1 of neutral red to 100 of the salt solution, or methylene blue 1 to 20,000 of the salt solution.¹

In the method of *Arnold*² the cells are protected from pressure of the cover-glass and the study facilitated by the use of thin sections of dried

¹ Consult for theory of vital staining *Ruzicka*, *Zeits. f. wiss. Mik.*, Bd. xxii., p. 91, 1905. For colorability of living cells see *Coco*, *Cbl. f. allg. Path.*, Bd. xiii., p. 604, 1902.

² *Arnold*, *Münch. med. Wochenschr.*, p. 585, 1906.

elder pith dipped in the fluid containing the living cells and tinged with the coloring agent.

For the methods of studying the circulation on the curarized frog see page 111.

Rapid Fixation and Frozen Sections.

A rapid fixation and development of detail in structural elements in fluids may be secured by allowing a drop of formalin to run under the cover-glass and mingle with the salt solution, the flow being directed by a bit of filter paper put close to the edge of the cover-glass on the side opposite to that on which the fixative is added. The formalin may be washed out by water and the latter replaced by dilute methylene blue for staining.

When an immediate diagnosis of a solid tissue is required, useful results may sometimes be obtained by a combination of the freezing method with the use of formalin as a fixative as suggested by Cullen.¹ Any form of freezing microtome and either ether or liquid carbonic acid may be used.

Cullen's procedure is as follows: The frozen sections are put in a 5 per-cent. watery solution of formalin for from three to five minutes; in 50-per-cent. alcohol for three minutes; in absolute alcohol for one minute. They are now washed in water, stained with hæmatoxylin, decolorized in acid alcohol (1-per-cent. hydrochloric acid), rinsed in water, contrast-stained and dehydrated with eosin alcohol, cleared with creosote or oil of cloves, and mounted in balsam. The tissues shrivel considerably by this method. The disintegration of the sections and especially the considerable shrinkage which they undergo on treatment with alcohol, may be largely obviated by spreading the sections, as they thaw, on an albumen fixative film upon a cover-glass or slide—see below—and conducting the hardening and staining manipulations with the specimen in position upon the glass.

Hodenpyl² has found that, when time permits, satisfactory results are secured by placing very small pieces of the fresh tissue for an hour in 5-per-cent. solution of formalin; then, after washing out the formalin, making frozen sections in the usual way. The sections are now dropped for a moment into a solution of egg albumen of the following composition:

Egg Albumen	10
Sodium Carbonate	1
Water	30
Add a lump of camphor to prevent decomposition.	

The sections are now spread on the slide, the excess of fluid being drained off, and are pressed against the glass with a bit of fine cheese cloth. They are finally fixed in place by a short immersion in strong

¹ Cullen, Johns Hopkins Hospital Bulletin, vol. vi., p. 67, 1895.

² Hodenpyl, "A Modification of Cullen's Method of Preparing Fresh Sections for Microscopic Work," Medical Record, vol. liii., p. 351, 1898.

alcohol. The section, now fast on the glass, is stained and mounted, *in situ*. This procedure, which can be carried out in a little more than an hour, gives a fair chance for an early morphological diagnosis in solid tissues, though the minute structural details are often much altered.

Fixation, Hardening and Preservation.

ALCOHOL is the most commonly employed fixative and hardening agent for routine purposes. It is used in the strength of from 80 to 95 per-cent. at first, the pieces of tissue to be hardened not being larger than 1 or 2 cubic centimetres. There should be in bulk many times as much alcohol as tissue to be hardened. A little absorbent cotton may be placed in the bottle to keep the blocks of tissue from sticking to the bottom. After twenty-four hours the alcohol should be renewed. On the third day the tissue is transferred to 97 per-cent. or to absolute alcohol for completion of the hardening, which will usually be within five or six days.

While for many purposes other and more delicate methods of hardening tissues are to be recommended, alcohol is most useful for solid tissues in which bacteria are to be sought, for such specimens as are not quite fresh and in which the process of decay is to be immediately checked, and in general for tissues in which the determination of topographical features for diagnostic or other purposes is the chief end in view.

FORMALIN, or formol, is the trade name for a 37-per-cent. aqueous solution of formaldehyde. In diluted solutions it is a valuable fixative for delicate tissues. It is most commonly used in a solution of 10 parts (of the commercial formalin) to 90 of water. The fresh tissues, in small pieces, are put in this solution for forty-eight hours, the fluid being renewed at the end of twenty-four hours. They are then transferred to 60-per-cent alcohol for twenty-four hours, and the hardening is completed with strong alcohol.

MÜLLER'S FLUID, which has been much used as a hardening agent, has the following composition:

Potassium bichromate	2 parts.
Sodium sulphate	1 part.
Water	100 parts.

Müller's fluid is now most often used in combination with other fixatives.

Thus *Orth's fluid*, which is Müller's fluid to 100 parts of which 10 parts of commercial formalin are added, is a most valuable agent for fixing and hardening delicate cells. The mixture should be made at the time of using because it soon changes. The pieces of tissue should be small, the fluid largely exceeding the tissue in bulk. The hardening is completed in three or four days, when the specimens should be thoroughly washed in water and preserved in 80-per-cent. alcohol.

OSMIC ACID is of great value, especially in combination, for the hardening of small portions of delicate tissues, since it serves to fix the

elements in a nearly normal condition and stains them brown or black. Osmic acid stains most forms of fat black and on this account is a valuable agent for the detection of this substance in the tissues. It is generally used in 1-per-cent. aqueous solution, the tissues, in very small pieces and when quite fresh, being placed in it and allowed to remain for twenty-four hours. They are now washed thoroughly in water and may be preserved in 80-per-cent. alcohol.

Flemming's Osmic Acid Mixture.—For the purpose of fixing delicate tissue elements to show minute structural detail, such as mitotic figures, this mixture is of great value. It is made of

1-per-cent. solution of chromic acid	15 parts.
2-per-cent. solution of osmic acid	4 parts.
Hydric acetate, glacial	1 part.

This mixture does not keep well, and hence should be made up in small quantities. Small portions of tissue should soak in the mixture for twenty-four hours, then, after thorough washing in water, they are put for twenty-four hours in 70-per-cent. alcohol, and then in strong alcohol, in which they are kept.

CORROSIVE SUBLIMATE.—This is a most excellent fixative for delicate structures. A convenient form is *Lang's Solution*. Its formula is:

Mercuric chlorid	5 gms.
Sodium chlorid	6 gms.
Hydric acetate, glacial	5 c.c.
Water	100 c.c.

The tissues should remain in sublimate solution, as a rule, not longer than from one to three hours.

Specimens fixed in sublimate develop a mercurial precipitate, do not stain well, and become brittle unless the excess of sublimate is removed. This can be largely done by prolonged washing in running water. But it is much more easily and certainly accomplished by the chemical action of dilute iodine solution. The specimen is removed from the sublimate mixture and put at once into 70-per-cent. alcohol. To this is added from time to time a sufficient quantity of saturated alcoholic solution of iodine (or tincture of iodine) to give the alcohol a moderately deep iodine color. At first this color gradually disappears, and the iodine solution should be repeatedly added until the color persists. The specimens are now transferred to 70-per-cent. alcohol, and, after twenty-four hours, to strong alcohol.

Zenker's fluid is a good fixative and acts rapidly. It is a combination of Müller's fluid and corrosive sublimate with acetic acid. Its formula is:

Potassium bichromate	2 parts.
Sodium sulphate	1 part.
Mercuric chloride	5 parts.
Hydric acetate, glacial	5 parts.
Water	90 parts.

The acetic acid should be added at the time of using, since the complete mixture readily decomposes. Small pieces of tissue may be hardened in this solution in from twenty-four to forty-eight hours. They should then be carefully washed and preserved in 80-per-cent. alcohol. The use of iodine to remove the excess of sublimate, as described under Lang's solution above, is desirable here also.

Pathological specimens which occur, or are isolated, in the form of membranes, should be stretched with pins on a piece of wood or flat cork before being immersed in the preservative fluids. Minute structures, such as occur in exudates from the mucous membranes and in cyst fluids, renal casts, etc., may be hardened in Flemming's osmic-acid mixture or in formalin followed by alcohol. Under these conditions renewals or changes of the fluids may be effected in tubes by the use of the centrifugal machine. The specimens may finally be preserved in 80-per-cent. alcohol.

Decalcifying.

Bones which are the seat of lesions, and calcified tissues, must be freed from lime salts before thin sections can be made.

Tissues which are to be decalcified should be in small pieces and first well hardened in alcohol or in Orth's fluid.

Rapid decalcification may be secured by the combination with nitric acid of phloroglucin, the latter agent preventing the swelling of the tissue elements. One gram of phloroglucin is dissolved with gentle heat in 5 cubic centimetres of nitric acid. This solution, when effervescence has ceased, is of a ruby red color. To this are added 70 cubic centimetres of strong alcohol and 30 cubic centimetres of water. This solution deteriorates with age. Small pieces of bone or other tissue are suspended by thread in relatively large quantities—at least twenty times the bulk of the specimens—of this fluid. In from one to twenty-four hours, depending upon the size of the piece of bone, the decalcification is usually complete. The specimen is now washed thoroughly in running water; put for twenty-four hours in 80-per-cent. alcohol and then in strong alcohol. Bone decalcified in this way may be stained with hæmatoxylin and eosin.

Embedding and Section Cutting.

EMBEDDING.

Some dense tissues, after being well hardened, are sufficiently solid to permit of thin sections being made from them without further preparation, but in most cases very thin sections cannot be prepared without filling the interstices of the tissue with some embedding material, which gives it greater consistence and holds the tissue elements firmly in their natural relations to one another, while the section is being made. Celloidin and paraffin are the most generally useful materials for this purpose.

CELLOIDIN, a non-explosive, purified form of gun-cotton, is best

obtained in the form of thin shavings, since in this form it is most easily dissolved. A 6-per-cent solution is made in equal parts of sulphuric ether and strong alcohol. The specimen in small pieces is soaked for twelve hours in this celloidin solution diluted with an equal amount of the mixture of alcohol and ether, then for twelve hours in the 6-per-cent. celloidin solution. If the specimen be small and require but little support, it may now be laid directly on the end of a small block of wood or cube of glass or vulcanite, and a few drops of celloidin poured around it. In most cases, however, it is better to make a small paper box, in which the specimen is placed in a proper position, and the celloidin poured in around it so as completely to enclose it. In either case a considerable quantity of celloidin should be poured around the specimen, since the celloidin shrinks considerably in hardening. The paper box may be made by winding a strip of thin paper around the end of the supporting block, allowing it to project for a sufficient distance beyond the end. The paper is held in place by a rubber band. We have thus a cylindrical box with a solid bottom projecting below it by which the whole can be held in the clamp of the microtome.

After the specimen, either free on the end of the block or in its box, is surrounded by celloidin, it should be allowed to stand for a short time exposed to the air, so that the celloidin may harden on the outside by the evaporation of the ether. If the temperature be high, the too rapid evaporation of the ether will cause bubbles to appear in the mass. This should be avoided by covering the specimen with a bell-jar. After the celloidin mass has acquired sufficient hardness on the outside to keep its shape, the whole should be placed in 80-per-cent. alcohol, in which the celloidin will harden and acquire a sufficient consistence for cutting in a few hours. When this is accomplished the paper may be stripped off, and the specimen is ready for sectioning.

After the sections have been cut they may be stained in the usual way (see below) and mounted in glycerin or balsam. If mounted in balsam, the oil of *origanum cretici* is used for clearing.

The uncut portion of tissue may be preserved, embedded in celloidin, by keeping it in 80-per-cent. alcohol. It is better, in permanent preservation of uncut celloidin-embedded specimens in bulk, to cut them off from the wooden blocks, since alcohol extracts from these a dark resinous material which colors the specimen and interferes with the staining of sections. If glass or vulcanite blocks be used, the whole may be kept in alcohol.

Stepanow has recently devised a more rapid procedure in celloidin embedding. The celloidin solution is made by the following formula, a few days being required for dissolving:

Celloidin	15 gm.
Oil of cloves	50 c.c.
Ether	200 c.c.
Absolute alcohol	10 c.c.

The hardened specimen is transferred from strong alcohol to a small

portion of the solution in a closed bottle. In from three to six hours a small piece of ordinary tissue is usually impregnated. It is then put in position on the mounting block and placed in pure chloroform. In this the proper consistency for section cutting is secured in from two to three hours, after which the whole is transferred to 80-per-cent. alcohol. If the specimen remaining after sections have been secured is to be kept, it should be removed from the block and placed in chloroform.

For further details of this method see the original description.¹

PARAFFIN.—For some purposes, especially when extremely thin though not large sections are required, paraffin embedding is almost indispensable. The sections of tissues thus embedded may be cut exceedingly thin (2 to 3 μ , or even 1 μ , with the Minot-Blake microtome), and when these are fixed to the slide and appropriately stained, the conditions for the study of cytological details are more favorable than by any other method. For the paraffin technique the specimen should be small, say one-half cubic centimetre as a maximum limit. The specimen, freed from the preservative fluid, is dehydrated by graded alcohols as follows: 30-per-cent., 50-per-cent., 70-per-cent., 85-per-cent., and finally 95-per-cent., remaining in each of these alcohols for two or several hours, and is then placed in absolute alcohol. Complete dehydration of the specimen is indispensable, for, if the slightest trace of water be left in the specimen, shrinkage or other artificial changes in the tissue are apt to occur, when the specimen is transferred to the clearing media preparatory to immersion in the melted paraffin.

When the specimen is thoroughly dehydrated by absolute alcohol, it may be put in xylol or oil of cedar, remaining in this until it sinks and becomes clear. It is then immersed in a small dish or glass box of melted paraffin, kept in a constant temperature bath held at 52° C., where it remains until completely permeated by the paraffin. It is best to use paraffin which has a melting-point of 50° C. After the specimen has remained for a while in the first dish of melted paraffin, it is transferred to a second and then to a third dish of the same, in order to remove any clearing oil remaining in the specimen. The length of time of the paraffin immersion depends upon the size and density of the specimen; usually one-half hour is sufficient for small, soft, or porous fragments, an hour or one and a half hours for larger and denser tissues. A longer period of immersion may interfere with the finer structural details of the tissues.

A small paper box considerably larger than the specimen itself is filled with melted paraffin, and with a warm needle or forceps the specimen is transferred to the paper box and set in its proper position in the bottom, so that the surface to be cut lies against the bottom of the box. In order to avoid the slow cooling of the paraffin around the specimen in successive layers, which prevents the formation of a homogeneous mass, the paper box with its contents is quickly cooled by being put into cold water, even iced water. When the paraffin block is hard, it is fastened with paraffin on to one of the various discs belonging to the paraffin

¹ Stepanow, Zeitschr. f. wissenschaftl. Mikroskopie, Bd. xvii., p. 185, 1900.

microtome, trimmed so as to have a rectangular cutting surface, and sections are cut with a dry knife. In order to stain these sections, the paraffin must be removed from the interstices; this may be done with xylol. But when the supporting paraffin is removed from the sections they are liable to fall to pieces during the further staining and other manipulations. The only practical plan therefore with the great majority of paraffin sections is to affix them to a slide and carry them in this way through the various staining and mounting procedures.

The best way of affixing delicate paraffin sections to a slide is by means of a thin film of albumen. Equal parts of white of egg and glycerin are thoroughly stirred together, filtered through paper, and a small amount of carboic acid is added to prevent the growth of micro-organisms. A very small drop of this albumen mixture is placed on one end of the slide, and with the ball of the finger or a fold of cloth it is spread over the rest of the slide in as thin a film as possible. While this scarcely perceptible film of albumen fixative is still moist, the paraffin sections or the ribbons of serial sections, divided into proper lengths, are laid upon the film and gently tapped down flat with a small camel's-hair brush or the finger-tip.¹

The slide with the attached paraffin sections is now heated over a flame, warmed just sufficiently to begin to melt the paraffin; this is a very delicate point in the operation. Just enough heat must be used to melt the paraffin and no more. If the slide be heated beyond this point, the sections may be shrunken or completely ruined. While the slide is still warm, it is plunged into a jar of xylol, oscillated to and fro a few seconds, then placed in a jar of absolute alcohol, then passed through a series of jars containing different strengths of alcohol—95-per-cent., 70-per-cent., 50-per-cent., and 30-per-cent., remaining a few minutes in each, and finally into water. Now the sections upon the slide may be stained in whatever way desired, carried up through the graded alcohols to absolute alcohol, then cleared in xylol or other clearing media, and mounted in balsam.

Tightly covered cylindrical jars—the Coplin jar is excellent—or wide-mouthed bottles are used for the better manipulation of paraffin sections, the whole slide being dropped into the receptacle for staining as well as for the dehydration and clearing.

SECTION CUTTING.

This may be done in an emergency by the free hand with a razor ground flat on the lower side, but better sections can be obtained by means of a microtome, and practically all section cutting for microscop-

¹ Not infrequently very thin paraffin sections curl or become corrugated as they leave the knife, so that it is difficult to place them flat upon the fixative film. Should this occur, a few drops of water may be spread out in a thin layer over the albumen film while it is still moist on the side, and the whole slide, with the layer of water upon its surface, is very gently heated over the flame—just sufficiently to soften but not to melt the paraffin. If the sections are then floated on the warm layer of water, they will uncurl and flatten out. The water is then drained off, when the flattened sections will lie flat upon the fixative film and remain fastened there. All traces of the water are now allowed to evaporate in the air; or, the evaporation of the water may be hastened by exposure to a temperature four or five degrees below the melting-point of the paraffin.

ical purposes is done by some form of this instrument. One of the most useful of these is Thoma's. The Schanze microtome is also well adapted for general work, as are some of the American instruments made on the same plan. For cutting sections of tissues embedded in paraffin, and especially for serial sections, the Minot microtome of the improved form—the Blake-Minot microtome can, in skilled hands, cut sections $1\ \mu$ in thickness—is excellent.

Methods of Staining.

Sections of hardened tissues may be stained for microscopical study in a variety of ways, but for routine work the double staining with hæmatoxylin and eosin is most generally useful, and is applicable to nearly all cases.

HÆMATOXYLIN solution (Delafield's) is prepared as follows: To 100 cubic centimetres of saturated solution of ammonia alum add 1 gram of hæmatoxylin crystals dissolved in 6 cubic centimetres of 95-per-cent. alcohol. This solution is exposed to the light for a week, the color meanwhile changing from a dirty red to a deep bluish-purple color.¹ Then 25 cubic centimetres each of glycerin and wood naphtha are added. This mixture is allowed to stand for a day or two and is then filtered, and the filtration is repeated at intervals until a sediment no longer forms.

The solution is now ready for staining, the best results being obtained by diluting the fluid with from ten to twenty times its bulk of water. The sections are immersed in the fluid, and allowed to remain until they have acquired a distinct purple color which persists after rinsing in water. They are now placed for a moment in a dilute alcoholic solution of eosin, and then mounted in glycerin which has been colored lightly with an alcoholic solution of eosin. In this way the nuclei of the cells will be stained of a purple color, while the cell bodies, and to a certain extent the intercellular substance, will be colored a light rose red.

If specimens are to be mounted in Canada balsam, they are stained with hæmatoxylin as before, and the eosin staining is done by tinging with a saturated alcoholic solution of eosin, the alcohol with which the final dehydration of the specimen is accomplished. A similar result may be obtained by tinging the oil of cloves or origanum with which the clearing of the sections is effected.

Iron Hæmatoxylin (Heidenhain's).—Sections are soaked for an hour in a 2-per-cent. solution of ammonia sulphate of iron, then rinsed with water and put for an hour in a half-per-cent. aqueous solution of hæmatoxylin (prepared by heating); again rinsed and put again in the iron solution, in which the color gradually fades. The section must be watched during the process of the differentiation which takes place in the iron solution, and when this is accomplished to a proper extent the section is thoroughly washed in running water and mounted in the usual way. This method is especially valuable for the study of nuclear struc-

¹ The time required for this "ripening" of the solution may be spared by the use of hæmatin in the place of hæmatoxylin.

tures, the color of these ranging from blue to black, depending upon the length of time of immersion in the stain and the grade of differentiation.

By the use of this method, micro-organisms may be stained black, and in this condition are, as Leaming has shown, well fitted for the purposes of photomicrography.

PICRO-ACID FUCHSIN (Van Gieson's Stain).—This double stain, first suggested by Van Gieson, especially for the nerve tissue, has wide applications in both normal and pathological histology, and is most useful when following a deep hæmatoxylin stain.

It colors the fibrillated connective-tissue fibres and the neuroglia in general a bright or garnet red, and also the axis cylinders and ganglion cells. Myelin, muscle fibres, and certain other cells are stained yellow, while the nuclei after the hæmatoxylin stain are brownish red in color. Van Gieson's stain is also of value, although its limitations in this particular are not yet fully determined, as a coloring-agent for hyalin, amyloid, colloid, and mucin in the tissues. As a differential stain for fibrillated connective-tissue fibres it is of value in the study of various tumors and especially of the sarcomata.

It is commonly prepared in two strengths, the stronger for use especially in nerve-tissue staining, the weaker for general purposes. The formulæ and method of using as suggested by Freeborn¹ are as follows:

Picro-acid Fuchsin.

Stronger solution—

1-per-cent. aqueous solution acid fuchsin	15 c.c.
Saturated aqueous solution picric acid and water, each	50 c.c.

Weaker solution—

1-per-cent. aqueous acid fuchsin	5 c.c.
Saturated aqueous solution picric acid	100 c.c.

The tissues may be hardened either in alcohol, or in Orth's fluid, or in formalin.

Sections are first stained deeply with hæmatoxylin, washed in water, and put into the staining fluid, in which they remain for varying periods, depending upon the tissue and the strength of the stain, but in general from one to five minutes. The sections are now rapidly dehydrated by alcohol, cleared with oil of origanum, and mounted in balsam.

MALLORY'S ANILIN-BLUE STAIN.—This stain is especially useful in bringing out in blue the fibrillæ and reticulum of connective tissue, though various hyaline substances are similarly colored. The nuclei, protoplasm, elastic fibres, axis cylinders, neuroglia fibres, and fibrin are stained red; while red blood cells and myelin sheaths are yellow.

The details of the method are as follows:²

1. Fix in Zenker's fluid.
2. Embed in celloidin or paraffin.
3. Stain sections in a one-tenth-per-cent. aqueous solution of acid fuchsin for five minutes or longer.

¹ Freeborn, Proc. New York Path. Soc., 1893, p. 73.

² See Mallory and Wright, "Pathological Technic," 1904, p. 322.

4. Transfer directly to the following solution for twenty minutes or longer:

Anilin blue soluble in water (Grübler)	0.5
Orange G. (Grübler)	2.0
1-per-cent. aqueous solution of phosphomolybdic acid	100.

5. Wash and dehydrate in several changes of 95-per-cent. alcohol.
6. Clear in xylol or in oil of origanum.
7. Xylol balsam.

METHYLENE BLUE is a useful stain for many purposes. The tissues may be hardened in Zenker's or Orth's fluid.

GIEMSA'S¹ STAIN FOR BLOOD AND TISSUES.—The stain is prepared as follows:

Azur II-Eosin	3.0 gm.
Azur II	0.8 gm.
Glycerin c. p.	250.0 c.c.
Methyl alcohol c. p.	250.0 c.c.

The dyes are thoroughly dried over H₂SO₄, finely pulverized, and sifted through a fine-meshed silk sieve; then dissolved by shaking in the glycerin heated to 60° C. To this glycerin solution is added the methyl alcohol also heated to 60° C., the whole thoroughly shaken and allowed to stand for twenty-four hours and then filtered.

The stain is prepared for the market ready for use by Grübler.

For Staining Blood.—1. Air-dried blood smears are fixed for two to three minutes in methyl alcohol and dried off with filter paper.

2. The dye is diluted with water (1 drop of the dye to about 1 c.c. of distilled water). The water may to advantage be warmed to 30° to 40° C.

3. Pour the freshly diluted dye over the smear and stain for ten to fifteen minutes.

4. Wash off in water jet.

5. Dry partially with blotting paper and then in the air. Mount in balsam.

For Staining Tissues.—For staining tissues the following method of Schridde² may be useful.

1. Five micra paraffin sections are stained for twenty minutes in a mixture of two drops of Giemsa's solution and 1 c.c. of water.

2. Washed carefully in water.

3. Dried off with blotting paper.

4. Transferred immediately to anhydrous chemically pure neutral acetone.

5. Transferred to xylol. Mounted in neutral dammar.

UNNA'S POLYCHROME METHYLENE-BLUE STAIN.—This is prepared for the market by Grübler. The formula for its use given by Mallory and Wright is as follows:

1. Stain paraffin or celloidin sections hardened in alcohol in polychrome methylene-blue five to ten minutes or longer.

2. Wash in acidulated water.

¹ Giemsa, *Centbl. f. Bakt., Abth. I., Orig. Bd. xxxvii., p. 308, 1904.*

² Schridde, *Cent. f. allg. Path., Bd. xvi., p. 769, 1905.*

3. Fix in 10-per-cent. solution of bichromate of potassium half a minute.
4. Wash in water.
5. Dry on slide with filter-paper.
6. Decolorize in anilin plus 1-per-cent. hydrochloric acid (a few seconds only).
7. Wash off with oil of bergamot.
8. Balsam.

THIONIN.—Thionin is especially useful as a stain for mucin. In the following—Hoyer's formula—the mucin is colored red, the remaining tissue blue.

1. Harden in corrosive sublimate, followed by alcohol.
2. Paraffin sections are passed through xylol, chloroform, and 95-per-cent. alcohol to free them from paraffin, and are then placed in a 5-per-cent. aqueous solution of corrosive sublimate for three to five minutes.
3. Stain in a dilute solution of thionin for ten to fifteen minutes.
4. Alcohol.
5. Clear in the mixture of the oils of cloves and thyme.
6. Turpentine oil or oil of cedar.
7. Balsam.

The sublimate should not be removed from the tissues by iodine, as is usual as a preliminary to staining.

Thionin is useful for the staining of exudates, frozen sections, etc. It may be kept in a stock saturated aqueous solution to be variously diluted as used.

Methods of Preserving Specimens for Gross Demonstration and for Museums.

When specimens of abnormal tissues or organs are to be preserved entire for exhibition in jars in a museum, the superfluous parts are first removed and the requisite dissections made. Then they are carefully placed in the position and form which it is wished to preserve, by stuffing with horsehair or absorbent cotton and by the use of thread. When thus carefully adjusted they are either suspended or laid on a wad of absorbent cotton in 60- to 80-per-cent. alcohol or in 5-per-cent. formalin solution. In this they usually become hard, and finally, after the removal of the temporary stuffing and braces, are transferred for permanent exhibition to fresh, clear, 80-per-cent. alcohol, or, in case of formalin hardening, to a fresh solution of the formalin, to which, if the jar is likely to be exposed to cold, a little glycerin is added to prevent freezing. This description applies especially to such specimens as have cavities to distend or display.

The more simple specimens, such as the solid viscera, tumors, etc., may be washed and hardened in 60-per-cent. alcohol or in formalin solution.¹

¹For a method of preparing thick serial sections of brain for permanent preservation in formalin and gelatin see *Mankowsky*, *Cbl. f. Path.*, Bd. xvii., 1906, p. 467. Also, for the method of preserving sections and whole structures for exhibition in gelatin see *Watters*, *Medical Record*, vol. lxx., p. 985, 1906.

In many cases an excellent hardening is obtained by injecting the preservative fluid through the blood-vessels. The lungs are well hardened by pouring the fluid through the trachea into the air spaces.

Firm-walled cysts of various kinds are well preserved in a condition of distention by drawing off the natural contents through a fine cannula and refilling with, and immersing in, formalin solution. Delicate *cysts*, such as echinococcus cysts, small embryos in their membranes, cystic kidneys, etc., may be preserved in a nearly natural condition in formalin.¹

Kaiserling's Method of Fixing Natural Colors in Museum Specimens.²

1. Fixation for one to five days in:

Formaldehyde	200 c.c.
Water	1000 c.c.
Nitrate of potassium.....	15 gm.
Acetate of potassium	30 gm.

Change the position of the specimen frequently. The time of fixation varies with the tissue or organ and size of the specimen.

2. Drain and place in 80-per-cent. alcohol one to six hours, and then in 95-per-cent. alcohol for one to two hours, to restore the color, which is somewhat affected in the fixing solution.

3. Preserve in:

Acetate of potassium	200 gm.
Glycerin	400 c.c.
Water	2000 c.c.

Since exposure to light reduces the color contrasts, the specimen should be prepared and kept in the dark.

The Importance of Careful Fixation and Preservation.

We would most urgently commend to the reader the importance of putting pathological specimens, which are to be hardened and subsequently examined microscopically, at the earliest possible moment into the preservative fluids, *which should always be abundant*. Furthermore, when specimens are large it is very desirable to cut them open, so that the fluids may come into direct contact with the tissues. It should be borne in mind that immediately after death or the removal of parts from the body, especially in warm weather, changes commence in the tissues and progress very rapidly, so that in some cases a few hours' or even a few moments' delay will not only render subsequent microscopical examinations difficult and unsatisfactory, but may lead to serious errors. Alcohol and 10-per-cent. formalin are the most generally useful agents. *Carbolic acid and glycerin should not be used, even for the temporary preservation of fresh tissue*. They not only do not harden and preserve the

¹ For the technique of the clearing method by potassium hydroxid in the demonstration of ossification centres, distribution of blood-vessels, etc., see *Hill*, Johns Hopkins Hosp. Bull., vol. xvii., p. 111, 1906.

² See *Mallory and Wright*, "Pathological Technique," 1901, p. 360.

tissue elements, but they—especially glycerin—render them almost useless for microscopic examination.

The not uncommon practice of wrapping a specimen in a cloth soaked in alcohol or carbolic acid, and permitting it to remain in this for hours or days, is of no use whatever in preserving specimens of which microscopic examinations are to be made. Almost equally useless is the too common practice of placing a specimen in a bottle which it nearly fills, and pouring a little preservative fluid around it. Not only should the proper fluids be used, but these should be abundant, and the specimen so prepared and arranged that they may come into direct contact with it.

INDEX.

- Abbott and Gildersleeve*, on acid-fast bacteria, ref., 267
- Abdomen, examination, post-mortem, of, 1001, 1025
- Abdominal pregnancy, 842
viscera, position of, 1002
- Abel*, on suprarenal body, 434
- Abel and Davis*, on skin pigment, ref., 55
- Abramow*, on blood-vessel changes in syphilis, ref., 274; on peritonitis, ref., 694; on syphilis of blood-vessels, ref., 567
- Abrin poisoning, 153; ref., 203; 425
- Abscess, 89, 200
metastatic, 204
nature of, 199
of bone, 885, 888
brain, 964
heart, 538
kidney, 754
liver, 722
lung, 611
mamma, 844
muscle, 873
prostate, 866
spleen, 504
testicle, 857
repair of, 203
retropharyngeal, 648
splenic, 504
tropical, of liver, 722
- Absorption, 23
from peritoneum, 694
- Acardiacus acephalus*, 328
- acornus*, 328
amorphus, 328
anceps, 328
- Acarus scabiei*, 132
- Achard and Phulpin*, on terminal infection, ref., 158
- Achondroplasia, 896
- Achorion Schönleinii, 148
- Achromatic figure in mitosis, 66
- Acid, arsenious, 420
carbolic, 423
carbonic, 425
hydrochloric, 418
hydrocyanic, 423
nitric, 418
oleic, 44
osmic, as hardening fluid, 1029
oxalic, 419
sulphuric, 317
tartaric, 419
- Aconite poisoning, 425
- Acrania, 324, 927
- Acromegalia, 438
- Actinomyces, 136
bovis, 231
in lung, 612
- Actinomycosis, 230
of appendix, 691
brain, 976
intestine, 691
- Adamantinoma, 415
- Adami*, on arterio-sclerosis, ref., 565, 566; on blood in septicæmia, ref., 205; on dissecting aneurism, ref., 568; on heredity, ref., 14; on hypertrophy, ref., 62; on infection, ref., 151; on inflammation, 110; on inflammation and fibrosis, ref., 96; on mitosis, ref., 67; on retroperitoneal lipoma, ref., 697; on reversion, ref., 63
- Adami and Aschoff*, on myelins, ref., 44
- Adaptation, 8
of animals to alien substances, 195
- Addison's disease, 433
internal secretions of adrenals in, 434
- Adenitis, 483
- Adeno-carcinoma, 398
of uterus, 814
- Adeno-cystoma of ovary, 830
- Adenoids, 581, 648, 649, 650

- Adenoma**, 395, 398
 fibro-, 365
 of adrenals, 517
 Bartholin's glands, 795
 bladder, urinary, 788
 bronchi, 591
 gall-ducts, 743
 intestine, 690
 kidney, 776
 larynx, 585
 liver, 735
 lung, 635
 mamma, 849
 mouth, 645
 œsophagus, 653
 ovary, 830
 pancreas, 706
 pituitary body, 980
 prostate, 866
 stomach, 663
 testicle, 861
 uterus, 814
Adeno-sarcoma, 376
Adler, on gumma of heart, ref., 542; on emigration of leucocytes, ref., 86; on reaction of blood, ref., 453; on tumors of lung, ref., 636
Adler and Meltzer, on lymph-vessels, 576
Adrenalin, degeneration of heart muscle after injections of, ref., 541
Adrenals, 515
 accessory, 515
 atrophy of, 515
 degeneration of, 515
 examination, post-mortem, of, 1013, 1026
 fat infiltration of, 515
 hæmorrhage in, 516
 hypertrophy of, 62
 in Addison's disease, 433
 inflammation of, 516
 malformations of, 515
 myelin substances in, 515
 pigmentation of, 516
 preservation of, 1013
 size of, 1013
 syphilis of, 516
 thrombosis of, 516
 tuberculosis of, 433, 516
 tumors of, 517
 weight of, 1013
Ærobes, facultative, 137
 obligate, 137
Afanassieff, on granulation tissue, ref., 152
Age, relation of, to disease, 13
 relation of, to tumor growth, 344
Agnesia, 321
Agglutination, 179
 group, 180
 of streptococci, ref., 210
 test, 180
 technique of, 193
Agglutinative substances, 179
Agglutinins, 179
 in typhoid fever, 246
Aggressins, 153
Agnathia, 321
Ague cake, 505
Ahlfeldt, on cysts of placenta, ref., 826
Air emboli, 34
 in blood, 470
 blood, in caisson disease, 11
 pericardium, 518
 pleural cavities, 637
 micro-organisms in, 140, ref., 150
 supply, relation of, to disease, 9
Akerland, on membranous colitis, ref., 682
Albert, on trichiniasis, ref., 130
Albrecht, on albuminous degeneration, ref., 40; on myelogenous substances in cells, ref., 40; on origin of tumors, ref., 353.
Albumen film for fixing specimen to slide, 1028, 1034
Albuminous degeneration (see Degeneration, albuminous), 39
Albuminuria, 749
Alcohol as tissue fixative, 1029
 poisoning, 423
Alcoholism, chronic, atrophy of brain in, 932
 meningitis in, 917
 œdema of brain in, 913
Aleuronat exudates, 195
Alexander, on adrenals, ref., 515
Alexines, 109, 161, 170, 172
Aloes poisoning, 422
Amboceptor, 177
Amitosis, 65, 67
Ammonia poisoning, 419
Amœba dysentericæ, 115
 colitis, 676
 in liver abscess, 723
Amyelia, 928

- Amyloid, 47
 degeneration (see Degeneration,
 amyloid), 48
 masses in larynx and trachea, 586
 technique of staining, 50
 tests for, 50, 1012
 tumors of larynx and trachea, 586
 of tongue, 646
- Anæmia, 16, 19, 454
 aplastic, 474
 chlorotic, 471
 bone marrow in, 897
 infantum pseudo-leukæmica, 479
 local, 19
 marrow changes in, 897
 of brain, 934
 kidney, 748
 lung, 593
 liver, 709
 spleen, 501
 pernicious, 473
 phagocytosis in, after transfu-
 sion, 185
 secondary, 472
 splenic, 479
 Von Jaksch, 479
- Anaerobes, facultative, 137
 obligate, 137
- Anaphylaxis, 190
- Anaplasia in tumors, 351
- Anasarca, 22
- Anastomosis of blood-vessels, 18
- Anders*, on tuberculosis of heart, ref., 542
- Anderson*, on B. tuberculosis in blood,
 ref., 264
- Anderson and Goldberger*, on infective
 agent in Mexican typhus, 301
- Anderson and Rosenau*, on anaphylaxis,
 ref., 190
- Anencephalia, 325, 927
- Aneurism, 567
 cirroid, 569
 conditions leading to, 567
 cylindrical, 567
 dissecting, 568
 false, 568
 fusiform, 567
 miliary, 571
 multiple, 567
 mycotic, 567
 of aorta, 570
 brain, 936, 981
 cerebral arteries, 936
- Aneurism of coronary arteries, 570
 heart, 529
 heart valves, 530
 pulmonary arteries, 570
 splenic artery, 500
 sacculated, 567
 spurious, 568
 varicose, 569
- Aneurismal varix, 569
- Angina (see Pharyngitis), 648
 diphtheroid, 212
 membranous, 212
 Vincent's, 293
- Angio-lipoma, 382
- Angioma, 393
 cavernosum, 394
 hæm-, 393
 lymph-, 393
 of bone, 902
 bladder, urinary, 788
 brain, 977
 choroid plexus, 927
 ependyma, 927
 intestine, 688
 kidney, 776
 larynx, 585
 lips, 645
 liver, 734
 mamma, 848
 mouth, 645
 muscle, 875
 œsophagus, 653
 ovary, 829
 penis, 855
 peritoneum, 697
 spleen, 510
 stomach, 663
 thymus, 511
 tongue, 646
 uterus, 813
 telangiectoides, 393
- Angio-sarcoma, 374
- Anguillula, 131
- Anhydræmia, 454
- Anilin-blue stain, 1036
 dyes for bacteria, 143
 gentian-violet stain for bacteria, 143
- Animal, infectious diseases of, 319;
 also ref., 157
 parasites, 114
 species, relationships of, blood test
 in, 172
 venom, 424

- Ankylostoma duodenale, 128, 472
 Anopheles in malaria, 314
Anspach, on teratoma of ovary, ref., 837
 Anterior horn, myelitis of, 967
 Anthracosis of lung, 616
 Anthrax, 228
 bacillus, 229
 of intestine, 691
 Antiamboceptor, 177
 Antibodies, 175
 Anticytolysins, 175
 Anticytotoxins, 175
 Antiformin in sputum examinations, 260
 Antigen, 175
 Anti-immune substances, 177
 Anti-precipitin, 182
 Antitoxin, 164
 Asiatic cholera, 250
 definition of, 167
 diphtheria, 164, 285
 unit of, ref., 164
 plague, 289
 streptococcus, 211
 tetanus, 165, 287
 unit, ref., 164
 Antivenins, 424
 Anus, atresia of, 667
 Aorta, aneurism of, 570
 double, 522
 examination, post-mortem, of, 1018
 hypoplasia of, 439, 556
 insufficiency of, 552
 malformations of, 522
 rupture of, 557
 stenosis and obliteration of, 552, 571
 tuberculosis of, 567
 Aphthæ, 644
 Aplasia, 321
 Apoplectic foci in brain, 936
 Apoplexy, 21
 cerebral, 935
 of brain, 935
 placental, 823
 serous, of brain, 935
 spinal, 938
 Appendicitis, 684
 Appendix vermiformis, 684
 absence of, 667
 actinomycosis of, 691
 bacteria in, 687
 concretions in, 686
 cysts of, 686
 dilatation of, 686
 Appendix, diverticula of, 668
 foreign bodies in, 686
 gangrene of, 685
 in typhoid fever, 685
 inflammation of, 684
 inversion of, 688
 necrosis of, 685
 obliteration of lumen of, 686
 strictures of, 686
 tuberculosis of, 686
 tumors of, 690
 Arachnoid (see Pia mater), 912
 Argyria, 56
Arnaud, on Addison's disease, ref., 516
Arnold, on diapedesis, 21; on fibrin formation, ref., 86; on iron pigment in cells, ref., 616; on lymph-nodes, 481; on polyps of pharynx, ref., 650; on sarcoma of liver, 737; on weight of heart, ref., 1008
Arnsperger, on dermoid cysts of ovary, ref., 836
 Arsenic poisoning, 420
 Artefacts of nervous system, ref., 928, 929, 999
 Arteries, aneurism of, 567, 570
 atheroma of, 562
 calcification of, 559
 cerebral, aneurisms of, 936
 embolism of, 31, 942
 thrombosis of, 942
 coronary, aneurism of, 570
 distribution of, ref., 537
 embolism of, 538
 endarteritis of, 537
 examination, post-mortem, of, 1008
 fibrous nodules on, 521
 infarction of, 538
 lesions of, 537
 sclerosis of, 537
 thrombosis of, 537
 cysts, atheromatous, of, 561
 degeneration of, 557
 emboli in, 571
 hepatic, lesions of, 711
 inflammation of (see Arteritis), 559
 of brain and cord, 933
 pulmonary, aneurism of, 570
 embolism and thrombosis of, 596
 renal, embolism and thrombosis of, 749
 rupture of, 557

- Arteries, sclerosis of, 559
 syphilis of, 567
 terminal, embolism of, 29
 tuberculosis of, 566
 tumor emboli in, 571
 tumors of, 571
 wounds of, 557
- Arterio-sclerosis, 559
 classification of, 565
 conditions leading to, 564
 relation to heart hypertrophy, 554
 kidney lesions, 769
- Arteritis, acute, 559
 chronic, 559
 embolic, 559
 end-, 559
 peri-, 559, 566
 syphilitic, 567
 thrombo-, 559
 tuberculosis, 556
- Arthritis, 903
 chronic, 904
 deformans, 905
 exudative, 903
 gonococcal, 904
 gouty, 905
 pneumococcic, ref., 904
 rheumatic, 904
 sero-fibrinous, 904
 serous, 903
 suppurative, 904
 tuberculous, 906
 uritica, 905
- Arthropathy, hypertrophic pulmonary,
 ref., 438
- Arthropoda, 132
- Ascarelli*, on adipocere, ref., 987
- Ascaris* in liver, 739
 pancreatic duct, 707
 lumbricoides, 127
 maritima, 128
 mystax, 128
- Asch*, on excretion of bacteria by kidney,
 ref., 755
- Aschoff*, on compensatory hypertrophy,
 ref., 79; on cysts, ref., 361; on im-
 munity, 196; on tumors, 416
- Ascites, 23, 692
- Ascospores, 146
- Ashton, Norris, and Larenson*, on Stokes-
 Adams' disease, ref., 550
- Asiatic cholera, 247
- Askanazy*, on pigment, ref., 53
- Aspergillus*, ref., 147
 glaucus, 148
- Asphyxia, 9, 442
- Ataxia, cerebellar, 963
 Friedrich's, 963
 hereditary, 963
 locomotor, 957
- Ataxic paraplegia, 962
- Atelectasis of lung, 596
- Atelomyelia, 928
- Atheroma, 561
- Atlassoff*, on experimental typhoid fever,
 ref., 235
- Atrophia musculorum lipomatosa, 871
- Atrophy, 36
 acute yellow, of liver, 716
 experimental, 718
 brown, 38, 56
 of heart, 38, 529
 degenerative, 37
 disuse, 38
 general from malnutrition, 38
 neurotic, 39
 of adrenals, 515
 blood-vessels, 556
 bone, 876
 brain, 932
 heart, 528
 liver, 714, 716
 lymph-nodes, 481
 muscle, 868, 871
 pancreas, 702
 prostate, 863
 spleen, 500
 stomach, 656
 testicle, 857
 uterus, 803
 pigment, 714
 pressure, 38
 progressive muscular, 869, 955
 senile, 38
 simple, 36
- Atresia ani, 667
- Attraxine, 352
- Auer and Lewis*, on anaphylaxis, 191
- Auerbach*, on B influenzae, 234
- Aufrecht*, on experimental pneumonia,
 ref., 614
 on portals of entry of *B. tubercu-*
losis, ref., 264
- Auriculo-ventricular bundle of His, 550
- Auto-digestion of pancreas, 702
- Autohemolysis, ref., 176

- Auto-intoxication, 153, 417, 426
 Addison's disease as an, 434
 burns as excitants of, 9
 cachexia strumipriva as an, 430
 dyscrasic, 427
 enterogenic, 426
 exophthalmic goitre as an, 432
 gout as an, 436
 retention, 427
- Autolysins, 176
- Autolysis, 60, 98, 106
 in absorption of infarcts, ref., 30
 lung exudates, 557
- Autosite, 332
- Autopsies, making of (see Post-mortem examination), 985
 medico-legal, 1022
 on cases of suspected poisoning, 1022
 new-born, 1023
- Axis-cylinder process, nature of, 944
- Axone, degenerations in, 946
 nature of, 944
- Ayer, on cysts of intestine, ref., 690
- Azur II as a staining agent, 317, 1037
- Babes*, on bacteria in blood of cadaver, ref., 987; on hæmorrhagic infection, ref., 289
- Babesia bovis*, ref., 122
- Bacillus, 134
 acid-proof, 267
 aërogenes capsulatus, 34, 289
 in liver, 738
 anthracis, 228, 229
 immunization to, 230
 botulinus, 292
 cholerae gallinarum, 289
 coli communis, 214, 246
 conjunctivitis, 234
 diphtheria, 282, 283
 action of, in animals, 284
 branching forms of, ref., 284
 characters of, 284
 communicability of, 285
 pseudo-, 285
 diplo-, 135
 Ducrey's, 228
 dysenteria, 247, 677
 enteritidis, 291
 Friedlander, 216
 gas, 289
 glanders, 226
 grass, 267
- Bacillus*, hæmorrhagicus, 289
 septicus, 289
 venenosus, 289
- hay, 267
- Hoffmani, 285
- icteroides, ref., 302
- influenza, 233
- Koch-Weeks, 234
- lepræ, 269
- mallei, 226, 227
- toxic products of, 227
- mucosus capsulatus, 216
- œdematis maligni, 291
- of Shiga, 677
 whooping cough, 317
- paratyphosus, 247
- pestis, 288
- plague, 288
- proteus group of, 216
- proteus vulgaris, 217
- pseudodiphtheria, 285
- pseudo-influenza, 234
- pseudo-tetanicus, 287
- pseudo-tuberculosis, 227
 liquefaciens, 227
- pyocyaneus, 215
 in colitis, 678
- rhinoscleromatis, 282
- Shiga's, 247
- smegma, 267
- strepto-, 135
- suisepcticus, 289
- tetani, 286
 toxins of, 286, 287
- tuberculosis, 251, 257
 action of, in body, 262
 antiformin in examination of, 260
 bovine type, ref., 266
 branching forms of, ref., 257
 dead, action of, 260
 differentiation of, 267
 distribution of, 264
 in dried sputum and dust, 265
 methods of staining, 258
 numbers of, in lesions, 263
 portals of entry of, 264, 618
 sources of, 265
 toxic products of, 260
 varieties of, 260
- typhi murium, 289
- typhosus, 234, 235
 agglutination of, 246

- Bacillus*, typhosus, carriers, 245
 differentiation of, 246
 distribution of, in body, 244
 methods of staining, 246
 modes of infection with, 245
 viability of, 245
 Welchii, 289
 "X," ref., 302
 xerosis, 285
Bacmeister, on myoma of heart, ref., 556
Bacteria, 133
 absorption of, in peritoneum, 694
 acid-resisting, 267
 action of alexins on, 161
 cold and heat on, 137
 germicides on, 138
 in body, 152
 adaptation of, ref., 160
 aërobic, 137
 aërogenic, 139
 agglutination of, 179
 aggregations of, 135
 aggressins of, 153
 anaërobic, 137
 as disease excitants, 198
 attenuated cultures of, 162
 capsules of, 133
 chemotaxis in, 137
 chromogenic, 139
 classification of, 142
 clostridium forms, 134
 commensals in, 141
 cultivation of, 145
 cultures of, 145
 destruction of, by phagocytes, 161
 destruction of, in body, 170
 disposal of in blood, 151
 distribution of, 140, 150
 elimination of, through secretions,
 151
 endotoxins of, 139
 enzymes of, 139
 etiological relationships of, 154
 examination of specimens, post-
 mortem, for, 1021
 fermentation and, 139
 filamentous, 135
 flagella of, 133
 forms of, 134
 functional characters of, 142
 gas-producing, 139
 growth of, conditions of, 137
 hæmolysins of, ref., 153
Bacteria, higher, 135
 in air, 140, 150
 appendix vermiformis, 687
 bladder, urinary, 786
 blood, ref., 470
 post-mortem, 987
 body, 150
 dust, 140
 fluids, stains for, 143
 heart, 539
 inflammation, 152
 intestine, 678, 681
 kidney, 755, 761
 lung, 601, 614
 lymph-nodes, 481
 mouth, 646, ref., 647
 of children, ref., 647
 nose, 580
 soil, 140
 spleen, 511
 stomach, ref., 659
 suppuration, 201
 tissues, stains for, 143
 tumors, 347
 vagina, 797
 water, 141
 infective nature of, proofs of, 153
 insects as carriers of, 151
 insusceptibility to, 160
 involution forms, 134
 life of, conditions of, 137
 messmates in, 141
 metabolism of, 138
 metachromatic granules in, 134
 monomorphism in, 136
 motility of, 137
 multiplication of, 134, 137
 nutritional requirements of, 137
 opsonins of, 183
 parasitic, 141
 phagocytosis of, 183
 photogenic, 139
 pleomorphism, 136
 poisons of, 139, 152
 polymorphous, 135
 portals of entry of, 151
 products of, in body, 152
 protection of body against, 151
 ptomains of, 139
 pyogenic, 205
 relationships of, 141
 reproduction of, 134
 rod-like, 134

- Bacteria**, rôle of, in nature, 140
 saprophytic, 141
 species of, 142
 spheroidal, 134
 spiral, 134
 spores in, 136
 staining of, 143
 sterilization of, 137
 study of, morphological, 143
 symbiosis of, 142
 thermophilic, 138
 toxins of, 139, 152
 ultramicroscopic, ref., 134
 variations in, 136
 varieties of, 142
 zymogenic, 139
- Bacteriæmia**, 203
- Bacteriolysis**, 170, 173
- Bacterio-opsonins**, 184
- Bacterio-protein**; 152
- Bacteriotropic substances**, 184
- Baer**, on typhoid ulcers, ref., 240
- Baginsky**, on pseudo-membranous inflammation, ref., 212
- Bail**, on aggressins, 153; on disposal of bacteria in blood, ref., 151
- Bailey**, on lesions in hydrophobia, ref., 294
- Bailey and Ewing**, on Landry's paralysis, 969
- Bailey and Miller**, on embryology, ref., 320
- Balanitis**, 854
- Balantidium coli**, 120
- Baldauf**, on carcinoma of appendix vermiformis, ref., 690
- Baldwin**, on anæmic infarcts of liver, ref., 711
- Ballantyne**, on antenatal pathology, ref., 320; on congenital infection, ref., 151
- Banti**, on splenic anæmia, 479
- Bardeen**, on visceral changes following burns, ref., 10
- Barker**, on nervous system, ref., 942
- Barlow's disease**, ref., 438
- Bartel and Spieler**, on experimental tuberculosis, ref., 264
- Bartel and Stein**, on lymph-nodes in status lymphaticus, ref., 440
- Bartholin's glands**, cysts of, 795
- Basedow's disease**, 432
- Bashford**, on tumor transplantation, ref., 354
- Bashford and Murray**, on mitosis in tumors, ref., 351; on statistical investigation of cancer, ref., 353
- Basophile cells**, 461
- Bassoe**, on blastomycosis, ref., 146
- Batten**, on nerve lesions in diphtheria, ref., 283
- Baumgarten**, on coronary arteries, ref., 537; on portals of entry of *B. tuberculosis*, ref., 264; on tissue formation by endothelium, ref., 73; on urogenital tuberculosis, ref., 770
- Bayer**, on regeneration of lymph-nodes, 76
 "Beaker cells," 46
- Beck**, on *B. influenzae*, ref., 233; on toxins of *B. diphtheriæ*, ref., 284; on rhabdomyoma, ref., 861; on bacteria in lungs, ref., 614
- Beebe and Ewing**, on lympho-sarcoma of dogs, ref., 349, 369
- Beer**, on accessory adrenals, ref., 515; on atrophic glomerular cysts, ref., 767; on false diverticula of intestine, ref., 668
- Behring**, on portal of entry of *B. tuberculosis*, ref., 264
- Beitzke**, on cervical and bronchial lymph-nodes, ref., 592; on cervical and bronchial lymph-nodes in tuberculous infection, ref., 650; on mode of infection in pulmonary tuberculosis, ref., 264
- Bence Jones' proteid**, 902
- Benda**, on origin of miliary tuberculosis, ref., 620
- "Bends," the, 11
- Bennecke**, on angioma of intestine, ref., 688
- Beri-beri**, 318
- Berkeley**, on mosquitoes, ref., 316
- Berkeley and Beebe** on parathyroids, 514
- Bernheim and Gruber**, on mixed infections, ref., 157
- Berry**, on appendicitis, 688
- Bertarelli**, on animal inoculations in syphilis, ref., 274
- Bertarelli, Volpino, and Bovero**, on silver impregnation method, ref., 277
- Berthenson**, on tumors of heart, ref., 556
- Bettmann**, on bronchitis, ref., 589
- Bezaçon and Labbé**, on germicidal action of lymph-nodes, ref., 151
- Biedl and Kraus**, on elimination of bacteria, ref., 151; on bacteria in kidney, ref., 761

- Bierring and Egdahl*, on splenectomy, ref., 479
- Biggs*, on aortic aneurism, ref., 570
- Biland*, on cysts of placenta, ref., 826
- Bile-ducts, lesions of (see Gall-ducts), 740
- Bilirubin, 55
- Billings*, on infectious endocarditis, ref., 547
- Billings and Capps*, on myelogenous leukæmia, ref., 477
- Binder*, on congenital liver cirrhosis, ref., 730
- Biogen, 3
- Biophore, 3
- Birch-Hirschfeld*, on intestine as portal of entry for bacteria, 694
- Birt and Lamb*, on *Micrococcus melitensis*, ref., 288
- Bizzozero*, on tissue regeneration, 64
- Black death, 288
- Black leg, 291
- Bladder, circulation in, study of, 111
 gall (see Gall-bladder), 740
 urinary, 781
 circulation in, 111
 cysts of, 788
 dilatation of, 782
 diverticula of, 782
 examination, post-mortem, of, 1018, 1026
 extroversion of, 781
 foreign bodies in, 789
 hæmorrhage of, 783
 hernia of, 782
 hyperæmia of, 783
 hyperplasia of epithelium of, 784
 hypertrophy of, 782
 inflammation of (see Cystitis), 783
 malformations of, 781
 malpositions of, 782
 mucosa, repair of, ref., 71
 parasites of, 789
 perforation of, 783
 preservation of, 1013
 regeneration of mucous membrane in, 784
 rupture of, 782
 size of, 782, 1012
 study of inflammation in, 83
 tuberculosis of, 786
 tumors of, 786
- Bladder, urinary, weight of, 1012, 1026
 wounds of, 782
- Blastomycetes, 133, 146
- Blastomycosis, generalized, 147
- Blastomycotic dermatitis, 146
- "Bleeders," 22
- Blennorrhœa, 199
- Block and Hall*, on dermoid cyst of bladder, ref., 788
- Bloq and Marinesco*, on Friedrich's ataxia, ref., 963
- Blood, 452
 abnormal, leucocytes of, 461
 air in, 34, 470
 in caisson disease, 11
 alterations of, favoring thrombosis, 25
 amount, determination of, 455
 anæmia, 454
 aplastic, 474
 infantum pseudo-leukæmica, 479
 pernicious, 473
 secondary, 472
 splenic, 479
 Von Jaksch, 479
 anhydræmia, 454
 B. tuberculosis in, in pulmonary tuberculosis, ref., 618
 bacteria in, ref., 470
 capillaries, lesions of, 575
 carbonic oxide, effects of, on, 425
 cells, red, 456
 agglutination of test for, 194
 alterations in morphology of, 457
 alterations in number of, 456
 altitude, effect of, on, ref., 458
 defective formation of, 456
 destruction of, 456
 diminution of, 456
 gigantoblasts, 459
 lysis of, 171
 megalocytes, 458
 megaloblasts, 459
 microcytes, 457
 morphology of, 457
 normoblasts, 458
 nucleated, 458
 number of, 456
 opsonins of, 185
 phagocytosis of, 185
 poikilocytes, 457
 regeneration of, 77

- Blood cells, white, (see Leucocytes), 459**
 changes in circulation of, 15
 chloroma, 478
 chlorosis, 471
 circulation of, 15, 83
 circulation of, study of, in living
 animal, 111
 clots, forms of, 452
 coagulability of, 452
 crises, 458, 474
 diseases of, 471
 erythræmia, 455
 examination of, 316, 466
 extravasation of, 20
 fat in, 469
 fixed, examination of, in malaria,
 316
 foreign bodies in, 469
 forming organs, lesions of, 471
 fresh, examination of, in malaria,
 316
 frothing of, in caisson disease, 11
 gas in, 34
 hæmatogenesis, defective of, 457
 hæmoglobin, free, in, 454, 456
 index, 474
 hydræmia, 454
 in malaria, 310
 methods of examination
 of, 316
 septicæmia, ref., 235
 typhoid fever, 463
 laking of, 171
 leucocytes of, 459, 461
 leucocytosis, 462
 leukæmia, 475
 melanæmia, 470
 normal, leucocytes of, 459
 oligocythæmia, 454, 456
 parasites in, 470
 pigment, 53, 470
 test for, ref., 53
 plates, 465
 plethora, 455
 polycythæmia, 454
 precipitin test for, 181
 reaction of, 453
 regeneration of, 77
 relationships, 172
 staining of, 468
 sugar in, 13
 transudation of, 22
 tubercle bacilli in, 264
- Blood, typhoid bacilli in, 244**
 water of, 454
Bloodgood, on blood supply and tubercu-
 lous lesions in bone, ref., 888; on cysts
 of bone, ref., 903
Blood-vessels, anastomosis of, 18
 aneurism of, 570
 atrophy of, 556
 changes in walls of, 15
 embolism of, 28
 formation of, 75
 hypertrophy of, 557
 hypoplasia of, 556
 in frog, 113
 tumors, 338
 lesions of, in pulmonary tubercu-
 losis, 629
 relations of, to circulation, 15
 sclerosis of, 559
 conditions leading to, 564
 thrombosis of, 24
Blumenthal, on reaction of body in infec-
 tion, ref., 156
Blumer, on bacteriology of lobular pneu-
 monia, ref., 613; on tuberculosis
 of arteries, ref., 567; on tubercu-
 losis of stomach, ref., 659
Blumer and Laird, on hæmorrhagic septi-
 cæmia, ref., 291
Blumer and MacFarlane, on noma, ref.,
 794
**Body, cooling of, as predisposing to in-
 fection, ref., 614**
 cooling of, post-mortem, 988
 fluids, in inflammation, 108
 nature of living, 3
 safeguards of, against infection, 150
Boils (see Furuncle) 199
Bone, 876
 abscess of, 885, 888
 absorption of, 883
 achondroplasia, 896
 anæmia of, 897
 atrophy of, 876
 caries of, 891
 cells of, 876
 cysts of, 903
 decalcification of, 897, 1031
 enostoses, 899
 examination, post-mortem of, 1024,
 1026
 exostoses, 386, 899
 formation, new, of, 881

- Bone formation, dura mater, 922
 muscle, 874
 pia mater, 921, 923
 fractures of, 877
 general considerations, 876
 hæmorrhage of, 877
 healing of fractures of, 877
 hyperæmia of, 877
 hyperostosis, 900
 inflammation of (see Osteitis and Periostitis), 878
 lesions after typhoid fever, 243
 marrow in leukæmia and anæmia, 897
 in malaria, 311
 pigmentation of, 877
 regeneration of, 76
 necrosis of, 889
 new-formed, 387
 osteomalacia, 896
 osteophytes of, 881, 899
 phosphorus necrosis of, 890
 rachitic, 891
 regeneration of, 76, 877
 rickets, 891
 sclerosis of, 885
 sequestrum in, 890
 softening of, 896
 syphilis of, 881, 888
 transplantation of, 78
 tuberculosis of, 882, 887
 tumors of, 899
 ulceration of, 891
 wounds of, 877
- Bordet*, on immunity, 196
Bordet and Gengou, on bacillus of whooping-cough, 317; on fixation of complement, 189
Borrmann, on carcinoma of stomach, ref., 666; on metastasis in tumors, ref., 342
Borst, on pathological organization, ref., 110; on squamous epithelioma of stomach, ref., 666; on tumors, 416; on tumors of sacral region, ref., 359
Bostroem, on cholesteatomata, ref., 379; on tumors of pia mater, ref., 920
Bothriocephalus cordatus, 127
 cristatus, 127
 latus, 127, 472
Bottomley, on operative treatment of tuberculous peritonitis, ref., 696
Botulism, 291
Bovaird, on human and bovine tubercu-
 losis, ref., 266; on primary splenomegaly, ref., 508; on tuberculous bronchial lymph-nodes, ref., 487
Bovaird and Nicoll, on weight of thymus, ref., 511; on weight of viscera in infancy, ref., 990
Bradley, on cysts of thyroid, ref., 514
 Brain, 927
 abscess of, 964
 absence of, 927
 actinomycosis of, 976
 anæmia of, 934
 anencephalia, 325, 927
 aneurism, miliary, of, 936, 981
 apoplectic foci in, 936
 apoplexy of, 935
 serous, 935
 arteries of, 933
 atrophy of, 932
 blood-vessels, lesions of, 942
 cephalocele, 928
 circulatory changes in, 933
 cyclopia, 325
 cysts of, 979
 degeneration of, 940, 942
 neurone, 946
 primary, 955
 secondary, 953
 dissection, methods of, 993, 996
 embolism of, 940
 encephalocele, 928
 examination, post-mortem, of, 992
 fixing and hardening methods, 999
 hæmorrhage in, 935
 hernia of, 928
 holes in, 979
 hydrencephalocele, 928
 hydrocephalus, 927
 hydromeningocele, 928
 hyperæmia of, 934
 hypertrophy of, 931
 inflammation of (see Encephalitis), 964
 injuries of, 930
 lesions of, in Asiatic cholera, 248
 general paresis, 972
 malaria, 311, 312
 malformations of, 324, 927
 mantle, demonstration of, 997
 method of opening, 993, 996
 Meynert's method of opening, 996
 microcephalia, 928
 morphology of, 942

- Brain, nev.-born, 1024**
 weight of, 1025
 œdema of, 934
 parasites in, 979
 pigmentation of, 933
 porencephalus, 979
 preservation of, 998
 removal, post-mortem, of, 992
 in hydrocephalus, 1024
 sand, 376, 910, 912, 920, 927
 sclerosis of, 971
 softening of, 940, 964
 structure of, 942
 syphilis of, 975
 thrombosis of, 940
 tuberculosis of, 918, 974
 tumors of, 976
 vascular changes in, 933
 ventricles, nature and lesions of, 924
 tumors of, 927
 vessel walls, lesions of, 942
 weight of, 993, 1025
- Branchial fistulæ and cysts, 647**
Braunwarth, on cysts of kidney, ref., 774
Breasts (see Mamma), 842
Breus, on cysts of uterus, ref., 813
Brewer, on infection of kidney after injury, ref., 152; on inversion of appendix vermiformis, ref., 688
Brieger and Ehrlich, on degenerations in spinal cord, 948
 Bright's disease (see Nephritis), 753
Brigidi and Piccoli, on persistent thymus and Hodgkin's disease, ref., 511
Brill and Libman, on calcification of liver, ref., 722
Brill, Mandelebaum, and Libman, on primary splenomegaly, ref., 508
Brinckerhoff, on leprosy in the United States, ref., 270
Brinckerhoff and Tyzzer, on experimental smallpox in monkeys, ref., 306
- Bronchi, 586**
 calcification of, 592
 casts of, 589
 dilatation of, 589
 examination, post-mortem, of, 1009
 hæmorrhage of, 586
 inflammation of (see Bronchitis), 586
 lung stones in, 592
 occlusion of, 591
 preservation of, 1010
 syphilis of, 589
- Bronchi, tuberculosis of, 589, 591**
 tumors of, 591
- Bronchiectasia, 589**
- Bronchiolitis, exudativa, 589**
 acute catarrhal, 586
 capillary, 587
 chronic catarrhal, 588
 croupous, 588
 fibrinous, 589
 pseudo-membranous, 588
 purulent, 586
 syphilitic, 589
 tuberculous, 589
- Broncho-pneumonia, 608**
 excitants of, 613
 persistent, 611
 tuberculous, 624
- "Bronze skin," 54
- Brood capsules of tapeworm, 125**
- Brooks*, on acromegalia, ref., 438
- Brosch*, on œsophageal diverticula, ref., 652
 on trauma and formation of malignant tumors, ref., 345
- Brouardel*, on sudden death, ref., 448
- "Brown atrophy," 56
- Brown*, on snake poisons, ref., 424
- Brown and Thiry*, on diphtheritic septicæmia, ref., 284
- Brumpt*, on parasites, 132
- Brunn*, on peritonitis, ref., 696
- Bruns and Kayser*, on agglutinative reactions of colon-typhoid group, ref., 246
- Bubo, 485**
- Buboes, 272**
- Bubonic plague, 288**
- Buchbinder*, on entrance of bacteria through intestine, ref., 694
- Buday*, on cystic adenoma of mamma, ref., 850
- Buerger*, on *S. mucous capsulatus*, ref., 221
- Bunting*, on hæmolysis, ref., 174
- Burnham*, on actinomycosis of appendix, ref., 691
- Burns, death from, 10**
- Busse*, on tumors of kidney, ref., 777
- Butler*, on abnormalities of thoracic duct, ref., 576; on membranous enteritis, ref., 682
- Büttner*, on peritonitis, ref., 694
- Buxton*, on giant cells, ref., 103
- Buxton and Torrey*, on absorption from

- peritoneum, ref., 111; 694; on disposal of bacteria in blood, ref., 151; on removal of alien substances from peritoneal cavity, ref., 99
- Cachexia in tumors, 343**
 strumipriva, 429
- Cadaveric lividity, 986**
- Cæcum, inflammation of, 682**
- Caisson disease, 11**
 congestion of brain in, 934
- Calcareous infiltration, 50**
- Calcification in tissues, 51**
 of arteries, 559
 heart, 535
 kidney, 750, 753
 liver, 722
 muscle, 872
 penis, 855
 placenta, 823
 pleura, 639
 veins, 573
- Calcium carbonate in gall-stones, 744**
 salts in blood, 452
 tissues, 51, 52
 demonstration of, 52
- Calculi, ref., 52, 789**
 biliary, 743
 of appendix, 686
 bladder, urinary, 789
 composition of, 789, 790
 gall-bladder and -ducts, 743
 intestine, 690
 kidney, 774
 pancreatic ducts, 707
 prepuce, 855
 prostate, 866
 seminal vesicles, 863
 tonsil, ref., 649
 tonsillar, 52
- Calkins, on protozoa, ref., 115; on spirochetes, ref., 119; on vaccine bodies, 307**
- Callus in healing bone, 878**
- Calmette and Guerin, on intestinal origin of pulmonary tuberculosis, ref., 264**
- Campbell, on leptothrix, ref., 232**
- Cancer (see Carcinoma), 395, 400**
 bodies, 347
 cell, 402
- Canon, on bacteriology of blood, ref., 470**
- Canon and Pielicke, on excitant of measles, 310**
- Cantharides poisoning, 422**
- Capps, on aneurism of coronary arteries, ref., 570**
- Capsules, blood, of tapeworm, 125**
- Carbolic acid poisoning, 423**
- Carbonic-oxide poisoning, 425**
- Carbuncle, 200, 228**
- Carcino-adenoma, 398**
- Carcinoma, 395, 400**
 and tuberculosis, ref., 267
 alveolar, 414
 characters of, 400
 colloid, ref., 412
 cylindrical-celled, 405, 410
 encephaloid, 412
 epitheliomatous type, 406
 fibro-, 411
 gelatinous, 406, 412
 giant-celled, 410
 medullary, 412
 melano-, 415
 mitosis in, 402
 molle, 412
 myxomatodes, 414
 neuro-, 410
 of adrenals, 517
 appendix vermiformis, 690
 arteries, 571
 bladder, urinary, 788
 bone, 903
 brain, 977
 bronchi, 591
 dura mater spinalis, 922
 gall-bladder and -ducts, 743
 Fallopiian tubes, 841
 heart, 556
 intestine, 690
 kidney, 777
 larynx, 585
 lips, 645
 liver, 736
 lung, 635
 lymph-nodes, 497
 mamma, 850
 mamma, male, 867
 mouth, 645
 muscle, 875
 nerves, 979
 œsophagus, 653
 ovary, 830
 pancreas, 706
 penis, 855
 pericardium, 522

- Carcinoma of peritoneum, 699
 pharynx, 651
 pleura, 642
 prostate, 866
 salivary glands, 701
 seminal vesicles, 863
 spleen, 510
 stomach, 663
 statistics of, 664
 testicle, 861
 thyroid, 514
 tongue, 646
 urethra, 792
 uterus, 815
 vagina, 797
 veins, 575
 ventricles of brain, 927
 vulva, 795
 scirrhus, 411
 serum injections in, 356
 simplex, 406, 411
 squamous, 405
 telangiectoides, 412
 transplantation of, in mice, 356
- Caries of bone, 891
Carlisle, on relapsing fever, 292
 Carotid gland, 517
Carrel, on tissue transplantation, 78
Carrel and Guthrie, on transplantation of organs, ref., 78
Carroll, on mosquito in yellow fever, ref., 303
Carter, on excretion of pigment by kidney, ref., 755; on mosquito in yellow fever, ref., 303
 Cartilage in pia mater spinalis, 923
 loose, in joints, 907
 regeneration of, 76
Cary and Lyon, on pneumococcus inflammation, 219
 Caryochromes, 943
 Caseation, 59
Castellani, on yaws, 293
 Casts of kidney, 749
 Catarrh, dry, 588
 purulent, 199
 Catarrhal fever, epidemic, 233
Care, on pneumococcal arthritis, ref., 904
Cecil, on relation of pancreas to diabetes, ref., 435
 Cells, atrophy of, 36
 "beaker," 46
 blood, red, (see Blood cells), 456
 Cells, white, (see Leucocytes), 459
 changes in, 35
 chemistry of, as related to Ehrlich's hypothesis, 166
 degeneration of, 36, 39
 division, amitotic, 65, 67
 direct, 65, 67
 indirect, 65
 mitotic, 65
 modes of, 64
 giant, in epithelioma, 410
 inclusions in tumors, 347
 "mother," 586
 necrobiosis, 36
 necrosis of, 36
 prickle, 406
 regeneration of, 64, 68, 167
 impulse to, 79
 regressive changes in, 35
 relationship of, to organs, 5
 serous infiltration of, 45
 significance of, 4
 spider, in glioma, 387
 spinal, 406
- Celloidin as tissue embedding medium, 1031
 Cephalhæmatoma, 1024
 Cephalocele, 928
 Cerebellar ataxia, 963
 Cerebellum, atrophy of, 963
 Cerebrum, malformations of, 927
Cérenville, Tavel, etc., on necrotic colitis, ref., 681
 Cervix uteri, hyperplasia of, 805
 Cestoda, 124
 Chalk-stones, 436
 Chalicosis of lung, 616
 Chancre, 271
 soft, 228
 Chancroid, 228
Chantemesse and Podwysotsky, on circulatory disturbances, ref., 34; on conditions of disease, ref., 14; on fever, ref., 441
Chapman, on kidney lesions in scarlatina, ref., 307
 Charbon, 228
 Charcot-Leyden crystals, 589, 897
Cheesman and Meltzer, on local predisposition in infection, ref., 152
 Cheesy degeneration, 59
 Cheloid, 364
 Chemotaxis, 85, 137

- Chemotaxis, negative, 85
- Chiari*, on auto-digestion of pancreas, ref., 702; on atypical typhoid, ref., 243; on syphilitic aortitis, ref., 567
- Chibret*, on adamantinoma, ref., 416
- Chittenden and Albro*, on skin pigment, ref., 55
- Chlamydozoa, 309
- Chloral hydrate poisoning, 424
- Chloroform, in experimental cirrhosis, 730
liver degeneration after use of, 716
poisoning, 424, 716
- Chloroma, 376, 478
- Chlorosis, 471
- Cholæmia, 13
- Cholangitis, 740
- Cholecystitis, 740
- Cholelithiasis, 743
- Cholera, Asiatic, 247
"carriers," 249
communicability of, 249
diagnosis of, 249
immunity in, 170
lesions of, 248
preventive inoculation in, 250
spirillum of, 247, 249
chicken, bacillus of, 289
spirillum, reproduction of, 135
- Cholesteatoma, 379
of pia mater cerebri, 920
- Cholesterin in gall-stones, 744
- Chondroma, 383
of bone, 900
bronchi, 591
choroid plexus, 927
clitoris, 795
dura mater cerebri, 911
spinalis, 922
heart, 556
larynx, 585
lips, 645
liver, 737
lung, 634
lymph-nodes, 497
mammary, 848
mouth, 645
muscle, 875
ovary, 829
peritoneum, 697
pia mater cerebri, 920
salivary glands, 700
testicle, 860
- Chondroma of veins, 575
uterus, 813
osteoid, 900
- Chondro-sarcoma, 376
- Chorda dorsalis, 384
- Chordæ tendinæ, abnormal, 525
- Chordoma, 384
- Chorionepithelioma, 820
hydatid moles, relation to, 826
of pregnancy, 820
testicle, 822, 863
with teratoma, 822
- Chorionic villi, 820
wandering cells, 821
- Choroid plexus, brain sand in, 927
cysts of, 927
lesions of (see Ependyma), 924
tumors of, 927
- Christian*, on myeloma, ref., 902
on pneumonic exudates, ref., 605
- Chromatic figure in mitosis, 66
- Chromatolysis, 947, 949, 950, 958
- Chromophilic bodies, 943.
- Chromosomes, 65
- Cicatricial tissue, 93
- Circle of Willis, 933
- Circulation, collateral, 18
disturbances of, favoring thrombosis, 25
in living animal, study of, 34, 111
of blood, 83
- Circulatory system, 518
- Cirrhosis hepatis anthroptica, 730
of liver (see Liver, cirrhosis of), 725
- Citron, on immunity, ref., 165
- Cladotrix, 136
- Clairmont*, on action of saliva on bacteria, ref., 150
- Clasmatocytes, 366
- Clegg*, on cultures of *B. lepræ*, ref., 269
- Clitoris, anomalies of, 793
- Cloacæ, 668
- Clostridium forms of bacteria, 134
- Clots, heart, 531
- Club-foot, 326
- Club-hand, 326
- Cloudy swelling (see Degeneration, albuminous), 39
- Coagulation necrosis, 58, 59
in tuberculosis, 254
of blood, 452
- Coats*, on tumor of pineal gland, 983

- Cobbett and Melsome*, on granulation tissue in infection, ref., 152
- Cocci, 134
- Coccidia, 121
oviforme, 121
in liver, 740
- Coccus, diplo-, 135
strepto-, 135
- Coco*, on colorability of living cells, ref., 1027
- Cohnheim's hypothesis of origin of tumors, 344, 351
- Colchicum poisoning, 422
- Cole*, on typhoid meningitis, ref., 243
- Coleman and Buxton*, on typhoid bacilli in blood, 244
- Colitis, 675
acute catarrhal, 675
acute infectious, 675, 677
amæbic, 676
chronic, 682
croupous, 680
excitants of, 675, 677, 678, 681
experimental, ref., 678
membranous, 682
mucous, 682
necrotic, 681
nodular, 680
pseudo-membranous, 680
- Collateral circulation, 17
- Collodium sacs, ref., 319
- Colloid degeneration, 45, 47
technique of staining, 47
- Colocynth poisoning, 422
- Colon bacillus (see *B. coli communis*), 214
group, 214
dilatation of, 671
inflammation of (see Colitis), 675
- Complement, 177
deviation of, 189
fixation of, 189
in whooping-cough, 317
- Concretions in appendix vermiformis, 686
in intestine, 690
pancreas, 707
- Concurrent infection, 157
- Condyloma, 272
pointed, of vulva, 794
- Cone*, on chronic gastritis, 658
on tuberculous œsophagitis, ref., 653
- Conforti*, on tumors of omentum, ref., 698
- Congenital abnormalities, 320
infection, ref., 151, 157
- Congestion (see Hyperæmia), 16, 594
chronic, 19
hypostatic, 19, 594
post-mortem, 986
venous, 17
- Conium poisoning, 425
- Conjunctiva, trachoma, 308
- Conjunctivitis, gonorrhœal, 222
- Connective tissue, regeneration of, 73
tumors, 357
- Connell*, on fat embolism, ref., 34
- Constitutio lymphatica, 439
- Contagium, ref., 159
- Contrecoup, injury by, 930
- Contusions, post-mortem, 989
- Cooling of body, post-mortem, 988
- Coplin*, on branchial cysts, ref., 647; on pulmonary œdema, ref., 595; on tumors of œsophagus, ref., 654
- Copper poisoning, 422
- Corner and Fairbanks*, on sarcoma of stomach, ref., 663
- Cornet*, on tuberculosis, 268
- Cornet and Meyer*, on tuberculosis, 268
- Cornil and Carnot*, on regeneration of mucous membranes, ref., 71
- Corning*, on cysts of appendix, ref., 686; on diverticula of appendix, ref., 668
- Corpora aliena articularum, 907
amylacea, 50
in brain, 941
ependyma, 927
prostate, 866
cavernosa, inflammation of, 854
plates, fibrous, in, 854
- Corpuseles, Gluge's, 941, 966
- Corrosive sublimate as fixative, 1030
for blood, 467
poisoning, 421
kidney in, 51, 750, 753
- Councilman*, on acute interstitial nephritis, ref., 759; on arterio-sclerosis, 565; on cerebro-spinal meningitis, ref., 224; on excitant of smallpox, 306; on gonorrhœal myocarditis, ref., 538; on lung lobule, ref., 602; on sudden deaths due to heart, ref., 528
- Councilman and Lafleur*, on amœba dysenterix, 115
- Councilman, Mallory, and Pearce*, on bacteriology and pathology of diphtheria, ref., 283

- Councilman, Mallory, and Wright*, on cerebro-spinal meningitis, ref., 225
- Coupland and Pasteur*, on tumors of spinal cord, ref., 977
- Courmont and Duffau*, on spleen in infection, ref., 151; ref., 504
- Cowie*, on differentiation of smegma and tubercle bacilli, ref., 267
- Cowper's glands*, lesions of, 867
- Coyne and Cavalié*, on experimental nephritis, ref., 769
- Coyon*, on bacteria of stomach, ref., 659
- Craig*, on entamœba histolytica, ref., 116
- Cramer*, on sunstroke, 437; on transplantation of ovary, ref., 78
- Craniopagus*, 330
- Craniorrhachischisis totalis*, 324
- Cranioschisis*, 324
- Craniotabes*, 894
- Craw*, on agglutination of typhoid bacilli, ref., 246
- Crenothrix*, 136
- Cretinism*, 430
- Croton oil poisoning*, 422
- Croup*, 583
- Crowder*, on tuberculous lymphadenitis, ref., 488
- Cryptorchismus*, 856
- Culex*, in avian malaria, 314
- Cullen*, on adenomatous myoma of uterus, ref., 813; on calcification of heart muscle, ref., 541; on carcinoma of uterus, 815; on cysts of Bartholin's glands, ref., 795; on cysts of vagina, ref., 797; on frozen sections, 1028; on hydrosalpinx, ref., 838; on myoma of round ligament, ref., 813; on peritonitis, ref., 694; on sarcomatous changes in myoma of uterus, ref., 813; on tuberculosis of uterus, ref., 806;
- Cunningham*, on death from electric currents, ref., 11; on lesions of thyroid, ref., 429
- Curare*, use of, ref., 34
- Currie, Brinckerhoff, and Hollman*, on cultures of *B. lepræ*, ref., 269
- Curschmann*, on *B. typhosus* in bladder, ref., 786
- Curschmann's spirals*, 589
- Cushing*, on gall-bladder infections, ref., 742; on gonococcus peritonitis, ref., 694; on rôle of micro-organisms in gallstones, ref., 745
- Cyclopia*, 325, 927
- Cylindroma*, 380
- Cystadenoma adamantinum*, 415
- of mamma, 850
- ovary, 830
- glandular, 832
- papillary, 835
- Cysticercus cellulosæ*, 124
- in brain, 979
- heart, 556
- kidney, 781
- muscle, 875
- peritoneum, 699
- pia mater cerebri, 921
- spinalis, 923
- in spleen, 511
- ventricles of brain, 927
- tæniæ mediocanellatæ, 124
- Cystitis, acute catarrhal*, 783
- chronic, 784
- croupous, 785
- emphysematous, 786
- en plaque*, 785
- excitants of, 786
- exudative, 783
- hyperplastic, 785
- necrotic, 784
- nodular, 785
- suppurative, 785
- tuberculous, 786
- with pyelo-nephritis, 771
- Cystocele*, 795
- vaginal, 782
- Cysts*, 359
- atheromatous, 561
- branchial, 645, 647
- ciliated, ref., 361
- congenital, 360
- daughter, 125
- dermoid, 360
- of bladder, urinary, 788
- bone, 903
- choroid plexus, 927
- lungs, 635
- mouth, 645
- muscle, 875
- nose, 581
- ovary, 836
- penis, 855
- peritoneum, 699
- scrotum, 855
- skin, 360
- spleen, 510

- Cysts, dermoid of thymus, 511
 thyroid, 514
 echinococcus, 125
 follicular, of ovary, 836
 foreign body, 360
 grand-daughter, 125
 hydatid, 125
 of appendix vermiformis, 686
 bladder, urinary, 788
 bone, 903
 brain, 979
 choroid plexus, 927
 Fallopian tubes, 841
 intestine, 690
 kidney, 772
 liver, 737
 mamma, 852
 male, 867
 mesentery, 699
 œsophagus, 654
 omentum, 699
 ovary, 360, 830, 836, 837
 pancreas, 706
 parovarium, 837
 pericardium, 522
 pia mater cerebri, 921
 placenta, 826
 pleura, 642
 prostate, 866
 spinal cord, 978
 spleen, 510
 stomach, 666
 tongue, 646
 urethra, 792
 uterus, 822
 vagina, 797
 vulva, 795
 preservation of, 1039
 retention, 360
 of Cowper's glands, 867
 larynx, 585
 retroperitoneal, 699
 retro-ovarian, 841
 sebaceous, of penis, 855
 transudation, 360
- Cysto-sarcomata, 375
- Cytase, 179
- Cytolsins, anti-, 175
- Cytolysis, 60, 171, 174
 Ehrlich's hypothesis, application of,
 to, 176
 in liver, 715
 phagocytes in, 178
- Cytolytic substances, 171, 174
- Cytoryctes vaccinæ, 305
 variolæ, 116
- Cytotoxins, anti-, 175
- DaCosta*, on blood, ref., 452
- Dagonet*, on tumors of dura mater, ref.,
 911
- Dahms*, on differentiation of smegma and
 tubercle bacilli, ref., 267
- Daughter cysts, echinococcus, 125
- Davenport*, on chemotaxis, ref., 86
- Davis*, on adrenals, ref., 516; on B. influ-
 enzæ, ref., 234; on diabetic gangrene,
 ref., 434; on Ducey's bacillus, 228; on
 excitant of whooping-cough, ref., 317;
 on meningococcus in blood, ref., 225
- Dayton*, on hæmolymp-nodes, ref., 498
- Dead tissues, disposal of, in body, 98, 103
- Death, black, 288
 causes of, 9
 sudden, 446
 and persistent thymus, ref., 440,
 448
 in status lymphaticus, 439,
 448
 lesions leading to, 446
 violent, 442
 time of, as determined post-mortem,
 988
- Decalcification of tissues, 1031
- Deciduoma malignum, 820
- Decomposition, post-mortem, 987
- Degeneration, 39
 acute, 39
 albuminous, 39
 of heart, 533
 kidney, 751
 liver, 716
 muscle, 871
 pancreas, 703
 stomach, 656
- amyloid, 48
 of adrenals, 515
 arteries, 558
 heart, 535
 intestine, 671
 kidney, 753
 liver, 720
 lymph-nodes, 482
 muscle, 872
 pancreas, 703
 placenta, 823

- Degeneration, amyloid of spleen, 500
 stomach, 656
 thyroid, 512
 uterus, 803
 tests for, 50, 1012
 ascending, of nervous system, 954
 axonal, 948
 cheesy, 59
 colloid, 45, 47
 of thyroid, 512
 combined system, 962
 descending, in nervous system, 953
 diffuse, of spinal cord, 963
 fatty, 40, 41
 of arteries, 557
 endocardium, 535
 kidney, 752
 heart muscle, 534
 joints, 903
 liver, 720
 muscle, 871
 pancreas, 703
 placenta, 823
 prostate, 863
 stomach, 656
 uterus, 803
 veins, 593
 glycogenic, 44
 of kidney, 753
 liver, 721
 granular, 39
 hyaline, 48
 of arteries, 558
 heart, 535
 lymph-nodes, 482
 muscle, 871
 pancreas, 703
 prostate, 863
 thyroid, 512
 hydropic, 45
 in inflammation, 97
 lardaceous, 48
 mucous, 45
 myelinic, 43
 neurone, 946
 of dendrites, 946
 ganglion cells, ref., 965,
 966
 neurone systems, 951
 nerves, 970
 nervous system, 946
 parenchymatous (see Degeneration,
 albuminous), 39
- Degeneration, neurone of kidney, 751
 liver, 716
 primary, of nervous system, 953
 secondary, of nervous system, 953
 waxy, 48
 of muscle, 872
Delafield, on colitis, 675
Delafield's hæmatoxylin solution, 1035
Delamare, on syphilitic nephritis, ref., 770
Delamare and Lecène, on giant cells in
 carcinoma, ref., 410
 Dendrites, 943
 degeneration of, 947
 Dermacentor occidentalis as agent of in-
 fection in Rocky Mountain fever, 301
 Dermatitis, blastomycotic, 146
 Dermoid cysts (see Cysts, dermoid), 360
 Desmoid, 565
De Witt, on dysmenorrhœa, ref., 804; on
 islands of Langerhans, ref., 704; on
 myositis ossificans, ref., 874
 Diabetes, bronzed, 435
 mellitus, 434
 internal secretions in, 435
 phloridzin, 435
 Diapedesis, 86
 hæmorrhage by, 20
 Diaphragm, eventration of, 692
 examination, post-mortem, of, 1003
 malpositions of, 691
 vault of, 1003
 Diastematomyelia, 928
 Diaster phase of mitosis, 66
 Diathesis, hæmorrhagic, 22
 Dicephalus, 331
Dieudonné, on plague bacillus, ref., 288
 Digestive system, 643
 Digitalis poisoning, 425
 Dioxydiamidoarsenobenzol, 119
 Diphtheria, 282
 antitoxin, 164, 285
 theory of, 165
 bacillus of, 282, 283
 bacteriology of, 283
 communicability of, 285
 concurrent infections in, 284
 diagnosis of, 285
 immunization, artificial, in, ref., 304
 lesions in, 282
 of larynx, 583
 of pharynx, 648
 pseudo-, 212
 septicæmia in, 284

- Diphtheria, toxin, 164, 285
 Diplobacilli, 135
 Diplococci, 135
 Diplococcus intracellularis meningitidis, 223
 characters of, 225
 pneumoniæ, 217
 character of, 218
 in mouths of healthy persons, ref., 219
 occurrence of, 219
 sources of, 219
 staining reactions of, 220
 Diplomyelia, 928
 Diprosopus, 331
 Dipygi, 330
 Disease, adaptation to, 8
 characters of, 4
 conditions of, 8
 external, 9
 internal, 9
 contagious, ref., 159
 disposition to, 8
 excitants of, 5
 general, 429
 infectious, 156
 bibliography of, 319
 classification of, 197
 communicable, 159
 communicability of, 158
 definition of, 160
 endemic, 159
 epidemic, 159
 general considerations, 197
 non-communicable, 159
 of animals, 319
 unknown origin, 318
 pandemic, 159
 occupational, 9
 "specific," 197
 Disposition to disease, 8
 Distoma hæmatobium, 123
 hepaticum, 123
 in liver, 739
 veins, 575
 lanceolatum, 123
 sinense, 123
 Diverticula, false, of intestine, 668
 Meckel's, 667
 of bladder, urinary, 782
 intestine, 667
 œsophagus, 652
 pharynx, 647
 Djewitsky, on tumors of heart valves, ref., 556
 Dmochowski and Janowski, on cysts in liver, ref., 736; on pyogenic powers of typhoid bacillus, ref., 244
 Dobrowolski, on lymph-nodules of larynx, etc., ref., 649
 Dock, on chloroma, ref., 376; ref., 479; on sarcoma of stomach, ref., 663; on trichomonas, ref., 120
 Dock and Warthin, on chloroma, ref., 479
 Donath and Landsteiner, on paroxysma hæmoglobinuria, ref., 456
 Dorsel, on invisible microbes, ref., 319
 Doty, on quarantine in yellow fever, ref. 303
 Doud, on cervical tuberculous lymph-nodes, ref., 487; on cysts of mesentery, ref., 699
 Dropsy, 22, 518
 Drowning, death from, 443
 Drysdale's corpuscles, 835
 Ducrey's bacillus, 228
 Duct, thoracic, lesions of, 576
 Dum-dum fever, 119
 Dunbar, on typhoid fever, ref., 244
 v. Dungern, on immunity, 196
 Dura mater cerebri, 908
 bone in, 911
 hæmorrhage of, 908
 inflammation of (see Pachymeningitis), 909
 structure of, 908
 syphilis of, 911
 thrombosis of, 908
 tuberculosis of, 911
 tumors of, 911
 examination, post-mortem, of, 992
 methods of hardening, 998
 spinalis, 921
 bone in, 922
 hæmorrhage of, 922
 inflammation of (see Pachymeningitis), 922
 parasites of, 922
 structure of, 921
 tuberculosis of, 922
 tumors of, 922
 Dürk, on bacteria in lungs of children, ref., 614
 Durham, on mosquito in yellow fever, ref., 303

- Dust infection in tuberculosis, 265
Dutton and Todd, on tick fever in monkeys, 293
Duval, on cultures of *B. lepræ*, ref., 269
 on parasites of scarlatina, ref., 307
 Dysentery (see Colitis), 675
 amœbic, ref., 116
 bacillus of, 247, 677
 Dysmenorrhœa, membranous, 804
 Dyspnœa, 9
 Ear, internal, examination, post-mortem,
 of, 998
 middle, relation of, to meningitis,
 ref., 917
Eber, on animal tuberculosis, ref., 263
 Ecchondroses, 384
 Ecchymoses, 21, 989
 Echinococcus, 125
 cysts, 125
 exogena, 126
 in brain, 979
 heart, 556
 kidney, 781
 liver, 738
 muscle, 875
 peritoneum, 699
 pleura, 642
 prostate, 866
 spleen, 511
 testicle, 863
 thyroid, 514
 uterus, 822
 veins, 575
 ventricles of brain, 927
 multilocularis, 126
 scolecipariens, 126
Eckersdorff, on sarcoma of lung, ref., 634
 Eclampsia, lesions of liver in, 716, 718
 Ectopia cordis, 323
 Ectopic pregnancy, 841
 Ectosarc, 116
Eden, on placenta, ref., 822
Edsall and Ghriskey, on communicability
 of pneumonia, ref., 606
 Egg albumen for fixing section to slide,
 1028, 1034
 Ehrlich's hypothesis, 176
Ehrlich, on experimental tumors of mice,
 ref., 351; on immunity, 196; side chain
 hypothesis of, 165; triacid stain for
 blood, 468
Ehrlich and Apolant, on tumor transplan-
 tation, ref., 354
Ehrlich and Lazarus, on diseases of blood,
 ref., 471
 Elaterium poisoning, 422
Elbe, on calcification of kidney, ref., 753
 Electricity, action of, on bacteria, 138
 death from, 10
 Elephantiasis of penis, 855
 scrotum, 855
 vulva, 794
Elser, on cerebro-spinal meningitis, ref.,
 225
Elser and Huntoon, on meningococcus in
 blood, ref., 225
Elting, on gonorrhœa, ref., 221; on
 gonococcus, ref., 223
 Embedding tissues, 1031
 Emboli, 28
 air, 34
 fat, 29, 34, 469
 of lungs, 595
 forms of, 29
 liver-cell, ref., 29
 parenchyma-cell, ref., 29
 placental-cell, ref., 29
 sources of, 31
 tumor-cell, 34
 Embolism, 28
 effects of, 29
 of arteries, 571
 brain, 940
 cerebral arteries, 31
 kidney, 748
 mesenteric vessels, 671
 spinal cord, 942
 spleen, 502
 paradoxical, 32
 retrograde, 32
 study of, in living animal, 34
Emerson, on experimental nephritis, ref.,
 769; on pneumothorax, ref., 637
 Embryo, age of, to determine, 1023
 malformations of, 320
 size of, 1023
 Emphysema of bladder, urinary, 786
 lung, 597
 interstitial, 599
 vesicular, 597
 Empyema, 199, 638
 excitants of, 639
 Encephalitis, in new-born, 972
 suppurative, 965
 chronic, 971
 hæmorrhagic, 965

- Encephalitis, acute, 964
 disseminated, 965
 parenchymatous, *ref.*, 965
 Encephalocele, 928
 Encephalomeningocele, 325
 Enchondroma (see Chondroma), 383
 Endarteritis, 559
 obliterating, 560
 of coronary arteries, 537
 Endemic disease, 159
 Endocarditis, 542
 acute, 543
 bacteria in, 544
 chronic, 547
 ulcerative, 548
 gonorrhœal, *ref.*, 545
 infective, *ref.*, 545, 547
 malignant, 544
 bacteria in, 544
 mycotic, 544
 stenosis of valves in, 548
 thrombi in, 546
 tuberculous, 548
 ulcerative, acute, 543
 chronic, 548
 malignant, 544
 vegetations in, 543, 546, 548
 verrucous, 543
 Endocardium, degeneration of, 535
 lesions of, 530, 542
 Endometritis, 804
 acute catarrhal, 804
 chronic, 804
 exfoliative, 804
 membranous, 806
 puerperal, 808
 tuberculous, 806
 syphilitic, 807
 Endometrium, hyperplasia, glandular of, 805
 inflammation of (see Endometritis), 804
 Endophlebitis, 573, 574
 Endosarc, 116
 Endothelioma, 377
 of adrenals, 517
 appendix vermiformis, 690
 bone, 901
 brain, 977
 dura mater cerebri, 911
 spinalis, 922
 kidney, 776
 liver, 735
 of lung, 634
 lymph-nodes, 497
 lymph-vessels, 577
 nerves, 979
 ovary, 830
 pericardium, 522
 peritoneum, 698
 pia mater cerebri, 920
 spinalis, 923
 pleura, 641
 salivary glands, 700
 thymus, 511
 thyroid, 514
 uterus, 813
 vagina, 797
 Endothelium, regeneration of, 75
 Endotoxin, 152
 bacterial, 139
 Energy, cell, 3
 transformations of, in cells, 35
Engelken, on adenoma of kidney in children, *ref.*, 776
 Enostoses, 899
 Entamoeba histolytica, 115
 in colitis, 676
 Enteritis, acute catarrhal, 672
 chronic catarrhal, 672
 exudative, 673
 follicular, 672
 nodular, 672
 phlegmonous, *ref.*, 673
 pseudo-membranous, 672
 streptococcus, *ref.*, 681
 suppurative, 673
 syphilitic, 674
 tuberculous, 673
 Enteroliths, 690
 Enzymes, bacterial, 139
 proteolytic, in phagocytes, 105
 Eosin-hæmatoxylin stain for nerve tissue, 981
 Eosinophile cells, 461
 Ependyma, 924
 cysts of, 927
 inflammation of, 924
 lesions of, 924
 method of hardening, 998
 parasites of, 927
 tumors of, 927
 Ependymitis, 924
 Epicardial nodules, 521
 Epidemic disease, 159
 Epididymitis, 858

- Epignathus, 332
 Epispadias, 324, 781, 853
 Epistaxis, 21, 579
 Epithelial bodies, 514
 cell tumors 395
 pearls, 407
 Epithelioma (see also under Carcinoma),
 405, 406
 adamantinum, 415
 basal-celled, 408
 giant-celled, 410
 neuro-, 410
 of mamma, 851
 nose, 581
 scrotum, 855
 uterus, 815
 Epithelium, growth of, following injec-
 tions of Scharlach R, 352
 regeneration of, 71
 Epulis, 373
 of mouth, 645
 Erdheim, on thyroid, ref., 512
 Erlanger, on Stokes-Adams' disease, ref.,
 549
 van Ermenghem, on intestinal bacteria,
 ref., 681
 Ernst, on cartilage tumors, ref., 383
 on immunity, 196
 on metastases in chondroma, ref., 384
 on psammoma, ref., 912
 Erysipelas, 211
 of penis, 854
 vulva, 793
 Erythremia, 455
 Erythrocytes (see Blood cells, red), 456
 Erythrocyto-opsonins, 184
 Escherich and Pfandler, on B. coli, ref.,
 214
 Esser, on circulatory changes in lungs,
 ref., 595
 Etat mamelonné of stomach, 657
 Ether poisoning, 424
 Etienne, on tuberculosis of endocardium,
 ref., 548
 Ewing, on adipocere, ref., 987; on bacteria
 in smallpox, ref., 305; on blood, ref.,
 452; on blood changes in disease of
 liver, ref., 734; on eclampsia, ref., 718;
 on epithelial cell changes in measles,
 ref., 310; on ganglion cells, ref., 243,
 948; on immunity in typhoid fever,
 ref., 245; on lesions of goitre, 432; on
 lymphatic constitution, ref., 440, 448;
 on malarial nephritis, ref., 761; on
 sudden death, ref., 448; on syphilis,
 ref., 276; on toxic hypoleucocytosis,
 ref., 464; on vaccine bodies, 306
Ewing and Strauss, on precipitin test for
 blood, ref., 182
 Examination, post-mortem, 933
 Exophthalmos, 432
 Exostoses, 386, 899
 Exudates, 23, 199
 autolysis of, 202
 in inflammation, 87
 rôle of, 108
 sterile, method of securing, 195
 Exudation, study of, on frog, 111
 Eye, examination, post-mortem, of, 998
 malformations of, 325, 927
 Face, malformations of, 643
 Fæces, typhoid bacilli in, 244, 245

Fahr, on syphilitic aortitis, ref., 567
Falkson, on tumor of pineal gland, 980
 Fallopian tubes, 838
 absence of, 838
 closure of, 838
 cysts of, 841
 dilatation of, 838
 ectopic pregnancy, 841
 examination, post-mortem, of, 1020
 hæmorrhage of, 839
 hydrosalpinx, 838
 hyperplasia of muscle wall, 839
 inflammation of, 839
 malformations of, 838
 malpositions of, 838
 preservation of, 1020
 pyosalpinx, 840
 size of, 1020
 changes in, 838
 syphilis of, 840
 tuberculosis of, 840
 tumors of, 841
Falla, on senile gangrene, ref., 58
Faltin, on bacteria of urinary passages,
 ref., 786
 Famine fever, 292
 Farcin de bœuf, 232
 Farcy, 226
Farmer, Moore and Walker, on mitosis in
 tumors, 351
 Fat-acid crystals, technique of staining,
 ref., 44
 emboli, 29, 34

- Fat-acid** in blood, 469
 necrosis, 59
 stains for, 44, 1029
 technique of fixation, 44
 tissue, regeneration of, 77
Fatigue, action of, on neurones, 950
Fatty degeneration, 40, 41
 infiltration, 40, 43
Favus, 148
Feldmann, on chordoma of sacrum, ref., 385
Fenomenou, on cysts of placenta, ref., 826
Fenwick, on hair balls in stomach, ref., 666; on sarcoma of stomach, ref., 663
Fermentation and yeasts, 146
 bacteria in, 139
Ferments, bacterial, 139
Fever, 440
 famine, 292
 catarrhal, epidemic, 233
 hospital, 300
 inflammatory, ref., 204
 jail, 300
 Malta, 287
 paratyphoid, 247
 puerperal, ref., 204, 808
 relapsing, 292
 Rocky Mountain spotted, 301
 scarlet, 307
 seven-day, 292
 ship, 300
 spirillum, 292
 splenic, 228
 spotted, 300
 Rocky Mountain, 301
 suppurative, ref., 204
 surgical, ref., 204
 Texas, 122
 tick, 301
 traumatic, ref., 204
 typhoid, 234
 typhus, 300
 yellow, 302
Fibrin, 86
Fibrinogen, 452
Fibroblasts, 74, 93
Fibroma, 362
 diffusum, 794
 of penis, 855
 durum, 362
 intracanalicular, 365, 847
 molle, 362
 molluscum, 363
Fibroma of appendix vermiformis, 690
 bladder, urinary, 786
 bone, 899
 brain, 976
 bronchi, 591
 dura mater cerebialis, 911
 spinalis, 922
 ependyma, 927
 Fallopian tubes, 841
 gall-bladder and -ducts, 743
 heart, 556
 intestine, 688
 joints, 907
 kidney, 776
 larynx, 585
 liver, 735
 lymph-nodes, 497
 lung, 634
 mamma, 847
 mammary, 867
 mouth, 645
 muscle, 875
 oesophagus, 653
 ovary, 298
 penis, 855
 pericardium, 522
 peritoneum, 696
 pharynx, 650
 pia mater cerebialis, 920
 spinalis, 923
 pleura, 641
 salivary glands, 700
 scrotum, 855
 spleen, 510
 spinal cord, 978
 stomach, 662
 testicle, 860
 tongue, 646
 uterus, 809
 vagina, 797
 vulva, 794, 795
 papillare, 809
 pericanalicular, 848
Fibrosis, 96
Fibrous tissue, hyperplasia of, 96
 in pulmonary tuberculosis, 630
Ficker, on flies and typhoid, ref., 245
Field, on parasites in scarlatina, ref., 307
Filaria medinensis, 130
 sanguinis hominis, 131
 in kidney, 781
 lymph-nodes, 497
 lymph-vessels, 576

- Filarial lymphatic varix, ref., 131
 Filariasis, 131
 First intention, healing by, 82
Firth, on micro-organisms in air, ref., 150
Fischer, on atypical epithelioma, ref., 352; on cholera spirillum, ref., 135; on false diverticula of intestine, ref., 668
 Fish poisoning, 425
Fischl, on foetal infection, ref., 158
 Fistula, 90
 branchial, 647
 recto-vaginal, 796
 vesico-vaginal, 796
Fitz, on cysts of pancreas, ref., 707; on dilatation of colon, ref., 671; on pancreas, ref., 706
Fixateur, 179; ref., 184
 Fixation of immune, substance, 173
 tissues, 1029
 rapid, 1028
 tumor tissue, 362
 Fixative, 179
 Flagella of bacteria, 133
Flechsig, on tables dorsalis, 962
Fleischer and Loeb, on experimental myocarditis, ref., 539
 Flemming's osmic acid mixture, 1030
Fletcher, on tuberculous cavities in liver, ref., 733
Flexner, on abrin and ricin intoxication, ref., 203; on autolysis, 106; on bubonic plague, ref., 612; on connective tissue in cirrhosis, ref., 727; on dysentery, ref., 678; on etiology of syphilis, ref., 276; on experimental pancreatitis, ref., 705; on experimental meningitis, 225; on fatty degeneration of heart, ref., 535; on focal necroses in typhoid fever, ref., 241; on focal necrosis of liver, ref., 715; on hæmolysis, 174; on hyperplasia of heart, ref., 541; on plague, ref., 288; on poliomyelitis, ref., 299; on serum therapy in meningitis, 226; on syphilis of stomach, ref., 659; on terminal infection, ref., 158; on thrombi, ref., 26; on toxalbumin intoxication, ref., 153; on tuberculous œsophagitis, ref., 653; on typhoid bacilli in heart, ref., 244
Flexner and Anderson, on B. diphtheriæ in lungs, ref., 284
Flexner and Jobling, on serum therapy in meningitis, ref., 226; on transplantation of tumors, 355
Flexner and Lewis, on anterior poliomyelitis, ref., 299
Flexner and Noguchi, on snake venom, ref., 425
Flexner and Pearce, on experimental pancreatitis, ref., 705
Flezner and Sweet, on experimental colitis, ref., 678
 Flies, as carriers of tuberculosis, ref., 151 as carriers of typhoid, ref., 151, 245
Flockemann, on pulmonary syphilis, ref., 634
Flügge, on distribution of bacteria in sneezing, etc., 265
 Focal necroses, 203
 Flukes, 123
 Foetal inclusions, 333
 infections, 157
 Fœtus acardiacus, 328
 malformations of, 320
 size of, at various periods, 1023
Ford, on bacteria in body, ref., 150; on intestinal bacteria, ref., 681
 Foreign-body tubercles, 102
 Foreign bodies, injuries from, 11
 substances, disposal of, in body, 98
 disposal of, in body, experimental study of, 110
 Formalin as tissue fixative, 1029
 Formaldehyde (see Formalin), 1029
 Formative stimuli, 79, 350
 Formol (see Formalin), 1029
Forsyth, on Haffkine method in plague, ref., 289
Foster, on changes in aorta, ref., 564
Foulerton, on blastomycetes, 146
Fox, on paratyphoid, ref., 247
 Fractures, post-mortem, 990
 Frambœsia tropica, 293
Frank, on chorionepithelioma, ref., 820, 822; on secretions of corpus luteum, ref., 822; on thyroid tissue in ovary, ref., 836
Freeborn, on picro-acid-fuchsin stain, 1036
Freeman, on fatty infiltration of liver in children, ref., 720; on focal necrosis in measles, 310; on spread of typhoid, ref., 245; on typhoid and oysters, ref., 245; on vaccination, ref., 307
Frenkel and Bassal, on chordoma, ref., 385

- Frieberger and Frohner* on infectious diseases of animals, 319
Friedlander bacillus, 216
Friedmann, on tonsils as portals of entry for tubercle bacilli, ref., 650
Friedrich's ataxia, 963
Friedrich, on ataxia, ref., 963
Frog, circulation in, study of, 34
 circulation of blood in, 83
 plates, Thoma's, 111
 study of inflammation in, 111
Frost, on anterior poliomyelitis, ref., 300
Frothingham, on demonstration of Negri bodies, 297
 Frozen section of tissues, 1028
Fuerst, on giant cells, ref., 103
Fungus, favus, 148
 fission, 133
 mould, 133, 147
 poisoning, 423
 ray, 231
 yeast, 133, 146
Furuncle, 199
Futterer, on squamous epithelioma of stomach, ref., 666
- Gallaverdin*, on stricture of intestine, ref., 671
 Gall-bladder, bacteria in, 742
 calculi of, 743
 dilatation of, 743
 examination, post-mortem of, 1016
 infections of, 742
 inflammation of, 740
 lesions of, 740
 perforation of, 740
 tumors of, 743
 Gall-ducts, abscesses of, 741
 bacteria in, 741, 742
 calculi of, 743
 constriction of, 742
 dilatation of, 743
 examination, post-mortem, of, 1016
 infection of, 741
 inflammation of, 740
 lesions of, 740
 new-formed, in cirrhosis, 727
 occlusion of, 740, 742
 tumors of, 743
 Gall-stones, 743
 composition of, 744
 in pancreatic duct, 707
 rôle of micro-organisms in, 745
- Gamboge poisoning, 422
 Ganglia, basal, blood supply of, ref., 425
 Ganglion cells (see Neurones), 944, ref., 948
 degeneration of, 962, 965, 966
 Gangrene, 57
 diabetic, 434
 dry, 58
 emphysematous, 290
 moist, 58
 of appendix vermiformis, 685
 lung, 599
 pancreas, 705
 vagina, 797
 vulva, 794
 senile, ref., 58
Gappisch, on actinomyces-like structures in tonsillar crypts, ref., 649
 Gas bacillus, 34, 289
 in blood, 34
 pleura, 637
 formation, post-mortem, 987
 B. aërogenes in, 290, 987
 phlegmon, 290
 Gastritis, 656
 acute catarrhal, 656
 chronic, 656
 croupous, 658
 diphtheritic, 658
 exudative, 658
 membranous, 658
 phlegmonous, 658
 suppurative, 650
 syphilitic, 659
 toxic, 659
 tuberculous, 659
Gay, on complement fixation, ref., 183
Gay and Southard, on anaphylaxis, ref., 190
Gaylord, on origin of fibrin, ref., 637
Geissler, on tuberculosis of arteries, ref., 566
 Gemmules, 944
 General diseases, 429
 Genito-urinary organs, examination, post-mortem, of, female, 1019, 1026
 male, 1018, 1026
 new-born, 1023
Géraudel, on changes in liver, ref., 743
 Germicides, 138
 Germs, 133
Gerulanos, on dermoid cysts of penis, ref., 855

- Ghon and Sachs*, on *B. aerogenes capsulatus*, ref., 290
- Giannettasio*, on umbilical tumors, ref., 667
- Giant cells, 67, 102
in epithelioma, 410
- Giemsa stain, for blood, 317
for blood and tissues, 1037
- Gigantism, 438
- Gigantoblasts, 459
- Gilbert and Lippmann*, on gall-bladder infections, ref., 742
- Gilchrist*, on blastomycotic dermatitis, ref., 146; on fibroma molluscum, 363
- Glanders, 226
diagnosis of, 227
- Glands, Nabothian, ectasia of, 805
- Glegg*, on hay fever, ref., 580
- Glioma, 387
of adrenals, 517
brain, 976
ependyma, 927
- Glio-sarcoma, 370, 388
- Glockner*, on endothelioma, ref., 380; on endothelioma of pleura, ref., 642
- Glomerulo-nephritis, 757
- Glomeruli, lesions of, 756
- Glossina morsitans, 117
palpalis, 118
- Glossitis, 646
- Glottis, œdema of, 582, 1011
- Gluge's corpuscles, 941, 966
- Glycogen infiltration, 44
technique of staining, 44
- Glycogenic degeneration, (See Degeneration, glycogenic), 144
- Glycosuria, ref., 435
- Goitre, 513
exophthalmic, 432
- Goldberger*, on mosquito in yellow fever, ref., 303
- "Golden" coccus, 206
- Golgi*, neurone conception of, 943
- Gonococcus, see *M. gonorrhœæ*, 221
in inflammation of rectum, 683
peritonitis, ref., 694
salpingitis, ref., 840
vaginitis, 796
- Gonorrhœa, 221
- Goodale*, on acute tonsillitis, ref., 649
- Goodwin and v. Sholly*, on meningococcus, ref., 225
- Gordinier and Lartigau*, on *B. typhosus* in empyema, ref., 639
- Gottstein*, on micro-organisms in air, ref., 150
- v. Gourévitch*, on cirrhosis, ref., 730
- Gout, 435
joint lesions in, 905
- Gowers, tract of, 952
- Graafian follicles, hæmorrhage in, 827
- Graf*, on periarteritis nodosa, ref., 566
- Graham*, on displacements of liver, 708
- Graham-Smith*, on diphtheria bacillus in mouths of healthy persons, ref., 285; on precipitin test for blood, ref., 182; on xerosis bacillus, ref., 285
- Gram's stain for bacteria, 144
Weigert's modification, 144
- Granulation tissue, 92
in wound infection, ref., 152
- Granulations, 92
exuberant, 95
- Granuloma, infectious, ref., 251
- Grass bacillus, 267
- Graves' disease, 432
- Greenough*, on cell inclusions in cancer, ref., 350
- Greenough and Hartwell*, on cystic hyperplasia of mamma, ref., 845
- Greff*, on trachoma bodies, 308
- Gregarinæ, 121
- Griffith*, on aneurism of coronary arteries, ref., 570; on dilatation of colon, ref., 671
- Grippe, 233
- Grober*, on infection of pleura, ref., 640; on pleura as portal of entry for bacteria, ref., 614
- Ground water, 141
- Group agglutination, 180
- Guarnieri*, on smallpox, 305
- Guinea worm, 130
- Guiteras*, on mosquito in yellow fever, ref., 303
- Gummata, 273
of bone, 881
heart, 542
kidney, 770
pancreas, 706
ovary, 829
- Gums, tumors of, 645
- Gurd*, on gonorrhœal salpingitis, ref., 840
- Guthrie*, on transplantation of organs, ref., 78
- Guy and Ferrier*, on forensic medicine, 426

- Guyot*, on formation of lymph-vessels in pleurisy, ref., 640
- Gwyn*, on typhoid bacilli in urine, ref., 244
- Haasler*, on regeneration of bone marrow, ref., 76
- Hæmagglutinins, injection of, into animals, 715
- Hæmangioma, 393
- Hæmatemesis, 21, 655
- Hæmatocele, 857
uterine, 803
- Hæmatogenesis, defective, 457
- Hæmatoidin, 53, 457
- Hæmatolysis, 456
- Hæmatoma, 21
of pia mater cerebri, 919
polypoid, of uterus, 803
- Hæmatometra, 800
- Hæmatomyelia, 939
- Hæmatomyelopore, 939
- Hæmatoxylin as staining agent, 1035
- Hæmatozoon of Texas fever, 122
- Hæmaturia, 21
- Hæmochromatosis, 54
- Hæmoglobin index, 474
- Hæmoglobinæmia, 454, 456
- Hæmoglobinuria, 456
of cattle, 122
- Hæmolymp-nodes, 497, ref., 499
compensatory hypertrophy of, ref., 73
- Hæmolysins, 171
auto-, ref., 176
bacterial, ref., 206
- Hæmolysis, 53, 54, 172
by *Staphylococcus pyogenes aureus*, 206
Streptococcus pyogenes, 209
tests, technique of, 194
- Hæmolytic serum, 171
- Hæmopericardium, 518
- Hæmophagocytosis, 195
- Hæmophilia, 22
- Hæm-opsonins, 184
- Hæmoptysis, 21
- Hæmorrhage, 20
by diapedesis, 20
rhexis, 20
capillary, 935
forms of, 21
in new-born, 22
- Hæmorrhage in organs (see various organs)
intermeningeal, 913
spontaneous, in spinal cord, 938
- Hæmorrhagic diathesis, 22
infarction, 21
septicæmia, 289
- Hæmorrhoids, 684
urethral, 792
vesical, 783
- Hæmosiderin, 53, 457
- Hæmosporidia, 122
of malaria, 312
- Hæmothorax, 637
- Hæmotoxins, 171
- Haffkine*, preventive inoculation in cholera, 250
in plague, 289
- Hair ball in stomach, 667
- Halberstædter and v. Prowazek*, on trachoma, ref., 308
- Haldane and Smith*, on determination of amount of blood in body, ref., 455
- Hall*, on lesions of bronchial lymph-nodes, ref., 592
- Halliburton*, on bacterial products, ref., 152
- Hamburger, on lymph formation, ref., 22
- Hamilton*, on flies as carriers of typhoid, ref., 151; on rupture of heart, ref., 527
- Hamilton and Horton*, on pseudo-diphtheria bacilli, ref., 285
- Hammar*, on accessory lung, ref., 593
- Hand*, on tuberculosis of lymph-nodes, ref., 592
- Handmann*, on weight of brain, ref., 993
- Hanging, death from, 443
- v. Hansemann*, on atypical mitosis in tumors, 350
- Haptines, ref., 168
- Haptophorous group, 167
- Harbitz*, on lesions of bronchial lymph-nodes, ref., 592; on tuberculosis of lymph-nodes, ref., 487; on tuberculosis of lymph-nodes, ref., 265
- Hardening of tissues, 1029
- Hare*, on medical complications of typhoid fever, ref., 244; on tumors of mediastinum, ref., 636
- Harelip, 321
- Harris*, on cysts of ureter, ref., 774
- Hasenfeld*, on hypertrophy of heart, ref., 554

- Hasslauer*, on bacteria of nose, ref., 580
on meningococcus, ref., 225
- Hauser*, on fibrin formation, ref., 86
- Hay bacillus, 267
fever, ref., 580
- Hayem's solution, 467
- Head, examination, post-mortem, of, 991
- Healing by first intention, 82
second intention, 94
of wounds, 91
- Heart, 522
hypertrophy of, 61
abnormalities of, 522, 525
abscess of, 539
action, irregular, 550
aneurism of, 529
dissecting of, ref., 570
anomalies of, 522
aorta, insufficiency and stenosis of, 552
atrophy of, 528
bacteria in, 539
beat, cause of, 549
block, 549
calcification of, 535
chordæ tendinæ, abnormal, of, 525
circulation, interference with, 550
clots, 531, 1005
degeneration of, 533
dilatation of, 528, 550, 555
displacements of, 526
embolism of, 538
endocardium, degeneration of, 535
inflammation of (see Endocarditis), 542
examination, post-mortem of, 1004, 1025
His bundle, 550
hyperplasia, fibrous, of, 541
replacement, of, 540
hypertrophy of, 550, 554, 555
hypoplasia of, 439, 526
infarction of, 31
infiltration, fatty, of, 535
inflammation of, 538
insufficiency of, 553
lesions of, in typhoid fever, 242
malformations of, 522
malpositions of, 525
muscle, fatty degeneration of, 534
myocardium, segmentation and fragmentation of, 536
parasites in, 556
- Heart, pericardial lesions (see Pericardium)
pigment in, 529
polypi, 531
position of, 1004
preservation of, 1009
relation of, to circulation of blood, 15
reptilian, 523
ruptures of, 526
septa, abnormal, 525
size of, 1004
stenosis of, 553
Stokes-Adams' disease, 549
sudden death in lesions of, ref., 528
syphilitic of, 542
thrombosis of, 531, 537
tuberculosis of, 542, 548
tumors of, 522, 556
valves, aneurism of, 530
aortic, insufficiency of, 552
stenosis of, 552
changes in, 15, 555
insufficiency of, 552
lesions of, 529, 552
mitral, insufficiency of, 553
stenosis of, 553
pulmonary, lesions of, 553
stenosis of, 552
tricuspid, lesions of, 553
vegetations, 531
ventricles, hypertrophy of, 552
left, hypertrophy of, 554, 555
right, hypertrophy of, 554, 555
weight of, 1008
wounds of, 526
- Heat, damage from, 9
exhaustion, 436
- Hedrére*, on mixed tumors of kidney, ref., 776
- Heidenhain's iron hæmatoxylin, 1035
- Heinz*, on inflammation, ref., 110; on origin of fibrin, ref., 637; on phagocytic power of liver endothelium, ref., 721; on physiology of blood-vessels, ref., 564; on physiology of heart, ref., 550; on physiology of lungs, ref., 603
- Hektoen*, on aortic aneurism, ref., 570; on cardiac anomalies, ref., 524; on changes in myocardium, ref., 536; on endarteritis in tuberculosis, ref., 559; on giant cells, ref., 103; on infectious diseases of unknown origin, ref., 319; on inoculation of measles, ref., 310; on

- opsonins, 185; on phagocytosis and opsonins, ref., 187; on phagocytosis of anthrax bacilli, ref., 230; on yeasts and moulds in disease, ref., 149
- Hektoen and Harris*, on secondary sarcoma of liver, ref., 737
- Hektoen and Ruediger*, on opsonins, 184
- Helbing*, on rhabdomyoma, ref., 390
- Held's stain for nerve tissue, 982
- Hellebore poisoning, 422
- Heller*, on pleural lymph-nodes, ref., 603; on removal of viscera, post-mortem, ref., 990
- Helly*, on blood-forming organs, ref., 471
- Hemicephalia, 324
- Hepatic artery, lesions of, 711
- Hepatitis, 722
 - acute exudative, 722
 - interstitial, chronic (see Liver, cirrhosis of), 725
 - peri-, 733
 - purulent, 722
 - syphilitic, 730
 - tuberculous, 731
- Hepatization, gray, of lung, 605
 - red, of lung, 604
- Hepatolytic serum, 174
- Heppner*, on hermaphroditism, ref., 853
- Herdmann and Boyce*, on typhoid and oysters, ref., 245
- Heredity, relationship of, to disease, 13
 - relation of, to tumor growth, 344
- Hermaphroditism, 853
 - pseudo-, 853
- Hernia cerebri, 930
 - crural, of uterus, 802
 - inguinal, 802
 - ischiatric, 802
 - of brain, 928
 - intestine, 670
 - uterus, 802
 - vagina, 795
 - ventral, of uterus, 802
 - vesico-vaginalis, 795
- Herpes tonsurans, 148
 - of prepuce, 854
- Herrick*, on portal pressure in cirrhosis, ref., 727
- Herrick and Janeway* on trichina, 129
- Herring*, on development of glomeruli, ref., 756
- Herrmann*, on adrenals, ref., 515
- Herter*, on chemical pathology, ref., 426
- Herter and Williams*, on experimental cirrhosis, ref., 730
- Herzheimer*, on action of tubercle bacillus, ref., 253; on adeno-carcinoma of liver, ref., 736; on dead tubercle bacilli, ref., 260; on fat stain, 44; on primary carcinoma of liver, ref., 736
- Herzog*, on insects as plague carriers, ref., 289
- Hess*, on cysts, ref., 361
- Heterotopia, 346, 929
 - false, 929
- Hewitt*, on necrosis of renal epithelium, ref., 751
- Hill*, on potassium hydroxid clearing method, ref., 1039
- Hintz and Lubarsch*, on elimination of bacteria, ref., 151
- Hirsch*, on hypertrophy of heart, ref., 554; on streptococcus enteritis, ref., 681
- His, bundle of, 550
- Hiss*, on cultivation of typhoid bacilli, 246; on leucocyte extract, 188; on staining encapsulated pneumococci, 220; on staining streptococcus capsules, 209; on typhoid bacillus, ref., 235
- Hiss and Russell*, on *B. dysenteriae*, ref., 677; on *B. typhosus*, ref., 246
- Hiss and Zinsser*, on bacteriology, 133; on immunity, 196; on tuberculin, ref., 262
- Hodenpyl*, on etiology of appendicitis, ref., 688; on faucial tonsils, ref., 649; on actinomycosis of lung, ref., 230; on frozen sections, 1028; on lung pigment, ref., 616; on regression of tumors, 356; on spleen, 499; on tuberculosis of pleura, 641
- Hodgkin's disease, 489
- Hoer*, on uvula in abnormal conditions, ref., 648
- Hoffmann*, on carbonic oxide poisoning, ref., 425; on dusty trades and consumption, ref., 616; on hermaphroditism, ref., 853; on myeloma, ref., 902
- Hofmeier*, on placenta, ref., 826
- Homén*, on streptococcus toxin, ref., 211
- Honl*, on hæmorrhagic infections, ref., 439
- Honsell*, on tumors of tonsil, ref., 651
- Hookworm, 128
 - disease, 129
- Hopkins*, on phagocytosis of red blood cells, ref., 185

- Hormones, ref., 435
 Horseshoe kidney, 325, 746
 Hospital fever, 300
 Hour-glass uterus, 799
Howard, on *B. mucosus capsulatus*, ref., 216; on cardiac hypertrophy, ref., 555; on economic loss by insects, ref., 151; on extra-intestinal lesions induced by typhoid bacillus, ref., 242; on hæmorrhagic septicæmia, ref., 291
Howard and Hoover, on tropical abscess of liver, ref., 723
Howard and Ingersoll, on bacteria in nasal inflammation, ref., 580
Howell, on heart beat, ref., 549
Howland and Richards, on liver in chloroform anæsthesia, 716
 Howship's lacunæ, 883
 Hoyer's formula for thionin stain, 1038
Hueter, on congenital tumors of intestine, ref., 688
Huguenin, on bacteria in smallpox, ref., 305
Hunter, on insects as carriers of plague, ref., 151
Hurdon, on endothelioma of cervix uteri, ref., 813
Hutchinson, on vulnerability of apex of lung, ref., 631
 Hyaline degeneration, 48
 substances, 47
 technique of staining, 48
 Hydatids, 125
 of liver, 738
 Hydræmia, 454
 Hydrarthrosis, 23
 Hydrencephalocele, 928
 Hydrocele, 23, 856
 Hydrocephalus, 22, 924, 925
 acute, 918
 chronic, 925
 congenital, 925
 externus, 928
 internus, 927
 method of removing brain in, 1024
 primary, 926
 secondary, 926
 Hydrochloric acid, 418
 Hydrocyanic acid poisoning, 423
 Hydromeningocele, 928
 Hydrometra, 799
 Hydromyelia, 929
 Hydronephrosis, 772
 Hydropericardium, 22, 518
 Hydroperitoneum, 23
 Hydrophobia, 294
 animal inoculations in, 295
 diagnosis of, 298
 excitants of, 295
 immunization, artificial, in, ref., 304
 Negri bodies in, 295
 Pasteur method in, 297
 preventive inoculation in, 297
 virus of, 295
 Hydropneumothrax, 637
 Hydropic degeneration, 44
 Hydrops cystidis felleæ, 743
 Hydrorrhachis, 929
 Hydrosalpinx, 838
 Hydrostatic test, 1025
 Hydrothorax, 22, 636
 Hymen, anomalies of, 793
 Hyperæmia, 16
 active, 16
 of bladder, urinary, 783
 bone, 877
 brain, 934
 kidney, 748
 liver, 709
 lung, 593
 pia mater cerebialis, 913
 spleen, 502
 thyroid, 512
 uterus, 802
 vulva, 793
 passive, 16
 Hypernephroma, 777
 of liver, 735
 Hyperostosis, 900
 Hyperplasia, 61
 cystic, of mamma, 845
 fibrous, of heart, 541
 glandular, of endometrium, 805
 nodular, of intestine, ref., 672, 679
 of fibrous tissue, 96
 liver, 734
 lymph-nodes, 488
 neuroglia, 951
 spleen, 504, 508
 thyroid, 513
 replacement, 61, 96
 of heart, 540
 musele, 874
 Hypersusceptibility, 190
 Hypertrophy, 61
 compensatory, 61, 62

- Hypertrophy, compensatory, of heart, 555**
 functional, 61
 numerical, 61
 of brain, 931
 heart, 61, 550
 kidney, 62, 747
 liver, 62
 mamma, 847
 muscle, 62, 871
 pineal gland, 980
 prostate, 863
 thymus, 511
 tongue, 646
 tonsil, 649
 pseudo-, 61
 simple, 61
Hyphæ, 147
Hyphomycetes, 133, 147
Hypoleucocytosis, 463, 464
Hypophysis cerebri, 517, 980
 in acromegalia, 438
 tumors of, 980
Hypoplasia, 321
Hypospadias, 324, 853
Hypostasis, post-mortem, 987

Ice-cream poisoning, 425
Ichoræmia, ref., 204
Ichthyosis, 644
Icterus, 13, 54
 gravis, 716
Ileo-cæcal tuberculosis, hyperplastic, 682
Immune body, 172
 substance, 170, 172
Immunity, 160
 acquired, 161, 162
 active, 162
 anti-bacterial, 162, 169
 anti-microbial, 162, 169
 anti-toxic, 162, 163
 artificial, to streptococcus, 211
 tumors, 355
 bactericidal, 162, 169
 bacteriolytic, 162, 169
 bibliography of, 196
 definition of, 160
 Ehrlich's hypothesis of, 165
 hereditary, 161
 natural, 161
 nature and forms of, 160
 passive, 163
Immunization, artificial, 161, 162
 artificial, specific characters of, 192
Immunization, natural, 161
 of animals to alien substances, 195
 processes involved in, 192
Incubation period of infection, 156
Index, hæmoglobin, 474
 opsonic, 187, 220
India ink stain for Treponema pallidum, 278
Infantile paralysis, 299
Infarction, 29
 hæmorrhagic, 21
 of heart, 31
 intestine, 31, 671
 kidney, 31, 748
 liver, 30, 711, 712
 lung, 30, 596
 muscle, 873
 placenta, 823
 spleen, 31, 502
Infarcts, 29
 absorption of, autolytic processes in, ref., 30
 anæmic, 30
 hæmorrhagic, 29
 location of, 30
 white, 30
Infection and immunity, 156
 communicability of, 158
 concurrent, 157
 condition of body in, 155
 of micro-organisms in, 155
 congenital, 157
 definition of, 156, 160
 fœtal, 157
 forms of, 157
 hæmorrhagic, ref., 439
 incubation period in, 156
 latent, ref., 151
 mixed, 157
 predisposition to, 155
 proofs of, 154
 purulent, ref., 204
 spleen in, ref., 152
 sub-, ref., 151
 terminal, 157
 theory of, ref., 153
 through granulation tissue, ref., 152
 wound, experimental studies on, ref., 152
Infectious diseases, 156, 197
 bibliography of, 319
 classification of, 197
 communicability of, 158

- Infectious diseases, conditions influencing
 occurrence of, 155
 definition of, 156, 159
 general considerations, 197
 of animals, 319
 unknown origin, 318
 protozoa in, 317
- Infectious granuloma, *ref.*, 251, 348
- Infectious granulomata, 348, 361
- Infiltration, calcareous, 50
 fatty, 40, 43
 of adrenals, 515
 heart, 535
 muscle, 871
 pancreas, 703
 glycogen, 44
 hydropic, of muscle, 871
 purulent, 90
 serous, 45
 of muscle, 872
- Inflammation, 81
 bacteria in, 152
 cardinal symptoms of, 87
 catarrhal, 97
 characterization of, 110
 degeneration in, 97
 experimental study of, 110
 exudative, 87, 89
 practical study of, 111
 fibrinous, 97
 general survey of, 107
 hæmorrhagic, 97
 in non-vascular tissue, 82
 in organs (*see various organs*).
 in vascular tissue, 83
 interstitial, 96, 98
 micro-organisms in, 88
 muco-purulent, 97
 mucous, 97
 necrotic, 97
 parenchymatous, 98
 phlegmonous, 200
 practical study of, 111
 productive, 97
 pseudo-membranous, 97
 purulent, 97
 reparative, 97
 resolution in, 90
 resorption in, experimental study of,
 110
 serofulous, 487
 sero-purulent, 97
 serous, 97
- Inflammation, significance of, 107
 special phases of, 97
 suppurative, 97, 198
 tuberculous, 251
 diffuse, 252, 255
- Influenza, 233
 bacillus, 233
- Infusoria, 115, 120
- Insects as carriers of disease, 151
 of plague, *ref.*, 151
- Insects, method of study of, 132
- Insolation, 436
- Intermediary body, 177
- Internal secretions, 427
- Interstitial inflammation, 96
- Intestine, 667
 absorption in, *ref.*, 681
 actinomycosis of, 691
 amœbæ in, 676
 anthrax in, 691
 bacteria in, 678, 811
 cloacæ, 668
 concretions in, 690
 cysts of, 690
 degeneration of, 671
 dilatation of, 671
 diverticula of, 667
 dysentery, 675
 embolism of, 671
 examination, post-mortem of, 1002,
 1014, 1026
 hæmorrhage in, 671
 hernia of, 670
 hyperæmia of, 671
 hyperplasia of, in typhoid fever, 235
 nodular, 672, 679
 incarceration of, 668
 infarction of, 31, 671
 inflammation of (*see Enteritis and*
Colitis), 672, 675, 682, 683
 intussusception of, 669
 invagination of, 669
 lesions of, in Asiatic cholera, 248
 in typhoid fever, 235, 242
 malformations of, 667
 malpositions of, 667
 mycosis of, 691
 parasites in, 691
 permeability of wall of, for bacteria,
 ref., 681
 polyps of, 688
 preservation of, 1015
 ruptures of, 671

- Intestine, strictures of, 671
 syphilis of, 674, 683.
 transposition of, 667
 tuberculosis of, 673, 682
 tumors of, 688
 ulcers of, 674, 675, 681, 682
 volvulus of, 668
 wounds of, 671
- Intoxication, auto-, 153
 septic, 153, 156
- Intussusception of intestine, 669
- Inversio vesicæ, 324
- Involution forms of bacteria, 134
- Iodin test for amyloid, 1012
- Ipsen*, on intestinal tuberculosis, ref., 674
- Iron hæmatoxylin solution, 1035
 "masked," ref., 53
 reactions for, ref., 53
- Irons and Graham*, on blastomycosis, ref. 146
- "Irritation forms" of leucocytes, 462
- Ischæmia, 19
- Ischiopagus, 330
- Isolysins, 176
- Itch insect, 132
- Jackson, Porter and Quinby*, on thrombosis of mesenteric veins, ref., 671
- Jacob*, on carcinoma of stomach, ref., 666
- Jacobi*, on cysts of omentum, ref., 699
- Jacobson*, on hair balls in stomach, ref., 666
- Jacobsthal*, on infantile scorbutus, ref., 438
- Jaeger*, on cerebro-spinal meningitis, 225
- Jail fever, 300
- Jakowski*, on formation of thrombi, ref., 25
- Jalap poisoning, 422
- James*, on lesions of stomach as portals of entry for bacteria, ref., 659; on pneumopericardium, ref., 518
- Jamin and Merkel*, in coronary arteries, ref., 537
- Janeway, T. C.*, on hypertrophic pulmonary arthropathy, ref., 438
- Janiceps, 330
- Janowski*, on suppurative inflammation, ref., 202
- Janus*, 330
- Jaundice (see *Icterus*), 13, 54
- Jaw, malformations of, 643
- Jaworski and Korolewicz*, on occult hæmorrhage in gastro-intestinal canal, ref., 655
- Jelliffe*, on death from electric currents, ref., 11
- Jellinek*, on myeloma, ref., 902
- Jenner*, vaccination in smallpox, 304
- Jessup*, on carcinoma of appendix vermiformis, ref., 690
- Jochmann*, on bacterisæmia in pulmonary tuberculosis, ref., 631
- Joints, 903
 cartilage, loose, in, 907
 degeneration of, 903
 false, 878
 inflammation of (see *Arthritis*), 903
 tuberculosis of, 906
 tumors of, 906
- Jopson and White*, on sarcoma of large intestine, ref., 690
- Jordan*, on acute osteomyelitis, ref., 887
- Jordan, Russell, and Zeil*, on typhoid bacillus in water, ref., 245
- Jores*, on arterio-sclerosis, ref., 561
- Jørgenson*, on micro-organisms and fermentation, ref., 146
- Josserand and Bonnet*, on myocarditis, ref., 538
- Jürgelunas*, on granulation tissue in infection, ref., 152
- Jürgens*, on virulence of pneumococcus, ref., 220
- v. Kahlden*, on cysts of ovary, ref., 836
 on periarteritis nodosa, ref., 566
- Kaiserling's fluid for color specimen, 1039
- Kala-azar, 119, 480
- Kappis*, on urogenital tuberculosis, ref., 770
- Karakascheff*, on adrenals, ref., 516
- Karcher*, on bacteria in bronchitis, ref., 588
- Karyokinesis, 65, 67
- Karyolysis, 57
- Karyomitosis, 67
- Karyorrhesis, 57
- Kataplasia, 63
- Kedrowsky*, on emphysematous cystitis, ref., 786
- Keen*, on surgical complications of typhoid fever, ref., 244
- Keen and Funke*, on carotid tumors, ref., 517

- Keen, Pfahler, and Ellis*, on hypernephroma, ref., 777
- Keith and Flack*, on His bundle, ref., 550
- Kelly*, on cirrhosis, ref., 730; on hypernephroma, ref., 777; on leukæmia, ref., 475; on tumors of appendix vermiformis, ref., 690
- Kelly and Hurdon* on vermiform appendix, ref., 688
- Kelynack*, on pathology of vermiform appendix, ref., 688; on renal growths, ref., 777
- Kerr*, on statistics of lobar pneumonia, ref., 606
- Keyes*, on snake poisons, ref., 425
- Kidney**, 746
- abscess of, 754
 - absence of, 746
 - albuminuria, 749
 - anæmia of, 748
 - arterio-sclerosis, relation of, 769
 - atrophied, 766
 - bacteria in, 755, 761
 - calcification of, 750, 753
 - calculi of, 774
 - casts in, 749
 - congestion of, 748
 - cysts of, 772
 - degeneration of, 751
 - dilatation of, 772
 - embolism of, 748
 - examination, post-mortem of, 1011, 1026
 - excretion of bacteria by, 755
 - pigment by, 755
 - glomeruli, alterations in, 756
 - granular, 766
 - horseshoe, 325, 746
 - hyaline casts in, 749
 - hydronephrosis, 772
 - hyperæmia of, 748
 - hypertrophy of, 62, 747
 - infarction of, 31, 748
 - infection, ascending, of, 755
 - embolic, of, 754
 - of, after injury, ref., 152
 - inflammation of (see Nephritis), 753
 - lesions of, in malaria, 311
 - sublimate poisoning, 51, 750, 753
 - typhoid fever, 243
 - lobulation, fœtal, of, 747
 - lobulated, 326
- Kidney**, malarial parasites in, 761
- malformations of, 746
 - malpositions of, 747
 - movable, 747
 - necrosis of, 750
 - parasites in, 781
 - pelvis, lesions of, 771
 - perinephritic suppuration, 772
 - preservation of, 1013
 - red, large, 761
 - regeneration of, 72, ref., 748
 - surgical, 755
 - regeneration of, 72
 - syphilis of, 770
 - thrombosis of, 748
 - tuberculosis of, 769
 - tubules, lesions of, 757
 - tumors of, 776
 - wandering, 747
 - weight of, 1012, 1026
 - white, large, 765
- Kinnicut*, on orchitis in typhoid fever, ref., 243; on phlegmonous gastritis, ref., 659
- Kirchheim*, on hypertrophy of breast, ref., 847
- Kisskalt*, on cooling of body and pneumonia, ref., 614; on natural immunity, ref., 161
- Kitt*, on comparative pathology, 319; on hæmorrhagic infection, ref., 289
- Klebs*, on malformations of generative organs, ref., 853
- v. Klecki*, on elimination of bacteria by kidney, ref., 761
- Kleine and Möllers*, on inherited immunity, ref., 161
- Klimenko*, on permeability of intestinal wall for bacteria, ref., 681
- Klipstein*, on bacteria in lung, ref., 614
- Klotz*, on arterio-sclerosis, ref., 565; on calcareous degeneration, ref., 52; on formation of fat in cells, ref., 40
- Knor*, on epicardial nodules, 521; on lipomyoma of uterus, ref., 813
- Knox and Schorer*, on rhabdomyoma of heart, ref., 556
- Kober*, on tuberculosis in cattle, ref., 266
- Kobert*, on poisons, 426
- Koch*, on B. tuberculosis, 268
- Koch-Weeks bacillus*, 234
- Kolisko*, on blood supply of basal ganglia, ref., 425

- Kolle*, on cholera spirillum, ref., 249; on specificity of infectious agents, ref., 165
- Kolle and Hetsch*, on animal inoculations in hydrophobia, ref., 295; on experimental bacteriology, 196; on tuberculosis, 268
- Kolle and Wassermann*, on immunity, 196
- Kossel*, on Texas fever, 122
- Kollar*, on cardiac thrombi, ref., 532
- Koplik and Van Arsdale*, on acute osteomyelitis in childhood, ref., 887
- Kraus*, on regeneration of fat tissue, ref., 77
- Kraus and Levaditi*, on immunity, ref., 165
- Krehl*, on fever, ref., 439, on heart lesions, ref., 553
- Krompecher*, on basal-celled carcinoma, ref., 410; on epithelium and endothelium, ref., 396
- Kruse and Pasquale*, on abscess of liver, ref., 724; on necrotic colitis, ref., 681
- Kühnau*, on bacteriology of blood, ref., 470
- Külble*, on bacteria in lymph-nodes, ref., 481
- Labia, lesions of, 793, 794
- Lachner-Sandoval*, on ray fungi, ref., 232
- La grippe, 233
- Lambert*, on sunstroke, ref., 437
- Lamy and Mayer*, on renal secretions, ref., 748
- Lando*, on pancreas lesions in hepatic cirrhosis, ref., 728
- Landsteiner*, on sweat-gland adenoma, ref., 399
- Landsteiner and Stoerk*, on cystitis en plaque, ref., 785
- Landry's paralysis, 969
- Lang and Ullmann*, on syphilis, ref., 274
- Lang's solution, formula for, 1030
- Langerhans, islands of, degeneration of, 703
 development of, ref., 704
 hypertrophy of, ref., 704
- Langhans' cells, 820
- Langmann*, on hæmosporidia, 122; on snake poisons, ref., 424
- Lanz and Tarel*, on appendicitis, ref., 688
- Lardaceous degeneration, 48
- Larkin*, on multiple neuroma, ref., 393
- Lartigau*, on atypical typhoid, ref., 243; on *B. coli*, 214; on *B. pyocyaneus*, 215; on bacteriology of angina, ref., 649; on concurrent infection in tuberculosis of lungs, ref., 631; on gonorrhæal endocarditis, ref., 545; on ileo-cæcal tuberculosis, ref., 683; on *M. tetragenus*, 216; on pulmonary complications in typhoid fever, ref., 243; on tuberculosis, 268;
- Lartigau and Nicoll*, on adenoids, ref., 581; on tuberculosis of tonsil, ref., 650
- Laryngitis, acute catarrhal, 582
 chronic catarrhal, 583
 croupous, 583
 phlegmonous, 584
 pseudo-membranous, 583
 syphilitic, 584
 tuberculous, 584
- Larynx, 581
 amyloid masses in, 586
 cysts of, 585
 examination, post-mortem, of, 1010, 1025
 foreign bodies in, 442
 hæmorrhage from, 582
 inflammation of (see Laryngitis), 582
 malformations of, 581
 œdema of, 582
 preservation of, 1011
 syphilis of, 584
 tuberculosis of, 584
 tumors of, 585
- Lasio*, on regeneration of mucous membrane of bladder, ref., 785; on repair of bladder mucosa, ref., 71
- Lavenson*, on pernicious anæmia, ref., 475
- Lâwen*, on sarcoma of uterus, ref., 813
- Lead poisoning, 421
- Le Count*, on lymphoma, ref., 497
- Leers*, on precipitin test, ref., 182, 194
- Legry*, on lung stones, ref., 639
- Lehndorff*, on chloroma, ref., 376, 479
- Leiomyoma, 388
 of œsophagus, 653
 ovary, 829
 veins, 575
- Leishman*, on opsonins, 183
- Leishman-Donovan bodies, 119
- Leishmania donovani*, 480
 infantum, 480
- Leith*, on phlegmonous gastritis, ref., 659

- Lentz*, on dysentery, ref., 678
Leonhardt, on myxoma of heart, ref., 556
Leopold and Levi, on moulds, ref., 147
 Lepra, 269
 anæsthetica, 976
 bacilli, 269
 Leprosy, 269
 of nervous system, 976
 orchitis in, 860
 Leptomeningitis, 914
 Leptothrix, 136, 232
 in vagina, 797
Lesser, on action of poisons, 426
 Leucocyte extract, 188
 Leucocytes, 459
 abnormal, 461
 amitosis in, 68
 as phagocytes, 100, 104, 108, 161, 178, 463
 as pus cells, 201
 basophile, 461
 classification of, 459
 degenerative changes in, 464
 development of, 77
 emigration of, 83
 eosinophile, 461
 ferments of, 87, 475
 formation of, 77
 in abscess, 89
 cytolysis, 178
 exudates, 108
 inflammation, 108
 leukæmia, 475
 malaria, 310
 pus, 201
 suppuration, 198
 irritation forms, 462
 lymphocytes, 459
 large, 462
 method of securing, 195
 mononuclear, large, 459
 myeloblasts, 462
 myelocytes, 461
 normal, 459
 plasma cells, 462
 polynuclear neutrophile, 461
 proportions of, in normal blood, 461
 regeneration of, 77
 transitional, 459
 Leucocythæmia, 475
 Leucocytolysis, 465
 Leucocytosis, 462
 cachetic, 464
 Leucocytosis, hypo-, 463, 464
 in acute lobar pneumonia, 220
 in infection, 463
 mixed, 462
 polynuclear eosinophile, 464
 pathological, 463
 physiological, 463
 Leucolysis, 179
 Leucolytic serum, 174
 Leucomains, ref., 139
 Leucoplakia buccalis, 644
 Leuco-protease, 105
 Leukæmia, 475
 bone marrow in, 897
 liver lesions in, 734
 lymph-node lesions in, 475
 lymphatic, acute, 475
 chronic, 475
 myelogenous, acute, 476
 chronic, 477
 pseudo-, 489
 spleen in, 509
Levaditi and Manouélian, on silver impregnation method, ref., 277
Levaditi and Roché, on syphilis, ref., 276
Levene, on autolysis, ref., 107
Lewin, on toxicology, 426
Lewis, on acromegalia, ref., 438; on anaphylaxis, ref., 191; on types of B. tuberculosis, ref., 266
Lewis and Rosenow, on portal thrombosis, ref., 712
Lewkowiez, on bacteria in mouths of nurslings, ref., 647
Lexer, Kuliga, and Turk, on blood supply and tuberculous lesions in bone, ref., 888
Libman, on bacteria in blood, ref., 547; on paratyphoid, ref., 247; on sarcoma of small intestine, ref., 690
 Lice as agents of infection in Mexican typhus, 301
Liefmann, on hay fever, ref., 580
 Life, chemistry of, 3
 Lightning, death from, 10
Linck, on chordoma, ref., 385
v. Lingelsheim, on dysentery, ref., 678; on streptococci, ref., 211; on tetanus, ref., 287
 Lip, hare, 321, 643
 Lipæmia, 469
 Lipoma, 382
 angio-, 382
 arborescens, 907

- Lipoma, molle, 382**
 of appendix vermiformis, 690
 bone, 901
 brain, 976
 bronchi, 587
 dura mater cerebri, 911
 spinalis, 922
 ependyma, 927
 Fallopian tubes, 841
 heart, 556
 intestine, 688
 joints, 907
 kidney, 776
 larynx, 585
 liver, 735
 mamma, 848
 mouth, 645
 muscle, 875
 œsophagus, 653
 penis, 855
 pericardium, 522
 peritoneum, 696
 pia mater cerebri, 920
 scrotum, 855
 stomach, 662
 testicle, 860
 tongue, 646
 uterus, 813
 vulva, 795
- Lipomatosis, 43**
Liposis, 43
Lipo-sarcoma, 376
Lissauer, zone of, degeneration of, 958
Lithopedion, 842
*Little, on B. aërogenes capsulatus in puer-
 peral infections, ref., 290*
- Liver, 708**
 abscess of, 722
 amœbic, 723
 bacteria in, 723
 metastatic, 724
 multiple, 724
 tropical, 722
 absence of, 708
 accessory, 708
 adrenal tissue in, 515, 736
 agglutinative thrombi in, 715
 anæmia of, 709
 atrophy of, 714
 acute yellow, 716
 experimental, 718
 biliary passages, lesions of (see Gall-
 ducts), 740
- Liver, bronze, 722**
 calcification of, 722
 capsule, inflammation of, 734
 chloroform, effect of, on, 716
 cirrhosis of, 725
 anthracotic, 730
 ascites in, 728
 associated lesions in, 727
 atrophic, 726
 biliary, 729
 congenital, 729
 experimental, 730
 hypertrophic, 728
 nature of, 730
 portal circulation in, 727
 congestion of, 710, 748
 cysts of, 737
 cytolysis in, 715
 degeneration of, 716
 displacements of, 708
 examination, post-mortem, of, 1002,
 1016, 1026
 fluke, 575
 foamy, 738
 focal necrosis of, 241, 714
 gall-ducts, lesions of (see Gall-
 bladder and -ducts), 740
 gall-ducts, new-formed, in cirrhosis,
 727
 gas in, 738
 gumma in, 731
 hæmorrhage in, 709
 hobnail, 725
 hydatids of, 738
 hyperæmia of, 709
 hyperplasia of lymphatic tissue in,
 734
 hypertrophy of, 62
 infarction of, 30, 711, 712
 infiltration, fatty, of, 719
 inflammation of (see Hepatitis), 722
 jaundice with necrosis of, 715
 lesions of, in eclampsia, 716, 718
 in malaria, 311, 721
 lesions of, in typhoid fever, 241
 in yellow fever, 302
 malformations of, 708
 malpositions of, 708
 metabolism, disturbances of, 718
 movable, 708
 necrosis of, 714
 nutmeg, 710
 parasites of, 738

- perihepatitis, 733, 734
 pigmentation of, 714, 721, 730
 preservation of, 1017
 regeneration of, 72, ref., 717
 reversion of cells, in cirrhosis, 727
 rupture of, 709
 size of, 1016
 changes in, 708, 1016, 1026
 syphilis of, 730
 thrombosis of, 711, 714, 715
 tubercles, solitary, of, 733
 tuberculosis of, 731
 tumors of, 734
 vessels, lesions of, 711
 weight of, 1016, 1026
 wounds of, 708
- Lividity, cadaveric, 986
- Livingood*, on sarcoma of œsophagus, ref., 653
- Lobelia poisoning, 425
- Lochte*, on hyperplasia of spleen, ref., 511
- Locke*, on visceral changes following burns, ref., 10
- Lockjaw (see Tetanus), 286
- Locomotor ataxia, 957
- Loeb*, on artificial parthenogenesis, ref., 79
- Loeb, Leo*, on corpus luteum secretion, ref., 822; on mixed tumors of thyroid, ref., 514
- Löffler*, diphtheria bacillus of, 283
- Löffler's stain* for bacteria, 145
- Löhlein*, on opsonins, ref., 184
- Lohrlich*, on mediastinum, ref., 636
- Lommel*, on ciliated epithelium of respiratory organs, ref., 587
- Longcope*, on bone-marrow in infections, ref., 243; on Hodgkin's disease, ref., 495; on reduction of complement, 192
- Longcope and Donhauser*, on lymphatic leukemia, 462
- Lonicer*, on congenital syphilis, ref., 731
- Loomis*, on gumma of heart, ref., 542
- Lord*, on B. influenzae, ref., 234; on flies and tuberculosis, ref., 151
- Lossen*, on exudative peritonitis, ref., 693; on splenic anæmia, ref., 479
- Lothrop and Pratt*, on filaria, ref., 131
- Louse, 132
- Low*, on appendicitis, ref., 688
- Löwit*, on hypoleucocytosis, ref., 464
- Lubarsch* on B. tuberculosis, ref., 257; on bone in tonsils, ref., 649; on emboli, 29; on endothelioma, ref., 380; on foetal infection, ref., 158; on portal of entry of B. tuberculosis, ref., 264; on tumors, 416
- Lubarsch's grouping of tumors*, 359
- Lüdke*, on tubercle bacilli in blood, ref., 618
- Lühe*, on malaria, ref., 316
- Lungs, 593
- abscess of, 611
 absence of, 593
 accessory, 593
 actinomyces in, 612
 anæmia of, 593
 anthracosis of, 601, 616
 apical vulnerability of, ref., 631
 atelectasis of, 596
 autolysis in exudates, 606
 B. diphtheriæ in, 284
 bacteria in, 601, 614
 broncho-pneumonia, 608
 brown induration of, 594
 calcification in, 639
 "carinified," 597
 cavity formation in, 628
 chalicosis of, 616
 circulation in, study of, 113
 circulatory changes in, 593, 595
 congestion of, 593, 594
 cysts of, 635
 dust particles in, 600
 embolism of, 34, 595, 596
 emphysema of, 597
 epithelium, inflammation of, 601, 615
 examination, post-mortem, of, 1009, 1025
 exudation in, 601, 605
 gangrene of, 599
 hæmorrhage of, 595
 hepatization of, 604, 605
 hyperæmia of, 593
 hypostatic congestion of, 612
 infarction of, 30, 596
 inflammation of (see Pneumonia) 600
 injuries of, 593
 lesions of, in asphyxia, 442
 in typhoid fever, 243
 lobule, ref., 602
 lymph-vessels of, 601
 malformations of, 593
 œdema of, 595

- Lungs, perforation of, 593
 phthisis, 627
 pigmentation of, 601, 616
 pneumokoniosis, 616
 portal of entry for bacteria, 600;
 ref., 614
 tubercle bacilli, 618
 preservation of, 1010
 reaction of tissue in, 618
 resolution, commencing, in, 605
 siderosis of, 616
 stones, 592; ref., 639
 streptothrix in, 612
 structure of, 600
 syphilis of, 633
 thrombosis of, 596
 transposition of, 544
 tuberculosis of (see Tuberculosis,
 pulmonary), 618
 tumors of, 634
- Lupus, 267
- Lusk*, on metabolism in diabetes, ref., 434;
 on nutrition, ref., 9
- Lymph, transudation of, 22
- Lymph-follicles, 481
- Lymph formation, ref., 22
- Lymph-nodes, 481
 atrophy of, 481
 bacteria in, ref., 481
 bone in, 487
 bronchial, as portals of entry for
 bacteria, 592
 lesions of, 592
 pigmentation of, 592
 tubercle bacilli in, 592
 degeneration of, 482
 general characters of, 481
 germicidal action of, ref., 151
 hæmo-, 497, ref., 499
 Hodgkin's disease, 489
 hyperplasia of, 488
 in leukæmia, 475
 scrofula, 487
 status lymphaticus, 440
 typhoid fever, 240
 inflammation of, 483
 mesenteric, lesions of, in typhoid
 fever, 240
 œdema of, 482
 parasites in, 497
 pigmentation of, 483
 pseudo-leukæmia, 489
 regeneration of, 76, ref., 486
- Lymph-nodes, scrofula of, 487
 suppuration of, 485
 syphilis of, 488
 tracheal, lesions of, 592
 tuberculosis of, 265, 486
 tumors of, 497
- Lymph-nodules, 481
 lesions of, in typhoid fever, 235
- Lymph-vessels, 576
 dilatation of, 576
 formation of, 76
 inflammation of, 577
 of nose, ref., 580
 syphilis of, 577
 thrombosis of, 28, 576
 tuberculosis of, 577
 tumors of, 577
- Lymphadenitis, 483
 tuberculous, generalized, 488
- Lymphangiectasis, 576
- Lymphangioma, 395, 576
 of liver, 737
- Lymphangitis, 577
- Lymphatic constitution, 439
 tissue in liver, hyperplasia of, 734
- Lympho-adenoma of mediastinum, 636
- Lympho-protease, 105
- Lympho-sarcoma of mediastinum, 636
- Lymphocytes, 459
 large, 462
- Lymphocytoma, 370
- Lymphocytosis, 464
- Lymphoma, 361, 488, 495
 of intestine, 688
 lung, 634
 mediastinum, 636
- Lymphorrhagia, 576
- Lymphosarcoma, 370
- Lynch*, on congenital infection, ref., 151
- Lyon*, on lipomatosis, ref., 43
- Lytic substances, 171, 174, 176
- MacCallum*, on angioma of intestine, ref.,
 688; on changes in myocardium, ref.,
 536; on hæmatozoan infection of birds,
 315; on hypertrophy of islands of Lan-
 gerhans, ref., 704; on lesions of goitre,
 432; on metabolism in fever, ref., 441;
 on phlegmonous enteritis, ref., 673; on
 regenerative changes in liver, ref., 717;
 on reparative phases of cirrhosis, ref.,
 730; on tumors of parathyroids, ref.,
 515

- MacCallum and Voegtlin*, on parathyroids 514
- Macé*, on bacteria in body, ref., 647;
on typhoid bacilli, ref., 244
- Macfadyen*, on toxic products of pneumococcus, ref., 219
- Macfadyen and MacConkey*, on tubercle bacilli in mesenteric lymph-node, ref., 674
- Machard*, on perforation of gall-bladder, ref., 740
- Macrocytase, 179
- Macrogametes, 314
- Macroglossia, 646
- Macrophages, 93, 104
- Maculæ tendinæ, 520
- MacWilliams*, on carcinoma of appendix vermiformis, ref., 690
- Madura foot, 232
- Madzar*, on bacteria in mouth, ref., 647
- Maladie pyocyannique*, 215
- Malakoplakie, 785
- Malaria, 310
- Malaria, æstivo-autumnal type, 313
- avian, 315
 - bibliography of, ref., 316
 - blood, lesions of, in, 310, 312
 - methods of examination of, 316
 - chronic, 311
 - excitant of, 312
 - mosquitoes as intermediary host, in, 314
 - parasite of, 312
 - crenate bodies of, 313
 - flagellate bodies of, 313
 - pigmentation of liver in, 721
 - quartan type, 312
 - tertian type, 312
 - visceral lesions of, 310
- Malformations, 320
- involving single individuals, 321
 - involving two individuals, 327
- Malignant pustule, 228
- Mallein, 227
- Mallory*, on excitant of scarlet fever, 307;
on lesions of typhoid fever, 239; on myoglia fibrils, ref., 389; on necrosis of liver, ref., 715; on neuroglia fibrils, 388; on staining amœbæ, ref., 116
- Mallory and Wright*, on staining fat-acid, ref., 44
- Mallory and Wright anilin blue stain, 1036
- Mallory's anilin-blue stain, 1036
- Malta fever, 287
- Mamma, 842
- abscess of, 844
 - absence of, 842
 - accessory, 842
 - cysts of, 852
 - hæmorrhage in, 842
 - hyperplasia, cystic, of, 845
 - hypertrophy of, 847
 - inflammation of (see Mastitis), 843
 - male, lesions of, 867
 - malformations of, 842
 - nipple, inflammation of, 843
 - regeneration of, 72
 - syphilis of, 846
 - tuberculosis of, 845
 - tumors of, 847
 - ulcers of, 846
- Manasse*, on amyloid masses in larynx, ref., 586
- Mandlebaum*, on teratoma of mediastinum, ref., 636
- Manfredi*, on germicidal action of lymph-nodes, ref., 151
- Mankowsky*, on preparation of brain sections, ref., 1038
- Mann*, on melanin, ref., 55; on micro-chemical reactions for iron, ref., 53
- Marchand*, on classification of tumors, ref., 357; on endothelioma, ref., 380; on malformations, ref., 320; on tissue regeneration, ref., 77
- Marchi*, on degeneration of nerve fibres, ref., 954
- Marchi's* method of staining nerve fibres, 981, 999
- Marchiafava and Bignami*, on malaria, 314, ref., 316
- Marcus*, on entrance of bacteria through intestine, ref., 694
- Marfan*, on concurrent infection in pulmonary tuberculosis, ref., 631; on bronchial lymph-nodes, ref., 592
- Marie*, on spastic paraplegia, 956
- Marinesco*, on chromatolysis, 950
- Marrow, bone, in anæmia, 897
- leukæmia, 897
 - malaria, 311
 - pigmentation of, 877
- Martius*, on auto-intoxication, ref., 417
- Martin*, on flies as carriers of typhoid, ref., 151

- Martin and Rennie*, on cardiac thrombosis, ref., 532
- Marx*, on primary sarcoma of liver, ref., 737
- Maschka*, on poisons, 426
- Mastigophora*, 115, 117
- Mastitis*, 843
 acute exudative, 843
 chronic, 845
 suppurative, 844
 tuberculous, 845
- Maximow*, on amyloid degeneration, ref., 50
- McCampbell*, on Mexican typhus, 301
- McCrae*, on collodium sacs, ref., 319; on mycotic aneurisms, ref., 567; on visceral changes following burns, ref., 10
- McCrae, Fyshe and Ainley*, on acute lobar pneumonia, ref., 606
- McCrae and Klotz*, on fat in liver, ref., 720
- McFarland*, on vaginitis, 796
- McNeal and Novy*, on cultivation of trypanosomes, 122
- McWeeny*, on rupture of œsophagus, ref., 651
- "Measle," 124
- Measles*, 309
 inoculation of, 310
- Meat poisoning*, 291
- Meckel's diverticulum*, 323, 667
- Mediastinitis*, 636
- Mediastinum*, inflammation of, 636
 tumors of, 636
- Medico-legal autopsies*, 1022
- Megaloblasts*, 459
- Megalocytes*, 458
- Melanæmia*, 470
- Melanins*, 55
- Melano-carcinoma*, 415
- Melano-sarcoma*, 370
- Melanuria*, 55
 in melano-sarcoma, ref., 372
- Meltzer*, on cardiac arrhythmia, ref., 550; on functional provision, ref., 69; on œdema, ref., 22; on protection of body against bacteria, ref., 151; on pulmonary œdema, ref., 595; on pyloric stenosis, ref., 655
- Membranes and ventricles of brain*, 908
- Membranous dysmenorrhœa*, 804
- Mendelson*, on apoplexy of thymus, ref., 511
- Menetrier*, on epithelial metaplasia, ref., 63
- Meningitis*, 914
 acute, 914
 basilar, 917
 cellular, acute, 914
 cerebro-spinal, acute, 223
 epidemic, 223
 serum therapy in, 226
 chronic, 917
 exudative, acute, 914
 relation of middle ear to, ref., 917
 spinal, 923
 syphilitic, 919
 tuberculous, 918, 923
 typhoid, ref., 243
- Meningocele*, 324
- Meningococcus* (see *Diplococcus intracellularis meningitidis*), 223, 225
- Merismopedia*, 135
- Merkel*, on angioma of liver, ref., 735
- Merkel*, on bone in lymph-nodes, ref., 487
- Merozoites in malaria*, 312
- Mesentery*, circulation in, study of, 111
 cysts of, 699
 study of inflammation in, 83
- Meslay and Parent*, on tuberculosis of parotid, ref., 700
- Mesothelioma*, 377
- Metachromatic granules in bacteria*, 134
- Metamorphosis, reversionary*, 63
- Metaplasia*, 62
- Metastasis of tumors*, 341, 350
- Metazoa*, 123
- Metcalf and Safford*, on carcinoma of ureter, ref., 788
- Melchnikoff*, on cytolysis, 178; in inflammation, 108; on immunity, 196; on phagocytosis, 104, 106; on protective action of skin, ref., 150
- Melchnikoff and Roux*, on animal inoculations in syphilis, 274
- Methylene blue stain*, 1037
 for bacteria, 145
 polychrome, 1037
- Metritis, acute*, 807
 chronic, 808
 para-, 808
 peri-, 808
- Metrorrhagia*, 21
- Mexican typhus*, 300
- Meyer*, on obstruction of venæ cavæ, ref.,

- 573; on regeneration of lymph-nodes, ref., 76
- Meynert's method of opening brain, 996
- Micrencephalus, 325
- Microbes, 133
- Microcephalia, 928
- Micrococci, 134
- Micrococcus catarrhalis, 226
- gonorrhœæ, 221
 - characters of, 222
 - melitensis, 288
 - pyogenes, 209
 - aureus, 205
 - tetragenus, 216
- Microcytase, 179
- Microcytes, 457
- Microgametes, 314
- Microgametocytes, 314
- Micron, ref., 134
- Micro-organisms, forms of, 133
- communicability of, 158
 - in disease, 150
 - fermentation, ref., 146
 - inflammation, 88
 - mouth, 646
 - tumors, 347
 - relation of, to infection, 156
 - rôle of, in formation of venous thrombi, ref., 25
 - ultra-microscopic, 317
- Microphages, 104
- Microsporion furfur, 148
- Microtomes, 1035
- Mieczkowski, on rôle of micro-organisms in gall-stones, ref., 745
- Miescher, tubes of, 121
- Mignot, on rôle of micro-organisms in gall-stones, ref., 745
- Miller, on bacteria of non-pregnant uterus, ref., 804; on dead tubercle bacilli, ref., 260
- Milne, on repair of liver, ref., 717
- Minot, on cell development, ref, 69; on embryological basis of pathology, ref., 357; on regressive processes, ref., 35; on relation between endothelium and mesothelium, ref., 377
- Misick, on teratoma of liver, ref., 737
- Mitchell, on foreign bodies in appendix vermiformis, ref., 686
- Mitosis, 65
- abnormal phases of, 66
 - in carcinoma, 402
- Matosis in tumors, 339
- significance of, 67
- Mitotic figure, 66
- Mitulescu, on tubercle bacilli on books, ref., 266
- Moles, hydatid, of placenta, 826
- of placenta, 824
 - pigmented, of skin, 372
- Molluscum contagiosum, 415
- Monaster, 65
- Monomorphism in bacteria, 136
- Monsters, 320
- double, 328
- Montgomery, on lung pigment, ref., 592
- Monti and Berggrun, on Von Jaksch anæmia, ref., 479
- Moore, on diseases of animals, ref., 157; on vaccination, ref., 307
- Morbus maculosus neonatorum, 22
- Morf, on sarcoma of thyroid, ref., 514
- Morgan, on regeneration, ref., 69
- Morphin poisoning, 422
- Morrow, on leprosy, ref., 270
- Morris, on cysts of mediastinum, ref., 636
- Morse, in cirrhosis in childhood, ref., 729
- Moschcowitz, on carcinoma of appendix vermiformis, ref., 690; on non-parasitic cysts of liver, ref., 737; on tetanus, ref., 287
- Moser, on tuberculosis of heart, ref., 542
- Moser and v. Pirquet, on agglutination of streptococci, ref., 210
- Mosny, on typhoid and oysters, ref., 245
- Mosquitoes in malaria, 314
- in yellow fever, 303
- Most, on lymph-vessels of nose and pharynx, ref., 580
- Mouisset and Mouriquand, on sublimate poisoning, ref., 421
- Moulds, 133, 147
- as excitants of pneumonia, 613
 - higher, 148
 - methods of study of, 149
- Mouth, 643
- bacteria in, 646; ref., 647
 - cysts of, 645
 - disinfection of, ref., 219
 - inflammation of (see Stomatitis), 643
 - malformations of, 643
 - micro-organisms in, 646
 - syphilis of, 644
 - tuberculosis of, 644

- Mouth, tumors of, 645
- Mucin, technique of staining, 47, 1038
- Mucous degeneration, 45
 - membranes, inflammation of, pseudo-membranous, 212
 - membranes, regeneration of, ref., 71
 - patches in syphilis, 272
 - of mouth, 645
- Mühlmann*, on body changes, ref., 36
- Muir*, on repair of liver, ref., 717
- Müller*, on abrin and ricin intoxication, ref., 203; on comparative histology of lungs, ref., 602; on hypertrophy of heart, 554; on lipoma of kidney, ref., 776; on natural immunity, ref., 161; on thyroid, ref., 512
- Müller's fluid, 1029
- Mummification, 58
- Mumps, 699
- Muscle, 868
 - atrophy of, 868, 871
 - lipomatous, 871
 - progressive, 869, 955
 - spinal, 955
 - bone in, 874
 - degeneration of, 871
 - embolism of, 873
 - hæmorrhage of, 873
 - hyperplasia of, 874
 - hypertrophy of, 62, 871
 - pseudo-, 871
 - infarctions of, 873
 - infiltration, fatty, of, 871
 - hydropic, of, 872
 - inflammation of (see Myositis), 873
 - injuries of, 873
 - necrosis of, 868
 - ossification of, 874
 - parasites of, 875
 - pigmentation of, 868
 - regeneration of, 70
 - relation of, to circulation, 16
 - rupture of, 873
 - syphilis of, 875
 - trichinia in, examination of, 131
 - tuberculosis of, 875
 - tumors of, 875
- Muscles, relation of, to circulation of blood, 16
- Musgrave and Clegg*, on amœbæ, 116; on trypanosomiasis, ref., 118
- Musser, Pearce, and Gwyn*, on actinomycosis, ref., 232
- Myasthenia gravis*, 873
- Mycelium, 147
- Mycetoma, 232
- Mycosis, intestinal, 229, 691
 - pharyngis, 647
- Myelin bodies, 43
 - degeneration, 43
- Myelitis, acute disseminated, 966
 - anterior horn, 967
 - central, 967
 - chronic, 972, 973
 - parenchymatous, ref., 966
 - peripheral, 967
 - polio-, anterior, 967
 - transverse, 966, 973
 - unilateral, 967
- Myeloblasts, 462
- Myelocytes, 461, 477, 897
- Myelogenous substances in cells, ref., 40
- Myeloma, 376, 902
- Myelomeningocele, 324
- Myeloplaxes, 901
- Myocarditis, 538
 - chronic interstitial, 539
 - gonorrhœal, ref., 538
 - interstitial, 538
 - suppurative, 538
 - syphilitic, 542
 - tuberculous, 542
- Myocardium, lesions of, in diphtheria, ref., 283
 - lesions of (see Heart)
 - segmentation of, 536
- Myoglia fibrils, 389
- Myoma, 388
 - levicellulare, 388
 - of appendix vermiformis, 690
 - bladder, urinary, 788
 - intestine, 688
 - kidney, 776
 - mamma, 848
 - stomach, 662
 - testicle, 861
 - uterus, 810
 - vagina, 797
 - striocellulare, 390
- Myomalacia, ref., 538
- Myo-sarcoma, 376
- Myositis, chronic, 873
 - interstitial, 873
 - ossificans, 386, 874
 - poly-, 874
 - suppurative, 873

- Myositis, syphilitic, 875
 tuberculous, 875
 Myxo-chondroma, 383
 Myxœdema, 429
 internal secretions of thyroid in, 430
 Myxoma, 365
 gelatinosum, 365
 medullare, 366
 molle, 365
 of bone, 899
 brain, 976
 dura mater spinalis, 922
 Fallopian tubes, 841
 heart, 556
 larynx, 585
 liver, 737
 lymph-nodes, 497
 mamma, 848
 mamma male, 867
 muscle, 875
 œsophagus, 653
 peritoneum, 697
 pia mater cerebralis, 920
 spinalis, 923
 salivary glands, 700
 testicle, 860
 Myxo-sarcoma, 376
 Myxosporidia, 121

 Nabothian glands, 805
 Naegeli, on blood, ref., 452
 on diseases of blood, ref., 471
 on statistics of tuberculosis, ref., 263
 Nævi, vascular, 394
 Nagana, 117
 Nebelthau, on intestinal tuberculosis, ref., 674
 Neck, appearance of, in strangulation, 443, 989, 1024
 cysts of, 647
 Necker, on statistics of tuberculosis, ref., 263
 Necrobiosis, 36
 Necrosis, 36, 56
 coagulation, 58, 59
 fat, 59
 of pancreas, 704
 focal, 58, 203
 in inflammation, 97
 liquefaction, 56
 of appendix vermiformis, 685
 bone, 889
 kidney, 750
 Necrosis of liver, 241, 714
 muscle, 868
 phosphorus, of bone, 890
 zonal, of liver, 715
 Negri bodies, 116, 295
 staining methods for, 296
 impression method, 297
 Neisser, on animal inoculations in syphilis, 274
 Neisser and Baermann, on animal inoculations in syphilis, 274
 Neisser and Lipstein, on Staphylococcus pyogenes aureus, ref., 208
 Neisser and Sachs, on hæmolytic tests, ref., 182
 Neisser and Scholtz, ref., on gonococcus, 223
 Nematoda, 127
 Nephritis, diffuse, acute, 756
 degenerative type, 759
 excitants of, 760
 exudative type, 759
 glomerular type, 757
 hæmorrhagic type, 759
 interstitial type, 758
 parenchymatous type, 759
 productive type, 759
 variations in type, 759
 chronic, 762
 consideration of, 762
 excitants of, 768
 indurative type, 766
 interstitial type, 766
 parenchymatous type, 763
 variations in type, 768
 experimental, ref., 769
 exudative, 759
 general considerations, 753
 glomerulo-, 757
 interstitial, 759, 766
 malarial, ref., 761
 peri-, 772
 productive, 759
 pyelo-, 771
 suppurative, 754
 syphilitic, 770
 tuberculous, 769
 Nephrolytic serum, 174
 Nerve cell, degenerations of, 946
 nature of, 943
 pigment in, 943
 structure of, 943
 fibres, degeneration of, 946

- Nerve fibres, Marchi's method of staining, 981
 myelin sheath, 944
 Schwann sheath, 944
 tissue, eosin-hæmatoxylin stain for, 981
 Held's method of staining, 982
 Marchi's method of staining, 981
 Nissl's method of staining, 982
 preparation and study of, 980
 regeneration of, 69, 951
 Weigert's method of staining, 981
 tracts, crossed pyramidal, 952
 degeneration of, 953
 direct pyramidal, 952
 degeneration of, 953
- Nerves, degeneration of, 946, 970
 degeneration of neurone, 946
 in tumors, 338, 362
 inflammation of (see Neuritis), 970
 injuries of, 931
 leprous inflammation of, 976
 lesions of, in diphtheria, ref., 283
 morphology of, 942
 preservation of, 1001
 regeneration of, 951
 relation of, to circulation, 16
 sclerosis of, 971
 tumors of, 979
- Nervous system, 908
 artefacts of, ref., 928
 degeneration, primary, of, 955
 secondary of, 953
 degenerations of, 946, 951
 neurone theory of, 943
 preparation and study of, 980
 regeneration of, 951
 relations of, to circulation of
 blood, 16
 syphilis of, 975
 tuberculosis of, 974
 tumors of, 976
- Netter, on bacteria in exudative pleuritis, ref., 638; on pneumococcus in empema, ref., 640; on preventive inoculation in plague, ref., 289
- Neuberger, on calcification of kidney, ref., 753
- Neufeld, on agglutination of streptococci, ref., 210
- Neufeld and Rimpau, on opsonins, 184
- Neufeld and Topfer, on opsonins, ref., 184
- Neumann, on bacteria of nose, ref., 580
- Neurilemma, 946
- Neuritis, acute, 918
 chronic, 973
 exudative, 918
 multiple, 918
 optic, 957
- Neuro-epithelioma, 388, 410
- Neuroglia, 945
 cells, genesis of, ref., 357
 hyperplasia of, 951
 nature of, 945
 types of, 945
 fibrils, ref., 388
 in glioma, 387
- Neuroglioma ganglionare, 976
- Neurolytic serum, 174
- Neuroma, 390
 amputation, 391, 931
 false, 391, 931
 fibrillar, 391.
 ganglioniforme, 390
 of adrenals, 517
 liver, 735
 nerves, 979
 plexiform, 391
- Neurone, degenerations in, 946, 953, 955, 970
 nature of, 943
 theory of nervous system, 943
- Neuroncs, action of fatigue on, 950
 toxins on, 948, 970
 degeneration, primary, of, 955
 secondary, of, 953
 motor, cortico-spinal, 952
 degeneration of, 955, 956
 motor, peripheral, 952
 degeneration of, 955, 956
 upper, 952
 nutritional disturbance of, 948
 sensory, lower, 952
 peripheral, 952
 degeneration of, 957
 upper, 952
 systems of, 951
- Neurocytes hydrophobiæ, 116, 296
- New-born, encephalitis of, 972
 examination, post-mortem, of, 1023
 size and characters of, 1023
 tissues, preservation of, 1026
- Newman, on malignant disease of tonsils, ref., 651
- Newton, on rupture of heart, ref., 527

- Nicolas and Beau*, on spleen in infection, ref., 152
- Nichols*, on experimental yaws, ref., 293; on ganglion cells in typhoid fever, ref., 243; on transplantation of organs, ref., 78; on tumor transplantation, ref., 354
- Nicolle*, on infective agent in typhus fever, ref., 300
- Nichols and Richardson*, on arthritis deformans, ref., 905
- Nipple, absence of, 842
eczema of, 843
inflammation of, 843
- Nissl's stain for nerve tissue, 982
- Nitric acid, 418
- Nitrobenzol poisoning, 423
- Nocard and Leclainche*, on infectious diseases of animals, 319
- Nocard and Roux*, on ultra-microscopic organism, 319
- Nocardia, 136, 232
- Noguchi, modification of Wassermann reaction, 281
- Noguchi and Cohen*, on trachoma bodies, ref., 309
- Noma, 644
of vulva, 794, 797
- von Noorden* on diseases of blood, ref, 471
- Normoblasts, 458
- Norris, C. C.*, on carcinoma of appendix vermiformis, ref., 690
- Norris, Charles*, on bacterial precipitins, 182; on myeloma, ref., 902
- Norris, G. W.*, on tuberculous pericarditis, ref., 521
- Norris and Larkin*, on streptothrix pneumonia, ref., 232
- Norris, Pappenheimer, and Flournoy*, on relapsing fever, 292
- Northrup*, on emphysema of lung, ref., 598; on reptilian heart, ref., 523; on tuberculous bronchial lymph-nodes, ref., 487
- Northrup and Crandall*, on scurvy in infants, ref., 438
- Norton*, on persistent thymus, ref., 511
- Nose, 579
adenoids, 581
bacteria in, 580
cysts of, 581
hæmorrhage from, 579
hay fever, ref., 580
inflammation of (see Catarrh), 579
Nose, lymph-vessels, of, ref., 580
malformations of, 579
mucous membranes of, 579
polyps of, 581
tumors of, 581
- Novy*, on pathogenic trypanosomes, ref., 118; on protozoa, ref., 115
- Novy and Knapp*, on relapsing fever, ref., 293
- Novy and McNeal*, on *Trypanosoma lewisi*, 117
- Noyes*, on accessory adrenals, ref., 515
- Nutmeg liver, 710
- Nutrition, disturbances of, 9
relationship of, to disease, 9
- Nuttall*, on blood relationships, 172, ref., 181; on rôle of insects in infection, ref., 151
- Nuttall and Shipley*, on anopheles in malaria, ref., 316
- Nux vomica poisoning, 424
- Nymphæ, anomalies of, 793
- Obermeier, spirochæte of, 292
- Occupation, relation of, to disease, 9
- Ochronosis, 55
- Odontoma, 387
- Œdema, 22
malignant, 291
of brain, 934
glottis, 582, 1011
labia, 793
larynx, 582
lung, 593
lymph-nodes, 482
pia mater cerebri, 913
uterus, 802
purulent, 200
- Oertel*, on echinococcus in liver, ref., 739; on necrosis of liver, ref., 715
- Œsophagitis, 653
- Œsophagus, 651
abscesses in, 653
cysts of, 654
dilatation of, 651
diverticula of, 652
examination, post-mortem, of, 1010
foreign bodies in, 652, 653
hæmorrhage in, 651
inflammation of, 653
malformations of, 651
perforation of, 651
rupture of, 651

- Esophagus, stenosis of, 652**
 syphilis of, 653
 tuberculosis of, 653
 tumors of, 653
 ulcer of, 651
 varices in, 651
Oidiomycosis cutis, 146
Oidium, 147
 albicans, in mouth, 147, 644
 vagina, 797
Oligocythæmia, 454, 456
Omentum, cysts of, 699
 examination, post-mortem, of, 1002
 hernia of, 670
 tumors of, ref., 698
Oophoritis, 827
 acute exudative, 827
 chronic interstitial, 828
 syphilitic, 829
 tuberculous, 829
**Ophûls, on "acid-proof" bacilli in gan-
 grene, ref., 600; on atypical typhoid,
 ref., 243; on corpora amylacea, ref., 50**
**Opie, on experimental atrophy of liver
 cells, 718; on filarial lymphatic varix,
 ref., 131; on hæmochromatosis, ref.,
 54; on lesions of pancreas, ref., 704;
 on leucocytic exudates after intra-
 peritoneal injection of bacteria, ref.,
 694; on proteolytic enzymes in phago-
 cyte, 105; on relation of pancreas to
 diabetes, ref., 435; on zonal necroses
 of liver, ref., 715**
**Opie and Meakins, on hæmorrhagic necro-
 sis of pancreas, ref., 705**
**Opitz, on entrance of bacteria through
 intestine, ref., 694**
Opium poisoning, 422
Oppenheim, on multiple sclerosis, ref., 972
**Oppenheimer, on bacterial poisons, ref.,
 152**
Opsonic index, 187
 in acute lobar pneumonia, 220
 power, determination of, 186
 substances, 183
Opsonins, 183
 clinical significance of, 186
 fixation of, 185
 in typhoid fever, 246
Orchitis, 857
 acute exudative, 857
 chronic, 858
 leptous, 860
 Orchitis, syphilitic, 860
 tuberculous, 858
Oriental plague, 288
Ornithodoros moubata, 293
**Orthmann, on retro-ovarian cysts, ref.,
 841**
Orth's fluid, 1029
**Oshima, on bacteria in mouths of healthy
 children, ref., 647; on malignant tumors
 of kidney in children, ref., 777**
**Osler, on cretinism, ref., 430; on hair balls
 in stomach, 666; on Madura foot, ref.,
 232**
**Osler and McCrae, on carcinoma of stom-
 ach in young, ref., 664**
Osmic acid, as fixative, 1029
Ossification, irregular, in rickets, 892
 syphilis, 888
 of bronchi, 592
Osteitis, 882
 condensing, 885
 ossifying, 883
 rarefying, 883
 suppurative, 885
 syphilitic, 888
 tuberculous, 887
 ulcerative, 891
Osteoblasts, 876, 881
Osteo-chondroma, 383
 of mamma, 848
Osteoclasts, 60, 103, 876, 883
Osteoid tissue, 878
Osteoma, 385
 of brain, 976
 bone, 899
 dura mater cerebri, 911
 lung, 634
 mamma, 848
 peritoneum, 697
 pia mater cerebri, 920
 muscle, 874
 penis, 855
 testicle, 860
Osteomalacia, 896
Osteomyelitis, 886
 chronic, 887
 infectious, acute, 886
 malignant, 887
Osteophytes, 386, 881, 889
Osteo-porosis, 883
Osteo-sarcoma, 373
Osteo-sclerosis, 885
Otis and Evans, in blastomycosis, ref., 146

- Otto*, on cysts of spleen, ref., 510
Ottolenghi, on bacteria in blood of cadaver, ref., 987
 Ovarian pregnancy, 842
 Ovaries, 826
 absence of, 826
 cystadenomâ of, 830
 cysts of, 830, 836, 837
 displacements of, 826
 ectopic pregnancy, 842
 examination, post-mortem, of, 1020, 1026
 hæmorrhage of, 827
 hernia of, 826
 hyperæmia of, 826
 hypertrophy of, 62
 inflammation of (see Oophoritis), 827
 malformations of, 826
 malpositions of, 826
 preservation of, 1020
 regeneration of, 73
 size of, 1020
 changes in, 826
 syphilis of, 829
 teratoma of, 836
 thyroid tissue in, ref., 836
 transplantation of, ref., 78
 tuberculosis of, 829
 tumors of, 829
 weight of, 1020
 Ovula Nabothi, 805, 822, 1020
 Oxalic acid, 419
 Oxyuris in vagina, 797
 vermicularis, 128
 Oysters and typhoid fever, 245
 Pacchionian bodies, 912, 992
 Pachydermia diffusa, 583
 verrucosa, 583
 Pachymeningitis, 909, 922
 acute externa, 909, 922
 interna, 909
 chronic, 909, 922
 interna hæmorrhagica, 910, 922
 syphilitic, 911
 tuberculous, 911, 922
Packard, on faucial tonsils, ref., 649
 Paget's disease, 843
 Palate, cleft, 643
 Pancreas, 701
 absence of, 701
 accessory, 701
 69
 Pancreas, atrophy of, 702
 autodigestion of, 702
 bacteria in, 705
 calculi in ducts of, 707
 cholelithiasis, effect of, on, 705
 concretions in ducts of, 707
 cysts of, 706
 degeneration of, 703
 diabetes, relation of, to, 435, 703
 displacements of, 701
 ducts, dilatation of, 706
 examination, post-mortem, of, 1017
 fat necrosis of, 704
 foreign bodies in ducts of, 707
 gangrene of, 705
 gummata in, 706
 hæmorrhage in, 705
 infiltration, fatty, of, 703
 inflammation of, 705
 Langerhans' islands, degeneration of, 703
 lesions of, in diabetes, 435, 703
 cirrhosis of liver, 728
 malformations of, 701
 necrosis of, 704
 parasites of, 707
 preservation of, 1018
 size and weight of, 1017
 syphilis of, 706
 tuberculosis of, 706
 tumors of, 706
 Pancreatic duct, malformations of, 701
 Pancreatitis, 705
 Pancreolytic serum, 174
 Pandemic disease, 159
 Papilloma, 364
 of bladder, urinary, 786
 Fallopian tubes, 841
 gall-ducts, 743
 kidney, 776
 larynx, 585
 mouth, 645
 œsophagus, 653
 ovary, 829, 835
 penis, 854
 stomach, 662
 vagina, 797
 vulva, 794
Pappenheimer, on thymus, ref., 511
 Pappenheim's method of staining tubercle bacilli, 258
 Paraffin embedding, 1033
 Paralysis, acute ascending, 969

- Paralysis, infantile, 299
 Landry's, 969
 spinal, infantile, 967
 spastic, 955
- Parametritis, 808
- Paraphimosis, 854
- Paraplegia, ataxic, 962
 spastic, 955
- Parasite, 332
- Parasites, animal, 114
 in blood, 470
 plant, 133
- Parathyroid glands, 514
- Paratyphoid, 247
- Parenchymatous degeneration, 39
- Paresis, general, lesions of brain in, 972
- Paris green poisoning, 421
- Park, R., on osteomyelitis, ref., 887
- Park, W. H., on agglutination tests in classification, ref., 181; on B. influenzae, ref., 234; on serum therapy, ref., 165
- Park and Krumweide, on types of B. tuberculosis, ref., 266
- Park and Williams, on B. dysenteriae ref., 677; on bacteriology, 133; on diphtheria antitoxin, 285; on infection of children with bovine tuberculosis, ref., 266; on preventive inoculations in hydrophobia, ref., 298; on protozoa, ref., 115; on typhoid carrier, ref., 245
- Parotid gland, 699
 inflammation of, 699
 tuberculosis of, 700
 tumors of, 700
- Parotitis, 699
- Parovarium, cysts of, 837
- Parsons, on bone lesions in typhoid fever, ref., 243
- Pässler and Heineke, on hypertrophy of heart, ref., 554; on relation of hypertrophy of heart to kidney disease, ref., 768
- Pasteur method in hydrophobia, 297
- Pathological morphology, characterization of, 5
 physiology, characterization of, 5
 specimens, preservation of, 1027
- Pathology, classifications of, 6
 comparative, 319
 definitions of, 3, 5
 divisions of, 5
 general introduction to, 3
 special, 451
- Paulowsky, on elimination of bacteria in body, ref., 151
- Payr, on transplantation of thyroid, ref., 78
- Pearce, on cytolytins, 175; on degeneration of heart muscle, ref., 541; on experimental cirrhosis, ref., 730; on hæmagglutinins and liver necroses, ref., 715; on islands of Langerhans, ref., 704; on leptothrix, ref., 232; on œdema, ref., 22; on pancreas in congenital syphilis, ref., 706; on regeneration of kidney, ref., 72; on regeneration of liver, ref., 717; on thrombi, ref., 26
- Pearce and Winne, on hæmagglutinins and liver necroses, ref., 715; on thrombi, ref., 26
- Pearce, Hill, and Eisenbrey, on experimental nephritis, ref., 769
- Pearls, epithelial, 407
- Pearson, on animal immunization against tuberculosis, ref., 262
- Pediculus capitis, 132
 vestamenti in Mexican typhus, 301
- Pellew, on arsenic poisoning, ref., 421
- Penis, 853
 absence of, 853
 balanitis, 854
 calcification of, 855
 calculi of, 855
 condyloma of, 854
 corpora cavernosa, inflammation of, 854
 cysts of, 855
 elephantiasis of, 855
 enlargement of, 853
 epispadias, 853
 erysipelas of, 854
 examination, post-mortem, of, 1018
 furuncles of, 854
 hæmorrhage in, 854
 herpes of, 854
 hypospadias, 853
 indurations of, 854
 inflammation of, 854
 injuries of, 854
 malformations of, 853
 ossification of, 855
 paraphimosis, 854
 phimosis of, 854
 congenital, 853
 syphilis of, 854
 tuberculosis of, 854

- Penis, tumors of, 854
 ulcers of, 854
 Pentastomum denticulatum in liver, 739
 lymph-nodes, 497
 spleen, 511
 Periarteritis, 559
 nodosa, 566
 Pericarditis, 518
 acute, 519
 bacteria in, 520
 chronic, 520
 exudative, 519
 fibrinous, 519
 obliterative, 520
 purulent, 520
 sero-fibrinous, 519
 suppurative, 520
 tuberculous, 521
 Pericardium, 518
 air in, 518
 calcification of, 520
 cysts of, 522
 dropsy of, 518
 examination, post-mortem, of, 1004
 fibroid nodules in, 521
 gas in, 518
 hæmorrhage in, 518
 hydro-, 518
 inflammation of, 518
 pneumo-, 518
 tuberculosis of, 521
 tumors of, 522
 Perihepatitis, 733
 Perimetritis, 808
 Perinephritic suppuration, 772
 Periosteum, hæmorrhage in, 877
 hyperæmia of, 877
 inflammation of (see Periostitis), 878
 tumors of, 899
 Periostitis, 878
 exudative, 879
 fibrous, 880
 ossifying, 880
 suppurative, 879
 syphilitic, 881
 tuberculous, 882
 Periphlebitis, 573
 Peripneumonia of cattle, organism of, 319
 Perisplenitis, 507
 Peritoneum, 691
 absorption from, ref., 111, 694
 ascites of, 692
 cysts of, 699
 Peritoneum, hæmorrhage in, 692
 inflammation of (see Peritonitis), 692
 malformations of, 691
 parasites of, 699
 tuberculosis of, 695
 tumors of, 696
 Peritonitis, 692
 acute, 692
 bacterial excitants of, 694
 cellular, 692
 chronic, 695
 chronic, 694, 695
 exudative, 693
 gonococcus, ref., 694
 suppurative, 693
 tuberculous, 695
Perkins, on *B. mucosus capsulatus*, ref., 216
Perkins and Pay, on bacteria in smallpox, ref., 305
Perrone, on appendicitis, 688
 Pertussis, 317
 Pest (see Plague), 288
 Petechiæ, 21
Peterson, on non-malignant rectal strictures, ref., 684
Peterson and Haines, on legal medicine, 426
Petruschky, on ray fungi, ref., 232
 Peyer's patches in typhoid fever, 235
Pfaff, on œsophageal diverticula, ref., 652
Pfeiffer, on bacteriolysis, 170
 phenomenon, 170
 Phagocytes, 99, 161
 action of, 105, 111
 counting, 187
 enzymes in, 105
 forms of, 103
 in cytolysis, 178
 Phagocytic count, 187
 Phagocytosis, 98, 183
 by leucocytes, 463
 experimental study of, 110
 Phagolysis, 179
 Pharyngitis, 648
 adenoids in, 648
 catarrhal, 648
 tuberculous, 649
 Pharyngo-mycosis leptothrica, 232
 Pharynx, 647
 abscess in, 648
 adenoids, 648, 649, 650

- Pharynx, as portal of entry for tubercle bacilli, 650
 cysts of, 647
 diverticula of, 647
 examination, post-mortem, of, 1010, 1025
 fistulæ of, 647
 inflammation of (see Pharyngitis), 648
 lesions of, 581
 malformations of, 647
 mycosis of, 647
 polyps of, 650
 preservation of, 1011
 tuberculosis of, 649
 tumors of, 650
- Phimosis, 854
 congenital, 853
 para-, 854
- Phlebectasia, 572
- Phlebitis, 573
 acute infective, 573
 chronic, 574
 endo-, 574
 peri-, 574
 syphilitic, 575
 tuberculous, 575
- Phleboliths, 27, 533
- Phlegmon, 200
 gaseous, 290
- Phloridzin diabetes, ref., 435
- Phloroglucin as decalcifying agent, 1031
- Phosphorus necrosis of bone, 890
 poisoning, 419
 fat embolism in, 34
- Phthisis, 627
- Pia mater cerebri, 912
 blood in, 913
 bone in, 921
 cysts of, 921
 hæmorrhage in, 913
 hyperæmia of, 913
 inflammation of (see Meningitis), 914
 œdema of, 913
 Pacchionian bodies in, 912
 parasites of, 921
 pigmentation of, 914, 921
 structure of, 912
 syphilis of, 919
 tuberculosis of, 918
 tumors of, 919
- Pia mater cerebri, examination, post-mortem, of, 992
 methods of hardening, 998
 spinalis, 922
 bone in, 923
 cartilage in, 923
 hæmorrhage in, 922
 inflammation of (see Meningitis, spinal), 923
 parasites of, 923
 tuberculosis of, 923
 tumors of, 923, 977
- Pic and Bonnamour*, on arterio-sclerosis, ref., 565
- Pic*, on hydatid moles, ref., 826; on ochronosis, ref., 55
- Picro-acid-fuchsin stain, 1036
- Pierson and Ravenel*, on moulds, ref., 147
- Pigment, anthracotic, 53, 616
 extraneous, 53, 56
 hæmatogenous, 53
 hepatogenous, 53, 54
 in blood, 470
 metabolic, 55
 of red blood cells, 456
 skin, ref., 55
- Pigmentation, 53
 of adrenals, 516
 bone marrow, 877
 brain, 933
 heart, 529
 liver, 714, 721, 730
 lungs, 601, 616
 lymph-nodes, 483
 muscle, 868
 nerve cells, 943
 pia mater cerebri, 914, 921
 pleura, 641
 spleen, 501
- Piles, 684
- Pilocarpin exudates, 195
- Pineal gland, lesions of, 980
- Pinworm, 128
- Piroplasma bigeminum, 122
- Pituitary body, 517, 980
- Pityriasis versicolor, 148
- Placenta, 822
 apoplexy of, 823
 calcification of, 823
 cysts of, 826
 degenerations of, 823
 hæmorrhage in, 823
 infarction of, 823

- Placenta, inflammation of, 823**
 lesions of, 822
 moles of, 824
 polyps in, 824
 structure of, *ref.*, 822
 syphilis of, 823
 tuberculosis of, 823
 tumors of, 824
Plague, bacillus of, 288
 bubonic, 288
 lobular pneumonia of, 612
 insects and, 289
 insects as carriers of, *ref.*, 151
 oriental, 288
 preventive inoculation in, 289
 pulmonary, 288
 rats and squirrels and, 289
 septicæmic, 288
 swine, bacillus of, 289
Plant parasites, 133
Plasma cells, 74, 93, 462
Plasmodium malarie, 312
Plaut, on yeasts and moulds in disease,
ref., 149
Pleomorphism, in bacteria, 136
Plethora, 16, 455
Pleura, 636
 air in, 637
 as portals of entry for bacteria, *ref.*,
 614
 calcification of, 639
 cysts of, 642
 echinococcus of, 642
 empyema, 638
 gas in, 637
 hæmorrhage in, 637
 hydro-pneumothorax, 637
 hydrothorax, 636
 inflammation of (*see* Pleuritis), 637
 pigmentation of, 641
 pyo-pneumothorax, 637
 tuberculosis of, 640
 tumors of, 641
Pleural cavities, air in, 637
 tests for, 1003
 examination, *post-mortem*, of,
 1003, 1009, 1025
 gas in, 637
Pleurisy (*see* Pleuritis), 637
Pleuritic adhesions, 640
Pleuritis, 637
 acute, 637
 chronic, 640
Pleuritis, dry, 637
 exudative, 637
 fibrinous, simple, 637
 sero-fibrinous, 637
 excitants of, 638
 sicca, 637
 suppurative, 638
 tuberculous, 640
 with effusion, 637
Plimmer bodies, 348
Pneumococcal vaccines, 220
Pneumococco-opsonic index, 220
**Pneumococcus (*see* Diplococcus pneu-
 monie), 218**
 lanceolatus, 217
 of Fränkel, 217
 Friedländer, 216
Pneumonia, 600
 aspiration, 611
 broncho-, 608, 609
 excitants of, 612, 613
 exudates in, 611
 tuberculous, 624
 cheesy, 627
 classification of, 603
 cooling of body as determining, 614
 crisis in, 219, 606
 croupous, 603
 excitants of, 218
 experimental, *ref.*, 614
 in animals, *ref.*, 614
 exudative, 603
 fibrinous, 603
 hæmatogenous, 611
 hypostatic, 612
 interstitial, 614
 lobar, acute, 603
 associated lesions in, 606
 bacteria in, 607
 complications of, 606
 concurrent infection in, 607
 delayed resolution in, 607
 diplococcus of, 218
 experimental, 218, 614
 mixed infection in, 607
 statistics of, 606
 suppurative inflammation
 in, 607
 lobular, 608
 excitants of, 613
 exudate in, 611
 "organizing," 607
 "patchy," 608

- Pneumonia, "purulent infiltration" in,** 608
 pyæmic, 611
 reversion of epithelium in, 615
 septic, 611
 syphilitic, 633
 tuberculous, 618
Pneumokoniosis, 56, 616
Pneumonitis (see Pneumonia), 600
Pneumomycosis, ref., 147
Pneumopericardium, 518
Pneumothorax, 637
Poikilocytes, 457
Poisoning, examination, post-mortem,
 in cases of, 1014, 1016, 1022
 meat, 291
Poisons, 417
 abrin, 153, ref., 203, 425
 aconite, 425
 alcohol, 423
 aloes, 422
 ammonia, 419
 animal venom, etc., 424
 arsenic, 420
 bacterial, 139, 152
 bibliography of, 426
 cantharides, 422
 carbolic acid, 423
 carbonic oxide, 425
 chloral hydrate, 424
 chloroform, 424, 716
 colchicum, 422
 colocynth, 422
 conium, 425
 copper, 422
 corrosive sublimate, 421
 croton oil, 422
 cyanide of potassium, 423
 digitalis, 425
 elaterium, 422
 endogenous, 417, 426, 427
 ether, 424
 exogenous, 417
 fungi, 423
 gamboge, 422
 hellebore, 422
 histogenic, 427
 hydrochloric acid, 418
 hydrocyanic acid, 423
 jalap, 422
 lead, 421
 lesions induced by, 417
 lobelia, 425
 Poisons, morphin, 422
 nitric acid, 418
 nitrobenzol, 423
 nux vomica, 424
 opium, 422
 oxalic acid, 419
 Paris green, 421
 phosphorus, 419
 potash, 419
 potassium nitrate, 419
 potassium oxalate, 419
 ptomain, 425
 ricin, 153; ricin, ref., 203, 425
 savin, 422
 scammony, 422
 Scheele's green, 421
 soda, 419
 stramonium, 425
 strychnin, 424
 sulphuric acid, 417
 tartar emetic, 422
 tartaric acid, 419
 turpentine, 422
 vegetable irritants, 422
 venom, animal, 153, 424
 veratria, 422
 Polaillon, on lung stones, ref., 639
 Polar body, 65
 Poliomyelitis, acute anterior, 299, 967
 communicability of, 300
 immunity in, 300
 Polycythæmia, 454
 Polymyositis, acute primary, 874
 Polyps, adenoid, 650
 of bronchi, 592
 heart, 531
 intestine, 688
 nose, ref., 580, 581
 pharynx, 650
 placenta, 824
 urethra, 792
 uterus, 803, 810
 Popon, on arsenic poisoning, 421
 Porcile, on plasma cells in liver, ref., 74
 Porencephalus, 979
 Portal vein, lesions of, 711
 Porter, on coronary arteries, ref., 537
 Possell, on echinococcus in liver, ref., 739
 Post-mortem changes in blood distribu-
 tion, 986, 990
 in cholera, 248
 pyæmia, 204
 septicæmia, 204

- Post-mortem contusions, 989
 cooling of body, 988
 cultures, 1021
 decomposition, 987
 discoloration of viscera, 1002
 examination, 985
 after asphyxia, 442
 drowning, 444
 strangulation, 443
 closure of body after, 1021
 external inspection, 986
 for bacteria, 1021
 internal inspection, 990
 lividity, cadaveric, 986
 medico-legal, 1022
 method of making, 986
 of abdomen, 1001, 1025
 adrenals, 1013, 1026
 aorta, 1018
 base of cranium, 998
 bladder, 1018, 1019, 1026
 bones, 1026
 brain, 992, 1024
 bronchi, 1009
 diaphragm, 1003
 dura mater, 992
 ear, 988
 eyes, 998
 Fallopian tubes, 1020
 gall-bladder, 1016
 -ducts, 1016
 genito-urinary organs, fe-
 male, 1019, 1026
 male, 1018, 1026
 hæmolymp-nodes, 1018
 head, 991, 1024
 heart, 1004, 1025
 internal ear, 998
 intestine, 1002, 1014, 1026
 kidney, 1011, 1026
 larynx, 1010, 1025
 liver, 1002, 1016, 1026
 lung, 1009, 1025
 new-born, 1023
 œsophagus, 1010
 omentum, 1002
 ovaries, 1020
 pancreas, 1017
 pericardium, 1004
 pharynx, 1010, 1025
 pia mater, 992
 pleural cavities, 1009, 1025
 prostate gland, 1018
- Post-mortem examination of solar plexus,
 1018
 spinal cord, 999
 spleen, 1013, 1026
 stomach, 655, 1003, 1015,
 1026
 testicles, 1018
 thoracic duct, 1018
 thorax, 1001, 1024
 thymus, 1025
 thyroid, 1010, 1025
 trachea, 1011
 umbilical cord, 1026
 urethra, 1018
 uterus, 1019
 vagina, 1019
 vesiculæ seminales, 1018
 vulva, 1019
 putrefactive changes, 987
 fractures, 990
 gas formation, 987
 hypostasis, 986
 identification, 986
 lividity, 986
 marks of violence, 989
 putrefaction, 987
 rigidity, 988
 rise of temperature, 988
 softening of viscera, 1002
 wounds, 990
- Potash poisoning, 418
 Potassium bicarbonate in Müller's fluid,
 1029
 nitrate poisoning, 419
 oxalate poisoning, 419
Potter, Diltman, and Bradley, on opsonins,
 ref., 187
Powers, on carcinoma of branchial cleft,
 ref., 651
Pratt, on coronary arteries, ref., 537; on
 histology of acute lobar pneumonia,
 ref., 606; on paratyphoid, ref., 247;
 on typhoid bacillus, ref., 244
Preble, on gastro-intestinal hæmorrhage
 in cirrhosis, ref., 728; on œsophageal
 varices, ref., 651; on pneumococcus
 endocarditis, ref., 544
Preble and Hektoen, on multiple neuroma,
 ref., 393
 Precipitating substances, 181
 Precipitin test in forensic medicine, 181
 technique of, 194
 Precipitins, 181

- Precipitins, anti-, 182
 in typhoid fever, 246
 nature of, 182
- Pregnancy, abdominal, 842
 chorionepithelioma of, 820
 extra-uterine, 841
 interstitial, 842
 ovarian, 842
 toxæmia of, liver in, 718
 tubal, 841
 tubo-abdominal, 842
 vomiting, pernicious, in, 718
- Prepuce, absence of, 853
 lesions of, 854
- Preservation of tissues, 1029
- Pribram*, on bacterial hæmolysins, ref., 153
- Proescher and Reddy*, on paratyphoid, ref., 247
- Proglottides of tapeworm, 124
- Prolapsus uteri, 801
- Prosopothoracopagus, 330
- Prostate, 863
 abscess of, 866
 atrophy of, 863
 concretions of, 866
 cysts of, 866
 degenerations of, 863
 examination, post-mortem, of, 1018
 hyperplasia of, 864
 hypertrophy of, 863
 inflammation of, 864
 parasites in, 866
 tuberculosis of, 866
 tumors of, 866
- Prostatitis, 864
- Proteids, defensive, 161
 protective, 109
- Proteins, 3
- Proteus group of bacilli, 216
- Prothrombin, 452
- Protoplasmic processes, 944
- Protozoa, 114
 classification of, 115
 cultivation of, 115
 effects of, 115
 in infectious diseases, 317
 tumors, 347
 methods of study of, 122
 modes of transmission of, 114
- Proud flesh, 95
- Prudden*, on bacteria in exudative pleuritis, ref., 638; on dead tubercle bacilli, ref., 260; on experimental tuberculosis, ref., 631; on malignant endocarditis, ref., 545; on multiple neuroma, ref., 393; on pseudo-hypertrophy of muscle in multiple neuroma, ref., 871; on pseudo-membranous inflammation, ref., 212; on rhabdomyoma of parotid gland, ref., 390;
- Prudden and Hodenpyl*, on dead tubercle bacilli, ref., 260
- Psammoma, 376
 of dura mater cerebialis, 912
 spinalis, 922
 pia mater cerebialis, 920
- Pseudo-diphtheria, 212
 bacillus, 285
- Pseudo-hermaphrodites, 793
- Pseudo-hermaphroditism, 853
- Pseudo-hypertrophy of muscle, 871
- Pseudo-leukæmia, 489
 granulomatous, 491
 infantum, 479
 spleen in, 509
- Ptomain poisoning, 425
- Ptomain, bacterial, 139
- Puerperal fever, 808
- Purpura hæmorrhagica, 438
- Pus, 89, 201
 cells, 201
- Pustules, 199
 malignant, 228
- Putnam*, on hæmorrhagic encephalitis, ref., 965
- Putnam and Taylor*, on spinal-cord degeneration, ref., 963
- Putrefaction, post-mortem, 987
- Pyæmia, 203
 crypto-genetic, 204
 post-mortem changes, 204
 septicæ-, 204
- Pycnosis, 57
- Pyelitis, 771
- Pyelo-nephritis, chronic, 771
 suppurative, 771
- Pygopagus, 331
- Pylorus, stenosis of, 662
 congenital, 654
- Pyogenic bacteria, 205
- Pyo-pneumothorax, 637
- Pyosalpinx, 840
- Pyo-septicæmia, ref., 204
- Pyramids, anterior, 952
- Pyrexia, 440

- Quarter-evil, 291
Quenu and Branca, on regeneration of intestinal epithelium, ref., 682
 Quinsy, 649
- Rabies (see Hydrophobia), 294
 Race, relationship of, to disease, 13
 Rachitis, 891
 foetal, 896
 Radium, injuries from, 11
 Radziewsky, on bacterial infection, ref., 153
 Rainey, tubes of, 121
Ramsay, on tumors of adrenals, ref., 517
 Ranula, 646, 700
Raschkes, on endothelioma of vagina, ref., 797
Ravenel, on bovine tubercle bacillus, ref., 260; on entrance of bacteria through intestine, ref., 694; on human and bovine tuberculosis, ref., 266; on portals of entry of *B. tuberculosis*, ref., 264
Ravenel and McCarthy, on lesions of hydrophobia, ref., 294
Raviart, on tuberculosis of heart, ref., 542
 Ray fungus, 231
 Receptors, 166
 Rectocele vaginalis, 796
 Rectum, 683
 examination, post-mortem, of, 1018
 hæmorrhoids, 684
 inflammation of, 683
 strictures of, 684
Reed, on focal necrosis in typhoid fever, ref., 241; on Hodgkin's disease, ref., 495
Reed and Carroll, on excitant of yellow fever, ref., 302; on mosquito in yellow fever, ref., 303
Reed, Carroll and Agramonte, on mosquito in yellow fever, ref., 303
Reed, Vaughan and Shakespeare, on typhoid fever in army camps, ref., 245
 Regeneration, 64
 of bladder mucosa, ref., 71
 blood, 77
 blood-vessels, 75
 bone, 76
 bone-marrow, 76
 cartilage, 76
 cells, 68
 impulse to, 79
 connective tissue, 73
 Regeneration of endothelium, 75
 epithelium, 71
 fat tissue, 77
 kidney, 72
 liver, 72
 lymph-nodes, 76
 lymph-vessels, 76
 mammary-glands, 72
 mucous membranes, ref., 71
 muscle tissue, 70
 nerve tissue, 68, 951
 ovary, 73
 salivary glands, 72
 testicle, 73
 thyroid, 72
 Regression in cells, 35
Reinbach, on colloid, ref., 513; on granulation tissue, ref., 95
Reineboth and Kohlhardt, on cooling of body and pneumonia, ref., 614
 Relapsing fever, 292
 in animals, 292
Renon, on aspergillus, ref., 147
 Reproductive organs, female, 793
 male, 853
 Resolution in inflammation, 90
 Resorption, 23
 in inflammation, experimental study of, 110
 Respiration, relation of, to circulation of blood, 16
 Respiratory system, lesions of, 579
 Reversion, 63
 Rhabdomyoma, 390
 of heart, 556
 muscle, 875
 parotid, 701
 testicle, 861
 Rhabdonema strongyloides, 131
 Rheumatism, acute, 318
 articular, 904
 Rhexis, hæmorrhage by, 20
 Rhinitis, 579
 acute catarrhal, 579
 chronic catarrhal, 580
 pseudo-membranous, 580
 syphilitic, 580
 tuberculous, 580
 Rhinoscleroma, 281
 Rhizopoda, 115
Rhodes, on hæmorrhage of larynx, ref., 582
Ribbert, on appendicitis, ref., 688; on cell

- regeneration, 79; on cholesteatomata, ref., 379; on chordoma, ref., 385; on compensatory hypertrophy, ref., 80; on fatty degeneration, 41; on liver cirrhosis, ref., 730; on metaplasia, ref., 63; on miliary tubercles, ref., 252; on regeneration of lymph-nodes, ref., 486; on reversion, ref., 63; on tissue transplantation, ref., 78; on tuberculosis of pleura, ref., 641; on tumors, 416
- Ribbert's hypothesis of origin of tumors, 351
- Richter*, on ilio-cæcal tuberculosis, ref., 683
- Ricin poisoning, 153, ref., 203, 425
- Ricker*, on relationship of yeasts and moulds to human disease, ref., 149
- Ricketts, 891
fœtal, 896
- Ricketts*, on blastomycosis, ref., 146; on immunity, 196; on infection in Rocky Mountain fever, 301
- Ricketts and Gomez*, on Rocky Mountain spotted fever, 301
- Ricketts and Wilder*, on Mexican typhus, 301
- Richelmann*, on statistics of carcinoma, ref., 404
- Rieder*, on leucocytosis, ref., 464
- Riesman*, on Meckel's diverticulum, ref., 667; on pulmonary œdema, ref., 595
- Rigor mortis, 988
- Ring worm, 148
- Ritchie*, on bacteria in bronchitis, ref., 588; on cystic kidney, ref., 774; on immunity, 196
- v. *Ritók*, on arterial hypoplasia, ref., 1018
- Rizford and Gilchrist*, on protozoan infection, 121
- Robertson*, on tonsillar calculi, ref., 649
- Robin*, on precipitin test, ref., 182
- Robinson*, on pulmonary complications in typhoid fever, ref., 243
- Rocky Mountain spotted fever, 301
- Rodet, Lagriffoul, and Aly Wahby*, on soluble poisons of typhoid bacillus, ref., 235
- Roentgen rays, injury from, 11
- Roger*, on conditions of disease, ref., 14
- Roger and Garnier*, on tuberculosis of thyroid, ref., 512
- Rolleston*, on carcinoma of intestine, ref., 690; on diseases of liver, ref., 725
- Rolleston and Crofton Atkins*, on pyloric stenosis, ref., 655
- Rolleston and Hayne*, on congenital cirrhosis, ref., 729
- Rolly and Liebermeister*, on death of bacteria in small intestine, ref., 681
- Rosenau*, on collodium sacs, ref., 319; on viability of *B. tuberculosis*, ref., 257
- Rosenau and Anderson*, on anaphylaxis, ref., 190
- Rosenberger*, on acid-fast bacteria, ref., 267; on bacteriology of blood, ref., 470; on tuberculosis of mesenteric nodes, ref., 674
- Rosenow*, on blood cultures in pneumonia, ref., 606; on *D. pneumoniæ* in blood, 218; on leucocytosis in pneumonia, 220; on pneumococcus serum, 219
- Ross*, on method of counting phagocytes, ref., 187
- Ross and Milne*, on tick fever, ref., 293
- Round worms, 127
- Roux*, on invisible microbes, ref., 319
- Ruckert*, on bone in tonsil, ref., 649
- Ruediger*, on destruction of streptococci, 211
- Russell bodies, 347
- Russell*, on ovarian cysts, ref., 836; on preventive inoculation in typhoid fever, ref., 246
- Russell and Fuller*, on typhoid bacillus in water, ref., 245
- Russell, Batten, and Collier*, on spinal-cord degeneration, ref., 963
- Rutimeyer*, on Friedrich's ataxia, ref., 963
- Ruzicha*, on theory of vital staining, ref., 1027
- Saccharomyces, 146
- Sacerdotti*, on hypertrophy of kidney, ref., 747
- Sachs*, on indurations of corpora cavernosa penis, ref., 854
- Sacral region, tumor of, 359
teratomata, 333
- Sago spleen, 500
- Sailer and Rhein*, on eventration of diaphragm, ref., 692
- Saliva, action of, on bacteria, ref., 150
- Salivary glands, 699
calculi in ducts of, 700
ducts of, 700
inflammation of, 699

- Salivary glands, regeneration of, 72
 tumors of, 700
 mixed, 700
- Salpingitis, 839
- Salvetti*, on congenital rickets, ref., 891
- Sanarelli*, on *B. icteroides*, ref., 302
- Sand, intestinal, 691
- Saprophytes, 141
- Sarcina, 135
- Sarcodina, 115
- Sarcoma, 366
 adeno-, 376
 alveolar, 375
 angio-, 374
 chondro-, 376
 cysto-, 375
 fibro-, 376
 giant-celled, 372
 glio-, 370, 388
 lipo-, 376
 lympho-, 370
 melano-, 370
 mixed forms, 375
 myelogenic, 901
 myeloid, 372
 myo-, 376
 myxo-, 376
 of adrenals, 517
 appendix vermiformis, 690
 arteries, 571
 bladder, urinary, 786
 bone, 900
 brain, 977
 bronchi, 591
 dura mater cerebri, 911
 spinalis, 922
 ependyma, 927
 Fallopian tubes, 841
 heart, 556
 intestine, 690
 kidney, 776
 larynx, 585
 liver, 737
 lung, 634
 lymph-nodes, 497
 mammary, 850
 male, 867
 muscle, 875
 nerves, 979
 nose, 581
 oesophagus, 653
 ovaries, 829
 pancreas, 706
- Sarcoma of penis, 855
 pericardium, 522
 peritoneum, 697
 pharynx, 651
 pia mater cerebri, 921
 spinalis, 923
 pleura, 641
 prostate, 866
 salivary glands, 700
 spinal cord, 977, 978
 spleen, 510
 testicle, 861
 thymus, 511
 thyroid, 514
 tongue, 646
 uterus, 813
 vagina, 797
 veins, 575
 vulva, 795
 osteo-, 373
 osteoid, 901
 parosteal, 901
 periosteal, 900
 round-celled, 369
 spindle-celled, 368
 transplantation of, in mice, 356
- Sarcoptes hominis*, 132
- Sarcosporidia, 121
- Sauerbeck*, on aggressins, ref., 153
- Savin poisoning, 422
- Sayer*, on pneumonumycosis, ref., 147
- Scagliosi*, on lesions of myocardium in diphtheria, ref., 283
- Scammony poisoning, 422
- Scarlat oil, injections of, effect of, 352
- Scarlatina, 307
 excitants of, 307
- Scarlet fever, 307
- Scars, post-mortem examination of, 990
- Schaffer*, on islets of gastric mucosa in oesophagus, ref., 651
- Schaudinn*, on entamoebahistolytica, 115;
 on *Treponema pallidum*, 119
- Schaudinn and Hoffmann*, on *Spirochæta pallida*, 274
- Scharlach R stain for fat, 44
- v. Scheibner*, on tonsils as portals of entry for tubercle bacilli, ref., 650
- Schilder*, on glioma of adrenal, ref., 517
- Schizomycetes, 133
- Schlagenhauser*, on sarcoma and carcinoma in same breast, ref., 850
- Schlegel*, on actinomycosis, ref., 232

- Schlesinger*, on streptococcus hæmolyticus, ref., 209
- Schmidt*, on amyloid tumors, ref., 646; on pathology of bone, ref., 903; on squamous epithelium in prostate, ref., 866
- Schmidtman*, on carbonic oxide poisoning, ref., 425
- Schmoll*, on Stokes-Adams' disease, ref., 550
- Schmorl*, on embolism of chorionic cells, ref., 821
- Schnarrwyler*, on phlegmonous gastritis, ref., 659
- Schorr*, on complex tumors of mouth, ref., 645
- Schottmüller*, on *S. mucosus capsulatus*, ref., 221
- Schridde*, on congenital absence of appendix, ref., 667; on Giemsa's stain, 1037
- Schridde and Naegeli*, on fixation of blood, ref., 467
- Schultze*, on crypts of Lieberkuhn, ref., 682; on cyst of stomach, ref., 666; on degeneration of nervous system, 954; on lymphatic leukæmia, 462
- Schulze*, on *B. tuberculosis*, ref., 257
- Schwalbe*, on malformations, ref., 320
- Schwann*, sheath of, 944
- Schwarz*, on disappearance of bacteria from blood, ref., 151
- Scirrhus*, 411
- Sclérose en plaque*, 971
- Sclerosis, amyotrophic lateral, 956
 - multiple, of brain, 971
 - spinal cord, 973
 - of brain, 971
 - coronary arteries, 537
 - spinal cord, 957
 - posterior spinal, 957
- Scolex, 124
- Scorbutus, 437
 - infantile, 437
- Scrofula 487
- Scrotum, cysts of, 855
 - elephantiasis of, 855
 - malformations of, 853
 - teratoma of, 855
 - tumors of, 855
 - varicocele of, 856
- Scudder*, on tuberculosis of breast, ref., 846
- Scurvy, 437
- Sébileau*, on orchitis, 860
- Secretions, internal, 427
 - internal, in acromegalia, 438
 - Addison's disease, 433
 - diabetes, 435
 - exophthalmic goitre, 432
 - myxœdema, 430
- Section cutting, 1034
- Seiffert*, on rhabdomyoma of heart, ref., 556
- Selective filtration, 86
- Seminal vesicles, lesions of, 863
 - tumors of, 863
- Seller*, on bacteria in healthy bodies, ref., 150
- Senility, ref., 36, 38
- Sensibilizing substance, 179
- Septicæmia, 152, 156, 203
 - hæmorrhagic, 289
 - in diphtheria, 284
 - plague, 288
 - post-mortem changes, 204
- Septico-pyæmia, 204
- Sequestrum, 59
 - of bone, 890
- Serum, 86
 - antitoxic, 164
 - collection of, for tests, 195
 - diagnosis of syphilis, 278
 - hæmolytic, 172
 - hæmotoxic, 172
 - hepatolytic, 174
 - inactivated, 172
 - injections of, in carcinoma, 356
 - leucolytic, 174
 - nephrolytic, 174
 - neurolytic, 174
 - of exudation, 86
 - pancreolytic, 174
 - reactivated, 172
 - spermatolytic, 174
 - therapy, 191
 - therapy in diphtheria, 164
 - therapy in meningitis, 226
 - thyreolytic, 174
- Serum-sickness, 190
- Seven-day fever, 292
- Sex, relation of, to disease, 13
 - relation of, to tumor growth, 344
- Shaw*, on chyloform ascites, ref., 692
- Sheath of Schwann, 944
- Sherrington, on elimination of bacteria in secretions, ref., 151

- Shiga, bacillus of, 677
- Ship fever, 300
- Shiple and Fearnside*, on parasites, ref., 123
- Shober*, on displacements of colon, ref., 667
- Side-chain hypothesis of Ehrlich, 165
- Siderosis of lung, 616
- Silbermann*, on sudden death following burns, ref., 10
- Silberschmidt*, on peritonitis, ref., 694
- Simmons*, on Hodgkin's disease, ref., 495
- Simon*, on blood, ref., 470; on resolution of exudate in pneumonia, ref., 606
- Sinus pocularis, dilatation of, 792
- Sittmann*, on elimination of bacteria by kidney, ref., 761
- Skin, blastomycosis of, 146
 bronzed, 433
 in yellow fever, 302
 melano-sarcoma of, 372
 pigmentation of, in Addison's disease, 433
 protective action of, against bacteria, ref., 150
 tuberculosis of, 267
- Slaughter*, on Haffkine method in plague, ref., 289
- Sleeping sickness, 118
- Smallpox, 303
 bacteria in, 305
 excitant of, 305
 immunization, artificial, in, 304, ref., 305
 protozoa in, 305
 vaccination in, 304
- Smegma bacillus, 267
- Smith, A. H.*, on carcinoma of thoracic duct, ref., 576
- Smith, Th.*, on adaptation of bacteria, ref., 160; on bacterial association in infection, ref., 157; on bovine tubercle bacillus, 260; on parasitism of *B. tuberculosis*, ref., 262; on sarcosporidia in mice, ref., 122; on transmitted immunity, 196
- Smith and Kilbourne*, on Texas fever, 122
- Soaps, rôle of, in formation of fat in cells, ref., 40
- Sobernheim*, on anthrax, 229
- Soda poisoning, 419
- Sodium sulphate in Müller's fluid, 1029
- Sokoloff*, on adeno-carcinoma of liver, ref., 736
- Solar plexus, examination, post-mortem, of, 1018
- Somatochromes, 943
- Soor, 644
- Specimens, preservation of, in gross, 1038
- Spengler*, on concurrent infection in tuberculosis, ref., 267
- Spermatocele, 857
- Spermolytic serum, 174
- Spider cells in glioma, 387
- Spina bifida, 326, 929
- Spinal apoplexy, 938
 cord, 928
 absence of, 928
 amyelia, 928
 apoplectic clots in, 938
 artefacts of, 928, 999
 arteries of, 933
 asymmetries of, 929
 atelomyelia, 928
 atrophy of muscle of, 955
 blood-vessels, lesions of, 942
 circulatory changes in, 933
 cysts of, 978
 degeneration of, 942
 diffuse, 963
 neurone in, 946
 primary, 955
 secondary, 953
 diastematomyelia, 928
 diplomylia, 928
 distortions of, 929
 embolism of, 942
 examination, post-mortem, of, 999, 1025
 hæmorrhage in, 938
 hæmatomyelia, 939
 hæmatomyelopore, 939
 heterotopia, 929
 false, 929
 hydromylia, 929
 hydrorrhachis externa, ref., 929
 interna, 929
 inflammation of (see Myelitis), 966
 injuries of, 931
 post-mortem, 999
 lesions of, in tabes, 958
 malformations of, 928
 morphology of, 942

- Spinal cord, post-mortem changes in, 999
 preservation of, 1001
 removal, post-mortem, of, 999
 sclerosis of, 971, 973
 segments of, 1001
 spina bifida, 929
 structure of, 942
 syphilis of, 975
 syringomyelia, 978
 false, 940
 thrombosis of, 942
 tuberculosis of, 974
 tumors of, 977
 vascular changes in, 933
 vessel walls, lesions of, 942
 weight of, 1000
 nerve roots, anomalies of, 929
 paralysis, spastic, 955
 infantile, 967
- Spiremes, 65
- Spirillum, 118, 134
 cholerae asiatica, 247, 249
 reproduction of, ref., 135
 toxic products of, 250
 fever, 292
 of Finkler and Prior, 250
 sputigenum, 251
 tyrogenum, 251
- Spirochæte, 118
 duttoni, 293
 in tumors, 119
 obermeieri, 119, 292
 in spleen, 511
 pallida (see *Treponema pallidum*),
 119, 274
 pertenuis, 294
 recurrentis, 292
 refringens, 275
- Spleen, abscess of, 504
 accessory, 499, 1014
 anæmia of, 501
 atrophy of, 500
 cysts of, 510
 degeneration of, 500
 displacements of, 499
 embolism of, 502
 examination, post-mortem, of, 1013,
 1026
 hæmorrhage in, 500
 hyperæmia of, 502
 hyperplasia of, 504, 508
 hypertrophy of, 62
- Spleen in infection, ref., 152
 leukæmia and pseudo-leukæmia,
 509
 malaria, 311
 relapsing fever, 292
 infarction of, 31 502,
 inflammation of (see Splenitis) 504
 lesions of, in cirrhosis of liver, 728
 in typhoid fever, 240
 malformations of, 499
 parasites of, 511
 pigmentation of, 501
 preservation of, 1014
 rupture of, 500
 sago, 500
 size of, 1014
 syphilis of, 506
 thrombosis in, 503
 tuberculosis of, 506
 tumors of, 510
 weight of, 1014, 1026
 wounds of, 500
- Splenectomy, in splenic anæmia, 480
- Splenic fever, 228
- Splenitis, chronic indurative, 505
 hyperplastic, 504
 peri-, 507
 suppurative, 504
 syphilitic, 507
 tuberculous, 507
- Splenomegaly, primary, 508
- Sporangium, 147
- Spores, in bacteria, 136
 yeast, 146
- Sporozoa, 115, 120
- Spotted fever, 300
 Rocky Mountain, 301
- Sputum, methods of staining, 258
- Staining methods, 1035
- Staphylococcus cereus, 208
 epidermis albus, 208
 pyogenes albus, 208
 pyogenes aureus, 205
 salivarius pyogenes, 208
- Starck, on œsophageal diverticula, ref.,
 639
- Starling, on internal secretions, ref., 427
- St. Arnold, on bony tumors of breast,
 ref., 848
- Stasis, 19
- Status lymphaticus, 439
- Stäubli, on animal parasites in blood, ref.,
 470

- Steele*, on sarcoma of peritoneum, ref., 698
- Stegomyia calopus*, 303
- Steinhaus*, on liver infarcts, ref., 713
- Stengel*, on Stokes-Adams' disease, ref., 550
- Stenosis of aorta, 552
 mitral valve, 553
 pylorus, 654, 662
 right heart, 553
- Stepanow*, on celloidin embedding, 1032
- Sterling, Anderson, and Rosenau*, on anaphylaxis, ref., 190
- Stern*, on malignant tumors in childhood, 416
- Sternberg* on "Bacillus X," ref., 302; on blastomycosis, ref., 146; on chloroma, ref., 376; on lesions of bronchial lymph-nodes, ref., 592; on tuberculosis of lymph-nodes, ref., 491
- Stiles*, on dissemination of carcinoma of the breast, ref., 851
- Stimson*, on preventive inoculations in hydrophobia, ref., 298
- Stimulins, 181
- Stokes*, on cysts of vagina, ref., 797
- Stokes-Adams' disease, 549
- Stomach, 654
 absence of, 654
 atrophy of, 656
 bacteria of, ref., 659
 cadaveric changes in, 655
 cysts of, 666
 degenerations of, 656
 dilatation of, 662
 displacement of, 662
 erosions, hæmorrhagic of, 662
 état mamelonné, 657
 examination, post-mortem, of, 655, 1003, 1015, 1026
 foreign bodies in, 667
 hæmorrhage in, 655, 662, 728
 hair balls in, 667
 inflammation of (see Gastritis), 656
 injuries of, 655
 malformations of, 654
 malpositions of, 654
 preservation of, 1016
 rupture of, 655
 syphilis of, 659
 tuberculosis of, 659
 tumors of, 662
 ulcers of, 660
- Stomatitis, aphthous, 644
 catarrhal, 643
 chronic, 644
 croupous, 644
 gangrenous, 644
 parasitic, 644
 phlegmonous, 644
 syphilitic, 644
 tuberculous, 644
 ulcerative, 644
- Stones, lung, 592
- Stramonium poisoning, 425
- Strangulation, 9
 death from, 443
- Straus*, on infantile paralysis, ref., 969; on tuberculosis, 268; on eclampsia, ref., 718
- Strawberry marks, 394
- Streptobacilli, 135
- Streptococci, 135
 anaërobic, ref., 210
- Streptococcus antitoxin, 211
 brevis, 209
 conglomeratus, 209
 erysipelatis, ref., 212
 in intestine, 678
 longis, 209
 mucosus capsulatus, 221
 in pneumonia, 221
 phagocytosis of, 211
 pyogenes, 209
 agglutination of, ref., 210
 artificial immunity to, 211
 bibliography of, ref., 211
 in inflammation, 88
- Streptothrix, 136
- Stricture of appendix, 686
 rectum, 684
 urethra, 790
- Stroebe*, on tuberculosis of aorta, ref., 567
- Strong*, on amœbic dysentery, ref., 116; on preventive inoculations in Asiatic cholera, ref., 250
- Strongylus gigas*, 128
 in kidney, 781
 longevaginatius, 128
 subtilis, 128
- Strouse*, on pneumococcus infections, ref., 219
- Struma, 513
 ovariorum, 836
- Stomatitis, 512

- v. Strumpel*, on primary acute polymyositis, ref., 874
 Strychnin poisoning, 424
Stuhlern, on *B. mucosus capsulatus*, ref., 216
 Subinfection, ref., 151
 Sublimate, corrosive, as fixative, 1030
 poisoning, kidney in, 51, 750, 753
 Sublingual gland, inflammation of, 700
 tumors of, 700
 Submaxillary gland, inflammation of, 700
Substance sensibilisatrice, 179, 183
 Sudan III, stain for fat, 44
 Suffocation, 9, 442
 Suggillations, 21
 Sulphuric acid, 417
 Sunstroke, 436
 Suppuration, 89, 94, 198
 Suprarenal bodies (see Adrenals), 515
 capsules (see Adrenals), 515
 Surra, 117
 Susceptibility to disease, 14
Sutton, introduction to general pathology, 416
 Swelling, cloudy, 39
 white, 25
 Symbiosis, 142
Symmers, on necrosis of liver, ref., 715
 Syncytium, 820
 Synophthalmia, 325
 Synotia, 321
 Syphilis, 270
 and tabes dorsalis, 962
 animal inoculations in, 274
 congenital, 273
 of bone, 888
 constitutional, 272
 diagnosis of, 274
 dioxydiamidoarsenobenzol in, 119
 etiology of, ref., 276
 immunization in, 276
 of adrenals, 516
 arteries, 567
 bone, 881, 888
 brain, 975
 bronchi, 589
 dura mater cerebri, 911
 endometrium, 807
 Fallopian tubes, 840
 heart, 542
 intestine, 674
 kidney, 770
 larynx, 584
 Syphilis of liver, 730
 lung, 633
 lymph-nodes, 488
 lymph-vessels, 577
 mammary, 846
 mouth, 644
 muscle, 875
 nervous system, 975
 nose, 580
 oesophagus, 653
 ovary, 829
 pancreas, 706
 penis, 854
 periosteum, 881
 pia mater cerebri, 919
 placenta, 823
 rectum, 683
 spinal cord, 975
 stomach, 659
 testicle, 860
 thymus, 511
 thyroid, 512
 urethra, 792
 vagina, 797
 veins, 575
 primary, 271
 secondary, 272
 serum diagnosis of, 278
 spirochetes in, 119, 274
 Spirochæta pallida in, 119, 274
 tertiary, 272
 Treponema pallidum in, 274
 Wassermann reaction, 278
 Syringomyelia, 978
 false, 940
 Tabardillo, 301
 Tabes dorsalis, 957
 lesions of nerves in, 957, 958
 syphilis, relation of, 962
Tænia cucumerina, 127
 echinococcus, 125
 flavopunctata, 127
 madagascariensis, 127
 mediocanellata, 124
 nana, 127
 saginata, 124
 solium, 124
 Talipes, 326
 Talipomanus, 326
 Tape worms, 124
 Tartar emetic poisoning, 422
 Tartaric acid, 419

- Tattoo marks, 990
- Tawara*, on abnormal chordæ tendinæ, ref., 525
- Tavel and Lanz*, on peritonitis, ref., 694
- Taylor*, on auto-intoxication, ref., 426; on fatty degeneration, ref., 40; on poisons, 426; on volvulus of Meckel's diverticulum, ref., 667
- Tchistovitch*, on crisis in pneumonia, ref., 606
- Tendeloo*, on retroperitoneal lymph-nodes, ref., 697
- Teratoids, 333
- Teratoma, ref, 345, 358
 of liver, 737
 muscle, 875
 ovary, 836
 pineal gland, 980
 scrotum, 855
 testicle, 863
 vagina, 797
 sacral, 333
- Terminal infection, 158
- Terry*, on chemical therapy in trypanosomiasis, ref., 118
- Testicle, 855
 abscess of, 857
 absence of, 855
 atrophy of, 857
 chorionepithelioma of, 822, 863
 cryptorchismus, 856
 cysts of, 861, 863
 epididymitis, 858
 examination, post-mortem, of, 1019
 hæmatocele, 857
 hydrocele, 856
 hypertrophy of, 62
 inflammation of (see Orchitis), 857
 leprosy of, 860
 malformations of, 855
 malpositions of, 856
 parasites of, 863
 regeneration of, 73
 spermatocele, 857
 syphilis of, 860
 teratoma of, 863
 tuberculosis of, 858
 tumors of, 860
 varicocele, 856
 weight of, 1019
- Tetano-toxin, 286, 287
- Tetanus, 286
 antitoxin, 165
 theory of, 165
 diagnosis of, 287
 in animals, 286
 lesions of, 286
- Tetany following removal of parathyroids, 514
- Tetrads, 135
- Texas fever, hæmatozoon of, 122
- Thacher*, on melanuria, 372
- Thayer*, on malarial nephritis, ref., 761; on venous thrombosis in typhoid fever, ref., 243
- Thayer and Hewetson*, on malaria, ref., 316
- Thionin stain, 1038
- Thoma*, on arterio-sclerosis, ref., 554, 565; on conditions of disease, ref., 14; on fissures in cervical region, ref., 647; on hypertrophy, ref., 747; on inflammation, ref., 110; on malformations, ref., 320; on waxy degeneration of muscle, ref., 872
- Thoma's frog plates*, 111
- Thomas and Hibbard*, on lesions of myocardium in diphtheria, ref., 283
- Thompson*, on parathyroids, ref., 514
- Thompson and Leighton*, on transplantation of parathyroids, ref., 515
- Thoracic duct, examination, post-mortem, of, 1018
 lesions of, 576
- Thoracopagus, 329
- Thorax, examination, post-mortem, of, 1001, 1024
- Thorel*, on experimental nephritis, ref., 769; on lesions of œsophagus, ref., 654; on lesions of salivary glands, ref., 700; on lesions of stomach, 666; on regeneration of kidney epithelium, ref., 748.
- Thorndike and Cunningham*, on hypernephroma, ref., 777
- Threadworm, 128
- Thrombi, 24
 agglutinative, 26
 in liver, 715
 alterations, in, 27
 arterial, 26
 canalized, 26
 causes of, 24
 degeneration of, 27
 forms of, 24, 26
 hyaline, 27, 48

- Trombi, infective, 26**
 marasmatic, of liver, 711
 marantic, 25
 micro-organisms in formation of,
 ref., 25
 mixed, 24
 obstructing, 26
 organization of, 27, 95
 parietal, 26
 primary, 26
 propagated, 26
 red, 24
 secondary, 26
 simple, 26
 softening of, 27
 solid, 26
 stagnation, 25
 venous, 26
 rôle of micro-organisms in, ref., 25
 white, 24
- Thromboarteritis, 559**
- Thrombokinase, 452**
- Thrombosis, 24**
 causes of, 24, 25
 effects of, 27
 of adrenals, 516
 brain, 940
 coronary arteries, 537
 dura mater cerebri, 908
 heart, 531
 kidney, 748
 liver, 711, 714, 715
 lung, 596
 lymph-vessels, 28, 576
 spinal cord, 942
 splenic vein, 503
 veins, 573
- Thrush, 147, 644**
- Thymus, 511**
 accessory, 511
 examination, post-mortem, of, 1025
 hæmorrhage in, 511
 hypertrophy of, 511
 inflammation of, 511
 in status lymphaticus, 440
 malformations of, 511
 new-born, size and weight of, 1025
 syphilis of, 511
 tuberculosis of, 511
 tumors of, 511
- Thyreolytic serum, 174**
- Thyroid, 512**
 accessory, 512
- Thyroid, degeneration of, 512**
 examination, post-mortem, of, 1010,
 1025
 extract in myxœdema, 430
 goitre, 513
 hyperæmia of, 512
 hyperplasia of, 513
 hypertrophy of, 62
 in Graves' disease, 432
 in myxœdema, 429
 inflammation of, 512
 malformations of, 512
 para-, 514
 parasites in, 514
 regeneration of, 72
 syphilis of, 512
 tissue in ovary, ref., 836
 transplantation of, ref., 78, 429
 tuberculosis of, 512
 tumors of, 514
 weight of, 1011, 1025
- Tic douloureux, 974**
- Tick fever, 293, 301**
 of cattle, hæmatozoon of, 122
- Tidy, on post-mortem examination, ref.,
 989**
- Tilger, on cysts of pancreas, ref., 707**
- Tinea circinata, 148**
- Tischner, on experimental closure of
 hepatic artery and gall-ducts, ref., 711**
- Tissue, calcification in, 51**
 changes, regressive, 35
 cicatricial, 93
 fixation of, 1029
 rapid, 1028
 fresh, method of staining, 1027
 frozen section of, 1028
 method of preparation and staining,
 980, 1027
 granulation, 92
 necrotic, disposal of, 59
 non-vascular, injury to, 82
 tension, 79
 transplantation of, 77
 vascular, injury to, 83
- Tongue, 645**
 absence of, 645
 cysts of, 646
 "furred," 646
 hypertrophy of, 646
 inflammation of, 646
 malformations of, 645
 tumors of, 646

- Tonsil, calculi of, ref., 649
 hypertrophy of, 649
 inflammation of, 649
 leptothrix in crypts of, 232
 portal of entry for tubercle bacilli,
 ref., 650
 tuberculosis of, ref., 650
 Tonsillitis, 649
 Tooth, on degeneration of spinal cord,
 954
 Tophi, 436
 Toxæmia, 153, 202
 Toxalbumins, 152
 Toxalbumose, 152
 Toxin, binding of, ref., 167
 diphtheria, 164
 fixing of, ref., 167
 molecule, character of, 167
 of Asiatic cholera, 250
 diphtheria, 285
 tetano-, 286, 287
 Toxins, 152
 action of, on neurones, 948
 bacterial, 139
 cellular, ref., 152
 hæmo-, 171
 Toxoids, ref., 167
 Toxophorous group, 167
 Trachea, 581
 amyloid masses in, 586
 death from pressure on, 592
 examination, post-mortem, of, 1011
 lesions of, 585
 malformations of, 581
 preservation of, 1011
 tumors of, 585
 Trachoma, 308
 bodies, 309
 granules, 309
 Tracy, on microchemical reactions for
 iron, ref., 53
 Transplantation of tissue, 77
 autoplastic, 78
 heteroplastic, 78
 Transudates, 23
 Transudation, 22
 Trauma, 11
 Trematoda, 123
Trepinski, on tabes dorsalis, 962
 Treponema pallidum, 119, 274
 demonstration of, 276
 India ink stain, 278
 staining methods, 277
 Treponema, pertenuis, 294
 Trichina spiralis, 129
 in lymph-nodes, 497
 muscle, 875
 examination of, 131
 Trichiniasis, 130
 Trichocephalus dispar, 129
 Trichomonas vaginalis, 120, 797
 Trichophyton tonsurans, 148
 Triplets, 327
 Trypanosomes, 117
 brucei, 117
 evansi, 117
 gambiense, 118
 lewisi, 117
 pathogenic, 117
 Trypanosomiasis, 117
 Tsetse-fly disease, 117
 Tubal pregnancy, 841
 Tubercle, 251
 bacillus (see *B. tuberculosis*), 251,
 257
 conglomerate, ref., 251
 development of, 254
 diffuse, 255
 foreign-body, 102
 forms of, 255
 granulum, ref., 251
 "healed," 622
 miliary, 251, 252, 621, 640
 polyhedral-celled, 255
 solitary, of liver, 733
 tissue, ref., 252
 Tuberculin, diagnostic use of, 261
 therapeutic use of, 262
 Tuberculosis, 251
 agglutination in, 261
 and cancer, ref., 267
 animal, 263
 autopsy findings in, ref., 263
 bacillus of, 251, 257
 bibliography of, 268
 bovine, infection of children with,
 ref., 266
 complex factors in, 262
 concurrent infection in, 266
 diffuse, 252, 255
 dust infection in, 265
 frequency of, 263
 immunity in, 262
 lesions of, 251
 "localized," 251
 lymphoid, 255

- Tuberculosis, miliary, generalized, 252**
 localized, 251
 necrosis, coagulation in, 254
 of adrenals, 516
 appendix vermiformis, 686
 arteries, 566
 bladder, urinary, 786
 bone, 882, 887
 brain, 974
 bronchi, 589, 591
 dura mater, *cerebralis*, 911
 spinalis, 922
 Fallopian tubes, 840
 heart, 542
 ileo-cæcal region, 682
 intestine, 673
 joints, 906
 kidney, 769
 larynx, 584
 liver, 731
 lungs, 618
 experimental, 631
 lymph-nodes, 486, 265
 lymph-vessels, 577
 mamma, 845
 mouth, 644
 muscle, 875
 nervous system, 911, 922, 923,
 974
 nose, 580
 œsophagus, 653
 ovary, 829
 pancreas, 706
 parotid, 700
 penis, 854
 pericardium, 521
 peritoneum, 695
 periosteum, 882
 pharynx, 649
 pia mater *cerebralis*, 918
 spinalis, 923
 pleura, 640
 prostate, 866
 seminal vesicles, 863
 skin, 267
 spinal cord, 974
 stomach, 659
 testicle, 858
 thymus, 511
 thyroid, 512
 urethra, 792
 uterus, 806
 vagina, 797
- Tuberculosis of veins, 575**
 predisposition in, *ref.*, 252
 pulmonary, 618
 and pigmentation, 641
 apex in, 631
 broncho-, 624
 cavities in, 626, 628
 classification of, 619
 complex forms of, 627
 concurrent infection in, 631
 diffuse, 627
 distribution, of lesions in, 630
 experimental, 631
 exudative, 627
 fibrous tissue formation in, 630
 flies, as carriers of, *ref.*, 151
 focal 619
 healing in, 630
 miliary, acute, 619
 chronic, 622
 modes of infection, in, 618, 620
 641
 secondary lesions in, 629
 statistics of, *ref.*, 263
 tuberculin, 261
- Tubes of Miescher, 121**
 Rainey, 121
- Tubo-abdominal pregnancy, 842**
- Tumors, 336**
 age as factor in growth of, 344
 anaplasia in, 351
 autonomy of, 337
 bacteria in, 347
 benign, 342
 bibliography of, 416
 biological origin of, 347, 350
 cachexia of, 343
 cell anarchy in, 337
 cell inclusions in, 347
 characters of, 336
 classification of, 357
 Lubarsch's, 359
 congenital, 358
 connective-tissue type of, 357
 degenerative processes in, 339
 diagnosis of, 343
 dissemination of, 341
 epithelial tissue type, 358
 etiology of, 344
 excitants of, 347
 intrinsic, 350
 extensions of, 340
 fixation of tissue, 362

- Tumors, heredity, bearing of, on, 344
 immunity, artificial, to, 355
 local predisponents to, 345
 malignancy of, 342
 malignant, 342
 metastasis of, 341, 350
 metastatic, 341
 micro-organisms as excitants of, 347
 mixed, of parotid gland, 700
 muscle tissue type, 357
 nature and characters of, 336
 occurrence and growth of, 344
 origin of, 344
 Cohnheim's hypothesis, 346, 351
 Ribbert's hypothesis, 351
 parasitic, 347
 protozoa in, 347
 seats of (see under various tissues and viscera, and types of tumors)
 serum injections in, 356
 sex factor in growth of, 344
 shape of, 340
 size of, 340
 splenic, 504
 technique of fixation of, 362
 tissue types in, 338
 transplantation of, 354
 trauma as factor in occurrence of, 345
 vascular tissue type, 358
 yeasts in, 349
- Tunnidiff*, on Vincent's angina, ref., 293
Türk, on "irritation forms" of leucocytes 462; on leucocytosis, 464
Turner, on sarcoma of pia mater and spinal cord, ref., 977; on tumor of pineal gland, 980
 Turpentine poisoning, 422
Tuttle, on streptothrix pneumonia, ref., 232
 Twins, 327
 Typhoid carriers, 245
 fever, 234
 bacillus of, 235
 bibliography of, 247
 blood in, 463
 experimental, 235
 flies as carriers of, ref., 151, 245
 immunity to, 245
 lesions of, 235
 appendix vermiformis in, 685
 Typhoid fever, lesions of, circulatory organs in, 242
 digestive organs in, 242
 genito-urinary organs in, 243
 intestines in, 235
 liver in, 241
 lymph-nodes, mesenteric, in, 240
 lymph-nodules in, 235
 nervous system in, 243
 Peyer's patches in, 235
 respiratory organs in, 243
 spleen in, 240
 mixed infections in, 244
 para-, 247
 preventive inoculations in, 245
 secondary lesions in, 242
 septicæmic forms of, 243
 toxæmia in, 241
 ulceration of intestine in, 237
 meningitis, ref., 243
 Typhus fever, 300
 Mexican, 300
 lice as agents of infection in, 301
 mouse, bacillus of, 289
 recurrens, 292
Tyzzar, on *Coccidium oviforme*, ref., 121
Uffenheimer, on permeability, of intestine wall for bacteria, ref., 681
Uhlenhuth and Weidanz, on precipitin tests, ref., 182
 Ulceration, 58
 of intestine in typhoid fever, 237
 Ulcers, 58
 of intestine, 674, 675, 681, 682
 mamma, 846
 mouth, 644
 œsophagus, 651
 penis, 854
 stomach, 660
 urethra, 792
 phagedenic, of uterus, 803
Ullmann, on tonsils, ref., 650
Ulrich, on lipoma of kidney, ref., 776
 Umbilicus, tumors of, 699
Uncinaria americana, 128
 duodenalis, 128
Uncinariasis, 129
 Unna's glycerin-ether mixture, 278

- Unna's polychrome methylene-blue stain, 1037
- Urachus, malformations of, 782
- Ureter, carcinoma of, ref., 788
 cysts of, 774
 inflammation of, 771
 malformations of, 746
- Urethra, cysts of, 792
 dilatation of, 790
 examination, post-mortem, of, 1018
 gonorrhœa of, 792
 hæmorrhoids of, 792
 inflammation of (see Urethritis), 791
 malformations of, 790
 malpositions of, 790
 perforations of, 792
 polyps of, 792
 prolapse of, 791
 rupture of, 791
 strictures of, 790
 syphilis of, 792
 tuberculosis of, 792
 tumors of, 792
 wounds of, 791
- Urethritis, catarrhal, 791
 chronic, 792
 croupous, 792
 syphilitic, 792
 tuberculous, 792
- Urinary organs, 746
- Urine, typhoid bacilli in, 244, 245
- Uterus, 797
 absence of, 797
 atrophy of, 803
 bacteria in, ref., 804, 809
 bicornis, 798
 chorionepithelioma of, 820
 chorionic villi, 820
 cysts of, 822
 degenerations of, 803
 dilatation of, 799
 displacements of, 800
 double, 798
 elevation of, 801
 enlargement of, 799
 examination, post-mortem of, 1019, 1026
 flexions of, 800
 hæmatocele, 803
 hæmatoma, polypoid, of, 803
 hæmatometra, 800
 hæmorrhage of, 802
 hernia of, 802
- Uterus, hour-glass, 799
 hydrometra, 799
 hyperæmia of, 802
 hyperplasia of mucous membrane, glandular, 805
 infantile, 1020
 inflammation of (see Endometritis and Metritis), 804, 807
 inversion of, 802
 Langhans' cells, 820
 malformations of, 797
 malpositions of, 800
 parasites of, 822
 perforation of, 802
 placenta, lesions of, 822
 polyps of, 803, 810
 position of, 1019
 pregnant, inflammation of, 808
 prolapse of, 801
 rupture of, 802
 size of, 1020
 changes in, 798
 syncytium, 820
 syphilis of, 807
 tuberculosis of, 806
 tumors of, 809
 ulcer, corroding, of, 803
 versions of, 800
 weight of, 1020
- Vaccination, 304
- Vaccine bodies, 305
- Vaccines, bacterial, 186
 in acute lobar pneumonia, 220
 pneumococcal, 220
- Vaccinia, 304
- Vacuole, 45
- Vacuolization, 45
- Vagina, 795
 absence of, 795
 bacteria in, 79; ref., 804
 closure of, 795
 cystocele, 795
 cysts of, 797
 dilatation of, 795
 double, 795
 examination, post-mortem, of, 1019
 fistulæ of, 796
 gangrene of, 797
 hernia of, 795
 inflammation of (see Vaginitis), 796
 lengthening of, 795
 malformations of, 795


- Vagina, malpositions of, 795
 narrowing of, 795
 parasites in, 797
 perforation of, 796
 prolapse of, 795
 syphilis of, 797
 tuberculosis of, 797
 tumors of, 797
 wounds of, 796
- Vaginitis, 796
 catarrhal, 796
 gangrenous, 797
 suppurative, 797
 syphilitic, 797
 tuberculous, 797
- Valsalva, sinus of, aneurism of, 530
- Van Gehuchten*, on nervous system, ref., 942
- Van Gieson*, on artefacts of nervous system, ref., 928; on death from electric currents, ref., 11; on hæmatomyelopore, ref., 939; on post-mortem examination of brain, ref., 998; on sunstroke, 437
- Van Gieson's* picro-acid-fuchsin stain, 1036
 stain for Negri bodies, ref., 297
- Varices, œsophageal, 651
- Variococele, 856
- Variola, 303
- Varix aneurismal, 569
 lymphatic, filarial, ref., 131, 576
- Vaughan*, on alkaloidal poisons, ref., 426;
 on spread of typhoid, ref., 245
- Vaughan and Novy* on cellular toxins, ref., 152
- Vaughan and Wheeler*, on anaphylaxis, 191
- de Vecchi*, on tuberculosis of adrenals, ref., 434
- Vein stones, 27
- Veins, 572
 anastomosis of, 18
 calcification of, 573
 degeneration of, 573
 dilatation of, 572
 about umbilicus, in cirrhosis, 728
 hepatic lesions of, 714
 inflammation of (see Phlebitis), 573
 obstruction of, 18
 parasites of, 575
 perforation of, 573
 portal lesions of, 711
- Veins, rupture of, 573
 syphilis of, 575
 thrombosis of, 573
 tuberculosis of, 575
 tumors of, 575
 umbilical, lesions of, 712
 varicose, in labia, 793
 wounds of, 573
- Veit*, on chorionic cells, ref., 821
- Vena cava, thrombosis of, 573
- Venom, animal, 153, 424
- Ventricles of brain, lesions of, 924, 925
 tumors of, 927
- Veratria poisoning, 422
- Vibrio cholerae asiaticæ*, 247, 249
 Massawah, 251
 Metschnikovi, 251
 proteus, 250
- Vierordt*, on weight of viscera, etc., ref., 990
- Vincent*, on angina, ref., 293
- Vincent's* angina, 293
- Virchow*, on tumors, 416
- Virus, fixed, 295, 297
 of hydrophobia, 295
- Viscera, changes in, following extensive burns, ref., 10
 weight of, ref., 990
- Vogel*, on accessory lung, ref., 593
- Volkman*, on mixed tumors of salivary glands, ref., 701
- Voluntary muscle, 868
- Volvulus of intestine, 668
 Meckel's diverticulum, ref., 667
- Von Hibler*, on gonococcus, ref., 223
- Von Jaksch anæmia, 479
- von Volkman*, on endothelioma, ref., 380
- Vulva, 793
 condyloma of, 794
 cysts of, 795
 elephantiasis of, 794
 erysipelas of, 794
 examination, post-mortem, of, 1019
 gangrene of, 794
 hæmorrhage of, 793
 hyperæmia of, 793
 inflammation of, 793
 malformations of, 793
 noma of, 794
 œdema of, 793
 syphilis of, 794
 tuberculosis of, 794
 tumors of, 794

- Vulva, varicose veins in, 793
 Vulvitis, 793
- Wachenheim*, on pyloric stenosis, ref., 655
Wadsworth, on experimental pneumonia, 218; ref., 614; on mouth disinfection, ref., 219; on puerperal infection, ref., 809; on staining *D. pneumoniae*, ref., 218; on staining encapsulated pneumococci, ref., 220
Wagener, on intestinal tuberculosis, ref., 674
Walker, on renal tuberculosis, ref., 770
Waller, law of, 947
Ward, on influence of parasites on host, ref., 123; on thyroid and pregnancy, ref., 512
Warfield, on carcinoma of male breast, ref., 867; on meningococcus endocarditis, ref., 545
Warrington, on structural alterations in nerve cells, 948
Warthin, on accessory adrenals, ref., 515; on carcinoma of gall-ducts, ref., 743; on emboli, 29; on hæmolymp-nodes, ref., 497; on multiple carcinoma, ref., 404; on pancreas, ref., 706
Warthin and Cowie, on placental and congenital tuberculosis, ref., 265
Waschkevisch, on lesions of diphtheria, ref., 282
Washbourn, on infective endocarditis, ref., 545
Wasielewski, on vaccine bodies, ref., 305
Wassermann, on congenital transmission of infectious agents, ref., 151; on mixed infections, ref., 157; on nature of infection, ref., 156; on serum therapy in meningitis, ref., 226; reaction in syphilis, 278
Watters, on preparation of museum specimens, ref., 1038
Wätzold, on adenoma of liver, ref., 736
Weaver, on agglutination of streptococci, ref., 210; on anaphylaxis, ref., 190
Weber, on changes in the blood ref., 456
Wechsberg, on action of tubercle bacillus, ref., 253
Weichselbaum, on *D. pneumoniae*, ref., 221
Weichselbaum and Ghon, on meningococcus, ref., 225
Weidenreich, on fixation of blood, ref., 467; on lymph-nodes, ref., 73; on lymph-nodes, ref., 481
Weigert, on immunity, 196; on origin of tumors, ref., 351; on tumor of hypophysis cerebri, 980; on tumor of pineal gland, 980
Weigert's stain for bacteria, 144
 stain for nerve tissue, 981
Weinberg, on tuberculosis and cancer, ref., 267
Weir, on duodenal ulcers, 675
Weiss, on bacteria in stomach, ref., 659; on intestinal bacteria, ref., 681
Welch, on adaptation in pathological processes, ref., 110; on agglutinative thrombi, ref., 27; on *B. aerogenes capsulatus*, 289, 290; on bacteria of body surfaces, ref., 150; on cardiac hypertrophy, ref., 550; on carcinoma of stomach, 664; on cirrhosis hepatic anthracotica, ref., 730; on fat embolism, ref., 469; on gastric ulcer, 660; on infective thrombi, ref., 25; on immunity, 196; on pulmonary œdema, ref., 595; on staining *D. pneumoniae*, 220; on thrombosis and embolism, ref., 28; on venous thrombosis, ref., 573
Weleminosky, on bronchial lymph-nodes, ref., 592
Welker, on technique of opsonic work, ref., 188
Wells, on autolysis, ref., 60; on calcification, ref., 52; on chemical pathology, ref., 426; on fat necrosis of pancreas, ref., 704; on infarcts, ref., 30; on proteolytic enzymes, ref., 103
Wells and Scott, on paratyphoid, ref., 247
Werigo, on disposal of bacteria in blood, ref., 151
Westenhoeffer, on cerebro-spinal meningitis, ref., 225; on mode of infection by *B. tuberculosis*, ref., 264; on plethora, ref., 455
Wharton's duct, dilatation of, 700
Wheeler, on viability of typhoid bacillus, ref., 245
Whipham, on carcinoma of appendix vermiformis, ref., 690; on mediastinitis, ref., 636
Whipple, on intestinal lesions in typhoid fever, ref., 240; on nodular colitis, ref., 680

- Whipple and Sperry*, on chloroform liver necroses, 716
- Whipworm, 129
- White*, on blood in septicæmia, ref., 205; on *S. pyogenes aureus* in skin lesions, ref., 208; on toxæmia of pregnancy, ref., 718
- "White swelling," 25
- Whooping-cough, 317
- Wichmann*, on amyloid degeneration ref., 50
- Wiener*, on melano-sarcoma of rectum, ref., 690
- Wiesel*, on arterio-sclerosis, ref., 564; on lesions of coronary arteries, ref., 537
- Wiesner*, on lesions of coronary arteries, ref., 537
- Wilder*, on sarcoma of bladder, ref., 786
- Williams*, on *B. diphtheriæ*, ref., 284; on bacteriology of vagina, ref., 804; on placental infarcts, ref., 823; on plasma cells, ref., 74; on sarcoma of pericardium, ref., 522
- Williams and Louden*, on parasites of scarlatina, ref., 307; on staining Negri bodies, 296
- Willis, circle of, 933
- Wilms*, on teratoma of ovary, ref., 837; on teratoma of testicle, ref., 863
- Wilson*, on cell development, ref., 68; on mitosis, ref., 67
- Wilson and Chowning*, on infective agent in Rocky Mountain fever, 301
- Wilson and Kalteyer*, on melano-sarcoma of skin, ref., 372
- Winkler*, on tuberculosis in children, ref., 263
- Wille*, on perforation of aorta, ref., 557
- Wladimiroff*, on characters of glanders bacillus, ref., 227; on relapsing fever, ref., 293
- Wolbach*, on lesions in x-ray examinations, ref., 11; on rhabdomyoma of heart, ref., 556
- Wolbach and Ernst*, on bovine tubercle bacillus, ref., 260
- Wolf*, on opsonic power of blood in pneumonia, 220
- Wollstein*, on agglutination with bacilli from whooping-cough, ref., 317, 318; on *B. influenzae*, ref., 234; on tuberculosis in children, ref., 265
- Wood, F. C.*, on blood, ref., 470; on *D. pneumoniæ*, ref., 219; on stain for blood, 317; on viability of *D. pneumoniæ*, 218; on tumors of salivary glands, ref., 380
- Wood, G. B.*, on faucial tonsils, ref., 649; on tonsils as portals of entry for tubercle bacilli, ref., 650; on tuberculosis of parotid, ref., 700
- Woodman and Tidy*, on poisons, 426
- Wool sorter's disease, 228
- Wormley*, on poisons, 426
- Worms, 123
 - guinea, 130
 - method of study of, 131
 - pin, 128
 - round, 127
 - tape, 124
 - thread, 128
 - whip, 129
- Wounds, granulation tissue in, significance of, ref., 152
 - healing of, 91
 - post-mortem, appearance of, 990
- Wright blood stain, 468
 - method of collecting serum, 195
- Wright, A.*, on opsonins, ref., 187; on preventive inoculation in typhoid fever, ref., 24 6
- Wright, J. H.*, on absorption in tonsils, ref., 649; on actinomyces-like structures in tonsillar crypts, ref., 649; on biology of actinomyces, ref., 232; on blood plates, 466; on Madura foot, ref., 232; on multiple myeloma, ref., 902; on nasal polyps, ref., 580
- Wright and Douglas*, on opsonins, 183
- Writer's cramp, 950
- Wrzosek*, on infection, ref., 151
- Xerosis bacillus, 285
- Xiphopagus, 329
- X-rays, lesions from, 11
- Yaws, 293
- Yeasts, 133, 146
 - in fermentation, 146
 - tumors, 349
 - methods of study of, 149
- Yellow fever, 302
 - excitant of, 302
 - lesions of, 302
 - mode of infection in, 302

- Yellow fever, mosquitoes and, 303
Yersin's anti-plague serum, 289
Young, on gonorrhœa, ref., 221; on nerves in tumors, ref., 338
Zahn, on ciliated cysts of pleura, ref., 642; on cysts, ref., 361; on statistics of intestinal tuberculosis, ref., 674; on stenosis of œsophagus, ref., 652; on tumors of mediastinum, ref., 636
Zenker's degeneration of muscle, ref., 872 fluid, 1030
Ziegler, on lesions of bones and joints, ref., 907; on tumors, 416
Zinsser, on leucocyte extract, ref., 189
Zooglœa, ref., 135
Zuber, on bronchial lymph-nodes, ref., 592
Zuntz, Löwy, Muller, and Caspari, on polycythæmia, ref., 455





COUNTWAY LIBRARY



HC 2M6P +

